



UNIVERSITÀ
DEGLI STUDI
FIRENZE

FLORE

Repository istituzionale dell'Università degli Studi di Firenze

Interstitial pregnancy treated with a single-dose of systemic methotrexate: A successful management

Questa è la Versione finale referata (Post print/Accepted manuscript) della seguente pubblicazione:

Original Citation:

Interstitial pregnancy treated with a single-dose of systemic methotrexate: A successful management / Corioni, Serena; Perelli, Federica; Bianchi, Claudia; Cozzolino, Mauro; Maggio, Luana; Masini, Giulia; Coccia, Maria Elisabetta. - In: JOURNAL OF RESEARCH IN MEDICAL SCIENCES. - ISSN 1735-1995. - ELETTRONICO. - 20:(2015), pp. 312-316.

Availability:

The webpage <https://hdl.handle.net/2158/1009558> of the repository was last updated on 2015-10-30T15:50:14Z

Terms of use:

Open Access

La pubblicazione è resa disponibile sotto le norme e i termini della licenza di deposito, secondo quanto stabilito dalla Policy per l'accesso aperto dell'Università degli Studi di Firenze (<https://www.sba.unifi.it/upload/policy-oa-2016-1.pdf>)

Publisher copyright claim:

La data sopra indicata si riferisce all'ultimo aggiornamento della scheda del Repository FloRe - The above-mentioned date refers to the last update of the record in the Institutional Repository FloRe

(Article begins on next page)

J Res Med Sci. 2015 Mar; 20(3): 312–316.

PMCID: PMC4468238

PMID: [26109980](#)

Interstitial pregnancy treated with a single-dose of systemic methotrexate: A successful management

[Serena Corioni](#), [Federica Perelli](#), [Claudia Bianchi](#), [Mauro Cozzolino](#), [Luana Maggio](#), [Giulia Masini](#), and [Maria Elisabetta Coccia](#)

Department of Maternal and Child Health, Careggi University Hospital, University of Florence, Largo Brambilla 3, 50100 Florence, Italy

Address for correspondence: Dr. Serena Corioni, Department of Maternal and Child, Azienda Ospedaliero-Universitaria Careggi, University of Florence, Largo Brambilla 3, 50100 Florence, Italy. E-mail: ti.liamtoh@yn.eres

Received 2014 May 4; Revised 2014 Sep 25; Accepted 2015 Jan 29.

Copyright : © Journal of Research in Medical Sciences

This is an open-access article distributed under the terms of the Creative Commons Attribution-Noncommercial-Share Alike 3.0 Unported, which permits unrestricted use, distribution, and reproduction in any medium, provided the original work is properly cited.

Abstract

Interstitial pregnancy is an ectopic pregnancy at high hemorrhagic risk. It often poses a diagnostic and therapeutic challenge to the clinician, with a significant risk of morbidity and mortality. It presents a difficult management problem with no absolute standard of care; the most appropriate treatment technique for these pregnancies remains controversial. We describe a case of unruptured interstitial pregnancy successfully treated with a single-dose of systemic methotrexate with subsequent ultrasound and serum beta human chorionic gonadotropin monitoring. Medical management can be a safe and successful option in selected cases that satisfy specific criteria and in women who are able to be monitored after treatment.

Keywords: Ectopic pregnancy, human chorionic gonadotropin monitoring, interstitial pregnancy, medical management, medical treatment, methotrexate, noninvasive treatment, ultrasound monitoring

INTRODUCTION

Interstitial pregnancy refers to an ectopic pregnancy (EP) that is implanted in the interstitial portion of the fallopian tube.[\[1,2\]](#)

It represents almost 2-4% of all ectopic pregnancies, but its incidence is unclear and is increasing because of the large use of assisted reproductive techniques in recent years. Other risk factors

include pelvic inflammatory disease, previous ipsilateral or bilateral salpingectomy, previous EP, previous tubal sterilization, uterine anomalies and a history of sexually transmitted infections.[1,3]

Diagnosis can be delayed due to the difficulty of distinguishing an interstitial pregnancy from an intrauterine pregnancy (in particular an angular pregnancy) in the early ultrasound (US) scanning.[4,5]

The mortality rate is as high as 2.5% (7 times higher than that of ectopic pregnancies in general). Thus, early detection and a high index of suspicion are crucial to reduce morbidity and mortality.[1]

Interstitial pregnancies present a difficult management problem with no absolute standard of care; several treatments are proposed, both medical and surgical, but the most appropriate technique for the treatment of these pregnancies remains controversial.[1,5]

In this report, we describe a case of unruptured interstitial pregnancy successfully treated with a single-dose of systemic methotrexate with subsequent US and serum beta human chorionic gonadotropin (b-hCG) monitoring.

CASE REPORT

A 36-year-old Chinese woman, gravida 2 para 1, was admitted in 2013 to our tertiary center (Careggi University Hospital, Florence, Italy) at 6 ± 4 weeks of amenorrhea for a suspicion of EP.

She was affected by essential hypertension in therapy with nifedipine given orally at a dose of 30 mg once daily. Her obstetric history included a normal vaginal delivery at 16 years old. At 17-year-old she underwent a tubal ligation with clip method in China because she didn't desire any other children in that period; 2 years before admission she decided to remove it.

Her general conditions were stable, and she did not refer any abdominal-pelvic symptom. The abdominal and vaginal examination did not reveal the pain. A mild vaginal bleeding was noted.

At the time of admission, serum level of hCG was 8681 IU/L and hemoglobin was 13.6 g/dL. Transvaginal US revealed an empty uterus with two anterior fibroids of <2 cm. In the left uterine horn, a mass of 37 mm \times 34 mm with a hypoechoic central area was present without sign of the fetal pole. The color Doppler showed the presence of a vascular ring, which proved an intense peripheral vascularization. Adnexa appeared normal; a corpus luteum was present in the right ovary. No free fluid was noted in Douglas pouch [Figure 1].

All blood tests were analyzed in the same laboratory (Careggi University Hospital, Florence, Italy) and all the transvaginal US were performed by the same person.

Considering the serum level of hCG (<10,000 IU/L), the patient's stable hemodynamic state, the size of the mass (diameter <4 cm), the absence of abdominal free fluid and the absence of hepatic, renal and hematological impairment, according with the patient we decided for conservative management and we performed medical therapy with methotrexate (a single-dose of intramuscular methotrexate 1 mg/kg, according to the protocol of our center, prepared by the centralized unit for cytotoxic drug preparations of Careggi University Hospital). She didn't have any side effects after treatment.

At follow-up US 6 days after treatment the mass reached a size of 46 mm \times 37 mm and didn't present a recognizable cleavage plane with the myometrium.

The patient was hospitalized for 11 days after treatment and remained asymptomatic throughout the hospital stay. This prolonged hospitalization was linked to the suspicion of poor compliance of the patient and to the need for accurate monitoring during the 1st days after this kind of treatment. The serum level of hCG decreased to 1570 IU/L on the day of discharge. The US check at discharge revealed two necrosis areas inside the mass and a reduction of peripheral vascularization [[Figure 2](#)].

The hCG level became negative 2 months later [[Table 1](#)].

The patient continued to be followed at the US center with transvaginal US performed every 2 weeks for the first 3 months and then monthly for further 3 months by the same operator that had performed US during hospitalization. She remained asymptomatic during the entire period of follow-up. At follow-up US 3 months after discharge the size of the mass in the left uterine horn was reduced to 32 mm × 27 mm with the persistence of a minimal vascularization. The US check performed 6 months after discharge showed an important reduction of the mass (19 mm × 16 mm) with the absence of vascularization [[Figure 3](#)]. We suggested the patient not to become pregnant for further 6 months after the period of follow-up.

The patient came to our center for routine gynecological visit in view of a future pregnancy about 1-year after treatment. The US check showed the complete resolution of the mass, so she could try to have a new pregnancy.

DISCUSSION

Interstitial pregnancy is an EP at high hemorrhagic risk, due to the rich vascular pattern of the interstitial portion of the fallopian tube supplied by ovarian and uterine arteries. [[6](#)]

Even if its prevalence is uncertain, due to a difficult differential diagnosis with angular pregnancies, an interstitial pregnancy should be considered in case of presence of risk factors for this disease: In our case, the patient had a previous tubal sterilization that is a high risk condition.

It's important to consider that trophoblastic tissue produces b-hCG almost 8 days after conception, with a normal doubling period of approximately 48 h, and an intrauterine sac should be viewed with US when b-hCG are equal or more than 1000 IU/L. When an interstitial pregnancy is suspected, on the basis of clinical signs or the presence of risk factors, a US exam should be performed as soon as possible. Several US features allow an early diagnosis such as an eccentric gestational sac surrounded by asymmetric and thin (<5 mm) myometrial layer, an empty uterine cavity and a thin echogenic line (“interstitial line sign”) that originates from the endometrium and carries on the edge of the bulking interstitial mass. [[7,8](#)]

In case of uncertain diagnosis three-dimensional US or magnetic resonance imaging can be performed but for our patient the diagnosis was clearly identified using transvaginal US; the US evaluation, performed by an expert staff, showed the typical features of interstitial pregnancies [[Figure 1](#)]. [[9](#)]

Differential diagnosis with an angular pregnancy is a critical aspect. While an interstitial pregnancy is implanted in the uterine portion of the tube, angular pregnancy is an intrauterine pregnancy located near the utero-tubal junction.

These two ectopic pregnancies cause a different uterine distortion: Usually the angular pregnancy leads to a bulge medial to the round ligament, and the interstitial one determines a lateral bulge.

Ultrasound differential diagnosis is based on the features of the myometrium adjacent to the gestational sac. Myometrium is thicker in angular pregnancies and surrounds all sides of the sac while in interstitial pregnancies it is present only in the supero-lateral portion of the sac. This feature was visible in our US exam [[Figure 1](#)].

The most common symptom of EP is vaginal bleeding associated with pain and lower abdominal cramps. Women with interstitial pregnancy could remain asymptomatic for several weeks because the interstitial portion of the tube can expand a lot before rupture, more than other tubal segments.

In the present patient, however, vaginal bleeding was an early symptom since it appeared before 7 weeks of amenorrhea, even if it was minimal at examination.

Traditional treatment for interstitial pregnancy consisted of cornual wedge resection or hysterectomy via laparotomy. This kind of surgery was considerably invasive and associated with high morbidity and negative effects on future woman fertility.[[4,5](#)]

More recently, less invasive laparoscopic techniques have developed. Laparoscopic cornual resection is well-described in literature, it is generally an effective and quite safe procedure if performed by an expert surgeon, but it could be complicated by important bleeding; additionally, surgery leaves a scar in an already weakened uterine wall and subsequently women are advised that future pregnancies should be delivered by elective caesarean section to avoid the risk of uterine rupture.[[1,4,5](#)]

The development of high-resolution US evaluation and rapid quantitative b-hCG assays has allowed the early detection of interstitial pregnancy, before the rupture, which has made possible a conservative, noninvasive treatment, represented by medical treatment.[[1,5,10](#)]

Medical management with methotrexate has been used as first-line treatment in appropriate cases. It has strict inclusion criteria (early gestation, diameter <4 cm, b-hCG <10,000 IU/L, no evidence of rupture) and success rates vary widely. This conservative treatment can be a successful option in cases that satisfy these criteria and in women who are able to be monitored for a quite long time after treatment and treated further if required.[[5,10](#)]

In the present case, all treatment options were considered, both conservative treatments (expectant management, systemic methotrexate, local injection of methotrexate or potassium chloride, selective uterine artery embolization) and surgical treatments (laparoscopic cornual resection, mini-cornual excision, cornuostomy, salpingotomy, transcervical suction evacuation, cornual wedge resection, hysterectomy).[[1](#)] The choice was depended on the gestational age at diagnosis, the clinical features and the patient's desire for future fertility. Since the diagnosis was early and made before rupture, a nonsurgical treatment option was chosen in order to avoid the uterine scar caused by surgical intervention and to give the patient the chance of a future vaginal delivery. In addition, the avoidance of anesthesia, necessary for a surgical strategy, would result in less morbidity for the patient.

It was decided for systemic methotrexate, a folic acid antagonist that inactivates dihydrofolate reductase resulting in depletion of nucleic acid synthesis.

The single-dose protocol was chosen, because it requires a shorter treatment with the use of a lower dose of the drug, and it results in fewer side effects while maintaining an efficacy equal to that of multiple-dose regimes. Our patient underwent an intramuscular single injection of methotrexate at a dose of 1 mg/Kg although several therapeutic regimes are described in the literature.

Main side effects linked to methotrexate administration, such as tubal rupture or hemoperitoneum, were evaluated and an intensive follow-up was conducted for the early detection of pregnancy persistence and possible complications[11] with both serial measurements of serum hCG and transvaginal US performed by an expert operator.

Human chorionic gonadotropin-value curves are used for monitoring patients treated conservatively and they are considered as an accurate marker for the identification of success or failure of the procedure.[12]

Human chorionic gonadotropin levels after methotrexate show a high variability and a rapid increase in hCG values is not strictly predictive of unsuccessful treatment since it occurs in a certain percentage of cases undergoing the resolution.[12]

As the French study of Bottin *et al.* showed, in our patient a 20% of decrease in hCG values between day 1 and day 4 after treatment seemed to be a predictive positive factor[13] [Table 1].

In conclusion, the early detection of interstitial EP with transvaginal US and sensitive serum b-hCG assays is the key for a successful management because it allows conservative methods instead of conventional surgical management, reducing the potential consequences on morbidity and subsequent fertility.[14]

Our case report confirmed the evidences of other studies, showing that invasive treatment should not be the first-line management of interstitial pregnancy in hemodynamically stable patients and that single-dose of systemic methotrexate may be a safe, effective and successful option in women who satisfy specific criteria.

AUTHOR'S CONTRIBUTION

SC contributed in the conception of the work, in the acquisition, analysis, and interpretation of data for the work, conducting the study, revising the draft, approval of the final version of the manuscript, and agreed for all aspects of the work. FP contributed in the conception of the work, in the acquisition, analysis, and interpretation of data for the work and agreed for all aspects of the work. CB contributed in the conception of the work, conducting the study, revising the draft, approval of the final version of the manuscript, and agreed for all aspects of the work. MC contributed in the conception of the work, revising the draft, approval of the final version of the manuscript, and agreed for all aspects of the work. LM contributed in the conception of the work, in the acquisition, analysis, and interpretation of data for the work and agreed for all aspects of the work. GM contributed in the design of the work, revising the draft, approval of the final version of the manuscript, and agreed for all aspects of the work. MEC contributed in the conception and design of the work, revising the draft, approval of the final version of the manuscript, and agreed for all aspects of the work.

Footnotes

Source of Support: Nil

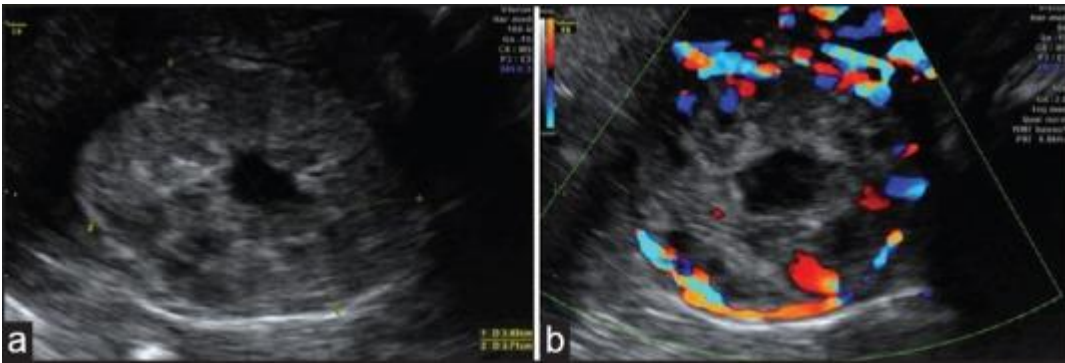
Conflict of Interest: None declared.

REFERENCES

1. Moawad NS, Mahajan ST, Moniz MH, Taylor SE, Hurd WW. Current diagnosis and treatment of interstitial pregnancy. *Am J Obstet Gynecol.* 2010;202:15–29. [PubMed: 20096253]
2. Pan J, Qian Y, Wang J. Bilateral interstitial pregnancy after *in vitro* fertilization and embryo transfer with bilateral fallopian tube resection detected by transvaginal sonography. *J Ultrasound Med.* 2010;29:1829–32. [PubMed: 21098855]
3. Choi YS, Eun DS, Choi J, Shin KS, Choi JH, Park HD. Laparoscopic cornuotomy using a temporary tourniquet suture and diluted vasopressin injection in interstitial pregnancy. *Fertil Steril.* 2009;91:1933–7. [PubMed: 18394611]
4. Moawad NS, Dayaratna S, Mahajan ST. Mini-cornual excision: A simple stepwise laparoscopic technique for the treatment of cornual pregnancy. *JSLs.* 2009;13:87–91. [PMCID: PMC3015918] [PubMed: 19366550]
5. Wright SD, Busbridge RC, Gard GB. A conservative and fertility preserving treatment for interstitial ectopic pregnancy. *Aust N Z J Obstet Gynaecol.* 2013;53:211–3. [PubMed: 23577788]
6. Zalel Y, Caspi B, Insler V. Expectant management of interstitial pregnancy. *Ultrasound Obstet Gynecol.* 1994;4:238–40. [PubMed: 12797190]
7. Timor-Tritsch IE, Monteagudo A, Matera C, Veit CR. Sonographic evolution of cornual pregnancies treated without surgery. *Obstet Gynecol.* 1992;79:1044–9. [PubMed: 1579304]
8. Ackerman TE, Levi CS, Dashefsky SM, Holt SC, Lindsay DJ. Interstitial line: Sonographic finding in interstitial (cornual) ectopic pregnancy. *Radiology.* 1993;189:83–7. [PubMed: 8372223]
9. Araujo Júnior E, Zanforlin Filho SM, Pires CR, Guimarães Filho HA, Massaguer AA, Nardoza LM, et al. Three-dimensional transvaginal sonographic diagnosis of early and asymptomatic interstitial pregnancy. *Arch Gynecol Obstet.* 2007;275:207–10. [PubMed: 16924515]
10. Gómez García MT, Aguarón Benitez G, Barberá Belda B, Callejón Rodríguez C, González Merlo G. Medical therapy (methotrexate and mifepristone) alone or in combination with another type of therapy for the management of cervical or interstitial ectopic pregnancy. *Eur J Obstet Gynecol Reprod Biol.* 2012;165:77–81. [PubMed: 22771188]
11. Natale A, Candiani M, Barbieri M, Calia C, Odorizzi MP, Busacca M. Pre-and post-treatment patterns of human chorionic gonadotropin for early detection of persistence after a single dose of methotrexate for ectopic pregnancy. *Eur J Obstet Gynecol Reprod Biol.* 2004;117:87–92. [PubMed: 15474251]
12. Natale A, Busacca M, Candiani M, Gruff L, Izzo S, Felicetta I, et al. Human chorionic gonadotropin patterns after a single dose of methotrexate for ectopic pregnancy. *Eur J Obstet Gynecol Reprod Biol.* 2002;100:227–30. [PubMed: 11750970]
13. Bottin P, Gnisci A, Crochet P, Butzbach P, Cravello L, Gamberre M, et al. Prognostic value of early hCG changes after methotrexate injection for ectopic pregnancy. *Gynecol Obstet Fertil.* 2014;42:3–7. [PubMed: 24309031]
14. Jermy K, Thomas J, Doo A, Bourne T. The conservative management of interstitial pregnancy. *BJOG.* 2004;111:1283–8. [PubMed: 15521876]

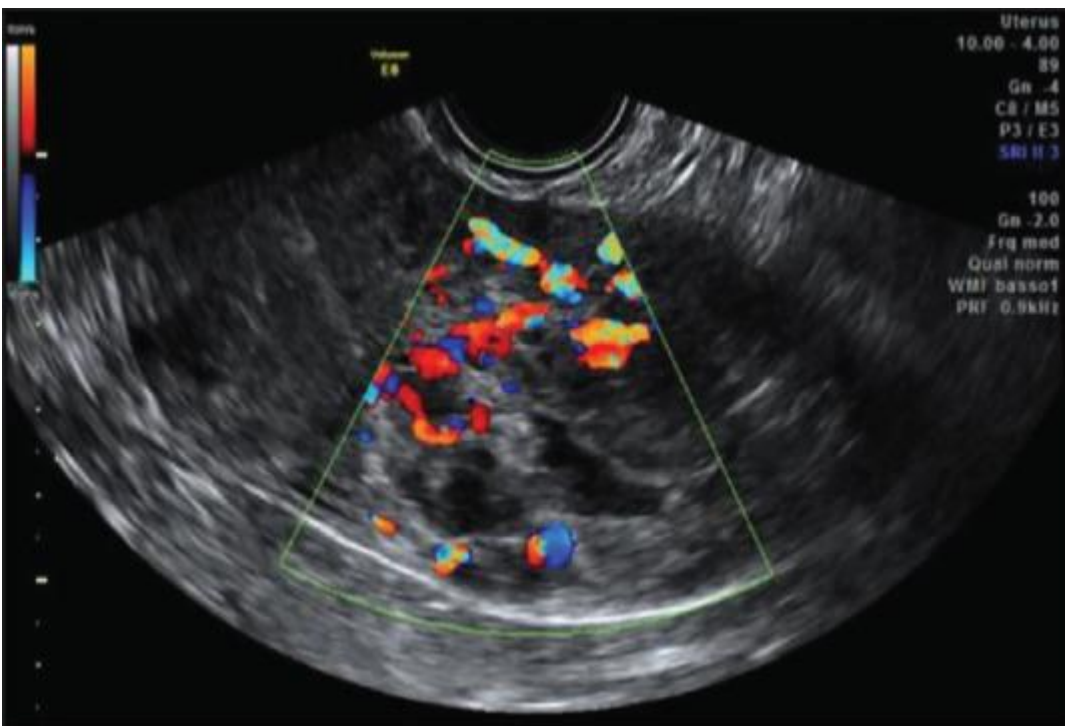
Figures and Tables

Figure 1



mass in the left uterine horn at patient admission with (a) and without (b) color Doppler

Figure 2



mass in the left uterine horn after treatment at patient discharge (in the context of the mass two areas of necrosis are visible)

Table 1

Human chorionic gonadotropin (hCG) values curve during 65 days after medical treatment (the serum level of hCG was analyzed in the same laboratory during hospitalization and during follow-up after the discharge)

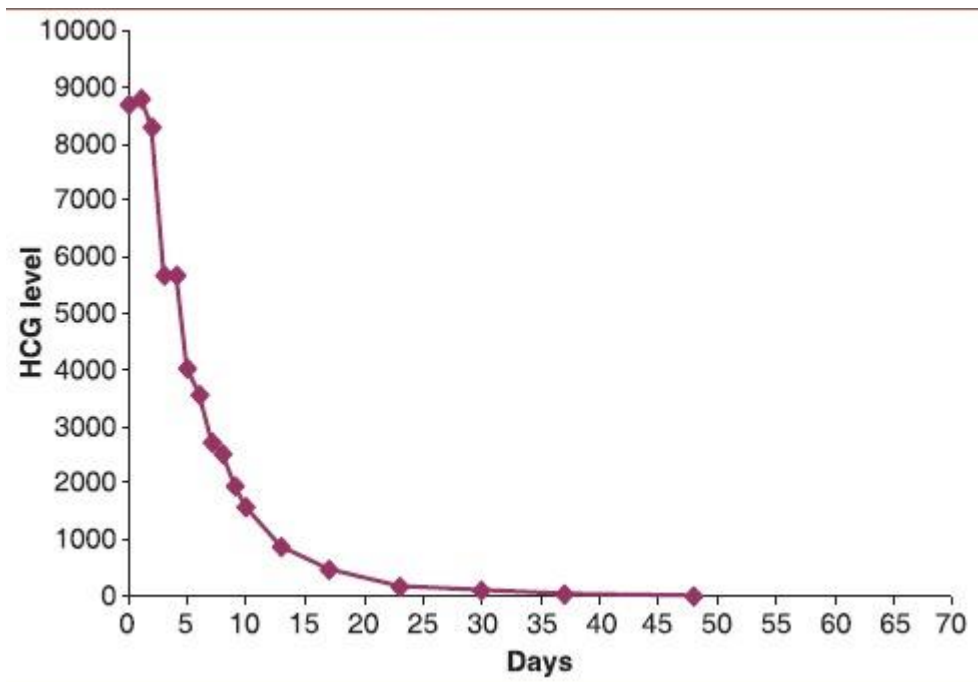
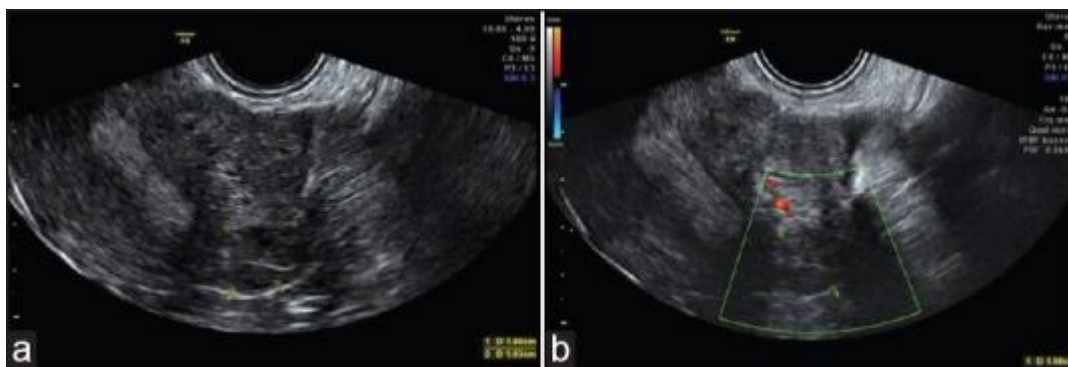

Figure 3



mass in the left uterine horn at follow-up visit 6 months after treatment with (a) and without (b) color Doppler