



UNIVERSITÀ
DEGLI STUDI
FIRENZE

FLORE

Repository istituzionale dell'Università degli Studi di Firenze

Study of the tendinous vascularization for the compound radial forearm flap plus flexor carpi radialis tendon

Questa è la Versione finale referata (Post print/Accepted manuscript) della seguente pubblicazione:

Original Citation:

Study of the tendinous vascularization for the compound radial forearm flap plus flexor carpi radialis tendon / Raspanti, Andrea; Delcroix, Luca; Ghezzi, Serena; Innocenti, Marco. - In: SURGICAL AND RADIOLOGIC ANATOMY. - ISSN 0930-1038. - STAMPA. - (2015), pp. N/A-N/A. [10.1007/s00276-015-1580-y]

Availability:

The webpage <https://hdl.handle.net/2158/1012550> of the repository was last updated on 2015-12-06T12:16:53Z

Published version:

DOI: 10.1007/s00276-015-1580-y

Terms of use:

Open Access

La pubblicazione è resa disponibile sotto le norme e i termini della licenza di deposito, secondo quanto stabilito dalla Policy per l'accesso aperto dell'Università degli Studi di Firenze (<https://www.sba.unifi.it/upload/policy-oa-2016-1.pdf>)

Publisher copyright claim:

La data sopra indicata si riferisce all'ultimo aggiornamento della scheda del Repository FloRe - The above-mentioned date refers to the last update of the record in the Institutional Repository FloRe

(Article begins on next page)

Study of the tendinous vascularization for the compound radial forearm flap plus flexor carpi radialis tendon

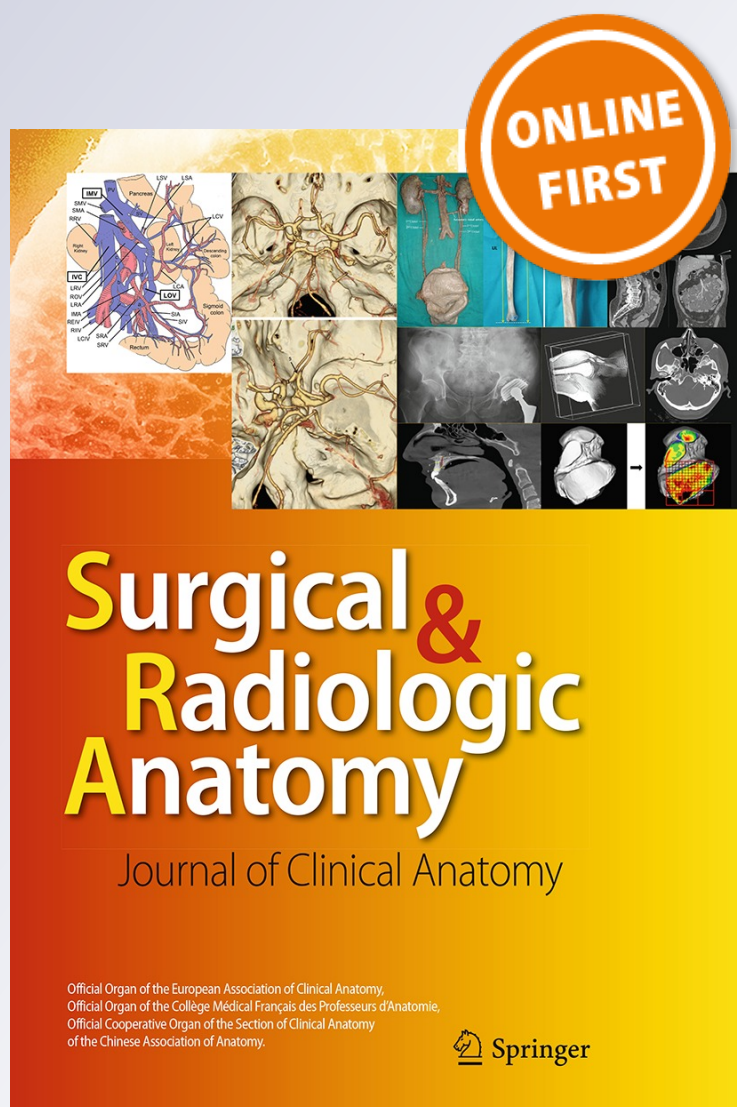
Andrea Raspanti, Luca Delcroix, Serena Ghezzi & Marco Innocenti

Surgical and Radiologic Anatomy

ISSN 0930-1038

Surg Radiol Anat

DOI 10.1007/s00276-015-1580-y



Your article is protected by copyright and all rights are held exclusively by Springer-Verlag France. This e-offprint is for personal use only and shall not be self-archived in electronic repositories. If you wish to self-archive your article, please use the accepted manuscript version for posting on your own website. You may further deposit the accepted manuscript version in any repository, provided it is only made publicly available 12 months after official publication or later and provided acknowledgement is given to the original source of publication and a link is inserted to the published article on Springer's website. The link must be accompanied by the following text: "The final publication is available at link.springer.com".

Study of the tendinous vascularization for the compound radial forearm flap plus flexor carpi radialis tendon

Andrea Raspanti¹ · Luca Delcroix¹ · Serena Ghezzi¹ · Marco Innocenti¹

Received: 2 July 2015 / Accepted: 19 October 2015
© Springer-Verlag France 2015

Abstract

Purpose The aim of this study was to explore the tendinous vascularization of *flexor carpi radialis* (FCR) and investigate the anatomical basis for harvesting the compound radial forearm flap (free or pedicled) with the vascularized tendon for the reconstruction of cutaneotendinous defects.

Methods The area of the radial forearm flap was studied in seventeen forearms of fresh cadavers injected with red latex. A lozenge-shaped flap about 9 cm long and 4 cm wide was raised along the axis of the radial artery. Dissection of the flap was carried out subfascially. We searched perforators going into the flap and the nutritive branches for the tendon sheath of FCR were dissected up to their origin from the radial artery. Their distance from the scaphoid tubercle was recorded.

Results We found nutritive branches for all the length of the tendon. The mean number of perforators going into the tendon sheath was 9.5 (range 8–12). Constant sizeable branches larger than 0.2 mm were identified from the scaphoid tubercle to the myotendinous junction; their distance from the scaphoid tubercle ranged between 0.5 and 12.5 cm. We found an average 0.8 perforators/cm of tendon (range 0.7–1). The donor sites were always closed primarily.

Conclusions Nutrient branches of the radial artery for the tendon of FCR were constantly found. Our anatomical findings confirm the possibility of raising a compound radial forearm flap including a sure vascularized tendon of FCR. Its clinical application provides a quick and

straightforward single-stage option for the reconstruction of complex cutaneotendinous defects.

Keywords Compound radial forearm flap · Flexor carpi radialis tendon · Vascularized tendon graft · Composite Chinese flap

Introduction

Loss of tissue resulting from cancer ablation or debridement of infected tissues or secondary to trauma provides the reconstructive surgeon with various challenges.

The rich vascular network of the forearm suggests that constant perforator vessels are likely to exist in the radial antebraichial region, which could supply not only the skin of the “Chinese flap” but also tendons passing through the flap, especially the tendon of *flexor carpi radialis* (FCR). Reid and Moss [14] yet reported a modification of the radial artery forearm flap for one-stage repair of dorsal hand injuries: they harvested the *palmaris longus* (PL) and a portion of the *brachioradialis* (BR) tendon along with fascia and skin. Other authors described as a slip of FCR tendon could be included in the flap [1, 7, 22]. These were clinical series, but in literature, we have found no study, which analytically justify the anatomical basis of harvesting such a compound flap. Instead, we can easily find many clinical papers where the entire FCR muscle was successfully harvested in composite myocutaneous flaps [2, 8, 10, 16, 19]. Evenly the international literature is rich in anatomical studies on the forearm neurovascular distribution [4, 5, 12, 15], but with the attention focused on vascularization of muscles and skin, not the tendons.

The aim of this study was to explore the tendinous vascularization of FCR and investigate the anatomical

✉ Andrea Raspanti
andrea.raspanti@live.it

¹ Plastic Surgery and Reconstructive Microsurgery Unit,
Department of Surgery and Translational Medicine,
University of Florence, Largo Piero Palagi, 1, Florence, Italy

basis for harvesting the compound radial forearm flap (free or pedicled) with the vascularized tendon for reconstruction of complex soft tissue defects, in a completely vascularized single-stage way.

Materials and methods

Seventeen amputated upper limbs of fresh adult cadavers (eight males and nine females) were used. Red latex was injected into the brachial artery. The classic area of the radial forearm flap was studied. Radial styloid, scaphoid tubercle, radial artery and tendons of BR, FCR and PL were marked (Fig. 1a). A lozenge shape flap about 9 cm long and 4 cm wide was designed along the axis of the radial artery (Fig. 1b); we preferred this size because in the clinical practice it is usually the limit for the primarily closure of the donor site. Under magnification loupes, a micrometer gauge (Mitutoyo, Economy Micrometer 0–25 mm, accuracy 0.01 mm) was used to determine vessels diameter, next to their origin from radial artery. For perforator vessels larger than 0.2 mm, a ruler (accuracy 1 mm) was used to determine their distance from the scaphoid tubercle.

Operative technique

The specimens were placed on a table, fully supinated. The flap was raised following the preoperative drawing. An exploratory incision was made on the medial border of the

flap, and the flap was raised ulnarward in the subfascial plane. During the harvest, unlike the conventional technique, a great attention was paid in preserving the fascia and its septa which surround the FCR tendon, including the perforators raising from the main vascular axis. Therefore, the fascia was raised starting from a more ulnar side (with a longitudinal incision made at the level of PL) and so a strip of antebrachial fascia, FCR tendon contained in a doubling of the fascia and the radial artery in the septum between FCR and BR, were harvested together in a single deep layer. This guaranteed a physiological gliding channel for the tendon and preserved its blood supply (Fig. 2). We searched for perforators going into the flap and especially the nutritive branches for the tendon sheath of FCR were dissected up to their origin from the radial artery, and their distance from the scaphoid tubercle was recorded (Fig. 3). Vessels with a diameter smaller than 0.2 mm were rarely found and difficult to preserve; for this reason and for a non-predictable good latex injection into such small vessels, those ones smaller than 0.2 mm were not considered. Therefore, tendon could be sectioned proximally at the myotendinous junction and distally as far as possible (usually at the level of the scaphoid tubercle). Then, this compound flap could be harvested both as a pedicled (reverse or direct flow) and as a free flap. The donor sites were closed primarily in all the specimens.

Results

We found nutritive branches for the tendon of FCR throughout its course, from the myotendinous junction until the entry into its osteofibrous channel at the carpus.

The mean number of nutritive branches larger than 0.2 mm (mean 0.33, range 0.2–0.6) going into the flap was 9.5 (range 8–12). Five to eight most distal perforators

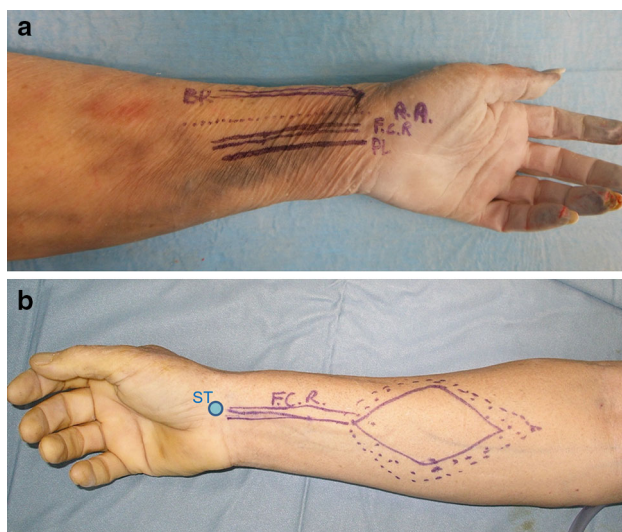


Fig. 1 **a** Left forearm: radial artery (RA) and tendons of brachioradialis (BR), flexor carpi radialis (FCR) and palmaris longus (PL) were marked. **b** Right forearm: preoperative marking of the lozenge-shaped flap on the donor site. The scaphoid tubercle (ST) is marked with the blue circle (colour figure online)

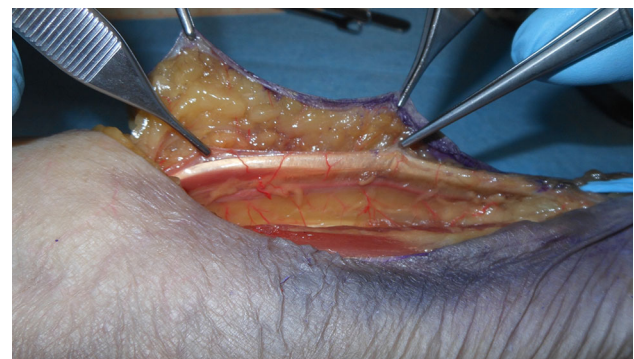

Fig. 2 Left forearm compound radial forearm flap augmented with the vascularized tendon of FCR during the harvest. Forceps hold the flap and FCR tendon sheath with deep fascia. Perforators for the tendon rise from the radial artery

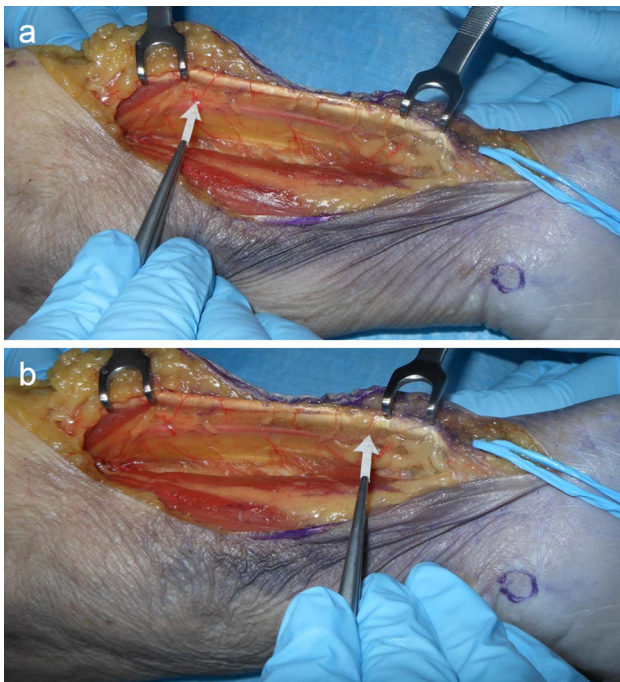


Fig. 3 Left forearm: vascular supply for FCR tendon. The scaphoid tubercle is approximately below the *blue loop*. **a** Arrow the most proximal perforator for the tendon sheath rising from the radial artery. **b** Arrow the most distal perforator for the tendon sheath rising from the radial artery (colour figure online)

directly reached the *paratenon* from the radial artery (or its volar division branch, once crossed the wrist), while one to five proximal perforators had an intramuscular course (distal belly of FCR), finally going into the myotendinous junction (Fig. 4). The distance from their origin to the scaphoid tubercle ranged between 0.5 and 12.5 cm.

In eleven out of seventeen forearms (65 %), the most distal perforator arose from the radial artery within 1.2 cm from the scaphoid tubercle, while in the remaining six specimens (35 %) the most distal perforator was located within 0.4 cm from this point. At least one branch larger than 0.2 mm was then present in every specimen within 1.6 cm proximal from the scaphoid tubercle (Fig. 5). More distal, at the end of the radial artery, close to the styloid process, the nutritive network for the tendon changed and its pre-insertional portion received more superficial nutritive branches directly from the radial artery and from its superficial volar branch (which is out of the septum) as well as from the vascular network of the wrist (Fig. 6). These ones cannot be considered real “perforator” branches and they did not go through the deep fascial layer. These branches were next to the pivot or the usual cutting level of the pedicle, and for this reason they might be frequently lost in clinical practice.

In eleven out of seventeen forearms (65 %), the most proximal perforator arose from the radial artery within

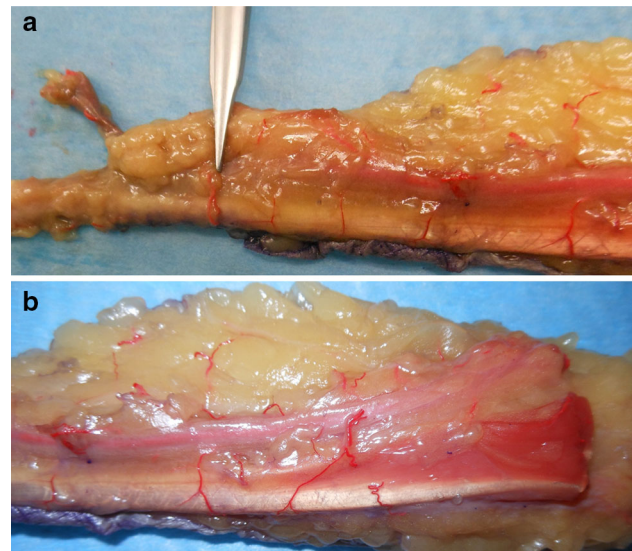


Fig. 4 **a** Distal and central perforators for FCR tendon, which perforate the deep fascia and go into the tendon sheath. A large perforator vessel is indicated. **b** Proximal perforators have an intramuscular course

10.7 cm from the scaphoid tubercle, while in the remaining six specimens (35 %) the most proximal perforator was located proximal from this point (Fig. 5). We stopped the count of the branches once reaching the myotendinous junction, where no other true tendon could be found.

The average length of FCR tendon found in specimens was 11.4 cm (range 8–13.5) (Fig. 7), so the mean value of perforators linear density was 0.8 perforators/cm of tendon (range 0.7–1).

Discussion

A multi-tissular defect involving distal region of superior or inferior limbs, particularly in case of trauma, infection or cancer ablation, needs a simultaneous reconstruction of both skin and tendon by means of vascularized tissue. Several donor sites are available in the human body which may meet the functional and cosmetic requests of the recipient site and several papers are available in the literature reporting the use of composite flaps, either pedicled or free. Vascularized tendon grafts were first reported by Taylor and Townsend [20] in 1979. They described two possible donor sites: one was the groin flap augmented with the external oblique aponeurosis for tendon reconstruction. The other was the free *dorsalis pedis* flap, which incorporated the extensor tendon to the toe. Subsequently, other donors for vascularized tendon grafts have been reported. Reid and Moss [14] described the radial forearm cutaneotendinous flap in 1983, harvesting the PL and a portion of the BR tendon along with fascia and skin. The following year, in 1984, Foucher [7] described a series of compound

Fig. 5 Distance of perforator arteries from the scaphoid tubercle (specimens 1–17)

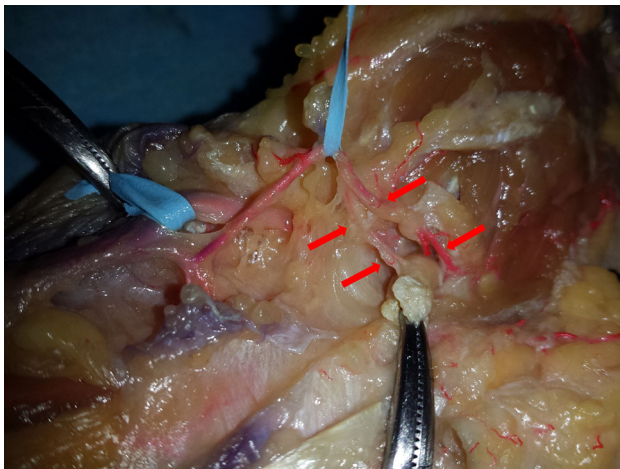
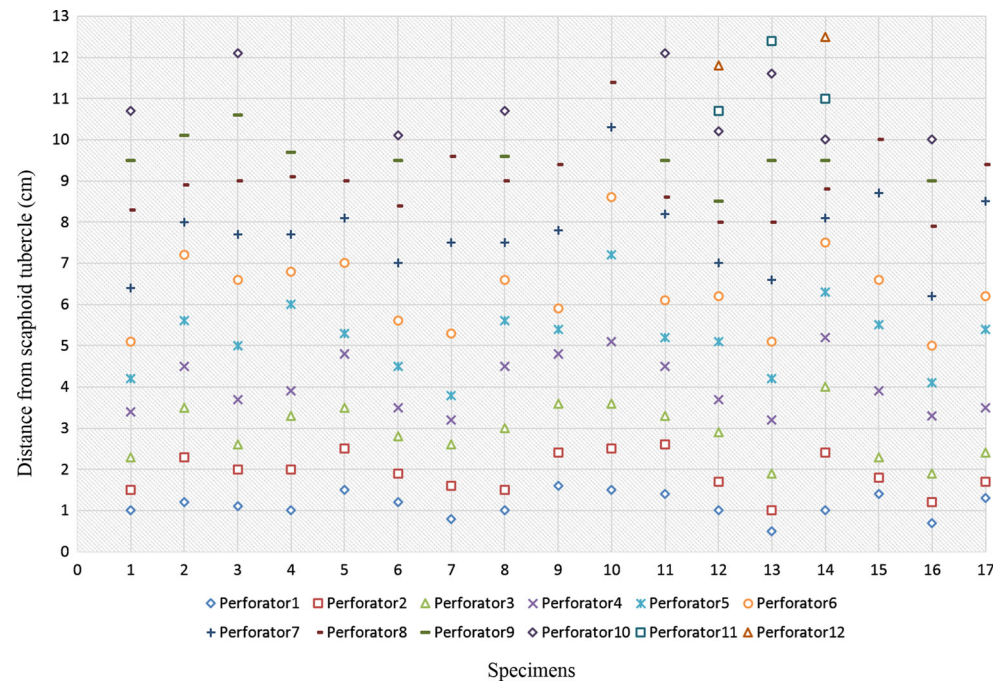


Fig. 6 Nutritive network for FCR tendon at the wrist. Pre-insertional portion (tendon held by the clamp) received more superficial nutritive branches (red arrows) from the superficial volar branch of the radial artery (which is out of the septum, raised by the small blue loop) and from the vascular network of the wrist (colour figure online)

radial artery forearm flaps in hand surgery, including vascularized nerve, bone and tendon. The BR tendon and the FCR tendon were included in the flaps as vascularized tendon grafts. In 1996, Yajima et al. [22] described a series of six patients with soft tissue defects involving the skin and extensor or flexor tendons: they treated them using a cutaneotendinous radial forearm flap, augmented with the PL tendon and FCR tendon. Moreover, FCR was widely used for harvesting composite myocutaneous forearm flaps [2, 8, 10, 16, 19], but in those cases only the muscle or the entire myotendinous unit was

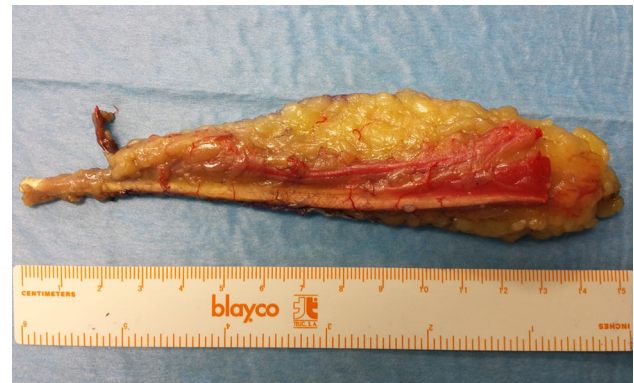

Fig. 7 Radial forearm free flap plus vascularized FCR tendon. The length of FCR tendon is shown

harvested. On the other hand, we can find some anatomical studies, from the Eighties onwards, dealing FCR vascularization [12, 15]. More recently, in 2008 and 2010, Chen et al [4, 5] studied the neurovascular distribution of forearm muscles. The studies were conducted, respectively, on ten and twenty-eight forearms of fresh cadavers and the authors found, according to the neurovascular distribution, that the forearm muscles could be divided into independent function units for muscle functional transplantation, but without reference to the single tendon vascularity. Therefore, despite the fact that in the international literature we can find several papers on the possibility of using the “Chinese flap” as a compound flap with vascularized tendons, there is no anatomical study targeted to examine the blood supply of FCR tendon in relation to its harvest together with the radial forearm flap. The present study

was stimulated by this lack, according to the leading paradigm in reconstructive surgery: “repair like with like”. This concept is particularly true when two or more tissues with different missions need to be simultaneously reconstructed. Very few donor sites can provide thin and pliable skin, together with a strong vascularized tendon. The radial forearm flap augmented with the FCR tendon well accomplishes the requests, with a strong and long tendon, sliding under an excellent skin. The FCR tendon is long enough to be doubled, to match a high mechanical strength, when required, or splitting into two parts. In this last case, it is possible to preserve the blood supply of each half, doubling the fascia and producing a small incision in the middle before splitting the tendon (a similar technique was described for hand reconstruction by Yajima et al. [22] in 1996). Otherwise, it can be slipped in case of excessive thickness. In addition, the size of FCR tendon allows for easy tendon suture or weaving inside residual tendon stumps, or even for easy passing in a bony tunnel according to the location of the defect. Last but not least, FCR tendon sheath, which is carefully preserved during the harvest, provides a physiological gliding channel and an adequate blood supply to the tendon. The difficulty in preserving the vascularization of the distal portion of the tendon is negligible, since it often is sacrificed because of a tendon suture, a reinsertion or passage in a bony tunnel. The same applies to the proximal stump. Furthermore, we found on average nine good central perforator arteries for the tendon, which could be all harvested with the deep fascia, thus ensuring a safe blood supply. Vascularized tendon grafts exhibit several advantages, experimentally [13, 17] and clinically [3, 9, 21] demonstrated, including a decreased likelihood to develop adhesion. In addition, thanks to the union of the tendon junction, rehabilitation can be started sooner than with conventional tendon grafts.

Such a compound flap can offer a valid solution for the one-stage repair of dorsal hand complex lesions [1, 7, 14, 22], if used as a pedicled flap. The presence of a long and strong vascularized tendon sliding under a very thin and pliable skin and the possibility of harvesting like a free flap offers an excellent solution also for reconstruction of distant areas, for example, foot and ankle [6, 11, 18]. We have a direct clinical experience in treating complex lesions of the Achilles tendon region with this compound free flap: we studied a series of six patients, observing good functional results after a mean follow-up of more than 36 months [11].

The present study has some limitations: first of all, the limited number of specimens. Despite this, we confirmed the possibility to find a constant blood supply for the tendon of FCR, when included in the compound radial forearm flap. The dissection technique should be carefully carried on, but the donor side is easily available and, bearing in mind the constant vascularization, flap harvesting can be done after a not too long learning curve.

Conclusions

Our anatomical findings support and confirm the “well known” possibility of raising a compound radial forearm flap augmented with the vascularized tendon of FCR. Its blood supply is almost constant and independent of that of the skin, and this must guide the harvesting.

Its clinical application allows, despite an acceptable donor-site morbidity, coverage of complex defects of soft tissues by means of a flap with a thin and pliable skin and a long, strong and vascularized tendon, which can freely slide into its natural sheath.

We consider it a quick and straightforward way for the completely vascularized single-stage reconstruction of many complex lesions, not only for the upper limb, but also as free flap in the reconstruction of complex defects of foot and leg.

Compliance with ethical standards

Conflict of interest All authors declare they have no conflicts of interest regarding financial, personal, or other matters that might affect the information, research, analysis, or interpretation of this article. The article processing charge was paid for by the authors.

References

- Adani R, Marcoccio I, Tarallo L (2003) Flap coverage of dorsum of hand associated with extensor tendons injuries: a completely vascularized single-stage reconstruction. *Microsurgery* 23:32–39
- Antohi N, Stan V, Nătescu C (2003) One-stage reconstruction of facial paralysis associated with severe skin scar deformity, using combined flexor carpi radialis muscle and radial forearm free flap. *Microsurgery* 23:194–197
- Cavadas PC, Pérez-García A, Thione A, Lorca-García C (2015) Single-stage reconstruction of flexor tendons with vascularized tendon transfers. *J Hand Surg Eur* 40:259–268
- Chen G, Jiang H, Lin ZH, Liu AT, Dang RS, Shen H (2008) Anatomic study of intramuscular nerve and blood vessel in forearm muscles: an anatomical study. *Zhonghua Zheng Xing Wai Ke Za Zhi* 24:228–231
- Chen G, Jiang H, Liu AT et al (2010) Neurovascular details about forearm muscles: applications in their clinical use in functional muscular transfer. *Surg Radiol Anat* 32:3–8
- Coşkunol E, Özdemir O, Özalp T (2005) Free radial forearm flap transfer for the reconstruction of the Achilles tendon and soft tissue defect: a case report. *Ulus Travma Acil Cerrahi Derg* 11:258–262
- Foucher G, van Genechten F, Merle N, Michon J (1984) A compound radial artery forearm flap in hand surgery: an original modification of the Chinese forearm flap. *Br J Plast Surg* 37:139–148
- Gordon D, Small J, Millar R (1992) Flexor carpi radialis myocutaneous flap. *Br J Plast Surg* 45:562
- Guimbeteau JC, Panconi B, Boileau R (1993) Mesovascularized island flexor tendon: new concepts and techniques for flexor tendon salvage surgery. *Plast Reconstr Surg* 92:888–903
- Hamilton RB, Proudman TW (1992) The radial forearm–flexor carpi radialis myocutaneous flap: case report. *Br J Plast Surg* 45:322–323

11. Innocenti M, Tani M, Carulli C, Ghezzi S, Raspanti A, Menichini G (2015) Radial forearm flap plus Flexor Carpi Radialis Tendon in Achilles tendon reconstruction: surgical technique, functional results, and gait analysis. *Microsurgery*. doi:[10.1002/micr.22481](https://doi.org/10.1002/micr.22481) [Epub ahead of print]
12. Liu HC, Wang YX, Yang ZM (1986) The study of the blood vessels and nerves of the flexor carpi radialis as a transplantation flap. *Hua Xi Yi Ke Da Xue Xue Bao* 17:25–28
13. Moriyama M (1992) Vascularized tendon grafting in the rabbit. *J Reconstr Microsurg* 8:83–91
14. Reid CD, Moss LH (1983) One-stage flap repair with vascularized tendon grafts in a dorsal hand injury using the “Chinese” forearm flap. *Br J Plast Surg* 36:473–479
15. Revol MP, Lantieri L, Loy S, Guérin-Surville H (1991) Vascular anatomy of the forearm muscles: a study of 50 dissections. *Plast Reconstr Surg* 88:1026–1033
16. Saulis AS, Sukkar SS, Dumanian GA (2002) The distally based radial artery/flexor carpi radialis muscle flap for dorsal hand reconstruction: a clinical and cadaver study. *J Hand Surg Am* 27:1081–1086
17. Singer DI, Morrison WA, Gumley GJ, O’Brien BM, Mitchell GM, Barton RM, Frykman GK (1989) Comparative study of vascularized and nonvascularized tendon grafts for reconstruction of flexor tendons in zone 2: an experimental study in primates. *J Hand Surg Am* 14:55–63
18. Stamate T, Budurcă AR, Tamaş C, Lazăr AN (1998) A free microsurgical transfer of a radial (Chinese) flap in reconstructing the lower limb. *Rev Med Chir Soc Med Nat Iasi* 102:161–166
19. Sukkar SM, Saulis AS, Dumanian GA (2002) Radial forearm skin with flexor carpi radialis muscle: a useful composite free flap. *Ann Plast Surg* 49:486–489
20. Taylor GI, Townsend P (1979) Composite free flap and tendon transfer, an anatomical study and a clinical technique. *Br J Plast Surg* 32:170–183
21. Wong R, Alam N, McGrouther AD, Wong JK (2015) Tendon grafts: their natural history, biology and future development. *J Hand Surg Eur* 40:669–681
22. Yajima H, Inada Y, Shono M, Tamai S (1996) Radial forearm flap with vascularized tendons for hand reconstruction. *Plast Reconstr Surg* 98:328–333