



UNIVERSITÀ
DEGLI STUDI
FIRENZE

FLORE

Repository istituzionale dell'Università degli Studi di Firenze

Levamisole adulterated cocaine and pulmonary vasculitis: Presentation of two lethal cases and brief literature review

Questa è la Versione finale referata (Post print/Accepted manuscript) della seguente pubblicazione:

Original Citation:

Levamisole adulterated cocaine and pulmonary vasculitis: Presentation of two lethal cases and brief literature review / Karch, Steven B; Busardò, Francesco Paolo; Vaiano, Fabio; Portelli, Francesca; Zaami, Simona; Bertol, Elisabetta. - In: FORENSIC SCIENCE INTERNATIONAL. - ISSN 0379-0738. - ELETTRONICO. - 265:(2016), pp. 96-102-102. [10.1016/j.forsciint.2016.01.015]

Availability:

The webpage <https://hdl.handle.net/2158/1024231> of the repository was last updated on 2016-08-09T14:23:34Z

Published version:

DOI: 10.1016/j.forsciint.2016.01.015

Terms of use:

Open Access

La pubblicazione è resa disponibile sotto le norme e i termini della licenza di deposito, secondo quanto stabilito dalla Policy per l'accesso aperto dell'Università degli Studi di Firenze (<https://www.sba.unifi.it/upload/policy-oa-2016-1.pdf>)

Publisher copyright claim:

La data sopra indicata si riferisce all'ultimo aggiornamento della scheda del Repository FloRe - The above-mentioned date refers to the last update of the record in the Institutional Repository FloRe

(Article begins on next page)

**LEVAMISOLE ADULTERATED COCAINE AND PULMONARY VASCULITIS:
presentation of two lethal cases and **brief literature review**.**

Authors:

Steven B. Karch^{1*}, Francesco Paolo Busardò^{2*}, Fabio Vaiano³, Angelo Montana⁴, Francesca Portelli⁵, Simona Zaami², Elisabetta Bertol^{3}.**

¹ Consultant Pathologist/Toxicologist, Barkeley, California, USA

² Department of Anatomical, Histological, Forensic and Orthopaedic Sciences, Sapienza University of Rome, Viale Regina Elena 336, 00161, Rome, Italy;

³ Department of Health Sciences, Forensic Toxicology Division, University of Florence, Italy

⁴ Department “G.F. Ingrassia”, Laboratory of Forensic Toxicology, University of Catania, Italy

⁵ Human Pathology Section, Department of Health Science, Palermo University School of Medicine, Palermo, Italy.

* Both authors contributed equally to the paper.

**Corresponding Author:

Prof. Elisabetta Bertol - Department of Health Sciences, Forensic Toxicology Division, University of Florence, Italy. E-mail: elisabetta.bertol@unifi.it

LEVAMISOLE ADULTERATED COCAINE AND PULMONARY VASCULITIS: presentation of two lethal cases and **brief literature review.**

Abstract:

The first case reports of levamisole-related disease in cocaine users were published in 2010, although levamisole adulteration of cocaine was first recognized several years earlier. Currently, more than 70% of street cocaine seizures, in the US and the EU, contain levamisole, which could potentially be converted to aminorex, though the reasons for this practice still remain obscure. **Here we report two fatal cases of isolated pulmonary vasculitis in abusers of levamisole-adulterated cocaine, where a complete autopsy, full toxicological analysis by gas chromatography–mass spectrometry (GC–MS) using a previously published method of Karch et al. and histological examination were performed. A control group composed of 11 cases of cocaine related deaths, where the presence of levamisole was excluded in blood, urine and hair, was used. Recent literature on the human pharmacokinetics of levamisole and aminorex is also reviewed.**

The toxicological analysis revealed positive qualitative and quantitative results for cocaine, benzoylecgonine and levamisole in both cases. In case 1 levamisole was found at the concentration of 13.5 and 61.3 mg/L in blood and urine respectively, whereas in case 2 at 17.9 and 70.2 mg/L. The histological examination highlighted in case 1 in heart samples microscopic evidence of the typical remodeling changes associated with chronic stimulant abuse, whereas lungs showed numerous lymphocytes surrounding and infiltrating the wall of small pulmonary vessels and a perivascular fibrosis with transforming fibroblasts. In case 2, the myocardial samples showed wide fields of myocardial necrosis characterized by hypercontraction of the myocytes with thickened Z-lines and short sarcomeres, whereas lung samples showed a significant intimal thickening of arteriole walls and lymphocytic infiltration of the wall and edema. Moreover, there were also numerous perivascular lymphocytic infiltrates.

Although the pathological cardiac findings have allowed us to establish the cause of death in both cases, the presence of pulmonary vasculitis in the lungs represent a further complication. If the disease had progressed to hemorrhage, it certainly would have been a contributory cause of death.

The two cases here reported allow us to advance a hypothesis about the possible correlation between the consumption of levamisole adulterated cocaine and pulmonary vasculitis and the comparison of these findings with the control group support this hypothesis.

However, this hypothesis is still weak, taking into consideration the fact that pulmonary vasculitis was detected in 2 cases only, making it impossible to exclude a different etiology of this finding.

Only through careful histological lung examinations of further cases of fatalities, related to levamisole adulterated cocaine, can this hypothesis be confirmed or refuted.

Keywords: levamisole, adulterated cocaine, pulmonary vasculitis, post-mortem toxicology.

1. Introduction:

The first case reports of levamisole-related disease in cocaine users were published in 2010 [1], although levamisole adulteration of cocaine was first recognized several years earlier. For many years levamisole was used as a safe, effective anthelmintic in humans. It is still used for that purpose by veterinarians and veterinary toxicologists were the first to deduce, while screening for race-horse doping, that levamisole was being partially converted to aminorex, therefore explaining why it can be found in post horserace testing [2]. Aminorex is an amphetamine-like drug with the proven ability to cause pulmonary hypertension in humans. Structures of levamisole and aminorex are given in Figure 1.

Aminorex was once sold as an anorectic called Menocil, but only in Switzerland, Austria and Germany. It was withdrawn from that market in 1972, after an epidemic of deaths from idiopathic pulmonary hypertension (IPH), which first began in the late 1960s. In early 2000 evidence began to emerge that cocaine in the United States and in Europe was being adulterated with levamisole. It is believed that today, more than 70% of street cocaine seizures, in the US and the EU [3], contain levamisole, which could potentially be converted into aminorex, though the reasons for this practice still remain obscure.

It has been suggested that, because aminorex is a serotonin reuptake blocker, it may act synergistically with cocaine to produce a greater “high.” Alternatively, aminorex has a much longer half-life than cocaine, and may exert an amphetamine-like effect which might prolong the pleasurable experience [4]. This seems a reasonable theory, although the actual conversion rate of levamisole to aminorex is not known. Retiform purpura, thought to be immune related, is the most

common complication of the use of levamisole/aminorex seen today [5]. It is far more commonly reported than IPH, however the true incidence of pulmonary hypertension is not known, possibly because its presence at autopsy is much less obvious than that of retiform purpura which is so obvious it cannot be overlooked. Cocaine-induced pulmonary vasculitis is mentioned in an occasional autopsy report, but usually in association with pulmonary hemorrhage in the presence of other systemic diseases [6-7]. Vasculitis in cocaine users is thought to be immune related as well. Agranulocytosis secondary to levamisole use is occasionally reported, as are myocardial infarction and vascular disease [8].

Here we report two fatal cases of isolated pulmonary vasculitis in abusers of levamisole-adulterated cocaine, where a complete autopsy, full toxicological analysis and histological examination were performed. Recent literature on the human pharmacokinetics of levamisole and aminorex is also reviewed.

2. The cases

2.1. Case 1:

A 51-year-old man with a long history of drug abuse, especially cocaine, while being taken to hospital because of bizarre behavior suddenly died. Although there was a minor scuffle with police, positional asphyxia was never an issue, and neither were Taser™ applications nor back compression.

A complete autopsy was performed three days after death. The presence of a severe pulmonary edema (right lung 920 g, left 650 g) was notable. Examination of the heart disclosed it was enlarged by almost two standard deviations above predicted size (420 grams versus 312 grams predicted). All the other organs were unremarkable.

2.2. Case 2:

A 35 year-old male collapsed during a party about 30 minutes after having snorted cocaine as witnessed by his friends. Despite the prompt resuscitation attempts he was pronounced dead 1 hour later.

According to his relatives and friends the deceased had a long history of cocaine abuse.

A complete autopsy was performed two days later. The heart was of normal shape and size (12 cm x 11.5 cm x 3.5 cm) and it weighed 375 g. At the section, the left ventricular wall was moderately increased (15mm). All the other organs were unremarkable, only a severe pulmonary and brain edema was found.

3. Materials and methods

3.1 Toxicology

3.1.1 Samples

For case 1 blood and urine samples were collected, whereas for case 2 in addition to blood and urine samples also a hair specimen (3 cm, from the posterior vertex region of head, close to the scalp as recommended by the Society of Hair Testing guidelines [9]) was taken.

3.1.2 Chemicals and instrumentation

Dichloromethane (DCM), ammonium hydroxide and toluene were purchased from Panreac Quimica S.L.U. (Castellar del Valle, Spain). Sodium hydroxide (NaOH), methanol (MeOH) and isopropanol were acquired from Carlo Erba Reagenti (Milano, Italy). Cocaine, benzoylecgonine, levamisole, mephentermine (N,2-dimethyl-1-phenylpropan-2-amine), cocaine-d₃ and benzoylecgonine-d₃ were supplied from Chemical Research 2000 (Rome, Italy). Hydrochloric acid (HCl), disodium hydrogen phosphate and sodium dihydrogen phosphate were acquired from J.T. Baker (Deventen, Holland). N-Methyl-N-(trimethylsilyl)trifluoroacetamide (MSTFA) and Water (H₂O) were obtained from Sigma (St. Louis, MO, USA) and B. Braun (Milano, Italy), respectively. Analysis was carried out on a gas chromatography instrument Agilent 7890A GC coupled with an Agilent MSD 5975C. The column was an Agilent HP-5MS (30 m length, 0.25 mm i.d. and 0.25 mm film thickness, Agilent Technologies). The start oven temperature was 100 °C for 2.25 min, and programmed to 180 °C at 40 °C /min, and 300 °C at 10 °C /min for 10 min. Electron ionization and selected ion monitoring (SIM) acquisition mode were used. The ions of interest were as follows: m/z 182, 82, 303 for cocaine, m/z 240, 82, 361 for benzoylecgonine and m/z 73, 148, 204 for levamisole. The underlined ions were used for quantitative analysis.

3.1.3 Toxicological analysis

All samples were analyzed by gas chromatography–mass spectrometry (GC–MS) using a previously published method of Karch et al. [10]. The method was readapted to the conditions of the present study and fully validated according to the guidelines provided by Peters et al. [11].

3.1.4 Hair analysis

Six segments of 0.5 cm length each were analyzed. Aliquots of 25 mg of decontaminated hair were incubated overnight in 1 mL of 0.1 N HCl, at 45 °C, in presence of 100 ng of mix IS solution. After cooling, 1.0 mL of 0.1 M phosphate buffer (pH 6–7) and few drops of 2 N NaOH were added. Centrifugation at 4000 rpm for 5 min was followed before a solid-phase extraction (SPE) with Bond Elut LCR-certify 130 mg column (Agilent Technologies). Columns were pretreated with 2 mL of MeOH and 2 mL of 0.1 M phosphate buffer (pH 6–7); afterwards, the sample was applied and the washing step was carried out with 2 mL of H₂O, 3 mL of 0.1 M HCl and 5 mL of MeOH. One mL of a mixture of DCM/isopropanol (8:2) at 2% of ammonium hydroxide was added twice as elution agent. The organic solution was dried under a gentle N₂ stream and derivatization with 25 mL of MSTFA at 75 °C for 15 min was followed. The residue was reconstituted with 25 mL of toluene and injected in the GC–MS system.

3.1.5 Biological fluids

Urine (1 mL) and blood (1 mL) samples were diluted with 2 mL of H₂O and 1000 ng of IS mix solution was added. Afterwards, 2.0 mL of 0.1 M phosphate buffer (pH 6–7) and a few drops of 2 N NaOH were added. The same SPE and derivatization procedures as above described for hair analysis were then performed.

3.2 Histological examination

For histological analysis the following samples were collected in case 1 and case 2 and fixed in 10% neutral buffered formalin: brain, lung, heart, liver, kidney, spleen, adrenal glands, thyroid, pancreas and cutis. All samples after fixation were paraffin-embedded, sectioned at 6 µm thickness and stained with haematoxylin and eosin.

3.3 Control group

Cases of cocaine related deaths, where the presence of levamisole was excluded in blood, urine and hair, were retrospectively reviewed from our archive. For all selected cases a complete autopsy, toxicological and histological analyses were performed. All cases of polydrug abuse have been excluded.

4. Results

4.1 Toxicological findings

Positive qualitative and quantitative results were obtained for cocaine, benzoylecgonine and levamisole in both cases. The results are given in Table I. Hair toxicological findings for case 2 are shown in Figure 2. Extracted ion chromatogram of levamisole obtained from the urine sample of case 2 and levamisole mass spectra are given in Figure 3A and B.

4.2 Histological results

Case 1

The heart samples showed microscopic evidence of the typical remodeling changes associated with chronic stimulant abuse (Fig. 4A and B). As would be expected in a chronic cocaine abuser, there was wide spread interstitial fibrosis and evidence of extensive myocardial remodeling. The presence of severe pulmonary edema and lymphocytes surrounding and infiltrating the wall of small pulmonary vessels was notable. Moreover, a perivascular fibrosis with transforming fibroblasts was found (Fig. 5A and B). There were no hemorrhages, and no micro-thrombi.

Case 2

The myocardial samples showed wide fields of myocardial necrosis characterized by hypercontraction of the myocytes with thickened Z-lines and short sarcomeres.

Lung samples showed a significant intimal thickening of arteriole walls and lymphocytic infiltration of the wall and edema. Moreover, there were also numerous perivascular lymphocytic infiltrates (Fig. 5C and D).

Histological examinations of the other organs did not reveal any pathology, except for wide spread visceral congestion.

In both cases the vascular infiltrate found in lung samples stained with haematoxylin and eosin was characterized by immunohistochemistry and a mixed mature B (CD20+) and T (CD3+) lymphocytic infiltrate was highlighted.

4.3 Control group

Eleven cases were identified; all data regarding age, sex, toxicological and pulmonary histological findings and the cause of death are reported in Table II. The main pulmonary findings at histology were: from a severe to a moderate pulmonary edema (6 cases, 54.5%), the presence of hemosiderin laden macrophages (3 cases, 27.3%), etc. The cause of death was cardiac in 8 cases (72.7%), excited delirium in 2 cases (18.2%) and pulmonary in 1 case (9.1%).

5. Discussion

The population pharmacokinetics of levamisole and aminorex have been characterized. Levamisole can be detected for up to 36 hours after ingestion in serum, but concentrations of aminorex in serum never exceeded the LOQ (0.34 ng/mL). Using a one compartment model, and a 100 mg oral dose of levamisole, Hess and his group calculated that $k_a = 1.2$ [1/h], $CL/F = 52$ l/h, $V/F = 347$ l, f (renal) = 0.0005, $t_{1/2} = 2.0$ h, $AUC = 1923$ ng/mL*h, $c_{max} = 214$ ng/mL, $t_{max} = 1.98$ h. Levamisole could be quantified in 42.5% of cocaine; concentrations in the positive plasma samples ranged from 2.2 to 224 ng/mL [12].

The pharmacokinetics of Minocel were never evaluated before it went on the market, as the available technology simply did not allow measurement of aminorex concentrations. Thus, several important questions still remain unanswered: (a) the rate of conversion of levamisole to aminorex, or (b) the amount of aminorex and duration of exposure to levamisole required to cause IPH. Most cases that occurred during the IPH epidemic began from six to nine months after aminorex use, with average dose ranges of 10 to 40 mg per day [13]. Currently, there is no way of knowing whether another epidemic of IPH may be in the making. We do know, however, that a substantial number of chronic abusers consume very large amounts of cocaine on a daily basis (multiple grams per day) [14], so the possibility of another outbreak of IPH among cocaine abusers remains a real possibility, especially as the formation of aminorex from levamisole seems to depend on the concentration of the latter.

In case 1, a cardiomegally was highlighted at autopsy with obvious evidence of myocardial remodeling which has already been linked to chronic stimulant abuse [15]. Whether the presence of levamisole made the remodeling changes worse is impossible to say given the evidence at hand. Although pathological changes in the heart may support the cause of death, the incidental finding of pulmonary lymphocytic vasculitis **may** represent an unrecognized complication of levamisole use. In case 2, the findings of the segmental (6*0.5cm) analysis of the 3 cm hair sample confirm that the 35 year-old male had a cocaine abuse history since cocaine was detected in all 6 segments. It is

accepted that head hair grows at an average rate of 1 cm each month [16-18], so the results here are consistent with retrospective analysis of 3-months cocaine/levamisole exposure. In segments 1, 2, 4 and 6 levamisole was detected suggesting that the administered cocaine was adulterated with the last drug intake. The first hair segment, the one closest to the scalp, showed the highest concentration of levamisole, which suggested consumption of adulterated cocaine during approximately the last 15 days of the deceased life. As in the first case, the pathological cardiac findings allowed us to establish the cause of death.

Taking into account the presence of pulmonary lymphocytic vasculitis in both cases and the possible correlation of this finding with levamisole it is interesting to note that in none of the cases of the control group pulmonary vasculitis was detected. The most common finding in lung samples of this group was a pulmonary edema (54.5% of cases), which was not found in the two cases here reported.

Pulmonary edema in cocaine users can represent another manifestation of catecholamine toxicity of the lungs, the heart, or both. Cocaine and the catecholamine excess occurring as a consequence of the use of cocaine, decrease myocardial contractility, lowering cardiac output, causing heart failure and the developing of pulmonary edema.

Moreover, the segmental analysis of hair in the control group has allowed us to exclude a previous intake of levamisole, variable time ranging from approximately a month and a half (case 4) to approximately 5 months (case 11).

A review of literature published in 2012 by Larocque and Hoffman [19] reported levamisole-induced complications in cocaine users and a total of 203 cases were identified; however, only in 57 cases the presence of levamisole was confirmed. The most common complications reported were neutropenia and moderate/severe cutaneous complications, especially retiform purpura with different degrees of necrosis and a predominant involvement of the ear lobes. Regarding pulmonary complications in a case series [20] 3 cases of pulmonary hemorrhage were reported.

However, it is important to underline that all these complications have been highlighted in living subjects; Larocque and Hoffman [19] until December 2011 have found only three deaths as a result of complications secondary to levamisole-tainted cocaine and the review of the literature of the last three years has detected only further 2 cases of complications leading to death, possibly related to levamisole or its metabolite: a case of acute coronary syndrome involving a 25-year-old man with a history of cocaine abuse [21] and a case of pulmonary hypertension involving a 51-year-old male native of Tunisia [10].

Hence, taking into consideration that the majority of data comes from living subjects and currently there are only a few cases of fatalities related to complications due to levamisole adulterated cocaine, possible complications such as pulmonary vasculitis may go unrecognized in comparison to cutaneous manifestations or agranulocytosis, the effects of which are more evident.

Therefore, the two cases here described confirm the necessity of the toxicological analysis of levamisole and adulterants, which could represent an additional health threat [22-23] and only through a careful analysis of further cases can this and other complications be highlighted. Presently, although cocaine can be adulterated with many substances like lidocaine, dextromethorphan, caffeine, sugars, creatine, benzocaine etc., levamisole represents one of the most popular cocaine adulterants, reaching more than 80% of illicit cocaine seized within United States borders [24].

6. Conclusions

Although the pathological cardiac findings have allowed us to establish the cause of death in both cases, the presence of pulmonary vasculitis in the lungs represent a further complication. If the disease had progressed to hemorrhage, it certainly would have been a contributory cause of death.

The two cases here reported allow us to advance a hypothesis about the possible correlation between the consumption of levamisole adulterated cocaine and pulmonary vasculitis and the comparison of these findings with the control group support this hypothesis. Moreover, in one of the two cases (case 2) it was possible to document a cocaine abuse history with levamisole adulterated cocaine during the 3 months previous to death.

However, this hypothesis is still weak, taking into consideration the fact that pulmonary vasculitis was detected in 2 cases only, making it impossible to exclude a different etiology of this finding.

Only through careful histological lung examinations of further cases of fatalities, related to levamisole adulterated cocaine, can this hypothesis be confirmed or refuted.

Moreover, numerous further points must be clarified; whether or not pulmonary vasculitis represents an acute or chronic complication of levamisole use and therefore segmental hair analysis is highly recommended in order to document a possible previous levamisole intake, if levamisole/aminorex induced-pulmonary vasculitis has been present for some time before converting to hemorrhagic vasculitis and finally if it represents an isolated finding or a manifestation of a multi-organ disease.

7. Conflict of Interest

The authors confirm that this article content has no conflicts of interest.

8. References

1. D.R. Czuchlewski, M. Brackney, C. Ewers, J. Manna, M.H. Fekrazad, A. Martinez, K.B. Nolte, B. Hjelle, I. Rabinowitz, B.R. Curtis, J.G. McFarland, J. Baumbach, K. Foucar, Clinicopathologic features of agranulocytosis in the setting of levamisole-tainted cocaine, *Am J Clin Pathol.* 133 (2010) 466-72.
2. E.N. Ho, D.K. Leung, G.N. Leung, T.S. Wan, A.S. Wong, C.H. Wong, L.R. Soma, J.A. Rudy, C. Uboh, R. Sams, Aminorex and rexamino as metabolites of levamisole in the horse, *Anal Chim Acta.* 638 (2009) 58-68.
3. C. Eiden, H. Peyriere, C. Diot, O. Mathieu, Prevalence of levamisole and aminorex in patients tested positive for cocaine in a French University Hospital, *Clin Toxicol (Phila).* 53 (2015) 604-608.
4. L.P. Raymon, D.S. Isenschmid, Letter to the editor: The possible role of levamisole in illicit cocaine preparations, *J Anal Toxicol.* 33 (2009) 620-622.
5. L. Geller, T.B. Whang, S.E. Mercer, R. Phelps, Retiform purpura: a new stigmata of illicit drug use?, *Dermatol Online J.* 17 (2011) 7.
6. X. Guo, R. Gopalan, S. Ugbarugba, H. Stringer, M. Heisler, M. Foreman, C. Nzerue, Hepatitis B-related polyarteritis nodosa complicated by pulmonary hemorrhage, *Chest.* 119 (2001) 1608-1610.
7. E. Silvestri, G. Emmi, M.M. D'Elis, T. Barnini, C. Tamburini, Pulmonary hemorrhage: not only vasculitis, *Intern Emerg Med.* 6 (2011) 577-580.
8. L. Garg, S. Gupta, A. Swami, P. Zhang, Levamisole/Cocaine Induced Systemic Vasculitis and Immune Complex Glomerulonephritis, *Case Rep Nephrol.* 2015;2015:372413.
9. G.A. Cooper, R. Kronstrand, P. Kintz, Society of Hair Testing guidelines for drug testing in hair, *Forensic Sci Int.* 218 (2012) 20-24.

10. S.B. Karch, B. Defraia, L. Messerini, F. Mari, F. Vaiano, E. Bertol, Aminorex associated with possible idiopathic pulmonary hypertension in a cocaine user, *Forensic Sci Int.* 240 (2014) 7-10.
11. F.T. Peters, O.H. Drummer, F. Musshoff, Validation of new methods, *Forensic Sci Int.* 165 (2007) 216-224.
12. C. Hess, N. Ritke, K. Sydow, L.M. Mehling, H. Ruehs, B. Madea, F. Musshoff, Determination of levamisole, aminorex, and pemoline in plasma by means of liquid chromatography-mass spectrometry and application to a pharmacokinetic study of levamisole, *Drug Test Anal.* 6 (2014) 1049-1054.
13. F. Follath, F. Burkart, W. Schweizer, Drug-induced pulmonary hypertension?, *Br Med J.* 1 (1971) 265-26.
14. K. Blaho, B. Logan, S. Winbery, L. Park, E. Schwilke, Blood cocaine and metabolite concentrations, clinical findings, and outcome of patients presenting to an ED, *Am J Emerg Med.* 18 (2000) 593-598.
15. S.B. Karch, G.S. Green, S. Young, Myocardial hypertrophy and coronary artery disease in male cocaine users, *J Forensic Sci.* 40 (1995) 591-595.
16. M.R. Harkey, Anatomy and physiology of hair, *Forensic Sci Int.* 63 (1993) 9-18.
17. H. Lazareth, G. Peytavin, L. Polivka, N. Dupin, The hairy-print for levamisole-induced vasculitis, *BMJ Case Rep.* 2012. DOI: 10.1136/bcr-2012-006602.
18. L. Polivka, G. Peytavin, N. Franck, L. Mouthon, N. Dupin, Testing for levamisole and cocaine in hair samples for the diagnosis of levamisole-related panniculitis, *J Eur Acad Dermatol Venereol.* 2014. DOI: 10.1111/jdv.12582.
19. A. Larocque, R.S. Hoffman, Levamisole in cocaine: unexpected news from an old acquaintance, *Clin Toxicol (Phila).* 50 (2012) 231-241.
20. M.M. McGrath, T. Isakova, H.G. Rennke, A.M. Mottola, K.A. Laliberte, J.L. Niles, Contaminated Cocaine and Antineutrophil Cytoplasmic Antibody-Associated Disease, *Clin J Am Soc Nephrol.* 6 (2011) 2799 – 2805.
21. K. Michaud, S. Grabherr, K. Shiferaw, F. Doenz, M. Augsburger, P. Mangin, Acute coronary syndrome after levamisole-adulterated cocaine abuse, *J Forensic Leg Med.* 21 (2014) 48-52.
22. T. Hofmaier, A. Luf, A. Seddik, T. Stockner, M. Holy, M. Freissmuth, G.F. Ecker, R. Schmid, H.H. Sitte, O. Kudlacek, Aminorex, a metabolite of the cocaine adulterant levamisole, exerts amphetamine like actions at monoamine transporters, *Neurochem Int.* 73 (2014) 32-41.

23. N. Barbera, F.P. Busardo, F. Indorato, G. Romano, The pathogenetic role of adulterants in 5 cases of drug addicts with a fatal outcome, *Forensic Sci Int.* 227 (2013) 74-76.
24. S.B. Karch, F. Mari, V. Bartolini, E. Bertol, Aminorex poisoning in cocaine abusers, *Int J Cardiol.* 158 (2012) 344-346.

Table I: Quantitative results for cocaine, benzoylecgonine and levamisole detected in blood and urine in case 1 and 2.

Case nº	Analytes	Blood (mg/L)	Urine (mg/L)
Case 1	COC	0.74	26.3
	BZE	1.8	93.6
	LEV	13.5	61.3
Case 2	COC	0.95	34.7
	BZE	4.6	248.3
	LEV	17.9	70.2

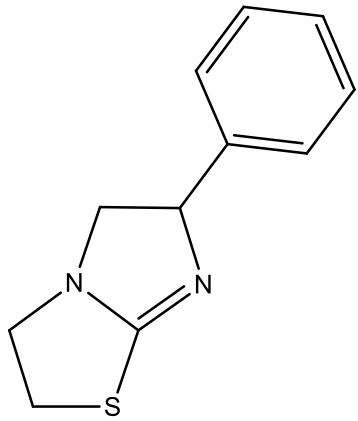
COC = cocaine; BZE = benzoylecgonine; LEV = levamisole.

Table II – Control group: 11 cases of cocaine related death where the presence of levamisole was excluded.

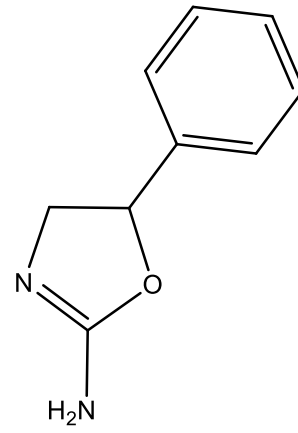
Case/Age/Sex	Toxicology (mg/L)				Histological pulmonary findings	Cause of death
	Blood		Urine			
	COC	BZE	COC	BZE		
1/24/M	1.15	2.84	8.6	19.7	Thickening of the smaller pulmonary arteries secondary to initial hyperplasia with myxoid change	Cardiac
2/31/M	0.92	1.26	No urine		Severe edema	Cardiac
3/37/F	0.62	0.95	38.9	94.1	Moderate edema	Cardiac
4/19/M	1.34	3.10	2.89	4.45	Marked subpleural vascular congestion and numerous hemosiderin laden macrophages	Cardiac
5/22/M	0.98	2.03	9.67	28.4	Moderate edema, abundant hemosiderin laden macrophages	Cardiac
6/29/M	0.57	0.85	2.13	3.19	Moderate edema	Cardiac
7/41/M	1.68	3.12	14.89	23.67	Severe alveolar hemorrhage with abundant hemosiderin laden macrophages	Pulmonary
8/27/M	2.10	3.61	88.4	113.6	Severe edema	Excited delirium
9/24/F	0.32	0.95	No urine		Dilated and congested peribronchial vessels	Cardiac
10/27/M	0.55	1.02	1.89	3.57	Intraalveolar capillary congestion and dilatation with focal septal fibrosis and necrosis	Excited delirium
11/35/F	0.59	1.12	ND	4.9	Moderate edema,	Cardiac

					intense cellular proliferation and increasing thickness of the alveolar walls	
--	--	--	--	--	---	--

Legend: COC = cocaine; BZE = benzoylecgonine; ND = not detected.



Levamisole



Aminorex

Fig. 1. Structures of levamisole and aminorex.

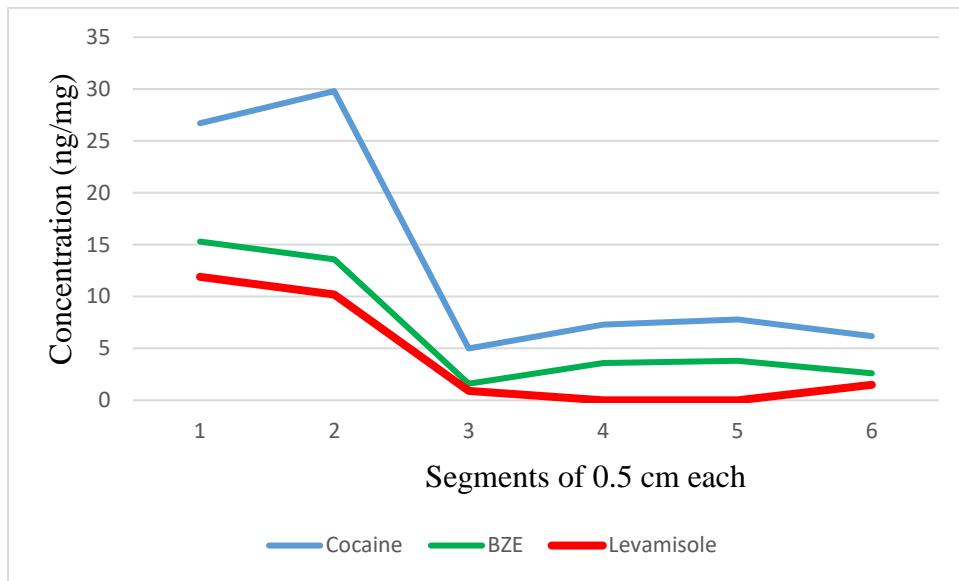


Fig. 2. Quantitative results for cocaine, benzoylecgonine and levamisole detected in the 6 hair segments in case 2. Segment 1 represents the one closest to the scalp.

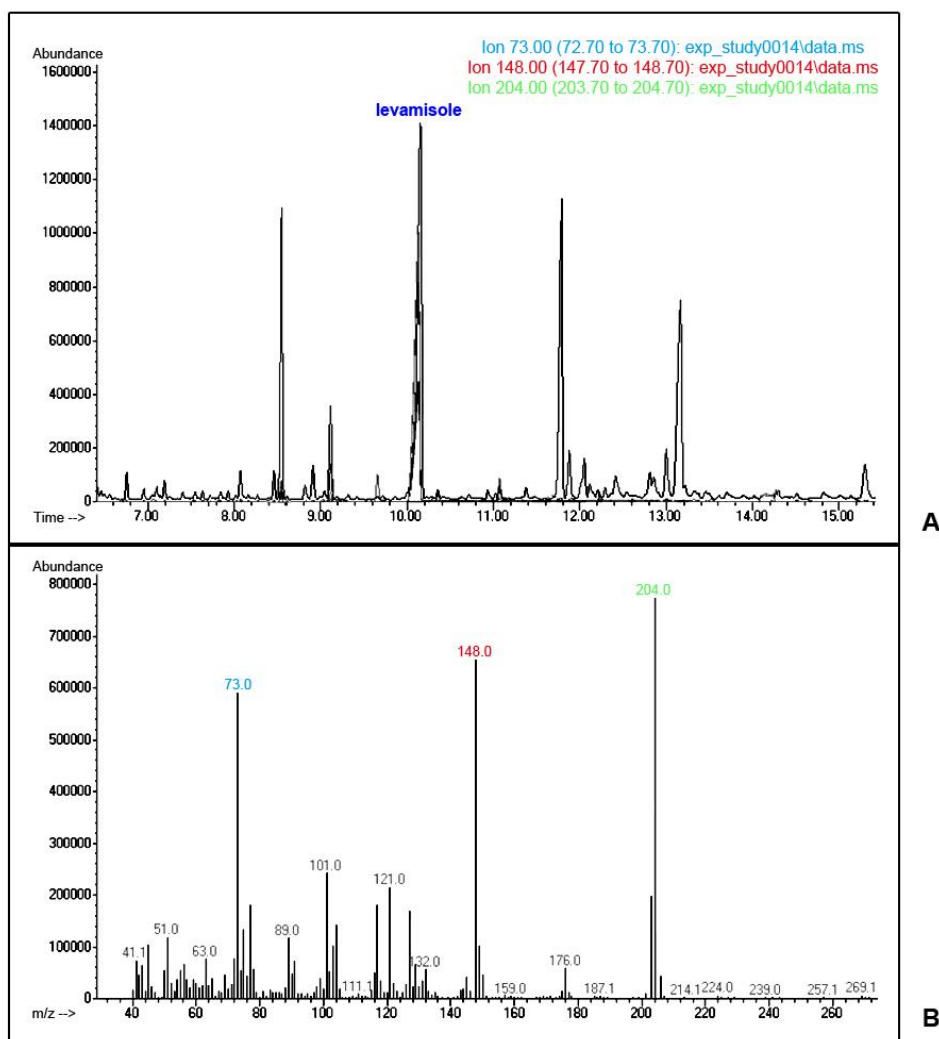


Fig. 3. Extracted ion chromatogram of the levamisole positive urine sample (case 2) (A), levamisole mass spectra (B).

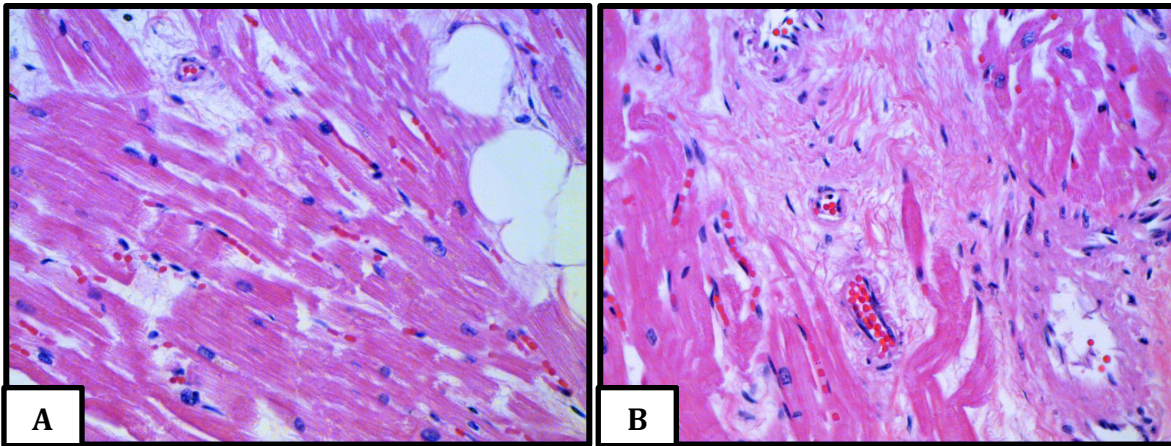


Fig. 4. (H&E) Case 1: myocardial disarray and abnormal fat deposits (A); Medial hypertrophy of small vessels, presence of autophagic hypertrophic myocytes and interstitial fibrosis (B).

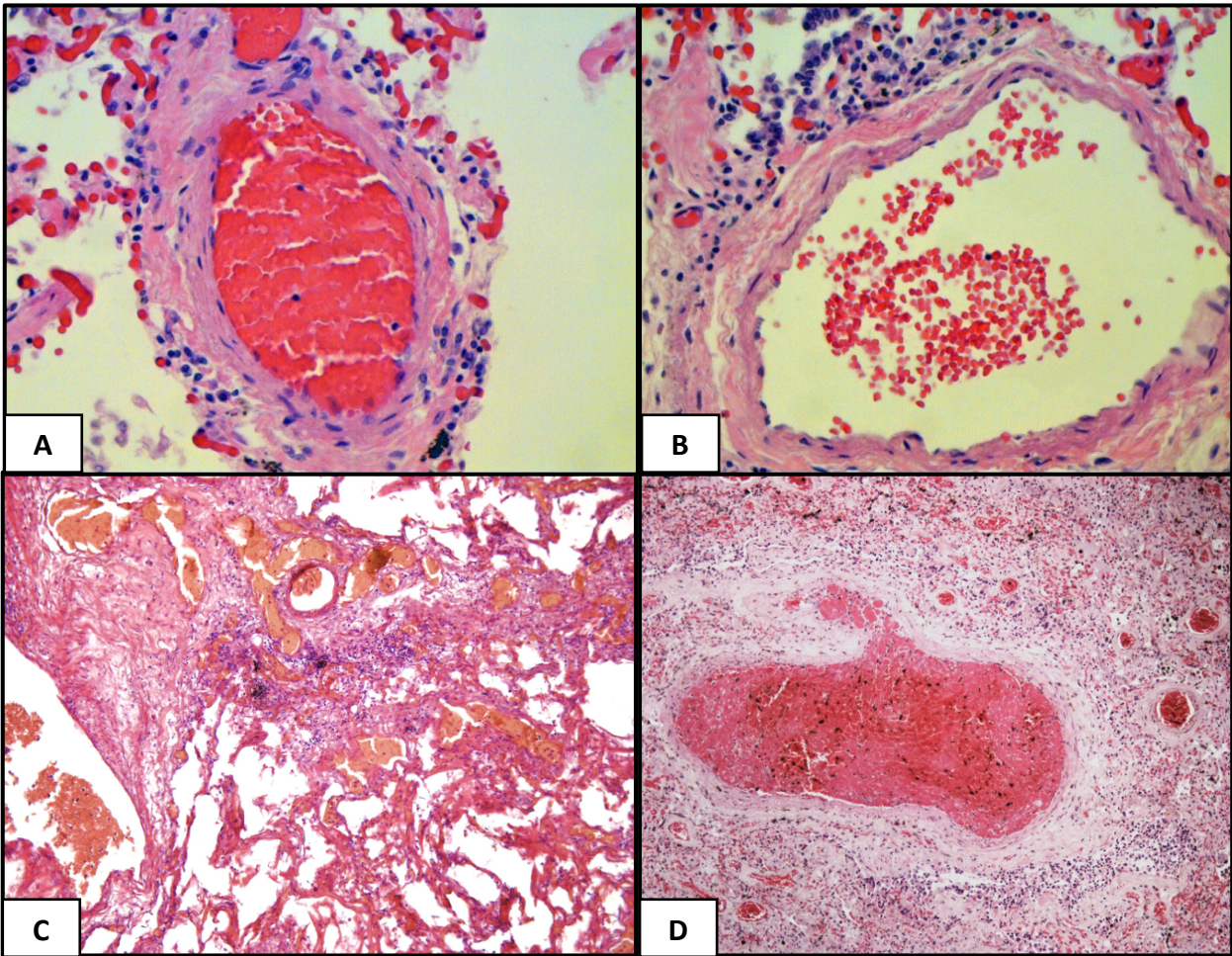


Fig. 5. (H&E). A and B case 1: lymphocytes surrounding and infiltrating the wall of small pulmonary vessels and perivascular fibrosis with transforming fibroblasts.

C and D case 2: intimal thickening of arteriole walls and lymphocytic infiltration and presence of numerous perivascular lymphocytic infiltrates.