

## Expert opinion on managing chronic HCV in patients with mixed cryoglobulinaemia vasculitis

Anna Linda Zignego, Jean-Michel Pawlotsky, Mark Bondin, Patrice Cacoub

► **To cite this version:**

Anna Linda Zignego, Jean-Michel Pawlotsky, Mark Bondin, Patrice Cacoub. Expert opinion on managing chronic HCV in patients with mixed cryoglobulinaemia vasculitis. *Antiviral Therapy, International Medical Press*, 2018, 23 (Suppl 2), pp.1-9. 10.3851/IMP3246 . hal-01981579

**HAL Id: hal-01981579**

**<https://hal.sorbonne-universite.fr/hal-01981579>**

Submitted on 15 Jan 2019

**HAL** is a multi-disciplinary open access archive for the deposit and dissemination of scientific research documents, whether they are published or not. The documents may come from teaching and research institutions in France or abroad, or from public or private research centers.

L'archive ouverte pluridisciplinaire **HAL**, est destinée au dépôt et à la diffusion de documents scientifiques de niveau recherche, publiés ou non, émanant des établissements d'enseignement et de recherche français ou étrangers, des laboratoires publics ou privés.

# Review

## Expert opinion on managing chronic HCV in patients with mixed cryoglobulinaemia vasculitis

Anna Linda Zignego<sup>1</sup>, Jean-Michel Pawlotsky<sup>2,3</sup>, Mark Bondin<sup>4</sup>, Patrice Cacoub<sup>5,6,7,8,\*</sup>

<sup>1</sup>Department of Clinical and Experimental Medicine, Interdepartmental Hepatology Center MASVE, University of Florence, Florence, Italy

<sup>2</sup>National Reference Center for Viral Hepatitis B, C and D, Department of Virology, Hôpital Henri Mondor, Université Paris-Est, Créteil, France

<sup>3</sup>INSERM U955, Créteil, France

<sup>4</sup>AbbVie, Inc., Chicago, IL, USA

<sup>5</sup>Sorbonne Universités, UPMC Univ Paris 06, UMR 7211, and Inflammation-Immunopathology-Biotherapy Department (DHU i2B), Paris, France

<sup>6</sup>INSERM, UMR\_S 959, F-75013, Paris, France

<sup>7</sup>CNRS, FRE3632, F-75005, Paris, France

<sup>8</sup>AP-HP, Groupe Hospitalier Pitié-Salpêtrière, Department of Internal Medicine and Clinical Immunology, F-75013, Paris, France

\*Corresponding author e-mail: [patrice.cacoub@aphp.fr](mailto:patrice.cacoub@aphp.fr)

## Abstract

Mixed cryoglobulinaemia vasculitis (CryoVas) is a small-vessel systemic vasculitis caused by deposition of mixed cryoglobulins and is characterized by a wide range of clinical symptoms. HCV is the primary cause of CryoVas, which is associated with significant morbidity and mortality. The mortality rate among patients with HCV-associated CryoVas is 3× that of the general population, with a 63% 10-year survival rate. First-line treatment for CryoVas is anti-HCV therapy because viral clearance is associated with clinical improvement. The introduction of highly effective, interferon-free, direct-acting antiviral regimens provides additional treatment options for these patients. Here, we review recent studies investigating the effect of antiviral therapy on HCV-associated CryoVas and provide expert opinion for health-care professionals managing these patients.

## Introduction

Mixed cryoglobulinaemia vasculitis (CryoVas) is a small-vessel systemic vasculitis caused by deposition of circulating immunoglobulins (Igs) called mixed cryoglobulins. Mixed cryoglobulins consist of polyclonal IgG and either monoclonal or polyclonal IgM with rheumatoid factor activity. CryoVas affects different organs and disease expression can range from mild clinical symptoms to life-threatening complications [1]. Patients exhibiting clinical symptoms associated with the disease should be considered for a diagnosis of CryoVas, which

is confirmed by testing for Igs that precipitate from serum when it is cooled to below core body temperature and resolubilize when the serum is rewarmed [1].

Infection with HCV has been identified as the main cause for CryoVas. HCV plays a primary role in the development of the immune complexes that initiate tissue damage, and over 90% of patients with CryoVas were infected with HCV [2–4]. Due to the causative association, testing for HCV in patients with CryoVas is necessary, and screening for CryoVas in HCV-infected patients with signs and symptoms of CryoVas is an important consideration in managing the disease.

## **Why should we treat HCV-infected patients suffering from CryoVas?**

HCV infection is highly prevalent in patients with CryoVas and mixed cryoglobulins are present in 25–45% of patients with HCV [4,5]. A minority of patients with HCV and mixed cryoglobulins exhibit symptomatic CryoVas, which is present in approximately 10–35% of patients who are HCV-positive and cryoglobulin-positive [4,5]. CryoVas has a variety of clinical features, which range from rare to highly prevalent, affecting mainly the skin, joints, peripheral nervous system and kidneys (Table 1). Symptoms are often initially mild, with fatigue, palpable purpura and arthralgia as the most common symptoms [6]. The disease may progress to more severe symptoms, including life-threatening widespread vasculitis with glomerulonephritis, or central nervous system, heart or gut involvement. The skin is where symptoms are most frequently exhibited, usually as purpura, though chronic cutaneous ulcers may follow [7]. The purpura begins in the lower limbs, with spread to the lower abdominal area, trunk and upper limbs occurring less frequently [1,7]. Joint pain is typically bilateral and symmetric, involving knees and hands [1]. A range of neurological manifestations can result, but the most frequently described neurological manifestation is a distal sensory or sensory–motor polyneuropathy, usually presenting as a painful, asymmetric paraesthesia, later becoming symmetric [7]. Renal involvement occurs in approximately 30% of patients, most frequently as acute or chronic type-I membranoproliferative glomerulonephritis [1].

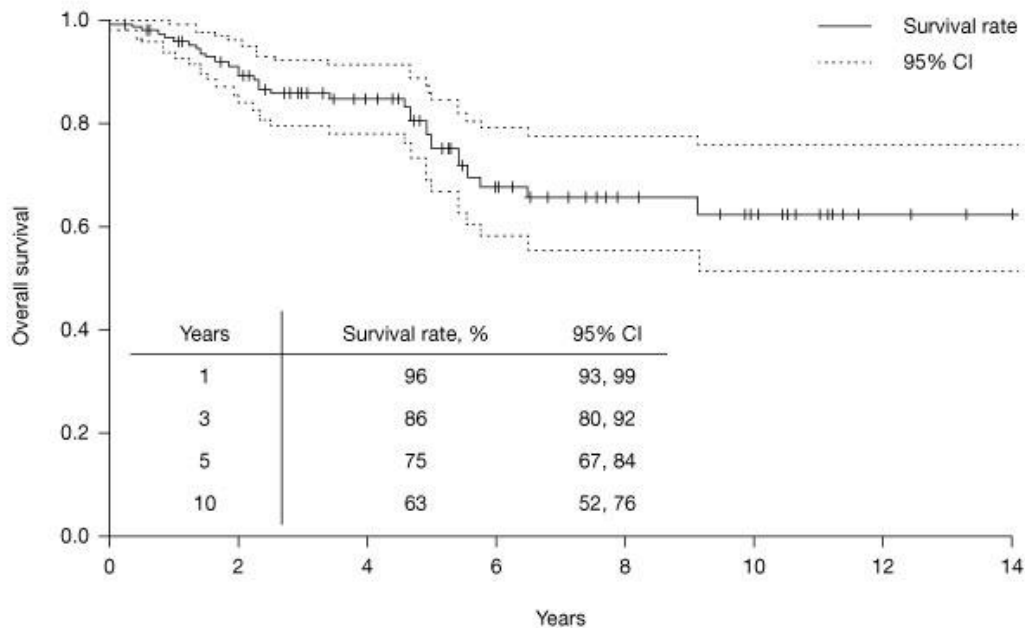
**Table 1.** Clinical features of mixed cryoglobulinaemia vasculitis associated with HCV infection [6]

Clinical features	Prevalence, % <sup>a</sup>
Purpura	98
Weakness	98
Arthralgia	91
Peripheral neuropathy	81
Liver involvement	73
Sicca syndrome	51
Raynaud's phenomenon	32
Renal involvement	31
B-cell NHL	11
Arthritis (non-erosive)	8
Hepatocellular carcinoma	3

Reprinted with permission from Hepatitis C virus syndrome: a constellation of organ- and non-organ specific autoimmune disorders, B-cell non-hodgkin's lymphoma, and cancer by Ferri C, Sebastiani M, Giuggioli D, *et al.* (2015) in *World J Hepatol* 7:327–343. <sup>a</sup>Prevalence calculated in 100 consecutive, unselected Italian patients with mixed cryoglobulinaemia (92% had chronic HCV infection) evaluated at the end of follow-up. NHL, non-Hodgkin lymphoma.

HCV-associated CryoVas is linked to significant morbidity and mortality [1,8]. In a study of 151 consecutive French patients with HCV-associated vasculitis, patients had a poor long-term prognosis (Figure 1). There were 32 deaths, which were predominately due to serious infection and/or end-stage liver disease, and the observed death rate was nearly 3× that of the expected mortality rate compared with age- and sex-matched individuals from the overall French population (standardized mortality ratio 2.7; 95% CI 1.8, 3.9) [8]. Among HCV-infected patients with CryoVas, the 1-year survival rate was 96%, the 3-year rate was 86%, the 5-year rate was 75% and the 10-year rate was 63% [8]. In multivariate analysis, severe fibrosis (hazard ratio [HR] 10.8, 95% CI 3.6, 32.1;  $P < 0.0001$ ) and the Five-Factors Score (FFS) vasculitis scoring system (HR 2.5, 95% CI 1.3, 4.8;  $P = 0.007$ ) were significantly associated with mortality [8]. The FFS ranges from 1 to 5 with points assigned for the presence of proteinuria (1 g/day), renal insufficiency (serum creatinine level  $> 140 \mu\text{mol/l}$ ), cardiomyopathy, severe gastrointestinal involvement and central nervous system involvement [8].

**Figure 1.** Kaplan–Meier estimates of survival for 151 patients with HCV-related vasculitis [8]



Reprinted with permission from Prognostic factors in patients with hepatitis C virus infection and systemic vasculitis by Terrier B, Semoun O, Saadoun D *et al.* (2011) in *Arthritis Rheum* 63:1748–1757. Patients were followed prospectively between 1993 and 2009 (median 54 months' follow-up).

Cryoglobulinaemia is correlated with longer duration of HCV infection and older age. However, cryoglobulinaemia is associated with advanced fibrosis/cirrhosis in patients with chronic HCV infection, regardless of age or disease duration [9–11].

A 15-year prospective cohort study of HCV-infected patients with either symptomatic CryoVas or no circulating cryoglobulins assessed overall survival, progression of liver disease and cryoglobulin-related complications in these patients [12]. The 15-year cumulative probability of renal insufficiency was significantly greater in HCV-infected patients with CryoVas than in those without CryoVas (33% versus 3%, respectively;  $P < 0.0001$ ) [12]. Patients with cryoglobulinaemic syndrome also had increased cumulative incidence of neurological impairment (31% versus 5%;  $P < 0.0001$ ) and B-cell non-Hodgkin lymphoma (15% versus 7%;  $P = 0.003$ ) [12]. In contrast, patients without CryoVas had a higher cumulative incidence of cirrhosis or hepatocellular carcinoma (25% versus 14%,  $P < 0.005$ ; 20% versus 8%,  $P = 0.003$ , respectively) [12]. The 15-year survival rate was not significantly different between the two groups (70% versus 72%), but patients in both groups who received antiviral therapy lived significantly longer than those who did not receive antiviral therapy [12]. An analysis of 231 Italian patients with CryoVas found a significantly lower survival rate in CryoVas patients (92% HCV-infected) compared with the expected survival of age- and sex-matched patients in the general population. Furthermore, CryoVas patients with renal involvement had increased risk of mortality (HR=2.97;  $P < 0.0001$ ) [13].

Though it is a less common clinical feature, CryoVas patients have an increased risk for the development of B-cell non-Hodgkin lymphoma [6]. In a retrospective study of 1,255 HCV-positive Italian patients with cryoglobulinaemic syndrome, patients were followed

cumulatively for 8,928 patient-years [14]. Overall, 59 patients developed B-cell non-Hodgkin lymphoma, resulting in an incidence rate that was 35× higher in cryoglobulinaemic syndrome patients than in the general population (6.6 versus 0.2 cases, respectively, per 1,000 patients) [14]. There were 20 cases of aggressive B-cell non-Hodgkin lymphoma in cryoglobulinaemic syndrome patients (2.2 cases per 1,000 patients), which was 12× greater than in the general population [14].

## How do we diagnose and treat HCV-infected patients with CryoVas?

### Diagnosis

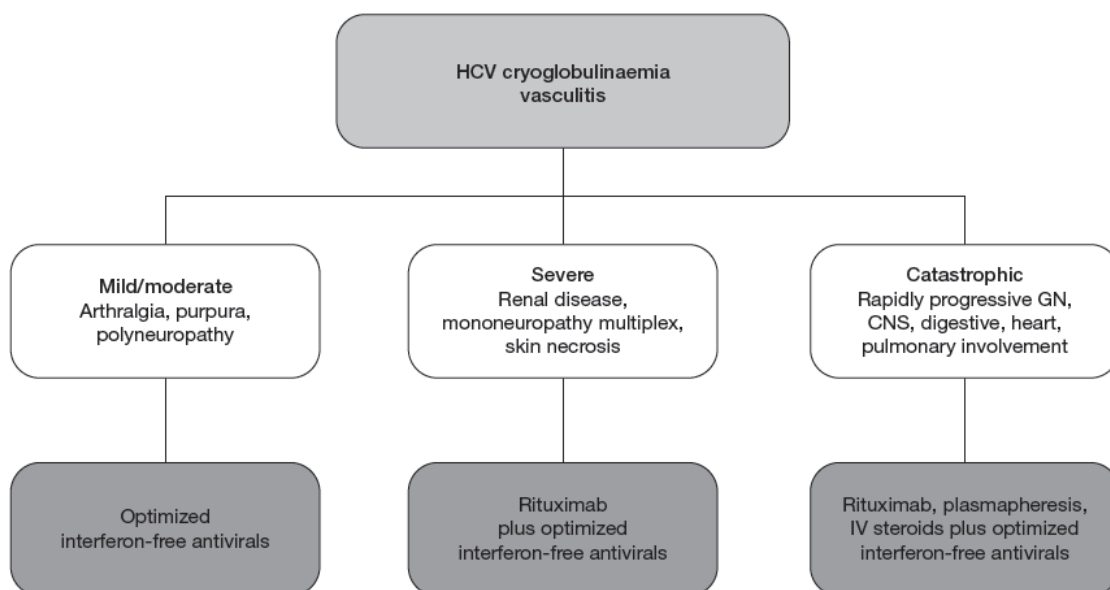
It is important that clinicians are able to recognize HCV-associated CryoVas and other extrahepatic manifestations of chronic HCV infection so that patients can receive timely diagnosis and treatment [15]. A diagnosis of CryoVas should be considered in patients who exhibit clinical features of the condition (Table 1), and further confirmed by the detection of cryoglobulins in the patient's serum [1]. Cryoglobulins are detected by precipitation from a patient's serum after it is cooled to 4°C for 7 days and resolubilization when the patient's serum is warmed back to 37°C [1]. Following detection of cryoglobulins, they are immunochemically categorized into three types: type I, consisting of monoclonal Igs; type II, consisting of a polyclonal IgG bound to a monoclonal IgM with rheumatoid factor activity; and type III, consisting of a polyclonal IgG bound to a polyclonal IgM with rheumatoid factor activity [1,7,16]. Type II and III cryoglobulins are referred to as mixed cryoglobulins, and 70–90% of patients with mixed cryoglobulinaemia have HCV infection [1]. Type I cryoglobulins are highly associated with B-cell lymphoproliferative disease, which can present as either haematological malignancy or a benign B-cell proliferation [1,7]. There are other laboratory tests that provide indirect evidence of cryoglobulinaemia and use markers that are easier to detect than cryoglobulins. These tests include low C4 serum complement fraction, decreased total haemolytic complement levels and presence of rheumatoid factor activity [1].

Diagnostic guidelines proposed by the International Study Group of Extrahepatic Manifestations Related to Hepatitis C Infection (ISG-EHCV) note that because serum mixed cryoglobulin levels may vary between patients, and in a single patient, over the course of the disease, patients with suspected CryoVas may require repeat screenings to avoid a false-negative error [15]. The guidelines also note that low C4 serum level may be a useful screening test [15]. Symptoms of CryoVas may also vary between patients and over the course of the disease, leading to difficulty in differentiating CryoVas from other diseases with overlapping symptoms. Guidelines issued by the ISG-EHCV, suggest using the presence of purpura, weakness, renal involvement, peripheral neuropathy and laboratory alterations in mixed cryoglobulins, low C4 and rheumatoid factor as parameters to differentiate a diagnosis of CryoVas from sicca syndrome, Sjögren's syndrome or rheumatoid arthritis [15]. Given that a relatively small proportion of HCV-infected patients with circulating cryoglobulins exhibit symptoms [4], testing for circulating cryoglobulins, complement, serum creatinine, rheumatoid factor and urinalysis upon initial clinical evaluation would improve the diagnosis rate [17]. However, given current goals to expand treatment availability, careful consideration must be given to the resources required to screen asymptomatic patients who are likely to be treated with a highly effective direct-acting antiviral (DAA) regimen.

## Treatment

Consistent with international guidelines on the treatment of chronic HCV, including both European Association for the Study of the Liver (EASL) and American Association for the Study of Liver Diseases (AASLD) treatment guidelines, treatment should be initiated without delay for patients with clinically significant extrahepatic manifestations of chronic HCV, including symptomatic CryoVas [18–20]. Indeed, patients with HCV-related vasculitis were rated as the highest-priority patients to treat among patients with extrahepatic manifestations [18]. Management of patients with HCV-associated CryoVas should be individualized according to the severity of CryoVas disease [1,21]. A proposed treatment algorithm for HCV-associated CryoVas is shown in Figure 2. Patients with mild-to-moderate CryoVas should be treated with an optimized interferon-free antiviral regimen. In severe cases, rituximab should be administered, with plasmapheresis if necessary, associated with interferon-free antiviral therapy [1]. There are limited treatment options beyond the treatments previously mentioned. Corticosteroids may be used to help control minor inflammatory symptoms, whereas other immunosuppressants should only be given in cases of refractory CryoVas [1,22].

**Figure 2.** Proposed treatment algorithm for HCV-associated mixed cryoglobulinaemia vasculitis [1]



Reprinted with permission from Cryoglobulinemia vasculitis by Cacoub P, Comarmond C, Domont F, *et al.* (2015) in *Am J Med* 128:950–955. CNS, central nervous system; GN, glomerulonephritis; IV, intravenous.



## Impact of treatment

CryoVas generally responds to clearance of HCV, as measured by achievement of a sustained virological response (SVR) [1,21]. A large cohort study of HCV-infected veterans in the United States ( $n=160,875$ ) found that viral clearance with interferon-based therapy (with or without ribavirin) significantly reduced the risk of CryoVas [23]. Patients who achieved SVR were less likely to develop CryoVas than those who did not receive treatment (adjusted HR 0.61, 95% CI 0.39, 0.94;  $P=0.0264$ ) and those who received treatment but did not achieve SVR (adjusted HR 0.55, 95% CI 0.33, 0.90;  $P=0.0170$ ) [23]. Initial studies with first-generation DAAs (for example, telaprevir or boceprevir) with pegylated interferon and ribavirin showed interesting results, although concerns about safety limited their use [24]. In a prospective, controlled cohort study of HCV-infected patients with or without CryoVas treated with pegylated interferon and ribavirin, the rate of SVR 24 weeks after the end of treatment (SVR24) was 61% among patients without CryoVas and was significantly lower in patients with CryoVas, at 49% ( $P=0.014$ ) [25]. Despite suboptimal efficacy, the majority (57% [36/63]) of patients with HCV-associated CryoVas who achieved an SVR24 had a complete clinical response (an improvement in all baseline clinical manifestations of CryoVas), whereas most others (40% [25/63]) had a partial clinical response (an improvement in at least half of the baseline clinical manifestations of CryoVas) at the end of long-term follow-up (mean follow-up of 92.5 months) [25]. A further open-label prospective cohort study evaluated the efficacy of pegylated interferon- $\alpha$  with ribavirin and a protease inhibitor (telaprevir or boceprevir) in HCV-infected patients with CryoVas [26]. Again, the SVR24 rate was suboptimal at 70% (16/23), but all patients had a clinical response of CryoVas, either complete (57% [13/23]) or partial (43% [10/23]) [26]. Discontinuation of antiviral therapy was required in 35% (8/23) of patients, and addition of the protease inhibitor to the regimen was associated with increased rates of anaemia, fatigue and infections compared with a similar study of pegylated interferon- $\alpha$  with ribavirin alone [26,27]. Furthermore, in a cohort of patients with severe liver disease, treatment with interferon-based triple therapy using a first-generation protease inhibitor was less effective in patients with CryoVas than in patients without CryoVas [28]. The introduction of interferon-free, DAA-based combinations has improved treatment efficacy, resulting in SVR rates greater than 90% and a very good safety profile, including in patients previously considered difficult to treat [24]. Studies of patients with HCV-associated CryoVas treated with DAAs have shown that CryoVas clinical response is also associated with SVR (Table 2). In the first prospective, open-labelled VASCUVALDIC study of 24 patients treated with sofosbuvir and ribavirin for 24 weeks, 74% (17/23) achieved SVR 12 weeks after the end of treatment (SVR12), whereas a complete clinical response was achieved by most patients (87% [20/23]) at 12 weeks post treatment [29]. Notably, purpura, skin ulcers and arthralgia disappeared in all cases, whereas renal involvement improved in four out of five cases [29]. Currently, sofosbuvir plus ribavirin is not widely used due to lower SVR rates compared with combination DAA therapies. In a prospective study of guideline-tailored, sofosbuvir-based DAA therapy (sofosbuvir plus ribavirin, or sofosbuvir plus simeprevir, daclatasvir or ledipasvir, with or without ribavirin) in 44 patients with HCV-associated CryoVas, all patients achieved SVR12 and SVR24 [30]. At the SVR24 time point, all patients had a CryoVas clinical response; 36% were full-complete responders (cleared all clinical manifestations of CryoVas), 41% were complete responders and 23% were partial responders [30]. In an open-label, prospective, multicentre study of 41 French patients with HCV-associated CryoVas treated with sofosbuvir plus daclatasvir for 12 or 24 weeks, all patients achieved SVR12 [31]. At week 24 of the study (SVR12 or end of treatment, depending on assigned treatment duration), 90% of patients had complete clinical response and 10% had partial clinical response [31]. Of note, this study also showed that



DAA-based therapy restored disturbances in peripheral B- and T-cell homeostasis [32]. A Spanish prospective study evaluated 64 HCV-infected patients with circulating cryoglobulins (either with CryoVas [ $n=35$ ] or asymptomatic circulating cryoglobulins [ $n=29$ ]) who received therapy with a DAA-containing regimen [33]. In the overall population, 94% (60/64) of patients achieved SVR12, and among patients with symptomatic CryoVas, 71% (25/35) achieved complete clinical response and 14% (5/35) had partial response [33]. A similarly high SVR rate was observed in a real-world, retrospective chart review of CryoVas patients treated with DAA-based regimens in the HCV-TARGET database [34]. The SVR rate in CryoVas patients was 92% (54/59), and among the 27 SVR patients with sufficient follow-up information, 19 (61%) had resolution of CryoVas symptoms [34]. In a retrospective case series of 12 HCV-infected patients with CryoVas who were treated with sofosbuvir-based regimens, the 83% (10/12) SVR12 rate was higher than the historical control group of CryoVas patients treated with pegylated interferon plus ribavirin (10% [1/10]) [35]. In the sofosbuvir-based treatment cohort, patients with evidence of renal involvement who achieved SVR12 had improvement in serum creatinine and reduction in proteinuria [35]. High SVR rates and a strong correlation between virological and clinical response were observed in a study using, in most cases (11 out of 17 patients), non-sofosbuvir-based therapy (paritaprevir/ritonavir, ombitasvir and dasabuvir, with or without ribavirin) [36].

**Table 2.** Outcomes of cryoglobulinaemia in patients with chronic hepatitis C treated with DAA regimens

Reference	DAA regimen	SVR rate, %	Clinical response, %
VASCUALDIC [29] ( $n=24$ )	SOF/RBV	74	88 <sup>a</sup>
Graggani <i>et al.</i> [30] ( $n=44$ )	SOF plus RBV, SIM, DAC or LDV	100	77 <sup>b</sup>
Saadoun <i>et al.</i> [31] ( $n=41$ )	SOF/DAC	100	90 <sup>a</sup>
Bonacci <i>et al.</i> [33] ( $n=64$ )	Not specified	94	71 <sup>c</sup>
Cristin <i>et al.</i> [34] ( $n=64$ )	Not specified	92	61 <sup>d</sup>

<sup>a</sup> Defined as improvement in all affected organs and the absence of clinical relapse. <sup>b</sup> 36% of patients had a full-complete response (cleared all clinical manifestations of cryoglobulinaemia vasculitis [CryoVas]), 41% had a complete response (improvement in all clinical manifestations), 23% had partial improvement. <sup>c</sup> Birmingham Vasculitis Activity Score =0, or all affected organs improved. <sup>d</sup> Resolution of all manifestations. DAA, direct-acting antiviral; DAC, daclatasvir; LDV, ledipasvir; RBV, ribavirin; SIM, simeprevir; SOF, sofosbuvir; SVR, sustained virological response.

In addition to eradication of HCV with interferon- or DAA-based therapies, immunotherapy with rituximab has also been shown to significantly reduce vasculitis disease activity in patients with severe CryoVas. Rituximab is a chimeric monoclonal antibody that binds to the CD20 antigen, a transmembrane protein selectively expressed on pre-B and mature lymphocytes [4]. CD20-positive cells are expanded and activated in CryoVas patients [37,38]. In a randomized controlled trial of rituximab versus conventional treatment (glucocorticoids, azathioprine or cyclophosphamide, or plasmapheresis) in 59 patients with severe CryoVas, only treatment with rituximab was shown to significantly reduce the mean Birmingham Vasculitis Activity Score (BVAS) from baseline ( $11.9 \pm 5.4$  [standard deviation (SD)]) up to month 24 ( $4.4 \pm 4.6$  [SD];  $P < 0.0001$ ) [39]. The BVAS ranges from 0 (remission) to 68 and includes scores assigned for general symptoms (arthralgia, arthritis and fever) and major organ involvement (skin, mucous membranes, ear/nose/throat, cardiovascular, pulmonary,

gastrointestinal, renal, nervous system). Persistent symptoms or manifestations at each site are assigned 1 point and new or worsening symptoms are assigned 2 points [36]. In this study, 93% (53/57) of patients were infected with HCV but were ineligible for antiviral therapy due to prior treatment failure or because treatment was contraindicated. Other studies have shown that rituximab improves patient outcomes when combined with antiviral treatment. A prospective cohort study of patients with HCV-associated CryoVas treated with pegylated interferon- $\alpha$  plus ribavirin found that patients who received rituximab prior to antiviral therapy had a shorter time to clinical remission ( $5.4 \pm 4.0$  [SD] months versus  $8.4 \pm 4.7$  [SD] months in patients who did and did not receive rituximab, respectively;  $P=0.004$ ) and had better renal response rates (81% versus 40% complete response;  $P=0.04$ ) [27]. In a similar prospective, single-centre, randomized study of pegylated interferon- $\alpha$  plus ribavirin with or without rituximab, 55% (12/22) of patients who received rituximab achieved complete response, compared with 33% (5/15) of patients who received pegylated interferon- $\alpha$  plus ribavirin alone ( $P<0.05$ ) [40]. The use of rituximab in CryoVas patients with advanced liver disease was not only safe but also associated with a consistent clinical improvement in hepatic function in patients with decompensated cirrhosis [41].

## Challenges in managing HCV and CryoVas

A significant challenge in treating patients with CryoVas is curing HCV infection in those with severe renal impairment (glomerular filtration rate  $<30$  ml/min/1.73 m<sup>2</sup>) or end-stage renal disease (ESRD) requiring dialysis [42]. The safety of sofosbuvir-based regimens has not been assessed in patients with severe renal impairment or ESRD, and these regimens are not indicated for treatment in these patients [43–46]. EASL and AASLD guidelines do not recommend sofosbuvir-containing regimens for patients with severe renal impairment or ESRD; the guidelines do recommend the cautious use of ribavirin only at a reduced dose and with haematopoietic monitoring [19,20]. For HCV GT1-infected patients, EASL guidelines recommend the combination of ritonavir-boosted paritaprevir, ombitasvir and dasabuvir or the combination of grazoprevir and elbasvir (both regimens without ribavirin for GT1b and with reduced-dose ribavirin for GT1a) [20]. For HCV GT4-infected patients, EASL guidelines recommend the combination of ritonavir-boosted paritaprevir and ombitasvir with reduced-dose ribavirin or the combination of grazoprevir and elbasvir without ribavirin [20]. For patients infected with HCV GT2 or GT3 who are in urgent need of treatment, EASL guidelines recommend the combination of sofosbuvir and velpatasvir or sofosbuvir and daclatasvir for GT2-infected patients and sofosbuvir and velpatasvir without ribavirin or sofosbuvir and daclatasvir with ribavirin for GT3-infected patients; renal function should be monitored in these patients and treatment interrupted immediately in the case of deterioration [20].

Several regimens have pangenotypic anti-HCV activity including the combination of sofosbuvir plus daclatasvir, which must be prescribed separately, and three fixed-dose combination regimens (sofosbuvir/velpatasvir, sofosbuvir/velpatasvir/voxilaprevir and glecaprevir/pibrentasvir). The latter two were recently approved in both the European Union and the United States [46–49]. It should be noted that sofosbuvir/velpatasvir/voxilaprevir is approved for both treatment-naïve and -experienced patients in the EU, whereas in the United States it is approved only as a salvage regimen for patients who have not responded to other DAA-containing regimens [46,47]. No dose adjustment of glecaprevir and pibrentasvir is required in patients with any degree of renal impairment, including those on dialysis [48,49], providing an additional option for CryoVas patients with severe renal impairment or ESRD.

Moreover, the combination of glecaprevir and pibrentasvir has been evaluated in patients with HCV genotype 1–6 infection and CKD stage 4–5 disease [50]. The overall SVR rate was 98%, which demonstrates that this combination has pangenotypic activity and is effective in patients with severe renal impairment.

Additionally, as the introduction of highly effective HCV therapies has increased the pool of CryoVas patients who have eradicated HCV, a small but significant population of patients who have CryoVas or have persistence of circulating cryoglobulins without CryoVas despite being cured of HCV are being identified. Studies of HCV-infected patients treated with interferon-based regimens have shown that a minority of patients who achieved viral eradication did not have a complete recovery of CryoVas-related symptoms and experienced persistence or relapse of CryoVas [51,52]. In most patients, relapse occurred shortly after interferon-based antiviral treatment was stopped, and symptoms were less severe and short-lived [52]. More recent clinical trials of DAA regimens have shown that persistence of CryoVas was rare after HCV clearance (0–3%) [25,30,31]. Available data suggest that the degree of reversibility of CryoVas is inversely correlated with the degree of lymphoproliferative disorder evolution and/or of organ damage, indicating that the eradication of HCV infection is needed as early as possible [53]. The long-term follow-up of such patients is mandatory, particularly to detect the appearance of non-Hodgkin lymphoma. Low- or medium-dose glucocorticoids, cyclophosphamide, mycophenolate mofetil, anti-CD20 antibodies rituximab or ofatumumab, or anti-B-cell activating factor antibody belimumab are potential second-line therapies for patients who have cleared HCV but continue to show symptoms of CryoVas [4,54].

## Unmet needs

An unmet need in the treatment of HCV-associated CryoVas is patients receiving early treatment. Patients in the early stage of HCV infection exhibiting symptoms of CryoVas may be considered less urgent to treat, despite the association of HCV clearance and resolution of symptoms. A cohort study of veterans in the United States treated with interferon-based therapy found that the protective effect of SVR against certain extrahepatic manifestations, such as glomerulonephritis and non-Hodgkin lymphoma, was lessened as the time from HCV diagnosis to initiation of HCV therapy increased [20]. To ensure that all CryoVas patients are eligible for HCV therapy, treatment options that include interferon-free, and ideally ribavirin-free, regimens are needed. Furthermore, it is important to ensure adequate follow-up for HCV-infected patients with CryoVas to rule out inadequate response or relapse. The long-term follow-up of patients with HCV cure and positive circulating cryoglobulins is mandatory, considering the risk of developing non-Hodgkin lymphoma.

## Conclusions

CryoVas is closely associated with HCV infection, and HCV eradication through antiviral therapy is the key therapeutic approach to be performed. Studies have shown that patients with HCV-associated CryoVas who achieved HCV eradication also achieved a complete or partial clinical reduction in CryoVas symptoms. The introduction of high-efficacy, interferon-free DAA regimens have led to more treatment options and higher virological, clinical and immunological response rates and have expanded the pool of CryoVas patients able to be treated. Also, immunotherapy with first-generation anti-CD20 drugs (rituximab), or future

second- or third-generation anti-CD20 drugs, in addition to antiviral therapy is an option for patients with severe CryoVas. Most HCV-infected patients with circulating cryoglobulins do not exhibit symptomatic disease, but the high correlation between HCV viral clearance and clinical response of CryoVas demonstrates the importance of the diagnosis and treatment of HCV-associated CryoVas. Patients with symptomatic disease that persists after antiviral therapy remain candidates for immunotherapy. As the pool of patients cleared of HCV with high-efficacy DAAs grows, the frequency of patients with persistence or relapse of CryoVas-associated symptoms after viral eradication will need to be monitored and optimized treatment options assessed.

## Acknowledgements

Medical editing support was provided by Scott Battle of Medical Expressions (Chicago, IL, USA), funded by AbbVie.

## Disclosure statement

ALZ: received consulting and lecturing fees from AbbVie, Bristol-Myers Squibb, Gilead, Merck Sharp & Dohme. J-MP: grants – Abbott, AbbVie, Gilead; advisor – Abbott, AbbVie, Gilead, Merck; lectures – Abbott, AbbVie, Gilead, Merck. MB: employee of AbbVie and may hold stock or options. PC: received consulting and lecturing fees from AbbVie, AstraZeneca, Bristol-Myers Squibb, Gilead, GlaxoSmithKline, Janssen, Merck Sharp & Dohme, Roche, Servier and Vifor; received grants from CNRS, INSERM, Université Pierre et Marie Curie, ANRS and WHO.

## References

1. Cacoub P, Comarmond C, Domont F, Savey L, Saadoun D. Cryoglobulinemia vasculitis. *Am J Med* 2015; **128**:950-955. [Medline doi:10.1016/j.amjmed.2015.02.017](#)
2. Agnello V, Chung RT, Kaplan LM. A role for hepatitis C virus infection in type II cryoglobulinemia. *N Engl J Med* 1992; **327**:1490-1495. [Medline doi:10.1056/NEJM199211193272104](#)
3. Misiiani R, Bellavita P, Fenili D, *et al.* Hepatitis C virus infection in patients with essential mixed cryoglobulinemia. *Ann Intern Med* 1992; **117**:573-577. [Medline doi:10.7326/0003-4819-117-7-573](#)
4. Dammacco F, Sansonno D. Therapy for hepatitis C virus-related cryoglobulinemic vasculitis. *N Engl J Med* 2013; **369**:1035-1045. [Medline doi:10.1056/NEJMra1208642](#)
5. PITER collaborating group. Kondili LA, Vella S, Zignego AL. Mixed cryoglobulinaemia: an important but frequently unrecognized and underestimated HCV-related condition in the real life practice. *Liver Int* 2018; **38**:183 [Medline doi:10.1111/liv.13490](#)
6. Ferri C, Sebastiani M, Giuggioli D, *et al.* Hepatitis C virus syndrome: a constellation of organ- and non-organ specific autoimmune disorders, B-cell non-hodgkin's lymphoma, and cancer. *World J Hepatol* 2015; **7**:327-343. [Medline doi:10.4254/wjh.v7.i3.327](#)
7. Terrier B, Cacoub P. Cryoglobulinemia vasculitis: an update. *Curr Opin Rheumatol* 2013; **25**:10-18. [Medline doi:10.1097/BOR.0b013e32835b15f7](#)

8. Terrier B, Semoun O, Saadoun D, Sene D, Resche-Rigon M, Cacoub P. Prognostic factors in patients with hepatitis C virus infection and systemic vasculitis. *Arthritis Rheum* 2011; **63**:1748-1757. [Medline doi:10.1002/art.30319](#)
9. Kayali Z, Buckwold VE, Zimmerman B, *et al.* Hepatitis C, cryoglobulinemia, and cirrhosis: a meta-analysis. *Hepatology* 2002; **36**:978-985. [Medline doi:10.1053/jhep.2002.35620](#)
10. Siagris D, Christofidou M, Tsamandas A, *et al.* Cryoglobulinemia and progression of fibrosis in chronic HCV infection: cause or effect? *J Infect* 2004; **49**:236-241. [Medline doi:10.1016/j.jinf.2004.05.002](#)
11. Saadoun D, Asselah T, Resche-Rigon M, *et al.* Cryoglobulinemia is associated with steatosis and fibrosis in chronic hepatitis C. *Hepatology* 2006; **43**:1337-1345. [Medline doi:10.1002/hep.21190](#)
12. Lauletta G, Russi S, Conteduca V, Sansonno L, Dammacco F, Sansonno D. Impact of cryoglobulinemic syndrome on the outcome of chronic hepatitis C virus infection: a 15-year prospective study. *Medicine (Baltimore)* 2013; **92**:245-256. [Medline doi:10.1097/MD.0b013e31829d2abc](#)
13. Ferri C, Sebastiani M, Giuggioli D, *et al.* Mixed cryoglobulinemia: demographic, clinical, and serologic features and survival in 231 patients. *Semin Arthritis Rheum* 2004; **33**:355-374. [Medline doi:10.1016/j.semarthrit.2003.10.001](#)
14. Monti G, Pioltelli P, Saccardo F, *et al.* Incidence and characteristics of non-Hodgkin lymphomas in a multicenter case file of patients with hepatitis C virus-related symptomatic mixed cryoglobulinemias. *Arch Intern Med* 2005; **165**:101-105. [Medline doi:10.1001/archinte.165.1.101](#)
15. Ferri C, Ramos-Casals M, Zignego AL, *et al.* International diagnostic guidelines for patients with HCV-related extrahepatic manifestations. A multidisciplinary expert statement. *Autoimmun Rev* 2016; **15**:1145-1160. [Medline doi:10.1016/j.autrev.2016.09.006](#)
16. Brouet JC, Clauvel JP, Danon F, Klein M, Seligmann M. Biologic and clinical significance of cryoglobulins. A report of 86 cases. *Am J Med* 1974; **57**:775-788. [Medline doi:10.1016/0002-9343\(74\)90852-3](#)
17. Zignego AL, Ferri C, Pileri SA, Caini P, Bianchi FB. Italian Association of the Study of Liver Commission on Extrahepatic Manifestations of HCV infection. Extrahepatic manifestations of hepatitis C virus infection: a general overview and guidelines for a clinical approach. *Dig Liver Dis* 2007; **39**:2-17. [Medline doi:10.1016/j.dld.2006.06.008](#)
18. Ramos-Casals M, Zignego AL, Ferri C, *et al.* Evidence-based recommendations on the management of extrahepatic manifestations of chronic hepatitis C virus infection. *J Hepatol* 2017; **66**:1282-1299. [Medline doi:10.1016/j.jhep.2017.02.010](#)
19. AASLD-IDSA. HCV guidance: recommendations for testing, managing, and treating hepatitis C. (Updated 21 September 2017. Accessed 9 January 2018.) Available from <http://www.hcvguidelines.org>
20. European Association for the Study of the Liver. EASL recommendations on treatment of hepatitis C 2016. *J Hepatol* 2017; **66**:153-194. [Medline doi:10.1016/j.jhep.2016.09.001](#)
21. Zignego AL, Ramos-Casals M, Ferri C, *et al.* International therapeutic guidelines for patients with HCV-related extrahepatic disorders. A multidisciplinary expert statement. *Autoimmun Rev* 2017; **16**:523-541. [Medline doi:10.1016/j.autrev.2017.03.004](#)
22. Saadoun D, Pineton de Chambrun M, Hermine O, *et al.* Using rituximab plus fludarabine and cyclophosphamide as a treatment for refractory mixed cryoglobulinemia associated with lymphoma. *Arthritis Care Res (Hoboken)* 2013; **65**:643-647. [Medline doi:10.1002/acr.21856](#)
23. Mahale P, Engels EA, Li R, *et al.* The effect of sustained virological response on the risk of extrahepatic manifestations of hepatitis C virus infection. *Gut* 2018; **67**:553-561. [Medline doi:10.1136/gutjnl-2017-313983](#)



24. Manns MP, Buti M, Gane E, *et al.* Hepatitis C virus infection. *Nat Rev Dis Primers* 2017; **3**:17006 [Medline doi:10.1038/nrdp.2017.6](#)
25. Gragnani L, Fognani E, Piluso A, *et al.* Long-term effect of HCV eradication in patients with mixed cryoglobulinemia: a prospective, controlled, open-label, cohort study. *Hepatology* 2015; **61**:1145-1153. [Medline doi:10.1002/hep.27623](#)
26. Saadoun D, Resche Rigon M, Thibault V, *et al.* Peg-IFNalpha/ribavirin/protease inhibitor combination in hepatitis C virus associated mixed cryoglobulinemia vasculitis: results at week 24. *Ann Rheum Dis* 2014; **73**:831-837. [Medline doi:10.1136/annrheumdis-2012-202770](#)
27. Saadoun D, Resche Rigon M, Sene D, *et al.* Rituximab plus peg-interferon-alpha/ribavirin compared with peg-interferon-alpha/ribavirin in hepatitis C-related mixed cryoglobulinemia. *Blood* 2010; **116**:326-334, quiz 504–505. [Medline doi:10.1182/blood-2009-10-248518](#)
28. Gragnani L, Fabbrizzi A, Triboli E, *et al.* Triple antiviral therapy in hepatitis C virus infection with or without mixed cryoglobulinaemia: a prospective, controlled pilot study. *Dig Liver Dis* 2014; **46**:833-837. [Medline doi:10.1016/j.dld.2014.05.017](#)
29. Saadoun D, Thibault V, Si Ahmed SN, *et al.* Sofosbuvir plus ribavirin for hepatitis C virus-associated cryoglobulinaemia vasculitis: VASCUVALDIC study. *Ann Rheum Dis* 2016; **75**:1777-1782. [Medline doi:10.1136/annrheumdis-2015-208339](#)
30. Gragnani L, Visentini M, Fognani E, *et al.* Prospective study of guideline-tailored therapy with direct-acting antivirals for hepatitis C virus-associated mixed cryoglobulinemia. *Hepatology* 2016; **64**:1473-1482. [Medline doi:10.1002/hep.28753](#)
31. Saadoun D, Pol S, Ferfar Y, *et al.* Efficacy and safety of sofosbuvir plus daclatasvir for treatment of HCV-associated cryoglobulinemia vasculitis. *Gastroenterology* 2017; **153**:49-52.e5. [Medline doi:10.1053/j.gastro.2017.03.006](#)
32. Comarmond C, Garrido M, Pol S, *et al.* Direct-acting antiviral therapy restores immune tolerance to patients with hepatitis C virus-induced cryoglobulinemia vasculitis. *Gastroenterology* 2017; **152**:2052-2062.e2. [Medline doi:10.1053/j.gastro.2017.02.037](#)
33. Bonacci M, Lens S, Londono MC, *et al.* Virologic, clinical, and immune response outcomes of patients with hepatitis C virus-associated cryoglobulinemia treated with direct-acting antivirals. *Clin Gastroenterol Hepatol* 2017; **15**:575-583.e1. [Medline doi:10.1016/j.cgh.2016.09.158](#)
34. Cristin D, Weiland AC, Langess J, *et al.* Treatment of HCV-induced cryoglobulinemic vasculitis with new direct acting antiviral (DAA) regimens. *Hepatology* 2017; **66**:613A
35. Sise ME, Bloom AK, Wisocky J, *et al.* Treatment of hepatitis C virus-associated mixed cryoglobulinemia with direct-acting antiviral agents. *Hepatology* 2016; **63**:408-417. [Medline doi:10.1002/hep.28297](#)
36. Gragnani L, Piluso A, Urraro T, *et al.* Virological and clinical response to interferon-free regimens in patients with HCV-related mixed cryoglobulinemia: preliminary results of a prospective pilot study. *Curr Drug Targets* 2017; **18**:772-785. [Medline doi:10.2174/1389450117666160208145432](#)
37. Fan HB, Zhu YF, Chen AS, *et al.* B-cell clonality in the liver of hepatitis C virus-infected patients. *World J Gastroenterol* 2009; **15**:1636-1640. [Medline doi:10.3748/wjg.15.1636](#)
38. Charles ED, Brunetti C, Marukian S, *et al.* Clonal B cells in patients with hepatitis C virus-associated mixed cryoglobulinemia contain an expanded anergic CD21low B-cell subset. *Blood* 2011; **117**:5425-5437. [Medline doi:10.1182/blood-2010-10-312942](#)
39. De Vita S, Quartuccio L, Isola M, *et al.* A randomized controlled trial of rituximab for the treatment of severe cryoglobulinemic vasculitis. *Arthritis Rheum* 2012; **64**:843-853. [Medline doi:10.1002/art.34331](#)
40. Dammacco F, Tucci FA, Lauletta G, *et al.* Pegylated interferon-alpha, ribavirin, and rituximab combined therapy of hepatitis C virus-related mixed cryoglobulinemia: a long-term study. *Blood* 2010; **116**:343-353. [Medline doi:10.1182/blood-2009-10-245878](#)

41. Petrarca A, Rigacci L, Caini P, *et al.* Safety and efficacy of rituximab in patients with hepatitis C virus-related mixed cryoglobulinemia and severe liver disease. *Blood* 2010; **116**:335-342. [Medline doi:10.1182/blood-2009-11-253948](#)
42. Cacoub P, Desbois AC, Isnard-Bagnis C, Rocatello D, Ferri C. Hepatitis C virus infection and chronic kidney disease: time for reappraisal. *J Hepatol* 2016; **65**:S82-S94. [Medline doi:10.1016/j.jhep.2016.06.011](#)
43. SOVALDI. (sofosbuvir). *Package insert* 2017. Gilead Sciences, Foster City, CA, USA.
44. HARVONI. (ledipasvir and sofosbuvir). *Package insert* 2017. Gilead Sciences, Foster City, CA, USA.
45. EPCLUSA. (sofosbuvir and velpatasvir). *Package insert* 2017. Gilead Sciences, Foster City, CA, USA.
46. VOSEVI. (sofosbuvir, velpatasvir and voxilaprevir). *Summary of Product Characteristics* 2017. Gilead Sciences International Ltd. Cambridge, United Kingdom.
47. VOSEVI. (sofosbuvir, velpatasvir and voxilaprevir). *Package insert* 2017. Gilead Sciences, Foster City, CA, USA.
48. MAVIRET. (glecaprevir and pibrentasvir). *Summary of Product Characteristics* 2017. AbbVie, Ltd, Maidenhead, UK.
49. MAVYRET. (glecaprevir and pibrentasvir). *Package insert* 2017. AbbVie, Inc., North Chicago, IL, USA.
50. Gane E, Lawitz E, Pugatch D, *et al.* Glecaprevir and pibrentasvir in patients with HCV and severe renal impairment. *N Engl J Med* 2017; **377**:1448-1455. [Medline doi:10.1056/NEJMoa1704053](#)
51. Levine JW, Gota C, Fessler BJ, Calabrese LH, Cooper SM. Persistent cryoglobulinemic vasculitis following successful treatment of hepatitis C virus. *J Rheumatol* 2005; **32**:1164-1167. [Medline](#)
52. Landau DA, Saadoun D, Halfon P, *et al.* Relapse of hepatitis C virus-associated mixed cryoglobulinemia vasculitis in patients with sustained viral response. *Arthritis Rheum* 2008; **58**:604-611. [Medline doi:10.1002/art.23305](#)
53. Zignego AL, Gragnani L, Visentini M, Casato M. Reply. *Hepatology* 2017; **65**:1771-1772. [Medline doi:10.1002/hep.28977](#)
54. Ostojic P, Jeremic IR. Managing refractory cryoglobulinemic vasculitis: challenges and solutions. *J Inflamm Res* 2017; **10**:49-54. [Medline doi:10.2147/JIR.S114067](#)