



UNIVERSITÀ
DEGLI STUDI
FIRENZE

FLORE

Repository istituzionale dell'Università degli Studi di Firenze

Life-Threatening Acute Pulmonary Thromboembolism Following Severe Carbon Monoxide Poisoning

Questa è la Versione finale referata (Post print/Accepted manuscript) della seguente pubblicazione:

Original Citation:

Life-Threatening Acute Pulmonary Thromboembolism Following Severe Carbon Monoxide Poisoning / De Gregorio, Maria Grazia; Olivotto, Iacopo; Migliorini, Angela; Vergara, Ruben; Buonamici, Piergiorgio; Marchionni, Niccolò; Valenti, Renato. - In: JACC. CASE REPORTS. - ISSN 2666-0849. - STAMPA. - 1:(2019), pp. 208-212. [10.1016/j.jaccas.2019.05.024]

Availability:

The webpage <https://hdl.handle.net/2158/1180346> of the repository was last updated on 2020-01-02T13:48:08Z

Published version:

DOI: 10.1016/j.jaccas.2019.05.024

Terms of use:

Open Access

La pubblicazione è resa disponibile sotto le norme e i termini della licenza di deposito, secondo quanto stabilito dalla Policy per l'accesso aperto dell'Università degli Studi di Firenze (<https://www.sba.unifi.it/upload/policy-oa-2016-1.pdf>)

Publisher copyright claim:

La data sopra indicata si riferisce all'ultimo aggiornamento della scheda del Repository FloRe - The above-mentioned date refers to the last update of the record in the Institutional Repository FloRe

(Article begins on next page)

CASE REPORT

ADVANCED

CLINICAL CASE

Life-Threatening Acute Pulmonary Thromboembolism Following Severe Carbon Monoxide Poisoning



A Plausible Association

Maria Grazia De Gregorio, MD, Iacopo Olivotto, MD, PhD, Angela Migliorini, MD, Ruben Vergara, MD, Piergiorgio Buonamici, MD, Niccolò Marchionni, MD, PhD, Renato Valenti, MD

ABSTRACT

A 57-year-old man admitted with severe carbon monoxide (CO) poisoning suffered life-threatening pulmonary embolism (PE) after hyperbaric oxygen therapy, in the absence of other risk factors for thromboembolism, and was successfully treated with thrombolysis. CO is a thrombophilic condition predisposing to PE and active surveillance is advisable. (**Level of Difficulty: Advanced.**) (J Am Coll Cardiol Case Rep 2019;1:208-12) © 2019 The Authors. Published by Elsevier on behalf of the American College of Cardiology Foundation. This is an open access article under the CC BY-NC-ND license (<http://creativecommons.org/licenses/by-nc-nd/4.0/>).

HISTORY OF PRESENTATION

A 57-year-old man was admitted to the emergency department for carbon monoxide (CO) poisoning suspicion, due to a malfunctioning heater at home. He appeared awake but confused, with recent memory loss, nausea and vomiting, diffuse tremors, and

mottled skin of the lower limbs. There were slight anisocoria and right-directed lateral nystagmus. Arterial blood gas analysis (BGA) in oxygen showed a lactic acidosis with high carboxyhemoglobin (**Figure 1**). The electrocardiogram (ECG) revealed sinus tachycardia and diffuse repolarization abnormalities (**Figure 1**); the echocardiogram showed diffuse left ventricular hypokinesia with ejection fraction of 30% and normal right ventricular size and function. A chest X-ray detected multiple lung consolidations with mild pleural effusion. Laboratory tests revealed leukocytosis, increased serum creatinine and troponin I values (3.72 µg/l, normal range 0.00 to 0.09 µg/l).

LEARNING OBJECTIVES

- CO poisoning is associated with a complex pathophysiology favoring thromboembolism.
- Systematic studies focusing on relationship between CO poisoning and risk of thromboembolic complications are lacking.
- The present observation supports the value of surveillance DVT/PE and consideration for routine prophylaxis in CO-poisoned patients.
- This issue may merit consideration in a future expert consensus document.

PAST MEDICAL HISTORY

Past medical history was unremarkable; cardiovascular risk factors included mild dyslipidemia and well-controlled hypertension on pharmacological therapy.

From Cardiovascular Department, Careggi University Hospital, Florence, Italy. Dr. Olivotto has received research grants from and served on the Speakers Bureau for Myokardia, Shire, Sanofi Genzyme, Bayer, and Menarini. All other authors have reported that they have no relationships relevant to the contents of this paper to disclose.

Manuscript received May 2, 2019; accepted May 9, 2019.

DIFFERENTIAL DIAGNOSIS

After hyperbaric oxygen therapy (HBOT), neurological findings and BGA had improved, ECG and echocardiogram were unchanged, and troponin I (3.89 µg/l) and inflammatory markers (C-reactive protein 143 mg/l [normal range <9 mg/l]) were elevated. A coronary angio-computed tomography (CT) scan was negative, supporting the hypothesis of left ventricular dysfunction induced by CO poisoning (1-3).

INVESTIGATIONS

By the next day, HBOT was repeated and the patient improved steadily. Antibiotic therapy was administered because of inflammatory markers and lung consolidations. On the third day the echocardiogram showed improved systolic function (LVEF 50%); a few hours later, the patient suddenly complained of worsening dyspnea followed by witnessed cardiac arrest. He was promptly resuscitated with complete recovery. The ECG showed sinus tachycardia with new onset of incomplete right bundle block and

diffuse ST-T abnormalities (Figure 1). The echocardiogram revealed right ventricular dilation and dysfunction with indirect evidence of pulmonary hypertension, raising clinical suspicion of pulmonary embolism (PE). An angio-CT confirmed a massive bilateral PE with large endoluminal defects of the pulmonary arteries in their main, segmental, and sub-segmental branches (Figure 2) and multiple consolidations. An ultrasound examination failed to identify lower limbs deep venous thrombosis (DVT).

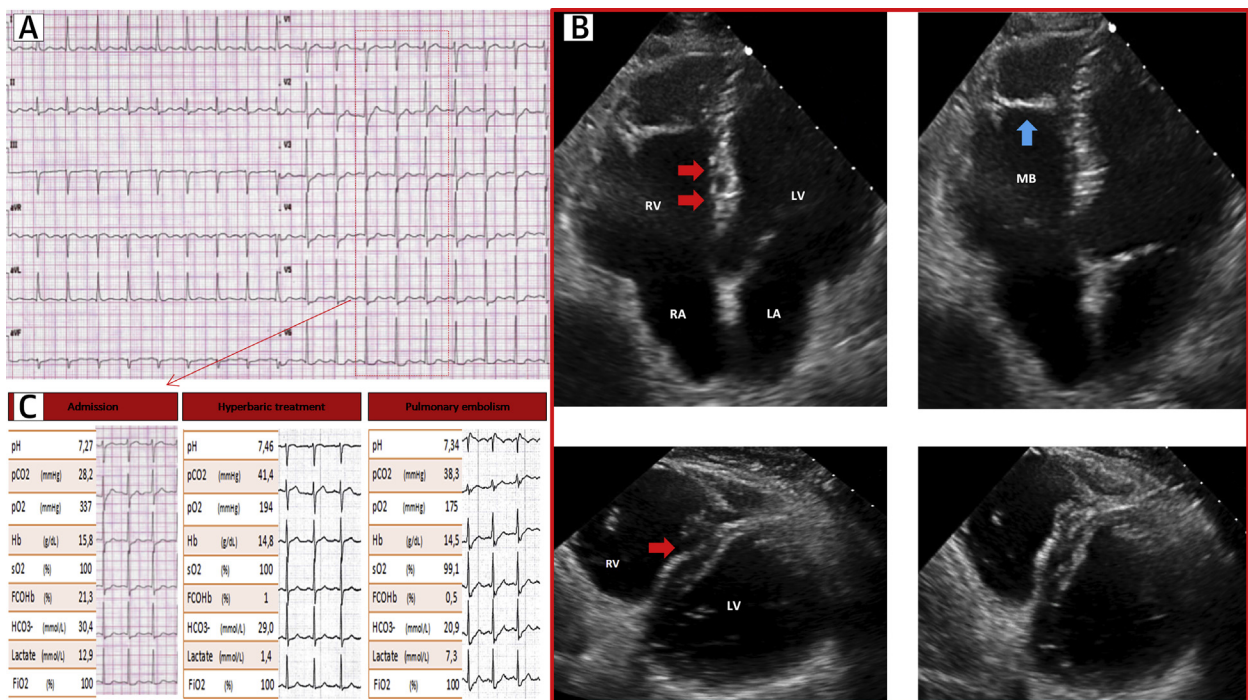
MANAGEMENT

The patient was tachypneic and tachycardic and N-terminal pro-B-type natriuretic peptide was elevated (4.233 pg/ml, normal range <334 pg/ml). Thrombolytic treatment was administered. About 30 min later, the right bundle block disappeared and heart rate decreased. BGA demonstrated satisfactory respiratory exchanges in Venturi mask with FiO2 50%; there were no bleeding complications. In the following

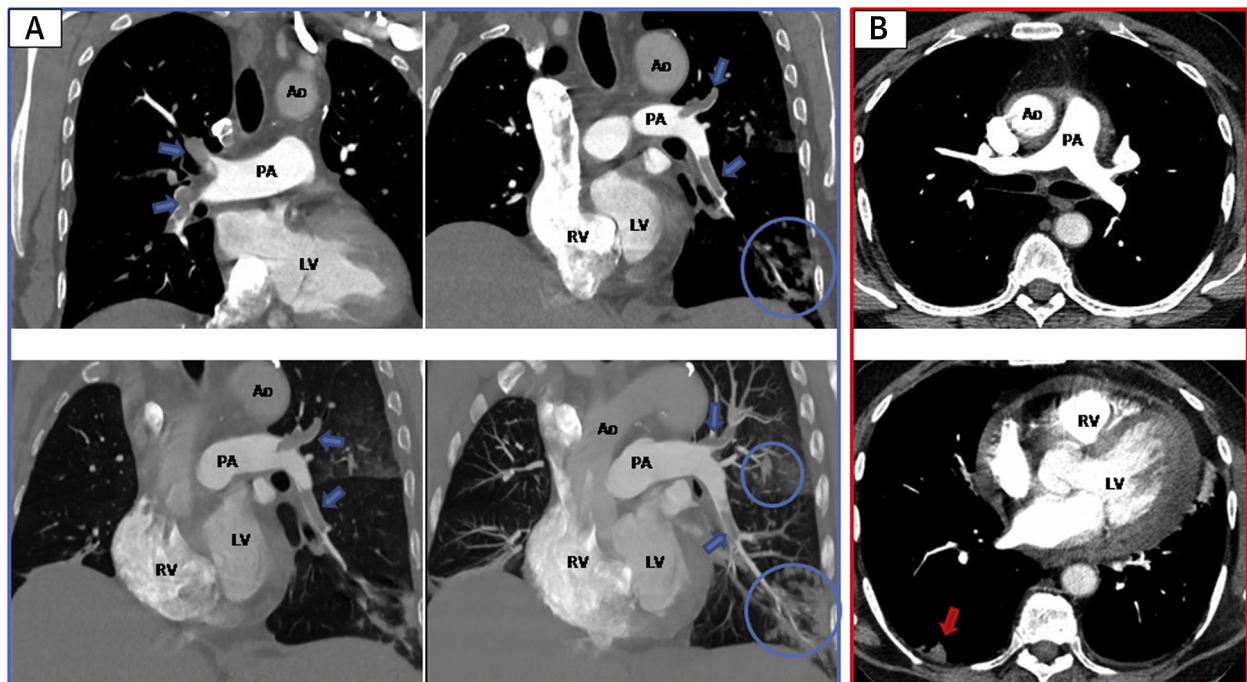
ABBREVIATIONS AND ACRONYMS

- BGA** = blood gas analysis
- CO** = carbon monoxide
- CT** = computed tomography
- DVT** = deep venous thrombosis
- ECG** = electrocardiogram
- HBOT** = hyperbaric oxygen therapy
- PE** = pulmonary embolism

FIGURE 1 Electrocardiographic, Echocardiographic, and Biochemical Findings



Patient's admission electrocardiogram with diffuse ST-T segment depression is shown (A). Echocardiographic biventricular telediastolic and telesystolic apical long axis and parasternal short axis views during pulmonary embolism are reported (B): red arrows show flattening of the interventricular septum, blue arrow indicates MB. Arterial blood gas analyses and electrographic changes during admission, after hyperbaric oxygen treatments, and after resuscitated cardiac arrest are shown (C). LA = left atrium; LV = left ventricle; MB = moderator band; RA = right atrium; RV = right ventricle.

FIGURE 2 Thoracic Angio-CT Evolution

Thoracic angio-CT scans show a massive bilateral pulmonary thromboembolism and multiple parenchymal consolidations (circles) (A). The blue arrows indicate endoluminal defects in the main and segmental branches of PA. Angio-CT scans performed after fibrinolysis show resolution of endoluminal defects of main and segmental branches of PA (B); the red arrow indicates a triangular consolidation compatible with pulmonary infarction. Ao = Aorta; CT = computed tomography; PA = pulmonary artery; other abbreviations as in Figure 1.

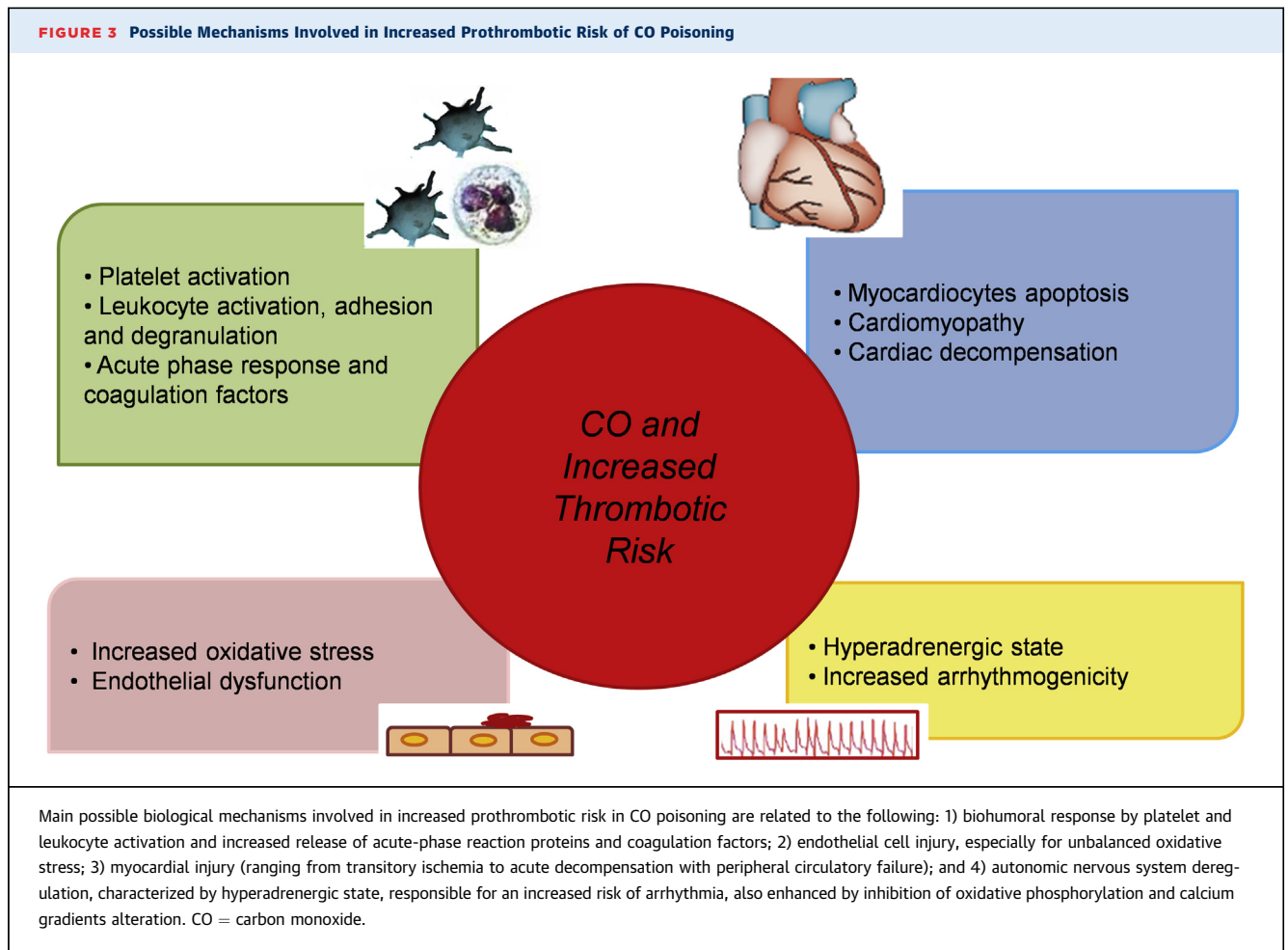
days, he remained stable on unfractionated heparin, and was later switched to rivaroxaban. Echocardiographic monitoring showed progressive normalization of biventricular function. Before discharge, a repeat angio-CT showed resolution of bilateral defects, except for sub-segmental branches and for a triangular parenchymal consolidation compatible with pulmonary infarction (Figure 2). Screening for thrombophilia only showed slight increase of lipoprotein(a) (392 mg/l [normal range <300 mg/l]) and factor VIII (191% [normal range 60% to 150%]).

DISCUSSION

CO is a colorless, odorless, and tasteless gas that binds with high affinity to many ferrous heme-containing proteins involved in different cellular pathways (1-3), especially to hemoglobin; thus, CO-bound hemoglobin has reduced oxygen carrying and delivery capacity. Furthermore, CO inhibits mitochondrial respiration impairing adenosine triphosphate production in tissues. Excessive CO concentration can activate platelets by displacement of nitric oxide from platelet surface

hemoproteins; displaced free nitric oxide can react with superoxide to produce peroxynitrite, further inhibiting mitochondrial function and increasing platelet and neutrophils activation. This process leads to a vicious circle enhancing inflammation and oxidative stress (3). CO cardiac toxicity is due to hypoxic damage and adverse effects at the cellular and molecular level. In particular, because CO binds the heme group of myoglobin with greater affinity than oxygen, its presence in the blood compromises oxygen supply to the cardiomyocyte mitochondria, causing a switch to anaerobic metabolism with consequent hypoxia, lactic acidosis, and apoptosis. Moreover, CO triggers endothelial dysfunction through enhanced transcapillary efflux, leukocyte sequestration within the endothelial lining, and increased oxidation of plasma lipoproteins (2). The clinical spectrum of cardiac toxicity in CO poisoning includes angina, arrhythmias, heart failure, myocardial stunning, myocardial infarction, cardiogenic shock, and sudden death.

By virtue of the complex pathophysiology outlined above, there are several reasons why CO poisoning may enhance risk of thrombosis (3,4) (Figure 3).



Epidemiological and environmental air studies have demonstrated an increased risk of cardiovascular events related to exposure to air pollutants and CO (3-5). The occurrence of DVT/PE in CO poisoning has been sporadically described (6,7) but systematic evaluation of thrombophilic factors is lacking in this setting. In the largest epidemiological study available (5), CO poisoning was associated with a 3.85-fold higher risk of DVT, although it was non-significantly associated with PE. Conversely, no association between CO poisoning and bleeding risk has been reported. Despite these data, neither PE nor CO poisoning guidelines mention the potentially lethal association of CO poisoning and DVT/PE (8,9).

Notably, our patient developed life-threatening PE in the absence of other obvious risk factors such as immobilization, trauma, or genetic evidence of thrombophilia. Only a slight increase of lipoprotein(a) and Factor VIII was identified; the latter was thought to be secondary to inflammatory response to CO poisoning (10).

FOLLOW-UP

Two months later no neurological sequelae or cardiologic dysfunction were found. Oxygen saturation was normal.

CONCLUSIONS

CO poisoning was the most likely trigger of life-threatening PE, occurring in a normally mobilized patient in the absence of other relevant risk factors for PE/DVT. In agreement with pertinent literature, our observation suggests that active surveillance and prophylaxis for DVT/PE should be considered in severe CO poisoning, including patients undergoing HBOT, generally suffering from more severe intoxication.

ADDRESS FOR CORRESPONDENCE: Dr. Renato Valenti, Cardiovascular Department, Careggi University Hospital, Largo Brambilla 3, I-50134 Florence, Italy. E-mail: renato.valenti2@tin.it.

REFERENCES

1. Ernst A, Zibrak JD. Carbon monoxide poisoning. *N Engl J Med* 1998;339:1603-8.
2. Lippi G, Rastelli G, Meschi T, Borghi L, Cervellin G. Pathophysiology, clinics, diagnosis and treatment of heart involvement in carbon monoxide poisoning. *Clin Biochem* 2012;45:1278-85.
3. Rose JJ, Wang L, Xu Q, et al. Carbon monoxide poisoning: pathogenesis, management, and future directions of therapy. *Am J Respir Crit Care Med* 2017;195:596-606.
4. Brook RD, Franklin B, Cascio W, et al. Air pollution and cardiovascular disease: a statement for healthcare professionals from the Expert Panel on Population and Prevention Science of the American Heart Association. *Circulation* 2004;109:2655-71.
5. Chung WS, Lin CL, Kao CH. Carbon monoxide poisoning and risk of deep vein thrombosis and pulmonary embolism: a nationwide retrospective cohort study. *J Epidemiol Community Health* 2015;69:557-62.
6. Lee Y, Lim TH, Kang H, Oh J, Ko BS. Pulmonary thromboembolism after carbon monoxide poisoning. *Am J Emerg Med* 2018;36:1717.e3-7.
7. Sevinc A, Savli H, Atmaca H. An interesting cause of pulmonary emboli: acute carbon monoxide poisoning. *Clin Appl Thromb Hemost* 2005;11:353-7.
8. Konstantinides SV, Torbicki A, Agnelli G, et al. 2014 ESC Guidelines on diagnosis and management of acute pulmonary embolism. *Eur Heart J* 2014;35:3033-80.
9. Wolf SJ, Maloney GE, Shih RD, Shy BD, Brown MD. Clinical policy: critical issues in the evaluation and management of adult patients presenting to the emergency department with acute carbon monoxide poisoning. *Ann Emerg Med* 2017;69:98-107.e6.
10. Kyrle PA, Minar E, Hirschl M, et al. High plasma levels of factor VIII and the risk of recurrent venous thromboembolism. *N Engl J Med* 2000;343:457-62.

KEY WORDS carbon monoxide, pulmonary embolism, prothrombotic risk