

Treatment of cardiac transthyretin amyloidosis: an update

Michele Emdin^{1,2*†}, Alberto Aimo^{3†}, Claudio Rapezzi⁴, Marianna Fontana^{5,6}, Federico Perfetto^{7,8}, Petar M. Seferović^{9,10}, Andrea Barison^{1,2}, Vincenzo Castiglione^{1,3}, Giuseppe Vergaro^{1,2}, Alberto Gianni^{1,2}, Claudio Passino^{1,2}, and Giampaolo Merlini^{11,12}

¹Institute of Life Sciences, Scuola Superiore Sant'Anna, Piazza Martiri della Libertà 33, 56127 Pisa, Italy; ²Cardiology Department, Fondazione Toscana Gabriele Monasterio, Via G. Moruzzi 1, 56124 Pisa, Italy; ³Cardiology Division, University Hospital of Pisa, via Paradisa 2, 56124 Pisa, Italy; ⁴Cardiology Division, University Hospital of Bologna, via Massarenti 9, 40138 Bologna, Italy; ⁵Institute of Cardiovascular Science, University College London, 62 Huntley St, Fitzrovia, London, UK; ⁶National Amyloidosis Centre, University College London, Royal Free Hospital, Gower Street, London, WC1E 6BT, UK; ⁷Regional Amyloid Centre, Azienda Ospedaliero Universitaria Careggi, Largo Piero Palagi 1, 50139, Florence, Italy; ⁸Department of Internal and Experimental Medicine, University of Florence, Largo Piero Palagi 1, 50139, Florence, Italy; ⁹Department of Internal Medicine, Belgrade University School of Medicine, Dr Subotica 8, 11000, Belgrade, Serbia; ¹⁰Cardiology Department, University Institute for Cardiovascular Diseases, Heroja Milana Tepića 1, Belgrade, Serbia; ¹¹Amyloidosis Research and Treatment Centre, Fondazione IRCCS Policlinico San Matteo, Viale Camillo Golgi 19, 27100, Pavia, Italy; and ¹²Department of Molecular Medicine, University of Pavia, Via C Forlanini 6, 27100, Pavia, Italy

Received 27 December 2018; revised 11 February 2019; editorial decision 21 April 2019; accepted 23 April 2019; online publish-ahead-of-print 20 May 2019

Transthyretin (TTR) is a tetrameric protein synthesized mostly by the liver. As a result of gene mutations or as an ageing-related phenomenon, TTR molecules may misfold and deposit in the heart and in other organs as amyloid fibrils. Cardiac involvement in TTR-related amyloidosis (ATTR) manifests typically as left ventricular pseudohypertrophy and/or heart failure with preserved ejection fraction. ATTR is an underdiagnosed disorder as well as a crucial determinant of morbidity and mortality, thus justifying the current quest for a safe and effective treatment. Therapies targeting cardiac damage and its direct consequences may yield limited benefit, mostly related to dyspnoea relief through diuretics. For many years, liver or combined heart and liver transplantation have been the only available treatments for patients with mutations causing ATTR, including those with cardiac involvement. The therapeutic options now include several pharmacological agents that inhibit hepatic synthesis of TTR, stabilize the tetramer, or disrupt fibrils. Following the positive results of a phase 3 trial on tafamidis, and preliminary findings on patisiran and inotersen in patients with ATTR-related neuropathy and cardiac involvement, we provide an update on this rapidly evolving field, together with practical recommendations on the management of cardiac involvement.

Keywords Transthyretin • Amyloidosis • Heart • Therapy

Introduction

Transthyretin (TTR) is a highly conserved protein involved in transportation of thyroxine (T4) and retinol-binding protein. TTR is synthesized mostly by the liver and is rich in beta strands with an intrinsic propensity to aggregate into insoluble amyloid fibres.¹ Fibrillogenesis requires the dissociation of TTR homotetrameric structure into misfolded monomers that self-assemble in soluble oligomeric species, presumably amyloid fibril precursors, which seem to exert significant cytotoxic effects in tissues.² Afterwards, oligomers aggregate into protofibrils and finally mature amyloid

fibres, which deposit within tissue leading to the development of TTR-related amyloidosis (ATTR).¹

ATTR can follow the deposition of either variant TTR (ATTRv, previously known as mutant ATTR)³ or wild type TTR (ATTRwt). Single base substitutions resulting in missense mutations represent the majority of the genetic alterations in ATTRv.⁴ More than 120 pathogenic mutations in the *TTR* gene have been described, resulting in a variable phenotypic presentation, ranging from pure polyneuropathy with autonomic dysfunction, to mixed neurological and cardiac presentation, and to selective cardiac involvement.⁴ The variant most commonly associated to cardiomyopathy is V122I, which is found in

* Corresponding author. Tel: +39 0503152189, Fax: +39 0503152109, Email: emdin@ftgm.it, m.emdin@santannapisa.it

† The first two authors contributed equally to the study.

Published on behalf of the European Society of Cardiology. All rights reserved. © The Author(s) 2019. For permissions, please email: journals.permissions@oup.com.

3.4% of African Americans.⁵ Outside the US, the V30M is the most frequent pathogenetic variant, with the phenotype varying by region.⁴ V30M is the most common TTR variant in patients with ATTRv with polyneuropathy, especially in endemic areas in Portugal, South America, Sweden, and Japan. In endemic areas, the disease may present as an early-onset (<50 years), rapidly progressive polyneuropathy, while in other regions it occurs as an isolated progressive polyneuropathy, apparently sporadic in elderly patients, frequently with a predominant cardiomyopathy.⁶ Other variants affecting primarily the heart are T60A, L111M, and I68L.⁴

Accurate statistics on the prevalence of ATTRv are difficult to obtain. Among Americans of European descent, it has an estimated incidence of 0.4 per million people/year, while this condition is believed to be more common among people with African ancestry and in specific geographic areas, such as northern Portugal or some regions of West Africa.⁴ Conversely, ATTRwt is a sporadic disorder with no specific biomarkers for its diagnosis, and most often affecting aged men (around 80% of cases).⁴ An autopsy study reported amyloid deposition in 25% of patients older than 85 years,⁷ although the clinical relevance of such deposits is undetermined, and it is reasonable to assume that only severe and widespread amyloid accumulation can produce disease manifestations by itself.

Cardiac ATTR should be searched in patients symptomatic for heart failure (HF), syncope, or bradyarrhythmia, with imaging findings suggestive of cardiac amyloidosis. In endemic areas, in patients with a positive family history, the diagnostic process is facilitated by the prototypic clinical presentation and the detection of the TTR variant, while the diagnosis is usually delayed in patients who have no family history. The presence of cardiac abnormalities including intracardiac conduction disorders, symptoms of dysautonomia, ruptured distal biceps tendon and carpal tunnel syndrome should suggest the diagnosis of ATTR amyloidosis. Cardiac involvement may manifest with left ventricular (LV) pseudohypertrophy and/or overt HF with preserved ejection fraction, possibly accompanied by conduction disturbances or arrhythmias. ATTR cardiomyopathy should be differentiated from ventricular hypertrophy secondary to pressure or volume overload, as well as from primary hypertrophy due to sarcomere gene mutations, other infiltrative conditions, or other aetiologies.⁸ Cardiac ATTR should be considered in all patients who have LV wall thickening, especially when QRS voltages are normal or low and the LV is not enlarged; the likelihood of diagnosis increases when cardiac biomarkers (troponins and/or natriuretic peptides) are increased, and symptoms or history of peripheral or autonomic neuropathy coexist.^{9,10} The diagnosis can be made either through the demonstration of TTR amyloid deposits on the endomyocardial biopsy or following a non-invasive algorithm in patients with no evidence of a monoclonal protein, where diphosphonate scintigraphy with ^{99m}Tc-labelled radiotracers play a central role¹¹ (Figure 1).

Cardiac ATTR has a favourable survival rate compared to light chain (AL) amyloidosis, with a median survival of 75 vs. 11 months.^{9,10} On the other hand, ATTR cardiomyopathy is a progressive disorder with very limited therapeutic options until very recently. This field is rapidly evolving, with the positive results of a phase 3 trial on tafamidis,¹² and preliminary findings on patisiran¹³ and inotersen¹⁴ in patients with ATTR-related neuropathy and cardiac involvement, warranting a dedicated review.

Inhibition of the synthesis of mutated transthyretin

Liver transplantation and combined liver–heart transplantation

Orthotopic liver transplantation was first proposed in 1990 as a potentially curative treatment of ATTRv-related polyneuropathy.¹⁵ Liver transplantation removes the source of mutated TTR molecules and prolongs survival, with a 20-year survival rate of 55.3%.¹⁶ Higher body mass index, younger age (<50 years), shorter disease duration, and V30M vs. non-V30M mutations have been identified as independent predictors of better survival.¹⁶ Nonetheless, tissue accumulation of TTR can continue after liver transplantation, likely because TTR amyloid fibres promote subsequent deposition of TTRwt. This was demonstrated in an autopsy study, in which patients not undergoing liver transplantation showed 60% variant TTR and 40% TTRwt in the heart, while the variant to TTRwt ratio was 25% to 75% after liver transplantation.¹⁷ Furthermore, patients with the V30M mutation undergoing liver transplantation showed increasing interventricular septal thickness at serial echocardiographic monitoring, denoting ongoing deposition of TTRwt in the transplanted heart.¹⁸

Combined heart and liver transplantation is feasible in younger patients with ATTRv cardiomyopathy, and small patient series suggest that it is associated with better prognosis than cardiac transplantation alone.¹⁹ On the other hand, it is currently unclear if liver transplantation is needed in the V122I mutation (i.e. the commonest TTR mutation causing cardiomyopathy).⁴ Limited organ availability, exclusion of older patients and of those with advanced systemic disease, and risks related to surgery and life-long immunosuppression represent further problems of liver or combined transplantation. Liver transplantation is not an option for patients with ATTRwt.¹⁹

Inhibition of TTR gene expression

Patisiran is a small interfering RNA blocking the expression of both variant and wt TTR.²⁰ It is encapsulated in lipid nanoparticles targeting the liver and administered through intravenous infusion.^{20,21} A phase 2 study on 29 patients with ATTRv and polyneuropathy showed that two doses of patisiran 0.3 mg/kg every 3 weeks reduced mean serum TTR levels by about 80%.²¹ This potent TTR knock-down was observed for both ATTRwt and ATTRv (V30M), and in patients receiving TTR tetramer stabilizers.²¹ In the APOLLO phase 3 trial enrolling 225 patients with ATTRv and polyneuropathy, those on patisiran (0.3 mg/kg once every 3 weeks for 18 months) experienced a significant improvement in neurological status. Severe adverse events had a similar incidence in the patisiran and placebo arms (28% vs. 36%); common adverse events occurring more frequently with patisiran included peripheral oedema, infusion-related reactions, and vision problems.¹³ These results led to the approval of patisiran for the treatment of adults with ATTRv-related polyneuropathy both in the USA and in the European Union, although patisiran has been approved in Europe only for the treatment of mild-to-moderate disease (Stage 1–2).

In the APOLLO trial, patients with echocardiographic evidence of cardiac involvement ($n = 126$, 56% of the total population) in the patisiran group displayed significantly lower decrease in cardiac output and increase in LV end-diastolic volume. Additionally, these patients

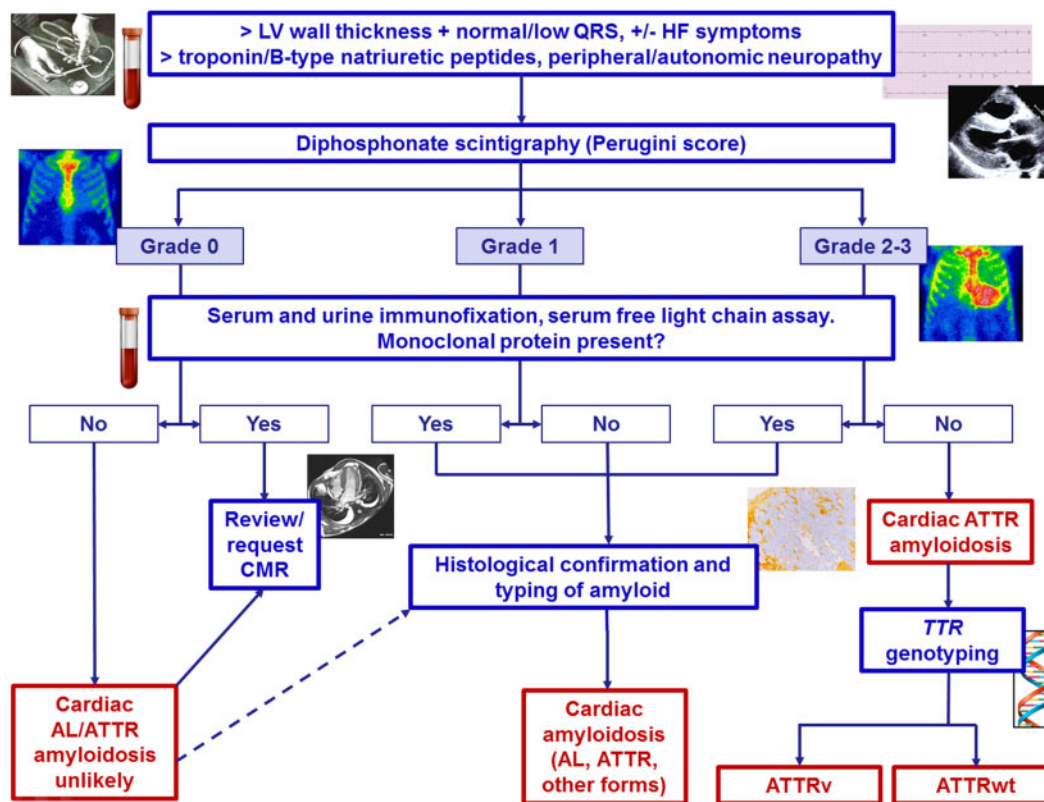


Figure 1 Diagnostic algorithm for cardiac transthyretin amyloidosis. Dashed line indicates a suggested, non-mandatory step. AL, amyloid light-chain amyloidosis; ATTR, amyloid transthyretin amyloidosis (ATTRv, variant transthyretin amyloidosis; ATTRwt, wild-type transthyretin amyloidosis); CMR, cardiac magnetic resonance; HF, heart failure. Modified from Gillmore *et al.*¹¹

experienced significant reduction in mean LV wall thickness, relative wall thickness, LV mass, and N-terminal fraction of pro-B-type natriuretic peptide (NT-proBNP) compared with baseline.^{13,22} These findings suggest that patisiran slows down LV functional deterioration, but also promotes favourable myocardial remodelling, an effect that was not demonstrated for inotersen and is still under investigation for tafamidis.

Another siRNA, revusiran, was investigated in a phase 3 trial (ENDEAVOUR), designed to assess 6-min walking distance and serum TTR levels in 200 patients with ATTRv cardiomyopathy. Patients were randomized 2:1 to revusiran or placebo, with revusiran administered subcutaneously at 500 mg daily for 5 days, then weekly for 18 months.²³ The study was discontinued because of 'an imbalance in mortality observed between patients treated with revusiran and placebo'.²³

The antisense oligonucleotides inotersen inhibits the production of both variant and wt TTR.²⁴ A single centre, open-label study evaluated 15 patients with cardiac ATTR (8 ATTRv, 7 ATTRwt), receiving weekly subcutaneous injections of inotersen (300 mg) for 12 months. Peak reduction in TTR concentration varied from 39% to 91% (mean 72%). Patients showed a stabilization of disease as measured by LV wall thickness, LV mass, 6-min walking distance, and global

systolic strain. The treatment was well tolerated, with no changes in renal function, low rates of thrombocytopenia, or injection site reactions.²⁴ In the multicentre, randomized, double-blind, placebo-controlled, phase 3 NEURO-TTR trial, patients with ATTRv and polyneuropathy ($n = 172$) were randomized to inotersen (300 mg weekly) or placebo. After 66 weeks, inotersen was well tolerated and slowed the decline in neurology scores.¹⁴ Following these results, inotersen has received FDA approval for patients with ATTRv-related polyneuropathy. In the NEURO-TTR trial, cardiomyopathy was present in 63% of patients, but the study was not powered to measure the effects of inotersen on cardiac disease.¹⁴

Tetramer stabilization

Selective stabilizers: tafamidis, AG10

The benzoxazole tafamidis is a small molecule that inhibits the dissociation of TTR tetramers by binding the T4-binding sites.²⁵ Tafamidis has become the first disease-modifying drug to be approved for use in adult patients with early-stage ATTRv-related polyneuropathy, while it does not stop disease progression in patients with Stage 2–3 polyneuropathy.^{26,27} It is currently available

in Europe and Japan for the treatment of ATTRv-related polyneuropathy, while it has not received FDA approval.

In a small open-label, single arm trial on patients with mutations other than the V30M and TTR amyloidosis (i.e. not limited to ATTRv-related polyneuropathy), tafamidis treatment (20 mg daily) achieved TTR tetramer stabilization over 6 weeks. At 12-month follow-up, no deterioration in quality of life and cardiac function, assessed through echocardiographic parameters and plasma NT-proBNP was reported, with some worsening of neurological function.²⁸ More recently, the positive results of the ATTR-ACT trial have raised great interest. In this phase 3 study, 441 patients with TTR cardiomyopathy (defined as medical history of HF, LV hypertrophy at echocardiography or demonstration of TTR amyloid deposition) were randomized in a 2:1:2 ratio to receive tafamidis 80 mg, tafamidis 20 mg, or placebo for 30 months.¹² When comparing the pooled tafamidis arms (80 mg and 20 mg) with the placebo arm, tafamidis treatment was associated with lower all-cause mortality than placebo [78 of 264 (29.5%) vs. 76 of 177 (42.9%); hazard ratio 0.70, 95% confidence interval (CI) 0.51–0.96], and a lower rate of cardiovascular-related hospitalizations with a relative risk ratio of 0.68 (0.48 per year vs. 0.70 per year; 95% CI 0.56–0.81).¹² The Kaplan–Meier survival curves showed that tafamidis resulted in a reduction in all-cause mortality, with the curves diverging after approximately 18 months of treatment, in agreement with the concept of tafamidis as a disease-modifying drug.¹² Additionally, tafamidis was able to relieve symptoms, as demonstrated by the lower rate of decline in 6-min walking distance and quality of life (measured through the Kansas City Cardiomyopathy Questionnaire-Overall Summary) at 30 months (both $P < 0.001$).¹² The drug was also well tolerated, with a similar incidence and type of adverse events between the tafamidis and the placebo group; furthermore, diarrhoea and urinary tract infections, i.e. common adverse events in patients with ATTR, were less common among patients receiving tafamidis than placebo.¹² A detailed assessment of the effects of tafamidis on NT-proBNP, troponins and echocardiographic measurements is ongoing.

Across patient subgroups, including ATTRwt vs. ATTRv, New York Heart Association (NYHA) Class I–II vs. III, and tafamidis dose (80 mg vs. 20 mg), the difference in all-cause mortality and frequency of cardiovascular-related hospitalizations favoured tafamidis over placebo.¹² In contrast, among patients in NYHA Class III at baseline, those receiving tafamidis had higher hospitalization rates, possibly because of a longer survival during a more severe phase of the disease.¹² An adequately powered survival analysis in NYHA Class III patients would be worthwhile.

Following these results, tafamidis has received the Breakthrough Therapy designation from the FDA for the treatment of patients with ATTR cardiomyopathy, which may prelude to an accelerated evaluation of tafamidis as a therapy for this condition.

The selective TTR stabilizer AG10 has been evaluated in a phase 2, randomized, double-blind, placebo-controlled, multicentre study enrolling 49 patients with symptomatic ATTR cardiomyopathy, both variant and wt. In November 2018, the positive results of this trial have been announced. AG10 (400 mg or 800 mg *per os* twice daily for 28 days) was well tolerated, increased circulating TTR levels (considered as a positive effect, possibly linked to lower tissue deposition), and induced near-complete stabilization of TTR. A phase 3 trial is planned to be initiated in the first half of 2019.²⁹

Non-selective agents: diflunisal

In 2006, a phase 1 study showed that non-steroidal anti-inflammatory drug (NSAID) diflunisal (250 mg *per os* b.i.d.), complexes to the T4 binding site and stabilizes TTR tetramers, thus preventing amyloid fibril formation *in vitro*.³⁰ In a small single-arm, open-label study, diflunisal was not effective in relieving cardiac dysfunction (evaluated as LV mass, ejection fraction or biomarkers), possibly because of the limited follow-up duration (0.9 ± 0.3 years).³⁰ Diflunisal appeared to be safe in the same patients,³¹ although the adverse effects from a chronic NSAID treatment are a source of concern.

Inhibition of oligomer aggregation and oligomer disruption

Epigallocatechin gallate

Epigallocatechin-3-gallate (EGCG) is the most abundant catechin in green tea.³² Epigallocatechin-3-gallate binds to soluble TTR decreasing the likelihood of tetramer dissociation, inhibits oligomer aggregation into amyloid fibres, thus promoting the disaggregation of TTR amyloid fibres.³² In a single centre, open-label study, 30 patients with cardiac ATTR (both variant and wt) received EGCG 675 mg/day *per os* and were compared with 35 cardiac ATTR patients treated with HF supportive therapy alone. Over 12 months of treatment, EGCG did not improve survival and did not change echocardiographic parameters or NT-proBNP, compared with baseline.³³

Degradation and reabsorption of amyloid fibres

Doxycycline-tauroursodeoxycholic acid (TUDCA)

Several hydrophobic molecules are effective in destabilizing and disaggregating amyloid fibres, which promote the reabsorption of amyloid deposits by tissue macrophages.³⁴ Tetracyclines, including doxycycline, proved able to cause complete disaggregation of amyloid fibres *in vitro*, generating non-toxic molecular species.³⁴ The combination of doxycycline and tauroursodeoxycholic acid (TUDCA) has a more pronounced effect, causing even complete amyloid clearance from tissues in animal models.³⁴

In a small phase 2 trial, 28 patients with ATTR received doxycycline and TUDCA for 12 months followed by a 6-month withdrawal period. The results were modest and difficult to interpret because of a very high dropout rate (86%) due to treatment failure (expressed as >30% NT-proBNP increase), side effects and voluntary dropouts.³⁵ In a phase 2, open-label study, the treatment was well tolerated, and no progression of cardiac involvement and neuropathy was found in a preliminary analysis on 20 patients.³⁶

Antibodies targeting serum amyloid P protein or amyloid fibrils

Serum amyloid P (SAP) is a normal plasma glycoprotein synthesized by the liver, which stabilizes and protects amyloid fibrils from proteolytic degradation.³⁷ Miridesap is a small molecule that binds circulating

SAP and promotes its hepatic clearance.³⁸ In 2002, Pepys *et al.*³⁷ administered miridesap to 7 patients with systemic amyloidosis, obtaining more than 90% reduction of circulating SAP. These results were confirmed by an open label study on 31 patients with advanced systemic amyloidosis, including 4 with ATTR, receiving subcutaneous miridesap injections b.i.d. The histological analysis demonstrated a significant, though incomplete, depletion of SAP within amyloid deposits.³⁸ In an open-label, single-dose-escalation, phase 1 trial, 15 patients with systemic amyloidosis received miridesap and then a dose of anti-SAP antibodies proportionate to their amyloid load, showing an improvement in liver function and a reduction in visceral amyloid deposits at 6 weeks; patients with cardiac disease were excluded.³⁹ In an extension phase of the same trial, miridesap therapy was assessed on 6 patients with cardiac amyloidosis (3 with ATTR). Neither cardiac adverse events nor improvements in cardiac involvement were reported.⁴⁰ These results led to a phase 2 study assessing whether monthly repeated courses of miridesap followed by anti-SAP antibodies is associated with a reduction in cardiac amyloid load and improvement in cardiac function in patients with ATTR cardiomyopathy.⁴¹ Patient enrolment was suspended on 22 August 2018, and a phase 1 trial was simultaneously stopped.⁴² Therefore, the development of anti-SAP antibody therapy has stopped and this approach is no longer evaluated. In contrast, a monoclonal antibody designed to specifically target TTR amyloid deposits (PRX004) has entered clinical evaluation with an ongoing phase 1 study on ATTRv.⁴³

Supportive treatment of cardiac involvement

Drug therapies

The application of guideline-recommended therapeutic algorithms for HF⁴⁴ to cardiac ATTR, with regard to therapies targeting cardiac damage and its direct consequences may yield a partial benefit. Beta-blockers may be poorly tolerated or contraindicated, for example because of hypotension, conduction disturbances, or impossibility of adequately increasing cardiac output, especially in cases with overt restrictive pathophysiology, when cardiac output becomes critically dependent on heart rate.⁴⁵ Angiotensin-converting enzyme inhibitors or angiotensin receptor blockers (ACEi/ARBs) may be poorly tolerated as well, particularly in hypotensive patients. Nonetheless, almost 30% of patients in the ATTR-ACT trial were on beta-blockers or ACEi/ARB.¹² Because of the lack of evidence on their prognostic impact in cardiac ATTR, no specific recommendation can be made, and these drugs might be considered in the absence of clear contraindications, starting from low doses, with slow up-titration and close monitoring. Mineralocorticoid receptor antagonists are frequently and safely used. Diuretic therapy is essential for dyspnoea relief and is often needed in high doses to reduce pulmonary and peripheral congestion, particularly in patients with severe diastolic dysfunction, although care should be taken to avoid worsening renal function and excessive preload reduction. Digoxin has been traditionally contraindicated because of old reports of increased toxicity in patients with amyloid cardiomyopathy,¹⁰ but a recent report suggests that it may be cautiously utilized in AL amyloidosis, at low doses and with

frequent drug concentration monitoring, while no data are available in TTR amyloidosis.⁴⁶ Finally, non-dihydropyridine calcium channel blockers are contraindicated because of their negative inotropic effect.

Patients with cardiac amyloidosis have an increased risk of atrial thrombosis even in sinus rhythm, likely because of a loss of atrial mechanical function.⁴⁷ Anticoagulation with either warfarin or the novel oral anticoagulants can usually be safely prescribed to patients with ATTR, with the same indications than in other disease settings because of the absence of any specific evidence. In a recent study on 58 patients with cardiac amyloidosis (50% with ATTR) referred to direct-current cardioversion for atrial arrhythmias, there was a high cancellation rate because of intracardiac thrombi even among patients who received adequate anticoagulation; performing a transoesophageal echocardiogram before DDCV is then advisable.⁴⁸

Implantable cardioverter-defibrillator

Sudden cardiac death has a high incidence and may result from tachyarrhythmias, but more often from electromechanical dissociation or arrhythmias not amenable to implantable cardioverter-defibrillator (ICD) therapy. This point has been most extensively studied in cardiac AL amyloidosis.⁴⁹ In a study on 53 patients with cardiac amyloidosis (33 AL, 10 ATTRwt, and 9 ATTRv), who received an ICD for either primary ($n = 41$) or secondary prevention ($n = 12$), the rate of appropriate ICD shocks was 32% in the first year and was observed almost exclusively in patients with AL amyloidosis.⁵⁰ Appropriate ICD shocks were more frequent in patients implanted for secondary prevention, and did not translate into overall survival benefit. Higher defibrillation thresholds and complication rates represent further concerns.⁵¹

Cardiac pacing

The infiltration of myocardial tissue by amyloid fibres predisposes to bradyarrhythmias. In a large series of patients with ATTRv-related polyneuropathy ($n = 262$), prophylactic pacemaker was implanted in patients ($n = 100$) with His-ventricular interval ≥ 70 ms, His-ventricular interval > 55 ms associated with a fascicular block, a first-degree atrioventricular (AV) block, or a Wenckebach anterograde point ≤ 100 b.p.m. Over a mean 45-month follow-up, a high-degree AV block was documented in 24 of the 95 patients (25%). The risk of high-degree AV block was higher in patients with first-degree AV block or Wenckebach anterograde point ≤ 100 b.p.m. (hazard ratio 3.5; 95% confidence interval 1.2–10).⁵² Although a screening electrophysiological study cannot be proposed to all TTR patients, these findings suggest that any conduction disturbance on 12-lead electrocardiogram (ECG) warrant further investigations, including at least ECG long-term Holter monitoring and close follow-up.

Left ventricular assist device and cardiac transplantation

Left ventricular assist device therapy is technically feasible in patients with cardiac amyloidosis but is associated with high short-term mortality and worse outcome than in dilated cardiomyopathy, as in other forms of restrictive cardiomyopathy.^{53,54}

Isolated cardiac transplantation is a valuable option for patients with end-stage HF when significant extracardiac disease is excluded.

Table 1 Therapies for cardiac transthyretin amyloidosis (ATTR): evidence from clinical trials

Drug	Author, year	Design	Population	Main efficacy results	Approved indications (FDA/EMA, February 2019)
Tafamidis	Maurer, 2018 ¹² (ATTR-ACT)	<ul style="list-style-type: none"> Phase 3, multicentre, double-blind, placebo-controlled trial 2:1:2 randomization to oral tafamidis 80 mg daily, tafamidis 20 mg daily, or placebo for 30 months 	<ul style="list-style-type: none"> ATTR cardiomyopathy (wt and v) Pooled tafamidis: n = 264 Placebo: n = 177 	<ul style="list-style-type: none"> Pooled tafamidis vs. placebo: all-cause mortality: 29.5% vs. 42.9%; HR 0.70; 95% CI 0.51–0.96 CV hospitalizations: 0.48 vs. 0.70/year; RR 0.68, 95% CI 0.56–0.81 At month 30, less decline in 6MWD and KCCQ-OS score (both $P < 0.001$) 	<ul style="list-style-type: none"> FDA: not approved EMA: adults with Stage 1 ATTRv-related polyneuropathy
Patisiran	Adams, 2018 ¹³ (APOLLO)	<ul style="list-style-type: none"> Phase 3, multicentre, double-blind, placebo-controlled trial 2:1 randomization to iv patisiran (0.3 mg/kg) or placebo once every 3 weeks for 18 months 	<ul style="list-style-type: none"> ATTRv-related polyneuropathy Cardiac disease: n = 126 (56%) 	<ul style="list-style-type: none"> Subgroup with cardiac disease: patients on patisiran displayed lower decreases in cardiac output, increases in LV end-diastolic volume, and decreases in mean LV wall thickness, relative wall thickness, LV mass and NT-proBNP at 18 months 	<ul style="list-style-type: none"> FDA: adults with ATTRv-related polyneuropathy EMA: adults with Stage 1–2 ATTRv-related polyneuropathy
Inotersen	Benson, 2017 ²⁴	<ul style="list-style-type: none"> Phase 2, single centre, open-label study Inotersen 300 mg weekly for 1 year Phase 3, multicentre, double-blind, placebo-controlled trial 2:1 randomization to weekly sc inotersen (300 mg) or placebo for 64 weeks 	<ul style="list-style-type: none"> ATTR cardiomyopathy n = 15 Stage 1–2 ATTRv-related polyneuropathy n = 108 (63%) with cardiac disease 	<ul style="list-style-type: none"> Disease stabilization (stable LV wall thickness, LVM, 6MWD, and global systolic strain) In the cardiac subgroup, slower progression of neurological disease among patients on inotersen, but no differences in global longitudinal strain and other echocardiographic variables 	<ul style="list-style-type: none"> FDA: adults with ATTRv-related polyneuropathy EMA: adults with Stage 1–2 ATTRv-related polyneuropathy
Revusiran	NCT02319005 (ENDEAVOUR) ²³	<ul style="list-style-type: none"> Phase 3, multicentre, double-blind, placebo-controlled trial Sc revusiran or placebo for 18 months 	<ul style="list-style-type: none"> ATTR cardiomyopathy n = 206 patients enrolled (revusiran = 140 vs. placebo = 66) 	<ul style="list-style-type: none"> NA 	<ul style="list-style-type: none"> FDA: not approved EMA: not approved
Diflunisal	Castaño, 2012 ³¹	<ul style="list-style-type: none"> Single-arm, open-label study Oral diflunisal 250 mg b.i.d. 	<ul style="list-style-type: none"> ATTR cardiomyopathy n = 13 	<ul style="list-style-type: none"> No significant change in LV mass, LVEF, or cardiac biomarkers over 0.9 ± 0.3 years 	<ul style="list-style-type: none"> FDA: not approved EMA: not approved
EGCG	Kristen, 2012 ³³	<ul style="list-style-type: none"> Single-centre study 	<ul style="list-style-type: none"> ATTR cardiomyopathy n = 19 	<ul style="list-style-type: none"> No increase in LV wall thickness or mass at echocardiography 	<ul style="list-style-type: none"> FDA: not approved EMA: not approved

Continued

Table 1 Continued

Drug	Author, year	Design	Population	Main efficacy results	Approved indications (FDA/EMA, February 2019)
Miridesap + anti-SAP antibody (dezamizumab)	Richards, 2018 ⁴⁰	<ul style="list-style-type: none"> Oral EGCG (500–700 mg daily) either through 1.5–2 L of green tea daily or green tea extracts for 12 months Phase 1, open-label, single-dose-escalation trial Cycles of sc miridesap + dezamizumab 	<ul style="list-style-type: none"> Systemic amyloidosis n = 23 (cardiac involvement, n = 6; ATTR cardiomyopathy, n = 3) 	<ul style="list-style-type: none"> No efficacy data on the subset with ATTR cardiomyopathy 	<ul style="list-style-type: none"> FDA: not approved EMA: not approved
	NCT03044353 ⁴¹	<ul style="list-style-type: none"> Phase 2, open-label trial Cycles of sc miridesap + dezamizumab 	ATTR or AL cardiomyopathy	NA (stopped)	

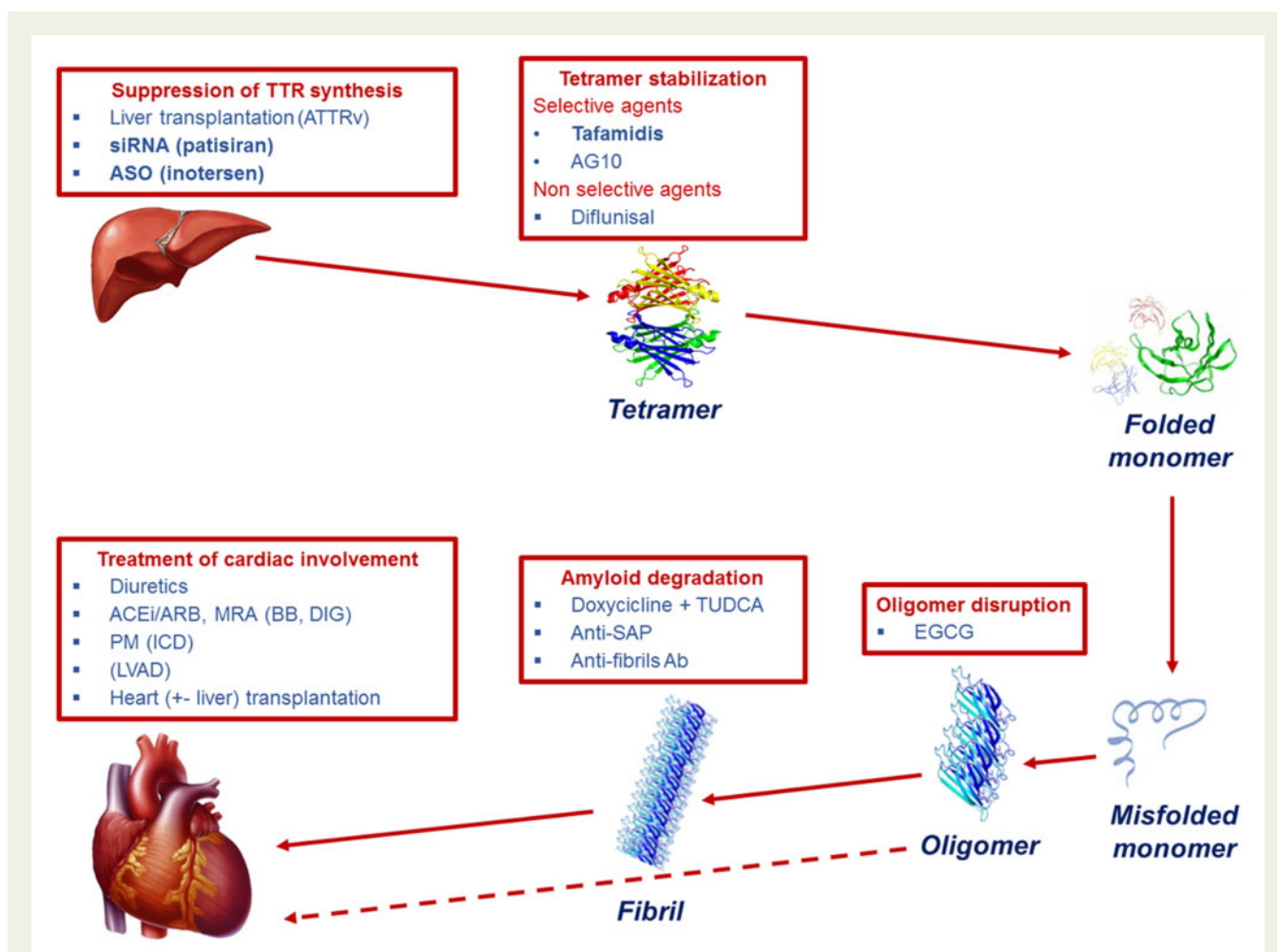
Drug approval status by the Food and Drug Administration (FDA) or European Medicines Agency (EMA) refers to the treatment of TTR amyloidosis.

AE, adverse event; ATTR, transthyretin amyloidosis (ATTRwt, wild-type transthyretin amyloidosis; ATTRrv, variant transthyretin amyloidosis); CI, confidence interval; CMR, cardiac magnetic resonance; CV, cardiovascular; EGCG, epigallocatechin-3-gallate; KCCQ-OS, Kansas City Cardiomyopathy Questionnaire Overall Summary; LV, left ventricular; LVEF, left ventricular ejection fraction; LVM, left ventricular mass; δ MWD, 6-min walking distance; NA, not available; NT-proBNP, N-terminal fragment of pro-B-type natriuretic peptide; RR, relative risk; SAP, serum amyloid P component; UTI, urinary tract infection.

In a case report, no recurrence of amyloid in the cardiac allograft and no systemic abnormalities were reported 5 years after heart transplantation.⁵⁵ A second patient with the same mutation was well 3 years later, with no evidence of allograft or systemic amyloid deposition.⁵⁶ Among 10 patients (2 ATTRwt, 7 ATTRrv, 1 undetermined), there was only one episode of amyloid recurrence in the cardiac graft.⁵⁷ The Stanford cardiac transplantation evaluation guidelines for ATTR summarize the screening examinations for transplantation candidates.⁵⁸

Which therapy for ATTR cardiomyopathy?

Table 1 summarizes evidence from clinical trials on the therapies for cardiac ATTR. The estimated prevalence of ATTR is increasing as a result of greater knowledge of the disease and more widespread availability of techniques for non-invasive assessment, such as diphosphonate scintigraphy. Cardiac involvement is a common feature of ATTR and a crucial determinant of morbidity and mortality, which justifies the current quest for safe and effective therapies. Until very recently, no evidence-based therapeutic options were available, also because patients with cardiac amyloidosis were systematically excluded from clinical trials on HF drugs, and dedicated, adequately powered trials were not performed. Liver transplantation (either alone or combined with heart transplantation) represented the only strategy impacting on patient prognosis, but was reserved to a small minority of patients because of the inherent limitations of transplantation and the uncertain benefit except for patients carrying the V30M mutation. A deeper understanding of ATTR pathogenesis has led to the assessment of other strategies to block transthyretin synthesis or to target other steps of the amyloidogenic cascade (*Take home figure*). Positive results in a phase 3 trial on the specific setting of ATTR cardiomyopathy have been found only for tafamidis. In the foreseeable future, this drug may become the first approved drug for ATTR cardiomyopathy and the standard of care for this condition, particularly in patients in NYHA Class I–II.¹² The other most promising approaches are patisiran and inotersen, which might prove even more effective than tafamidis as they block TTR synthesis, instead of stabilizing TTR tetramers. Hopefully, multiple therapeutic options will become available, allowing clinicians to tailor the therapeutic strategy on each patient, given the differential characteristics in terms of safety and efficacy. For instance, should patisiran and inotersen be proven equally effective, patisiran could be preferred for a patient receiving anticoagulants for atrial fibrillation, as therapy with inotersen may cause thrombocytopenia, and therefore increase the bleeding risk;^{13,14} inotersen should generally not be initiated in patients with urinary protein to creatinine ratio ≥ 1000 mg/g or estimated glomerular filtration rate < 45 mL/min/1.73 m², as treatment with inotersen can cause glomerulonephritis that may result in dialysis-dependent renal failure.¹⁴ Other perspectives for future research are combinations of drugs with complementary mechanisms of action, cost-effectiveness analyses on novel drugs, and well-designed studies to evaluate whether drugs for neurohormonal antagonism might have some role as adjunctive therapeutic strategies. For all these advances to occur, clinicians must become increasingly aware of red flags for ATTR cardiomyopathy and refer patients with



Take home figure The pathogenic cascade of cardiac transthyretin (TTR) amyloidosis and proposed therapeutic approaches for each step. The more promising approaches, for which a phase 3 study is available, are evidenced in bold, while the least established options are reported in brackets. Ab, antibody; ACEi/ARB, angiotensin converting enzyme inhibitor/angiotensin receptor blockers; ASO, antisense oligonucleotide; BB, beta-blockers; EGCG, epigallocatechin gallate; ICD, implantable cardioverter-defibrillator; LVAD, left ventricular assist device; ATTRv, variant transthyretin amyloidosis; MRA, mineralocorticoid receptor antagonists; PM, pacemaker; SAP, serum amyloid P component; siRNA, small interfering RNA; TUDCA, tauroursodeoxycholic acid.

suspected disease to specialized centres, where the diagnostic suspicion can either be confirmed or discarded, patients can receive state-of-the-art therapy and being enrolled in clinical trials.

Conflict of interest: C.R., unrestricted research grants and fees for board meetings from Pfizer; M.F., consultancy from Pfizer, Alnylam, GSK, Prothena; G.M., consultancy from Janssen, Millennium Takeda, Pfizer, Prothena, Ionis. All other authors declared no conflict of interest.

References

- Saelices L, Johnson LM, Liang WY, Sawaya MR, Cascio D, Ruchala P, Whitelegge J, Jiang L, Riek R, Eisenberg DS. Uncovering the mechanism of aggregation of human transthyretin. *J Biol Chem* 2015;**290**:28932–28943.
- Reixach N, Deechongkit S, Jiang X, Kelly JW, Buxbaum JN. Tissue damage in the amyloidoses: transthyretin monomers and nonnative oligomers are the major cytotoxic species in tissue culture. *Proc Natl Acad Sci USA* 2004;**101**:2817–2822.
- Benson MD, Buxbaum JN, Eisenberg DS, Merlini G, Saraiva MJM, Sekijima Y, Sipe JD, Westermarck P. Amyloid nomenclature 2018: recommendations by the International Society of Amyloidosis (ISA) nomenclature committee. *Amyloid* 2019;**25**:1–5.
- Maurer MS, Hanna M, Grogan M, Dispenzieri A, Witteles R, Drachman B, Judge DP, Lenihan DJ, Gottlieb SS, Shah SJ, Steidley DE, Ventura H, Murali S, Silver MA, Jacoby D, Fedson S, Hummel SL, Kristen AV, Damy T, Planté-Bordeneuve V, Coelho T, Mundayat R, Suhr OB, Waddington Cruz M, Rapezzi C; THAOS Investigators. Genotype and phenotype of transthyretin cardiac amyloidosis: THAOS (Transthyretin Amyloid Outcome Survey). *J Am Coll Cardiol* 2016;**68**: 161–172.
- Jacobson DR, Alexander AA, Tagoe C, Buxbaum JN. Prevalence of the amyloidogenic transthyretin (TTR) V122I allele in 14 333 African-Americans. *Amyloid* 2015;**22**:171–174.
- Planté-Bordeneuve V, Said G. Familial amyloid polyneuropathy. *Lancet Neurol* 2011;**10**:1086–1097.
- Tanskanen M, Peuralinna T, Polvikoski T, Notkola IL, Sulkava R, Hardy J, Singleton A, Kiuru-Enari S, Paetau A, Tienari PJ, Myllykangas L. Senile systemic amyloidosis affects 25% of the very aged and associates with genetic variation in alpha2-macroglobulin and tau: a population-based autopsy study. *Ann Med* 2008; **40**:232–239.
- Authors/Task Force members, Elliott PM, Anastasakis A, Borger MA, Borggrefe M, Cecchi F, Charron P, Hagege AA, Lafont A, Limongelli G, Mahrholdt H, McKenna WJ, Mogensen J, Nihoyannopoulos P, Nistri S, Pieper PG, Pieske B,

- Rapezzi C, Rutten FH, Tillmanns C, Watkins H. 2014 ESC Guidelines on diagnosis and management of hypertrophic cardiomyopathy: the task force for the diagnosis and management of hypertrophic cardiomyopathy of the European Society of Cardiology (ESC). *Eur Heart J* 2014;**35**:2733–2779.
9. Ng B, Connors LH, Davidoff R, Skinner M, Falk RH. Senile systemic amyloidosis presenting with heart failure: a comparison with light chain-associated amyloidosis. *Arch Intern Med* 2005;**165**:1425–1429.
 10. Gertz MA, Benson MD, Dyck PJ, Grogan M, Coelho T, Cruz M, Berk JL, Plante-Bordeneuve V, Schmidt HHJ, Merlini G. Diagnosis, prognosis, and therapy of transthyretin amyloidosis. *J Am Coll Cardiol* 2015;**66**:2451–2466.
 11. Gillmore JD, Maurer MS, Falk RH, Merlini G, Damy T, Dispenzieri A, Wechalekar AD, Berk JL, Quarta CC, Grogan M, Lachmann HJ, Bokhari S, Castano A, Dorbala S, Johnson GB, Glaudemans AW, Rezak T, Fontana M, Palladini G, Milani P, Guidalotti PL, Flatman K, Lane T, Vonberg FW, Whelan CJ, Moon JC, Ruberg FL, Miller EJ, Hutt DF, Hazenberg BP, Rapezzi C, Hawkins PN. Nonbiopsy diagnosis of cardiac transthyretin amyloidosis. *Circulation* 2016;**133**:2404–2412.
 12. Maurer MS, Schwartz JH, Gundapaneni B, Elliott PM, Merlini G, Waddington-Cruz M, Kristen AV, Grogan M, Witteles R, Damy T, Drachman BM, Shah SJ, Hanna M, Judge DP, Barsdorf AI, Huber P, Patterson TA, Riley S, Schumacher J, Stewart M, Sultan MB, Rapezzi C; ATTR-ACT Study Investigators. Tafamidis treatment for patients with transthyretin amyloid cardiomyopathy. *N Engl J Med* 2018;**379**:1007–1016.
 13. Adams D, Gonzalez-Duarte A, O'Riordan WD, Yang C-C, Ueda M, Kristen AV, Tourneir I, Schmidt HH, Coelho T, Berk JL, Lin K-P, Vita G, Attarian S, Planté-Bordeneuve V, Mezei MM, Campistol JM, Buades J, Brannagan TH, Kim BJ, Oh J, Parman Y, Sekijima Y, Hawkins PN, Solomon SD, Polydefkis M, Dyck PJ, Gandhi PJ, Goyal S, Chen J, Strahs AL, Nochor SV, Sweetser MT, Garg PP, Vaishnav AK, Gollob JA, Suhr OB. Patisiran, an RNAi therapeutic, for hereditary transthyretin amyloidosis. *NEJM* 2018;**379**:11–21.
 14. Benson MD, Waddington-Cruz M, Berk JL, Polydefkis M, Dyck PJ, Wang AK, Planté-Bordeneuve V, Barroso FA, Merlini G, Obici L, Scheinberg M, Brannagan TH 3rd, Litchy WJ, Whelan C, Drachman BM, Adams D, Heitner SB, Conceição I, Schmidt HH, Vita G, Campistol JM, Gamez J, Gorevic PD, Gane E, Shah AM, Solomon SD, Monia BP, Hughes SG, Kwoh TJ, McEvoy BW, Jung SW, Baker BF, Ackermann EJ, Gertz MA, Coelho T. Inotersen treatment for patients with hereditary transthyretin amyloidosis. *N Engl J Med* 2018;**379**:22–31.
 15. Holmgren G, Steen L, Ekstedt J, Groth C-G, Ericzon B-G, Eriksson S, Andersen O, Karlberg I, Nordén G, Nakazato M, Hawkins P, Richardson S, Pepys M. Biochemical effect of liver transplantation in two Swedish patients with familial amyloidotic polyneuropathy (FAP-met30). *Clin Genet* 2008;**40**:242–246.
 16. Ericzon BG, Wilczek HE, Larsson M, Wijayatunga P, Stangou A, Pena JR, Furtado E, Barroso E, Daniel J, Samuel D, Adam R, Karam V, Poterucha J, Lewis D, Ferraz-Neto BH, Cruz MW, Munar-Ques M, Fabregat J, Ikeda S, Ando Y, Heaton N, Otto G, Suhr O. Liver transplantation for hereditary transthyretin amyloidosis: after 20 years still the best therapeutic alternative? *Transplantation* 2015;**99**:1847–1854.
 17. Liepnies JJ, Zhang LQ, Benson MD. Progression of transthyretin amyloid neuropathy after liver transplantation. *Neurology* 2010;**75**:324–327.
 18. Okamoto S, Zhao Y, Lindqvist P, Backman C, Ericzon BG, Wijayatunga P, Henein MY, Suhr OB. Development of cardiomyopathy after liver transplantation in Swedish hereditary transthyretin amyloidosis (ATTR) patients. *Amyloid* 2011;**18**:200–205.
 19. Sack FU, Kristen A, Goldschmidt H, Schnabel PA, Dengler T, Koch A, Karck M. Treatment options for severe cardiac amyloidosis: heart transplantation combined with chemotherapy and stem cell transplantation for patients with AL-amyloidosis and heart and liver transplantation for patients with ATTR-amyloidosis. *Eur J Cardiothorac Surg* 2008;**33**:257–262.
 20. Coelho T, Adams D, Silva A, Lozeron P, Hawkins PN, Mant T, Perez J, Chiesa J, Warrington S, Tranter E, Munisamy M, Falzone R, Harrop J, Cehelsky J, Bettencourt BR, Geissler M, Butler JS, Sehgal A, Meyers RE, Chen Q, Borland T, Hutabarat RM, Clausen VA, Alvarez R, Fitzgerald K, Gamba-Vitalo C, Nochor SV, Vaishnav AK, Sah DW, Gollob JA, Suhr OB. Safety and efficacy of RNAi therapy for transthyretin amyloidosis. *N Engl J Med* 2013;**369**:819–829.
 21. Suhr OB, Coelho T, Buades J, Pouget J, Conceicao I, Berk J, Schmidt H, Waddington-Cruz M, Campistol JM, Bettencourt BR, Vaishnav A, Gollob J, Adams D. Efficacy and safety of patisiran for familial amyloidotic polyneuropathy: a phase II multi-dose study. *Orphanet J Rare Dis* 2015;**10**:109.
 22. Solomon SD, Adams D, Kristen A, Grogan M, González-Duarte A, Maurer MS, Merlini G, Damy T, Slama MS, Brannagan TH 3rd, Dispenzieri A, Berk JL, Shah AM, Garg P, Vaishnav A, Karsten V, Chen J, Gollob J, Vest J, Suhr O. Effects of patisiran, an RNA interference therapeutic, on cardiac parameters in patients with hereditary transthyretin-mediated amyloidosis. *Circulation* 2019;**139**:431–443.
 23. <https://clinicaltrials.gov/ct2/show/NCT02319005?term=revusiran> (15 March 2019).
 24. Benson MD, Dasgupta NR, Rissing SM, Smith J, Feigenbaum H. Safety and efficacy of a TTR specific antisense oligonucleotide in patients with transthyretin amyloid cardiomyopathy. *Amyloid* 2017;**24**:219–225.
 25. Bulawa CE, Connelly S, Devit M, Wang L, Weigel C, Fleming JA, Packman J, Powers ET, Wiseman RL, Foss TR, Wilson IA, Kelly JW, Labaudinière R. Tafamidis, a potent and selective transthyretin kinetic stabilizer that inhibits the amyloid cascade. *Proc Natl Acad Sci USA* 2012;**109**:9629–9634.
 26. Coelho T, Maia LF, Martins da Silva A, Waddington Cruz M, Planté-Bordeneuve V, Lozeron P, Suhr OB, Campistol JM, Conceição IM, Schmidt HH, Trigo P, Kelly JW, Labaudinière R, Chan J, Packman J, Wilson A, Grogan DR. Tafamidis for transthyretin familial amyloid polyneuropathy: a randomized, controlled trial. *Neurology* 2012;**79**:785–792.
 27. Lozeron P, Théaudin M, Mincheva Z, Ducot B, Lacroix C, Adams D; French Network for FAP (CORNAMYL). Effect on disability and safety of Tafamidis in late onset of Met30 transthyretin familial amyloid polyneuropathy. *Eur J Neurol* 2013;**20**:1539–1545.
 28. Merlini G, Planté-Bordeneuve V, Judge DP, Schmidt H, Obici L, Perlini S, Packman J, Tripp T, Grogan DR. Effects of tafamidis on transthyretin stabilization and clinical outcomes in patients with non-Val30Met transthyretin amyloidosis. *J Cardiovasc Transl Res* 2013;**6**:1011–1020.
 29. Sekijima Y, Dendle MA, Kelly JW. Orally administered diflunisal stabilizes transthyretin against dissociation required for amyloidogenesis. *Amyloid* 2006;**13**:236–249.
 30. <http://ir.eidostx.com/news-releases/news-release-details/eidos-therapeutics-announces-positive-phase-2-data-ag10> (20 March 2019).
 31. Castaño A, Helmke S, Alvarez J, Delisle S, Maurer MS. Diflunisal for ATTR cardiac amyloidosis. *Congest Heart Fail* 2012;**18**:315–319.
 32. Ferreira N, Cardoso I, Domingues MR, Vitorino R, Bastos M, Bai G, Saraiva MJ, Almeida MR. Binding of epigallocatechin-3-gallate to transthyretin modulates its amyloidogenicity. *FEBS Lett* 2009;**583**:3569–3576.
 33. Kristen AV, Lehrke S, Buss S, Mereles D, Steen H, Ehlermann P, Hardt S, Giannitsis E, Schreiner R, Haberkorn U, Schnabel PA, Linke RP, Röcken C, Wanker EE, Dengler TJ, Altland K, Katus HA. Green tea halts progression of cardiac transthyretin amyloidosis: an observational report. *Clin Res Cardiol* 2012;**101**:805–813.
 34. Cardoso I, Martins D, Ribeiro T, Merlini G, Saraiva MJ. Synergy of combined doxycycline/TUDCA treatment in lowering Transthyretin deposition and associated biomarkers: studies in FAP mouse models. *J Transl Med* 2010;**8**:74.
 35. Obici L, Cortese A, Lozza A, Lucchetti J, Gobbi M, Palladini G, Perlini S, Saraiva MJ, Merlini G. Doxycycline plus tauroursodeoxycholic acid for transthyretin amyloidosis: a phase II study. *Amyloid* 2012;**19**:34–36.
 36. Wixner J, Pilebro B, Lundgren HE, Olsson M, Anan I. Effect of doxycycline and ursodeoxycholic acid on transthyretin amyloidosis. *Amyloid* 2017;**24**:78–99.
 37. Pepys MB, Herbert J, Hutchinson WL, Tennent GA, Lachmann HJ, Gallimore JR, Lovat LB, Bartfai T, Alanine A, Hertel C, Hoffmann T, Jakob-Roetne R, Norcross RD, Kemp JA, Yamamura K, Suzuki M, Taylor GW, Murray S, Thompson D, Purvis A, Kolstoe S, Wood SP, Hawkins PN. Targeted pharmacological depletion of serum amyloid P component for treatment of human amyloidosis. *Nature* 2002;**417**:254.
 38. Gillmore JD, Tennent GA, Hutchinson WL, Gallimore JR, Lachmann HJ, Goodman HJ, Offer M, Millar DJ, Petrie A, Hawkins PN, Pepys MB. Sustained pharmacological depletion of serum amyloid P component in patients with systemic amyloidosis. *Br J Haematol* 2010;**148**:760–767.
 39. Richards DB, Cookson LM, Berges AC, Barton SV, Lane T, Ritter JM, Fontana M, Moon JC, Pinzani M, Gillmore JD, Hawkins PN, Pepys MB. Therapeutic clearance of amyloid by antibodies to serum amyloid P component. *N Engl J Med* 2015;**373**:1106–1114.
 40. Richards DB, Cookson LM, Barton SV, Liefgaard L, Lane T, Hutt DF, Ritter JM, Fontana M, Moon JC, Gillmore JD, Wechalekar A, Hawkins PN, Pepys MB. Repeat doses of antibody to serum amyloid P component clear amyloid deposits in patients with systemic amyloidosis. *Sci Transl Med* 2018;**10**:eaan3128.
 41. <https://clinicaltrials.gov/ct2/show/NCT03044353> (12 March 2019).
 42. <https://adinsight.springer.com/drugs/800038353> (12 March 2019).
 43. <https://clinicaltrials.gov/ct2/show/NCT0336580> (12 March 2019).
 44. Ponikowski P, Voors AA, Anker SD, Bueno H, Cleland JGF, Coats AJS, Falk V, González-Juanatey JR, Harjola VP, Jankowska EA, Jessup M, Linde C, Nihoyannopoulos P, Parissis JT, Pieske B, Riley JP, Rosano GMC, Ruilope LM, Ruschitzka F, Rutten FH, van der Meer P; ESC Scientific Document Group. 2016 ESC Guidelines for the diagnosis and treatment of acute and chronic heart failure: the Task Force for the diagnosis and treatment of acute and chronic heart failure of the European Society of Cardiology (ESC) Developed with the special contribution of the Heart Failure Association (HFA) of the ESC. *Eur Heart J* 2016;**37**:2129–2200.

45. Milani P, Dispenzieri A, Scott CG, Gertz MA, Perlini S, Mussinelli R, Lacy MQ, Buadi FK, Kumar S, Maurer MS, Merlini G, Hayman SR, Leung N, Dingli D, Klarich KW, Lust JA, Lin Y, Kapoor P, Go RS, Pellikka PA, Hwa YL, Zeldenrust SR, Kyle RA, Rajkumar SV, Grogan M. Independent prognostic value of stroke volume index in patients with immunoglobulin light chain amyloidosis. *Circ Cardiovasc Imaging* 2018;**11**:e006588.
46. Muchtar E, Gertz MA, Kumar SK, Lin G, Boilson B, Clavell A, Lacy MQ, Buadi FK, Hayman SR, Kapoor P, Dingli D, Rajkumar SV, Dispenzieri A, Grogan M. Digoxin use in systemic light-chain (AL) amyloidosis: contra-indicated or cautious use? *Amyloid* 2018;**25**:86–92.
47. Feng DLi, Edwards WD, Oh JK, Chandrasekaran K, Grogan M, Martinez MW, Syed IS, Syed II, Hughes DA, Lust JA, Jaffe AS, Gertz MA, Klarich KW. Intracardiac thrombosis and embolism in patients with cardiac amyloidosis. *Circulation* 2007;**116**:2420–2426.
48. El-Am EA, Dispenzieri A, Melduni RM, Ammash NM, White RD, Hodge DO, Noseworthy PA, Lin G, Pislaru SV, Egbe AC, Grogan M, Nkomo VT. Direct current cardioversion of atrial arrhythmias in adults with cardiac amyloidosis. *J Am Coll Cardiol* 2019;**73**:589–597.
49. Kristen AV, Dengler TJ, Hegenbart U, Schonland SO, Goldschmidt H, Sack FU, Voss F, Becker R, Katus HA, Bauer A. Prophylactic implantation of cardioverter-defibrillator in patients with severe cardiac amyloidosis and high risk for sudden cardiac death. *Heart Rhythm* 2008;**5**:235–240.
50. Lin G, Dispenzieri A, Kyle R, Grogan M, Brady PA. Implantable cardioverter defibrillators in patients with cardiac amyloidosis. *J Cardiovasc Electrophysiol* 2013;**24**:793–798.
51. Dhoble A, Khasnis A, Olomu A, Thakur R. Cardiac amyloidosis treated with an implantable cardioverter defibrillator and subcutaneous array lead system: report of a case and literature review. *Clin Cardiol* 2009;**32**:E63–E65.
52. Algalarrondo V, Dinanian S, Juin C, Chemla D, Bennani SL, Sebag C, Planté V, Le Guludec D, Samuel D, Adams D, Slama MS. Prophylactic pacemaker implantation in familial amyloid polyneuropathy. *Heart Rhythm* 2012;**9**:1069–1075.
53. Swiecicki PL, Edwards BS, Kushwaha SS, Dispenzieri A, Park SJ, Gertz MA. Left ventricular device implantation for advanced cardiac amyloidosis. *J Heart Lung Transplant* 2013;**32**:563–568.
54. Patel SR, Saeed O, Naftel D, Myers S, Kirklín J, Jorde UP, Goldstein DJ. Outcomes of restrictive and hypertrophic cardiomyopathies after LVAD: an INTERMACS analysis. *J Card Fail* 2017;**23**:859–867.
55. Thenappan T, Fedson S, Rich J, Murks C, Husain A, Pogoriler J, Anderson AS. Isolated heart transplantation for familial transthyretin (TTR) V122I cardiac amyloidosis. *Amyloid* 2014;**21**:120–123.
56. Hamour IM, Lachmann HJ, Goodman HJ, Petrou M, Burke MM, Hawkins PN, Banner NR. Heart transplantation for homozygous familial transthyretin (TTR) V122I cardiac amyloidosis. *Am J Transplant* 2008;**8**:1056–1059.
57. Davis MK, Kale P, Liedtke M, Schrier S, Arai S, Wheeler M, Lafayette R, Coakley T, Witteles RM. Outcomes after heart transplantation for amyloid cardiomyopathy in the modern era. *Am J Transplant* 2015;**15**:650–658.
58. Kpodonu J, Massad MG, Caines A, GeHA AS. Outcome of heart transplantation in patients with amyloid cardiomyopathy. *J Heart Lung Transplant* 2005;**24**:1763–1765.