



UNIVERSITÀ  
DEGLI STUDI  
FIRENZE

## FLORE

# Repository istituzionale dell'Università degli Studi di Firenze

### **Competences in bronchoscopy for Intensive Care Unit, anesthesiology, thoracic surgery and lung transplantation**

Questa è la Versione finale referata (Post print/Accepted manuscript) della seguente pubblicazione:

*Original Citation:*

Competences in bronchoscopy for Intensive Care Unit, anesthesiology, thoracic surgery and lung transplantation / Solidoro Paolo, Corbetta Lorenzo, Patrucco Filippo, Sorbello Massimiliano, Piccioni Federico, D'Amato Luigia, Renda Teresa, Petrini Flavia. - In: PANMINERVA MEDICA. - ISSN 0031-0808. - ELETTRONICO. - 61:(2019), pp. 367-385. [10.23736/S0031-0808.18.03565-6]

*Availability:*

The webpage <https://hdl.handle.net/2158/1180617> of the repository was last updated on 2019-12-20T15:25:39Z

*Published version:*

DOI: 10.23736/S0031-0808.18.03565-6

*Terms of use:*

Open Access

La pubblicazione è resa disponibile sotto le norme e i termini della licenza di deposito, secondo quanto stabilito dalla Policy per l'accesso aperto dell'Università degli Studi di Firenze (<https://www.sba.unifi.it/upload/policy-oa-2016-1.pdf>)

*Publisher copyright claim:*

La data sopra indicata si riferisce all'ultimo aggiornamento della scheda del Repository FloRe - The above-mentioned date refers to the last update of the record in the Institutional Repository FloRe

(Article begins on next page)

## REVIEW

### COMPETENCE IN INTERVENTIONAL PULMONOLOGY

# Competences in bronchoscopy for Intensive Care Unit, anesthesiology, thoracic surgery and lung transplantation

Paolo SOLIDORO <sup>1</sup> \*, Lorenzo CORBETTA <sup>2</sup>, Filippo PATRUCCO <sup>3</sup>, Massimiliano SORBELLO <sup>4</sup>,  
Federico PICCIONI <sup>5</sup>, Luigia D'AMATO <sup>6</sup>, Teresa RENDA <sup>7</sup>, Flavia PETRINI <sup>8, 9, 10</sup>

<sup>1</sup>SCDU of Pneumology, AOU Città della Salute e della Scienza di Torino, Molinette Hospital, University of Turin, Turin, Italy; <sup>2</sup>Unit of Interventional Pulmonology, University of Florence, Florence, Italy; <sup>3</sup>Unit of Pneumology, Department of Translational Medicine, Sant'Andrea Hospital, University of Piemonte Orientale, Vercelli, Italy; <sup>4</sup>Unit of Anesthesiology, Resuscitation, Vittorio Emanuele Policlinic, Catania, Italy; <sup>5</sup>Department of Critical Care and Support Therapy, IRCCS Istituto Nazionale dei Tumori Foundation, Milan, Italy; <sup>6</sup>Pediatric Intensive Care Unit, AORN "Santobono-Pausilipon", Naples, Italy; <sup>7</sup>Unit of Respiratory and Critical Care, Department of Cardio-thoracic and Vascular, Careggi University Hospital, Florence, Italy; <sup>8</sup>Department of Anesthesiology, Resuscitation and Intensive Care, University of Chieti-Pescara, Pescara, Italy; <sup>9</sup>Section of Perioperative Medicine, Pain Therapy, Intra-hospital Emergency and Intensive Care, ASL 2, Lanciano-Vasto-Chieti, Chieti, Italy; <sup>10</sup>SIAARTI, Rome, Italy

\*Corresponding author: Paolo Solidoro, SCDU of Pneumology, AOU Città della Salute e della Scienza di Torino, Molinette Hospital, University of Turin, Turin, Italy. E-mail: [psolidoro@cittadellasalute.to.it](mailto:psolidoro@cittadellasalute.to.it)

## ABSTRACT

Over the last decades, the use of flexible bronchoscopy has greatly increased in intensive care, anesthesia and thoracic surgery for diagnostic purpose, management of critical patients and to facilitate airway management for tracheal intubation, one lung ventilation and lung transplant management. The huge availability of endoscopic instruments and devices for airway management has amplified indications and possibilities for bronchoscopic procedures performed by intensive care physicians, anesthesiologists, endoscopists, and surgeons too. These practices need adequate technical skills that can be acquired only through defined learning pathways. This manuscript summarizes the indications and the competencies needed to perform bronchoscopic procedures in intensive care, anesthesia and thoracic surgery settings.

(Cite this article as: Solidoro P, Corbetta L, Patrucco F, Sorbello M, Piccioni F, D'Amato L, *et al.* Competences in bronchoscopy for Intensive Care Unit, anesthesiology, thoracic surgery and lung transplantation. Panminerva Med 2019;61:367-85. DOI: 10.23736/S0031-0808.18.03565-6)

KEY WORDS: Education - Pulmonary medicine - Intensive Care Units.

*In the future, as at present, the internist will tap and look and listen on the outside of the chest...; the roentgenologist will continue to look through the patient; but in a continually increasing proportion of cases, the surgeon, the internist and the roentgenologist will ask the bronchoscopist to look inside the patient.*  
Chevalier Jackson, MD - 1928

The ability to address difficulties in airway control is fundamental in anesthesia and resuscitation, and bronchoscopy is an indispensable tool to achieve correct intubation and to improve patient ventilation and oxygenation in any medical or surgical setting.<sup>2-4</sup>

Over the last 40 years, the use of bronchoscopy has gained widespread diffusion in clinical practice.

It is now well recognized its essential role in the management of the difficult airways and represents a standard of care for the diagnosis and treatment for many conditions in critical care setting.<sup>1</sup>

## Bronchoscopy in Intensive Care Unit and anesthesiology

### Knowledge of the diseases

Knowledge of basic disease and indications are reported in the article entitled "Flexible bronchoscopy and basic bi-

opsy technique” available in this journal issue.<sup>5</sup> Specific knowledge for intensivists and anesthesiologists can be summarized as follows:

- normal, variant and abnormal bronchial anatomy, and relationships of bronchial tree to other important intrathoracic structures (mediastinum, and other intrathoracic structures);
- thoracic imaging (computed tomography scan [CT], positron emission tomography [PET]);
- full working knowledge of all the equipment required (bronchoscopes, forceps, bronchoalveolar lavage [BAL], brushing) including disposable bronchoscopes;
- anesthesia and sedation technique and complications;
- prevention and management of possible complications;
- predictors of difficult/impossible mask ventilation and difficult intubation conditions as: limited inter-incisor distance, high Mallampati grade without change upon phonation, mandibular protrusion, abnormal neck anatomy, sleep apnea or snoring, and obesity with a body mass index of 30 kg/m<sup>2</sup> or greater and large neck circumference, congenital airway deformities (e.g. Pierre Robin syndrome), head and neck cancers (e.g. supraglottic tumors and neck radiation), trauma of face/neck or upper airway, presence of beard.<sup>6</sup>

*Indications for procedure*

Bronchoscopy in the Intensive Care Unit (ICU) may be used for a large number of indications, either diagnostic or therapeutic often overlapping in these contexts,<sup>7</sup> as listed in Table I.

ASPIRATION

Aspiration of gastric content is harmful and in the critical care setting may often be unrecognized. In most cases small amount of liquid content is aspirated as a result of passive

regurgitation; the presence of gastric tube does not seem to be protective, hence the recommendation of keeping head tilt at 30° degree in case of sedated and intubated patients.

Bronchoscopy appears useful in cases of aspiration of particulate content, causing atelectasis on chest X-ray, and of large volume of gastric content that can be removed reducing the inflammatory reaction.<sup>8,9</sup>

INFECTIONS

Respiratory infections of the critically ill patients can be classified as community-acquired (CAP), ventilator associated (VAP) and pneumonia in the immunocompromised patients.

Blind, non-bronchoscopic, protected alveolar lavage and protected specimen brush are used in intubated patients, and there is no evidence supporting the superiority of flexible bronchoscopy-guided BAL over blind techniques. Nonetheless flexible bronchoscopy (FB) is suitable for etiologic diagnosis of pulmonary infectious disease, if the aforementioned non-bronchoscopic methods fail to identify etiologic agent. Moreover, FB-guided BAL may be considered as the best diagnostic tool for the diagnosis of *Pneumocystis jirovecii* (*carinii*).<sup>10, 11</sup>

HEMOPTYSIS

FB can identify the source of bleeding and address therapeutic interventions. In case of mild/moderate hemoptysis cold saline and low dose epinephrine can be instilled locally; fibrin precursor can be administered as well.

In case of massive hemoptysis, utilization of rigid bronchoscope should be considered, as its larger working channel allows more efficient suction of blood and ventilation can be ensured through side port allowing therapeutic intervention. Placement of a Fogarty balloon tipped catheter can be used as a temporary damage-control strategy or therapeutic option; after its deployment, it is inflated to include the bleeding area and removed after 24 or 48 hours. If definite control of condition is achieved it can be removed, otherwise other strategies, especially if bronchial lesions are present, including cryosurgery, laser photocoagulation and electrocautery should be adopted. In case of massive unilateral bleeding, selective bronchial intubation of the non-diseased lung and one lung ventilation (OLV) should be considered as a life-saving option.<sup>3, 12, 13</sup>

THORACIC TRAUMA

Tracheobronchial lesions are reported in 2.8% of patients with severe non-penetrating chest trauma.<sup>14</sup> Lacerations or

TABLE I.—*Indications for flexible bronchoscopy in ICU.*

Diagnostic	Therapeutic
Management of secretions or atelectasis	Restoring airway patency
Airway evaluation Failed extubation	Difficult intubation
Hemoptysis microbiological samples	Hemorrhage control
Central airway obstruction	Removal of foreign body
Strictures, stenosis and airway lesions; prolonged mechanical ventilation	Guidance for percutaneous tracheostomy; dilation

fractures of the bronchial tree can be recognized on FB examination and suspected when fracture of clavicle, upper ribs, sternum, chest or lung contusions are present.<sup>15</sup> Persistent air leak despite thoracostomy tube and persistence of massive pneumothorax are an urgent indication for FB, as a main bronchus rupture could be present.<sup>12</sup>

AIRWAY INHALATION INJURY

Is a common condition in fire victims, it can be categorized in thermal or chemical injury and more often involves the upper airways. Inhalation injury can be asymptomatic during the first 72 hours and FB has to be performed early when there is a clinical suspicion. FB serial examinations of the airways allow the recognition the extent of inflammatory lesions and the early recognition of area of necrosis. FB examination can only explore the larger diameter portions of the bronchial tree whereas the involvement of distal airways can account for the severity of respiratory dysfunction.<sup>14, 16-18</sup>

LOBAR COLLAPSE

FB is used to restore airway patency in those regions of atelectasis when conventional treatments such as physiotherapy and recruitment maneuvers failed.<sup>3</sup> In addition to aspiration in the affected area, local instillation of normal saline or mucolytics can be administered to fluidify thick and tenacious secretions; use of routine FB after lung resection surgery has been reported not to be superior to standard treatments including physiotherapy and suction.<sup>19</sup>

AIRWAY MANAGEMENT IN DIFFICULT INTUBATION

FB can be used for airway management of expected difficult patients to intubate in the operating theatre; it has been used as first approach for the intubation of the critically ill patients and higher success of first pass intubation have been reported. Maintenance of spontaneous breathing during FB intubation is crucial in patients predicted to be difficult to ventilate in order to avoid hypoxemia.<sup>20</sup>

ONE-LUNG VENTILATION

OLV is commonly used during thoracic anesthesia, is seldom used in ICU if not in the case of air leak, bronchopleural fistula or lung transplant, or in case of monolateral massive bleeding. OLV can be accomplished placing a double-lumen tracheal (DLT) tube in the airways or a bronchial blocker (BB).

DLT is usually inserted under laryngoscopy and FB is passed through the tracheal lumen to confirm the correct

DLT position. BB is passed through a standard endotracheal tube along with FB, under direct visualization, positioned in the bronchus that is supposed to be excluded from ventilation.<sup>21</sup>

PERCUTANEOUS TRACHEOSTOMY

During percutaneous dilatational tracheotomy (PDT), direct FB visualization reduces the incidence of complications (false airways, pneumothorax, subcutaneous emphysema, posterior wall lesions, periprocedural bleeding).

Contraindications for procedure

Contraindications to FB are due to patient's severe critical ill conditions as severe hypoxia, hypercarbia, instable hemodynamic status and alteration of fluids and electrolytes balance, summarized in Table II.<sup>3, 7, 12</sup>

Complications

FB is considered a safe procedure, if carried out by an experienced bronchoscopist fully capable to judge risks and benefits in actual clinical scenarios, especially in critically ill patients. Complications can be related to anesthesia or sedation, with FB or other reasons including ancillary techniques and are summarized in Table III.<sup>7</sup>

TABLE II.—Risk conditions of flexible bronchoscopy in ICU.

Respiratory and airway	Cardiovascular	Other side effects
Acute bronchospasm	Hemodynamic instability (on vasopressor or inotropes)	Coagulation disorders
Pneumothorax	Unstable Arrhythmias	Raised ICP
Hypoxemia: Oxygen Saturation (<90% on FiO <sub>2</sub> =100)	Acute ischemic changes	Severe Acidosis pH<7.2
Tracheal tube internal diameter <8 mm (using FB 5.7 mm)		

TABLE III.—Complications of Flexible Bronchoscopy in ICU.

Local anesthesia	Bronchoscopy	Biopsy or brushing
<ul style="list-style-type: none"> <li>• Respiratory arrest</li> <li>• Cardiac failure</li> <li>• Convulsion</li> </ul>	<ul style="list-style-type: none"> <li>• Airway obstruction</li> <li>• Laryngospasm</li> <li>• Bronchospasm</li> <li>• Hypoxemia</li> <li>• Hypotension</li> <li>• Vasovagal reaction</li> <li>• Pneumonia</li> <li>• Pulmonary edema</li> <li>• Hemorrhage</li> </ul>	<ul style="list-style-type: none"> <li>• Pneumothorax</li> <li>• Hemorrhage</li> </ul>

Critically ill patients often receive analgesics or sedative drugs to blunt stress response and to facilitate patient-ventilator interaction. Cautious titration of drugs administration should aim to minimize airway reflexes avoiding systemic or cardiovascular side effects during FB. The same warning applies to lidocaine administration that should not exceed 7.0 mg/kg when used for topicalization due to potential severe side-effects such as methemoglobinemia, seizures or severe cardiac toxicity. Lipid emulsion, for rescue therapy, has to be promptly available.<sup>22</sup>

Infective risks related to airway manipulation include bacteremia and fever, especially when dealing with immunocompromised patients.<sup>23</sup> Hypoxemia is more frequently reported and can be particularly severe in critical care. Hypoxemia is the result of alveolar collapse and saline instillation as in BAL.

The presence of the FB itself causes a reduction of 10 to 20 mmHg in PaO<sub>2</sub> but a drop as high as 30 to 60 mmHg has been described, mostly as a consequence of the marked fall in tidal volume (TV) and functional residual capacity (FRC). Basing on similar mechanism, also hypercarbia could appear, resulting in modification of pH and worsening of respiratory exchanges. Modification of both static and dynamic lung volumes may occur, and lung compliance decreases as a result of suctioning and surfactant wash-out due to saline instillation. This can be of significant concern in patients affected by pneumonia or ARDS.<sup>1, 7</sup>

Major pathological effects are listed in Table IV.

Increase in airway resistance due to the partial obstruction of the FB is particularly severe in the intubated patients. Peak inspiratory pressure, positive end-expiratory

TABLE IV.—Physiological alterations due to flexible bronchoscopy in ICU.

Respiratory	Cardiovascular	Other side-effects
<ul style="list-style-type: none"> <li>• Increase in airway resistance</li> <li>• Reduction of lung compliance</li> <li>• Worsening of gas exchange (hypoxemia - hypercarbia)</li> </ul>	<ul style="list-style-type: none"> <li>• Reduction or increase of cardiac output</li> <li>• Increase in hearth rate</li> <li>• Increase in pulmonary arterial pressure</li> </ul>	<ul style="list-style-type: none"> <li>• Increase in intracranial pressure</li> </ul>

pressure and TV are affected; altered cardiopulmonary interactions can affect hemodynamic status as well.

In order to minimize the aforementioned responses, matching the correct size of the instrument with ETT tube is mandatory (Table V).

Arrhythmias may occur from the effects of hypoxemia and increased sympathetic tone during the examination, and can precipitate poor cardiac function.

**Knowledge of the instruments**

Knowledge of bronchoscopes and accessories are reported in the article entitled “Flexible bronchoscopy and basic biopsy technique” available in this journal issue.<sup>5</sup> Specific knowledge for intensivists and anesthesiologists can be summarized as follows:

*Invasive and non-invasive interfaces*

Devices for bronchoscopy under mechanical ventilation are:

- supraglottic airway devices (SADs);
- endotracheal tubes and tracheostomy cannulae;
- univent tube;
- endotracheal DLT and endobronchial tube;
- hollow airway catheters.

Non-invasive ventilation (NIV) and facial masks are described here:

- endoscopic facial mask: these masks share the same basic design. They have two ports. One port is intended for instrument insertion provided with a soft silicone sealing ring allowing passage of the endotracheal tube or the fiberoptic instrument with minimal leaks, while the other connects to ventilation circuit allowing assisted ventilation through bag-mask unit, Mapleson circuit or anesthesia machine. The silicone port can be located at the center of the mask or at the bottom, as for the Patil-Syracuse mask. In patients affected by mild-moderate respiratory failure, NIV is nowadays commonly performed as a first line treatment to avoid intubation or re-intubation after weaning. Those patients may require FB for diagnostic or therapeutic purposes. NIV can be preemptively adopted in subjects with impending respiratory failure, requiring FB. NIV can

TABLE V.—Flexible bronchoscope and endotracheal tube diameters.

	6.0 mm	7.0 mm	8.00 mm	9.00 mm
Cross-sectional area of tube without bronchoscope; mm <sup>2</sup>	28.3	38.5	50.3	63.6
Remaining tube area with bronchoscope <i>in situ</i> : mm <sup>2</sup>	6.8	17.0	28.7	42.1
Proportion of tube cross-section area obstructed	76.0%	55.8%	42.9%	33.8%

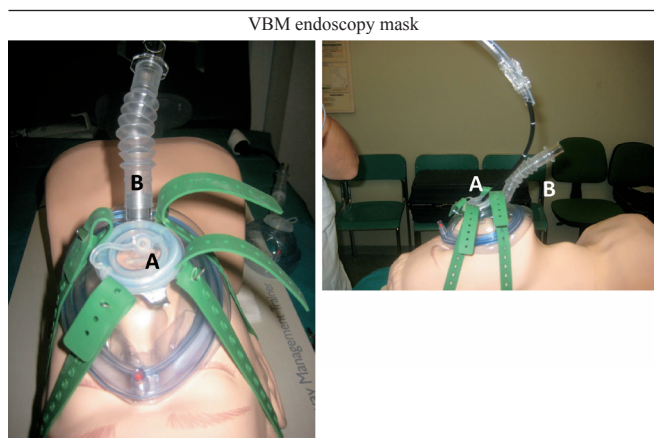


Figure 1.—Endoscopic mask with a central orifice (A) for placement of bronchoscope and additional port (B) that can be connected to a circuit for non-invasive ventilation.

also be maintained during FB with selected patient interfaces. In any case the procedure is at higher risk and has to be performed by an experienced operator.

Access to the airways during NIV can be achieved:

- orally when patients are on Nasal CPAP;
- *via* endoscopic facemasks (Figure 1);
- attaching a T-adaptor or a catheter mount with suctioning port to a full-face mask.

Alternatively, High-flow nasal cannula (HFNC) can be used to deliver oxygen during FB.

Mild sedation and local topicalization may be used, the latter performed by “spray as you go” technique while gently advancing the instrument through the patient’s airway.

Higher levels of oxygen supplementation are required, especially in the hypoxiemic patients, in whom a risk of procedural worsening and need of intubation has been reported up to 8 hours after procedure.

Repeated FB during NIV can be useful in COPD patients unable to clear secretions to avoid endotracheal intubation and invasive ventilation.<sup>24-26</sup>

### Disposable FB systems

Different kind of disposable instruments are today available: some manufacturers developed flexible video-endoscopes to be covered with single-use sheaths provided with suction/working channel. Other devices come as single-use, in different sizes with or without operative channels for different purposes and to be connected to dedicated reusable monitors.

There is no evidence favoring one system over the other, and a certain number of studies underlining the potential advantages of single-use FB systems:

- no need for sterilization of the FB after use;
- reduction or abolishing of cross-infections (especially in critical care settings);
- potential reduction of costs (whereas any cost/benefit analysis should take account of settings, number of procedures, indications);
- reduction of FB damage during training or specific procedures (*i.e.* percutaneous tracheostomy);
- potential increased availability of FB in remote locations, in low number of FB procedures settings with option for coupling with SADs for rescue intubation.

The effective performance of these devices needs to be compared with reusable FB in specific settings (*i.e.* FB intubation), taking account that specific procedures might or could not be performed with these devices (operative bronchoscopy, biopsies, EBUS, etc.).

### Core basic skills

Basic skills are reported in the article entitled “Flexible bronchoscopy and basic biopsy techniques” available in this journal issue.<sup>5</sup>

Specific skills for the ICU must include:

- ability to choose appropriate sedation techniques and interfaces for awake patients on oxygen therapy (*e.g.* HFNC, NIV);
- safe administration of intravenous sedation and how

TABLE VI.—*Drugs for local anesthesia.*

Medication	Dose	Onset	Peak	Duration	Metabolism	Adverse effects	Toxicity	Reversal agents
Benzocaine	10-20% 2-3 spray	15-30 sec	7 min	12-15 min	Hepatic	Contact dermatitis, altered taste sensation	Methemoglobinemia	Methylene blue if methemoglobinemia is present
Tetracaina	Solution 0.25-0.5% Total not to exceed 20 mg. Nebulized 0.5% Total not to exceed 20 mg	30 sec 5-10 min	1-10 min 8-15 min	30-150 min 30 min	Hepatic	Bradycardia, hypotension, GI upset	Cardiac arrest, ventricular arrhythmias	

TABLE VII.—*Drugs for sedation and anesthesia: benzodiazepines.*

Medication	Dose	Onset	Peak	Duration	Metabolism	Adverse effects	Toxicity	Reversal agents
Midazolam	0.01-0.006 mg/kg iv bolus 1-2.5 mg IV in 2-5 minutes	0.5-1 min	5-10 min	1-2 h	Hepatic	Hypotension, respiratory depression, CNS depression, ataxia	Respiratory arrest, coma	Flumazenil
Diazepam	2.5-20 mg over 30 min	1min	8 min	1-3 h	Hepatic	Respiratory depression, CNS depression, slurred speech, ataxia	Propylen glycol toxicity, respiratory arrest, coma	Flumazenil
Lorazepam	Bolus: 1 mg/kg Continuous: 0.01-0.1 mg/kg/h	10-15 min	15-30 min	4-8 h	Hepatic	Respiratory depression, CNS depression, ATN, lactic acidosis, ataxia	Propylen glycol toxicity, respiratory arrest, coma	Flumazenil

TABLE VIII.—*Drugs for sedation and anesthesia: opioids.*

Medication	Dose	Onset	Peak	Duration	Metabolism	Adverse effects	Toxicity	Reversal agents
Fentanyl	0.5-20 mcg/kg	5-10 min	1-2 h	1-2 h	Hepatic	Respiratory depression, rigidity, bradycardia	Respiratory arrest, hypotension, hypoxia, shock	Naloxone
Alfentanil	5-10 mcg/kg	Immediate	Immediate	1-2 h	Hepatic	Respiratory depression, rigidity	Respiratory arrest, hypotension, hypoxia, shock	Naloxone
Remifentanyl	Induction: 0.1-1 mg/kg Maintenance 0.05-0.2 mg/kg/min	1-3 min	3-5 min	3-10 min	Blood and tissue esterases	Respiratory depression, rigidity, hypotension	Respiratory arrest, hypotension, hypoxia, shock	Naloxone

TABLE IX.—*Drugs for sedation and anesthesia: others.*

Medication	Dose	Onset	Peak	Duration	Metabolism	Adverse effects	Toxicity
Propofol	Bolus 1 mg/kg, 0.5-3 mg/kg every 3-5 minutes Maintenance 25-75 mcg/kg/ min	30 sec	2 min	3-5 min	Hepatic	Injection site irritation, bradycardia, hypotension, respiratory depression, muscle spasm	Propofol infusion syndrome, hypotension, hypoxia, shock cardiac arrest
Ketamine	Bolus 1-4.5 mg/kg, in 1 minute Maintenance 0.01- 0.03 mg/ kg/min	30-40 sec	1 min	5-10 min	Hepatic	Hypertension, tachycardia, apnea, laryngeal spasm, emergence hallucination, raised ICP	Coma, hearth failure, respiratory arrest, seizures
Remifentanyl	Bolus 1 mcg/Kg over 10 min Maintenance 0.5-1 mcg/kg/h	1 min	15-30 min	1-2 h	Hepatic	Hypotension, bradycardia	Oversedation, hypotension
Dexmedetomidine	Bolus 1 mcg/kg IV over 10 minutes — Maintenance 0.6-0.7 mcg/kg/h IV	5-10 min	15 min	1-2 h	Hepatic	Bradycardia, hypotension	

to reverse excessive sedation (Table VI, VII, VIII, IX);<sup>22</sup>

- safe administration of local anesthetic including appreciation of potential toxicity (Table VI);<sup>22</sup>
- prevention and management, within the multidisci-

plinary team, of any complications arising during the procedure (bleeding, pneumothorax, cardiac and respiratory complications);

- choice of the size of bronchoscope, devices for

ventilation and modality of ventilation and oxygenation (Table V);

- ability to choose appropriate interfaces for patients on NIV (e.g. endoscopic facemask) or suitable bronchoscope for patients on invasive mechanical ventilation (endotracheal or tracheostomic tube ideally at least 2 mm larger than bronchoscope diameter);
- replacing tracheostomy tubes and bronchoscopic evaluation in case of weaning and decannulation;
- performance of percutaneous tracheostomy with bronchoscopy guide;
- assessment of tracheal lesions (perforation, ring fracture, granulomas, cicatricial stenosis);
- prevention and management, within the multidisciplinary team, of any complications arising during the procedure (bleeding, pneumothorax, cardiovascular and respiratory complications).

### Procedural steps for practical training

All bronchoscopic procedures should be performed after accurate check of needed drugs and devices using dedicated check-lists and according to specific algorithms. The knowledge of devices, guidelines and algorithms is mandatory and must be complemented by non-technical skills. Finally, in addition to specific skills, it is essential to always outline the operational strategy with the team before starting any bronchoscopic procedure. This section focuses mainly on technical issues regarding the use of the FB. The reader is invited to consult the specific guidelines for the remaining aspects of the procedures described.

#### *Awake fiber-optic intubation*

Awake fiberoptic intubation (A-FOI) is the first-choice strategy in difficult airway patients, although emerging data suggest an important role also for videolaryngoscopes, including the awake intubation technique.<sup>27-29</sup>

Main steps of A-FOI are:<sup>6, 30-32</sup>

- choice of the proper endotracheal tube (ETT); loading the ETT and passing the bronchoscope through the ETT;
- introduction of the bronchoscope can be performed nasally or orally with an oral bite block in conscious patients with topical anesthesia alone, or in sedated or anaesthetized patients. In circumstances in which mask ventilation may be difficult and risk of airway loss is high, a spontaneous breathing technique is preferred. A nasal approach is particularly useful in patients with a large tongue, limited mouth opening, receding lower jaw, or tracheal devia-

tion, or in cases in which an unobstructed surgical field is beneficial (e.g. dental surgery);

- alternative option is preliminary insertion of ETT before FB, so to avoid the situation of difficult ET passage through upper airways despite FB being in trachea. The risk of bleeding and secretions limits this technique as both could hinder or worsen FB performance;
- if FOI includes the jaw thrust, tongue protrusion, positioning the scope in the midline of the pharynx during advancement, and rotating the ETT 90° counter-clockwise, if resistance is encountered during advancement, facilitate passage through the vocal cords;
- a laryngoscope blade or a dedicated oral airway can be used as an adjuvant to displace the tongue in order to facilitate bronchoscope and ETT passage;
- once the scope enters the trachea, it is advanced to the level of the mid-trachea, where a previously loaded ETT is then guided into the trachea;
- the ETT should be turned gently counter-clockwise with retraction and then re-advanced if resistance is encountered during placement;
- once the ETT is passed, a bronchoscopic view should verify placement, with optimal tube positioning 2–3 cm above the carina in an adult patient. The scope is then withdrawn as the tube is held in place by hand;
- finally, tube placement is checked by end-tidal carbon dioxide and auscultation and subsequently secured and connected to a circuit for ventilation;
- deep sedation should be achieved only after sure passage of the ETT beyond the vocal cords, especially in case of predicted difficult intubation/ventilation.

#### *Fiberoptic intubation through supraglottic airway devices*

Fiberoptic intubation through supraglottic airway device (SAD) can be the right solution in case of unpredicted difficult airway and failed intubation scenario, when SAD positioning is indicated to maintain adequate oxygenation. This technique has been shown to have a higher success rate than blind intubation through SAD in potentially difficult airway patient. It should be performed using a FB to minimize the risk of airway trauma. The second SADs generation, designed to support both ventilation and intubation, have been claimed to minimize the risk of aspiration of gastric contents.<sup>33</sup> Several 1<sup>st</sup> and 2<sup>nd</sup> generation SADs are available to assist and facilitate FB intubation, either as planned and rescue technique. Use of this technique should be advised in case of a failed intubation scenario with optimal ventilation granted through a rescue SAD and adequate experience in the technique. The re-

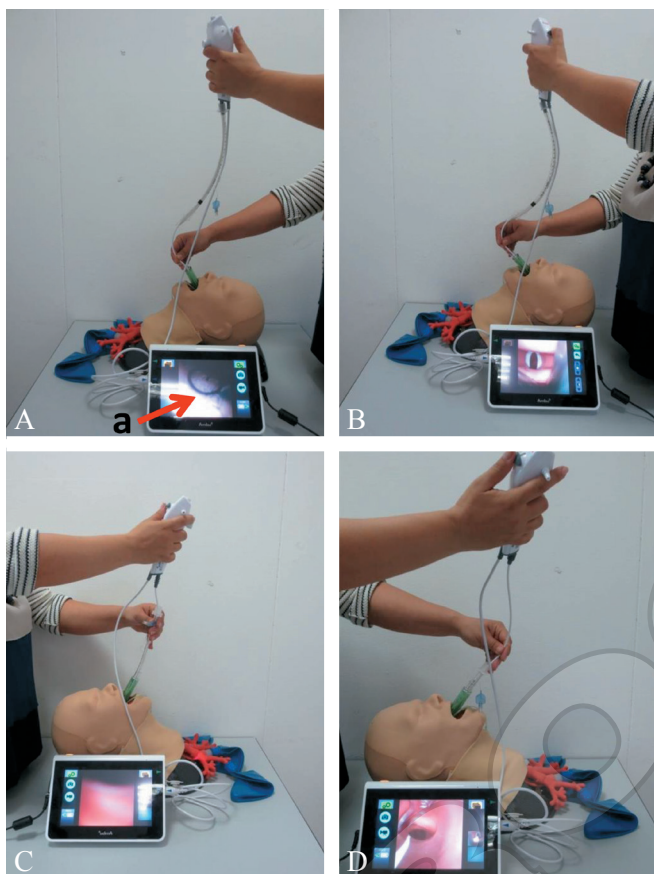


Figure 2.—Placement of endotracheal tube through a supraglottic airway device. Second generation Laryngeal Mask Airway (LMA, AuraGain™) equipped with integrated navigation marks to provide guidance as to how far the flexible bronchoscope has been introduced (\*). A, B) Insertion of bronchoscope mounted with a well-lubricated, fully deflated ETT through the laryngeal mask; C) advancement of the ETT into the trachea with the bronchoscope at its lower end until its position was 2-3 cm above the carina (D).

removal of SAD (if planned) after intubation might be tricky with some SADs and result in loss of airway. Recent papers suggest the use of an oxygenated intubation technique through SAD combining use of catheter mount and ETT cuff inflation inside SAD during intubation maneuver.<sup>34</sup>

#### PLACEMENT OF ENDOTRACHEAL TUBE THROUGH A SAD

Main steps for placement of an endotracheal tube through a SAD are (Figure 2):<sup>35, 36</sup>

- choose the size of the SAD on the patient's weight according to the manufacturer's recommendations. Check for both lubrication of the airway channel and correct deflation of the cuff (the i-gel cuff is a soft gel-like non-inflatable cuff);

- check that the level of anesthesia (or unconsciousness) is adequate before attempting insertion of SAD. The head of the patient, if possible, should be positioned extended with flexion of the neck in a position normally used for tracheal intubation (*i.e.* the “sniffing” position);

- stop face mask ventilation, keep the oropharyngeal space open, and insert the SAD in the oropharynx. Ventilate the patient's lungs until capnography curve confirms normal ventilation;

- insert the fob mounted with a well-lubricated, fully deflated ETT through the SAD. Advance the FOB with the ETT into the trachea at its lower end until its position is 2-3 cm above the carina;

- remove the scope, inflate the ETT cuff, connect the ETT to the breathing circuit and start ventilation.

If necessary, SAD removal is safer using an airway exchange catheter (AEC) or dedicated tools provided with some SADs (*i.e.* LMA Fastrach - Teleflex Medical or AirQ, Mercury Medical). It serves as a guide if the tube accidentally comes out during the removal of the SAD. During this maneuver secure the ETT with the fingers in the oropharynx as soon as the SAD is out far enough.

#### INTUBATION THROUGH SADs USING THE AINTREE INTUBATION CATHETER

The Aintree intubation catheter (Cook Medical, Bloomington, IN, USA) is a hollow and blunt-tipped catheter with an internal diameter of 4.7 mm. It has centimeter markings from 5 to 35 cm on the outside to help with placement. The catheter is long enough to fit completely over a flexible bronchoscope, leaving enough space at the end of the scope for FB flexing and to navigate. An ETT needs to be of an internal diameter of 7.0 mm or greater to accommodate the Aintree intubation catheter (AIC). The distal opening of AIC has a small side hole on each side to prevent ‘whipping’ of the catheter inside the patient's airway if jet ventilation is used (recent papers anyway strongly discourage use of JV through airway catheters to avoid barotrauma).

The technique is not recommended for airway rescue, and should be performed as a stepwise process:<sup>33, 37</sup>

- select appropriate sizes of AIC, ETT and FB (maximum diameter 4.2 mm). Preload the AIC onto the FOI, lubricating the outer surface of both;

- place appropriate SAD in oropharynx (LMA Supreme is not recommended for AIC intubation);

- introduce the FB with loaded the AIC through the SAD and advance it to 2-3 cm before the carina;

- remove only the FB;
- deflate SAD cuff and start withdrawing it taking care not to advance the AIC (ensure that it never exceeds 26 cm from the lips). Apply counter pressure to the AIC and remove SAD;
- using a laryngoscope, railroad the ETT over the AIC, maintaining the tip orientation anteriorly and advance it into the trachea;
- confirm ventilation with capnography, remove the AIC and, if possible, check the final position of ETT with FB.

The AIC can be used also for FB-guided placement or exchange of endotracheal or nasotracheal tubes.

#### Airway management in anesthesia for thoracic surgery

Airway management for thoracic surgery requires specific skills for DLT and bronchial blocker (BB) placement. DLT is usually preferred to BB because it allows both lung isolation and separation.<sup>38</sup> BB, placed through standard single lumen tube, is the best choice in case of difficult airway.<sup>39</sup> Bronchoscopy is considered essential to confirm the right position of DLTs and BBs.

#### Double lumen tube placement

The DLT placement aims to position the bronchial lumen in the correct bronchus (left or right) allowing the tracheal lumen to ventilate the opposite bronchus. The right DLT is more difficult to put in place because of the risk of occlusion of the right upper lobe bronchus.

Main steps of FOB-guided DLT placement:

- select appropriate size of DLT and FOB;
- perform tracheal intubation with the use of laryngoscope/videolaryngoscope;
- advance the DLT until a slight resistance is perceived;
- after adequate lubrication of the FOB, introduce it into the tracheal lumen of the DLT and identify the carina;
- verify the correct position of the bronchial lumen (the bronchial cuff must be barely visible) (Figure 3);
- verify the patency of the bronchus;
- repeat the FOB control after patient position changes and throughout the intervention if necessary.

Some anesthesiologists prefer to introduce the DLT in the trachea and to guide it into the desired bronchus using the FOB introduced in the bronchial lumen.

If a right DLT is used, the FB is useful to adjust the depth of the bronchial lumen, taking care to ensure the correct position of the ventilation slot for the right upper lobe bronchus.

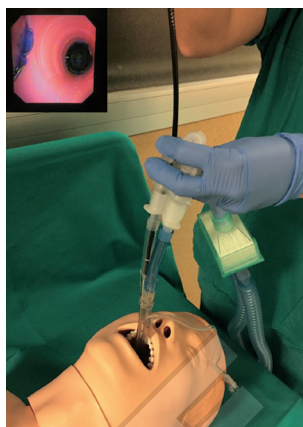

Figure 3.—Bronchoscopic check of the correct position of a left DLT in a mannequin model. The FB is inserted in the tracheal lumen. In the small image the right main bronchus is patent while the bronchial lumen of the DLT is correctly placed in the left main bronchus (the blue bronchial cuff is slightly visible).

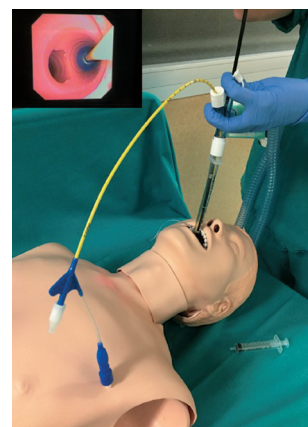


Figure 4.—Bronchoscopic check of the correct position of an Arndt bronchial blocker in a mannequin model. The FB is inserted through the bronchoscopy port of the airway adapter. In the small image the left main bronchus is patent while the BB is correctly placed in the right main bronchus (the blue cuff is inflated).

#### Bronchial blocker placement

Today, different BBs are available for lung isolation. Each BB needs a specific insertion technique (not described in this context). Anyhow, the first step is always standard intubation with a single lumen conventional endotracheal tube. Afterwards, the FB is inserted and a first inspections of the airway is performed. Finally, the BB is inserted and positioned with the FB. Arndt BB (Cook Medical, Bloomington, IN, USA) is guided in place using the guide loop coupled with the FB (Figure 4). Other BBs, like Cohen (Cook Medical), Uniblocker (Fuji Systems Corporation, Tokyo, Japan) and EZ-blocker (Teleflex Medical Ltd, Athlone, Ireland), are placed under direct FOB vision. The BB correct position must be checked again after patient positioning and throughout surgery if necessary.

#### Percutaneous dilatational tracheostomy

Tracheostomy is one of the most commonly performed procedures in critically ill patients requiring long-term mechanical ventilation. Percutaneous tracheostomy (PT) has gained widespread acceptance and has replaced surgical tracheostomy as the technique of choice in many ICUs.<sup>40-43</sup> Several percutaneous methods, *i.e.* Ciaglia single/multiple dilators, Fantoni, Griggs, Frova's Percu Twist™ (Teleflex Medical), Ciaglia Blue Dolphin™ (Cook Medical) use a modification of the Seldinger technique; in addition, iden-

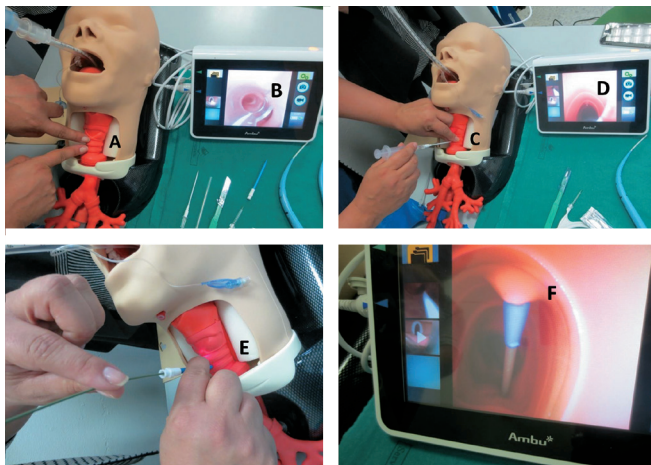


Figure 5.—Percutaneous dilatational tracheostomy (PDT). Tracheal landmarks (A). Bronchoscope is inserted distally through the ETT (B) until the point of the anterior neck incision (A). Insertion of introducer needle (C) with endoscopic view (D). Insertion of dilator (E) over wire with endoscopic view (F).

tification of the optimal PT technique in critically ill patients remains unclear. Bronchoscopic guidance of PDT is increasingly recommended as a safety measure facilitating the choice of the correct tracheostomy site, trans-illumination for blood vessels identification, verification of the intra-tracheal guidewire and dilator placements, positioning of the tracheal cannula. It has been shown that neck ultrasound is not inferior to bronchoscopy in terms of major complications and procedure duration, but this technique does not provide a view of the posterior wall of the trachea<sup>44</sup> and cannot be used during dilation phase. Recent papers suggest the use of both techniques, indicating they cannot be mutually exclusive.<sup>45</sup>

The Ciaglia's PDT is between the most common approaches.<sup>46-48</sup> Whichever PT procedure requires a trained multidisciplinary tracheostomy team:<sup>48</sup> an operating physician to perform tracheostomy, a physician managing bronchoscope and airways, an assistant holding the ETT




Figure 6.—Percutaneous dilatational tracheostomy (PDT). Insertion of dilator over wire (A) with endoscopic view (B). Tracheostomy tube (C) insertion over introducer (D, E) with endoscopic view (F).

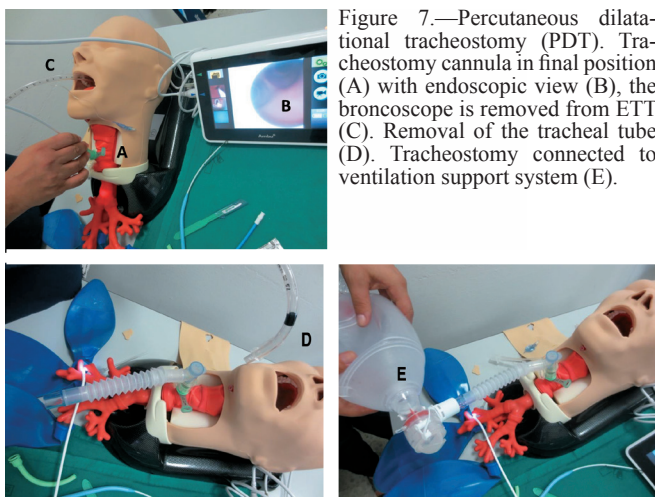


Figure 7.—Percutaneous dilational tracheostomy (PDT). Tracheostomy cannula in final position (A) with endoscopic view (B), the bronchoscope is removed from ETT (C). Removal of the tracheal tube (D). Tracheostomy connected to ventilation support system (E).

and a paramedical staff who assists with the bronchoscope, monitoring the vital signs and administering medication.

Main steps of Ciaglia Blue Rhino technique<sup>47, 48</sup> (Figure 5, 6, 7):

- interrupt in adequate advance enteral nutrition, if any;
- sedate and paralyze the patient before positioning. Keep patient on ventilation and 100% FiO<sub>2</sub>. Continuously monitor vital signs, pulse oximetry and ventilator parameters;
- prepare the surgical field with antiseptic agents and drape it. Check all parts of the tracheostomy set;
- properly position the patient. Extend the neck for better tracheal. Verify the anatomy and identify the site of insertion (preferentially between either the first and second or the second and third tracheal rings). A pre-procedure ultrasound should be done if anatomy is not clear (*e.g.*, morbid obesity) and to seek for pretracheal vessels;
- insert the FB in ETT with adequate swivel or port allowing maintenance of adequate ventilation; deflate the ETT cuff and withdraw ETT under FB view until cuff is visualized just below vocal cords and anterior neck incision is transilluminated, then reinflate the cuff;
- infiltrate the skin of surgical site with local anesthetic containing a vasoconstrictor;
- make a 2-cm transverse incision at the proposed insertion site;
- insert a 14-gauge cannula-over-the-needle through the skin incision with non-dominant hand stabilizing the trachea during the process and under FB guidance, aspirating for air. Tracheal placement of needle is confirmed by aspirating air bubbles into the saline filled syringe attached to the needle, and by direct visualization through the bronchoscope;

- withdraw the needle leaving the cannula in place and insert Seldinger guidewire through the cannula;
- dilate the insertion site using a small tracheal dilator;
- withdraw the tracheal puncture cannula and insert a stiffer cannula guide over the guidewire. Use the single, graduated and sharply tapered dilator with a hydrophilic coating and dipped in water-based jelly, for complete dilatation in one step. Load the complete assembly over the guidewire and advance as a unit into trachea;
- after adequate dilatation, dilator is removed and tracheostomy tube with appropriate adapter is inserted into trachea over the guiding catheter;
- remove the guidewire assembly and leave the tracheostomy tube in place. Connect tracheostomy tube to the ventilator, remove the bronchoscope from ETT and insert it into tracheostomy tube to confirm correct placement. Secure the tracheostomy tube to the neck;
- insert again the bronchoscope into the ETT, deflate the cuff, withdraw ETT and check supra-stomal trachea and glottic space.

#### Theoretical and practical training

Bronchoscopy in ICU and anesthesiology setting need different levels of competence. Firstly, trainees must learn airway management techniques and algorithms (predicted and unpredicted difficult intubation, SADs insertion). Afterwards, trainees must devote to advanced FOB-based techniques like intubation through SADs, DLTs and BBs placement, ICU diagnostic and therapeutic techniques, and PT.<sup>49</sup>

Many resources are available for training purpose:

- printed and multimedia resources concerning airway management are easily available. A simple online bronchoscope simulator is freely available too ([www.thoracic-anesthesia.com](http://www.thoracic-anesthesia.com)). Even Apps for smartphone are available for training purpose (*i.e.* Double Lumen App by Crystal Clear Solutions, a simulator for DLTs and BBs positioning);
- skill simulation and task training on plastic simulators (*e.g.* airway mannequins for intubation, FOI and SAD insertion: Laerdal Airway Trainer, Ambu Airway Management Trainer, TruCorp AirSim; airway mannequins for tracheostomy: TruCorp AirSim Advance Combo bronchi, TruCorp AirSim Combo X);<sup>50-54</sup>
- simulation with virtual simulators and Model Fidelity (*e.g.* Symbionix BRONCH Mentor, AccuTouch Virtual Reality Bronchoscopy Simulator, Orsim Operating Room Simulation);<sup>55-59</sup>
- training on animal model<sup>60</sup> and cadaver;<sup>37, 61, 62</sup>

- training on the patient with a tutor and then under supervision: a video monitor for larger image display may be most effective for the novice or trainee;<sup>51, 63, 64</sup>

- non-technical skill and teamwork simulation: the simulation and practice of crisis management may be as important as technical skill learning with any particular airway technique. Algorithms developed for difficult airway management as well as preplanned strategies may be most useful during such clinical scenarios.<sup>65, 66</sup> A course on bronchoscopy in anesthesia and critical care settings must include an introductory session, ending in a quantitative and qualitative competence assessment on flexible bronchoscopy and basic techniques and then a specific session on the topic.

### Quantitative and qualitative assessment

#### Quantitative assessment

There is no uniform mandatory requirement for the optimum number of procedures, which should be done under supervision and trained on simulators before undertaking bronchoscopy alone during anesthesia or ICU procedures. Predominantly, the recommendations consist in expert opinions and depend on the complexity of the procedure being undertaken.<sup>67-70</sup>

Number of procedures that should be undertaken under supervision:

- bronchoscopy *via* nasal and oral route and *via* tracheostomy and ETT: 50-100;<sup>71, 72</sup>
- nasotracheal FOI: 45;<sup>73</sup>
- difficult intubation: unknown.

FB intubation is best accomplished by those clinicians who use a bronchoscope in their daily practice.<sup>6</sup> Some have suggested that an acceptable level of expertise may be achievable after 10 FOI on anesthetized patients<sup>31, 74-76</sup> and 15-20 intubations on awake patients with normal anatomy.<sup>74, 75</sup> Due to lack of standardization for this skill acquisition, the actual level of competence following training is difficult to assess:

- double lumen tube positioning: 22-38;<sup>77</sup>
- tracheostomy: 20 supervised procedures.<sup>48, 70, 72, 78</sup>

#### Qualitative assessment

The qualitative assessment includes:

- multiple choice questions (MCQ);
- case-based questionnaire;
- case-based discussion (CBD);
- simulated assessment;
- direct observation of procedural skills (DOPS): pre-

determined checklist of a specific task on the use of FB in ICU (e.g. PDT-STAT, Percutaneous Dilatational Tracheostomy Skill and Task Assessment Tool).<sup>69</sup>

#### Outcome assessment

The outcome assessment is based on:

- percentage of complications from the operative room register;
- ability to introduce the bronchoscope: >90%;
- measures of performance of a specific task on the use of FB in ICU (time to task completion, number of attempts).

#### Competence maintenance (by logbook)

Number of procedures/year:

- bronchoscopy *via* nasal and oral route and *via* tracheostomy and ETT: 25/year,<sup>72</sup> 50/year;<sup>71</sup>
- difficult intubation: unknown.

Retraining should be undertaken to maintain knowledge and procedural skills on a yearly basis after a high-fidelity simulation practice.<sup>56</sup>

- double lumen tube: unknown;
- tracheostomy: 10/year.<sup>78</sup>

### Bronchoscopy in thoracic surgery

A thorough understanding of the role of bronchoscopy is needed in the diagnostic evaluation and management of patients with benign and malignant disorders of the chest. Pulmonary and thoracic surgery trainees have a different bronchoscopic approach. Pulmonary fellows may be more focused on the diagnostic and palliative management of a particular chest disorder; thoracic surgery trainees focus on the information that endoscopic findings can give them regarding surgical treatment. At the moment, there are no reports in the literature evaluating the level of proficiency of recently graduated thoracic surgery trainees, but it is highly unlikely that most are fully competent in advanced therapeutic bronchoscopy at the completion of their residency. The American Board of Thoracic Surgery (ABTS) requires resident-trainees in the general thoracic surgery track to perform bronchoscopic diagnostic procedures, including simple procedures such as inspective bronchoscopy, BAL and endobronchial or transbronchial biopsy, and therapeutic procedures including “core out” of tumor, laser, dilatation of strictures, stent placement, and photodynamic therapy, or other interventions such as cryotherapy, electrocautery, or argon plasma coagulation.<sup>68, 79, 80</sup>

This section describes the knowledge and skills that both pulmonologists and thoracic surgeon fellows must master. Some procedures are prevalently related to pulmonology (e.g. EBUS/EUS), but they must become part of the knowledge of a thoracic surgeon as well; while the interventional pulmonology fellows must become acquainted with others, although they are prevalently surgical in nature. It is therefore fundamental that training sessions are organized jointly, with an exchange of experiences between the two. The tools for the practical training include low and high-fidelity simulators, although non-technical skills and teamwork simulation are recommended.

### Knowledge of the diseases and instruments

#### *Indications for procedures*

Indications are usually divided in three sections:

- preoperative bronchoscopy includes procedures for the diagnosis and the acquisition of information regarding surgical treatment of pulmonary resection. In particular, diagnostic bronchoscopies are now fundamental for the correct diagnosis and staging of the malignant lesion, with diagnosis of central or peripheral neoplasm, and staging of lymph nodes involvement. For the diagnosis, we must remake the role of basic procedures such as biopsies with forceps or TBNA of the visible lesion; for peripheral lesions an undoubted role is played by fluoroscopy and other guidance tools as radial EBUS, endobronchial navigation bronchoscopy (ENB), ultrathin bronchoscopy and the combination of all these instruments. For the correct staging of the lesion, a complete evaluation should provide the integration of radiological and metabolic exams (positron-emission tomography [PET]) with cytological samples obtained from lymph nodes with fine needle or histologic TBNA. For completeness, the possibility to review and re-examine images recorded during bronchoscopy is fundamental for the thoracic surgeon in order to define correct position and characteristics of the lesion with endobronchial tree;<sup>81-86</sup>

- during surgical procedure: sometimes the bronchoscopy support is needed for the correct placement of DLT, Univent, endobronchial tubes or BB;<sup>39</sup>

- postoperative bronchoscopies are usually performed to evaluate and treat surgical complications; in particular for hemorrhagic complications, to remove endobronchial mucus plugs and clots, to evaluate suture-related complications, to diagnose broncho-pleural fistulae, tracheo-bronchial stenosis, to collect specimens for microbiologic cultures.<sup>87-91</sup>

The trainee should pay particular attention to:

- lung cancer and mesothelioma: radiographic and ultrasound chest imaging, diagnosis and staging;
- pneumothorax and pleural effusion;
- emphysema and lung volume reduction surgery (LVRS);
- lung transplantation;
- tracheal stenosis.

A thorough knowledge of airways anatomy of bronchial tree, lung parenchyma, vascularization of lung, bronchi and thoracic wall, and their anatomical variants is required. The trainee should have the familiarity with principal surgical techniques and the ability to select the most appropriate treatment option;<sup>92, 93</sup> he/she should be familiar with diagnosis of peri- and postoperative complications diagnosis and management.

Technical knowledge of flexible and operative bronchoscopy, interventional endo-sonography, pleural procedures, endoscopic and surgical emphysema treatment are needed, in particular:

- insertion and management of chest drainage;
- rigid bronchoscopy and positioning of stent, valves and coils;
- glues and reabsorbable materials;
- thoracoscopy and video-assisted thoracoscopy (VATS);
- mediastinoscopy;
- laryngoscopy.

#### Core basic skills

The core basic skills are described here:

- expertise in the clinical evaluation and management of the main respiratory diseases; active participation in the multidisciplinary team — including pulmonologist, radiologist, oncologist, thoracic surgeons, etc. — in making the best diagnostic and staging evaluation and final decision;
- competency in flexible and, optionally, rigid bronchoscopy;
- preoperative assessment in lung cancer: inspection bronchoscopy, including Narrow Band Imaging (NBI) and EBUS, in order to select the most appropriate treatment option; histology diagnosis of the lesion and assessment of the planned resection margins, including evaluation with multiple biopsies of submucosal infiltration; evaluation of lung sparing surgery; evaluation of the bronchial caliber for possible discrepancies;
- diagnosis, evaluation and treatment of tracheal stenosis: when considering tracheal resection for benign and

malignant pathology; accurate measurements of normal and abnormal airway must be taken with rigid bronchoscope;

- diagnosis and treatment of surgical complications with flexible and rigid bronchoscopy, thoracic ultrasound and pleural procedures.

#### Procedural steps for practical training (check list)

Procedural steps for flexible and rigid bronchoscopy are reported in the articles entitled “Flexible bronchoscopy and basic biopsy technique” and “Operative bronchoscopy” available in this journal issue.<sup>5</sup> Specific knowledge for thoracic surgery are the steps involved in the measurement of tracheal stenosis for resection. The rigid bronchoscope, with telescope inserted almost to the end, is used to measure the distance from the carina to the inferior margin, superior margin, and inferior border of the cricoid. This is done starting distally and moving proximally. A ruler measures a proximal fixed point from the bronchoscope to the incisors. This allows the surgeon to make a schematic drawing showing relative distances between the carina and the distal margin of the lesion, the length of the lesion, and between the proximal margin of the lesion and the cricoid cartilage.

#### Hands-on practical training

Training for flexible and rigid bronchoscopy are reported in the articles entitled “Flexible bronchoscopy and basic biopsy technique” and “Operative bronchoscopy” available in this journal issue.<sup>5</sup>

Specific for bronchoscopy in thoracic surgery:

- preoperative bronchoscopy: for diagnostic procedures; interventional pulmonologists should assist at least at 25 lobectomies and sleeve lobectomies; case-based discussion of patients eligible for planned procedures; participation at tumor board meetings;
- for diagnosis and treatment of surgical complications: observer at Course in Thoracic Surgery Unit where are performed at least 100 procedures/year, being present in operating room twice a week for 4 weeks, to observe surgical procedures and to position chest drainage under a surgeon supervision; video-forum on emergency and elective surgery cases; use of video-systems for tutoring, as well as the most recent disposable bronchoscopes; skill simulation or task training and non-technical skill team simulation.
- training on diagnosis and treatment of late surgical complications (*i.e.* tracheal stenosis) and LVRS.

### Quantitative and qualitative assessment

#### Quantitative assessment

Number of procedures are:


- for interventional pulmonologists: 100;
- for thoracic surgeons: the American Board of Thoracic Surgery (ABTS) requires resident-trainees in the general thoracic surgery track to perform 40 bronchoscopic procedures: 30 simple diagnostic procedures, including airway inspection, BAL, and endobronchial or trans-bronchial biopsy, and 10 therapeutic procedures (an established practice in most thoracic surgery programs is to perform intraoperative bronchoscopy in almost all patients undergoing thoracic surgical procedures).

#### Qualitative assessment

Qualitative assessment includes:

- multiple choice questions (MCQ);
- case-based questionnaires;
- direct observation of procedural skills (DOPS) for flexible and rigid bronchoscopy.

#### Competence maintenance

Number of procedures/year:  established practice in most thoracic surgery programs is to perform intraoperative bronchoscopy in almost all patients undergoing thoracic surgical procedures.

### Bronchoscopy in lung transplantation

Lung transplantation is a well-established treatment for end-stage lung diseases, offering patients a potential increase of survival and improvement of quality of life.<sup>94, 95</sup>

In lung transplantation bronchoscopic procedures are pivotal in pre-transplant selection of the donor and in the post-operative management, in particular in diagnosis and treatment of post-transplantation complications: airway stenosis, fistulas, infections, acute and chronic rejection.<sup>96-101</sup> Traditional diagnostic bronchoscopy is performed in case of regular monitoring examinations (for the scheduled follow-up or for the early diagnosis of complications) or “as needed”, based on clinical necessities.<sup>95-105</sup> Overall, both early diagnosis of rejection or infections, in particular viral ones, and evaluation of the balance between infection and immunity response, lead to changes in treatment plans in 60% of diagnostic protocols.<sup>106</sup> Bronchial and trans-bronchial biopsies are crucial in the diagnosis of

lymphocyte bronchitis-bronchiolitis and acute or chronic rejection; recently cryobiopsies have been introduced in some centers for the trans-bronchial surveillance of acute and chronic rejections, providing larger samples to analyze,<sup>107-110</sup> but the use in follow-up procedures seems to be difficult to manage in daily clinical practice because of the need of rigid procedures; the management of surgical and anastomotic complications requires a considerable experience with rigid bronchoscopy.<sup>111</sup>

#### Knowledge of the diseases and instruments

Indication for the procedures are:

- pretransplant evaluation of recipient: microbiological and cytomorphological sampling;
- pretransplant evaluation of lung donor: microbiological sampling;
- during transplant: evaluation of surgical sutures and microbiological sampling;
- post-transplant: microbiologic and cytomorphologic/histologic surveillance on the basis of surveillance scheme of each lung transplantation center;
- post-transplant: management of airways complications; diagnosis of oncologic complications (*i.e.* lung cancer, lymphomas).

Trainee must have experience on general pulmonology pathologies and on cystic fibrosis, pulmonary hypertension, respiratory infections and indications for lung transplantation; among specific knowledge, the physician needs a particular experience on: imaging interpretation, surgical techniques of lung transplantation, technical knowledge on flexible and operative bronchoscopy, endoscopic and surgical treatment of emphysema, clinics of lung transplantation (onset times of complications from re-perfusion, primary graft dysfunction, acute and chronic rejection, anastomotic complications, bacterial, viral, mycotic and parasitic infections, immunosuppressive regimens of induction and maintenance employed to reduce the rate of rejection and infection-related complications, management of waiting list ranked by lung allocation score), interpretation of BAL, EBB and TBB specimens, local epidemiology of infections.<sup>79, 112-115</sup>

#### Core basic skills

The lung transplantation team needs some skills relative to the management of the patient; in particular the physicians need expertise in the clinical evaluation and management of respiratory diseases; an active participation in the transplantation multidisciplinary team, including pulmonologist,

radiologist, oncologist, thoracic surgeons, etc., is crucial for the selection of candidates and case discussion of clinical problems. Among other skills required for the optimal clinical management of the patient, the physician should be competent in evaluation and management of timing of complications' development (*i.e.* ischemia-reperfusion injury, acute and chronic rejection, bacterial, viral and mycotic and parasitic infections, anastomotic complications) and management of post-transplantation complications with flexible and rigid bronchoscopy.

Concerning technical skills, the pulmonologist who works in a lung transplantation team needs competency in: flexible and rigid bronchoscopy with particular competence in bronchial and trans-bronchial biopsies, mechanical dilatation, stent choice and positioning (optional and under evaluation: trans-bronchial cryobiopsies because not performed in all centers); endoscopic lung volume reduction procedures for the management of native lung hyperinflation in single lung transplantation for COPD and of prolonged postsurgical air leaks.

#### Procedural steps for practical training

Procedural steps include three specific phases.

Preoperative evaluation of the graft:

- exclusion of bronchial lesions and full evaluation of microbiology and cytology of recipients of organs, to be done during the initial selection stages; this phase could be repeated during *ex-vivo* lung perfusion reconditioning procedure of the explanted organ;
- exclusion of purulent secretion in the donor.

During transplantation procedure:

- evaluate surgical sutures with particular attention to donor-recipient diameter discrepancy of main bronchi, ischemia of the mucosa, completeness of sutures.

During follow-up of the transplanted patient:

- performance of FB in acute and chronic rejection;
- performance of rigid bronchoscopy and stent positioning and dilations procedures; management and surveillance of pulmonary and bronchial infections;
- indications for bronchoscopy in ICU.

#### Hands-on practical training

In addition to general theoretical and practical training, common to all procedures, there are specific practical training for bronchoscopy in lung transplantation:

- for FB and relative procedures;
- course in Lung Transplantation Unit where at least 20 transplantations/year are performed, participating in pre-

and post-transplantation bronchoscopy procedures in the operating room, in the ICU for microbiology and anastomosis monitoring procedures, in resuscitation-related procedures, in the pulmonology ward for follow-up procedures;

- case-based discussions on patients eligible for operation;
- participation at Lung Tumor Board meetings discussing lung transplantation;
- for anastomotic complications;
- non-technical skills scenarios.

### Qualitative and quantitative assessment

#### Quantitative assessment

Assessment criteria for Flexible bronchoscopy and basic biopsy technique and Operative bronchoscopy procedures are discussed more in detail elsewhere in this special issue.

In order to reach the specific competence for lung transplantation, we suggest a learning curve at least 20% longer.

#### Qualitative assessment

Qualitative assessment includes:

- MCQ;
- case-based questionnaires;
- DOPS for flexible and rigid bronchoscopy.

### References

1. Kabadayi S, Bellamy MC. Bronchoscopy in critical care. *BJA Educ* 2017;17:48–56.
2. Henderson JJ, Papat MT, Latto IP, Pearce AC, Difficult Airway S; Difficult Airway Society. Difficult Airway Society guidelines for management of the unanticipated difficult intubation. *Anaesthesia* 2004;59:675–94.
3. Liebler JM, Markin CJ. Fiberoptic bronchoscopy for diagnosis and treatment. *Crit Care Clin* 2000;16:83–100.
4. Weiss YG, Deutschman CS. The role of fiberoptic bronchoscopy in airway management of the critically ill patient. *Crit Care Clin* 2000;16:445–51, vi. [vi.]
5. Valentini I, Lazzari L, Michieletto L, Innocenti M, Savoia F, Del Prato B, *et al.* Competence in flexible bronchoscopy and basic biopsy technique. *Panminerva Med* 2018;61:000–000.
6. Petrini F, Accorsi A, Adrario E, Agrò F, Amicucci G, Antonelli M, *et al.*; Gruppo di Studio SIAARTI “Vie Aeree Difficili”; IRC e SARNePI; Task Force. Recommendations for airway control and difficult airway management. *Minerva Anestesiol* 2005;71:617–57.
7. Guerreiro da Cunha Fragoso E, Gonçalves JM. Role of fiberoptic bronchoscopy in intensive care unit: current practice. *J Bronchology Interv Pulmonol* 2011;18:69–83.
8. Marik PE. Aspiration pneumonitis and aspiration pneumonia. *N Engl J Med* 2001;344:665–71.
9. Raghavendran K, Nemzek J, Napolitano LM, Knight PR. Aspiration-induced lung injury. *Crit Care Med* 2011;39:818–26.
10. Berton DC, Kalil AC, Teixeira PJ. Quantitative versus qualitative cultures of respiratory secretions for clinical outcomes in patients with ventilator-associated pneumonia. *Cochrane Database Syst Rev* 2012;1:CD006482.
11. Du Rand IA, Blaikley J, Booton R, Chaudhuri N, Gupta V, Khalid S, *et al.*; British Thoracic Society Bronchoscopy Guideline Group. British Thoracic Society guideline for diagnostic flexible bronchoscopy in adults: accredited by NICE. *Thorax* 2013;68(Suppl 1):i1–44.
12. Raof S, Mehrishi S, Prakash UB. Role of bronchoscopy in modern medical intensive care unit. *Clin Chest Med* 2001;22:241–61, vii. [vii.]
13. Susanto I. Comparing percutaneous tracheostomy with open surgical tracheostomy. *BMJ* 2002;324:3–4.
14. Bertelsen S, Howitz P. Injuries of the trachea and bronchi. *Thorax* 1972;27:188–94.
15. Cassada DC, Munyikwa MP, Moniz MP, Dieter RA Jr, Schuchmann GF, Enderson BL. Acute injuries of the trachea and major bronchi: importance of early diagnosis. *Ann Thorac Surg* 2000;69:1563–7.
16. Bingham HG, Gallagher TJ, Powell MD. Early bronchoscopy as a predictor of ventilatory support for burned patients. *J Trauma* 1987;27:1286–8.
17. Masanes MJ, Legendre C, Lioret N, Maillard D, Saizy R, Lebeau B. Fiberoptic bronchoscopy for the early diagnosis of subglottal inhalation injury: comparative value in the assessment of prognosis. *J Trauma* 1994;36:59–67.
18. Hassan Z, Wong JK, Bush J, Bayat A, Dunn KW. Assessing the severity of inhalation injuries in adults. *Burns* 2010;36:212–6.
19. Jaworski A, Goldberg SK, Walkenstein MD, Wilson B, Lippmann ML. Utility of immediate postlobectomy fiberoptic bronchoscopy in preventing atelectasis. *Chest* 1988;94:38–43.
20. Ma KC, Chung A, Aronson KI, Krishnan JK, Barjaktarevic IZ, Berlin DA, *et al.* Bronchoscopic intubation is an effective airway strategy in critically ill patients. *J Crit Care* 2017;38:92–6.
21. Merli G, Guarino A, Della Rocca G, Frova G, Petrini F, Sorbello M, *et al.*; SIAARTI Studying Group on Difficult Airway. Recommendations for airway control and difficult airway management in thoracic anesthesia and lung separation procedures. *Minerva Anestesiol* 2009;75:59–78, 79–96.
22. McCambridge AJ, Boesch RP, Mullon JJ. Sedation in Bronchoscopy: A Review. *Clin Chest Med* 2018;39:65–77.
23. Um SW, Choi CM, Lee CT, Kim YW, Han SK, Shim YS, *et al.* Prospective analysis of clinical characteristics and risk factors of postbronchoscopy fever. *Chest* 2004;125:945–52.
24. Maitre B, Jaber S, Maggiore SM, Bergot E, Richard JC, Bakthiari H, *et al.* Continuous positive airway pressure during fiberoptic bronchoscopy in hypoxemic patients. A randomized double-blind study using a new device. *Am J Respir Crit Care Med* 2000;162:1063–7.
25. Antonelli M, Pennisi MA, Conti G, Bello G, Maggiore SM, Michetti V, *et al.* Fiberoptic bronchoscopy during noninvasive positive pressure ventilation delivered by helmet. *Intensive Care Med* 2003;29:126–9.
26. Baumann HJ, Klose H, Simon M, Ghadban T, Braune SA, Hennigs JK, *et al.* Fiber optic bronchoscopy in patients with acute hypoxemic respiratory failure requiring noninvasive ventilation—a feasibility study. *Crit Care* 2011;15:R179.
27. Rosenstock CV, Thøgersen B, Afshari A, Christensen AL, Eriksen C, Gätke MR. Awake fiberoptic or awake video laryngoscopic tracheal intubation in patients with anticipated difficult airway management: a randomized clinical trial. *Anesthesiology* 2012;116:1210–6.
28. Ahmad I, Bailey CR. Time to abandon awake fiberoptic intubation? *Anaesthesia* 2016;71:12–6.
29. Lewis SR, Butler AR, Parker J, Cook TM, Schofield-Robinson OJ, Smith AF. Videolaryngoscopy versus direct laryngoscopy for adult patients requiring tracheal intubation: a Cochrane Systematic Review. *Br J Anaesth* 2017;119:369–83.
30. Facciolo N. La broncoscopia in unità di terapia intensiva. *Rassegna di Patologia dell'Apparato Respiratorio* 2000;24:212–9.

31. Heidegger T. Videos in clinical medicine. Fiberoptic intubation. *N Engl J Med* 2011;364:e42.
32. Collins SR, Blank RS. Fiberoptic intubation: an overview and update. *Respir Care* 2014;59:865–78, discussion 878–80.
33. Frerk C, Mitchell VS, McNarry AF, Mendonca C, Bhagrath R, Patel A, *et al.*; Difficult Airway Society intubation guidelines working group. Difficult Airway Society 2015 guidelines for management of unanticipated difficult intubation in adults. *Br J Anaesth* 2015;115:827–48.
34. Landsdalen HE, Berge M, Kristensen F, Guttormsen AB, Søfteland E. Continuous ventilation during intubation through a supraglottic airway device guided by fiberoptic bronchoscopy: a observational assessment. *Acta Anaesthesiol Scand* 2017;61:23–30.
35. Moser B, Audigé L, Keller C, Brimacombe J, Gasteiger L, Bruppacher HR. Flexible bronchoscopic intubation through the AuraGain™ laryngeal mask versus a slit Guedel tube: a non-inferiority randomized-controlled trial. *Can J Anaesth* 2017;64:1119–28.
36. Moser B, Keller C, Audigé L, Dave MH, Bruppacher HR. Fiberoptic intubation of severely obese patients through supraglottic airway: A prospective, randomized trial of the Ambu(R) AuraGain laryngeal mask vs the i-gel airway. *Acta Anaesthesiol Scand* 2018. [Epub ahead of print].
37. Lopez NT, McCoy SK, Carroll C, Jones E, Miller JA. Non-Conventional Utilization of the Aintree Intubating Catheter to Facilitate Exchange Between Three Supraglottic Airways and an Endotracheal Tube: A Cadaveric Trial. *Mil Med* 2018. [Epub ahead of print].
38. Licker M, Le Guen M, Diaper J, Triponez F, Karenovics W. Isolation of the lung: double-lumen tubes and endobronchial blockers. *Trends in Anaesthesia and Critical Care* 2014;4:47–54.
39. Campos JH, Hallam EA, Van Natta T, Kernstine KH. Devices for Lung Isolation Used by Anesthesiologists with Limited Thoracic Experience: Comparison of Double-lumen Endotracheal Tube, Univent® Torque Control Blocker, and Arndt Wire-guided Endobronchial Blocker®. *Anesthesiology* 2006;104:261–6.
40. Cheung NH, Napolitano LM. Tracheostomy: epidemiology, indications, timing, technique, and outcomes. *Respir Care* 2014;59:895–915, discussion 916–9.
41. Vargas M, Sutherasan Y, Antonelli M, Brunetti I, Corcione A, Laffey JG, *et al.* Tracheostomy procedures in the intensive care unit: an international survey. *Crit Care* 2015;19:291.
42. Brass P, Hellmich M, Ladra A, Ladra J, Wrzosek A. Percutaneous techniques versus surgical techniques for tracheostomy. *Cochrane Database Syst Rev* 2016;7:CD008045.
43. Mehta C, Mehta Y. Percutaneous tracheostomy. *Ann Card Anaesth* 2017;20(Supplement):S19–25.
44. Gobatto AL, Besen BA, Tierno PF, Mendes PV, Cadamuro F, Joelsons D, *et al.* Ultrasound-guided percutaneous dilational tracheostomy versus bronchoscopy-guided percutaneous dilational tracheostomy in critically ill patients (TRACHUS): a randomized noninferiority controlled trial. *Intensive Care Med* 2016;42:342–51.
45. Trouillet JL, Collange O, Belafia F, Blot F, Capellier G, Cesario E, *et al.* Tracheostomy in the intensive care unit: guidelines from a French expert panel. *Ann Intensive Care* 2018;8:37.
46. Ciaglia P, Firsching R, Syniec C. Elective percutaneous dilational tracheostomy. A new simple bedside procedure; preliminary report. *Chest* 1985;87:715–9.
47. Byhahn C, Wilke HJ, Halbig S, Lischke V, Westphal K. Percutaneous tracheostomy: ciaglia blue rhino versus the basic ciaglia technique of percutaneous dilational tracheostomy. *Anesth Analg* 2000;91:882–6.
48. Lerner AD, Yarmus L. Percutaneous Dilational Tracheostomy. *Clin Chest Med* 2018;39:211–22.
49. Grande B, Kolbe M, Biro P. Difficult airway management and training: simulation, communication, and feedback. *Curr Opin Anaesthesiol* 2017;30:743–7.
50. Stringer KR, Bajenov S, Yentis SM. Training in airway management. *Anaesthesia* 2002;57:967–83.
51. Guglielmi M, Urbaz L, Tedesco C, Pusceddu A, Sogni A, Ronzoni G. A structured training program for awake fiber optic intubation: teaching the complete package. *Minerva Anestesiol* 2010;76:699–706.
52. Heard AM, Lacquiere DA, Riley RH. Manikin study of fibreoptic-guided intubation through the classic laryngeal mask airway with the Aintree intubating catheter vs the intubating laryngeal mask airway in the simulated difficult airway. *Anaesthesia* 2010;65:841–7.
53. Michalek P, Donaldson W, Graham C, Hinds JD. A comparison of the I-gel supraglottic airway as a conduit for tracheal intubation with the intubating laryngeal mask airway: a manikin study. *Resuscitation* 2010;81:74–7.
54. Parotto M, Jansen JQ, AboTaiban A, Ioukhova S, Agzamov A, Cooper R, *et al.* Evaluation of a low-cost, 3D-printed model for bronchoscopy training. *Anesthesiol Intensive Ther* 2017;49:189–97.
55. Goldmann K, Steinfeldt T. Acquisition of basic fiberoptic intubation skills with a virtual reality airway simulator. *J Clin Anesth* 2006;18:173–8.
56. Boet S, Borges BC, Naik VN, Siu LW, Riem N, Chandra D, *et al.* Complex procedural skills are retained for a minimum of 1 yr after a single high-fidelity simulation training session. *Br J Anaesth* 2011;107:533–9.
57. Chandra DB, Savoldelli GL, Joo HS, Weiss ID, Naik VN. Fiberoptic oral intubation: the effect of model fidelity on training for transfer to patient care. *Anesthesiology* 2008;109:1007–13.
58. Graeser K, Konge L, Kristensen MS, Ulrich AG, Hornbech K, Ringsted C. Airway management in a bronchoscopic simulator based setting: an observational study. *Eur J Anaesthesiol* 2014;31:125–30.
59. K Latif R, Bautista A, Duan X, Neamtu A, Wu D, Wadhwa A, *et al.* Teaching basic fiberoptic intubation skills in a simulator: initial learning and skills decay. *J Anesth* 2016;30:12–9.
60. Terragni P, Mascia L, Faggiano C, Tenaglia T, Morello E, Succo G, *et al.* A new training approach in endoscopic percutaneous tracheostomy using a simulation model based on biological tissue. *Minerva Anestesiol* 2016;82:196–201.
61. Lopez A, Sala-Blanch X, Valero R, And Prats, A. Cross-Over Assessment of the AmbuAuraGain, LMA Supreme New Cuff and Intersurgical I-Gel in Fresh Cadavers. *Open J Anesthesiol* 2014;4:332–9.
62. Vignes SM, Cover CG, Chedid NR, Kleinpeter SM, Palomino J. A Novel, Adaptable Laryngeal Mask to Facilitate a Percutaneous Dilational Tracheostomy: Proof-of-Concept Prototype Demonstration on a Mannequin Model and Cadaver. *J Bronchology Interv Pulmonol* 2015;22:319–25.
63. Erb T, Hammer J, Rutishauser M, Frei FJ. Fiberoptic bronchoscopy in sedated infants facilitated by an airway endoscopy mask. *Paediatr Anaesth* 1999;9:47–52.
64. Beiderlinden M, Karl Walz M, Sander A, Groeben H, Peters J. Complications of bronchoscopically guided percutaneous dilational tracheostomy: beyond the learning curve. *Intensive Care Med* 2002;28:59–62.
65. Myatra SN, Kalkundre RS, Divatia JV. Optimizing education in difficult airway management: meeting the challenge. *Curr Opin Anaesthesiol* 2017;30:748–54.
66. Higgs A, McGrath BA, Goddard C, Rangasami J, Suntharalingam G, Gale R, *et al.*; Difficult Airway Society; Intensive Care Society; Faculty of Intensive Care Medicine; Royal College of Anaesthetists. Guidelines for the management of tracheal intubation in critically ill adults. *Br J Anaesth* 2018;120:323–52.
67. Fielding DI, Maldonado F, Murgu S. Achieving competency in bronchoscopy: challenges and opportunities. *Respirology* 2014;19:472–82.
68. Ernst A, Wahidi MM, Read CA, Buckley JD, Addrizzo-Harris DJ, Shah PL, *et al.* Adult Bronchoscopy Training: Current State and Suggestions for the Future: CHEST Expert Panel Report. *Chest* 2015;148:321–32.
69. Murgu SD, Kurman JS, Hasan O. Bronchoscopy Education: An Experiential Learning Theory Perspective. *Clin Chest Med* 2018;39:99–110.
70. Mullan JJ, Burkart KM, Silvestri G, Hogarth DK, Almeida F, Berkowitz D, *et al.* Interventional Pulmonology Fellowship Ac-

- creditation Standards: Executive Summary of the Multisociety Interventional Pulmonology Fellowship Accreditation Committee. *Chest* 2017;151:1114–21.
71. British Thoracic Society Bronchoscopy Guidelines Committee, a Subcommittee of Standards of Care Committee of British Thoracic Society. British Thoracic Society guidelines on diagnostic flexible bronchoscopy. *Thorax* 2001;56(Suppl 1):i1–21.
  72. Ernst A, Silvestri GA, Johnstone D; American College of Chest Physicians. Interventional pulmonary procedures: Guidelines from the American College of Chest Physicians. *Chest* 2003;123:1693–717.
  73. Smith JE, Jackson AP, Hurdley J, Clifton PJ. Learning curves for fiberoptic nasotracheal intubation when using the endoscopic video camera. *Anaesthesia* 1997;52:101–6.
  74. Ovassapian A, Yelich SJ, Dykes MH, Golman ME. Learning fiberoptic intubation: use of simulators v. traditional teaching. *Br J Anaesth* 1988;61:217–20.
  75. Morris IR. Fiberoptic intubation. *Can J Anaesth* 1994;41:996–1007; discussion -8.
  76. Heidegger T, Gerig HJ, Ulrich B, Schnider TW. Structure and process quality illustrated by fiberoptic intubation: analysis of 1612 cases. *Anaesthesia* 2003;58:734–9.
  77. Slinger P. Acquisition of competence in lung isolation: simulate one, do one, teach...repeat PRN. *J Cardiothorac Vasc Anesth* 2014;28:873–6.
  78. Bolliger CT, Mathur PN, Beamis JF, Becker HD, Cavaliere S, Colt H, *et al.*; European Respiratory Society/American Thoracic Society. ERS/ATS statement on interventional pulmonology. *Eur Respir J* 2002;19:356–73.
  79. Fielding D, Phillips M, Robinson P, Irving L, Garske L, Hopkins P; Thoracic Society of Australia and New Zealand. Advanced interventional pulmonology procedures: training guidelines from the Thoracic Society of Australia and New Zealand. *Respirology* 2012;17:1176–89.
  80. 2018 ABOTSBI. 2018.
  81. Wang Memoli JS, Nietert PJ, Silvestri GA. Meta-analysis of guided bronchoscopy for the evaluation of the pulmonary nodule. *Chest* 2012;142:385–93.
  82. Rivera MP, Mehta AC, Wahidi MM. Establishing the diagnosis of lung cancer: Diagnosis and management of lung cancer, 3rd ed: American College of Chest Physicians evidence-based clinical practice guidelines. *Chest* 2013;143(Suppl):e142S–65S.
  83. Gex G, Pralong JA, Combescure C, Seijo L, Rochat T, Soccal PM. Diagnostic yield and safety of electromagnetic navigation bronchoscopy for lung nodules: a systematic review and meta-analysis. *Respiration* 2014;87:165–76.
  84. Vilman P, Clementsen PF, Colella S, Siemsen M, De Leyn P, Dumoureaux JM, *et al.* Combined endobronchial and esophageal endosonography for the diagnosis and staging of lung cancer; European Society of Gastrointestinal Endoscopy (ESGE) Guideline, in cooperation with the European Respiratory Society (ERS) and the European Society of Thoracic Surgeons (ESTS). *Endoscopy* 2015;47:c1.
  85. Ost DE, Ernst A, Lei X, Kovitz KL, Benzaquen S, Diaz-Mendoza J, *et al.*; AQuIRE Bronchoscopy Registry. Diagnostic Yield and Complications of Bronchoscopy for Peripheral Lung Lesions. Results of the AQuIRE Registry. *Am J Respir Crit Care Med* 2016;193:68–77.
  86. Belanger AR, Akulian JA. An update on the role of advanced diagnostic bronchoscopy in the evaluation and staging of lung cancer. *Ther Adv Respir Dis* 2017;11:211–21.
  87. Cardillo G, Carbone L, Carleo F, Batzella S, Jacono RD, Lucantoni G, *et al.* Tracheal lacerations after endotracheal intubation: a proposed morphological classification to guide non-surgical treatment. *Eur J Cardiothorac Surg* 2010;37:581–7.
  88. Agostini P, Cieslik H, Rathinam S, Bishay E, Kalkat MS, Rajesh PB, *et al.* Postoperative pulmonary complications following thoracic surgery: are there any modifiable risk factors? *Thorax* 2010;65:815–8.
  89. Cardillo G, Carbone L, Carleo F, Galluccio G, Di Martino M, Giunti R, *et al.* The Rationale for Treatment of Postresectional Bronchopleural Fistula: analysis of 52 Patients. *Ann Thorac Surg* 2015;100:251–7.
  90. Fuso L, Varone F, Nachira D, Leli I, Salimbene I, Congedo MT, *et al.* Incidence and Management of Post-Lobectomy and Pneumonectomy Bronchopleural Fistula. *Hai* 2016;194:299–305.
  91. Cypel M, Yasufuku K. Complications during minimal invasive thoracic surgery: are new surgeons prepared? *Lancet Oncol* 2018;19:17–9.
  92. D'Andrilli A, Venuta F, Maurizi G, Rendina EA. Bronchial and arterial sleeve resection after induction therapy for lung cancer. *Thorac Surg Clin* 2014;24:411–21.
  93. Emmanouilides C, Tryfon S, Baka S, Titopoulos H, Dager A, Filipou D. Operation for preservation of lung parenchyma in central lung cancer—in vivo and ex situ reimplantation techniques. *Anticancer Res* 2015;35:1675–81.
  94. Weill D, Benden C, Corris PA, Dark JH, Davis RD, Keshavjee S, *et al.* A consensus document for the selection of lung transplant candidates: 2014—an update from the Pulmonary Transplantation Council of the International Society for Heart and Lung Transplantation. *J Heart Lung Transplant* 2015;34:1–15.
  95. Orens JB, Estenne M, Arcasoy S, Conte JV, Corris P, Egan JJ, *et al.*; Pulmonary Scientific Council of the International Society for Heart and Lung Transplantation. International guidelines for the selection of lung transplant candidates: 2006 update—a consensus report from the Pulmonary Scientific Council of the International Society for Heart and Lung Transplantation. *J Heart Lung Transplant* 2006;25:745–55.
  96. Chakinala MM, Ritter J, Gage BF, Aloush AA, Hachem RH, Lynch JP, *et al.* Reliability for grading acute rejection and airway inflammation after lung transplantation. *J Heart Lung Transplant* 2005;24:652–7.
  97. Lehto JT, Koskinen PK, Anttila VJ, Lautenschlager I, Lemström K, Sipponen J, *et al.* Bronchoscopy in the diagnosis and surveillance of respiratory infections in lung and heart-lung transplant recipients. *Transpl Int* 2005;18:562–71.
  98. Luecke K, Trujillo C, Ford J, Decker S, Pelaez A, Hazelton TR, *et al.* Anastomotic Airway Complications After Lung Transplant: Clinical, Bronchoscopic and CT Correlation. *J Thorac Imaging* 2016;31:W62–71.
  99. Mahmood K, Ebner L, He M, Robertson SH, Wang Z, McAdams HP, *et al.* Novel Magnetic Resonance Imaging for Assessment of Bronchial Stenosis in Lung Transplant Recipients. *Am J Transplant* 2017;17:1895–904.
  100. Mohanka MR, Mehta AC, Budev MM, Machuzak MS, Gildea TR. Impact of bedside bronchoscopy in critically ill lung transplant recipients. *J Bronchology Interv Pulmonol* 2014;21:199–207.
  101. Rademacher J, Suhling H, Greer M, Haverich A, Welte T, Warnecke G, *et al.* Safety and efficacy of outpatient bronchoscopy in lung transplant recipients - a single centre analysis of 3,197 procedures. *Transplant Res* 2014;3:11.
  102. Glanville AR. Bronchoscopic monitoring after lung transplantation. *Semin Respir Crit Care Med* 2010;31:208–21.
  103. McWilliams TJ, Williams TJ, Whitford HM, Snell GI. Surveillance bronchoscopy in lung transplant recipients: risk versus benefit. *J Heart Lung Transplant* 2008;27:1203–9.
  104. Sandrini A, Glanville AR. The controversial role of surveillance bronchoscopy after lung transplantation. *Curr Opin Organ Transplant* 2009;14:494–8.
  105. Valentine VG, Gupta MR, Weill D, Lombard GA, LaPlace SG, Seokane L, *et al.* Single-institution study evaluating the utility of surveillance bronchoscopy after lung transplantation. *J Heart Lung Transplant* 2009;28:14–20.
  106. Eyüboğlu FO, Küpeli E, Bozbaş SS, Ozen ZE, Akkurt ES, Aydoğan C, *et al.* Evaluation of pulmonary infections in solid organ transplant patients: 12 years of experience. *Transplant Proc* 2013;45:3458–61.
  107. Arcasoy SM, Berry G, Marboe CC, Tazelaar HD, Zamora MR, Wolters HJ, *et al.* Pathologic interpretation of transbronchial biopsy

for acute rejection of lung allograft is highly variable. *Am J Transplant* 2011;11:320–8.

**108.** Greenland JR, Jones KD, Hays SR, Golden JA, Urisman A, Jewell NP, *et al.* Association of large-airway lymphocytic bronchitis with bronchiolitis obliterans syndrome. *Am J Respir Crit Care Med* 2013;187:417–23.

**109.** Hetzel J, Eberhardt R, Herth FJ, Petermann C, Reichle G, Freitag L, *et al.* Cryobiopsy increases the diagnostic yield of endobronchial biopsy: a multicentre trial. *Eur Respir J* 2012;39:685–90.

**110.** Yarmus L, Akulian J, Gilbert C, Illei P, Shah P, Merlo C, *et al.* Cryo-probe transbronchial lung biopsy in patients after lung transplantation: a pilot safety study. *Chest* 2013;143:621–6.

**111.** Fruchter O, Fridel L, Rosengarten D, Raviv Y, Rosanov V, Kramer MR. Transbronchial cryo-biopsy in lung transplantation patients: first report. *Respirology* 2013;18:669–73.

**112.** Bensted K, McKenzie J, Havryk A, Plit M, Ben-Menachem E. Lung Ultrasound After Transbronchial Biopsy for Pneumothorax Screening in Post-Lung Transplant Patients. *J Bronchology Interv Pulmonol* 2018;25:42–7.

**113.** Dutau H, Vandemoortele T, Laroumagne S, Gomez C, Boussaud V, Cavaillès A, *et al.* A new endoscopic standardized grading system for macroscopic central airway complications following lung transplantation: the MDS classification. *Eur J Cardiothorac Surg* 2014;45:e33–8.

**114.** Michaud GC, Channick CL, Marion CR, Tighe RM, Town JA, Luks AM, *et al.* ATS Core Curriculum 2015. Part I: Adult Pulmonary Medicine. *Ann Am Thorac Soc* 2015;12:1387–97.

**115.** Stewart S, Fishbein MC, Snell GI, Berry GJ, Boehler A, Burke MM, *et al.* Revision of the 1996 working formulation for the standardization of nomenclature in the diagnosis of lung rejection. *J Heart Lung Transplant* 2007;26:1229–42.

---

*Conflicts of interest.*—The authors certify that there is no conflict of interest with any financial organization regarding the material discussed in the manuscript. Article first published online: October 31, 2018. - Manuscript accepted: October 16, 2018. - Manuscript received: October 12, 2018.

PROOOF  
MINERVA MEDICA