


## Randomized Controlled Trial

# Comparison of the dento-skeletal effects produced by Leaf expander versus rapid maxillary expander in prepubertal patients: a two-center randomized controlled trial

Valeria Paoloni<sup>1</sup>, Veronica Giuntini<sup>2</sup>, Roberta Lione<sup>3,4</sup>, Michele Nieri<sup>5</sup>, Valeria Barone<sup>6</sup>, Matilde Marino Merlo<sup>7</sup>, Francesca Mazza<sup>8</sup>, Stefano Passaleva<sup>8</sup>, Paola Cozza<sup>4,9</sup> and Lorenzo Franchi<sup>10,11</sup> 

<sup>1</sup>Department of Systems Medicine, University of Rome, Tor Vergata, Italy <sup>2</sup>Department of Experimental and Clinical Medicine, The University of Florence, Italy <sup>3</sup>Department of Systems Medicine, University of Rome, Tor Vergata, Italy <sup>4</sup>UniCamillus - Saint Camillus International University of Health Sciences, Rome, Italy <sup>5</sup>Department of Experimental and Clinical Medicine, The University of Florence, Italy <sup>6</sup>Private Practice, Florence, Italy <sup>7</sup>Postgraduate Program in Orthodontics, The University of Florence, Florence, Italy <sup>8</sup>SOC Odontostomatologia, AUSL Toscana centro, Florence, Italy <sup>9</sup>Department of Systems Medicine, University of Rome, Tor Vergata, Italy <sup>10</sup>Department of Experimental and Clinical Medicine, The University of Florence, Florence, Italy <sup>11</sup>Thomas M. Graber Visiting Scholar, Department of Orthodontics and Pediatric Dentistry, School of Dentistry, The University of Michigan, Ann Arbor, MI, USA

Correspondence to: Lorenzo Franchi, Department of Experimental and Clinical Medicine, School of Dentistry, Università degli Studi di Firenze, Firenze, Italy. E-mail: [lorenzo.franchi@unifi.it](mailto:lorenzo.franchi@unifi.it)

## Summary

**Objective:** This study aimed to compare the skeletal and dentoalveolar effects produced by slow maxillary expansion (SME) with the Leaf expander versus the conventional rapid maxillary expansion (RME) on digital dental casts, lateral and postero-anterior cephalometric radiographs.

**Trial design:** This is a superiority, two-center, two arms parallel balanced randomization trial.

**Methods:** Patients in the mixed dentition were included with a transverse interarch discrepancy of at least 3 mm. An expansion screw using moderate continuous forces (Leaf group) was compared to a conventional RME screw (RME group). The primary response variable was the difference in maxillary intermolar width (U6-U6) measured at baseline (T0) and one-year follow-up (T1) on the digital dental casts. Other dento-skeletal variables were also measured on digital dental casts and cephalograms. Computer-generated block randomization was used with allocation concealed in sequentially numbered opaque sealed envelopes. The examiner was blinded on the type of expander used. Linear models were used for statistical analysis.

**Results:** Twenty-eight patients in the Leaf group and 28 patients in the RME group were randomized and included in the study. There were no dropouts. U6-U6 did not show a statistically significant difference between the two groups (−0.4 mm in favor of the RME group, 95% CI from −1.2 to 0.5,  $P = 0.365$ ). As for the other secondary variables no statistically significant differences were found between the two groups except maxillary intercanine width (U3-U3, −0.9 mm in favor of the RME group, 95%CI from −1.5 to −0.3,  $P = 0.005$ ) and maxillary skeletal width (Mx-Mx, −1.4 mm in favor of the RME group, 95%CI from −2.4 to −0.3,  $P = 0.013$ ).

**Conclusions:** No significant differences between the RME and Leaf groups were detected for any of the analyzed dento-skeletal variables except the T1-T0 differences in U3-U3 and Mx-Mx that were significantly greater in the RME group.

**Registration:** The study was registered in the ISRCTN register on 08/11/2016 with the number ISRCTN18263886.

**Funding:** No funding or conflict of interest to be declared.

## Introduction

Rapid maxillary expansion (RME) is a common clinical orthopedic procedure used to treat maxillary transverse deficiency by opening the midpalatal suture (1–4).

Maxillary constriction can be associated with several problems that include occlusal disharmony, aesthetics, and functional difficulties such as narrowing of the pharyngeal airway, increased nasal resistance, alterations in tongue posture, and mouth breathing (5). Therefore, early treatment of this malocclusion through palatal expansion is strongly recommended.

RME creates heavy forces at the sutural site over a short period of time and produces immediate midpalatal suture separation by disruption of the sutural connective tissue. Forces produced by this appliance have been reported in the range of 16–20 kg (6).

According to Cannavale *et al.*, (4) RME induces a long-term improvement of the upper intercanine and intermolar width with an anterior overall gain of 2.9 mm and a posterior overall gain of 4.4 mm.

Although RME is an effective procedure, some authors have focused on the unwanted consequences of these heavy forces on sutures, periodontal alveolar bone, and dental structures identified as adverse effects (2). Recently the interest towards slow maxillary expansion (SME) with moderate maxillary expansion forces, obtained for example by using the Leaf Expander (7–12), has increased.

The Leaf Expander is a nickel-titanium expander capable of a uniform, slow, continuous force. The main advantages of the use of this device are its easy activation and that no cooperation is required (no compliance issues). The Leaf Expander can produce a controlled predominant bodily movement of the teeth using light, predetermined, and constant forces (7). Another advantage of the Leaf expander versus conventional RME is the lower levels of pain during the first few days after the application of the expander (9, 10). However, the evidence is insufficient to determine a difference in the dento-skeletal effects between RME and SME and whether heavy or moderate forces deliver the best treatment for correction of posterior crossbites (3).

Moreover, to our knowledge, no randomized controlled trial (RCT) has analyzed the dentoskeletal effects of RME compared with SME using the Leaf Expander. Therefore, the objective of this two-center RCT was to compare the skeletal and dentoalveolar effects induced by the Leaf Expander versus the conventional RME on digital dental casts, and lateral and postero-anterior cephalometric radiographs.

The present RCT follows the guidelines of CONSORT 2010 (13).

## Materials and methods

### Trial design

This is a superiority, two-center, two arms parallel balanced randomization trial. This study was conducted in the Orthodontic Clinics of two University Hospitals. The coordinating center (center #1)

was the University of Florence while the other center (center #2) was the University of Rome Tor Vergata. The study was registered in the ISRCTN register on 08/11/2016 with the ISRCTN18263886 number.

### Participants

To be included in the study patients had to present with the following characteristics:

1. prepubertal phase of development (cervical stage [CS] 1 or 2 in cervical vertebral maturation) (14),
2. early or intermediate mixed dentition stage (15) with fully erupted upper and lower first permanent molars.
3. presence of the second upper deciduous molars available as an anchoring teeth. The second deciduous molar was considered available as anchoring tooth when the root had the same length as the clinical crown at the radiographic examination (16),
4. posterior transverse interarch discrepancy (PTID) (17) of at least 3 mm. PTID was calculated on dental casts with a caliper as the difference between the maxillary intermolar width (distance between the central fossae of right and left permanent first maxillary molars) and the mandibular intermolar width (distance between the tips of the distobuccal cusps of right and left permanent first mandibular molars).

Exclusion criteria were:

1. age older than 14 years,
2. pubertal or postpubertal stage of development (CS 3–6),
3. late deciduous or late mixed dentition,
4. agenesis of upper second premolars (assessed on initial panoramic radiograph),
5. Class III malocclusion,
6. cleft lip and/or palate and craniofacial syndromes,
7. patients unable to be followed for at least 1 year.

All patients' parents signed informed consent before starting the trial.

The study was approved by the Pediatric Ethics Committee of the Tuscany Region (No. 57/2016 of 28/04/2016) and by the Independent Ethics Committee of the University of Rome Tor Vergata (No. 6/16 of 15/01/2016).

### Interventions

All patients received a butterfly palatal expander (18). This appliance has a butterfly-shaped stainless steel framework banded and cemented on maxillary second primary molars that extend forward to the palatal surfaces of first maxillary deciduous molars.

The Leaf Group received an expansion screw that delivers continuous moderate forces (Leaf Expander - Leone SpA, Sesto Fiorentino, Firenze, Italy) (Figure 1). The RME group was treated with a conventional RME screw that generates intermittent heavy forces (expansion screw with telescopic guides A2620 - Leone SpA, Sesto Fiorentino, Firenze, Italy) (Figure 2). In both groups, 10-mm

screws were used. If the 10-mm screw was not sufficient to correct the transverse interarch discrepancy, a second expansion phase was planned after the completion of the study.

As for the Leaf Expander, the Ni-Ti screws developed 900 g of force. An initial expansion of 4.5 mm was achieved in about 2–3 months. Patients were checked every 2 weeks to monitor the deactivation of the spring. The clinicians activated monthly this screw by 15-quarter turns with one-quarter turn corresponding to 0.1 mm of activation (15 activations of the screw generated 1.5 mm of activation). Three clinicians treated the patients in center #1 while two clinicians treated the patients in center #2. The clinical experience was similar for all clinicians (5–10 years).

The RME screw was activated by the patients' parents at 1/4 of a turn per day (one activation, 0.2 mm per turn). Activation of the screw commenced immediately after the appliance was cemented in place. Also in this group patients were checked every 2 weeks during which approximately 3 mm of expansion was obtained.

In both groups, the expansion screw was activated until the desired palatal expansion was reached (palatal cusps of the upper second deciduous molars approximating the buccal cusps of the lower second deciduous molars).

Both expanders were kept on teeth as a passive retainer and removed after one year from their application.

## Outcomes

The primary outcome of the study was the difference in maxillary intermolar width (U6-U6) measured at baseline (T0) and one-year follow-up (T1) on the digital dental casts.

Secondary outcomes were the T1-T0 differences in the variables measured on digital dental casts and postero-anterior and lateral cephalograms.

For each patient dental casts, lateral and postero-anterior cephalograms were taken at baseline (T0) and after the retention period (T1, 1 year after the expander bonding).

Maxillary and mandibular dental casts of all subjects were scanned using the extraoral scanner OrthoXscan (OrthoXscan; Dentaform GmbH and co, Ispringen, Germany) and Ortho Insight 3D (Motion View Software, Hixson, TN, USA). All models were then exported in a Standard Tessellation Language format (STL digital file) and they were digitized using Viewbox 4 software (dHAL software, Kifissia, Greece).

The following transverse linear values were recorded (17):

1. maxillary intermolar width (U6-U6): distance between the central fossae of right and left maxillary first permanent molars,
2. maxillary intercanine width (U3-U3): distance between the tips of the cusps of right and left maxillary deciduous canines,
3. mandibular intermolar width (L6-L6): distance between the tips of the distobuccal cusps of right and left mandibular first permanent molars,
4. mandibular intercanine width (L3-L3): distance between the tips of the cusps of right and left mandibular deciduous canines,
5. Posterior Transverse Interarch Discrepancy (PTID): the difference between maxillary and mandibular intermolar widths.

Upper (U6) and lower (L6) first permanent molar bucco-lingual inclinations (BLIs) were measured (Figure 3). To evaluate the tooth inclination, a best fit occlusal plane was set passing through the vestibular cusp tips of first permanent molars, first and second deciduous molars, deciduous canines, and the incisal margins of lateral and central incisors. This plane was used as a reference for generating one additional reference plane: i.e. the para-coronal plane. The upper arch was divided into four sectors: from the left first permanent molar to the left first deciduous molar; from the left first deciduous molar to the left lateral incisor; from the right lateral incisor to the right first deciduous molar; from the right first deciduous molar to the right first permanent molar. For each sector, the para-coronal plane was obtained perpendicular to the occlusal plane. For every analyzed tooth a curve passing through the long axis was drawn and

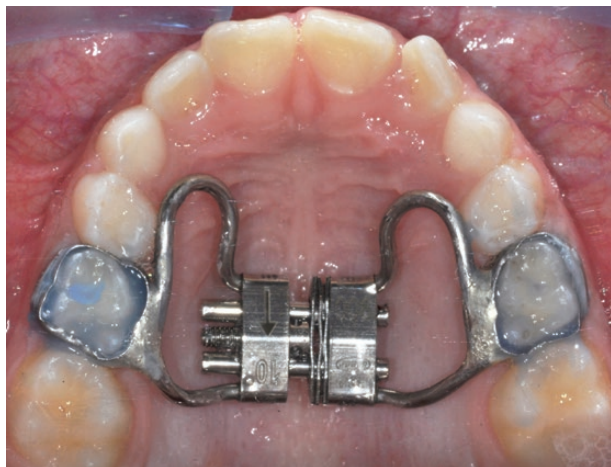


Figure 1. Leaf expander.

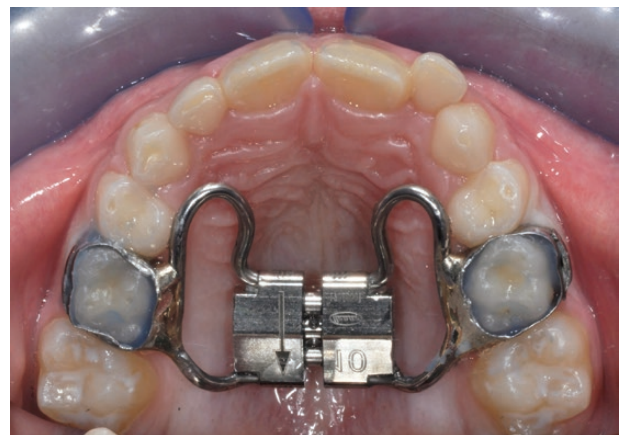


Figure 2. Conventional rapid maxillary expander.

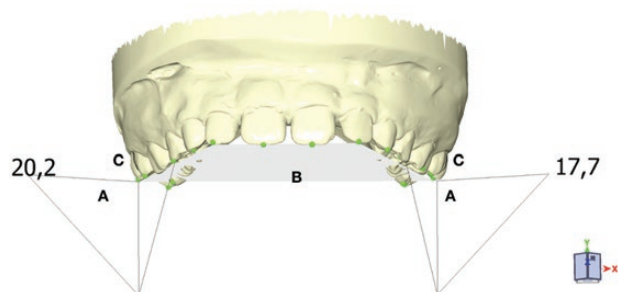


Figure 3. For both left and right sector, a para-coronal plane (A) was obtained perpendicularly to the occlusal plane (B). A curve passing through the first permanent molar long axis was drawn and a best fit line was set using the most occlusal and the most gingival points of the curve as reference (C). Tooth inclination was obtained by the angle formed between the best fit line of each tooth and the para-coronal plane.

the best fit line was set using the most occlusal and the most gingival points of the curve as reference. Tooth inclination was obtained by the angle formed between the best fit line of each tooth and the para-coronal plane. The following measurements were performed:

1. U6 BLI (mean value for BLI between right and left U6),
2. L6 BLI (mean value for BLI between right and left L6).

On the postero-anterior cephalometric radiographs the following bilateral cephalometric landmarks were used:

1. maxillary skeletal landmarks (Mx): the point located at the depth of the concavity of the lateral maxillary contour, at the junction of the maxilla and the zygomatic buttress,
2. maxillary molar dental landmarks (Um): the most prominent lateral point on the buccal surface of the maxillary first permanent molar,
3. mandibular molar dental landmark (Lm): the most prominent lateral point on the buccal surface of the mandibular first permanent molar.

From the digitized PA cephalograms, three width measurements were derived for each patient by connecting the corresponding bilateral cephalometric landmarks (19): maxillary skeletal width (Mx-Mx), maxillary intermolar width (Um-Um), and mandibular intermolar width (Lm-Lm).

On the lateral cephalograms the following measurements were assessed:

1. SNA angle: maxillary sagittal position,
2. SNB angle: mandibular sagittal position,
3. ANB angle: maxillomandibular sagittal discrepancy,
4. SN to Mandibular Plane (Go-Me): mandibular inclination relative to the cranial base,
5. Palatal Plane (ANS-PNS) to Mandibular Plane (Go-Me): maxillomandibular vertical relationship.

Patient-reported outcome measures were analyzed in a previous study (10).

### Sample size

In this study sample size was determined considering pain as a primary outcome variable (10). To highlight a difference between the two treatment modalities of 1.5 points on the VAS pain scale, considering a standard deviation of 1.87 (20), a two-tailed significance level of 5%, and a power of 80%, a sample size of 56 patients (28 per treatment) was required, taking into account a 10% withdrawal rate from the study. Twenty-eight patients (14 per treatment) were enrolled in each center. This sample size was adequate also for the other primary outcome variable (difference in maxillary intermolar width) considering a difference between the two treatment modalities of 1.5 mm, a standard deviation of 1.4 mm (21), a two-tailed significance level of 5%, and a power of 80%.

### Randomization and allocation concealment

A computer-generated random number list was used to allocate patients to treatments. Block randomization was used to assign the same number of patients to each treatment in the two centers.

The allocation sequence was concealed by the statistician (M.N.), who used opaque and sealed envelopes, sequentially numbered for each of the two centers. The envelopes were opened by the operators only when the expander was prepared for cementation.

### Blinding

The clinicians couldn't be blinded about the treatment that they were providing. The patients and parents did not know whether

the expander used was the Leaf or conventional RME expander. However, they could not be blinded, because they could observe the expander that required different activation.

The examiner (V.P.) was blinded on the type of expander used.

### Statistical methods

The intra-rater agreement was calculated on 20 repeated measures (after a 2-week washout period) with Intraclass Correlation Coefficients (ICCs). ICC was also used to calculate the repeatability between PTID measured on casts with a caliper and digital dental casts.

Descriptive statistics were performed using means and standard deviations for quantitative variables and frequency and percentage for qualitative variables.

Linear models were used considering the center as a fixed effect. The primary outcome variable was the difference in U6-U6. Explanatory variables were the treatment (Leaf vs RME expander) and the covariate (U6-U6 at baseline). The interaction between the treatment and the center was considered in the models only if statistically significant.

Similar models were also performed for the secondary outcome variables (T1-T0 differences in the variables measured on digital dental casts and the postero-anterior and lateral cephalograms).

For each statistical model the estimate of the treatment effect (the estimate of the difference between the two treatments used), the *P*-value, and the 95% confidence interval were provided.

Statistical analysis was carried out according to the modified intention-to-treat method (drop-outs were not included in the analysis). The unit of analysis was represented by the patient. All statistical computations were performed with statistical software (JMP vers. 13.0.0, SAS Institute Inc, Cary, NC, USA and MedCalc version 19.6.4, MedCalc Software Ltd., Ostend, Belgium).

### Results

The intra-rater reproducibility was excellent for all variables (range from 0.94 to 0.99). The repeatability between the PTID measured on casts with a caliper and digital dental casts was good (22) (ICC = 0.63).

Fifty-six patients were enrolled in the trial and randomly allocated to maxillary expansion with the two types of screw. Twenty-eight patients were allocated to the Leaf expander (Leaf Group) and 28 patients were allocated to the conventional RME expander (RME Group). Twenty-eight patients, 14 per group, were treated in center #1 and 28 patients, 14 per group, were treated in center #2 (Figure 4).

The patients were recruited and treated in the two University Hospitals from October 2016 to November 2018. The last 12-month follow-up was carried out in November 2019.

The demographic characteristics of patients at the beginning of therapy are shown in Table 1. No differences between the two groups were observed for any of the variables at baseline.

All patients received the treatment assigned by randomization. There were no withdrawals from the trial and no deviations from the protocol (Figure 4). Two patients of the Leaf Group refused to repeat the cephalograms at T1. Therefore, for the Leaf Group, 26 postero-anterior and lateral cephalograms were analyzed.

Duration of active therapy was  $4.5 \pm 1.1$  months in the Leaf group and it was  $1.0 \pm 0.4$  months in the RME group (difference 3.5 months,  $P < 0.0001$ ).

In Table 2 descriptive statistics and statistical comparisons for T1-T0 differences are illustrated.

The primary outcome variable (U6-U6) did not show a statistically significant difference between the two groups ( $-0.4$  mm in favor of the RME group, 95%CI from  $-1.2$  to  $0.5$ ,  $P = 0.365$ ).

As for the other secondary variables no statistically significant differences were found between the two groups except for U3-U3 ( $-0.9$  mm in favor of the RME group, 95%CI from  $-1.5$  to  $-0.3$ ,  $P = 0.005$ ) and Mx-Mx ( $-1.4$  mm in favor of the RME group, 95%CI from  $-2.4$  to  $-0.3$ ,  $P = 0.013$ ). Nevertheless, in both these comparisons, there were significant interactions between the device and the center ( $P = 0.015$  for U3-U3 and  $P = 0.019$  for Mx-Mx). In particular, the differences were significant only in center #2 favoring

the RME group for both variables ( $-1.7$  mm for U3-U3 and  $-2.6$  mm for Mx-Mx). In center #1 the differences between the two groups for both variables were not significant ( $-0.1$  mm for both U3-U3 and Mx-Mx). No other interaction was statistically significant for any of the analyzed variables.

## Discussion

The objective of this two-center RCT was to compare the skeletal and dentoalveolar effects produced by the Leaf Expander versus the conventional RME evaluated on digital dental casts, lateral and postero-anterior cephalograms. It should be emphasized that this is the first RCT that compared the dento-skeletal effects induced by the Leaf Expander versus the conventional RME. In this study, deciduous teeth were used as anchoring teeth. The literature has reported potential periodontal and endodontic damage of RME on anchoring teeth (2); therefore, some authors (23) have suggested using primary teeth as anchoring teeth.

No statistically significant difference between the two groups was found for the primary outcome variable T1-T0 difference in maxillary intermolar width (U6-U6). Similarly, no statistically significant differences were found between the two groups for all the other variables except for the T1-T0 differences in U3-U3 and Mx-Mx that were significantly greater in the RME group ( $-0.9$  mm and  $-1.4$  mm, respectively). These results are partially in disagreement with those reported by Lanteri *et al.* (8) who found no statistically significant differences for any of the dento-skeletal transverse variables measured on postero-anterior cephalograms when comparing Leaf Expander and the conventional RME. The differences in results between the current study and that by Lanteri *et al.* (8) could be because the Lanteri *et al.* study was retrospective and included only a very limited number of patients (10 per group). The results of the present study disagree also with a retrospective study performed on digital dental casts by Cossellu *et al.* (12) who found that the T1-T0

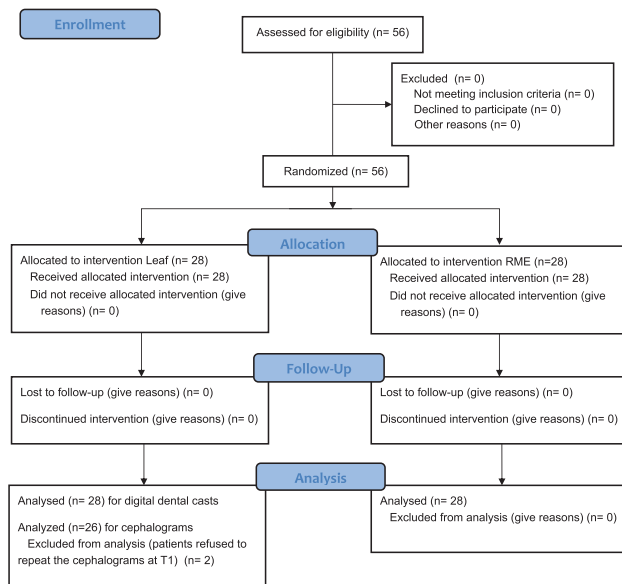


Figure 4. CONSORT flow diagram.

Table 1. Patient demographics at baseline. In round brackets the percentage for qualitative variables and the standard deviation for quantitative variables; in square brackets minimum and maximum.

Variable	Leaf Group N = 28	RME Group N = 28
Center (#1)	14 (50%)	14 (50%)
Center (#2)	14 (50%)	14 (50%)
Gender, female	17 (61%)	12 (43%)
Gender, male	11 (39%)	16 (57%)
Age, years [min; max]	8.0 (1.3) [5.7; 11.0]	8.4 (1.0) [5.9; 10.4]
Posterior Transverse Interarch Discrepancy, mm*	$-5.0$ (1.8) [ $-3.0$ ; $-10$ ]	$-4.3$ (1.1) [ $-3.0$ ; $-7.5$ ]
Maxillary intermolar width (U6-U6), mm	41.7 (2.0)	41.7 (2.3)
Maxillary intercanine width (U3-U3), mm	29.4 (1.9)	30.0 (2.3)
Mandibular intermolar width (L6-L6), mm	46.0 (2.3)	45.4 (2.6)
Mandibular intercanine width (L3-L3), mm	25.5 (2.0)	25.5 (1.9)
Posterior Transverse Interarch Discrepancy, mm**	$-4.2$ (1.2)	$-3.7$ (1.1)
U6 bucco-lingual inclination (BLI), degrees	18.9 (6.8)	15.6 (6.2)
L6 bucco-lingual inclination (BLI), degrees	46.0 (8.1)	46.2 (7.7)
Maxillary skeletal width (Mx-Mx), mm	50.8 (4.2)	51.0 (5.4)
Maxillary intermolar width (Um-Um), mm	49.1 (4.5)	49.1 (4.8)
Mandibular intermolar width (Lm-Lm), mm	50.4 (4.2)	50.2 (4.5)
SNA, degrees	79.8 (3.2)	79.4 (2.4)
SNB, degrees	75.6 (2.8)	75.6 (3.0)
ANB, degrees	4.2 (1.6)	3.7 (2.0)
SN-Mandibular Plane (Go-Me), degrees	34.2 (5.3)	36.3 (5.0)
Palatal Plane-Mandibular Plane, degrees	26.2 (4.7)	26.8 (4.6)

\*Calculated on dental casts with a caliper.

\*\*Calculated on digital dental casts.

**Table 2.** Statistical comparisons between Leaf Group and RME Group for T1-T0 differences

Variable	Leaf Group N = 28	RME Group N = 28	Difference	95% Confidence Interval	P value
Maxillary intermolar width (U6-U6), mm	4.1 (1.7)	4.5 (1.4)	-0.4	-1.2; 0.5	0.365
Maxillary intercanine width (U3-U3), mm	2.2 (1.4)	3.0 (1.3)	-0.9	-1.5; -0.3	0.005*
Mandibular intermolar width (L6-L6), mm	0.5 (1.2)	0.5 (1.1)	0.1	-0.3; 0.6	0.577
Mandibular intercanine width (L3-L3), mm	0.7 (1.0)	0.3 (1.0)	0.4	-0.0; 0.9	0.070
Posterior Transverse Interarch Discrepancy, mm	3.6 (1.7)	4.0 (1.4)	-0.7	-1.4; 0.1	0.084
U6 bucco-lingual inclination (BLI), degrees	-7.1 (5.8)	-3.5 (3.8)	-1.8	-3.9; 0.2	0.077
L6 bucco-lingual inclination (BLI), degrees	-4.5 (5.9)	-3.5 (4.9)	-1.1	-3.4; 1.2	0.338
Maxillary skeletal width (Mx-Mx), mm	2.3 (1.6)†	3.7 (2.4)	-1.4	-2.4; -0.3	0.013*
Maxillary intermolar width (Um-Um), mm	3.3 (1.9)†	3.2 (1.6)	0.1	-0.8; 1.0	0.889
Mandibular intermolar width (Lm-Lm), mm	0.7 (1.0)†	0.8 (0.9)	-0.1	-0.6; 0.5	0.827
SNA, degrees	0.2 (0.3)†	0.1 (0.4)	0.1	-0.1; 0.3	0.498
SNB, degrees	0.8 (0.5)†	0.8 (0.7)	0.1	-0.2; 0.4	0.580
ANB, degrees	-0.7 (0.6)†	-0.6 (0.8)	0.1	-0.3; 0.4	0.749
SN-Mandibular Plane (Go-Me), degrees	0.9 (1.7)†	0.6 (1.6)	0.1	-0.8; 1.0	0.807
Palatal Plane-Mandibular Plane, degrees	0.4 (1.5)†	0.5 (1.3)	-0.2	-1.0; 0.6	0.651

†N = 26; \*Significant interaction.

difference in deciduous intercanine width (53–63) was significantly greater in the Leaf group while the T1-T0 difference in maxillary intermolar width was significantly greater in the RME group. The differences in results could be attributed to the different appliance design of the Leaf and RME expanders. In the study by Cossellu *et al.* (12), in fact, the Leaf expander extended to the lingual aspects of the maxillary deciduous canines while the RME expander presented wire extensions lingually to the maxillary deciduous canines and the maxillary permanent first molars. In the present study, the Butterfly design of the expander presented with no wire extension to the lingual surfaces of either the maxillary deciduous canines or the maxillary permanent first molars.

The other only RCTs (9, 10) that compared the Leaf expander versus the conventional RME analyzed only patient-reported outcome measures like pain, difficulty in speaking, difficulty in keeping the expander clean, difficulty in swallowing, and hypersalivation. Both RCTs showed that conventional RME produced higher levels of pain during the first few days after the application of the expander.

Similar to the results of the current study, two systematic reviews (11, 24) found no statistically significant difference in maxillary intermolar width between RME and SME. It should be pointed out, however, that in both reviews SME was performed with appliances different from the Leaf expander. As for the maxillary skeletal expansion, the results of this study confirmed those by Rutili *et al.* (11) who showed that RME induced a significantly greater posterior skeletal expansion than SME. It should be noted that in the systematic review by Rutili *et al.* (11) SME was obtained using the same screw expander as for the RME, with different activation protocols. Additionally, in the systematic review by Rutili *et al.* (11) the posterior skeletal expansion was measured on CBCTs while in the present study it was recorded on postero-anterior cephalograms.

In the present study for the variables U3-U3 and Mx-Mx a significant interaction between center and treatment was detected. In particular, for these variables, the differences between the RME group and Leaf groups were large and statistically significant in favor of RME in center #2 while they were small and insignificant in center #1. The differences between the two centers for these variables are difficult to explain. The number of clinicians and their level of experience was similar in the two centers. Most probably these differences can be ascribed to differences among patients in the two centers that could not be identified.

A limitation of this study was the presence of several operators, which could have determined the high heterogeneity between the centers. On the other hand, however, this fact increases the possibility of extrapolating the results to the normal clinical routine. Another limitation is the lack of a follow-up observation after the retention phase. However, we plan to collect follow-up data at least 1 year after the removal of the expander. Finally, in this study, we did not perform an occlusal radiograph to assess the opening of the midpalatal suture. It is hoped that this aspect will be explored in future studies analyzing the effects produced by SME with the Leaf expander in growing patients.

## Conclusions

No significant differences between the RME and Leaf groups were found for any of the analyzed dento-skeletal variables with the exception of the T1-T0 differences in U3-U3 and Mx-Mx that were significantly greater in the RME group. These differences, however, were smaller than 1.5 mm and probably not clinically relevant. Therefore, the choice between the two expansion modalities is left to the clinician's preference.

## Conflict of interest

The Authors declare that they have no conflict of interest.

## Data availability

Data are available on request.

## Acknowledgements

The Authors would like to thank the Leone Company for having provided the expansion screws and the Laboratory Firenze Ortodonzia for having provided the expanders for the trial.

## References

- McNamara, J.A. (2000) Maxillary transverse deficiency. *American Journal of Orthodontics and Dentofacial Orthopedics*, 117, 567–570.

2. Lione, R., Franchi, L. and Cozza, P. (2013) Does rapid maxillary expansion induce adverse effects in growing subjects? *The Angle Orthodontist*, 83, 172–182.
3. Agostino, P., Ugolini, A., Signori, A., Silvestrini-Biavati, A., Harrison, J.E., and Riley, P. (2014) Orthodontic treatment for posterior crossbites. *Cochrane Database Systematic Reviews*, 8, Cd000979.
4. Cannavale, R., Chiodini, P., Perillo, L. and Piancino, M.G. (2018) Rapid palatal expansion (RPE): meta-analysis of long-term effects. *Orthodontics and Craniofacial Research*, 21, 225–235.
5. McNamara, J.A. Jr, Lione, R., Franchi, L., Angelieri, F., Cevidanes, L.H., Darendeliler, M.A. and Cozza, P. (2015) The role of rapid maxillary expansion in the promotion of oral and general health. *Progress in Orthodontics*, 16, 33.
6. Camporesi, M., Franchi, L., Doldo, T. and Defraia, E. (2013) Evaluation of mechanical properties of three different screws for rapid maxillary expansion. *Biomedical engineering online*, 12, 128.
7. Lanteri, C., Beretta, M., Lanteri, V., Gianolio, A., Cherchi, C. and Franchi, L. (2016) The Leaf expander for non-compliance treatment in the mixed dentition. *Journal of Clinical Orthodontics: JCO*, 50, 552–560.
8. Lanteri, V., Cossellu, G., Gianolio, A., Beretta, M., Lanteri, C., Cherchi, C. and Farronato, G. (2018) Comparison between RME, SME and Leaf Expander in growing patients: a retrospective postero-anterior cephalometric study. *European Journal of Paediatric Dentistry*, 19, 199–204.
9. Ugolini, A., Cossellu, G., Farronato, M., Silvestrini-Biavati, A. and Lanteri, V. (2020) A multicenter, prospective, randomized trial of pain and discomfort during maxillary expansion: Leaf expander versus hyrax expander. *International Journal of Paediatric Dentistry*, 30, 421–428.
10. Nieri, M., Paoloni, V., Lione, R., Barone, V., Marino Merlo, M., Giuntini, V., Cozza, P. and Franchi, L. (2020) Comparison between two screws for maxillary expansion: a multicenter randomized controlled trial on patient's reported outcome measures. *European Journal of Orthodontics*, in press.
11. Rutili, V., Mrakic, G., Nieri, M., Franceschi, D., Pierleoni, F., Giuntini, V. and Franchi, L. Dento-skeletal effects produced by rapid versus slow maxillary expansion using fixed jackscrew expanders: a systematic review and meta-analysis. *European Journal of Orthodontics*, in press.
12. Cossellu, G., Ugolini, A., Beretta, M., Farronato, M., Gianolio, A., Maspero, C. and Lanteri, V. (2020) Three-dimensional evaluation of slow maxillary expansion with leaf expander vs. rapid maxillary expansion in a sample of growing patients: direct effects on maxillary arch and spontaneous mandibular response. *Applied Sciences (Switzerland)*, 10, 13.
13. Moher, D., Hopewell, S., Schulz, K.F., Montori, V., Gøtzsche, P.C., Devereaux, P.J., Elbourne, D., Egger, M. and Altman, D.G.; Consolidated Standards of Reporting Trials Group. (2010) CONSORT 2010 explanation and elaboration: updated guidelines for reporting parallel group randomised trials. *Journal of Clinical Epidemiology*, 63, e1–37.
14. McNamara, J.A. Jr and Franchi, L. (2018) The cervical vertebral maturation method: a user's guide. *The Angle Orthodontist*, 88, 133–143.
15. Franchi, L., Baccetti, T., De Toffol, L., Polimeni, A. and Cozza, P. (2008) Phases of the dentition for the assessment of skeletal maturity: a diagnostic performance study. *American Journal of Orthodontics and Dentofacial Orthopedics*, 133, 395–400.
16. Ugolini, A., Cerruto, C., Di Vece, L., Ghislanzoni, L.H., Sforza, C., Doldo, T., Silvestrini-Biavati, A. and Caprioglio, A. (2015) Dental arch response to Haas-type rapid maxillary expansion anchored to deciduous vs permanent molars: a multicentric randomized controlled trial. *The Angle Orthodontist*, 85, 570–576.
17. Tollaro, I., Baccetti, T., Franchi, L. and Tanasescu, C.D. (1996) Role of posterior transverse interarch discrepancy in Class II, Division 1 malocclusion during the mixed dentition phase. *American Journal of Orthodontics and Dentofacial Orthopedics*, 110, 417–422.
18. Cozza, P., Giancotti, A. and Petrosino, A. (1999) Butterfly expander for use in the mixed dentition. *Journal of Clinical Orthodontics: JCO*, 33, 583–7.
19. Cameron, C.G., Franchi, L., Baccetti, T. and McNamara, J.A. Jr. (2002) Long-term effects of rapid maxillary expansion: a posteroanterior cephalometric evaluation. *American Journal of Orthodontics and Dentofacial Orthopedics*, 121, 129–135.
20. Baldini, A., Nota, A., Santariello, C., Assi, V., Ballanti, F. and Cozza, P. (2015) Influence of activation protocol on perceived pain during rapid maxillary expansion. *The Angle Orthodontist*, 85, 1015–1020.
21. Mutinelli, S., Manfredi, M., Guiducci, A., Denotti, G. and Cozzani, M. (2015) Anchorage onto deciduous teeth: effectiveness of early rapid maxillary expansion in increasing dental arch dimension and improving anterior crowding. *Progress in Orthodontics*, 16, 22.
22. Cicchetti, D.V. and Sparrow, S.A. (1981) Developing criteria for establishing interrater reliability of specific items: applications to assessment of adaptive behavior. *American Journal of Mental Deficiency*, 86, 127–137.
23. Cozzani, M., Rosa, M., Cozzani, P. and Siciliani, G. (2003) Deciduous dentition-anchored rapid maxillary expansion in crossbite and non-crossbite mixed dentition patients: reaction of the permanent first molar. *Progress in Orthodontics*, 4, 15–22.
24. Bucci, R., D'Antò, V., Rongo, R., Valletta, R., Martina, R. and Michelotti, A. (2016) Dental and skeletal effects of palatal expansion techniques: a systematic review of the current evidence from systematic reviews and meta-analyses. *Journal of Oral Rehabilitation*, 43, 543–564.