



UNIVERSITÀ  
DEGLI STUDI  
FIRENZE

## FLORE

# Repository istituzionale dell'Università degli Studi di Firenze

### **Acute appendicitis in a patient immunised with COVID-19 vaccine: a case report with morphological analysis**

Questa è la Versione finale referata (Post print/Accepted manuscript) della seguente pubblicazione:

*Original Citation:*

Acute appendicitis in a patient immunised with COVID-19 vaccine: a case report with morphological analysis / Marconi, Ettore; Crescioli, Giada; Bonaiuti, Roberto; Pugliese, Lavinia; Santi, Raffaella; Nesi, Gabriella; Cerbai, Elisabetta; Vannacci, Alfredo; Lombardi, Niccolò. - In: BRITISH JOURNAL OF CLINICAL PHARMACOLOGY. - ISSN 0306-5251. - ELETTRONICO. - (2023), pp. 1-1. [10.1111/bcp.15421]

*Availability:*

The webpage <https://hdl.handle.net/2158/1271254> of the repository was last updated on 2025-01-31T14:59:52Z

*Published version:*

DOI: 10.1111/bcp.15421

*Terms of use:*

Open Access

La pubblicazione è resa disponibile sotto le norme e i termini della licenza di deposito, secondo quanto stabilito dalla Policy per l'accesso aperto dell'Università degli Studi di Firenze (<https://www.sba.unifi.it/upload/policy-oa-2016-1.pdf>)

*Publisher copyright claim:*

Conformità alle politiche dell'editore / Compliance to publisher's policies

Questa versione della pubblicazione è conforme a quanto richiesto dalle politiche dell'editore in materia di copyright.

This version of the publication conforms to the publisher's copyright policies.

La data sopra indicata si riferisce all'ultimo aggiornamento della scheda del Repository FloRe - The above-mentioned date refers to the last update of the record in the Institutional Repository FloRe

(Article begins on next page)

Vannacci Alfredo (Orcid ID: 0000-0001-5259-2026)

Acute appendicitis in a patient immunised with COVID-19 vaccine: a case report with morphological analysis

Ettore Marconi<sup>1\*</sup>, Giada Crescioli<sup>2,3\*</sup>, Roberto Bonaiuti<sup>2</sup>, Lavinia Pugliese<sup>4</sup>, Raffaella Santi<sup>5</sup>, Gabriella Nesi<sup>5</sup>, Elisabetta Cerbai<sup>2</sup>, Alfredo Vannacci<sup>2,3\*</sup>, Niccolò Lombardi<sup>2,3\*</sup>

\* *Co-first and co-last authors*

#### Affiliations

1. Health Search, Italian College of General Practitioners and Primary Care, Florence, Italy.
2. Department of Neurosciences, Psychology, Drug Research and Child Health, Section of Pharmacology and Toxicology, University of Florence, Florence, Italy.
3. Tuscan Regional Centre of Pharmacovigilance, Florence, Italy.
4. Histopathology and Molecular Diagnostics, Careggi Teaching Hospital, Florence, Italy.
5. Pathology Section, Department of Health Sciences, University of Florence, Florence, Italy.

#### Corresponding Author

Prof. Alfredo Vannacci, MD, PhD

Department of Neurosciences, Psychology, Drug Research and Child Health

Section of Pharmacology and Toxicology

University of Florence

Viale G. Pieraccini 6 - 50139 - Florence, Italy

Phone number: +39 055 27 58 206

Email address: [alfredo.vannacci@unifi.it](mailto:alfredo.vannacci@unifi.it)

Running Title: Acute appendicitis and COVID-19 vaccine

Principal Investigator statement: The authors confirm that the principal investigator for this article is Niccolò Lombardi.

This article has been accepted for publication and undergone full peer review but has not been through the copyediting, typesetting, pagination and proofreading process which may lead to differences between this version and the Version of Record. Please cite this article as doi: 10.1002/bcp.15421

Keywords: Pharmacovigilance; COVID-19; Vaccine; Appendicitis; Case report; Histology.

Word count: 1573

Tables: 0

Figures: 1

What is already known about this subject?

- mRNA COVID-19 vaccines are recognised as extremely effective and safe.
- Post-marketing surveillance of adverse drug reactions is based more on spontaneous reporting and observational studies than on clinical trials.
- Serious adverse events have been suggested as signals in the post marketing surveillance of COVID-19 vaccines.
- Appendicitis is currently considered a serious adverse event of special interest.

What this study adds?

- COVID-19 vaccines induce strong Th1 immune responses.
- A relationship between an increased Th1-driven response and appendicitis has been suggested.
- As in our case, granulomatous inflammation is a common form of nonspecific chronic inflammation of the appendix.

Abstract

Although the benefit/risk profile for mRNA COVID-19 vaccines is recognised as extremely favourable, appendicitis is currently considered an adverse event (AE) of special interest. We describe the case of a 58-year-old female who presented with signs and symptoms of appendicitis approximately 48 hours after her first injection of the Pfizer-BioNTech vaccine. Abdominal ultrasound revealed fluid collection in the right iliac fossa and cecal wall thickening. Following the surgical visit, CT scan with contrast showed a distended appendix

with thickened walls, suggestive of acute appendicitis. The patient tested negative to upper respiratory COVID-19 reverse transcription-polymerase chain reaction.

Clinical trials and observational studies suggest a possible association between appendicitis and COVID-19 vaccines. Th-1 driven granulomatous inflammation reported in our case represents an infrequent nonspecific chronic inflammation of the appendix, especially in the setting of delayed or interval appendectomy. Following 2018 WHO criteria, the present case of appendicitis was considered as consistent to immunisation.

In view of the current paediatric vaccination campaign, we recommend monitoring the safety profile and potential gastrointestinal AEs associated with mRNA COVID-19 vaccines, to swiftly manage subjects with gastrointestinal symptoms and prevent potential complications.

## Introduction

More than two years into the COVID-19 pandemic, an unprecedented number of mass vaccination programs are underway in several countries. To date, over 10 billion doses have been administered worldwide.<sup>1</sup>

Approval studies have shown that both adenovirus-vectored and messenger RNA (mRNA) COVID-19 vaccines are efficacious and have a very good safety profile. No clinical trials have as yet reported any serious safety hazards, demonstrating a low incidence of serious adverse events (AEs), defined as any untoward medical occurrence which, at any dose, causes patient death, hospitalisation or its prolongation, or else persistent disability/incapacity. Nevertheless, serious AEs may not always emerge in phase 3 studies, due to the small sample size, restrictive inclusion criteria, limited duration of follow-up, and study participants at times differing from the general population.

Appendicitis is an acute gastrointestinal condition that is usually most frequent in younger people. Indeed, it commonly occurs between the ages of 10 and 30, with the highest incidence in children and adolescents.<sup>2</sup> Appendicitis is mentioned in the information fact sheet of the Pfizer-BioNTech vaccine approved by the FDA, after an increase in cases in the vaccine arm of a large clinical trial.<sup>3</sup> However, no causal relationship has been established, nor is it labelled for the other vaccines.<sup>4</sup> In view of the recent authorization for administering COVID-19 vaccines to the paediatric population, especially mRNA vaccines, more attention must be paid to avoid possible complications related to acute appendicitis in this subset.

## Case description

In mid-January 2021, a 58-year-old female academic healthcare professional presented to the emergency department (ED) of Careggi University Hospital (Florence, Italy) with pain in the right iliac fossa (RIF). She reported mild pain in the same site two weeks earlier, which had subsided with oral scopolamine and a bland diet. The patient referred to having fever, nausea and vomiting the day before ED admission and that her general practitioner prescribed a penicillin-based antibiotic (amoxicillin/clavulanate), with no improvement in symptoms. She denied diarrhoea, dyspnea and dysuria. Furthermore, the patient has never tested positive for COVID-19 in the past. The patient stated she had received the I dose of Pfizer-BioNTech vaccine approximately 48 hours prior to ED admission (January 16, 2021).

Her past medical history included left quadrantectomy with radiotherapy for breast cancer and, at the time of ED admission, she was on perindopril/amlodipine therapy for arterial hypertension. The patient confirmed she was a non-smoker, did not drink alcohol or use recreational drugs, nor was she allergic to any drugs.

At physical examination, the abdomen was flat and soft, but painful on deep palpation in RIF and hypogastrium. Blumberg, Murphy and Giordano signs were negative, and peristalsis was normal. ECG revealed normal heart rate, PR and ST-T intervals.

Laboratory tests showed normal haemoglobin levels (12.5 g/dL; range 12.0-16.0), significant leukocytosis ( $12.1 \times 10^9/L$ ; range 4.0-10.0), neutrophilia (78.4%; range 37.0-75.0), high fibrinogen levels (636.0 mg/dL; range 200.0-400.0) and increased prothrombin time (13.3 seconds; range 9.5-12.0). Amylase, lipase, urine analysis, liver and renal function tests were normal. The RT-PCR test for COVID-19, following hospital protocol, was negative.

An abdominal ultrasound scan was requested for suspected appendicitis, which revealed fluid collection in the RIF and thickening of the cecal wall. CT scan with contrast disclosed a distended appendix (maximum thickness 12 mm) with thickened walls, typical of acute appendicitis. The patient was transferred to an inpatient ward and a video-laparoscopic appendectomy was performed under full COVID-19 precautions.

On gross examination, the appendix was swollen, measuring 8 cm in length and 2.5 cm in maximum diameter. Histology showed diffuse acute and chronic inflammatory infiltrates with scattered non-necrotizing granulomas throughout all layers of the appendiceal wall (Figure 1). Of note, numerous granulomas were identified within the germinal centres of lymphoid follicles. The presence of serosal giant cells surrounded by florid granulation tissue was suggestive of prior appendiceal rupture. No foreign bodies, obstructing lesions or infective microorganisms were detected.

The postoperative course was uneventful. After 4 days of hospitalisation (1 in ED and 3 in the ward), the patient was discharged and prescribed oral amoxicillin/clavulanate, subcutaneous low-molecular-weight heparin and oral acetaminophen/codeine as needed.

#### Final diagnosis and outcome

Final diagnosis of the case was acute appendicitis. Applying the 2018 WHO algorithm to assess causal relationship between mRNA COVID-19 vaccine and acute appendicitis,<sup>5</sup> the suspected association was found to be indeterminate (B1 - Temporal relationship is consistent but there is insufficient definitive evidence that vaccine caused the event).

#### Follow-up

The patient was followed up at home by her general practitioner, with no clinical complications. Then, the patient was administered with the II (February 6, 2021) and III doses (October 27, 2021) of mRNA COVID-19 vaccine without the occurrence of any other AEs.

#### Discussion

Clinical trials have shown that most COVID-19 vaccines are efficacious, with a satisfactory safety profile.<sup>6</sup> Trials on the Pfizer-BioNTech vaccine have revealed a mild imbalance between vaccinated and placebo groups with respect to the number of cases of hypersensitivity reactions, acute myocardial infarction, cerebrovascular accidents and appendicitis.<sup>7</sup> It is unclear, however, whether the risk of appendicitis is higher in the vaccinated than in the general population. Evidence from literature is scarce with conflicting results, and global longitudinal studies are required to clarify any possible relationship.

Using data from the largest healthcare organisation in Israel, Barda N et al.<sup>7</sup> noted that such a risk was higher in vaccinated than non-vaccinated patients (risk ratio, 1.40; 95% CI, 1.02 to 2.01; risk difference, 5.0 events per 100,000 persons; 95% CI, 0.3 to 9.9). These authors also examined records from over 240,000 infected subjects to estimate the effects of documented SARS-CoV-2 infection on the incidence of the same AEs, and found that SARS-CoV-2 infection was not associated with any meaningful events, including appendicitis.

Li X et al.<sup>8</sup> performed a multinational network cohort study to quantify the background incidence rates of 15 pre-specified AEs that might need evaluation after COVID-19 vaccination. Based on electronic health records and health claims data from eight countries (Australia, France, Germany, Japan, the Netherlands, Spain, the United Kingdom, and the United States), they found that anaphylaxis, Bell's palsy, appendicitis and immune

thrombocytopenia were essentially rare in all age groups. Notwithstanding the considerable variability of AE rates within age and sex subgroups, appendicitis was more common in younger populations.

From a pharmacovigilance perspective, Mitchell J et al.<sup>4</sup> reviewed all cases of appendicitis following administration of COVID-19 vaccines reported to VigiBase (WHO). The authors observed an apparent increase of such cases within 4 days of vaccination and a possible dose-response relationship.

Globally, the incidence of appendicitis is approximately 11 cases per 10,000 life years,<sup>9</sup> with the highest incidence in late childhood and early adulthood. The occurrence of appendicitis is low in the neonatal period but most frequent between ages 12 and 18, where it is the leading cause of abdominal surgical emergency.

The exact pathophysiology of appendicitis, as well as any potential causal association with COVID-19 vaccines, is still unclear. Appendicoliths, lymphoid hyperplasia and lymphadenopathy have been identified as relevant causes of appendicitis.<sup>4</sup> Although lymphadenopathy is listed among AEs of COVID-19 vaccines, abdominal lymphadenopathies are greatly underreported since they are usually diagnosed only after abdominal imaging. Immune response could also contribute to the onset of appendicitis. COVID-19 status should also be considered, as a previous infection may enhance immune response to vaccination.<sup>10</sup> Interestingly, COVID-19 vaccines induce strong Th1 immune responses, and a possible relationship has been suggested between an increased Th1-driven response and appendicitis. In particular, Th1 responses and cytotoxic cells may provide the background for the development of gangrenous and perforated appendicitis, in contrast to the Th2 immune response observed in phlegmonous appendicitis.<sup>11</sup>

Granulomatous appendicitis is seen in less than 2% of appendectomy specimens. However, granulomatous inflammation represents a common form of nonspecific chronic inflammation of the appendix, especially in the setting of delayed or interval appendectomy, as in our case.<sup>12</sup> Pathologists should be aware of this inflammatory pattern, not to misinterpret findings as Crohn's disease, infectious disorders, sarcoidosis or foreign-body reactions without relevant clinical history.<sup>13</sup>

Recently, an observational study aimed to describe US surveillance data collected through the Vaccine Adverse Event Reporting System (VAERS) and v-safe during the first 6 months of the US COVID-19 vaccination program, found a total of 383 cases of appendicitis associated with mRNA vaccines, accounting for 1.3 reports per million doses administered. Based on available real-world data, appendicitis is currently considered an AE of special interest.<sup>14</sup>

At the end of March 2022, Kildegaard et al. in Denmark performed a nationwide cohort study to assess the risk of appendicitis after receiving an mRNA COVID-19 vaccine compared with the risk of appendicitis in unvaccinated individuals.<sup>15</sup> Although authors reported several limitations, they found no association between immunisation with mRNA-based COVID-19 vaccines and appendicitis, and they stated that further studies from different settings are needed to clarify this association.

While clinical trials on the efficacy and safety of COVID-19 vaccines have not yet involved the paediatric population, the European Medicines Agency has recommended extending the use of the Pfizer-BioNTech vaccine to children aged 5 to 11.<sup>16</sup> Since limited information is available on acute appendicitis following immunisation, especially in children, healthcare providers and national health services should be aware of the potential relationship between COVID-19 vaccines and acute appendicitis.

#### Conclusions

The present case highlights the risk of acute appendicitis as an event potentially associated with COVID-19 vaccines. Considering the ongoing COVID-19 vaccination campaign aimed at younger individuals, we recommend monitoring safety profiles and potential AEs especially in children, so that any gastrointestinal symptoms following immunisation can be rapidly diagnosed and managed.

#### Acknowledgements

The authors declare that this research was conducted in the absence of any commercial or financial relationship that could be construed as a potential conflict of interest. This research did not receive any specific grant from funding agencies in the public, commercial, or not-for-profit sectors.

#### Contributors

N.L. conceived the original idea; E.M., G.C., and N.L. wrote the manuscript; L.P., R.S., and G.N. performed the morphological analyses; R.B., E.C., and A.V. contributed to the analyses of the results and revised the manuscript for critical content; all authors revised and approved the manuscript.

#### Competing Interest

All authors have no conflicts of interest to disclose.

Availability of data

Data are available upon reasonable request to the corresponding author.

Accepted Article

## References

1. Our World In Data. Coronavirus (COVID-19) Vaccinations. [https://ourworldindata.org/covid-vaccinations?country=OWID\\_WRL](https://ourworldindata.org/covid-vaccinations?country=OWID_WRL). Published 2022. Accessed March 21, 2022. [https://ourworldindata.org/covid-vaccinations?country=OWID\\_WRL](https://ourworldindata.org/covid-vaccinations?country=OWID_WRL)
2. di Saverio S, Podda M, de Simone B, et al. Diagnosis and treatment of acute appendicitis: 2020 update of the WSES Jerusalem guidelines. *World Journal of Emergency Surgery*. 2020;15(1). doi:10.1186/S13017-020-00306-3
3. FDA. Comirnaty and Pfizer-BioNTech COVID-19 Vaccine. Published 2022. Accessed March 21, 2022. <https://www.fda.gov/emergency-preparedness-and-response/coronavirus-disease-2019-covid-19/comirnaty-and-pfizer-biontech-covid-19-vaccine#additional>
4. Mitchell J, Yue QY. Appendicitis as a possible safety signal for the COVID-19 vaccines. *Vaccine X*. 2021;9:100122. doi:10.1016/j.jvacx.2021.100122
5. WHO World Health Organization. *Causality Assessment of an Adverse Event Following Immunization (AEFI): User Manual for the Revised WHO Classification*. Second Edition.; 2018. Accessed March 22, 2022. chrome-extension://efaidnbmnnnibpcajpcglclefindmkaj/viewer.html?pdfurl=https%3A%2F%2Fwww.who.int%2Fvaccine\_safety%2Fpublications%2Faefi\_manual.pdf&clen=1956918&chUNK=true
6. Polack FP, Thomas SJ, Kitchin N, et al. Safety and Efficacy of the BNT162b2 mRNA Covid-19 Vaccine. *New England Journal of Medicine*. 2020;383(27):2603-2615. doi:10.1056/NEJMoa2034577
7. Barda N, Dagan N, Ben-Shlomo Y, et al. Safety of the BNT162b2 mRNA Covid-19 Vaccine in a Nationwide Setting. *New England Journal of Medicine*. 2021;385(12):1078-1090. doi:10.1056/NEJMoa2110475
8. Li X, Ostropolets A, Makadia R, et al. Characterising the background incidence rates of adverse events of special interest for covid-19 vaccines in eight countries: multinational network cohort study. *BMJ*. Published online June 14, 2021:n1435. doi:10.1136/bmj.n1435
9. Ferris M, Quan S, Kaplan BS, et al. The Global Incidence of Appendicitis. *Annals of Surgery*. 2017;266(2):237-241. doi:10.1097/SLA.0000000000002188
10. Manisty C, Otter AD, Treibel TA, et al. Antibody response to first BNT162b2 dose in previously SARS-CoV-2-infected individuals. *The Lancet*. 2021;397(10279):1057-1058. doi:10.1016/S0140-6736(21)00501-8
11. Rubér M, Berg A, Ekerfelt C, Olaison G, Andersson RE. Different cytokine profiles in patients with a history of gangrenous or phlegmonous appendicitis. *Clinical and Experimental Immunology*. 2005;143(1):117-124. doi:10.1111/j.1365-2249.2005.02957.x
12. Guo G, Greenson JK. Histopathology of Interval (Delayed) Appendectomy Specimens. *The American Journal of Surgical Pathology*. 2003;27(8):1147-1151. doi:10.1097/00000478-200308000-00013
13. Tucker ON, Healy V, Jeffers M, Keane FBV. Granulomatous appendicitis. *The Surgeon*. 2003;1(5):286-289. doi:10.1016/S1479-666X(03)80047-1
14. Rosenblum HG, Gee J, Liu R, et al. Safety of mRNA vaccines administered during the initial 6 months of the US COVID-19 vaccination programme: an observational study of reports to the Vaccine Adverse Event Reporting System and v-safe. *The Lancet Infectious Diseases*. Published online March 2022. doi:10.1016/S1473-3099(22)00054-8
15. Kildegaard H, Ladebo L, Andersen JH, et al. Risk of Appendicitis After mRNA COVID-19 Vaccination in a Danish Population. *JAMA Intern Med*. 2022 Apr 25. doi:10.1001/jamainternmed.2022.1222
16. EMA. Comirnaty COVID-19 vaccine: EMA recommends approval for children aged 5 to 11. Published 2022. Accessed March 21, 2022. <https://www.ema.europa.eu/en/news/comirnaty-covid-19-vaccine-ema-recommends->

Accepted Article

approval-children-aged-5-  
11#:~:text=EMA's%20human%20medicines%20committee%20(CHMP,children%20aged  
%2012%20and%20above

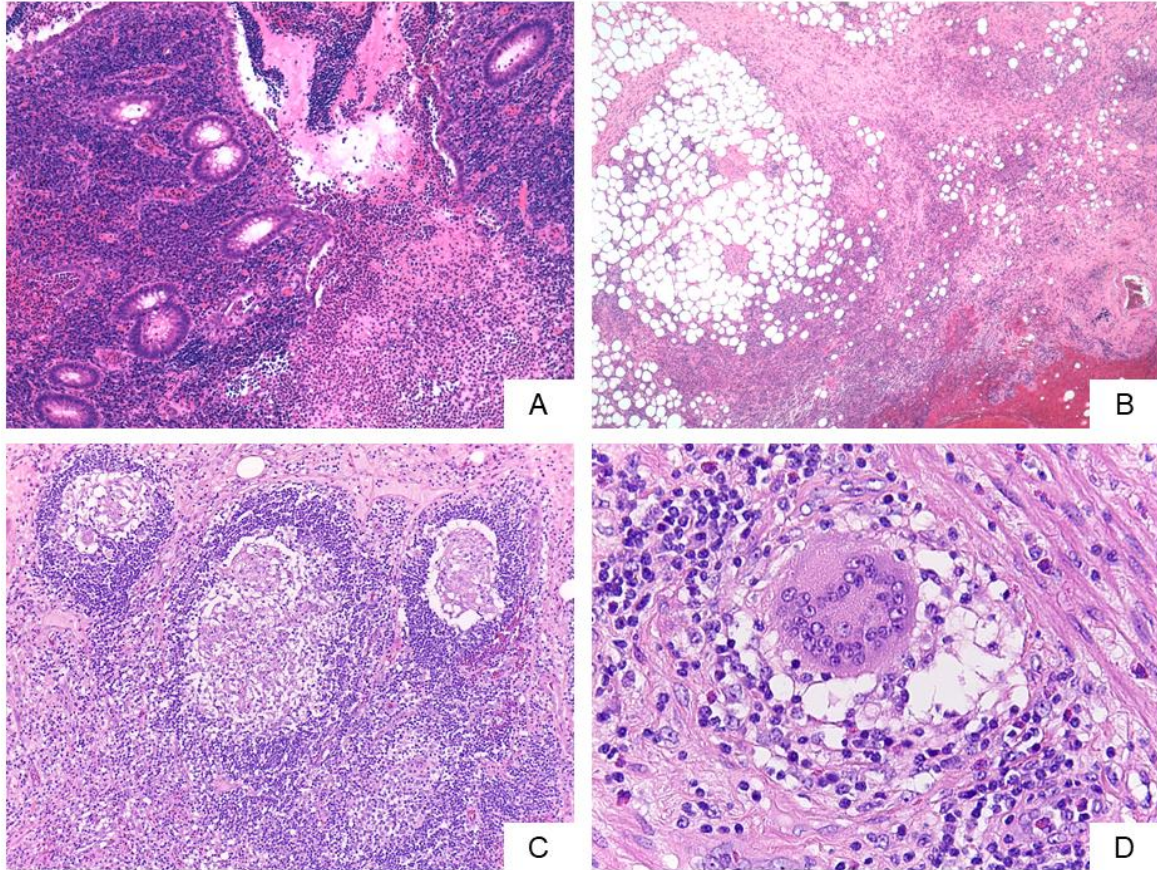


Figure 1. A: Prominent mucosal disease with cryptitis, crypt abscess and erosions. Collections of neutrophils were seen in the lumen (H&E, x100). B: Subserosal layer of the appendix with fibrosis and abundant acute and chronic inflammation (H&E, x100). C: Non-necrotizing epithelioid granulomas within germinal centres of lymphoid follicles (H&E, x200). D: Scattered foreign-body type giant cells were also present (H&E, x400).

Accepted