



UNIVERSITÀ
DEGLI STUDI
FIRENZE

FLORE

Repository istituzionale dell'Università degli Studi di Firenze

Recurrent intra-stent coronary restenosis in a carrier of non-disease-specific antinuclear antibodies

Questa è la Versione finale referata (Post print/Accepted manuscript) della seguente pubblicazione:

Original Citation:

Recurrent intra-stent coronary restenosis in a carrier of non-disease-specific antinuclear antibodies / Tomberli, Benedetta; Fumagalli, Stefano; Minopoli, Tiziana Cristina; Menale, Silvia; Scheggi, Valentina; Marchionni, Niccolò. - In: EUROPEAN JOURNAL OF CASE REPORTS IN INTERNAL MEDICINE. - ISSN 2284-2594. - ELETTRONICO. - (2024), pp. 1-4. [10.12890/2024_004412]

Availability:

The webpage <https://hdl.handle.net/2158/1356585> of the repository was last updated on 2024-11-23T14:43:10Z

Published version:

DOI: 10.12890/2024_004412

Terms of use:

Open Access

La pubblicazione è resa disponibile sotto le norme e i termini della licenza di deposito, secondo quanto stabilito dalla Policy per l'accesso aperto dell'Università degli Studi di Firenze (<https://www.sba.unifi.it/upload/policy-oa-2016-1.pdf>)

Publisher copyright claim:

La data sopra indicata si riferisce all'ultimo aggiornamento della scheda del Repository FloRe - The above-mentioned date refers to the last update of the record in the Institutional Repository FloRe

(Article begins on next page)



RECURRENT INTRA-STENT CORONARY RESTENOSIS IN A CARRIER OF NON-DISEASE-SPECIFIC ANTINUCLEAR ANTIBODIES

Benedetta Tomberli¹, Stefano Fumagalli², Tiziana Cristina Minopoli², Silvia Menale², Valentina Scheggi³, Niccolò Marchionni²

¹ Division of Cardiology, Cardiothoracovascular Department, Azienda Ospedaliero-Universitaria Careggi, Florence, Italy

² Department of Experimental and Clinical Medicine, University of Florence, Florence, Italy

³ Division of Cardiovascular and Perioperative Medicine, Cardiothoracovascular Department, Azienda Ospedaliero-Universitaria Careggi, Florence, Italy

Corresponding author: Valentina Scheggi **e-mail:** valentina.scheggi@gmail.com

Received: 21/02/2024 Accepted: 26/02/2024 Published: 05/04/2024

Conflicts of Interests: The Authors declare that there are no competing interests.

Patient Consent: The patient signed written informed consent.

Acknowledgements: All authors take responsibility for all aspects of the reliability of the data presented and their discussed interpretation. This case report adheres to the principles outlined in the Declaration of Helsinki and follows the ethical standards of the institutional review board.

This article is licensed under a Commons Attribution Non-Commercial 4.0 License

How to cite this article: Tomberli B, Fumagalli S, Minopoli TC, Menale S, Scheggi V, Marchionni N. Recurrent intra-stent coronary restenosis in a carrier of non-disease-specific antinuclear antibodies. *EJCRIM* 2024;**11**:doi:10.12890/2024_004412

ABSTRACT

Intracoronary in-stent restenosis (ISR) is a phenomenon that generally occurs between 3 and 6 months after stent placement. With the introduction of drug-eluting stents (DES), the incidence of ISR has decreased but not disappeared. We report a case of reiterant in-stent restenosis of an 81-year-old female patient who underwent multiple percutaneous coronary intervention and two coronary artery bypass surgeries. ISR is possibly associated with extra-stent, stent-related and intra-stent factors. Here, we excluded the first two and focused on the intra-stent factors that seem more likely in our case. A challenging diagnostic workup led us to the hypothesis of a coronary vasculitis potentially triggered by some component of the stent in a predisposed patient carrier of non-disease-specific ANA, with an exaggerated immune response. No recurrence of ISR occurred after the introduction of steroids. Biological and intra-stent causes of ISR should be taken into careful consideration to aim for the early detection of the underlying mechanism of restenosis and to embrace the best therapeutic strategy.

KEYWORDS

Intracoronary in-stent restenosis, coronary vasculitis, autoimmune disease

LEARNING POINTS

- Intra-stent restenosis is possibly associated with extra-stent, stent-related and intra-stent factors.
- Coronary vasculitis is potentially triggered by some component of the stent in a predisposed patient.
- Immunosuppressive treatment should be taken into consideration in case of recurrent intra-stent restenosis.



INTRODUCTION

Since the first introduction of percutaneous transluminal coronary angioplasty (PTCA) in the management of coronary heart disease, early postoperative thrombosis or delayed intra-stent restenosis (ISR) have been the main factors potentially limiting its clinical efficacy. ISR is defined as a stenosis >50% of the stent lumen found at angiography^[1]. High rates of ISR associated with bare-metal stents led to the development of drug-eluting stents (DES), which delayed neointimal formation, with the incidence of ISR reduced to 5–10%. Despite further improvements in-stent scaffold design and drugs eluted with most modern DES, ISR rates with second-generation DES remained similar and continue to pose a therapeutic challenge^[2]. Hypersensitivity to the scaffold polymer or the eluted drug, local inflammation and delayed healing are considered among the main contributors to neointima formation, leading to ISR^[1]. However, autoimmune diseases have been also mentioned as further potential ISR determinants^[3].

CASE DESCRIPTION

Here, we describe the case of an 81-year-old woman with recurrent ISR. She had multiple cardiovascular risk factors in the absence of other severe comorbidities. She was admitted to the Emergency Department for the first time in March 2018 due to non-ST-elevation myocardial infarction, timely treated with PTCA and double DES implantation in the proximal-middle tract of circumflex (Cx) and in the middle tract of right coronary artery (RCA). She was discharged on dual antiplatelet, aggressive lipid-lowering and antihypertensive treatment. In October 2018, she experienced a further NSTEMI caused by proximal occlusion of left anterior descending artery (LAD), associated with Cx ISR, treated with DES implantation in the LAD and balloon angioplasty of Cx; occlusion of RCA was also shown, with distal reperfusion through re-opened LAD. Despite optimal adherence to drug therapy, between October 2018 and August 2022 she experienced three relapses of angina on minimal exercise or at rest at 6-month intervals: in all those instances, a prompt coronary angiography demonstrated > 90% ISR of proximal LAD and Cx (Fig. 1). She therefore underwent surgical revascularisation with off-pump coronary artery bypass surgery with implantation of left internal mammary artery (LIMA) on LAD and a Y-graft of the right internal mammary artery (RIMA) for the obtuse marginal branch. Over the following months she experienced multiple episodes of acute coronary syndrome relapses and underwent three further PTCA. Coronary angiography during the first episode (October 2020) demonstrated a critical stenosis of LIMA-LAD (Fig. 2), occlusion of the Y-graft to the obtuse marginal, a critical stenosis of ostial left main and a > 90% stenosis proximal LAD and Cx extended to distal left main. A PTCA with double DES implantation in left main and LAD and Cx bifurcation had a good immediate angiographic result (Fig. 2). Two further ISR of proximal LAD/Cx symptomatic for angina at rest were treated with

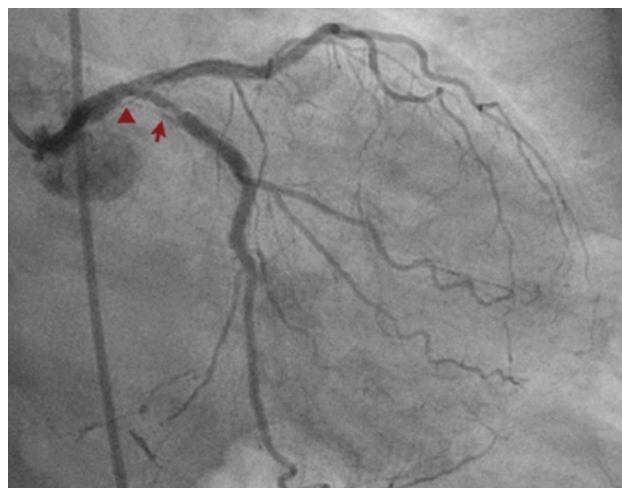


Figure 1. Coronary angiography: critical stenosis of the ostial left main artery (arrowhead) and critical in-stent restenosis of the proximal Cx (arrow).

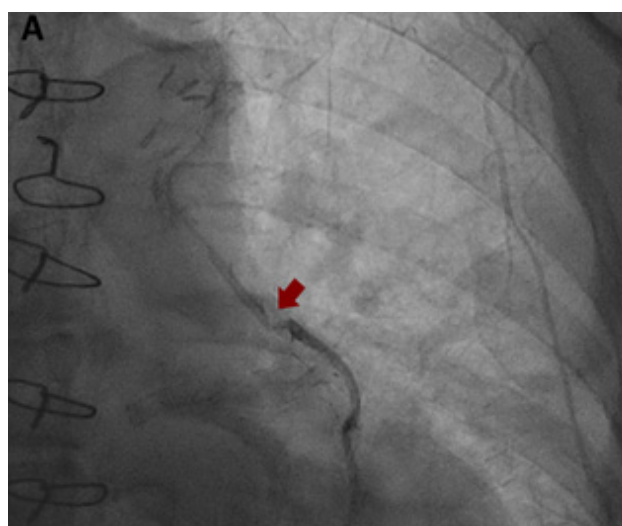


Figure 2. Critical occlusion of LIMA-RIMA anastomosis on LAD.

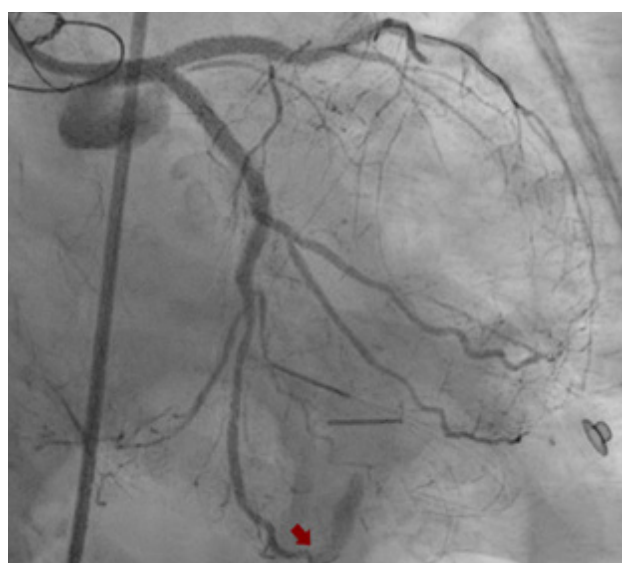

Figure 3. Result of PTCA of left main coronary artery and proximal LAD-Cx. Venous bypass to the second obtuse marginal branch probably occluded, as suggested by stagnation of contrast medium in the distal part of the graft (arrow). Selective bypass angiography was not performed.

successful PTCA (drug-eluting or simple balloon angioplasty) in February and October 2021 (Fig. 3). In January 2022, she was re-operated on as a new, urgent coronary artery bypass surgery with venous conduits, because of a new critical ostial occlusion of LAD and circumflex Cx with ECG and hemodynamic instability. The further clinical course was complicated by a hyper-acute coronary artery bypass surgery occlusion two days after the procedure, treated with emergent PTCA with DES implantation in the left main coronary artery and LAD-Cx bifurcation.

Based on such a complex clinical history, we hypothesised an inflammatory pathogenesis of accelerated and repeated ISR and, accordingly, we planned a wide laboratory search, which revealed anti-proliferating cell nuclear antigen (PCNA2) antibodies [1:640]. Though these antibodies are considered poorly specific^[4], we initiated an anti-inflammatory and immunosuppressive treatment with colchicine and steroids. An ¹⁸F-FDG PET whole-body scan performed after two weeks of steroid therapy was negative for vasculitis or paraneoplastic processes.

In July 2022, a follow-up coronary CT scan showed a stable picture of coronary artery disease, in the absence of significant ISR. In October 2022, the patient was reviewed by an immunologist, who recommended the discontinuation of steroids and the introduction of methotrexate 15 mg per week; HLA-B51 typing, with the suspicion of Behçet's syndrome, was negative. On January 2023, the patient was re-hospitalised for symptomatic New York Heart Association (NYHA) class III heart failure with severe left ventricular systolic dysfunction (LVEF) at 38%: a coronary angiography revealed a sub-occlusive ISR of proximal LAD and middle-tract Cx. On that occasion, an intravascular imaging with optical coherence tomography (OCT) showed that ISR lesions consisted of remarkable neointimal hyperplasia (Fig. 4). A further, successful PTCA consisted of DES implantation in the left main LAD and percutaneous old balloon angioplasty of ISR of the Cx, with progressive improvement of the left ventricular ejection fraction to 55%. Full-dose steroids were restarted with prednisone 25 mg/day, with subsequent reduction to 5 mg daily as a maintenance dose. The clinical course over the following 9 months was uneventful.

DISCUSSION

ISR, defined as a luminal narrowing of > 50% of a stented coronary segment or within 5 mm of a stent edge^[2], occurs most often 3–6 months after stent placement, though cases with later onset have been described^[5]. ISR usually manifests clinically as recurring angina or as an acute myocardial infarction in about 10% of cases^[6-7].

Development of ISR may be attributed to a variable interplay of three categories of factors that are outlined in Figure 5: extra-stent factors (which impede adequate stent expansion such as vessel calcification, multiple stent layers, vessel size), stent-related factors (under-expansion, under-sizing, fracture/gap, edge restenosis) and intra-stent factors (local inflammation leading to aggressive neointimal proliferation

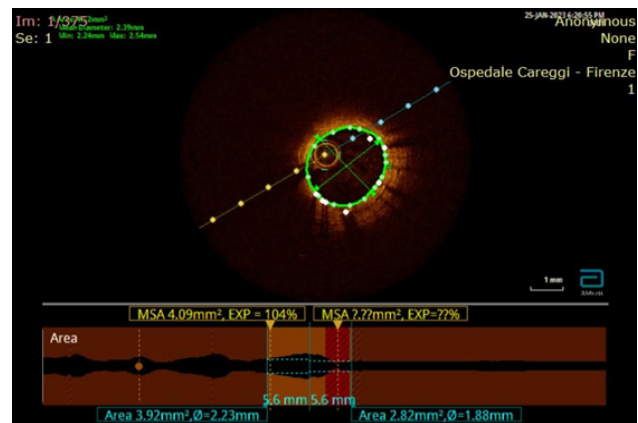


Figure 4. Intravascular imaging with OCT showing ISR lesions consisting of neointimal hyperplasia.

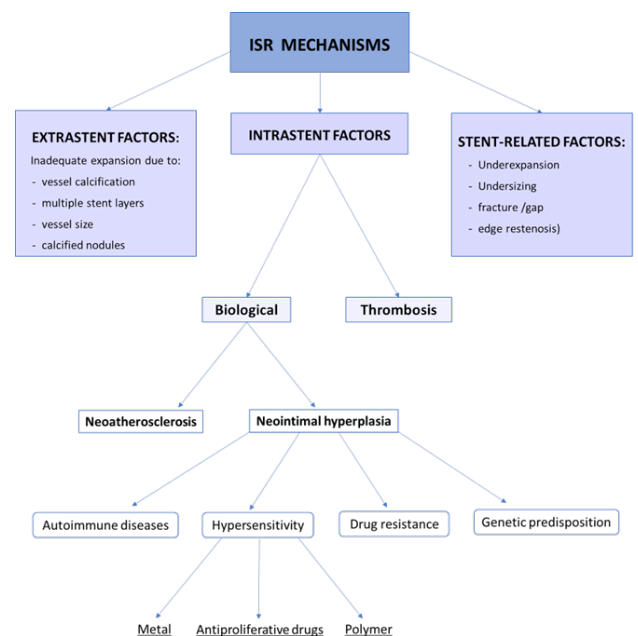


Figure 5. Outline of mechanisms potentially involved in ISR.

or late neo-atherosclerosis)^[2,8]. We excluded the presence of extra-stent or stent-related factors, and we focused our attention on intra-stent mechanisms (Fig. 3).

(1) Neointimal proliferation, which consists of a non-specific inflammatory response to vessel mechanical injury, promotes vascular smooth muscle cell proliferation or migration^[9]. It can be triggered by several factors: (a) hypersensitivity to any of the three stent components, i.e. metal, polymer or drug eluted^[7,9-11]; (b) autoimmune diseases with vasculitis of coronary vessels, such as in Kawasaki disease, Takayasu arteritis, polyarteritis nodosa and giant cell arteritis^[12], Behçet's syndrome, or vasculitis of undefined origin, presenting with recurring ISR^[13]; (c) resistance to antiproliferative drugs (such as sirolimus and its analogues) or cytotoxic drugs (such as paclitaxel) eluted by DES^[14] although currently, there are no laboratory tests for diagnosing such a resistance, which is suspected by the clinical evolution after PTCA^[15]; (d) gene mutation, another potential pathogenetic intra-stent factor, which has been reported as a cause of exaggerated local inflammatory

reaction leading to intimal hyperplasia^[9,15-16].

(2) Neo-atherosclerosis (Fig. 4), is an accelerated progression of atherosclerosis, compared to de novo atherosclerosis. Little is known about its pathogenesis and predisposing factors. Importantly, neo-atherosclerosis is less frequent in bare-metal stents compared to DES, as a possible result of delayed re-endothelialisation^[17].

Each of the above-mentioned mechanisms of ISR was taken into consideration in our case analysis.

A hypersensitivity reaction against stent metals was excluded by negative history and negative (nickel, molybdenum, platinum, and chromium) or non-diagnostic (weak positivity against nickel) patch tests. Hypersensitivity against eluted drugs and polymers was considered unlikely, as DES implanted in several PTCA were different.

Several mechanisms that may be involved in neo-atherosclerosis have been analysed. Resistance to clopidogrel was excluded by specific genetic testing for CYP2C19 polymorphism. Thanks to aggressive treatment with high-intensity statins and ezetimibe, low-density lipoprotein cholesterol has been maintained constantly around 50 mg/dl; we deemed it unlikely that an isolated elevation (964 mg/dl) of lipoprotein(a) could have been responsible for so many rapidly recurring episodes of ISR.

Resistance to antiproliferative drugs was also taken into consideration but was deemed to be inconsistent with the patient's history, because – as already mentioned – DES used were largely different and the bypass graft showed early stenosis process.

Finally, we carefully analysed the possibility of an autoimmune pathogenesis. Several elements support the hypothesis of an autoimmune vasculitis. Recurrent ISR occurred very early; the patient also developed a non-statin-induced myositis, which responded well to immunosuppressive therapy (with corticosteroids and methotrexate), with a likely protective anti-inflammatory action on coronary vessels as well. At the one-year coronary CT scan, no further ISR was noticed. The autoimmune panel was positive for a pleomorphic antinuclear antibody (ANA) pattern, with a titre test >1:640 for PCNA2 (anti-proliferating cell nuclear antigen), a particular type of ANA whose clinical significance is still not completely clarified. The ANA positivity, along with clinical history and the tendency to mouth ulcers referred to, raised the suspicion of Behçet vasculitis, but investigation of HLA-B51 polymorphism gave negative results. To further investigate this hypothesis, an ¹⁸F-FDG PET scan was performed but was negative for vascular areas of hypermetabolism, though we acknowledge that PET was obtained after 2 weeks of high-dose corticosteroids. Conversely, an inflammatory process resulting in rapid development of vasculitis was supported by the OCT imaging, suggesting that restenotic areas were represented by thickened fibrous material (Fig. 4).

The hypothesis of coronary vasculitis was reinforced by the positive response to long-term steroid administration. Moreover, after a free clinical period, a further ISR occurred when steroids were withdrawn. In conclusion, a vasculitis of

unknown origin highly responsive to immunosuppressive treatment is a likely – though rare – mechanism to be taken into consideration in case of recurrent ISR.

REFERENCES

1. Hu W, Jiang J. Hypersensitivity and in-stent restenosis in coronary stent materials. *Front Bioeng Biotechnol* 2022;**10**:1003322.
2. Shlofmitz E, Iantorno M, Waksman R. Restenosis of drug-eluting stents: a new classification system based on disease mechanism to guide treatment and state-of-the-art review. *Circ Cardiovasc Interv* 2019;**12**:e007023.
3. Pepe M, Napoli G, Carulli E, Moscarelli M, Forleo C, Nestola PL, et al. Autoimmune diseases in patients undergoing percutaneous coronary intervention: a risk factor for in-stent restenosis? *Atherosclerosis* 2021;**333**:24–31.
4. Schur PH. Laboratory testing for the diagnosis, evaluation, and management of systemic lupus erythematosus: still more questions for the next generations: a tribute and thanks and in memory of my mentor: Henry G. Kunkel. *Clin Immunol* 2016;**172**:117–121.
5. Chioncel V, Andrei CL, Brezeanu R, Sinescu C, Avram A, Tatu AL. Some perspectives on hypersensitivity to coronary stents. *Int J Gen Med* 2021;**14**:4327–4336.
6. Omeh DJ, Shlofmitz E. Restenosis of stented coronary arteries. 2023 Aug 8. In: StatPearls [Internet]. Treasure Island (FL): StatPearls Publishing; 2024 Jan.
7. Bazyani A, Simion P, Anghel L, Statescu C, Tinica G. Multiple in-stent restenosis. a rare cause of resistance to antiproliferative drugs? *Maedica (Bucur)* 2019;**14**:38–44.
8. Alfonso F, Coughlan JJ, Giacoppo D, Kastrati A, Byrne RA. Management of in-stent restenosis. *EuroIntervention* 2022;**18**:e103–e123.
9. Buccheri D, Piraino D, Andolina G, Cortese B. Understanding and managing in-stent restenosis: a review of clinical data, from pathogenesis to treatment. *J Thorac Dis* 2016;**8**:E1150–E1162.
10. Slodownik D, Danenberg C, Merkin D, Swaid F, Moshe S, Ingber A, et al. Coronary stent restenosis and the association with allergy to metal content of 316L stainless steel. *Cardiovasc J Afr* 2018;**29**:43–45.
11. Dangas GD, Claessen BE, Caixeta A, Sanidas EA, Mintz GS, Mehran R. In-stent restenosis in the drug-eluting stent era. *J Am Coll Cardiol* 2010;**56**:1897–1907.
12. Khanna S, Garikapati K, Goh DSL, Cho K, Lo P, Bhojaraja MV, et al. Coronary artery vasculitis: a review of current literature. *BMC Cardiovasc Disord* 2021;**21**:7.
13. Kikuchi S, Okada K, Hibi K, Maejima N, Yabu N, Uchida K, et al. Coronary arteritis: a case series. *Eur Heart J Case Rep* 2020;**4**:1–6.
14. Yoon S-O, Roux PP. Rapamycin resistance: mTORC1 substrates hold some of the answers. *Curr Biol* 2013;**23**:R880–883.
15. Koch W, Böttiger C, Mehilli J, von Beckerath N, Neumann FJ, Schömig A, et al. Association of a CD18 gene polymorphism with a reduced risk of restenosis after coronary stenting. *Am J Cardiol* 2001;**88**:1120–1124.
16. Fitridge R, Thompson M, editors. Mechanisms of vascular disease: a reference book for vascular specialists [Internet]. Adelaide (AU): University of Adelaide Press; 2011.
17. Kazemian MR, Solouk A, Tan A, Seifalian AM. Preventing in-stent restenosis using lipoprotein (a), lipid and cholesterol adsorbent materials. *Med Hypotheses* 2015;**85**:986–988.