



UNIVERSITÀ
DEGLI STUDI
FIRENZE

FLORE

Repository istituzionale dell'Università degli Studi di Firenze

PRESSURE LAVAGE UNDER ULTRASOUND GUIDANCE: A NEW APPROACH FOR OUTPATIENT TREATMENT OF INTRAUTERINE

Questa è la Versione finale referata (Post print/Accepted manuscript) della seguente pubblicazione:

Original Citation:

PRESSURE LAVAGE UNDER ULTRASOUND GUIDANCE: A NEW APPROACH FOR OUTPATIENT TREATMENT OF INTRAUTERINE ADHESION / Coccia ME; Becattini C; Bracco GL; Pampaloni F; Bargelli G; Scarselli G.. - In: FERTILITY AND STERILITY. - ISSN 0015-0282. - STAMPA. - 75:(2001), pp. 601-606.

Availability:

The webpage <https://hdl.handle.net/2158/15717> of the repository was last updated on

Terms of use:

Open Access

La pubblicazione è resa disponibile sotto le norme e i termini della licenza di deposito, secondo quanto stabilito dalla Policy per l'accesso aperto dell'Università degli Studi di Firenze (<https://www.sba.unifi.it/upload/policy-oa-2016-1.pdf>)

Publisher copyright claim:

La data sopra indicata si riferisce all'ultimo aggiornamento della scheda del Repository FloRe - The above-mentioned date refers to the last update of the record in the Institutional Repository FloRe

(Article begins on next page)

Pressure lavage under ultrasound guidance: a new approach for outpatient treatment of intrauterine adhesions

Maria Elisabetta Coccia, M.D., Ph.D., Carolina Becattini, M.D., Gian Luca Bracco, M.D., Francesca Pampaloni, M.D., Gianni Bargelli, M.D., and Gianfranco Scarselli, M.D.

Department of Obstetrics and Gynaecology, Perinatology, and Human Reproduction, University of Florence Medical School, Florence, Italy

Objective: To present pressure lavage under ultrasound guidance (PLUG) as a new therapeutic procedure for selected cases of intrauterine adhesions (IUA).

Design: An open clinical investigation with no control group.

Setting: Teaching hospital.

Patient(s): Seven consecutive patients referred to our department for secondary amenorrhea due to IUA.

Intervention(s): A newly developed technique based on sonohysterography was used to monitor the effects of intrauterine injections of saline solution on the continuous accumulation of saline in the uterine cavity for the mechanical disruption of IUA.

Main Outcome Measure(s): Lysis of intrauterine adhesions, restoration of menses, and increased pregnancy rate in infertile patients.

Result(s): Five patients with mild IUA obtained satisfactory lysis of adhesions by the use of the PLUG technique. A second-look hysteroscopy after 1 month showed that filmy adhesions persisted in two patients with moderate IUA. These adhesions were removed successfully during hysteroscopy. Restoration of menses was obtained and has continued in all patients. Two of the three infertile patients became pregnant.

Conclusion(s): This technique is safe and ideal as an in-office procedure. PLUG allows complete lysis in mild IUA cases, and the need for therapeutic, and possibly follow-up hysteroscopy, can be avoided. In moderate IUA cases, the procedure may represent a useful initial step in reducing the need for operative hysteroscopy. (Fertil Steril® 2001;75:601–6. ©2001 by American Society for Reproductive Medicine.)

Key Words: Asherman's syndrome, intrauterine adhesions, sonohysterography, ultrasound monitoring, hysteroscopy

Intrauterine adhesions (IUA) were first reported by Asherman in 1948 (1). They may occur following curettage for the evacuation of postabortion or postdelivery tissue. Hysterosalpingography, hysteroscopy (2), ultrasound (3), and recently magnetic resonance imaging (4, 5) have been used to demonstrate the presence of IUA.

Operative hysteroscopy has fully replaced dilatation and curettage or blind dissection (6, 7) in the treatment of Asherman's syndrome. During the last few years, a series of noninvasive methods for the treatment of IUA has been introduced (8–11). However, all of these procedures require radiologic exposure.

We recently developed pressure lavage un-

der ultrasound guidance (PLUG), a therapeutic procedure for selected cases of IUA. It is based on sonohysterography, in which various fluids are injected into the uterine area to improve visualization of the uterine cavity (12, 13). This prospective study reports our experiences using this technique as a therapeutic tool in selected cases of Asherman's syndrome.

MATERIALS AND METHODS

Patient Selection

Seven consecutive patients were included in the study. They were referred to our department from January 1998 to December 1998 for treatment of their secondary amenorrhea due to

Received June 6, 2000;
revised and accepted
September 25, 2000.

Reprint requests: Dr. Maria
Elisabetta Coccia, Via
Ippolito Nievo 2, 50134
Florence, Italy (FAX: +39
055 434 330/2398.396; E-
mail: mecoccia@tin.it).

0015-0282/01/\$20.00
PII S0015-0282(00)01770-2

IUA. Three were under the care of our infertility unit due to secondary infertility.

The clinical history of the seven patients included two full-term pregnancies, three curettages after miscarriage, and two curettages after caesarean section. The mean age of the patients was 32.3 ± 4.8 (age range 24–39 years). In all cases amenorrhea was present after some traumatic event, following curettage. Two women who had delivered at caesarean section underwent curettage. Neither one menstruated after breast feeding had been stopped. The mean length of time of amenorrhea was 9 months (range 6 to 18 months).

All patients underwent testing that included transvaginal ultrasound scanning and diagnostic hysteroscopy, which confirmed the presence of IUA. Ultrasonographic finding of IUA was based on the irregular shapes of the endometrial echoes, with single or multiple interruptions of the echogenic endometrial line. The hysteroscopy determined the extent of uterine cavity occlusion and the type of adhesions that were present, thus allowing for accurate staging of the disease.

According to March et al. (7), intrauterine adhesions can be classified at hysteroscopy as mild, moderate, or severe.

- *Mild* indicates that less than three-fourth of the uterine cavity is involved. Thin or filmy adhesions are present. The ostial areas and the upper fundus are minimally involved or show no adhesions.
- *Moderate* indicates that one-fourth to three-fourths of the uterine cavity is involved. There is no agglutination of the walls. Only adhesions are present. Ostial areas and the upper fundus are only partially occluded.
- *Severe* indicates that more than three-fourths of the uterine cavity is involved. Agglutination of the walls or thick bands can be present. Ostial areas and the upper cavity are occluded.

None of our patients presented with lower uterine segment/upper cervical canal adhesions. No patient had menstruated during the months following hysteroscopy. Notwithstanding distension of the cavity during hysteroscopy, the adhesions would not detach. Even using the tip of the hysteroscope had no effect.

Hysterosalpingography was not performed on any of the patients, given that the anatomical information provided by the previous procedures was sufficient for the diagnosis and the staging of the disease.

In this patient series, five of the seven patients had mild IUA and two had moderate IUA.

Before the start of the investigation, written informed consent was obtained from all of the patients, and they had full knowledge of the procedures to be undertaken. The ethics committee of the hospital (institutional review board) approved the study protocol.

General Operative Procedure

PLUG is performed in an outpatient setting.

During the procedure, the patient was placed in a dorsal lithotomy position. Ultrasound scanning with the use of a 5.5-MHz endovaginal probe (Aloka SSD-620, Tokyo, Japan) was performed to evaluate the condition of pelvic area and to obtain a detailed visualization of the endometrial echoes.

After vaginal disinfection, a speculum was positioned and a cervical cap applied to the cervix (cervical adapter, WISAP, Germany). The adapter we used is available in several sizes (small, medium, large) and has two catheters. One catheter allows for the creation of a vacuum; the other allows for the injection of the saline solution.

The speculum was then removed to reduce the presence of any disturbing echo. The 5.5-MHz endovaginal probe, with sterile cover, was then inserted. When necessary, a 3.5-MHz convex transducer was used transabdominally for additional visualization. A 60-mL syringe was then attached to the injection catheter and, under ultrasound guidance, sterile saline solution was injected into the uterine cavity (Figure 1).

Initially, injection of 5 to 10 mL of saline solution must proceed very slowly to allow for gradual dilatation. Then injection was continued, increasing the pressure; the piston was pushed until the patient started to feel pain, at which point it was stopped. The same procedure was repeated several times.

When intrauterine adhesions were present, single or multiple irregular filling defects of varying size were found in the uterine cavity. The distribution of the saline solution throughout the uterine cavity was hampered; the turbulent flow generated could be visualized as a hyperechogenic image. The presence of the cervical adapter prevented the leakage of any saline solution from the cervical canal. There was a continuous accumulation of the fluid in the uterine cavity, and mechanical disruption of the adhesions could be sonographically documented.

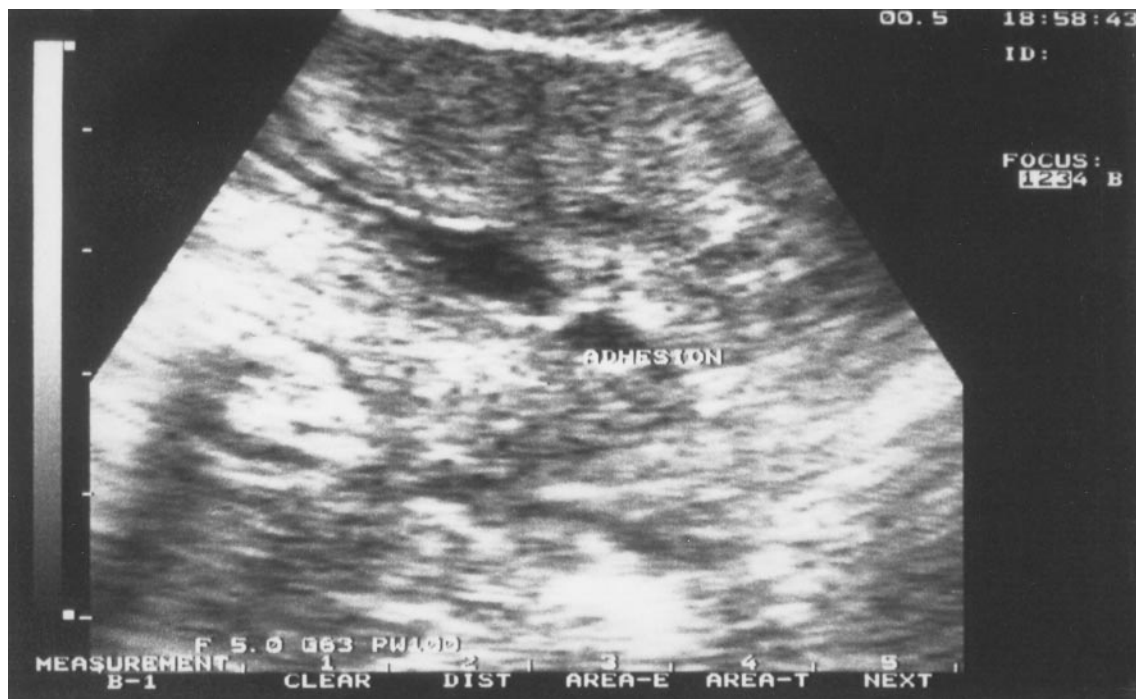The injecting of the saline solution was terminated when we could visualize complete distension of the uterine cavity with no residual interruption of the endometrial contour and no filling defects (Figure 2). We then removed the cervical adapter, and administered intramuscular cefazolin (1 g; Totacef, Mead Johnson) as an antibiotic prophylaxis.

The transvaginal ultrasound was performed 1 week after the PLUG procedure. This procedure was repeated following the same protocol when IUA persisted.

All patients were treated with an estrogenic preparation for 2 months after the procedure and they underwent a second-look hysteroscopy after 1 month.

FIGURE 1

Longitudinal section of the uterus during saline injection at the beginning of the procedure. The uterine cavity appears as an anechoic area and a hyperechogenic band is clearly seen crossing the cavity. Figure 1



Coccia. PLUG and treatment of IUA. *Fertil Steril* 2001.

RESULTS

Safety

No significant complications were observed during or after the PLUG procedure. It was usually well tolerated. Three patients complained of having moderate discomfort. No patient reported any discomfort that was so severe as to require local or general anesthesia.

The mean duration of the procedure was 17 ± 6 minutes (range 10–25 minutes). In one patient, the procedure took a particularly long time (25 minutes) due to extravasation of liquid across the myometrium, which temporarily impaired the visualization of the uterine cavity and required repeated 2- to 3-minute interruptions.

The mean amount of saline solution injected was 95 ± 20 mL up to a maximum of 150 mL. The total amount injected into each patient varied according to the thickness and extension of the adhesions. At follow-up evaluation, no mechanical complications or infections were observed.

Efficacy

After the PLUG procedure, the five patients with mild IUA obtained satisfactory lysis of the adhesions. These results were documented by ultrasound at the end of the procedure. No changes were noted either 1 week after the

PLUG procedure during the ultrasound examination, or at the 1-month second-look hysteroscopy.

In the two patients who had moderate IUA, ultrasound scanning was performed at the end of the procedure, and the results were compatible with satisfactory lysis of the IUA. However, 1 week later at the ultrasound scan, lysis was suboptimal in both patients. Thus, the PLUG procedure was repeated; the second-look hysteroscopy after 1 month showed the persistence of filmy adhesions. In one of these patients the adhesions were removed successfully during office hysteroscopy. The other patient required operative hysteroscopy under general anesthesia.

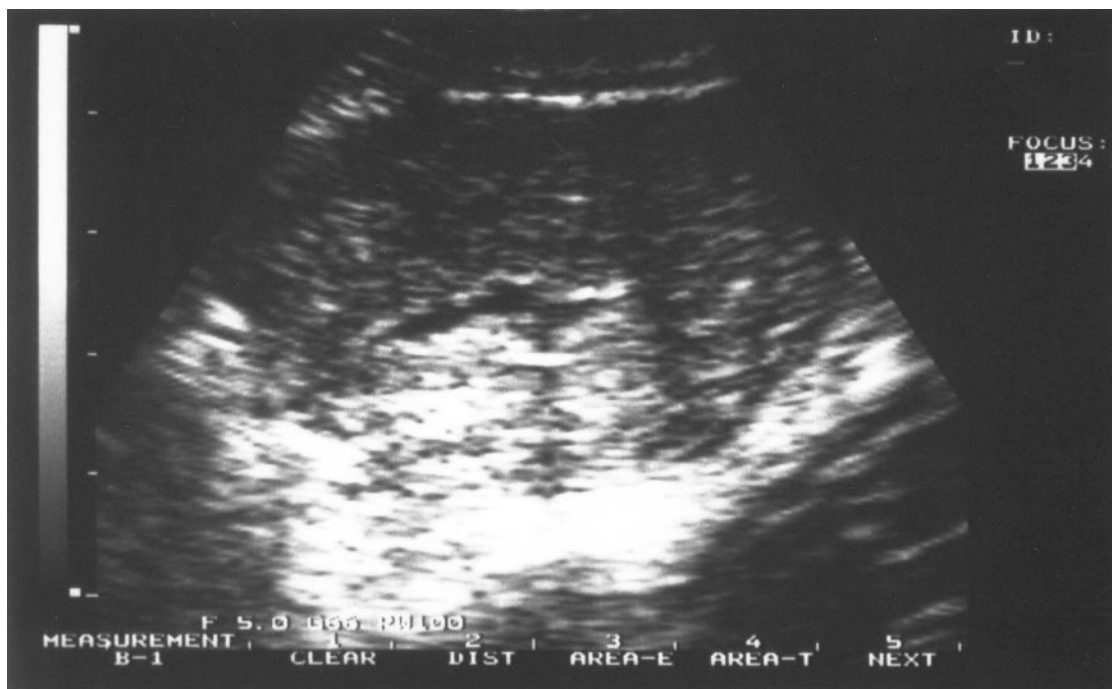
Restoration of menses was achieved in all patients after IUA lysis, and all of the patients have continued to menstruate. Two of the three infertile patients became pregnant; one had a normal delivery, but the other suffered a miscarriage.

DISCUSSION

The treatment of Asherman's syndrome was revolutionized in the 1970s by hysteroscopy (6, 7). The hysteroscopic management of IUA has been effective and ensures lysis of all adhesions. Valle and Sciarra (6) reported a restoration of

FIGURE 2

Transverse section of the uterus at the end of the procedure. The uterine cavity appears as an anechoic area with regular contours. The hyperechogenic band clearly visible in Figure 1 is not present.



Coccia. PLUG and treatment of IUA. *Fertil Steril* 2001.

menses in 88% of patients, with a delivery rate of 80% and a spontaneous abortion rate of 18%.

However, hysteroscopy is an invasive procedure that requires general anesthesia. It is also expensive and is not risk-free. Uterine perforation has been reported, but can be minimized by ultrasound guidance (14, 15). Also, minimally invasive techniques have been described recently in the literature that can be performed in an outpatient setting, thus reducing costs.

Ikeda et al. (8) described successful lysis of IUA using continuous ongoing instillation of iodine contrast medium through an insemination catheter. All of the patients in their series required minimal radiation exposure time, presumably because they had a mild form of the disease. However, the required dose can be unacceptably high in patients who have more extensive disease and in whom an increased amount of time is required to complete the lysis.

Even more recently, Karande et al. (9) presented a new technique for IUA lysis under fluoroscopic control. The investigators inserted a special catheter through the cervix with a balloon attached to its tip. The inflated balloon prevented reflux of the contrast medium and held the device in place. The catheter had a central channel through which hysteroscopic scissors could be introduced to help in lysing

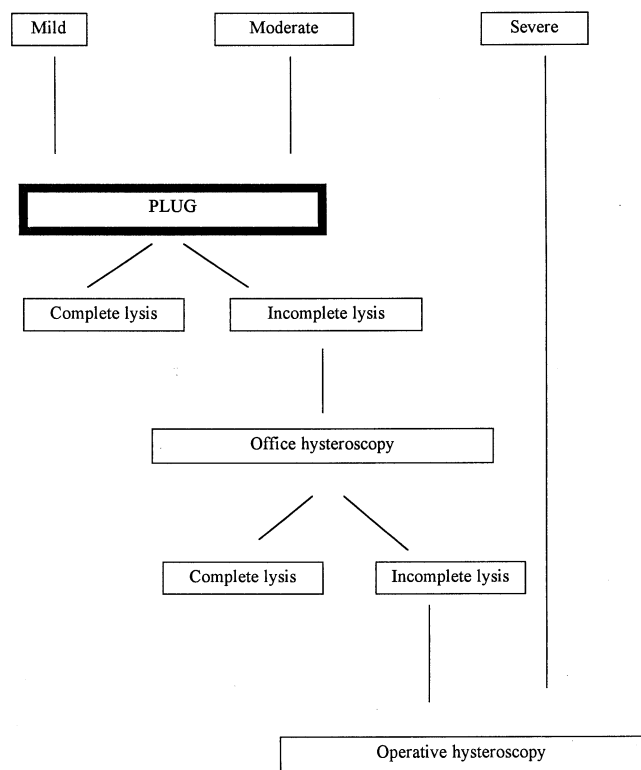
the adhesions, and a side channel through which an assistant could inject radiopaque dye to delineate the uterine cavity with its adhesions. The entire procedure was monitored using fluoroscopy. For the majority of patients this in-office procedure allows for complete lysis of the adhesions with minimal discomfort. The costs are much lower when compared to hysteroscopic treatment. The only limit of this technique would be, most probably, the radiation exposure.

Our study presents a newly developed IUA-treatment technique based on sonohysterography, where an intrauterine injection of saline solution leads to continuous accumulation of saline in the uterine cavity. Consequently, there is mechanical disruption of adhesions. The procedure is carried out using ultrasound monitoring. The PLUG procedure has some points in common with those previously described (8, 9). There are also some important differences.

PLUG shares many of the same advantages as the previously described techniques: reduced invasiveness, minimal costs, minimal discomfort for the patient, and feasibility in an outpatient setting. It also has additional advantages. The PLUG technique is safe. There have been no significant complications during or after the procedure. Because PLUG uses ultrasound monitoring, there is no radiation exposure. Given that prolonged instillation of liquid is possible, com-

FIGURE 3

Stepwise approach for treatment of patients with IUA. PLUG, pressure lavage under ultrasound.



Coccia. PLUG and treatment of IUA. *Fertil Steril* 2001.

plete lysis of IUA can take place exclusively by mechanical disruption. The procedure can be carried out using limited quantities of fluid, thus avoiding the well-known intravasation syndrome that sometimes follows hysteroscopic surgery, as large quantities of fluids increase the risk of this syndrome (16).

Patient selection is the critical factor that can determine the efficacy of PLUG: the extension and type of adhesions are the most important predictors of success. The success rate of the use of PLUG in our patients with mild to moderate IUA was excellent. In all seven patients, functional regeneration of the endometrial lining and the reappearance of withdrawal bleeding followed optimal morphologic restoration of the uterine cavity.

The aim of this study was to demonstrate that PLUG could restore the menstrual cycle, not necessarily fertility. In fact, we had only three patients who wished to have children. Two of the three infertile patients did become pregnant, although one pregnancy resulted in miscarriage. Even if the number of our patients is too small to arrive at any definite conclusion, the pregnancy rate was comparable with the results reported in the literature (17).

The use of a tool (cervical adapter with two catheters) that can be introduced into the cervix is one of the reasons for the success of PLUG. As liquid can be introduced without any spillage from the cervical canal, enough pressure can be obtained to distend the cavity. A hydrodissection-like effect may be the cause of the intrauterine adhesion disruption.

PLUG is indicated in mild cases of IUA, for which it is sufficient for the complete lysis of the adhesions. The PLUG-treated patients had optimal results that were confirmed at hysteroscopy 1 month after the procedure had been carried out and at subsequent ultrasound scans performed after 12 and 18 months. This suggests that when there is satisfactory lysis at the end of the procedure, a follow-up hysteroscopy may be unnecessary once lysis is associated with the restoration of withdrawal bleeding.

Patients with moderate IUA benefited less from PLUG than did subjects with mild IUA: incomplete lysis was more frequent in the former. In moderate IUA, repeated PLUG offered no additional advantage and a hysteroscopic procedure was necessary. However, we found that a first lavage under ultrasound guidance could render subsequent lysis feasible, with the use of in-office hysteroscopy. Thus, there was no further need for operative hysteroscopic treatment. This stepwise approach may be particularly helpful in reducing operating time and eliminating the necessity for general anesthesia.

Severe cases of IUA were not included in this study. Based on the existing literature, we believe that there is no indication for the use of PLUG in these patients. Prognosis is still very poor in severe IUA. The types of treatment available have not proved useful because there is no viable endometrium.

Based on our experiences, we suggest that patients with mild IUA should be treated with PLUG. In the event that PLUG is not successful in removing the adhesions, in-office hysteroscopy should be carried out. This is a valid approach when there is incomplete lysis. Patients with moderate IUA should be considered for PLUG as a preliminary step aimed at reducing the extent of the hysteroscopic procedure. Patients with severe IUA should be directly referred for operative hysteroscopy (Figure 3).

PLUG is safe and ideal for in-office procedures. It allows for complete lysis in patients with mild IUA, thus avoiding the need for therapeutic and possibly follow-up hysteroscopy. In moderate IUA cases, the procedure may represent a useful first step in reducing the need for operative hysteroscopy.

References

1. Asherman JG. Amenorrhea traumatica (atretica). *J Obstet Gynaecol Br Emp* 1948;55:23-7.
2. Fayez JA, Mutie G, Schneider PJ. The diagnostic value of hysterosalpingography and hysteroscopy in infertility investigation. *Am J Obstet Gynecol* 1987;156:558-60.
3. Confino E, Friberg J, Giglia RV, Gleicher N. Sonographic imaging of intrauterine adhesions. *Obstet Gynecol* 1985;66:596-8.

4. Fedele L, Bianchi S, Dorta M, Vignali M. Intrauterine adhesions: detection with transvaginal US. *Radiology* 1996;199:757-9.
5. Letterie GS, Haggerty MF. Magnetic resonance imaging of intrauterine synechiae. *Gynecol Obstet Invest* 1994;37:66-8.
6. Valle RF, Sciarra JJ. Intrauterine adhesions: hysteroscopic diagnosis, classification, treatment and reproductive outcome. *Am J Obstet Gynecol* 1988;158:1459-70.
7. March CM, Israel R, March AD. Hysteroscopic management of intrauterine adhesions. *Am J Obstet Gynecol* 1978;130:653-7.
8. Ikeda T, Morita A, Inamura A, Mori I. The separation procedure for intrauterine adhesions (synechia uteri) under roentgenographic view. *Fertil Steril* 1981;36:333-8.
9. Karande V, Levrant S, Hoxsey R, Rinehart J, Gleicher N. Lysis of intrauterine adhesions using gynecoradiologic techniques. *Fertil Steril* 1997;68:658-62.
10. McComb PF, Wagner BL. Simplified therapy for Asherman's syndrome. *Fertil Steril* 1997;68:1047-50.
11. Broome JD, Vancaillie TG. Fluoroscopically guided hysteroscopic di-
vision of adhesions in severe Asherman's syndrome. *Obstet Gynecol* 1999;93:1041-3.
12. Goldstein SR. Saline infusion sonohysterography. *Clin Obstet Gynecol* 1996;39:248-58.
13. Gaucherand P, Piacenza JM, Salle B, Rudigoz RC. Sonohysterography of the uterine cavity: preliminary investigations. *J Clin Ultrasound* 1995;23:339-48.
14. Shalev E, Shimoni Y, Peleg D. Ultrasound controlled operative hysteroscopy. *J Am Coll Surg* 1994;179:70-1.
15. Coccia ME, Becattini C, Bracco GL, Scarselli G. Ultrasound controlled operative hysteroscopy: a prospective study. *J Reprod Med* 2000;45:413-18.
16. Vilos GA. Intrauterine surgery using a new coaxial bipolar electrode in normal saline solution (Versapoint): a pilot study. *Fertil Steril* 1999;72:740-3.
17. Capella-Allouc S, Morsad F, Rongieres-Bertrand C, Taylor S, Fernandez H. Hysteroscopic treatment of severe Asherman's syndrome and subsequent fertility. *Hum Reprod* 1999;14:1230-3.