



UNIVERSITÀ  
DEGLI STUDI  
FIRENZE

FLORE

## Repository istituzionale dell'Università degli Studi di Firenze

### **Transthoracic three-dimensional echocardiographic reconstruction of left and right ventricles: In vitro validation and comparison with**

Questa è la Versione finale referata (Post print/Accepted manuscript) della seguente pubblicazione:

*Original Citation:*

Transthoracic three-dimensional echocardiographic reconstruction of left and right ventricles: In vitro validation and comparison with magnetic resonance imaging / R. PINI; GIANNAZZO G.; DI BARI M.; INNOCENTI F.; REGA L.; CASOLO G.; DEVEREUX R.B.. - In: AMERICAN HEART JOURNAL. - ISSN 0002-8703. - STAMPA. - 133:(1997), pp. 221-229.

*Availability:*

The webpage <https://hdl.handle.net/2158/219221> of the repository was last updated on

*Terms of use:*

Open Access

La pubblicazione è resa disponibile sotto le norme e i termini della licenza di deposito, secondo quanto stabilito dalla Policy per l'accesso aperto dell'Università degli Studi di Firenze (<https://www.sba.unifi.it/upload/policy-oa-2016-1.pdf>)

*Publisher copyright claim:*

La data sopra indicata si riferisce all'ultimo aggiornamento della scheda del Repository FloRe - The above-mentioned date refers to the last update of the record in the Institutional Repository FloRe

(Article begins on next page)

---

## Imaging and Diagnostic Techniques

# Transthoracic three-dimensional echocardiographic reconstruction of left and right ventricles: In vitro validation and comparison with magnetic resonance imaging

Riccardo Pini, MD,<sup>a</sup> Giuseppe Giannazzo, MD,<sup>a</sup> Mauro Di Bari, MD,<sup>a</sup> Francesca Innocenti, MD,<sup>a</sup> Luigi Rega, MD,<sup>b</sup> Giancarlo Casolo, MD,<sup>b</sup> and Richard B. Devereux, MD<sup>c</sup> *Florence, Italy and New York, N.Y.*

**Two-dimensional (2D) echocardiographic and angiographic measurements of ventricular volumes are limited by geometric assumptions concerning cavity shape. We compared in vitro the accuracy of a three-dimensional (3D) echocardiographic system suitable for transthoracic imaging to magnetic resonance imaging (MRI) in the measurement of left and right ventricular volumes. Ventricular cast volumes from 14 excised formalin-fixed sheep hearts filled with an agarose solution were compared with data derived from 3D echocardiography and MRI. Left and right ventricular volumes from 3D echocardiographic reconstructions agreed well with actual volumes without significant underestimation or overestimation. MRI progressively underestimated left ventricular volumes as these increased and systematically underestimated right ventricular volumes. Our echocardiographic system designed for 3D transthoracic imaging combines excellent measurements of left and right ventricular volumes and the computed reconstruction of tomographic slices with the full spatial resolution of the original 2D images. Thus in this in vitro model, 3D echocardiography exhibited greater accuracy than MRI. (*Am Heart J* 1997; 133:221-9.)**

Accurate determination of left and right ventricular volumes provides important pathophysiologic and prognostic information in patients with a variety of cardiac disorders. For many years, angiography has been the clinical standard for determining left ventricular volume. Recently, magnetic resonance im-

aging (MRI) has been validated as an accurate technique for determining both left and right ventricular volumes in vivo.<sup>1,2</sup> However, the high cost, long examination time, and immobility of MRI instrumentation limit the extensive use of this technique in clinical practice.

Compared with these techniques, echocardiography has the advantages of lower cost, better portability, high temporal resolution, and no ionizing radiation. Echocardiography allows accurate estimation of heart dimensions,<sup>3</sup> even though the lateral resolution of ultrasound is limited compared with that of angiography and MRI. Similar to angiography, two-dimensional (2D) echocardiography relies on geometric assumptions for determining ventricular volumes and thus involves considerable measurement errors, especially for determining right ventricular volume.<sup>4,5</sup>

Three-dimensional (3D) echocardiography may avoid the need for geometric assumptions, thereby allowing accurate evaluation of cardiac chamber size and shape, even in cavities with irregular or distorted geometry. Different systems have been proposed to achieve 3D reconstruction of the beating heart from multiple 2D echocardiographic images with known spatial orientation, obtained with both transthoracic or transesophageal probes. For transthoracic probes, transducer locating systems have included a mechanical arm with position sensors,<sup>6-8</sup> an acoustic ranging device with three fixed microphones and spark gaps affixed to a freely movable ultrasound probe,<sup>9-12</sup> or an electromagnetic locator device.<sup>13</sup> Although these systems have been demon-

From <sup>a</sup>Institute of Gerontology and Geriatrics, University of Florence, <sup>b</sup>Department of Radiology, Azienda Ospedaliera Careggi, and <sup>c</sup>Department of Medicine, The New York Hospital-Cornell Medical Center.

Reprint requests: Riccardo Pini, MD, Institute of Gerontology, University of Florence, Via delle Oblate 4, 50141 Florence, Italy.

Copyright © 1997 by Mosby-Year Book, Inc.  
0002-8703/97/\$5.00 + 0 4/176864

strated to provide accurate measurements of ventricular volumes, they only preserve the same spatial resolution as the original 2D images, in a limited number of imaging planes rather than through the entire cardiac volume. In fact, these systems provide only "wire frame" reconstruction of the ventricular cavities of autonomic information in areas between individual wire loops. Moreover, the mechanical arm may limit transducer movements and acoustic ranging devices reduce instrument portability, thereby impairing bedside examination. Recently, 3D echocardiographic reconstruction of the heart has been obtained by transesophageal probes,<sup>14-16</sup> with excellent image quality and volume quantitation. Nevertheless, due to its semiinvasive nature, an echographic system for 3D reconstruction of the heart based on a transesophageal probe may not gain widespread clinical application.

To overcome the technical limitations of previously proposed transthoracic systems for 3D echocardiography, we developed a new system based on a transthoracic transducer rotating around its central axis.<sup>17, 18</sup> A study in 40 patients demonstrated that our system can be easily used in the clinical arena,<sup>19</sup> and preliminary data obtained from *in vitro* preparations of excised animal hearts showed that our system can accurately determine left ventricular volumes.<sup>20</sup> Moreover, our system reconstructs images that maintain the same spatial and temporal resolution as the original 2D images while fully preserving system portability. Thus the current study was undertaken to compare *in vitro* estimates of left and right ventricular volume by 3D echocardiography to anatomic volumes. MRI was performed to establish its relative accuracy in volume quantitation compared with 3D echocardiography under comparable conditions.

## METHODS

**3D echocardiographic system.** To perform the transthoracic 3D reconstruction of the heart by ultrasound, we developed an echocardiographic system based on a 3.5 MHz dynamically focused annular array transducer rotating 180 degrees around its central axis. The ultrasonic beam profile exhibited a regular shape along the entire depth used to visualize the heart, with a lateral resolution of 1.3 mm at -6 dB. This transducer allows the acquisition of 51 standard fan-shaped 2D echocardiograms at 3.6-degree increments of rotation. Because the rotation axis is in the center of the 2D fan, a transducer rotation of 180 degrees permits the 3D visualization of a solid cone encompassing the heart. Comparing the 0-degree (first 2D scanning plane) and the 180-degree (51st scanning plane) images provides an immediate check of the rotation axis stability during the recording; in fact, if the transducer

maintains the same relative position to the heart during the examination, the 0- and 180-degree images are mirror images. If the 0- and 180-degree images differ, the acquisition is repeated; less than 2 minutes is needed to acquire the new study.

The transducer is connected to an echocardiographic system (SIM 5000, ESAOTE Biomedica, Florence, Italy) modified by adding an electronic circuit that, with an 8086 personal computer, controls the acquisition process and displays the scanning plane number on the screen, where the 2D images are displayed in real time. The system allows one to select between probe rotation at either fixed time intervals (excised heart) or intervals triggered by the electrocardiogram (ECG) (beating heart). In this latter mode, an entire cardiac cycle is recorded from each transducer position and the subsequent cycle is used to rotate the transducer; thus the system acquires images over 100 cardiac cycles, or 60 to 100 seconds in normal sinus rhythm. To reduce artifacts derived from heart rate variability and arrhythmias, the system repeats the cardiac cycle acquisition if the actual R-R interval differs from the mean value by more than a percentage threshold selected by the operator. At the operator's option, the system can also be used to rotate the scanning plane without the check on heart rate stability (i.e., during an irregular rhythm such as atrial fibrillation). The echocardiograph displays the 2D images on the screen in real time and the same images are stored on 1/2-inch video tape at a television frame rate of 25 frame/sec.

The videotaped 2D echocardiographic images were digitized using a 80386 personal computer and a monitor with 768 × 576 pixel resolution and 256 gray levels with a frame grabber (GTI Freeland, Indianapolis, Ind.). Only the first 50 2D images (scanning planes 0 to 49) were digitized because the image at the 50th increment of rotation (180 degrees) was used exclusively to check rotation axis stability. For beating hearts, up to 1250 images (25 frames throughout a cardiac cycle in each of the 50 scanning planes) are used to reconstruct the 3D images.<sup>18</sup> For each frame in the cardiac cycle, the 50 images acquired in cylindrical coordinates are processed by an algorithm for linear interpolation to reconstruct a 3D cone of information in Cartesian coordinates. Because the 2D echocardiographic fan-shaped images occupied only the central area of the screen, the computer uses the central 256 × 576 pixels of the original images to reduce both the computational time and the disk space without losing important echocardiographic information. Thus each of the up to 25 successive 3D images can be stored in matrices of 256 × 256 × 576 pixels and 256 gray levels, preserving the spatial resolution of the original 2D images. Because the 50 images used to reconstruct each 3D matrix are acquired during 100 consecutive cardiac cycles, each 3D image represents an average image derived from multiple heart beats. From the 3D matrices stored in the computer, 2D echocardiographic images in any plane at specified times in the cardiac cycle, or throughout the cardiac cycle, can be derived and visualized. For this *in vitro* validation, only one 3D matrix of data was reconstructed for each left and right ventricle. In this

study, the spatial resolution varied from 0.29 to 0.44 mm/pixel. The accuracy of the 3D reconstruction and volume calculation algorithms was tested with a standard ultrasound phantom (RMI, model 412A, Middleton, Wis.) and with balloons and surgical gloves filled with water and immersed in a fish tank.<sup>21</sup>

**Excised heart preparation.** Fourteen freshly excised sheep hearts were prepared by sewing shut one of the two venae cavae and three of the four pulmonary veins, to leave only one open vessel in each atrium. Pulmonary artery and aorta were left open to purge air. The hearts were fixed in formalin for 48 hours with pressure expansion to avoid chamber collapse; a pressure of 25 to 30 mm Hg was used to expand the left and right cavities. To obtain the ventricular casts, the heart cavities were filled with a heated 5% solution of agarose in water. After solidification of agarose with cooling, two wooden toothpicks were inserted orthogonally through the left and right sides of the heart at the level of the atrioventricular groove to mark a common reference plane for the 3D echocardiographic and MRI studies.

**Echocardiographic image acquisition and volume calculation.** Echocardiographic studies were performed with the excised hearts suspended and immersed in a fish tank filled with water. For each heart, two complete rotations of the imaging plane were performed to encompass the left and the right ventricles.

From the 3D volume images of the left and right ventricles reconstructed from the nonparallel images, up to 49 parallel tomographic planes were derived beginning parallel to the mitral or tricuspid valve plane, respectively, and extending to the ventricular apex in the short-axis orientation with 256 × 576 pixel resolution. With the current computer hardware and software, reconstruction of each 3D matrix and the subsequent selection of the short-axis tomographic planes required about 45 minutes. Slice thickness varied from 1.15 to 1.77 mm. The images were calibrated for distance and the volume (in cubic millimeters) of each voxel was calculated. For each short-axis image, three independent observers who did not know the actual volumes manually traced the endocardial border with a mouse connected to the frame grabber. To test intraobserver variability, the same slices were manually traced twice by one observer 10 days apart. The ventricular volumes were defined as the sum of the volumes of the individual slices derived from the 3D reconstruction of each ventricle.

From each series of manually traced endocardial borders, a 3D perspective image of the ventricular cavity was visualized by use of commercially available software for ray tracing<sup>22</sup> customized for our specific application. With this software the user can visualize the left and right ventricular cavities with any spatial orientation to compare the 3D reconstruction with the actual ventricular casts.

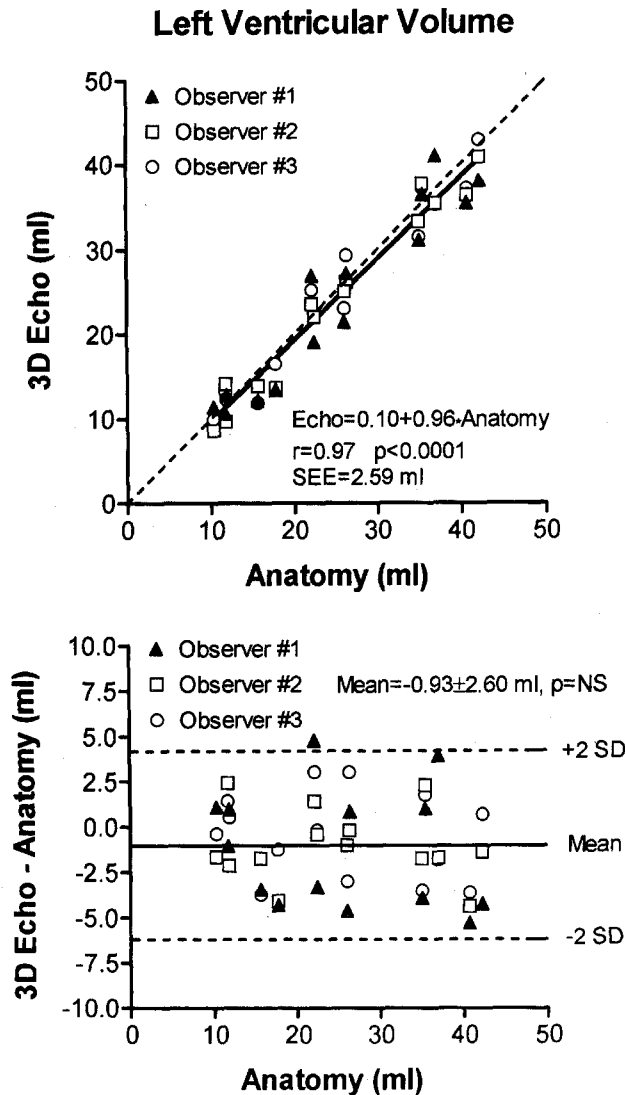
**MRI acquisition and volume calculation.** MRI was performed using a 0.5 Tesla commercially available system (Philips Gyroscan, Eindhoven, The Netherlands). The excised hearts were positioned inside the magnet and imaged with the head probe. We used a gradient echo imaging

technique without ECG gating and with the following parameters: alpha = 60 degrees, TE = 12 msec, TR = 21 msec, slice thickness = 5 mm, 256 × 256 matrix, field of view = 190 mm, two measurements. In a preliminary study, these parameters were found to provide optimal contrast between the left and right ventricular cavities and walls. After an initial localizing scan, the hearts were imaged in the short-axis plane. We used only one imaging plane to study both the left and the right ventricular cavities. The slices of the left and right ventricles were contiguous with no space in between. The calibration of the MRI system was verified by imaging test objects with known shape and volume.

The left and right ventricular cavities of the excised hearts were readily recognized because of the high contrast achieved with the imaging parameters. Image resolution was 0.7 × 5 mm. Up to 21 contiguous slices were necessary to cover both ventricles. The ventricles were easily differentiated from the atria because of the different wall thicknesses. The atrioventricular planes were also recognized because of the presence of the two orthogonal toothpicks, which appeared as "cross-shaped void streaks" in the MRI images; the slices with the atrioventricular planes were considered as part of the ventricular cavities. Left and right ventricular volumes were calculated simply by adding the left and right cavity volumes of each individual slice. These values were obtained by multiplying the slice thickness by the endocardial areas of the two chambers that were traced manually with the trackball of the MRI console.

**Anatomic volume calculation.** After imaging of the excised hearts, the left and right atrial myocardium was incised and carefully peeled off. After the atrioventricular planes were identified, the atrial casts were separated from the corresponding ventricular casts, the reference toothpicks being included in the ventricular cavities. Then the ventricular myocardium was incised and carefully peeled off the ventricular casts. The actual volumes of the ventricular casts were measured by water displacement in a graduated beaker. The actual anatomic volumes, calculated as the mean value of three repeated measurements, ranged from 10.3 to 42.2 ml for the left ventricles and from 38.3 to 77.6 ml for the right ventricles.

**Statistical analysis.** Values are expressed as mean ± SD. The accuracy of the ventricular volumes derived from the 3D echocardiographic reconstructions and MRI was examined by simple linear regression analysis or linear regression analysis with replication. Regression lines and line of identity were compared according to the method proposed by Zar.<sup>23</sup> The method of Bland and Altman<sup>24</sup> was used to determine differences between methods and to assess whether differences were systematically related to ventricular size. The bias, or systematic error, of each method was also expressed as a percentage of the anatomic volume (Percent error = [Measured volume - True volume] × 100/True volume), and the mean ± SD percent bias was calculated for each method. The mean percent biases were compared by nonparametric analysis of variance (Kruskal-Wallis statistic) and by the nonparametric Mann-



**Fig. 1.** Top, Correlation between left ventricular volumes derived from 3D echocardiographic reconstruction and anatomic values. The linear regression line (solid line) for pooled data of three independent observers was statistically equal to the line of identity (dotted line). Bottom, Bland-Altman data analysis of left ventricular volumes derived from 3D echocardiographic reconstruction. No systematic underestimation or overestimation was found.

Whitney U statistic. The imprecision, or random error, was defined as the absolute difference between the anatomic volume derived from the regression line equation calculated for each method and the true anatomic volume; imprecision was expressed as the percentage of the anatomic volume. The mean ± SD percent imprecisions were also compared by use of the Kruskal-Wallis statistic. Interobserver variability was expressed as the mean of the absolute differences between the measurements of the three observers and was examined by two-way analysis of variance. Intraobserver variability was expressed as the mean of the absolute differences between the two repeated mea-

**Table I.** Linear correlation between three-dimensional echocardiographic and true anatomic left ventricular volumes for the three independent observers

Observer	r	Regression equation	SEE (ml)
First	0.98*	$LV_{Echo} = -0.39 + 0.97 * LV_{Anat}$	2.09
Second	0.95*	$LV_{Echo} = 0.17 + 0.94 * LV_{Anat}$	3.41
Third	0.98*	$LV_{Echo} = 0.52 + 0.96 * LV_{Anat}$	2.44

SEE, Standard error of the estimate; LV, left ventricle; Echo, echocardiography; Anat, anatomy.

\*p < 0.001.

surements and was examined by Student t test. A p value < 0.05 was accepted as significant.

**RESULTS**

**3D echocardiography.** The reconstruction of the left ventricular cavities derived from the 3D echocardiographic data sets accurately reproduced the shape of the actual casts. Left ventricular volumes derived from 3D reconstructions agreed well with actual volumes. The correlation between measured and true left ventricular volumes was also excellent for the individual observers (Table I); the slopes and intercepts of the three individual regression lines were statistically equal to the line of identity, with a standard error of the estimate (SEE) ranging from 2.09 to 3.41 ml. Similarly, linear regression analysis for the pooled data of the three observers gave a regression equation of: left ventricular volume determined by 3D echocardiography = 0.10 + 0.96 \* anatomic left ventricular volume (r = 0.97, p < 0.0001, SEE = 2.59 ml), with no statistically significant difference from the line of identity (Fig. 1, top). 3D echocardiography did not systematically underestimate or overestimate the left ventricular volumes (-0.93 ± 2.60 ml, t = -1.58, p = not significant [NS]) (Fig. 1, bottom), with a percent bias of -3.7% ± 11.8% that remained constant over the range of explored anatomic volumes. The imprecision was 9.8% ± 7.2%. The intraobserver variability for the left ventricular volumes was 1.32 ml or 5.2% of the mean (t = 0.30; p = NS); the interobserver variability was 2.07 ml or 8.2% of the mean (F = 0.67; p = NS).

The correlation between measured and true right ventricular volumes was excellent for the individual observers (Table II); the slopes and intercepts of the three individual regression lines did not differ statistically from the line of identity, with an SEE ranging from 2.55 to 4.23 ml. Linear regression analysis for the pooled data of the three observers showed an excellent correlation between the true right ventricular volumes and the measures derived from 3D echocardiographic reconstructions; the re-

**Table II.** Linear correlation between 3D echocardiographic and true anatomic right ventricular volumes for the three independent observers

Observer	<i>r</i>	Regression equation	SEE (ml)
First	0.97*	$RV_{Echo} = 3.63 + 0.93 * RV_{Anat}$	2.55
Second	0.95*	$RV_{Echo} = -4.16 + 1.08 * RV_{Anat}$	4.01
Third	0.94*	$RV_{Echo} = -3.81 + 1.07 * RV_{Anat}$	4.23

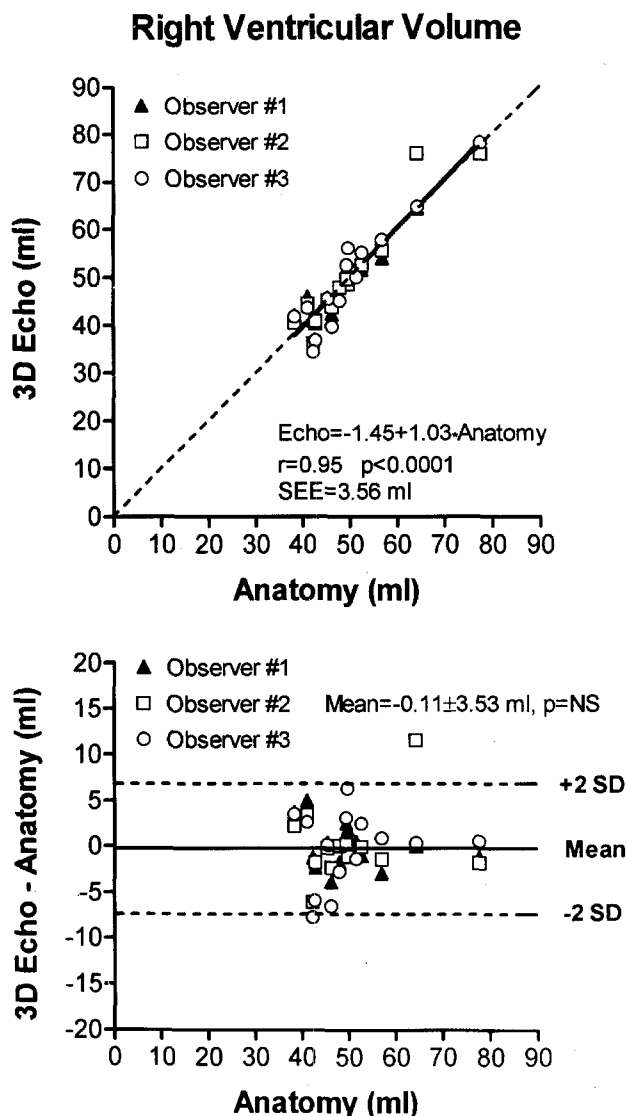
RV, Right ventricle. Other abbreviations as in Table I.

gression equation was: right ventricular volume determined by 3D echocardiography =  $-1.45 + 1.03 * \text{anatomic right ventricular volume}$  ( $r = 0.95$ ;  $p < 0.0001$ ;  $SEE = 3.56$  ml) (Fig. 2, top). The mean systematic error of 3D echocardiography in the estimate of right ventricular volumes did not differ statistically from zero ( $-0.11 \pm 3.53$  ml,  $t = -0.20$ ,  $p = NS$ ;  $-0.3\% \pm 7.4\%$ ) and no significant correlation existed between the bias and the true volumes (Fig. 2, bottom). The imprecision was  $5.2\% \pm 4.3\%$ . The intraobserver variability for the right ventricular volumes was 2.4 ml or 4.8% of the mean ( $t = 0.41$ ;  $p = NS$ ); the interobserver variability was 2.64 ml or 5.2% of the mean ( $F = 0.09$ ;  $p = NS$ ).

**MRI.** Measurements derived from MRI images correlated well with the true volumes for both the left ventricle (left ventricular volume as determined by MRI =  $2.39 + 0.87 * \text{anatomic left ventricular volume}$ ;  $r = 0.98$ ;  $p < 0.0001$ ;  $SEE = 2.22$  ml) (Fig. 3, top) and the right ventricle (right ventricular volume as determined by MRI =  $0.31 + 0.95 * \text{anatomic right ventricular volume}$ ;  $r = 0.98$ ;  $p < 0.0001$ ;  $SEE = 2.34$  ml) (Fig. 4, top). However, the two regression lines differed significantly from the line of identity. In fact, the regression line for the left ventricular volumes had a slope significantly different from one ( $F = 5.76$ ;  $p < 0.05$ ), and the regression line for the right ventricle was parallel to but below the line of identity ( $F = 8.41$ ;  $p < 0.01$ ). The mean systematic error of MRI in the estimate of left ventricular volumes did not differ statistically from zero ( $0.96 \pm 2.60$  ml;  $t = -1.39$ ;  $p = NS$ ;  $-2.2\% \pm 8.4\%$ ), but the bias correlated significantly with the true volumes ( $r = -0.57$ ;  $p < 0.05$ ) (Fig. 3, bottom). MRI systematically underestimated the right ventricular volumes ( $-1.79 \pm 2.29$  ml;  $t = -2.93$ ;  $p < 0.02$ ;  $-3.5\% \pm 4.6\%$ ) with no significant correlation between the bias and the true volumes ( $r = 0.19$ ;  $p = NS$ ) (Fig. 4, bottom). The imprecision was  $7.1\% \pm 5.0\%$  and  $3.6\% \pm 2.9\%$  for the left and the right ventricular cavities, respectively.

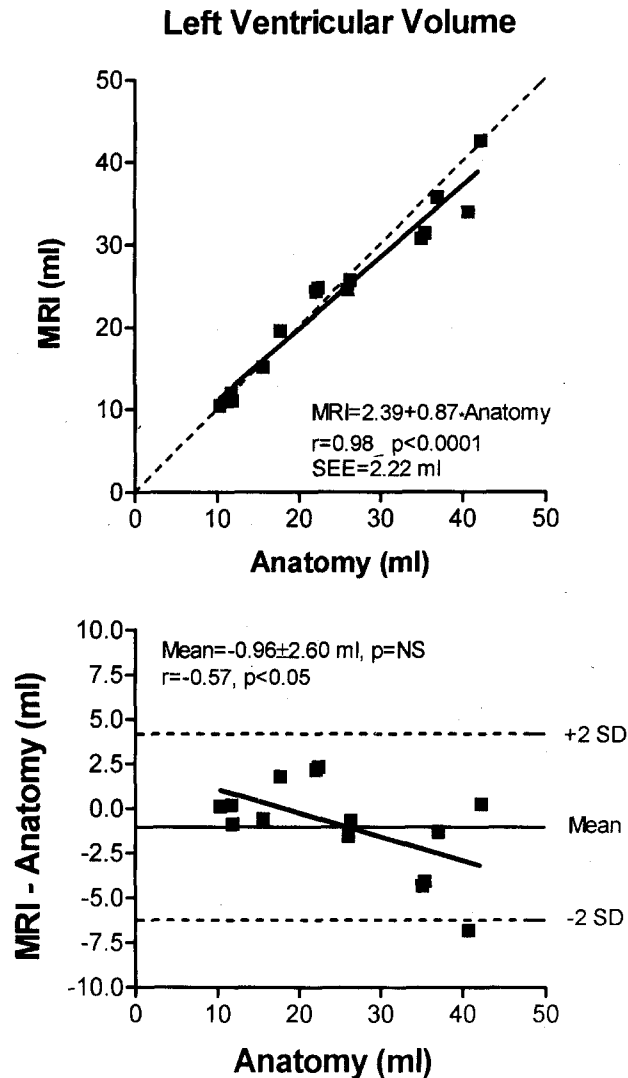
**DISCUSSION**

The present in vitro study demonstrated that our 3D echocardiographic system based on a transtho-



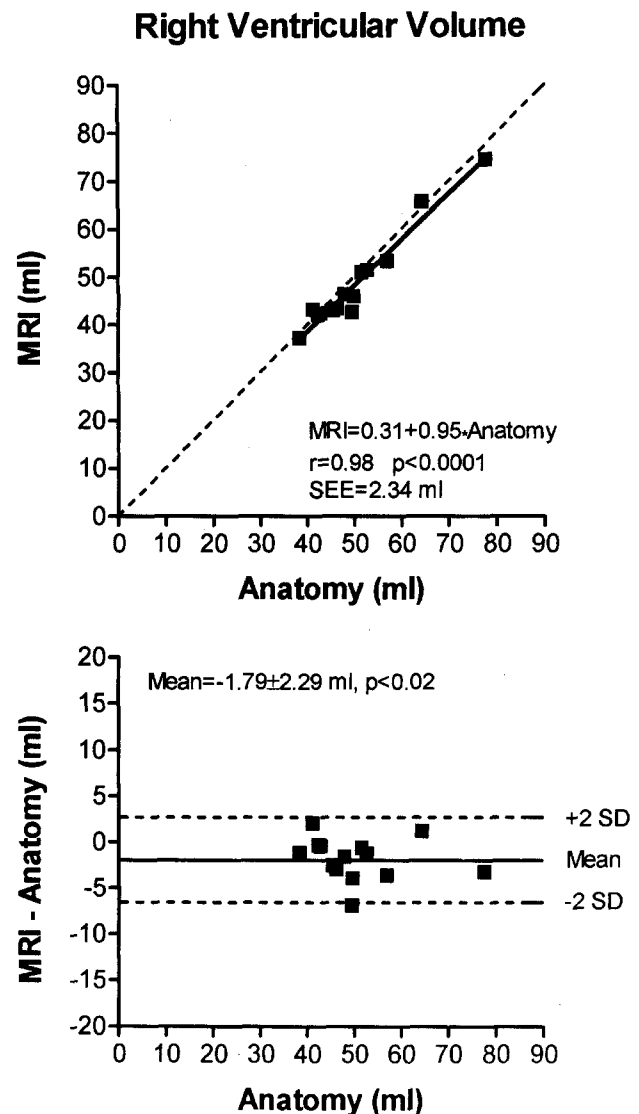
**Fig. 2. Top,** Correlation between right ventricular volumes derived from 3D echocardiographic reconstruction and anatomic values. The linear regression line (solid line) for pooled data of three independent observers was statistically equal to the line of identity (dotted line). **Bottom,** Bland-Altman data analysis of right ventricular volumes derived from 3D echocardiographic reconstruction. No systematic underestimation or overestimation was found.

racic rotating transducer allows for excellent measurements of left and right ventricular volumes of excised hearts. Interestingly, no substantial overestimate or underestimate by 3D echocardiography was detected, even for the trabeculated, irregularly shaped right ventricle. Indeed, the SEE was similarly low for both left and right ventricles. Compared with MRI, 3D echocardiography exhibited a similarly small mean systematic error for both left ( $-3.7\%$  vs  $-2.2\%$ ;  $p = NS$ ) and right ( $-0.3\%$  vs  $-3.5\%$ ;  $p = NS$ )



**Fig. 3. Top**, Correlation between left ventricular volumes derived from magnetic resonance imaging (MRI) and anatomic values. The slope of the linear regression line (*solid line*) was statistically different from the slope of the line of identity (*dotted line*). **Bottom**, Bland-Altman data analysis demonstrated that MRI bias was greater at larger volumes.

ventricular volumes. However, although 3D echocardiography accurately estimated both left and right ventricular volumes without any significant bias, MRI systematically underestimated the right ventricular volumes. Our results are in agreement with previous work<sup>8, 10, 11</sup> and demonstrate that our system maintains the same accuracy for cavities with an irregular shape such as the right ventricle, for which volume estimation from 2D echocardiographic images involves greater error.<sup>25, 26</sup> In particular, the SEE and the bias obtained in our series of



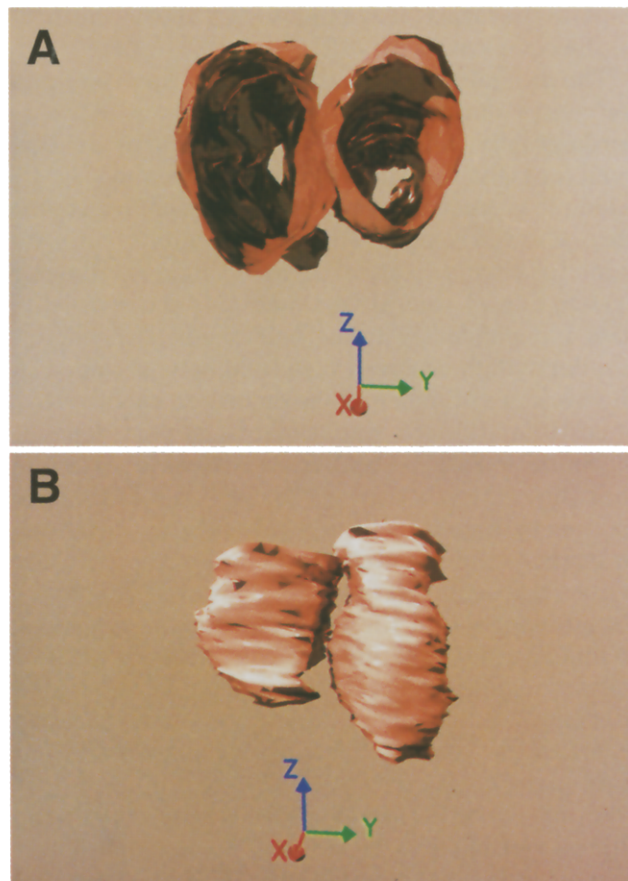
**Fig. 4. Top**, Correlation between right ventricular volumes derived from magnetic resonance imaging (MRI) and anatomic values. The intercept of the linear regression line (*solid line*) was statistically different from the intercept of the line of identity (*dotted line*). **Bottom**, Bland-Altman data analysis demonstrated that MRI consistently underestimated the anatomic volumes.

left ventricles were similar to the values reported by Handshumacher et al.<sup>10</sup> with a larger range of ventricular volumes. Of note, our results were obtained with intact hearts, whereas Handshumacher et al.<sup>10</sup> removed the atria and the right ventricular free wall before acquiring the echocardiographic images; thus our experimental design is more similar to the clinical setting. For the right ventricular volumes, our results are similar to those obtained by Jiang et al.,<sup>26</sup> even though those investigators acquired echocardiographic images directly from ventricular casts af-

ter removing them from the right ventricular cavities.

**Comparison with other 3D transthoracic echocardiographic systems.** Compared with probes connected to mechanical arms<sup>6-8</sup> or to an acoustic ranging device,<sup>9-12</sup> our 3D system based on a rotating transducer has the advantage of fully preserving both freedom of transducer movements and portability of the echographic instrumentation. A recently developed electromagnetic locator device allows for free movements of the transducer and maintains portability<sup>13</sup>; unfortunately, it requires the absence of metallic objects in the examining area. Moreover, the rotational probe we developed allows the reconstruction of 3D matrices with the same spatial and temporal resolution as the original 2D images (Fig. 5), whereas with the previously mentioned probes only wire frame models of the ventricular cavities can be obtained. Because our probe rotates with angular increments narrower than the transducer's lateral resolution, the 2D tomographic images derived from the reconstructed 3D matrices are visually indistinguishable from the standard 2D images. This ability to derive tomographic sections with any spatial orientation and with the same visual characteristics as the original 2D images allows the selection of planes correctly oriented even in patients with nonstandard acoustic windows. As demonstrated in a previous clinical series of 40 patients,<sup>19</sup> our system is easily applicable to a majority of subjects. Moreover, our 3D system requires a short acquisition time (<2 minutes) and allows an immediate check of the technical quality of the study. In fact, immediately at the end of the acquisition, the operator can compare the first (0-degree rotation) and the last (180-degree rotation) tomographic sections to verify the transducer stability before the 3D matrices are reconstructed.

**Comparison with other in vitro studies with MRI.** Volume measurements by MRI were previously reported to be highly accurate in both left and right ventricular casts.<sup>27-29</sup> However, Markiewicz et al.<sup>29</sup> found that MRI underestimated left and right ventricular output measured by thermodilution. In our study, left and right ventricular volumes measured by MRI correlated closely with the true volumes, but MRI underestimated right ventricular volumes. This underestimation could be partially explained because the MRI slice thickness (5 mm) could be relatively high for irregularly shaped cavities such as the right ventricle. In fact, MRI reveals on the screen a cavity that corresponds to the smallest area obtained by superimposing the cavity areas at the two extreme sides of each tomographic slice. Thus if the cavity shape changes considerably in two sections 5



**Fig. 5.** Three-dimensional perspective image of left (*right side*) and right (*left side*) ventricular cavities derived from manually traced endocardial borders. Ventricular cavities were seen from atrioventricular plane (**A**) and from anterior wall (**B**). Reference axis length = 1 cm.

mm apart, the MRI would tend to underestimate the true cavity area. Finally, the higher accuracy of 3D echocardiography compared with MRI cannot be explained by the fact that three independent observers measured the echocardiographic volumes whereas only one observer measured the MRI volumes. In fact, each of the three regression lines calculated from the echocardiographic data of the individual observers for each ventricle was statistically equal to the line of identity, whereas the regression line based on the MRI data differed statistically from the line of identity for both left and right ventricular volumes.

**Study limitations and future applications.** The 2D tomographic images, derived from the 3D echocardiographic matrices, maintained not only the same spatial resolution as the original 2D images, but also the dropouts that may be present in the original echocardiograms. Therefore the definition of the endocardial border is sometimes suboptimal, which can

explain the larger SEE exhibited by 3D echocardiography compared with MRI.

The animal hearts we used did not have any major ventricular shape distortion. However, 3D echocardiography exhibited accurate volume estimation even for right ventricles that cannot be modeled by a simple geometric formula and whose tomographic slices showed complex shapes. Preliminary data obtained *in vitro* with atrial cavities confirmed that our system allows accurate estimation of the heart cavities independently from their geometric shape.<sup>30</sup> Similarly high accuracy could likely be obtained in the presence of major shape distortion such as that of postinfarction left ventricular aneurysm. A possible limitation of this study could be related to the fact that the right ventricles were distended during the fixation with a relatively high pressure, which tended to increase their ventricular volumes and partially reduce trabecular irregularity. However, this hypothetical reduction of the right ventricular geometric complexity did not improve the accuracy of MRI measurements, and preliminary data demonstrated that our 3D echocardiographic system can accurately measure the volume of irregularly shaped left and right atrial cavities.<sup>30</sup>

Although our 3D system is easily applicable in the clinical setting, greater variability can be predicted *in vivo* because of subjects' varied disease states and differences in body habitus. In fact, the relative position of the heart with respect to the transducer might change with breathing, and respiratory gating would increase the acquisition time. With the current computer hardware and software configuration, the reconstruction of each 3D volume matrix takes 45 minutes of computer time. This time can be reduced by more than 75% by use of a personal computer with more random-access memory (RAM) and a faster processor. However, the entire process of reconstructing the 3D volume images and selecting the tomographic planes is totally automatic and, therefore, no user interaction is needed. Currently, the manual tracing of the endocardial border represents the most time-consuming step for the user: in fact, up to 25 minutes are required to complete the contouring of all sections needed to measure a ventricular volume (e.g., end diastolic or end systolic), depending on the observer's skill, the number of tomographic sections (average of 33 images for the left ventricle and 37 images for the right ventricle), and the technical quality of the tomographic slices. This time could be reduced by the development of new algorithms for semiautomatic border detection that use the 3D data set to fill in gaps sometimes present in the original 2D images.<sup>31</sup>

In conclusion, our 3D transthoracic echocardiographic system combines excellent measurement of ventricular volumes with the computed reconstruction of 3D volume images that maintain the same spatial and temporal resolution as the original 2D images without cumbersome external reference systems.

#### REFERENCES

- Sechtem U, Pflugfelder PW, Gould RG, Cassidy MM, Higgins CB. Measurement of right and left ventricular volumes in healthy individuals with cine MR imaging. *Radiology* 1987;163:697-702.
- Pattynama PMT, De Roos A, Van der Wall EE, Van Voorthuisen AE. Evaluation of cardiac function with magnetic resonance imaging. *Am Heart J* 1994;128:595-607.
- Pini R, Ferrucci L, Di Bari M, Greppi B, Cerofolini M, Masotti L, et al. Two-dimensional echocardiographic imaging: *in vitro* comparison of conventional and dynamically focused annular array transducers. *Ultrasound Med Biol* 1987;13:643-50.
- Bommer W, Weinert L, Neumann A, Neef J, Mason DT, DeMaria A. Determination of right atrial and right ventricular size by two-dimensional echocardiography. *Circulation* 1979;60:91-100.
- Ninomiya K, Duncan WJ, Cook DH, Olley PM, Rowe RD. Right ventricular ejection fraction and volumes after Mustard repair: correlation of two-dimensional echocardiograms and cineangiograms. *Am J Cardiol* 1981;48:317-24.
- Skorton DJ, Chandran KB, Nikravesh PE, Pandian NG, Kerber RE. Three-dimensional finite element reconstructions from two-dimensional echocardiograms for estimation of myocardial elastic properties. *Comput Cardiol* 1981, 383-6.
- Geiser EA, Christie LG, Conetta DA, Conti R, Grossman GS. A mechanical arm for spatial registration of two-dimensional echocardiographic sections. *Cathet Cardiovasc Diagn* 1982;8:89-101.
- Sawada H, Fujii J, Kato K, Onoe M, Kuno Y. Three dimensional reconstruction of the left ventricle from multiple cross sectional echocardiograms. Value for measuring left ventricular volume. *Br Heart J* 1983; 50:438-42.
- Moritz WE, Pearlman AS, McCabe DH, Medema DK, Ainsworth ME, Boles MS. An ultrasonic technique for imaging the ventricle in three dimensions and calculating its volume. *IEEE Trans Biomed Eng* 1983;30:482-91.
- Handschumacher MD, Lethor JP, Siu SC, Mele D, Rivera M, Picard MH, et al. A new integrated system for three-dimensional echocardiographic reconstruction: development and validation for ventricular volume with application in human subjects. *J Am Coll Cardiol* 1993;21:743-53.
- Sapin PM, Schroeder KD, Smith MD, DeMaria AN, King DL. Three-dimensional echocardiographic measurement of left ventricular volume *in vitro*: comparison with two-dimensional echocardiography and cineventriculography. *J Am Coll Cardiol* 1993;22:1530-7.
- Siu SC, Rivera M, Guerrero JL, Handschumacher MD, Lethor JP, Weyman AE, et al. Three-dimensional echocardiography. *In vivo* validation for left ventricular volume and function. *Circulation* 1993; 88:1715-23.
- Handschumacher MD, Jiang L, Lee MY, Williams MJA, Svizzero T, Levine RA. Accuracy of three-dimensional echocardiographic reconstruction by electromagnetic positional location: *in vivo* validation for right ventricular volume [abstract]. *Circulation* 1994;90:I-338.
- Flachskampf FA, Verlande RH, Schneider W, Ameling W, Hanrath P. Initial experience with a multiplane transesophageal echo-transducer: assessment of diagnostic potential. *Eur Heart J* 1992;13:1201-6.
- Martin RW, Bashein G, Nessly ML, Sheehan FH. Methodology for three-dimensional reconstruction of the left ventricle from transesophageal echocardiograms. *Ultrasound Med Biol* 1993;19:27-38.
- Wang XF, Li ZA, Cheng TO, Deng YB, Zheng LH, Hu G, et al. Clinical application of three-dimensional transesophageal echocardiography. *Am Heart J* 1994;128:380-8.
- Pini R, Mommini E, Masotti L, Greppi B, Cerofolini M, Devereux RB.

- Echocardiographic computed tomography of the heart: preliminary results [abstract]. *J Am Coll Cardiol* 1989;13:224A.
18. Pini R, Costi M, Mensah GA, Masotti L, Novins KL, Greenberg DP, et al. Computed tomography of the heart by ultrasound. *Comput Cardiol* 1991, 17-20.
  19. Katz AS, Wallerson DC, Pini R, Devereux RB. Visually determined long- and short-axis parasternal views and four- and two-chamber apical echocardiographic views do not consistently represent paired orthogonal projections. *Am J Noninvas Cardiol* 1993;7:65-70.
  20. Pini R, Giannazzo G, Di Bari M, Innocenti F, Devereux RB. Three-dimensional echocardiography: in vitro validation of left ventricular volumes [abstract]. *J Am Coll Cardiol* 1994;23:310A.
  21. Mensah GA, Pini R, Monnini E, Masotti L, Novins KL, Greenberg DP, et al. Three dimensional echocardiographic reconstruction: experimental validation of volume measurement [abstract]. *J Am Coll Cardiol* 1991;17:291A.
  22. Watkins CD, Coy SB, Finlay R. Photorealism and ray tracing in C. San Mateo, Calif: M & T Publishing, 1992.
  23. Zar JH. Biostatistical analysis, 2nd ed. Englewood Cliffs, NJ: Prentice-Hall, 1984:292.
  24. Bland JM, Altman DG. Statistical methods for assessing agreement between two methods of clinical measurement. *Lancet* 1986;1:307-10.
  25. Levine RA, Gibson TC, Aretz T, Gillam LD, Guyer DE, King ME, et al. Echocardiographic measurement of right ventricular volume. *Circulation* 1984;69:497-505.
  26. Jiang L, Handschumacher MD, Hibberd MG, Siu SC, King MA, Weyman AE, et al. Three-dimensional echocardiographic reconstruction of right ventricular volume: in vitro comparison with two-dimensional methods. *J Am Soc Echocardiogr* 1994;7:150-8.
  27. Longmore DB, Underwood SR, Hounsfield GN, Bland C, Poole-Wilson PA, Denison D, et al. Dimensional accuracy of magnetic resonance in studies of the heart. *Lancet* 1985;1:1360-2.
  28. Rehr RB, Malloy CR, Filipchuk NG, Peshock RM. Left ventricular volumes measured by MR imaging. *Radiology* 1985;156:717-9.
  29. Markiewicz W, Sechtem U, Kirby R, Derugin N, Caputo GC, Higgins CB. Measurement of ventricular volumes in the dog by nuclear magnetic resonance. *J Am Coll Cardiol* 1987;10:170-7.
  30. Pini R, Gianazzo G, Di Bari R, Innocenti F, Devereux RB. Three-dimensional echocardiography: in vitro validation of left and right atrial volumes [abstract]. *Circulation* 1995;92:I-799.
  31. Picard MH, Bosch HG, Morrissey RL, Reiber JHC. Automated echocardiographic ventricular volume quantitation: validation of a new border detection method [abstract]. *Circulation* 1994;90:I-608.