



UNIVERSITÀ  
DEGLI STUDI  
FIRENZE

## FLORE

# Repository istituzionale dell'Università degli Studi di Firenze

### **Rest Technetium-99m sestamibi tomography in combination with short-term administration of nitrates: feasibility and reliability for**

Questa è la Versione finale referata (Post print/Accepted manuscript) della seguente pubblicazione:

*Original Citation:*

Rest Technetium-99m sestamibi tomography in combination with short-term administration of nitrates: feasibility and reliability for prediction of postrevascularization outcome of asynergic territories / BISI G.; R. SCIAGRA'; SANTORO G.M.; FAZZINI P.F.. - In: JOURNAL OF THE AMERICAN COLLEGE OF CARDIOLOGY. - ISSN 0735-1097. - STAMPA. - 24:(1994), pp. 1282-1289.

*Availability:*

The webpage <https://hdl.handle.net/2158/222302> of the repository was last updated on

*Publisher:*

Attuale:ELSEVIER SCIENCE INC, 360 PARK AVE SOUTH, NEW YORK, USA, NY, 10010-1710 W B Saunders

*Terms of use:*

Open Access

La pubblicazione è resa disponibile sotto le norme e i termini della licenza di deposito, secondo quanto stabilito dalla Policy per l'accesso aperto dell'Università degli Studi di Firenze (<https://www.sba.unifi.it/upload/policy-oa-2016-1.pdf>)

*Publisher copyright claim:*

La data sopra indicata si riferisce all'ultimo aggiornamento della scheda del Repository FloRe - The above-mentioned date refers to the last update of the record in the Institutional Repository FloRe

(Article begins on next page)

## Rest Technetium-99m Sestamibi Tomography in Combination With Short-Term Administration of Nitrates: Feasibility and Reliability for Prediction of Postrevascularization Outcome of Asynergic Territories

GIANNI BISI, MD, ROBERTO SCIAGRÀ, MD, GIOVANNI M. SANTORO, MD,\*  
PIER FILIPPO FAZZINI, MD\*

Florence, Italy

**Objectives.** This study investigated the role of nitrate technetium-99m sestamibi imaging in predicting the postrevascularization outcome of chronically hypoperfused asynergic territories.

**Background.** Rest technetium-99m sestamibi myocardial scintigraphy underestimates the presence of viable myocardium in asynergic territories. Stimulation that improves coronary blood flow could increase tracer uptake in hibernating territories.

**Methods.** Nineteen patients with a previous myocardial infarction and left ventricular dysfunction scheduled for revascularization underwent quantitative technetium-99m sestamibi tomography under baseline conditions and during isosorbide dinitrate infusion. Global and regional function were assessed, respectively, before and after revascularization by radionuclide angiography and two-dimensional echocardiography.

**Results.** Seven patients (group A) showed postrevascularization regional function recovery, and 12 (group B) showed no significant changes. In group A, nitrate infusion induced a decrease in the extent of the global uptake defect [(mean  $\pm$  SD)  $-37.4 \pm$

21.6% of baseline value]; in group B, no change or a slight increase was observed ( $+5.8 \pm 8.4\%$ ,  $p < 0.0005$  vs. group A). The nitrate-induced changes in the extent of uptake defect correlated with postrevascularization changes in ejection fraction ( $r = -0.94$ , SEE 7.6). After revascularization, 11 asynergic vascular territories showed improvement (hibernating), and 34 remained unchanged (fibrotic). With administration of nitrates, 10 hibernating territories had a decrease in the extent of uptake defect, whereas only 4 of 34 of the fibrotic territories showed a nitrate-induced uptake improvement.

**Conclusions.** Short-term administration of isosorbide dinitrate immediately before injection of technetium-99m sestamibi increases tracer uptake in some chronically hypoperfused asynergic territories. This finding correlates with the observation of postrevascularization functional recovery. Nitrate technetium-99m sestamibi myocardial scintigraphy could be a promising method for the noninvasive detection of viable hibernating myocardium.

(*J Am Coll Cardiol* 1994;24:1282-9)

In patients with chronic coronary artery disease and left ventricular dysfunction the detection of viable hibernating myocardium in asynergic territories is important for predicting their functional outcome after revascularization (1,2). The recognition of a significant postrevascularization functional improvement in asynergic territories is the true reference standard for establishing the presence of hibernating myocardium. Therefore, it is also the most reliable way to test the accuracy of diagnostic methods used to evaluate myocardial viability. At present, the detection of an intact glucose metabolism in hypoperfused areas (perfusion/metabolism mismatch) by positron emission tomography is considered the most reliable imaging method for assessing myocardial viability

(3-5). However, the most widely used method is the observation of thallium-201 uptake using late redistribution or rest injection imaging (6-11). Although both methods are effective, they have important limitations. Positron emission tomography is expensive and confined to relatively few laboratories. Thallium-201 is not as reliable as positron emission tomography, mainly because of false negative results (4,5).

Several experimental studies (12-21) have demonstrated that the features of technetium-99m sestamibi are favorable for its use as a viability tracer. However, other reports (22-27) have suggested that in humans, rest technetium-99m sestamibi underestimates the extent of viable myocardium compared with positron emission tomography and thallium-201 imaging. More specifically, two studies (26,27) have suggested that segments with abnormally low technetium-99m sestamibi uptake may recover function after revascularization. However, taking technetium-99m kinetics into account, it is conceivable that interventions capable of increasing coronary flow during the tracer uptake could improve its detection of viable myocardium. Several reports (28-38) indicate that short-term nitrate administration increases coronary flow by means of

From the Nuclear Medicine Unit, Department of Clinical Pathophysiology, University of Florence and \*Division of Cardiology, Careggi Hospital, Florence, Italy.

Manuscript received November 10, 1993; revised manuscript received May 9, 1994; accepted June 2, 1994.

Address for correspondence: Dr. Gianni Bisi, Nuclear Medicine Unit, Department of Clinical Pathophysiology, University of Florence, Viale Morgagni 85, 50134 Florence, Italy.

different mechanisms. It has been also demonstrated (39,40) that nitroglycerin increases thallium-201 uptake in hypoperfused territories.

Therefore, this study was undertaken 1) to verify whether the short-term administration of isosorbide dinitrate could improve technetium-99m sestamibi uptake in hypoperfused territories; and 2) to test whether this improvement could be used for the detection of hibernating myocardium.

## Methods

**Patients.** The study group included 20 patients (18 men, 2 women; mean  $\pm$ SD age  $56.6 \pm 7.9$  years, range 44 to 71) with a history of previous myocardial infarction ( $\geq 3$  months), angiographically documented coronary artery disease, left ventricular wall motion abnormality and left ventricular ejection fraction  $< 50\%$ . No patient had unstable angina in the 3 months before the study. Patients with cardiac conditions other than coronary artery disease or those who had already undergone revascularization procedures were excluded. All patients had been scheduled for a revascularization procedure on the basis of their clinical condition, independently of the execution and the results of technetium-99m sestamibi imaging.

**Study protocol.** All patients suspended nitrate therapy for at least 48 h before the beginning of the study. All other therapies were continued, and the condition of the patients remained unchanged until the study was completed. The protocol included the execution of two-dimensional echocardiography to assess regional wall motion and two technetium-99m sestamibi studies, one at baseline conditions and the other after short-term administration of isosorbide dinitrate. During technetium-99m sestamibi injection for baseline scintigraphy, first-pass radionuclide angiocardigraphy was acquired to estimate global left ventricular function. The two perfusion studies were performed in random sequence, 24 h apart, after overnight fasting. All patients underwent coronary angiography within 2 weeks of the scintigraphic studies. Global and regional left ventricular function were again assessed with first-pass radionuclide angiocardigraphy and two-dimensional echocardiography, respectively, at least 3 months after the execution of coronary artery bypass grafting or at least 1 month after coronary angioplasty. All patients gave informed consent to participate in the study. The study protocol was approved by the ethics committee of our institution.

**Coronary angiography.** Selective coronary angiography was performed using the Judkins or Sones technique. Cineangiograms were evaluated on the basis of the agreement of two observers who had no knowledge of the clinical and scintigraphic data. Lesions that reduced lumen diameter  $> 50\%$  were considered significant. Collateral circulation was assessed and scored in four grades (collateral index) from 0 = none to 3 = complete filling of the epicardial vessel through collateral flow (38,41).

**Echocardiography.** Two-dimensional echocardiography was performed using an Aloka SSD-870 echocardiograph with 2.5- to 3.5-MHz transducers. Parasternal long-axis, parasternal

short-axis at basal and midventricular levels and apical two- and four-chamber views were obtained and recorded on videotape. The left ventricle was divided into 13 segments (42); six segments (anteroseptal, anterior, anterolateral, posterolateral, posteromedial, posteroseptal) were evaluated both at a basal and midventricular level in addition to a single apical segment. Seven segments were attributed to the left anterior descending coronary, two to the left circumflex coronary artery and four to the right coronary artery.

Regional wall motion was visually analyzed by two independent observers who had no knowledge of clinical, angiographic and scintigraphic findings. The following scoring system was used: 1 = normal; 2 = hypokinesia (clearly reduced systolic wall thickening and inward motion); 3 = akinesia (absence of systolic wall thickening and motion); 4 = dyskinesia (systolic wall thinning and outward motion). A segment was classified as asynergic if at least 50% of its total area exhibited abnormal wall motion. The wall motion index was calculated for each vascular territory as the sum of the scores of all the included segments divided by the number of segments (43). Discrepancies between the two observers were resolved by consensus.

**First-pass radionuclide angiocardigraphy.** First-pass radionuclide angiocardigraphy was acquired in the 30° right anterior oblique projection with the patient supine, using an Elscint Apex SP4 gamma camera equipped with a low energy all-purpose collimator and using a 20% window centered at the 140-keV photopeak of technetium-99m. Twenty-five millicuries (925 MBq) of technetium-99m sestamibi was injected through an indwelling cannula inserted into an antecubital vein of the right arm, followed by a booster flush of 20 ml of saline solution. The study was acquired in frame mode, using a  $\times 2$  zoom factor and an electrocardiographic gating. Left ventricular ejection fraction was calculated twice from the background-subtracted time-activity curve. The difference between the two measurements never exceeded two ejection fraction units, and the mean value was used for the data analysis.

**Nitrate test.** Ten milligrams of isosorbide dinitrate diluted in 100 ml of isotonic saline solution was administered over 20 min. Heart rate and blood pressure were controlled throughout the whole test. Technetium-99m sestamibi was injected after 15 min of infusion or earlier if there was a decrease in systolic blood pressure  $> 20$  mm Hg. Perfusion tomography was performed, as described next.

**Technetium-99m sestamibi scintigraphy.** The technetium-99m sestamibi dose was 25 mCi (925 MBq) for both baseline and the nitrate studies, and was injected while the patient was supine. Single-photon emission computed tomographic collection was performed 60 min later using an Elscint Apex SP4 gamma camera equipped with an ultra-high resolution collimator with a 20% window centered at the 140-keV photopeak of technetium-99m. The gamma camera head rotated in step and shoot mode over a 180° arc from the 45° right anterior oblique to the 45° left posterior oblique view, with 60 projections of 20 s each. Images were collected with a  $\times 1.4$  zoom factor and stored on  $64 \times 64$  matrices. Image reconstruction was performed using backprojection without a preprocessing

filter and with a Wiener reconstruction filter (dumping factor 1, full-width half-maximum 8 mm). No attenuation or scatter correction was used. The transaxial slices were realigned along the heart axis.

For the quantitative evaluation of the tomographic images, the short-axis slices were used (44). Their count profiles were generated by computer software and plotted onto a two-dimensional polar map. The count profile of each study was compared with a gender-specific data base of rest technetium-99m sestamibi studies performed in normal control subjects. The lower limit of the normal range was set at 2.5 SD below the mean value of the gender-specific control group (44). The extent of the abnormally low uptake was first expressed as a percent of the entire left ventricular wall. The quantitative polar map was then divided into three territories corresponding to the distribution of the coronary arteries. A separate analysis was performed for each territory, and to be considered significant, a defect had to be >12% of the left anterior descending and left circumflex coronary artery territories and >8% of the right coronary artery territory (45). Finally, the baseline and nitrate studies were directly compared, and the changes in both global and individual coronary perfusion defects were expressed as a percent of the extent of the defect at baseline.

**Follow-up evaluation.** To determine the extent of revascularization, regional left ventricular function was evaluated. An asynergic vascular territory was considered to be improved when the wall motion score index decreased >22% after revascularization compared with the prevascularization value (43). The vascular territories that showed a reduction in wall motion score index after revascularization were considered to be *hibernating*; territories that exhibited no changes were defined as *fibrotic*. On this basis patients were classified in two groups: group A, patients with postrevascularization regional (in at least one asynergic territory) functional recovery; group B, patients without recovery.

**Statistical analysis.** Results are expressed as mean value  $\pm$  SD. The nonparametric analysis of variance (Kruskal-Wallis one-way analysis by ranks) was used for the intragroup and intergroup data comparison. The comparison of proportions was made using the Fisher exact test. The relation between the changes induced by the nitrate test and the results of the revascularization procedures was analyzed using linear regression and the Spearman rank correlation coefficient. A probability value  $p < 0.05$  was considered significant.

## Results

**Patients.** One patient presented with a perioperative infarction and hence was excluded from any further data analysis. Data analysis includes the findings in 19 patients (Table 1). The presenting symptoms were effort angina and effort dyspnea in 13 patients, effort angina in 3 and effort dyspnea in 3. According to coronary angiography, 3 patients had one-vessel, 5 had two-vessel and 11 had three-vessel coronary artery disease. Of the 46 territories supplied by stenotic arteries, 24

**Table 1.** Demographic and Angiographic Data of the 19 Study Patients

Pt No./ Gender	Age (yr)	Infarct Site	LVEF	LAD (%)	LCx (%)	RCA (%)
1/F	62	Ant	47	100	90	75
2/M	52	Ant + Inf	34	95	100	100
3/M	56	Ant	49	100	75	100
4/M	44	Ant	30	90	50	100
5/M	61	Ant	29	100	0	0
6/M	48	Ant	23	100	75	100
7/M	50	Ant + Inf	46	100	90	100
8/M	71	Inf	40	90	0	100
9/M	59	Ant + Inf	26	0	75	100
10/M	59	Inf	25	90	99	90
11/M	56	Inf	30	95	50	90
12/F	69	Inf	27	90	90	90
13/M	64	Inf	48	90	75	90
14/M	61	Ant + Inf	19	100	0	100
15/M	47	Inf	32	90	0	75
16/M	56	Ant	48	100	0	0
17/M	54	Inf	49	50	75	100
18/M	49	Ant	34	90	50	0
19/M	47	Inf	35	0	90	0

Ant = anterior; F = female; Inf = inferior; LAD = left anterior descending coronary artery; LCx = left circumflex coronary artery; LVEF = left ventricular ejection fraction; M = male; Pt = patient; RCA = right coronary artery.

had no angiographically identifiable collateral circulation, and 6, 11 and 5 had collateral indexes of 1, 2 and 3, respectively.

Abnormal wall motion was identified in 45 vascular territories. Twenty-three of the 45 were the site of a previous infarction; the remaining 22 fulfilled the aforementioned involvement criteria but included mainly asynergic segments immediately contiguous to the infarcted ones. Nonetheless, 17 of these 22 noninfarcted asynergic areas were also supplied by critically stenotic coronary arteries. The prevascularization mean wall motion score index of the abnormal territories was  $2.3 \pm 0.6$ . The prevascularization mean left ventricular resting ejection fraction was  $35.3 \pm 10\%$ .

**Follow-up findings.** Complete revascularization was obtained using multiple coronary artery bypass grafting in 15 patients and coronary angioplasty of all stenosed vessels in 4.

The postrevascularization mean left ventricular rest ejection fraction was  $35.4 \pm 11\%$  ( $p = \text{NS}$  vs. prevascularization). The postrevascularization mean wall motion score index of the abnormal territories was  $2.2 \pm 0.7$  ( $p = \text{NS}$  vs. prevascularization). Of the 45 asynergic vascular territories demonstrated before revascularization, 11 showed a reduction in wall motion score index after intervention (from  $2.2 \pm 0.4$  to  $1.5 \pm 0.3$ ,  $p < 0.002$ ) and were considered to have been hibernating, whereas 34 showed no changes ( $2.4 \pm 0.6$  both before and after revascularization) and were classified as fibrotic. All 11 hibernating territories were found in 7 patients (at least one hibernating territory in each of them) who were classified as group A; these 7 patients also showed an ejection fraction improvement. Of the 34 fibrotic vascular territories, 4 were found in the group A patients and the remaining 30 in the

**Table 2. Comparison of Demographic, Clinical, Functional and Angiographic Data of the Two Study Groups**

	Group A (n = 7)	Group B (n = 12)	p Value
Age (yr)	53.3 ± 6.7	57.7 ± 7.9	NS
Infarct age (mo)	37.8 ± 44.3	70 ± 64.1	NS
CAD (no. of diseased vessels)	2.7 ± 0.8	2.3 ± 0.8	NS
Presenting symptoms			
Effort dyspnea and angina	6	7	NS
Effort dyspnea	1	2	NS
Effort angina	0	3	NS
Collateral score	3 ± 1.15	2 ± 1.47	NS
LVEF (%)	36.8 ± 10.4	34.4 ± 9.9	NS
WMSI	2.2 ± 0.3	2.4 ± 0.3	NS

Data presented are mean value ± SD or number of patients. CAD = coronary artery disease; LVEF = left ventricular ejection fraction; WMSI = wall motion score index (mean value for each patient).

other 12 patients who were classified as group B; none of them showed an ejection fraction improvement. Table 2 shows the comparison between the preoperative variables of the two groups, which were not statistically different in terms of demographic, clinical, angiographic or functional variables.

The 11 hibernating territories were not significantly different from the fibrotic ones with regard to preoperative wall motion score index (2.2 ± 0.3 vs. 2.4 ± 0.3) or collateral score (1.36 ± 1.02 vs. 0.82 ± 1.11). On the contrary, the mean degree of obstruction of the related coronary artery was greater in the 11 hibernating than in the 34 fibrotic vascular territories (91.8 ± 15.8% vs. 74.2 ± 36.4%, p < 0.05).

After revascularization, groups A and B were significantly different in terms of left ventricular global ejection fraction

(group A 43.4 ± 9.4%, group B 30.8 ± 8.4%, p < 0.02) as well as mean wall motion score index (group A 1.7 ± 0.3, group B 2.4 ± 0.3, p < 0.005). In all patients the revascularization procedure led to the disappearance of the preexisting anginal symptoms, but only group A patients also had a subjective improvement in their effort dyspnea.

**Baseline myocardial perfusion scintigraphy.** Table 3 summarizes the results of the baseline perfusion study performed before revascularization. In the 19 patients analyzed, the mean global extent of the abnormally perfused territories was 31.1 ± 15.4% of the left ventricular wall. No significant difference was found in the global extent of baseline perfusion defect between the patients in group A (30.8 ± 12.2%) and those in group B (31.3 ± 17.5%). The site and the extent of the perfusion defects confirmed both angiographic and echocardiographic findings. No significant perfusion defect was observed in normokinetic areas. The mean baseline extent of defect in the 11 hibernating areas was not significantly different from that of the 34 fibrotic territories (31.3 ± 21.2% vs. 46.8 ± 33.3%).

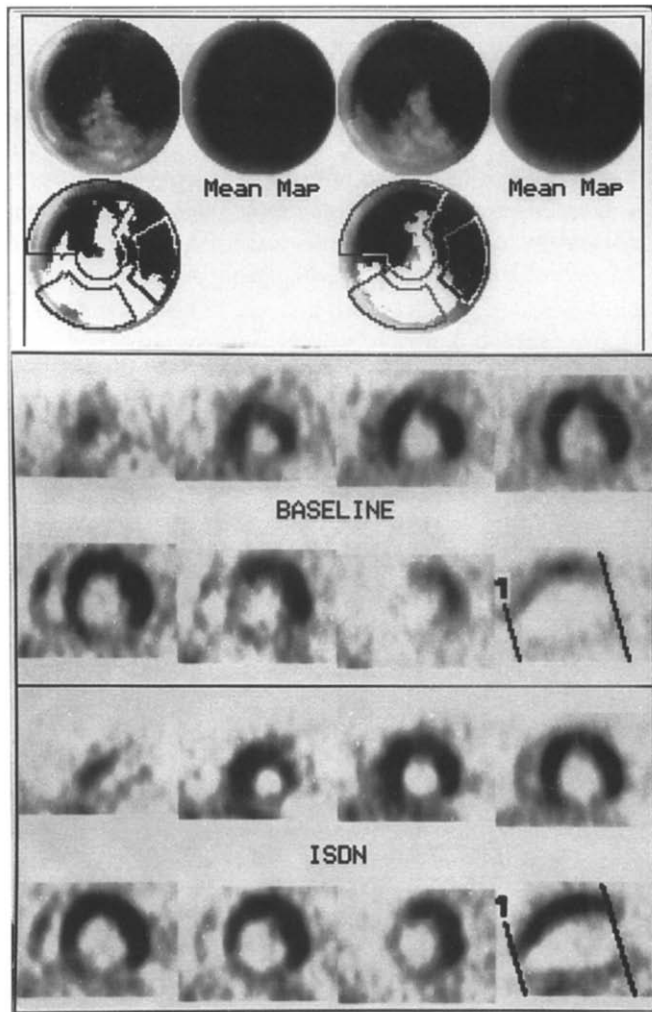
**Nitrate myocardial perfusion scintigraphy.** The isosorbide dinitrate infusion was performed in all patients without adverse reaction. Technetium-99m sestamibi was injected after 15 min in 15 patients; in another 4, the injection was anticipated because the systolic blood pressure decreased >20 mm Hg. Two examples of baseline and nitrate myocardial scintigraphic results are shown in Figures 1 and 2. The results of nitrate perfusion imaging in the individual patients are shown in Table 3.

In all of the patients, the mean extent of the global perfusion defects in the nitrate technetium-99m sestamibi images was 28.1 ± 15.5% of the left ventricular wall (p = NS vs. baseline). However a recognizable decrease (ranging

**Table 3. Results of Technetium-99m Sestamibi Imaging**

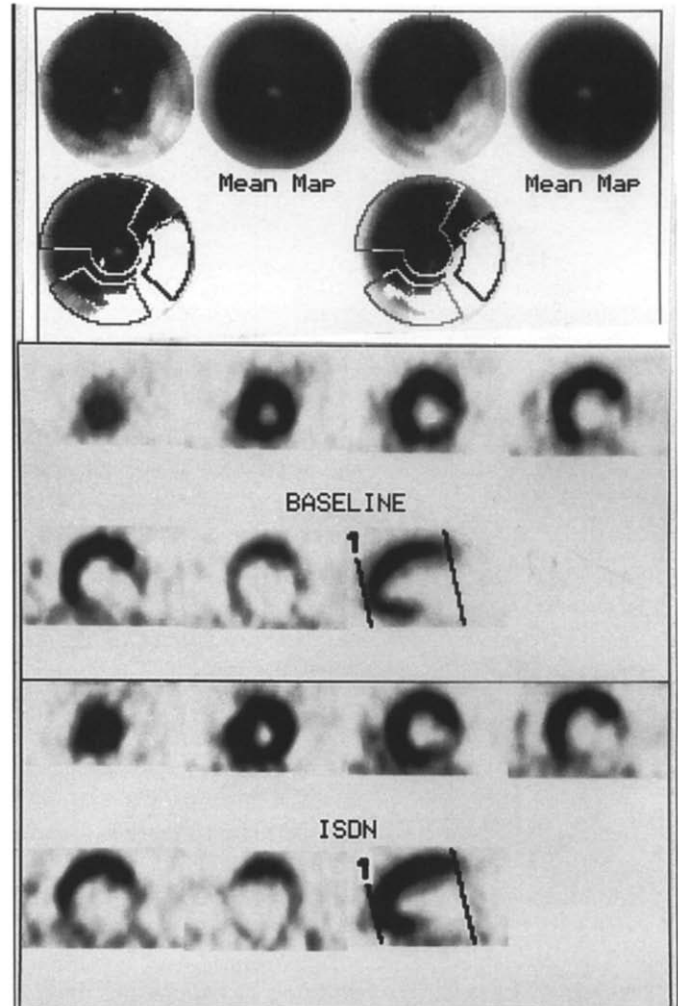
Pt No.	Total Extent		LAD Extent		LCx Extent		RCA Extent	
	Baseline	ISDN	Baseline	ISDN	Baseline	ISDN	Baseline	ISDN
1	32.4	27.8	57.6	50.1	3.5	0.7	0	0
2	35.1	22.7	36.4	27.6	6.8	3.6	48.7	24.8
3	15.2	9.2	17.5	4.6	1.3	0.1	14.8	24.9
4	45	31.8	42.8	24.4	18.7	14.6	76	73.9
5	37.3	26.8	65.7	52.9	2	0	0	0
6	12.4	2.1	12.2	2.1	12.6	0	9.3	0
7	38	25.7	56.4	34.1	0	0	43.5	41.3
8	14.5	13.9	2.3	5.2	0	0.4	73	57.4
9	18	18.4	1	1	19.8	7.2	66.3	67.3
10	52.9	53.1	38.6	38.7	73.6	77.7	95	94.1
11	38.4	41.8	25.9	27.7	64.8	63.9	35.4	53.8
12	36.1	37	6.9	9.2	55.8	57.4	94.6	96.4
13	15.7	18.5	2.3	1.5	2.4	8.2	68.6	72.5
14	69.1	65.6	82.8	78.5	14.4	6.7	90	91
15	27.9	30	3.6	3.4	88.6	91.1	54.7	65.4
16	11.2	13.9	22.6	25.5	0	0	0	0
17	27.1	29.4	1.2	1.5	56.5	57.5	84.4	88.4
18	43.6	44.9	79.1	78.3	0.6	0.5	0.2	2
19	21	20.9	0	0	88.3	88.3	34.4	33.8

Extent is expressed in percent of the entire left ventricular wall (= total extent) and the individual coronary artery territories. ISDN = isosorbide dinitrate; other abbreviations as in Table 1.



**Figure 1.** Technetium-99m sestamibi images from Patient 4. **Upper panel,** polar map displays. **Top left map** represents myocardial count distribution under baseline conditions, ranging from higher counts (in black) to lower counts (in light gray). **Lower left map** shows (in white) the regions with activity  $>2.5$  SD below the mean value of normal data base (Mean Map); on the right are the same displays of the study performed during isosorbide dinitrate infusion. **Middle and lower panels,** short-axis slices of the baseline and isosorbide dinitrate (ISDN) studies, respectively. A clear reduction in abnormal territories can be observed from apex (1) to base, as shown in lower left images (midventricular vertical long-axis slice).

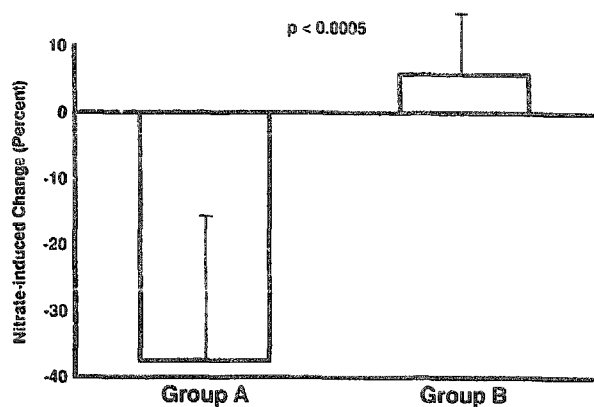
from 4% to 83%) was observed in nine patients, seven of whom were in group A. In group A patients, the mean extent of global perfusion defect decreased (from  $30.8 \pm 12.2\%$  to  $20.9 \pm 11\%$ ,  $p = 0.06$ ). However, in the remaining 10 patients, all of whom were in group B, there was a slight worsening of the extent of the defect in the nitrate images. Thus, in group B in its entirety, the global extent of the uptake defect was not significantly modified in the nitrate images ( $32.3 \pm 16.5\%$  vs. baseline  $31.3 \pm 17.5\%$ ,  $p = \text{NS}$ ). The difference in extent of perfusion changes (expressed as percent of the baseline value) induced by the nitrate test in the two groups was significant (group A,  $-37.4 \pm 21.6\%$  vs. group B,  $+5.8 \pm 8.4\%$ ,  $p < 0.0005$ ) (Fig. 3). The changes in global extent of the perfusion



**Figure 2.** Technetium-99m sestamibi images from Patient 19. Same image disposition as in Figure 1. The lack of any change in the isosorbide dinitrate (ISDN) study compared with that at baseline can be readily appreciated.

defect induced by the nitrate test and the changes in global ejection fraction after revascularization appeared to be correlated (Pearson  $r = -0.94$ , SEE 7.6,  $p < 0.000001$ ; Spearman rank correlation coefficient  $-0.9$ ,  $p < 0.0001$ ) (Fig. 4).

A significant decrease in the extent of the single-area perfusion defect after nitrate administration was observed in 14 territories; 10 territories were among the 11 hibernating. In the remaining four territories, postoperative wall motion score index remained unchanged. One territory with no reduction in extent of perfusion defect during the nitrate test had a postoperative improvement in wall motion. In the 11 hibernating territories, the baseline extent of the perfusion defect decreased to  $21.4 \pm 19.1\%$  with nitrate imaging. In the 34 fibrotic territories, the mean extent of the uptake defect was not influenced by nitrate administration ( $46.6 \pm 33.8\%$ ). Thus, with nitrate imaging, the mean extent of the perfusion defect in the hibernating territories was significantly smaller than that in the fibrotic ones ( $21.4 \pm 19.1\%$  vs.  $46.6 \pm 33.8\%$ ,  $p < 0.05$ ).



**Figure 3.** Bar graph showing the percent change ( $\pm$ SD) in the baseline value of the total extent of perfusion defect on technetium-99m sestamibi images induced by isosorbide dinitrate in both group A and B patients.

### Discussion

The study was designed to test whether the short-term administration of nitrates could influence the rest uptake of technetium-99m sestamibi by hypoperfused asynergic territories and whether this could be useful in the detection of viable hibernating myocardium. The study rationale was twofold. First, the favorable influence of nitrates on coronary blood flow, particularly in the case of short-term administration, has been previously exploited in the evaluation of asynergic or hypoperfused territories (36,39,40,46,47). Second, most experimental data support the use of technetium-99m sestamibi in the detection of viable hibernating myocardium (12-21).

**Nitrate effects on coronary blood flow.** Regional blood supply may be enhanced by the administration of sublingual or intravenous nitrates, especially in areas of reduced coronary flow (28,30). It has been demonstrated (31-33) that nitroglycerin and isosorbide dinitrate dilate ~70% of significant coronary stenoses. In both experimental and human studies

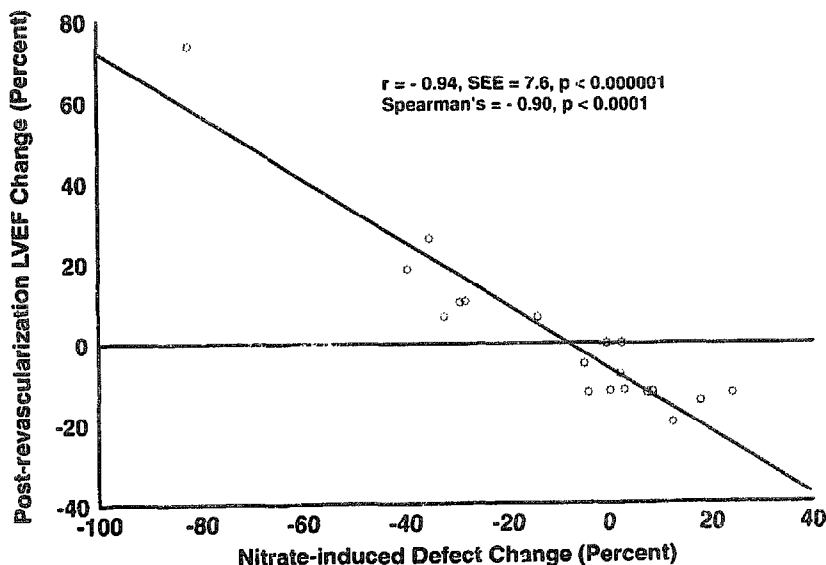
(29-35) on chronic coronary occlusions, nitroglycerin and isosorbide dinitrate dilated coronary collateral vessels and improved collateral blood flow to hypoperfused areas. The reduction in thallium-201 perfusion defect size after nitroglycerin administration in patients with coronary occlusion and a noninfarcted totally collateral-dependent myocardial region was explained by the improvement in coronary collateral function (37).

**Nitrate administration to study myocardial viability.** The estimate of contractile reserve in hypokinetic or akinetic left ventricular regions after short-term nitrate administration was used to identify viable myocardium (46,47). The functional improvement after nitroglycerin administration has been related to the hemodynamic effect of cardiac deloading as well as to the enhancement of regional myocardial blood flow (47). In this context, collateral circulation also has a role (36). Recently, nitrate administration has been used in conjunction with thallium-201 myocardial scintigraphy to improve the detection of viable myocardium (39,40). These preliminary reports indicate that nitroglycerin administration before thallium-201 reinjection could enhance its uptake in areas with apparently fixed perfusion defects.

**Technetium-99m sestamibi as viability tracer.** Previous studies in experimental animals (12,14,16) have shown that myocardial uptake of technetium-99m sestamibi is mainly related to coronary blood flow. However, cell membrane integrity and cellular viability have been shown to be necessary conditions for technetium-99m sestamibi uptake and retention (13,16,18,20). Furthermore, infarcted myocardium has been shown to be unable to extract the tracer (17). In a model of reperfusion after prolonged occlusion, Sinusas et al. (19) demonstrated a significantly lower technetium-99m sestamibi uptake compared with microsphere reperfusion flow; this reflected the decrease in viable tissue. Similar data were reported by Freeman et al. (21).

All these data suggest that technetium-99m sestamibi could

**Figure 4.** Correlation between the nitrate-induced change (percent of baseline value) in the total extent of perfusion and the postrevascularization change (percent of the prevascularization value) in left ventricular ejection fraction (LVEF).



be an excellent viability tracer. However, the results of the few available human studies were rather disappointing. Rocco et al. (22) found that regions with a severe reduction in tracer uptake at rest may still contain viable myocardium, as shown by the persistence of wall motion. Using positron emission tomographic metabolic imaging, Althoefer et al. (23) demonstrated a partially or even totally preserved glucose metabolism in half of the regions with rest technetium-99m sestamibi perfusion defects. Cuocolo et al. (24) found a significant thallium-201 uptake in regions with decreased technetium-99m sestamibi activity. Dondi et al. (25) showed that a 3-h delayed study after thallium-201 rest injection detected a higher number of reversible defects than rest technetium-99m sestamibi imaging. Finally, Marzullo et al. (26) demonstrated that segments with an abnormally low preoperative rest technetium-99m sestamibi uptake had a functional recovery after revascularization and that the rate of false necrotic segments was higher using technetium-99m sestamibi than using thallium-201 late redistribution images (27).

**Nitrate technetium-99m sestamibi imaging.** According to our results, isosorbide dinitrate infusion induced an increase in technetium-99m sestamibi uptake in part of the baseline hypoperfused territories, whereas in the majority, no nitrate-induced change could be demonstrated. A clear relation seems to be present between the detection of an increased tracer uptake in nitrate imaging and the recognition of functional recovery after revascularization. The patients were allocated to two groups according to postrevascularization outcome. With the exception of the results of technetium-99m sestamibi imaging after isosorbide dinitrate, none of the variables examined could have distinguished between the two groups preoperatively.

Moreover, analysis of the vascular territory data supports the relation between postrevascularization recovery and the decrease in extent of the perfusion defect in technetium-99m sestamibi nitrate imaging. The two groups of vascular territories (those with postrevascularization improvement that include hibernating tissue and those with unchanged regional function with mainly fibrotic tissue) were not significantly different in terms of prevascularization wall motion score index, collateral score index and extent of baseline technetium-99m sestamibi perfusion defect. On the contrary, the two groups of vascular territories were differentiated preoperatively by the response to the nitrate test. The degree of related vessel obstruction was significantly higher in the territories with postoperative improvement. This is not surprising because a marked decrease in coronary blood flow is the rule in the case of hibernating myocardium (1,2), whereas the absence of technetium-99m sestamibi uptake in asynergic territories not related to severely stenosed vessels is more likely explained by the presence of fibrotic tissue (19,21).

**Limitations of the study.** The small patient group is the most important limitation of the study. However, this limitation is shared by most of the studies (22,24-27) dealing with the detection of viable hibernating myocardium using technetium-99m sestamibi. The strict selection criteria of the

patients also meant that the study cohort mainly included subjects with severe wall motion abnormalities and diffuse coronary artery disease. Therefore, studies in a more balanced patient population are needed to define the clinical impact of technetium-99m sestamibi nitrate imaging. With regard to the quantitative evaluation of the tomographic images, we compared the count profiles of the baseline and nitrate studies with those of a data base of normal subjects that did not include patients with ventricular asynergy or dilation. Nevertheless, this should not have influenced the reliability of the present study because both baseline and nitrate images were compared with the same normal reference, and only relative changes in tracer uptake were considered. Another limitation of the present study is that the results of technetium-99m sestamibi nitrate scintigraphy were not compared with the other imaging methods currently used to detect viable hibernating myocardium. Therefore, it is not possible to define the relative reliability of technetium-99m sestamibi nitrate imaging and positron emission tomography or thallium-201 late redistribution or rest injection protocols.

**Conclusions.** This study demonstrates that short-term isosorbide dinitrate administration enhances the uptake of technetium-99m sestamibi in some severely hypoperfused territories. More specifically, the detection of an improved uptake in a hypoperfused territory appears to be related to postrevascularization functional recovery. This supports the hypothesis that such territories include viable hibernating myocardium. This study suggests that technetium-99m sestamibi nitrate imaging is clinically useful for the preoperative detection of viable myocardium as well as the prediction of postrevascularization outcome in asynergic areas. Further studies are warranted to define the value of technetium-99m sestamibi nitrate imaging and its role in the management of patients with chronic coronary artery disease and left ventricular dysfunction.

---

We thank Raffaele Giubbini, MD, and Orazio Zoccarato, MS, of the Nuclear Medicine Laboratory of the Brescia Civic Hospital, Brescia, Italy, for providing the data base of normal control subjects.

---

## References

1. Braunwald E, Rutherford JD. Reversible left ventricular dysfunction: evidence for the "hibernating myocardium." *J Am Coll Cardiol* 1986;8:1467-70.
2. Rahimtoola SH. The hibernating myocardium. *Am Heart J* 1988;117:211-21.
3. Tillisch JH, Brunken R, Marshall R, et al. Reversibility of cardiac wall motion abnormalities predicted by positron tomography. *N Engl J Med* 1986;314:884-8.
4. Brunken RC, Schwaiger M, Grover-McKay M, Phelps ME, Tillisch J, Schelbert HR. Positron emission tomography detects tissue metabolic activity in myocardial segments with persistent thallium perfusion defects. *J Am Coll Cardiol* 1987;10:557-67.
5. Tamaki N, Ohtani H, Yamashita K, et al. Metabolic activity in the areas of new fill-in after thallium-201 reinjection: comparison with positron emission tomography using fluorine-18 deoxyglucose. *J Nucl Med* 1991;32:673-8.
6. Iskandrian AS, Hakki A, Kane SA, et al. Rest and redistribution thallium-201 myocardial scintigraphy to predict improvement in left ventricular function after coronary artery bypass grafting. *Am J Cardiol* 1983;51:1312-6.
7. Cloninger KG, DePuey EG, Garcia EV, et al. Incomplete redistribution in delayed thallium-201 single photon emission computed tomographic

- (SPECT) images: an overestimation of myocardial scarring. *J Am Coll Cardiol* 1988;12:955-63.
8. Kiat H, Berman DS, Maddahi J, et al. Late reversibility of tomographic myocardial thallium-201 defects: an accurate marker of myocardial viability. *J Am Coll Cardiol* 1988;12:1456-63.
  9. Dilsizian V, Rocco TP, Freedman NM, Leon MB, Bonow RO. Enhanced detection of ischemic but viable myocardium by the reinjection of thallium after stress-redistribution imaging. *N Engl J Med* 1990;323:141-6.
  10. Ohtani H, Tamaki N, Yonekura Y, et al. Value of thallium-201 reinjection after delayed SPECT imaging for predicting reversible ischemia after coronary artery grafting. *Am J Cardiol* 1990;66:394-9.
  11. Bonow RO, Dilsizian V, Cuocolo A, Bacharach SL. Identification of viable myocardium in patients with chronic coronary artery disease and left ventricular dysfunction. Comparison of thallium scintigraphy with reinjection and PET imaging with <sup>18</sup>F-fluorodeoxyglucose. *Circulation* 1991;83:26-37.
  12. Okada RD, Glover D, Gaffney T, Williams S. Myocardial kinetics of technetium-99m-hexakis-2-methoxy-2-methylpropyl-isonitrile. *Circulation* 1988;77:491-8.
  13. Maublant JC, Gachon P, Moins N. Hexakis(2-methoxy isobutyl)isonitrile technetium-99m and thallium-201 chloride: uptake and release in cultured myocardial cells. *J Nucl Med* 1988;29:38-54.
  14. Li Q-S, Frank TL, Franceschi D, Wagner HN Jr, Becker LC. Technetium-99m methoxyisobutyl isonitrile (RP30) for quantification of myocardial ischemia and reperfusion in dogs. *J Nucl Med* 1988;29:153-48.
  15. Sinusas AJ, Watson DD, Cannon JM Jr, Beller GA. Effect of ischemia and postischemic dysfunction on myocardial uptake of technetium-99m-labeled methoxyisobutyl isonitrile and thallium-201. *J Am Coll Cardiol* 1989;14:1785-93.
  16. Meerding DJ, Leppo JA. Comparison of hypoxia and ouabain effects on the myocardial uptake kinetics of technetium-99m hexakis 2-methoxy-isobutyl isonitrile and thallium-201. *J Nucl Med* 1989;30:1500-6.
  17. Canby RC, Silber S, Pohost GM. Relations of the myocardial imaging agents <sup>99m</sup>Tc-MIBI and <sup>201</sup>Tl to myocardial blood flow in a canine model of myocardial ischemic insult. *Circulation* 1990;81:289-96.
  18. Piwnicka-Worms D, Kronauge JF, Chiu ML. Uptake and retention of hexakis(2-methoxyisobutyl isonitrile) technetium(I) in cultured chick myocardial cells. Mitochondrial and plasma membrane potential dependence. *Circulation* 1990;82:1826-38.
  19. Sinusas AJ, Trautman KA, Bergin JD, et al. Quantification of area at risk during coronary occlusion and degree of myocardial salvage after reperfusion with technetium-99m methoxyisobutyl isonitrile. *Circulation* 1990;82:1424-37.
  20. Beanlands RSB, Dawood F, Wen W-H, et al. Are the kinetics of technetium-99m methoxyisobutyl isonitrile affected by cell metabolism and viability? *Circulation* 1990;82:1802-14.
  21. Freeman I, Grunwald AM, Hoory S, Bodenheimer MM. Effect of coronary occlusion and myocardial viability on myocardial activity of technetium-99m-sestamibi. *J Nucl Med* 1991;32:292-8.
  22. Rocco TP, Dilsizian V, Strauss HW, Boucher CA. Technetium-99m isonitrile myocardial uptake at rest. II. Relation to clinical markers of potential viability. *J Am Coll Cardiol* 1989;14:1678-84.
  23. Althoefer C, Kaiser H-J, Dörr R, et al. Fluorine-18 deoxyglucose PET for the assessment of viable myocardium in perfusion defects in <sup>99m</sup>Tc-MIBI SPET: a comparative study in patients with coronary artery disease. *Eur J Nucl Med* 1992;19:334-42.
  24. Cuocolo A, Pace L, Ricciardelli B, Chiariello M, Trimarco B, Salvatore M. Identification of viable myocardium in patients with chronic coronary artery disease: comparison of thallium-201 scintigraphy with reinjection and technetium-99m-methoxyisobutyl isonitrile. *J Nucl Med* 1992;33:505-11.
  25. Dondi M, Tartagni F, Fallani F, et al. A comparison of rest sestamibi and rest-redistribution thallium single photon emission tomography: possible implications for myocardial viability detection in infarcted patients. *Eur J Nucl Med* 1993;20:26-31.
  26. Marzullo P, Sambucetti G, Parodi O. The role of sestamibi scintigraphy in the radioisotopic assessment of myocardial viability. *J Nucl Med* 1992;33:1925-30.
  27. Marzullo P, Parodi O, Reisenhofer B, et al. Value of rest thallium-201/technetium-99m sestamibi scans and dobutamine echocardiography for detecting myocardial viability. *Am J Cardiol* 1993;71:166-72.
  28. Cohn PF, Maddox D, Holman BL, Makis JE, Adams DF, See JR. Effect of sublingually administered nitroglycerin on regional myocardial blood flow in patients with coronary artery disease. *Am J Cardiol* 1977;39:672-8.
  29. Cohen MV, Sonnenblick EH, Kirk ES. Comparative effects of nitroglycerin and isosorbide dinitrate on coronary collateral vessels and ischemic myocardium in dogs. *Am J Cardiol* 1976;37:244-9.
  30. Gorman MW, Sparks HV. Nitroglycerin causes vasodilatation within ischemic myocardium. *Cardiovasc Res* 1980;14:515.
  31. Rafflenbeul W, Urthaler F, Russel RO, Lichtlen P, James TN. Dilatation of coronary artery stenosis after isosorbide dinitrate in man. *Br Heart J* 1980;43:546-9.
  32. Brown BG, Bolson EL, Petersen RB, Pierce CD, Dodge HT. The mechanism of nitroglycerin action: stenosis vasodilation as a major component of the drug response. *Circulation* 1981;64:1689-97.
  33. Brown BG. Response of normal and diseased epicardial coronary arteries to vasoactive drugs: quantitative arteriographic studies. *Am J Cardiol* 1985;56:23E-9E.
  34. Gage JE, Hess OM, Murakami T, Riher M, Grimm J, Krayenbühl HP. Vasoconstriction of stenotic coronary arteries during dynamic exercise in patients with chronic angina pectoris. Reversibility by nitroglycerin. *Circulation* 1986;73:865-76.
  35. Hisano K, Tomoike H, Inoue T, Mohri M, Nakamura M. Isosorbide dinitrate ameliorates myocardial ischemia after development of collateral function in a canine model. *J Pharmacol Exp Ther* 1989;248:1289-96.
  36. Fujita M, Yamanishi K, Hirai T, et al. Significance of collateral circulation in reversible left ventricular asynergy by nitroglycerin in patients with relatively recent myocardial infarction. *Am Heart J* 1990;120:521-8.
  37. Aoki M, Sakai K, Koyanagi S, Takeshita A, Nakamura M. Effect of nitroglycerin on coronary collateral function during exercise evaluated by quantitative analysis of thallium-201 single photon emission computed tomography. *Am Heart J* 1991;121:1361-6.
  38. Ohno A, Fujita M, Miwa K, Ejiri M, Asanoi H, Sasayama S. Importance of coronary collateral circulation for increased treadmill exercise capacity by nitrates in patients with stable effort angina pectoris. *Cardiology* 1991;78:323-8.
  39. Medrano R, Mahmarian JJ, Verani MS. Nitroglycerin before reinjection of thallium-201 enhances detection of reversible hypoperfusion via collateral blood flow: a randomized, double blind, parallel, placebo-controlled trial [abstract]. *J Am Coll Cardiol* 1993;21:221A.
  40. He Z-X, Darcourt J, Guigner A, et al. Nitrates improve detection of ischemic but viable myocardium by thallium-201 reinjection SPECT. *J Nucl Med* 1993;34:1472-7.
  41. Rentrop KP, Cohen M, Blanke M, Phillips R-A. Changes in collateral channel filling immediately after controlled coronary artery occlusion by an angioplasty balloon in human subjects. *J Am Coll Cardiol* 1985;5:587-92.
  42. Pierard LA, Sprynger M, Carlier J. Echocardiographic prediction of the site of coronary artery obstruction in acute myocardial infarction. *Eur Heart J* 1987;8:116-23.
  43. Smart SC, Sawada S, Ryan T, et al. Low-dose dobutamine echocardiography detects reversible dysfunction after thrombolytic therapy of acute myocardial infarction. *Circulation* 1993;88:405-15.
  44. DePasquale EE, Nody AC, DePuey EC, et al. Quantitative rotational thallium-201 tomography for identifying and localizing coronary artery disease. *Circulation* 1988;77:316-27.
  45. Maddahi J, Van Train K, Prigent F, et al. Quantitative single photon emission computed thallium-201 tomography for detection and localization of coronary artery disease: optimization and prospective validation of a new technique. *J Am Coll Cardiol* 1989;14:1689-99.
  46. Helfant RH, Pine R, Meister SG, Feldman MS, Trout RG, Banka VS. Nitroglycerin to unmask reversible asynergy. Correlation with post coronary bypass ventriculography. *Circulation* 1974;50:108-13.
  47. Chesbro JH, Ritman EL, Frye RL, et al. Regional myocardial wall thickening response to nitroglycerin. A predictor of myocardial response to aortocoronary bypass surgery. *Circulation* 1978;57:952-7.