



UNIVERSITÀ  
DEGLI STUDI  
FIRENZE

## FLORE

# Repository istituzionale dell'Università degli Studi di Firenze

### **Localized scleroderma-like lesions in autologous bone marrow transplantation.**

Questa è la Versione finale referata (Post print/Accepted manuscript) della seguente pubblicazione:

*Original Citation:*

Localized scleroderma-like lesions in autologous bone marrow transplantation / N. PIMPINELLI; M. SANTUCCI; A. BOSI. - In: EUROPEAN JOURNAL OF DERMATOLOGY. - ISSN 1167-1122. - STAMPA. - 2:(1992), pp. 12-14.

*Availability:*

The webpage <https://hdl.handle.net/2158/223204> of the repository was last updated on

*Terms of use:*

Open Access

La pubblicazione è resa disponibile sotto le norme e i termini della licenza di deposito, secondo quanto stabilito dalla Policy per l'accesso aperto dell'Università degli Studi di Firenze (<https://www.sba.unifi.it/upload/policy-oa-2016-1.pdf>)

*Publisher copyright claim:*

La data sopra indicata si riferisce all'ultimo aggiornamento della scheda del Repository FloRe - The above-mentioned date refers to the last update of the record in the Institutional Repository FloRe

(Article begins on next page)

## Localized scleroderma-like lesions in autologous bone marrow transplantation

NICOLA PIMPINELLI, MARCO SANTUCCI, ALBERTO BOSI

We describe the previously unreported occurrence of cutaneous lesions clinically resembling localized scleroderma (morphea) in 4/32 patients receiving autologous bone marrow transplantation (BMT). Histologically, these lesions were characterized by tight packing and hyalinization of collagen bundles of the reticular dermis, without any significant sclerosis and/or fibrosis, i.e. features of the very initial phases of the localized types of scleroderma and chronic cutaneous graft-versus-host disease (GVHD). The lesions showed a complete spontaneous regression in 3 to 9 months in all cases but one, who died due to a relapse of acute lymphoblastic leukaemia 14 months after the onset of the cutaneous lesions. We stress the importance of being aware of the possible occurrence of similar lesions in patients receiving BMT.

N. Pimpinelli: Clinica Dermatologica II, Via della Pergola 58, 50121 Firenze, Italy. M. Santucci: Istituto di Anatomia e Istologia Patologica, Università di Firenze, Italy. A. Bosi: Divisione di Ematologia, Unità Trapianto di Midollo Osseo, Ospedale di Careggi, USL 10/D, Firenze, Italy.

This work was supported by the Italian Ministries of Education and of Scientific and Technologic Research (University funds, 60%).

Reprints: N. Pimpinelli.

**Keywords:** autologous, bone marrow transplantation, scleroderma-like lesions, skin.

Cutaneous graft-versus-host disease (GVHD) occurs frequently in patients undergoing allogeneic bone marrow transplantation (BMT) [1]. In the acute phase of GVHD, skin lesions closely resemble those of cutaneous drug reactions (maculopapular or scarlatini-form rashes, developing into epidermal necrosis in severe cases) [1, 2]. A syndrome similar to acute GVHD has been reported to occur in patients receiving autologous or syngeneic BMT, both spontaneously (8% of cases) [3, 4] and as an effect of temporary administration of cyclosporin-A [5]; in this instance, it is a mild, self-limited disease.

In the chronic phase of GVHD, developing either from acute GVHD or *de novo*, skin lesions closely resemble scleroderma, both clinically and histologically [6, 7]. Two major types are recognized: a generalized type with an early lichenoid and a late sclerotic phase, and a localized type. The former type is characterized by the progressive development of diffuse poikilodermatous and/or sclerotic changes [6]. The localized type consists of a rough, irregular hyperpigmentation overlying areas of induration, thus resembling circumscribed scleroderma (morphea); these lesions may either enlarge, eventually forming large sclero-

tic to hidebound areas, or more rarely self-regress [6, 7]. In some cases, the localized cutaneous lesions are characteristically limited to the irradiation fields [8] or to areas of a previous measles exanthem [9].

We report in this paper the occurrence of localized, self-regressing, indurated lesions of the skin, clinically resembling morphea, in 4 patients receiving autologous BMT.

## Patients and methods

The clinical and pathologic records of 53 patients transplanted at the BMT Unit of Careggi Hospital, Florence, Italy (32 autologous, 21 allogeneic BMT) were reviewed.

Four patients receiving autologous BMT – whose personal data, diagnosis, and type of conditioning regimen are summarized in *Table 1* – developed peculiar cutaneous lesions 7–9 months after BMT. The lesions consisted of non-elevated, indurated plaques, ivory to hyperpigmented in colour, 2 to 11 cm in diameter, involving the skin and subcutis, and strictly localized on the upper arms (cases 7, 8, 21) or on the thigh (case 15) (*Fig. 1*). In all cases, a biopsy was taken from the lesional skin, fixed in buffered formalin or in Dubosq-Brazil liquid, and processed with routine methods.

The histologic examination showed minimal and non-specific epidermal changes, consisting of some liquefaction degeneration of the basal cells and a decrease in the rete ridges. The papillary dermis did not show any significant alterations, the collagen consisting – as it normally does – of loosely arranged fibres. Conversely, the reticular dermis constantly showed a slightly increased number of fibroblasts and some thickening of the collagen bundles. The latter, due to the dramatic narrowing of the spaces between them, quite often appeared to be tightly packed and hyalinized, staining more deeply eosinophilic than in normal skin (*Fig. 2*). A mild, predominantly lymphocytic cellular infiltrate was observed constantly around the blood vessels of the superficial plexus, and less frequently around the cutaneous appendages. Vascular changes were always slight, consisting of some endothelial swelling and edema of the vascular walls. The eccrine sweat glands appeared normal, lying near the cutaneous-subcutaneous border and being surrounded by fat. The subcutis showed no significant change. The post-transplant course of the patients

UPN <sup>(1)</sup>	Age/Sex	Diagnosis Status at BMT <sup>(2)</sup>	Transplant <sup>(3)</sup>	Conditioning Regimen <sup>(4)</sup> [10,11]
7	42/M	CML/CP	PBSCI	Bu + Cy
8	10/F	ALL(L1)/CR2	Auto	TBI + Cy
15	24/F	ANLL(M2)/CR1	Auto	Bu + Cy
21	17/M	ANLL(M2)/CR1	Auto	Bu + Cy

(1) UPN = unique patient number.  
 (2) ALL = acute lymphoblastic leukaemia; ANLL = acute non-lymphoblastic leukaemia; CML = chronic myelogenous leukaemia; CR1, CR2 = complete remission 1, 2; CP = chronic phase.  
 (3) PBSCI = peripheral blood stem cell infusion; Auto = autologous BMT.  
 (4) TBI = total body irradiation; Bu = busulfan; Cy = cyclophosphamide.

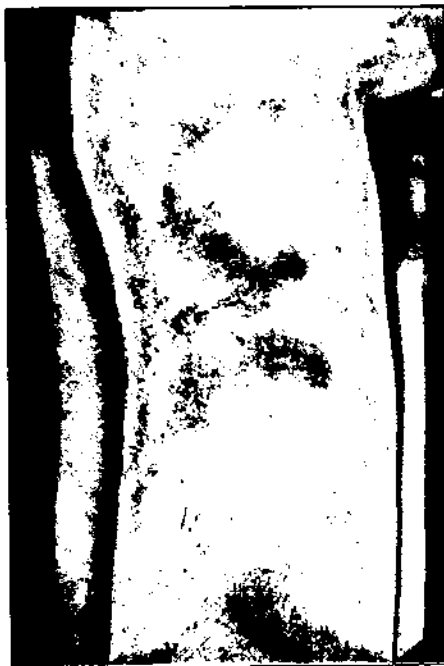

Figure 1. Large, non-elevated, indurated, slightly hyperpigmented plaque of the right arm (patient 21).




Figure 2. The reticular dermis shows a slightly increased number of fibroblasts and a thickening of the collagen bundles, which – due to the dramatic narrowing of the spaces between them – appear tightly packed and hyalinized (H and E).

up to the onset of the cutaneous lesions was nearly normal; no viral infection developed, and the immune status – as judged from the peripheral blood total lymphocyte count, the immune phenotyping of the circulating mononuclear cells, and the delayed cutaneous response to ubiquitous antigens – did not show any significant alterations.

Skin lesions showed a complete spontaneous regression in 3 to 9 months in all cases but one (No. 8); this patient had a relapse of acute lymphoblastic leukaemia shortly after BMT, and died 14 months after the onset of cutaneous lesions. Due to ethical reasons, no further biopsies were taken.

## Discussion

Skin lesions closely resembling circumscribed scleroderma (morphea), both clinically and histologically, are typical of chronic GVHD [6, 7]. In some patients, scleroderma-like cutaneous lesions are characteristically limited to irradiation fields [8] or to areas of a previous measles exanthem [9].

To the best of our knowledge, cutaneous lesions with the clinical (self-regressing, morphea-like plaques) and histologic features (tight packing and hyalinization

of collagen bundles) reported herein, have not yet been described in patients treated by autologous BMT.

The lesions observed in our patients show clinical features resembling those of localized scleroderma, and a histomorphologic profile similar to that observed in the very initial phases of localized types of scleroderma and chronic cutaneous GVHD [6, 7]. In fact, in our cases the clinical morphea-like picture was mainly supported by a hyalinization phenomenon, namely, confluence of collagen bundles due to the dramatic narrowing of the spaces between them, with increased eosinophilia. Conversely, fibrosis and/or sclerosis - basic features of fully developed lesions of both morphea and chronic cutaneous GVHD - were substantially absent.

At present, it is very hard to explain why these lesions do occur. It can be speculated that the complex mechanisms underlying the development of chronic GVHD [12, 13] may be partially - and temporarily - operating also in some patients undergoing autologous BMT, resulting in a condition similar to that occurring in chronic GVHD. While the concept of a drug-induced immune deficiency in the early post-transplant period is readily acceptable [5, 12], it is difficult to explain the late development of a self-limiting immune dysregulation in patients treated by autologous BMT, especially considering the absence of any detectable immune imbalance in the reported cases.

Independent of any possible speculation, it is important to be aware of the rare occurrence of morphea-like lesions in patients treated by autologous BMT. ■

## References

1. Saurat JH. Graft versus host reaction: why is it important for the dermatologist? *Dermatologica* 1988; 176: 1-5.
2. Sale GE, Lerner KG, Barker EA, Shulman HM, Thomas ED. The skin biopsy in the diagnosis of acute graft versus host disease in man. *Am J Pathol* 1977; 89: 621-36.
3. Mood AF, Vagelsang GB, Black LP, Farmer ER, Santos GW. Acute graft-vs-host disease. Development following autologous and syngeneic bone marrow transplantation. *Arch Dermatol* 1987; 123: 745-50.
4. Binsele H, Ehninger G, Schneider EM, et al. High frequency of graft-versus-host-like syndromes following syngeneic bone marrow transplantation. *Transplantation* 1988; 45: 579-85.
5. Jones RJ, Hess AD, Mann RB, Piantadosi S, Vagelsang GB, Farmer ER, Geiler RB, Santos GW. Induction of graft-versus-host disease after autologous bone marrow transplantation. *Lancet* 1989; 754-7.

6. Shulman HM, Sale GE, Lerner KG, Barker EA, Welden PL, Sullivan K, Gallucci B, Thomas ED, Storb R. Chronic cutaneous graft-versus-host disease in man. *Am J Pathol* 1978; 92: 545-70.
7. Van Vloten WA, Scheffer E, Dooren LJ. Localized scleroderma-like lesions after bone marrow transplantation in man: a chronic graft-versus-host reaction. *Br J Dermatol* 1977; 96: 337-41.
8. Socie G, Gluckman E, Cosset JM, Devergie A, Grinski T, Esperou H, Dutreix J. Unusual localization of cutaneous chronic graft-versus-host disease in the radiation fields in four cases. *Bone Marrow Transplantation* 1989; 4: 133-5.
9. Feryk JR. Sclerodermatous graft-versus-host disease limited to an area of measles exanthem (letter) *Lancet* 1978; i: 472.
10. Santos GW, Tutschko PJ, Brookmeyer R, et al. Marrow transplantation for acute non-lymphocytic leukemia after treatment with busulfan and cyclophosphamide. *N Engl J Med* 1983; 309: 1347-51.
11. Shank B, Hopfan S, Kim JH, et al. Hyperfractionated total body irradiation for bone marrow transplantation: 1. Early results in leukemia patients. *Int J Radiat Oncol Biol Phys* 1981; 7: 1109-15.
12. Ferrara JLM, Deeg HJ. Graft-versus-host disease *N Engl J Med* 1991; 324: 667-74.
13. Atkinson K. Chronic graft-versus-host disease. *Bone Marrow Transplantation* 1990; 5: 69-82.

## Riassunto

Lesioni sclerodermiformi localizzate dopo trapianto di midollo osseo autologo.

Viene descritta per la prima volta la comparsa di lesioni cutanee clinicamente simili a quelle della sclerodermia localizzata (morphea) in 4/32 pazienti sottoposti a trapianto di midollo osseo autologo. Le lesioni, regredite poi spontaneamente in 3-9 mesi, mostravano un aspetto istologico assai simile a quello delle fasi molto iniziali della morphea e della graft-versus-host disease (GVHD) cutanea cronica, i.e. stretta giustapposizione e ialinizzazione dei fasci collageni, in assenza di sclerosi e/o fibrosi significative. Viene sottolineato l'importanza di tenere presente la possibile insorgenza di lesioni sclerodermiformi in pazienti sottoposti a trapianto di midollo osseo autologo.

## ANNOUNCEMENTS

January 1992

London (Great-Britain), Meeting of the medical Society for the study of Venereal diseases. Programme: HIV infection: diagnosis of HIV infection on the neonate (J.F. Peutherer - Edinbourg); vaccines (J. Weber - London); partner information (R.A. Keenlyside - London). For information: M.J. Godley - Honorary secretary, MSSVD - The Florey Unit - Royal Berkshire Hospital - London Road - Reading, RG1 5AN.

February 1992

6-10 Cairo (Egypte), VII Zagazig international conference of dermatology and venereology. Organized by the Department of dermatology and venereology of Zagazig University, in association with the Jefferson center for international Dermatology, Jefferson Medical College of Thomas Jefferson University, in cooperation with the Section of dermatology of the College of physicians of Philadelphia and the international Society of Dermatology: tropical, geographic and ecologic. Theme: five thousand years of dermatology: from the Pharaohs to the 21st century. Programme: symposia; practical aspects of molecular biology; advances in dermatologic therapy; unusual aspects of common skin diseases; cutaneous surgery; tropical dermatology; dermatologic instrumentation; international medical education; sexually transmitted diseases.

Information and registration: Ms E. O'Shaughnessy-Jefferson Center for international dermatology-1020 Locust Street-Philadelphia, PA 19107. Tel.: (215) 955-5785. - Fax: (215) 955-5393.