



UNIVERSITÀ
DEGLI STUDI
FIRENZE

FLORE

Repository istituzionale dell'Università degli Studi di Firenze

THE TREATMENT OF BASAL CELL CARCINOMAS IN A PATIENT WITH XERODERMA PIGMENTOSUM WITH A COMBINATION OF IMIQUIMOD 5%

Questa è la Versione finale referata (Post print/Accepted manuscript) della seguente pubblicazione:

Original Citation:

THE TREATMENT OF BASAL CELL CARCINOMAS IN A PATIENT WITH XERODERMA PIGMENTOSUM WITH A COMBINATION OF IMIQUIMOD 5% CREAM AND ORAL ACITREIN / B. GIANNOTTI; L. VANZI; N. PIMPINELLI; E. DIFONZO. - In: CLINICAL AND EXPERIMENTAL DERMATOLOGY. - ISSN 0307-6938. - STAMPA. - 28:(2003), pp. 33-35.

Availability:

The webpage <https://hdl.handle.net/2158/24887> of the repository was last updated on

Terms of use:

Open Access

La pubblicazione è resa disponibile sotto le norme e i termini della licenza di deposito, secondo quanto stabilito dalla Policy per l'accesso aperto dell'Università degli Studi di Firenze (<https://www.sba.unifi.it/upload/policy-oa-2016-1.pdf>)

Publisher copyright claim:

La data sopra indicata si riferisce all'ultimo aggiornamento della scheda del Repository FloRe - The above-mentioned date refers to the last update of the record in the Institutional Repository FloRe

(Article begins on next page)

The treatment of basal cell carcinomas in a patient with xeroderma pigmentosum with a combination of imiquimod 5% cream and oral acitretin

B. Giannotti, L. Vanzi, E. M. Difonzo and N. Pimpinelli

Dipartimento Scienze Dermatologiche, Via degli Alfani, Firenze, Italy

Summary

Xeroderma pigmentosum (XP) is a rare autosomal recessive photosensitive disorder, which results in multiple face, neck and head basal cell carcinomas (BCCs), squamous cell carcinomas and melanomas. A 15-year-old boy with XP presented with multiple facial BCCs previously treated by surgical excision. Standard BCC treatments such as surgery are not ideal for patients with several facial BCCs because of the risk of scarring, and the patient refused further surgery. As an alternative, three times weekly application of imiquimod 5% cream in combination with oral acitretin (20 mg daily) was prescribed for 4–6 weeks. No adverse events were reported during treatment and all tumours had resolved at the 6-month follow up visit, highlighting the therapeutic potential of imiquimod 5% cream.

Introduction

Xeroderma pigmentosum (XP) is an autosomal recessive photosensitive disorder with an extremely high incidence of ultraviolet (UV)-related skin cancers. It is associated with impaired ability to repair UV-induced DNA damage.^{1,2} It reportedly effects 1 in 250 000 people in Europe and the USA, while its prevalence in Japan has been documented as 1 in 40 000.²

Clinical management of XP-related skin disorders consist of early diagnosis followed by a rigorous programme of sun protection, including avoidance of unnecessary UV exposure, wearing UV-blocking clothing and use of sun blocks on the skin.² Failure in early management of this condition generally results in basal cell carcinoma (BCC), squamous cell carcinoma (SCC) and malignant melanomas. Other complications of XP include ocular abnormalities.³ The carcinomas may be treated by surgery, curettage and electrodesiccation, cryosurgery, Mohs' micrographic surgery, CO₂ laser treatment or topical 5-fluorouracil.^{4–6} These methods, although effective on isolated

carcinomas, are not ideal for treating multiple tumours, primarily because of a higher risk of causing disfiguring scarring.

We report a novel method of treating multiple carcinomas in XP patients with the immune response modifier, imiquimod 5% cream. Imiquimod, a recommended treatment option for anogenital warts, has been shown to be effective in treating many other skin disorders, such as human papilloma virus-associated warts and skin carcinomas including BCCs.^{7–10}

Case report

A 15-year-old boy presented with XP with associated multiple BCCs and SCCs on his face. The first appearance of tumours was initially reported at the age of 3 years, and the number and size progressively increased with advancing age. Previous treatment for these tumours was surgical excision.

During physical examination, multiple freckles and dry, atrophic skin were observed on light-exposed surfaces. Conjunctivitis and ectropion were also evident. Many keratocanthomas and angiokeratomas were observed on the trunk and upper and lower extremities.

The 11 tumours (3–6 mm in diameter) proposed for treatment were located on the face. Some nodules had superficial ulcerations, and others were covered by

Correspondence: Dr B. Giannotti, Dipartimento Scienze Dermatologiche, via degli Alfani 37, 50121 Firenze, Italy.

Accepted for publication 21 July 2003

haemorrhagic crusts (Fig. 1a). In addition, Fig. 1(b,c) show multiple lesions on the right side of the face and above the right eyebrow, respectively. Only three of these tumours were biopsied (one was a BCC and two were SCCs), although physical and radiological examinations excluded lymphadenopathy and metastatic involvement, respectively. The patient and his parents refused surgery as a treatment option for all of the tumours proposed for treatment. As an alternative, a combination of oral acitretin (20 mg daily) and topically applied imiquimod 5% cream was prescribed.

The patient was instructed to apply imiquimod 5% cream three times a week for 4–6 weeks to two tumours at a time. The total duration of treatment depended on the rate at which the tumours resolved. Following treatment the tumours were confirmed as clinically clear (Fig. 2a). Perioral tumours located on the delicate skin around the mouth also completely cleared (Fig. 2b,c). Tumours located on the right side of the face (Fig. 2d) and above the right eyebrow (Fig. 2e) were confirmed to be clinically clear following treatment. During the course of treatment, the patient did not report any adverse events, although mild local erythema was observed during application of imiquimod 5% cream. All the tumours were completely cleared at

the 6-month follow-up visit. The patient continues to be seen every 4 weeks for clinical follow-up and there has been no recurrence of the tumours.

Discussion

Xeroderma pigmentation (XP) involves DNA repair and replication deficiencies that predispose homozygous individuals to a 1000-fold increase in melanoma and nonmelanoma skin cancers.¹¹ The high incidence of tumours that develop in sun-exposed areas of the skin of patients with XP (> 4000 times the incidence in the general population) has implicated the role of unrepaired UV-induced DNA lesions in skin carcinogenesis.¹² This hereditary condition has been found to be associated with mutations occurring within the tumour suppressor genes *p53* and *patched (PTCH)*.¹³ Within XP patients, *PTCH* mutations represent an earlier event in BCC development than *p53* alterations.¹⁴

Clinical management of carcinomas associated with XP consists of early diagnosis followed by a rigorous programme of sun protection. Despite extensive precautionary measures, it is inevitable that sufferers of XP will experience some cutaneous malignancies. However, the prophylactic usage of oral retinoids, topical retinoids,

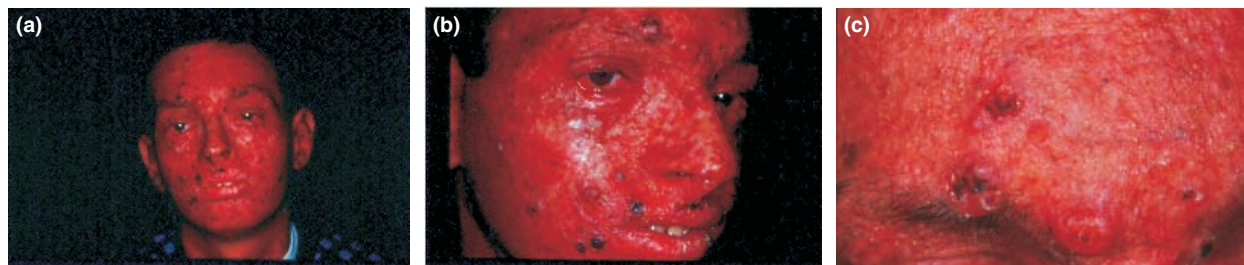

Figure 1 (a) Multiple basal and squamous carcinomas on the face of an XP patient before treatment; (b) multiple lesions on the right hand side of the face; (c) basal cell carcinoma lesion located above the right eyebrow.

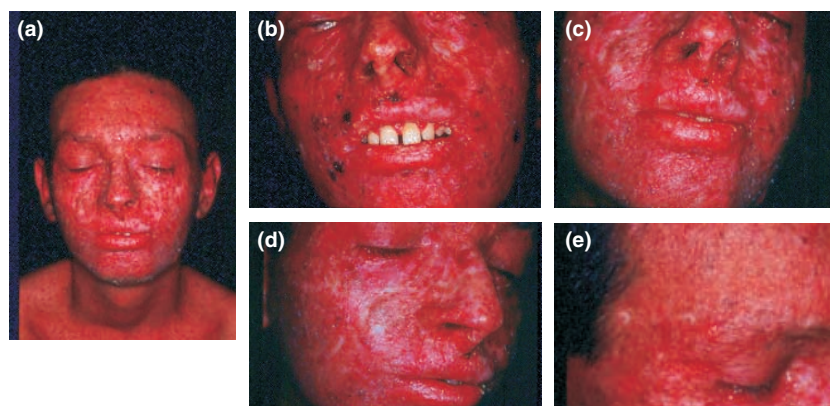


Figure 2 (a) Four to six weeks after treatment with imiquimod 5% cream, lesions on the face appear clinically clear and there is significant improvement and clearance of perioral lesions located around the mouth (b, c). (d) Lesions on the right hand side of the face successfully cleared following treatment. (e) Clearance of the BCC lesions above the right eyebrow.

local injection of interferon and the external use of prokaryotic DNA repair enzymes may slow down the onset of skin cancers.^{2,15} Conventional methods of treating BCC, e.g. surgery, cryotherapy and electrodesiccation may also be employed in XP-associated tumours.¹⁶ These treatments, although effective in the short term, may be associated with recurrence and scarring and may not be feasible for multiple tumours. In addition to these conventional treatment modalities, a recent study by Yarosh *et al.* demonstrated that topical application of DNA repair enzymes (endonuclease V) to sun-damaged skin of patients with XP lowered the rate of development of skin cancers, including BCCs, during a year of treatment.¹⁷

The introduction of imiquimod 5% cream as a treatment for anogenital warts⁷ has resulted in researchers identifying its potential use in treating both viral and nonviral skin conditions, including skin tumours such as BCC, even where these occur in the spectrum of hereditary conditions such as Gorlin's syndrome.^{10,18–21} These findings, together with its successful use in treating facial BCCs in XP patients, highlights the therapeutic potential of imiquimod 5% cream for cutaneous oncological conditions.

References

- 1 Stary A, Sarasin A. The genetics of the hereditary xeroderma pigmentosum syndrome. *Biochimie* 2002; **84**: 49–60.
- 2 Moriwaki S, Kraemer KH. Xeroderma pigmentosum-bridging a gap between clinic and laboratory. *Photodermatol Photoimmunol Photomed* 2001; **17**: 47–54.
- 3 Kraemer KH, Lee MM, Scotto J. Xeroderma pigmentosum. Cutaneous, ocular and neurologic abnormalities in 830 published cases. *Arch Dermatol* 1987; **123**: 241–50.
- 4 Drake MLA, Ceilley RI, Cornelison RL *et al.* Guidelines of care for basal cell carcinoma. *J Am Acad Dermatol* 1992; **26**: 117–20.
- 5 Kopera D, Cerroni L, Fink-Puches R, Kerl H. Different treatment modalities for the management of a patient with the nevoid basal cell carcinoma syndrome. *J Am Acad Dermatol* 1996; **345**: 937–9.
- 6 Hamouda B, Jamila Z, Najet R *et al.* Topical 5-fluorouracil to treat multiple or unresectable facial squamous cell carcinomas in xeroderma pigmentosum. *J Am Acad Dermatol* 2001; **44**: 1054.
- 7 Edwards L, Ferenczy A, Eron L *et al.* Self-administered topical 5% imiquimod cream for external anogenital warts. *Arch Dermatol* 1998; **134**: 25–30.
- 8 Hengge UR, Esser S, Schultewolter T *et al.* Self-administered topical 5% imiquimod for the treatment of common warts and molluscum contagiosum. *Br J Dermatol* 2000; **143**: 1026–31.
- 9 Schroeder TL, Sengelmann RD. Squamous cell carcinoma *in situ* of the penis successfully treated with imiquimod 5% cream. *J Am Acad Dermatol* 2002; **46**: 545–8.
- 10 Beutner KR, Spruance SL, Hougham AJ *et al.* Therapeutic response of basal carcinoma to the immune response modifier imiquimod 5% cream. *J Am Acad Dermatol* 1999; **41**: 1002–7.
- 11 Cleaver JE. Common pathways for ultraviolet skin carcinogenesis in the repair and replication defective groups of xeroderma pigmentosum. *J Dermatol Sci* 2000; **23**: 1–11.
- 12 Stary A, Sarasin A. The genetic basis of xeroderma pigmentosum and trichothiodystrophy syndromes. *Cancer Survey* 1996; **26**: 155–71.
- 13 Lacour JP. Carcinogenesis of basal cell carcinoma: genetics and molecular mechanisms. *Br J Dermatol* 2002; **146** (Suppl.): 17–9.
- 14 D'Errico M, Calcagnile A, Canzona F *et al.* UV mutation signature in tumour suppressor genes involved in skin carcinogenesis in xeroderma pigmentosum patients. *Oncogene* 2000; **19**: 463–7.
- 15 Somos S, Farkas B, Schneider I. Cancer protection in xeroderma pigmentosum variant (VP-V). *Anticancer Res* 1999; **19**: 2195–9.
- 16 Nguyen TH, Ho DQ. Nonmelanoma skin cancer. *Curr Treat Options Oncol* 2002; **3**: 193–203.
- 17 Yarosh D, Klein J, O'Connor A, Hawk J, Rafal E, Wolf P. Effect of topically applied T4 endonuclease V in liposomes on skin cancer in xeroderma pigmentosum: a randomised study. Xeroderma pigmentosum Study Group. *Lancet* 2001; **357**: 926–9.
- 18 Tyring SK, Arany I, Stanley MA *et al.* A randomised, controlled, molecular study of condylomata acuminata clearance during treatment with imiquimod. *J Infect Dis* 1998; **178**: 551–5.
- 19 Strauss RM, Doyle EL, Mohsem AH, Green ST. Successful treatment of molluscum contagiosum with topical imiquimod in a severely immunocompromised HIV-positive patient. *Int J STD AIDS* 2001; **12**: 264–6.
- 20 Marks R, Gebauer K, Shumack S *et al.* Imiquimod 5% cream in the treatment of superficial basal cell carcinoma: results of a multicentre 6 week dose-response trial. *J Am Acad Dermatol* 2001; **44**: 807–13.
- 21 Kagy MK, Amonette R. The use of imiquimod 5% cream for the treatment of superficial basal cell carcinomas in a basal cell nevus syndrome patient. *Dermatol Surg* 2000; **26**: 577–8.