



UNIVERSITÀ  
DEGLI STUDI  
FIRENZE

## FLORE

# Repository istituzionale dell'Università degli Studi di Firenze

### **Distributional map of the terminal and sub-terminal sugar residues of the glycoconjugates in the prepubertal and postpubertal testis of a**

Questa è la Versione finale referata (Post print/Accepted manuscript) della seguente pubblicazione:

*Original Citation:*

Distributional map of the terminal and sub-terminal sugar residues of the glycoconjugates in the prepubertal and postpubertal testis of a subject affected by complete androgen insensitivity syndrome (Morris's syndrome): lectin histochemical study / G. GHERI; G.B. VANNELLI; M. MARINI; G.D. ZAPPOLI THYRION; R.G. GHERI; E. SGAMBATI. - In: HISTOLOGY AND HISTOPATHOLOGY. - ISSN 0213-3911. - STAMPA. - 19:(2004), pp. 1-8.

*Availability:*

This version is available at: 2158/254266 since:

*Terms of use:*

Open Access

La pubblicazione è resa disponibile sotto le norme e i termini della licenza di deposito, secondo quanto stabilito dalla Policy per l'accesso aperto dell'Università degli Studi di Firenze (<https://www.sba.unifi.it/upload/policy-oa-2016-1.pdf>)

*Publisher copyright claim:*

(Article begins on next page)

# Distributional map of the terminal and sub-terminal sugar residues of the glycoconjugates in the prepubertal and postpubertal testis of a subject affected by complete androgen insensitivity syndrome (Morris's syndrome): lectin histochemical study

G. Gheri<sup>1</sup>, G.B. Vannelli<sup>1</sup>, M. Marini<sup>1</sup>, G.D. Zappoli Thyriou<sup>2</sup>, R.G. Gheri<sup>3</sup> and E. Sgambati<sup>4</sup>

<sup>1</sup>Department of Anatomy, Histology and Forensic Medicine. <sup>2</sup>Department of Clinical Physiopathology, Endocrine Unit and

<sup>3</sup>Department of Medicine, University of Florence, Policlinico di Careggi, Florence, Italy

**Summary.** In the present research we have investigated the distribution of the sugar residues of the glycoconjugates in the prepubertal and postpubertal testes of a subject with Morris's syndrome (CAIS, Complete Androgen Insensitivity Syndrome). For this purpose a battery of six horseradish peroxidase-conjugated lectins was used (SBA, PNA, WGA, ConA, LTA and UEAI). We have obtained a complete distributional map of the terminal and sub-terminal oligosaccharides in the tunica albuginea, interstitial tissue, lamina propria of the seminiferous tubules, Leydig cells, Sertoli cells, spermatogonia, mastocytes and endothelial cells. Furthermore the present study has shown that a large amount of sugar residues were detectable in the prepubertal and postpubertal testes but that some differences exist with particular regard to the Sertoli cells. The Sertoli cells and the Leydig cells of the retained prepubertal testis of the patient affected by Morris's syndrome were characterized by the presence of  $\alpha$ -L-fucose, which was absent in the retained prepubertal testis of the normal subjects. Comparing the results on the postpubertal testis with those obtained on the same aged testis of healthy subjects we have demonstrated that  $\alpha$ -L-fucose in the Sertoli and Leydig cells and D-galactose-N-acetyl-D-galactosamine in the Leydig cells are a unique feature of the subject affected by Morris's syndrome. D-galactose ( $\beta$ 1 $\rightarrow$ 3)-N-acetyl-D-galactosamine and sialic acid, which are present in the Leydig cells of the normal testis were never observed in the same cells of the postpubertal testis of the CAIS patient.

**Key words:** Oligosaccharides, Prepubertal and Postpubertal testis, Morris's syndrome

*Offprint requests to:* Prof. G. Gheri, Department of Anatomy, Histology and Forensic Medicine, Policlinico di Careggi, Viale Morgagni 85, Florence, Italy. Fax: +39554379500. e-mail: gheri@unifit.it

## Introduction

Patients affected by complete androgen insensitivity syndrome (CAIS or Morris's syndrome) have an XY pair of sex chromosomes which is due to a genetic defect in the androgen receptor, which enables the male hormone testosterone to exert its effect. A subject affected by CAIS has no virilization either during foetal or adult life and his external genitals are completely female in appearance, whereas the internal reproductive organs are missing. From a histological point of view the testes of adult patients affected by CAIS are characterized by Sertoli cell-only seminiferous tubules and by hyperplastic Leydig cells. The Sertoli cells appear mostly as immature elements (Regadera et al., 1999).

Sugar residues of the glycoconjugates in spermatogenic cells have been widely investigated by means of lectin histochemistry in sexually mature healthy human subjects (Lee and Damjanov, 1985; Malmi et al., 1987; Arenas et al., 1998).

To our knowledge no data are available in the literature on the distribution of the oligosaccharidic content of the glycoconjugates in testes of patients characterised by the complete androgen insensitivity syndrome.

The aim of the present research was to investigate the terminal and/or subterminal sugar residues of the glycoconjugates in the prepubertal and postpubertal testes of a patient affected by Morris's syndrome. For this purpose a battery of six HRP-conjugated lectins was used.

## Materials and methods

### *Specimens*

The retained prepubertal and postpubertal testis was surgically removed from the same patient affected by

CAIS at the age of 5 and 18 years respectively.

Orchidectomy specimens from two normal men (aged 18 and 20 years) were obtained at autopsy. The patient's history revealed the absence of reproductive, endocrine, or related disease and the presence of complete spermatogenesis in the testes. The retained prepubertal testes of two normal subjects (aged 5 and 6 years) were also collected. The specimens were collected 5-6 h after death. In order to evaluate post-mortem changes in the autopsy specimens, two testes obtained from testicular tumour surgery were immediately fixed and processed in the same way. All the specimens were fixed in Bouin fluid at 4 °C for 12 h and routinely processed for light microscopy to obtain 5 µm-thick paraffin sections. Some sections were stained with haematoxylin-eosin to get a general overview.

#### Lectin histochemistry

After hydration, the sections were treated with 0.3% hydrogen peroxide for 10 min to inhibit the endogenous peroxidase, rinsed in distilled water and washed with 1% bovine serum albumin (BSA) (Murata et al., 1983) in 0.1 M phosphate-buffered saline (PBS), pH 7.2. The sections were then incubated for 30 min at room temperature in horseradish peroxidase-conjugated lectins (HRP-lectin conjugated) dissolved in phosphate-buffered saline (0.1 M PBS pH 7.2, 0.1 M NaCl, 0.1 mM CaCl<sub>2</sub>, MgCl<sub>2</sub> and MnCl<sub>2</sub>) and then rinsed three times in PBS. The optimal concentration for each lectin (Sigma Chemical Co., St. Louis, MO) which allowed maximum staining with minimum background was as follows: SBA (*Glycine max*, binding specificity α/β-D-GalNAc > D-Gal) 20 mg/ml; PNA (*Arachis hypogaea*, binding specificity D-Gal (β1→3)-D-GalNAc) 25 mg/ml; ConA (*Canavalia ensiformis*, binding specificity α-D-Man > α-D-Glc) 50 µg/ml; WGA (*Triticum vulgare*, binding specificity (α-D-GlcNAc)<sub>n</sub> and sialic acid) 20 µg/ml; LTA (*Lotus tetragonolobus*, binding specificity α-L-Fuc) 25 mg/ml; and UEA I (*Ulex europaeus*, binding specificity α-L-Fuc) 25 mg/ml. Staining of the sites containing bound lectin-HRP was obtained by incubating the slides with PBS (pH 7.0), containing 3,3'-diaminobenzidine (DAB) (25 mg/100 ml) and 0.003%

hydrogen peroxide, for 10 min at room temperature. Specimens were rinsed in distilled water; dehydrated using graded ethanol solutions, cleared in xylene and mounted in Permount.

Controls for lectin staining included: 1) substitution of unconjugated lectins for lectin-HRP conjugates; 2) exposure to HRP and substrate medium without lectin; 3) oxidation with 1% periodic acid for 10 min prior to lectin staining; 4) exposure of sections to 10/12 µg/ml of each lectin-HRP conjugate containing 0.1 M D-galactose, D-glucose, D-mannose, L-fucose, N-acetyl-D-galactosamine, N-acetyl-D-glucosamine and methyl-D-mannopyranoside.

#### Enzymatic treatments

##### Sialidase digestion

In some experiments sialic acid was removed by pretreating the sections for 18 hr at 37° C in a solution of sodium acetate buffer 0.25 M, pH 5.5, containing 0.1 unit/ml sialidase (neuraminidase Type X from *Clostridium perfringens* (Sigma Chemical Co., St. Louis, MO), 5.0 mM CaCl<sub>2</sub> and 154 mM NaCl, prior to staining with lectin-HRP conjugates. Controls containing the sialidase buffer without the enzyme were also prepared.

##### Glucose oxidase digestion

Hydrolysis of terminal glucose residues was made using glucose oxidase from *Aspergillus niger* (Sigma Chemical Co., St. Louis, MO). The sections were incubated in 0.2 M sodium acetate buffer (pH 5) for 5 min and afterwards with the enzyme, at a dilution of 50 U/ml for 12 h at 37 °C.

#### Results

Lectin binding in the testis of healthy adult subjects is reported in Table 1. Our findings agree with those of Arenas et al. (1998).

Lectin binding in the retained prepubertal testes of normal subjects is reported in Table 2

**Table 1.** Lectin binding in the postpubertal normal testis .

	SERTOLI CELLS	LEYDIG CELLS	SPERMATOGONIA	TUNICA ALBUGINEA	INTERSTITIAL TISSUE	MASTOCYTES	ENDOTHELIAL CELLS
SBA	-	-	-	n.p.	1i	-	-
PNA	1c	1c	3c	n.p.	-	-	-
Neuraminidase PNA	1c	1c	3c	n.p.	1i, 3p	-	3
WGA	2gr	2gr	3c	n.p.	2i, 1p	-	2
UEAI	2c	-	-	n.p.	1i	-	3
LTA	-	-	-	n.p.	-	-	1
ConA	2gr	1gr	1c	n.p.	2i, 1p	-	-

gr: cytoplasmic granules; c: cytoplasm; i: interstitial tissue; p: lamina propria surrounding the seminiferous tubules; n.p.: not present; -, negative reaction; 1: weak reaction; 2: moderate reaction; 3: strong reaction.

*Oligosaccharides in CAIS testis*

*Prepubertal testis (Table 3)*

SBA

Cytoplasmic granules and the nucleus of the Sertoli cells, the nucleus of spermatogonia and a few Leydig cells reacted with this lectin. Strong reaction was observed within interstitial tissue while the lamina propria of the seminiferous tubules showed a weaker reaction (Fig. 1).

PNA

The mastocytes and the endothelial cells of the capillary vessels reacted with this lectin. A very weak reaction was observed in the nuclei of the Sertoli cells, of the spermatogonia and in the lamina propria of the seminiferous tubules (Fig. 2).

Following neuraminidase digestion a weak reaction was observed in the nucleus of the Sertoli cells and in the nucleus of the spermatogonia. The tunica albuginea showed strong reactivity especially in its most external portion. The lamina propria of the seminiferous tubules and the endothelial cells of the capillary vessels strongly reacted (Fig. 3).

WGA

The cytoplasm of the Sertoli cells, of the Leydig cells and the nucleus of the spermatogonia showed

reaction with this lectin. The tunica albuginea, especially in its most external portion, strongly reacted with WGA. Reactivity was observed in the fibres of the interstitial tissue, while the lamina propria of the seminiferous tubules showed weaker reactivity. The endothelial cells of the capillary vessels strongly reacted (Fig. 4). Following neuraminidase treatment a slight decrease in reactivity was seen in the endothelial cells.

UEAI

The nucleus and the cytoplasmic granules of the Sertoli cells, the nucleus of the spermatogonia and the cytoplasm of the Leydig cells reacted with this lectin (Fig. 5). Moderate reactivity was observed in the fibres of the interstitial tissue while stronger reactivity was seen in the lamina propria of the seminiferous tubules.

LTA

The cytoplasm and the nucleus of the Sertoli cells, the nucleus of the spermatogonia and the lamina propria of the seminiferous tubules showed a weak reaction with this lectin. LTA binding was observable in a few Leydig cells (Fig. 6).

ConA

The cytoplasmic granules and the nucleus of the Sertoli cells, the nucleus of the spermatogonia, and the

**Table 2.** Lectin binding in the prepubertal normal testis.

	SERTOLI CELLS	LEYDIG CELLS	SPERMATOGONIA	TUNICA ALBUGINEA	INTERSTITIAL TISSUE	MASTOCYTES	ENDOTHELIAL CELLS
SBA	-	-	-	np	3i, 3p	-	3
PNA	-	-	-	np	-	-	-
Neuraminidase PNA	1gr	-	-	np	1p	2	2
WGA	3gr	-	-	np	2i, 3p	-	3
UEAI	-	-	-	np	1i, 1p	-	3
LTA	-	-	-	np	2i, 1p	-	-
ConA	3gr	-	-	np	1p	-	1

gr: cytoplasmic granules; i: interstitial tissue; p: lamina propria surrounding the seminiferous tubules; n.p.: not present; -, negative reaction; 1: weak reaction; 2: moderate reaction; 3: strong reaction.

**Table 3.** Lectin binding in the prepubertal CAIS testis.

	SERTOLI CELLS	LEYDIG CELLS	SPERMATOGONIA	TUNICA ALBUGINEA	INTERSTITIAL TISSUE	MASTOCYTES	ENDOTHELIAL CELLS
SBA	2gr 2n	2c	2n	-	3i, 1p	-	-
PNA	1n	-	1n	-	1p	2	2
Neuraminidase PNA	1n	-	1n	3	3p	2	3
WGA	1c	1c	1n	3	2i, 1p	-	3
UEAI	2gr 2n	2c	1n	-	2i, 3p	-	-
LTA	1c 1n	2c*	1n	-	2p	-	-
ConA	1gr 1n	3c	1n	-	1p	-	-

gr: cytoplasmic granules; c: cytoplasm; n: nucleus; \*: only few cells; i: interstitial tissue; p: lamina propria surrounding the seminiferous tubules; -: negative reaction; 1: weak reaction; 2: moderate reaction; 3: strong reaction.

*Oligosaccharides in CAIS testis*

lamina propria of the seminiferous tubules showed a weak reaction. The cytoplasm of the Leydig cells strongly reacted (Fig. 7). Following glucose oxidase treatment no decrease in reactivity was detected.

*Post-pubertal testis (Table 4)*

**SBA**

The tunica albuginea and the Leydig cells reacted with this lectin (Fig. 8).

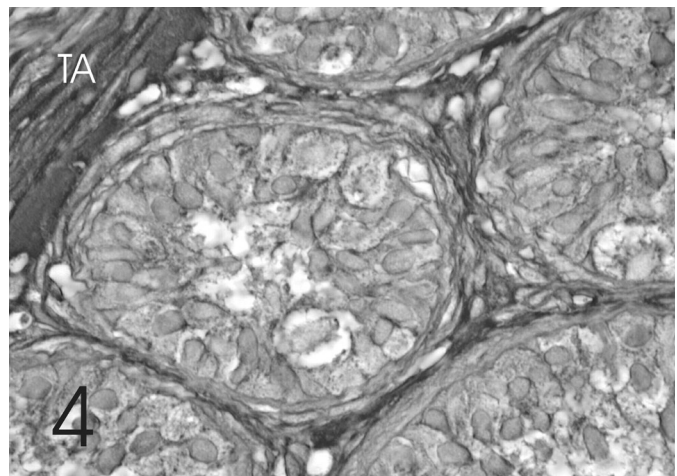
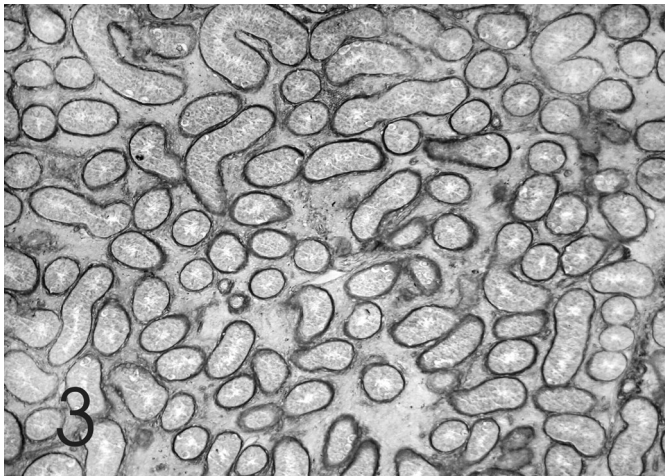
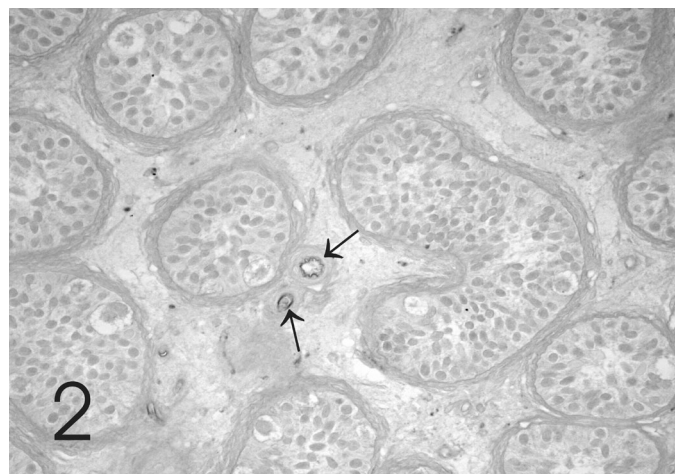
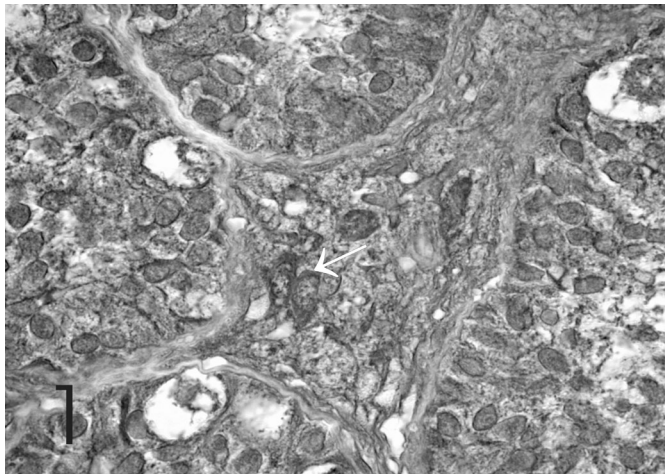
**PNA**

Reactivity was observed in the tunica albuginea, in

the lamina propria of the seminiferous tubules (Fig. 9) and in the granules of the mastocytes. Following neuraminidase digestion a strong reactivity appeared in the granules placed within the apical portion of the Sertoli cells and in the endothelial cells of the capillary vessels (Fig. 10).

**WGA**

The tunica albuginea, the cytoplasmic granules and the perinuclear zone of the Sertoli cells and the endothelial cells of the capillary vessels showed a strong reaction (Fig. 11), while the cytoplasm and the nucleus of the Leydig cells, and the interstitial tissue showed a moderate reactivity. Following neuraminidase treatment



**Fig. 1.** HRP-SBA – Prepubertal testis. Reactivity is detectable at the Sertoli cells, spermatogonia and Leydig cells (arrow). x 1280

**Fig. 2.** HRP-PNA – Prepubertal testis. The endothelial cells of the capillary vessels show strong reaction (arrows). x 470

**Fig. 3.** Neuraminidase-HRP-PNA – Prepubertal testis. Strong reaction is observable in the lamina propria of the seminiferous tubules. x 140

**Fig. 4.** HRP-WGA – Prepubertal testis. The tunica albuginea (TA) and the interstitial tissue show strong reaction. Weaker reaction is visible at the Sertoli cells and spermatogonia. x 1280

## Oligosaccharides in CAIS testis

a slight decrease in reactivity was observed in the Sertoli cells and in the endothelial cells.

### UEAI

A strong reaction with this lectin was observed in the tunica albuginea, the Leydig cells, the lamina propria of the seminiferous tubules and the endothelial cells of the capillary vessels, while the interstitial tissue showed a moderate reactivity (Fig. 12).

### LTA

A very weak reaction was detected in the cytoplasm of the Sertoli cells and in the lamina propria of the seminiferous tubules. The tunica albuginea and the cytoplasm of the Leydig cells showed a moderate to strong reactivity with this lectin (Fig. 13).

### ConA

A weak reactivity was detected in the cytoplasmic granules of the apical portion of the Sertoli cells and in the interstitial tissue. The Leydig cells and the tunica albuginea showed a strong reactivity with ConA (Fig. 14). Following glucose oxidase treatment no decrease in reactivity was detected.

### Discussion

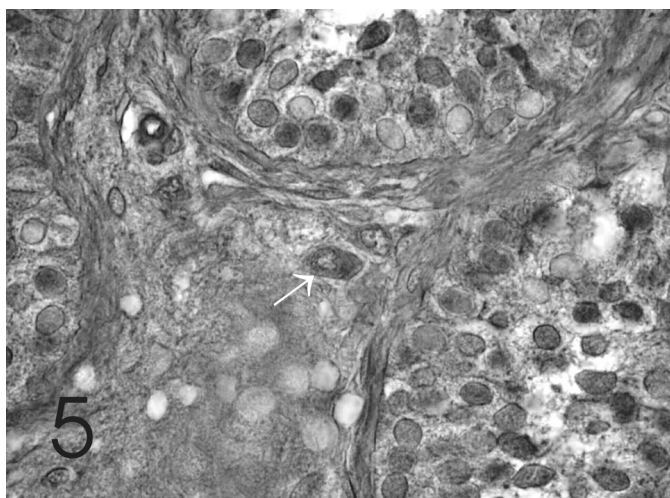
The results of the present lectin histochemical study has shown that a large amount of oligosaccharidic moieties of the glycoconjugates are present both in prepubertal and postpubertal testis of the subject affected by CAIS.

Although from a morphological point of view the retained prepubertal testis of the normal subject is at all

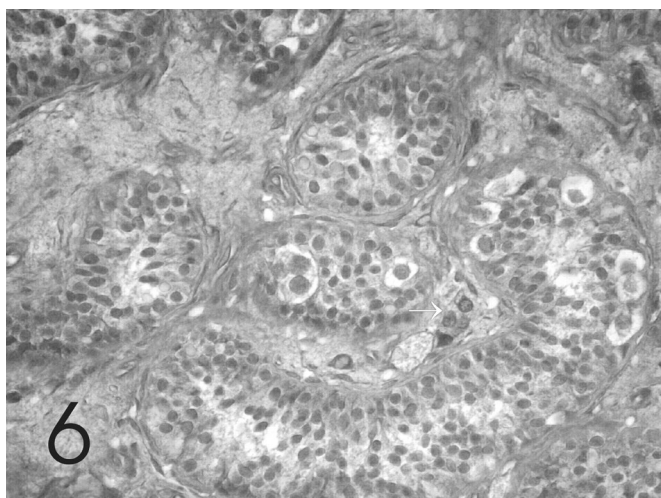
**Table 4.** Lectin binding in the postpubertal CAIS testis

	SERTOLI CELLS	LEYDIG CELLS	SPERMATOGONIA	TUNICA ALBUGINEA	INTERSTITIAL TISSUE AND LAMINA PROPIA	MASTOCYTES	ENDOTHELIAL CELLS
SBA	-	1c	abs.	3		-	-
PNA	-	-	abs.	2	1p	1	-
Neuraminidase PNA	3gr	-	abs.	2	2i	3	3
WGA	3gr	2c 2n	abs.	3	2i	-	3
UEAI	-	3gr	abs.	3	2i, 3p	-	3
LTA	1c	2c	abs.	3	1p	-	-
ConA	1gr	3c	abs.	3	1i	-	-

gr: cytoplasmic granules; c: cytoplasm; n: nucleus; i: interstitial tissue; p: lamina propria surroundin the seminiferous tubules; abs: absent; -, negative reaction; 1: weak reaction; 2: moderate reaction; 3: strong reaction.



**Fig. 5.** HRP-UEAI – Prepubertal testis. The cytoplasm and the nucleus of the Sertoli cells, the interstitial tissue, the lamina propria of the seminiferous tubules and the Leydig cells (arrow) show reactivity. x 1280



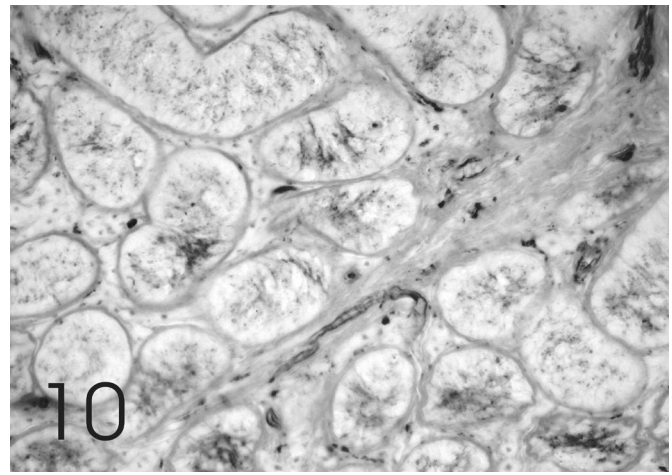
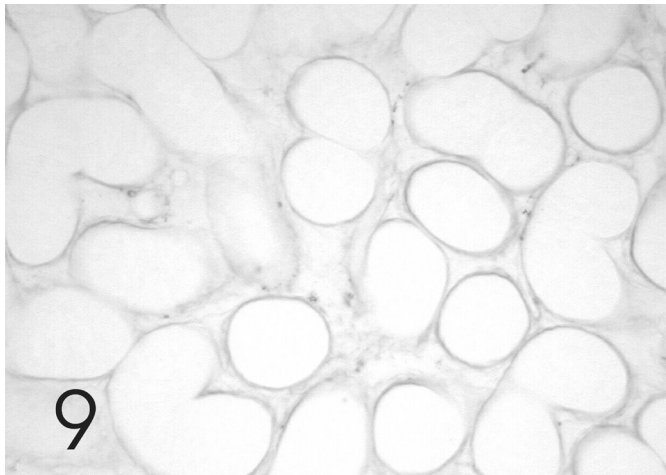
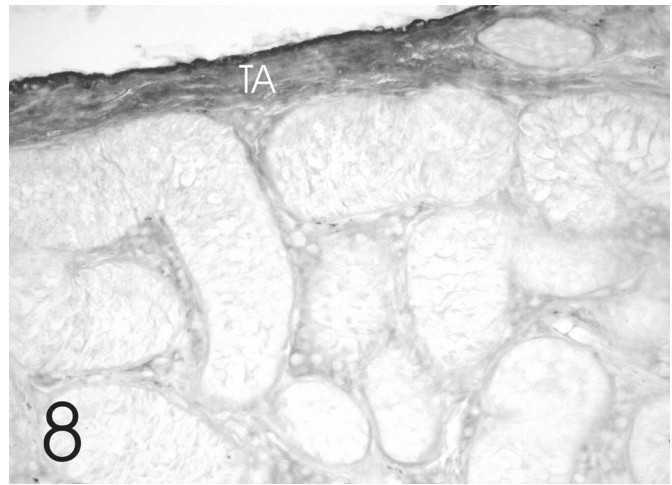
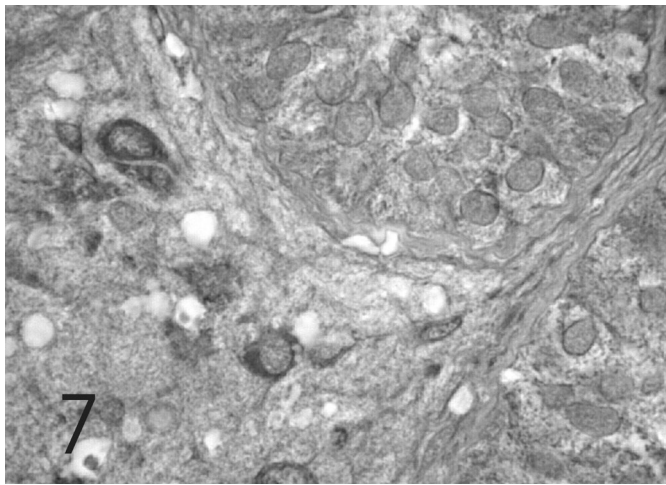
**Fig. 6.** HRP-LTA – Prepubertal testis. Moderate reactivity is observable in the Sertoli cells, spermatogonia and interstitial tissue. Only few Leydig cells (arrows) react with this lectin. x 470

*Oligosaccharides in CAIS testis*

similar to that of the patient affected by Morris' syndrome (Muller, 1984), great differences were observed with regard to the presence of sugar residues of the glycoconjugates. In fact, in the normal testis only D-galactose( $\beta$ 1 $\rightarrow$ 3)-N-acetyl-D-galactosamine, sialic acid and D-mannose were detected within the Sertoli cells.

$\alpha$ -L-fucose (LTA reactive) bound via an  $\alpha$ (1-6) linkage to the penultimate glucosaminyl residue or difucosylated oligosaccharides,  $\alpha$ -L-fucose (UEAI reactive) bound via a  $\beta$ 1,2 linkage to the penultimate D-galactose( $\beta$ 1-4)-N-acetyl-D-glucosamine residue (Debray et al., 1981; Shulte and Spicer, 1983; Foster et al., 1991) were only detected in the cytoplasm of the Sertoli cells of the prepubertal CAIS testis.

The Sertoli cells of the patient affected by Morris' syndrome showed absence of D-galactose( $\beta$ 1 $\rightarrow$ 3)-N-acetyl-D-galactosamine and sialic acid. The above mentioned oligosaccharidic distribution was also seen in the cytoplasm of the Leydig cells of the patient affected by CAIS, while the cytoplasm of the rare spermatogonia lacked N-acetyl-D-glucosamine which was detected in the same cells of the normal prepubertal testis. It is difficult to assess the physiological significance of such a different distribution of the sugar residues between the retained normal prepubertal testis and the testis of the subject affected by CAIS. However, if our data are confirmed in other CAIS patients, LTA and UEAI lectins could be considered as "markers" for the



**Fig. 7.** HRP-ConA – Prepubertal testis. The Leydig cells show strong reactivity. x 1280

**Fig. 8.** HRP-SBA – Postpubertal testis. Strong reactivity is observable in the tunica albuginea (TA). x 470

**Fig. 9.** HRP-PNA – Postpubertal testis. The lamina propria of the seminiferous tubules weakly reacts. x 230

**Fig. 10.** Neuraminidase-HRP-PNA – Postpubertal testis. Reactivity is observable in the Sertoli cells and in the endothelial cells of the capillary vessels. x 470

*Oligosaccharides in CAIS testis*

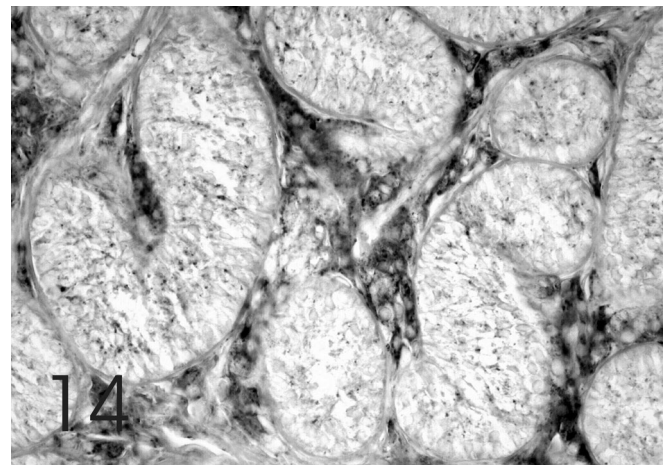
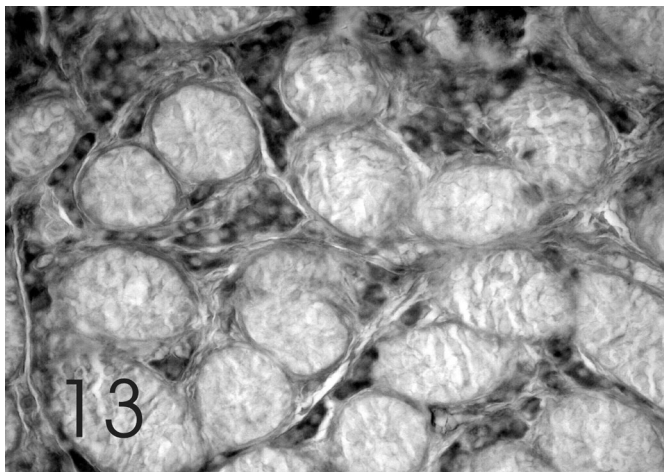
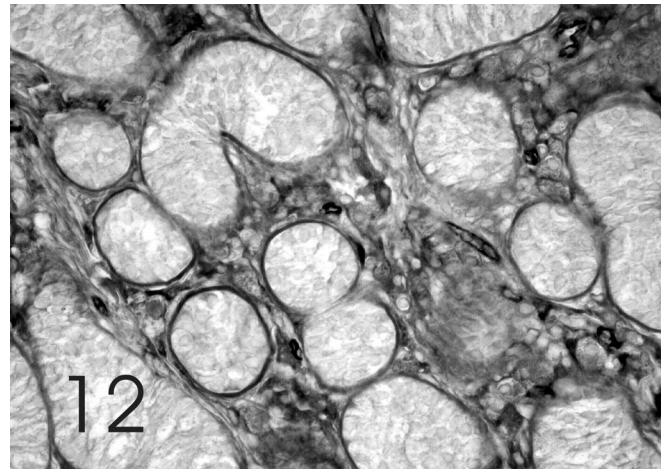
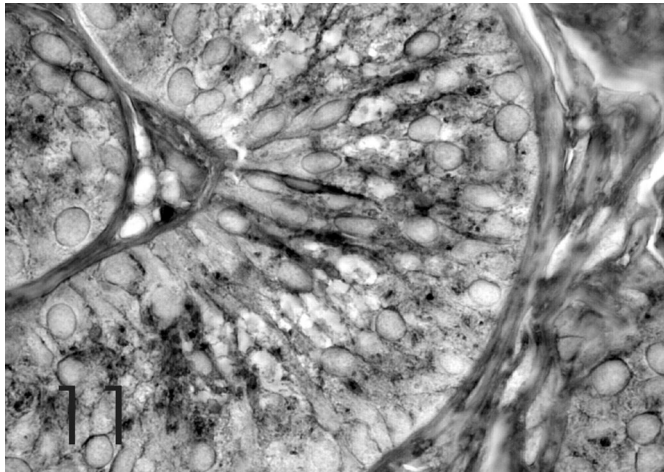
histopathological evaluation of this syndrome in the prepubertal testis.

Sertoli cells of the postpubertal testis were characterised by the presence of sialic acid, masking D-galactose( $\beta 1 \rightarrow 3$ )-N-acetyl-D-galactosamine; cytoplasmic granules, mainly placed in the apical portion of the cell, containing D-glucosamine residues and granules containing D-Mannose were detected. A little amount of  $\alpha$ -L-fucosyl residues, which bound only LTA, was observed within these cells. This finding suggests that the Sertoli cells in the postpubertal testis are characterised by  $\alpha$ -L-fucose bound via an  $\alpha$ -(1-6) linkage to the penultimate glucosaminyl residue or by difucosylated oligosaccharides.

The labelling of different lectins in the cytosol of the Sertoli cells could be related to their secretory activity. It

is well known that the Sertoli cells secrete paracrine factors that control both spermatogenesis as well as peritubular and Leydig cells (Skinner, 1993; Arenas et al., 1998). Sertoli cells are also involved in the production of extra cellular matrix and basement membrane (Raychoundhury, 1993; Dym, 1994). Furthermore Wight et al. (1992) claimed that proteoglycans produced by the Sertoli cells were involved in determining and maintaining tissue architecture, cell adhesion and migration.

It is noteworthy that N-acetyl-D-galactosamine seemed to be a unique feature of the prepubertal CAIS Sertoli cells. On the contrary, sialic acid and  $\alpha$ -L-fucose bound via  $\beta 1,2$  linkage to the penultimate D-galactose ( $\beta 1-4$ )-N-acetyl-D-glucosamine in the cytoplasmic granules seem to be a peculiar characteristic of the



**Fig. 11.** HP-WGA–Postpubertal testis. The Sertoli cells strongly react with this lectin. x 1280

**Fig. 12.** HRP- UEAI–Postpubertal testis. Strong reactivity is observable in the lamina propria of the seminiferous tubules and in the Leydig cells. x 470

**Fig. 13.** HRP-LTA–Postpubertal testis. The Leydig cells show strong reactivity. x 470

**Fig. 14.** HRP- ConA. Postpubertal testis. The Sertoli cells show weak reactivity. Strong reactivity is observable in the Leydig cells. x 470



postpubertal CAIS Sertoli cells.

Leydig cells showed similar lectin histochemical characteristics in the prepubertal and postpubertal CAIS testes.

Comparing our results on the postpubertal testis with those obtained on the testis of healthy adult subjects, some significant differences are to be noted.

$\alpha$ -L-fucose, although weakly reactive with LTA, within the Sertoli and the Leydig cells, seemed to be a unique feature of the subject affected by Morris's syndrome.

It could be hypothesized that  $\alpha$ -L-fucose (LTA reactive) bound via  $\alpha$ (1-6) linkage to the penultimate D-glucosaminyl residue, which was also detected in the retained prepubertal testis, could play a role in determining and/or maintaining the immaturity of the Sertoli cells (Aumuller and Peter, 1986; Regadera et al., 1999). If our data are confirmed in the postpubertal testes in other CAIS patients, the LTA lectin could be considered as a "marker" for the histopathological evaluation of this syndrome.

Another interesting difference was the presence of D-galactose-N-acetyl-D-galactosamine in the Leydig cells in the subject affected by Morris's syndrome and the absence of this sugar residue in the same cells of the normal one. On the contrary, while the Leydig cells of the normal testis showed the presence of D-galactose ( $\beta$ 1 $\rightarrow$ 3)-N-acetyl-D-galactosamine and sialic acid, these sugar residues were never observed within the Leydig cells of the postpubertal patient affected by complete androgen insensitivity syndrome.  $\alpha$ -L-fucose and/or D-galactose-N-acetyl-D-galactosamine could be responsible for the hyperplasia of the Leydig cells, which is a common finding in this pathology (Regadera et al., 1999).

The interstitial tissue of the postpubertal testis showed a slight content of  $\alpha$ -L-fucose bound via an  $\alpha$ (1-6) linkage to the penultimate glucosaminyl residue and/or of difucosylated oligosaccharides, which was not detected in the testis of the healthy subject. The presence of  $\alpha$ -L-fucose and the absence of N-acetyl-D-glucosamine in the lamina propria surrounding the seminiferous tubules of the postpubertal testis could have some significance in differentially regulating the exchanges between the Sertoli cells and the interstitial tissue and vice versa.

In conclusion, our data seem to indicate that the Leydig cells of the CAIS patient show a similar glycoproteic pattern before and after the puberty, different from that of the normal subjects.

The Sertoli cells of the CAIS patient, which are not affected by the action of testosterone due to the absence

of an androgenic receptor are, however, characterized by a process of pubertal glycoproteic differentiation, analogous to that of the normal subjects. However, probably because of the effect of testosterone, this process in the normal testis appears different from that in the CAIS testis with respect to types of sugar residues of the glycoconjugates.

## References

- Arenas M.I., Madrid J.F., Bethencourt F.R., Fraile B. and Paniagua R. (1998). Lectin binding of the human testis. *Int. J. Androl.* 21, 332-342.
- Aumuller G. and Peter S. (1986). Immunohistochemical and ultrastructural study of the Sertoli cells in androgen insensitivity. *Int. J. Androl.* 9, 99-108.
- Debray H., Decout D., Strecker G. and Montreuil G. (1981). Specificity of twelve lectins towards oligosaccharides and glycopeptides related to N-glycosylproteins. *Eur. J. Biochem.* 117, 41-55.
- Dym M. (1994) Basement membrane regulation of Sertoli cells. *Endocr. Rev.* 15, 102-115.
- Foster J.D., Getchell M.L. and Getchell T.V. (1991) Identification of sugar residues in secretory glycoconjugates of olfactory mucosae using lectin histochemistry. *Anat. Rec.* 229, 525-544.
- Lee M.C. and Damjanov I. (1985) Lectin binding sites on human sperm and spermatogenic cells. *Anat. Rec.* 212, 282-287
- Malmi R., Kallajoki, M. and Suominen J. (1987) Distribution of glycoconjugates in human testis. A histochemical study using fluorescein- and rhodamine- conjugated lectins. *Andrologia* 19, 322-332
- Muller J. (1984). Morphometry and histology of gonads from twelve children and adolescent with androgen insensitivity (testicular feminization) syndrome. *J. Clin. Endocrinol. Metab.* 59, 785-789
- Murata F., Tzuyama, S., Suzuky, S., Hamada, H., Ozaka, M. and Muramatsu T. (1983). Distribution of glycoconjugates in the kidney studied by use of labelled lectins. *J. Histochem. Cytochem.* 31(1a suppl.), 139-144
- Raychoudhury S.S., Blackshaw A. and Irving M.G. (1993) Hormonal modulations of the interactions of cultured rat testicular Sertoli and peritubular myoid cells. Effects on glycosaminoglycan synthesis. *J. Androl.* 14, 9-16.
- Regadera J., Martinez-Garcia F., Paniagua R. and Nistal M. (1999) Androgen insensitivity syndrome: an immunohistochemical, ultrastructural, and morphometric study. *Arch. Pathol. Lab. Med.* 123, 225-234
- Schulte B.A. and Spicer S.S. (1983) Histochemical evaluation of mouse and rat kidneys with lectin horseradish peroxidase conjugates. *Am. J. Anat.* 186, 345-362
- Skinner M. K. (1993). Secretion of growth factors and other regulatory factors. In: the Sertoli cells. Russel L.D. and Griswald M.D. (eds). Cache River Press, Clearwater, FL. pp 237-247.

Accepted June 9, 2003