



UNIVERSITÀ  
DEGLI STUDI  
FIRENZE

# FLORE

## Repository istituzionale dell'Università degli Studi di Firenze

### **BILATERAL CHONDROMA OF THE AURICLE**

Questa è la Versione finale referata (Post print/Accepted manuscript) della seguente pubblicazione:

*Original Citation:*

BILATERAL CHONDROMA OF THE AURICLE / R. QUERCETANI; R. GELLI; N. PIMPINELLI; U. REALI. - In: THE JOURNAL OF DERMATOLOGIC SURGERY AND ONCOLOGY. - ISSN 0148-0812. - STAMPA. - 14:(1988), pp. 436-438.

*Availability:*

The webpage <https://hdl.handle.net/2158/25499> of the repository was last updated on

*Terms of use:*

Open Access

La pubblicazione è resa disponibile sotto le norme e i termini della licenza di deposito, secondo quanto stabilito dalla Policy per l'accesso aperto dell'Università degli Studi di Firenze (<https://www.sba.unifi.it/upload/policy-oa-2016-1.pdf>)

*Publisher copyright claim:*

La data sopra indicata si riferisce all'ultimo aggiornamento della scheda del Repository FloRe - The above-mentioned date refers to the last update of the record in the Institutional Repository FloRe

(Article begins on next page)

*Bilateral Chondroma  
of the Auricle*

ROBERTO QUERCETANI, M.D.  
RICCARDO GELLI, M.D.  
NICOLA PIMPINELLI, M.D., Ph.D.  
UMBERTO M. REALI, M.D.

CASE REPORT

# Bilateral Chondroma of the Auricle

ROBERTO QUERCETANI, M.D.  
RICCARDO GELLI, M.D.  
NICOLA PIMPINELLI, M.D., Ph.D.  
UMBERTO M. REALI, M.D.

## CASE REPORT

**Abstract.** Benign extrasosseous cartilaginous lesions are uncommon and favor mainly the soft tissues of the hands and feet. We report a case of chondroma of both auricles. This localization has not been previously reported in the literature.

### INTRODUCTION

A case of chondroma of both auricles is reported. Such tumors are relatively common in the bones, especially the finger bones.<sup>1-5</sup> The extrasosseous form (Table 1) is uncommon (about 200 cases reported in the literature) and favors mainly the soft tissues of the fingers and toes.<sup>6-8</sup> The age of onset is usually between 30-60 years of age. The case presented here is of particular interest because of the exceptional localization of the tumor. We were unable to find any analogous reports in the literature.

### CASE REPORT

A 25-year-old male came to us in March 1985, presenting two small bilateral tumors of the pinnae. The lesions had appeared 5 years before and had grown slowly, although very little, since then. Familial and clinical histories were negative. Physical examination showed on the left scapha and anti-helix a small, elongated, tautly elastic tumor (6.0 × 3.0 mm), covered by apparently healthy skin with a smooth surface and undefined margins (Fig. 1). On the right scapha, near the helical border, we detected another small tumor (2.0 × 1.0 mm) covered by healthy skin, with better defined margins than the other tumor and a fibroelastic consistency, as if there were cartilage thickening. The lesions were completely asymptomatic.

Upon incision of the left auricle, the cartilage surface was irregularly swollen. Inside there was a kidney-shaped, cystic recess with a whitish granular wall containing a thready, mucous fluid (Fig. 2).

TABLE 1  
Extraskeletal Chondroma

Localization*	(%)
Fingers	80
Hands } Toes } Feet } Trunk }	20
Lung } Gut } Other }	Rare

\*Most frequently found on tendon, tendon sheath, and joint capsula

Roberto Quercetani, M.D., Consultant Dermatologist, II Department of Dermatology; Riccardo Gelli, M.D., Resident, Plastic Surgery Unit; Nicola Pimpinelli, M.D., Ph.D., Fellow, II Department of Dermatology; and Umberto M. Reali, M.D., Associate Professor of Plastic Surgery, and Head, Plastic Surgery Unit, are from the University of Florence, Florence, Italy.

Address reprint requests to U.M. Reali, M.D., Chirurgia Plastica Dermatologica, Via della Pergola 58, 50121 Firenze (Italy).

The tumor on the right pinna was solid and uniform in shape. These naked-eye aspects substantiated the different clinical appearance of the two lesions.

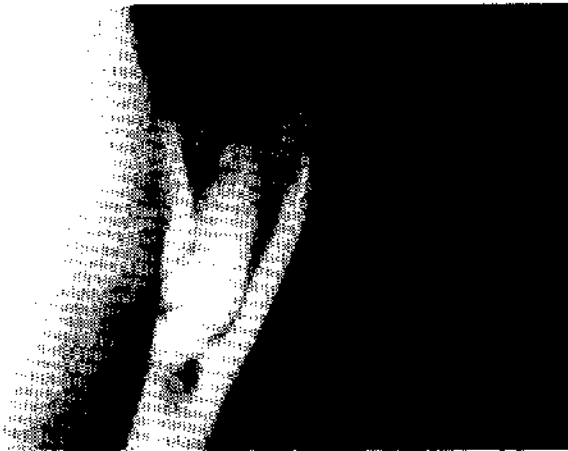

FIGURE 1. Tumor of the left auricle; clinical feature.

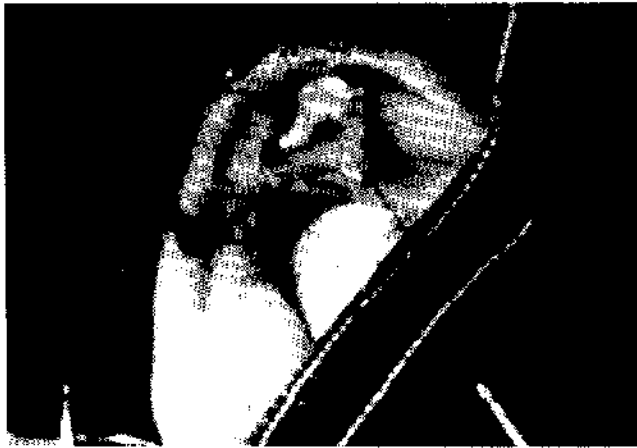

FIGURE 2. Tumor of the left auricle; note the kidney-shaped cystic recess.




FIGURE 4. Tumor of the left auricle; histologic finding: well evident typical chondrocytes (high magnification).

On histologic examination, hyaline cartilaginous tissue, rich in typical chondrocytes, was found inside the elastic cartilage of the auricle (Fig. 3). The chondrocytes were uniform in size with evident small nuclei (Fig. 4); they were gathered in isogen groups in some fields, with frequent mitotic figures. The specimen from the left pinna showed pseudocystic aspects (Fig. 3). There were small lacunae without separate walls. These features were absent in the specimen from the right ear (Fig. 5).

DISCUSSION

On the basis of the data referred, we made a diagnosis of extraskeletal chondroma. The lesions are typically single, only exceptionally bilateral,<sup>9</sup> and are comprised of small tumors, usually hard, but sometimes tautly elastic with a cystic aspect. In about 2/3 of the cases, histologic examination shows



FIGURE 3. Tumor of the left auricle; histologic finding: see the hyaline cartilaginous tissue, rich in typical chondrocytes, with pseudocystic lacunae (low magnification).




FIGURE 5. Tumor of the right auricle; histologic finding: the pseudocystic aspect is absent.

a mature hyaline cartilage<sup>10</sup> whose structure is sometimes altered by focal fibrosis (fibrochondroma), ossification (osteochondroma), or myxoid transformation (myxochondroma). In the other third of the cases, focal or diffuse calcification may convert the original shape of the lesion, masking its cartilaginous origin.<sup>6,10</sup> In conclusion, the present case is particularly worthy of attention because (1) the localization of the lesions is previously unreported, (2) bilateral lesions are uncommon, and (3) we found mature hyaline cartilage in the elastic cartilage of the auricles. This latter feature supports the opinion of many authors<sup>11-17</sup> that chondroma is a hamartoma.

## REFERENCES

1. Apfelberg DB, Druker D, et al. Subungual osteochondroma. Differential diagnosis and treatment. *Arch Dermatol* 115:472, 1979.
2. Campanacci M, Leonessa C, Boni A. Tumori cartilaginei dello scheletro della mano. *Chirurgia degli organi di movimento* 62:483-490, 1978.
3. Fornasier VL. Periosteal chondroma. *Clin Orthop* 124:233, 1977.
4. Jaffe HL. Juxtacortical chondroma. *Bull Hosp J Dis Orthop Inst* 17:20, 1956.
5. Lichtenstein L, Hall JE. Periosteal chondroma. A distinctive benign cartilage tumor. *J Bone J Surg* 34A:691, 1952.
6. Chung EB, Enzinger FM. Benign chondromas of soft parts. *Cancer*, 41:1414, 1978.
7. Dahlin C, Salvador H. Cartilaginous tumors of the soft tissues of the hands and feet. *Mayo Clin Proc* 49:721, 1974.
8. Lichtenstein L, Goldman RL. Cartilage tumors in soft tissues, particularly in the hand and foot. *Cancer* 17:1203, 1964.
9. Dellon A, Weiss SW, Mitch WE. Bilateral extraosseous chondromas of the hand in a patient with chronic renal failure. *Am Soc Surg Hand*, 3:139, 1978.
10. Enzinger FM, Weiss SW. Cartilaginous tumors and tumor like lesions of soft tissue. In: *Soft Tissue Tumors*. St. Louis, C.V. Mosby Company, 1983, pp 698-715.
11. Virchow R. Über die entstehung des enchondrom und seine beziehuns zur ecchondrosis und exostosis cartilaginea. *Montasberichte d Kgl Preufs Akad Wissenschaften* 760, 1875.
12. Hume JB. The causation of multiple exostoses. *Br J Surg* 17:236, 1929.
13. Muller E. Über hereditare multiple cartilagine exostosen und ecchondrosen. *Beitr Pathol Anat Allg Pathol* 57:232, 1913-1914.
14. Keith A. Studies on the anatomical changes which accompany certain growth disorders of the human body. I. The nature of the structure alterations in the disorder known as multiple exostoses. *J Anat* 54:101, 1920.
15. Jaffe HL. Hereditary multiple exostosis. *Arch Pathol* 36:335, 1943.
16. Jaffe HL. *Tumors and Tumorous Conditions of the Bones and Joints*. Philadelphia, Lea & Febiger, 1958.
17. Mülgram JW. The origins of osteochondromas and enchondromas. *Clin Orthop Relat Res* 174:264, 1983.