



UNIVERSITÀ
DEGLI STUDI
FIRENZE

FLORE

Repository istituzionale dell'Università degli Studi di Firenze

CD36(OKM5)+ dendritic cells in the oral mucosa of HIV- and HIV+ subjects

Questa è la Versione finale referata (Post print/Accepted manuscript) della seguente pubblicazione:

Original Citation:

CD36(OKM5)+ dendritic cells in the oral mucosa of HIV- and HIV+ subjects / PIMPINELLI N.; BORGOGNONI L.; RICCARDI R.; FICARRA G.; MORI M.; GAGLIOTI D.; P. ROMAGNOLI. - In: JOURNAL OF INVESTIGATIVE DERMATOLOGY. - ISSN 0022-202X. - STAMPA. - 97:(1991), pp. 537-542.

Availability:

The webpage <https://hdl.handle.net/2158/309890> of the repository was last updated on

Terms of use:

Open Access

La pubblicazione è resa disponibile sotto le norme e i termini della licenza di deposito, secondo quanto stabilito dalla Policy per l'accesso aperto dell'Università degli Studi di Firenze (<https://www.sba.unifi.it/upload/policy-oa-2016-1.pdf>)

Publisher copyright claim:

La data sopra indicata si riferisce all'ultimo aggiornamento della scheda del Repository FloRe - The above-mentioned date refers to the last update of the record in the Institutional Repository FloRe

(Article begins on next page)

CD36(OKM5)+ Dendritic Cells in the Oral Mucosa of HIV- and HIV+ Subjects

Nicola Pimpinelli, Lorenzo Borgognoni, Rossella Riccardi, Giuseppe Ficarra, Moira Mori, Domenico Gaglioti, and Paolo Romagnoli

Clinica Dermatologica II (NP, LB, MM) Chair of Maxillo-facial Surgery (GF, DG), and Department of Human Anatomy and Histology (RR, PR), Section Histology "E, Allara," University of Florence, Italy

In this study, we have investigated by light and electron microscopy the presence, distribution, and inner structure of CD36(OKM5)+ dendritic cells (DC) in the lamina propria and epithelium of the oral mucosa of HIV- and HIV+ subjects; in the latter, both clinically healthy areas and areas of hairy leukoplakia (HL) were studied. Perivascular CD36+ DC were present in the lamina propria of all the specimens studied. They were also found in small numbers in the epithelium of clinically healthy mucosa of HIV- and HIV+ subjects, but were practically absent from the epithelium of HL. CD36+ DC seemed to be regularly HLA-DR+ in HIV- subjects; this positivity was recognized only in some cells in the clinically healthy mucosa of HIV+ subjects, and practically never in HL. Because the only perivascular cells ob-

served in the clinically healthy areas of HIV+ subjects were CD36+, we investigated the ultrastructure of perivascular DC in these same areas. These cells were characterized by the presence of a prominent Golgi apparatus, many lysosomes, and focal adhesions to the extracellular matrix. It may be concluded that 1) CD36+ DC are physiologic components of the oral mucosa, 2) they share some ultrastructural features with macrophages, 3) no differences in numbers were found between HIV+ and HIV- subjects, and 4) these cells are affected in their expression of HLA-DR antigens during HIV infection, particularly in areas of HL. This may be a hint that the antigen-presenting function of these cells in the oral mucosa is negatively affected during HIV infection. *J Invest Dermatol* 97:537-542, 1991

The CD36 antigen is expressed by most peripheral blood monocytes [1-4]. This antigen is recognized by the monoclonal antibody (MoAb) OKM5 and possibly corresponds to the membrane-binding site for thrombospondin, a protein involved in cell adhesion [5]. A subset of CD36+, CD11b(OKM1)- peripheral blood monocytes are potent activators of autologous T cells in vitro, even in the absence of any added antigen [2,6-8]. This function is shared by epidermal ultraviolet (UV)-induced dendritic cells (DC), which are CD36+, CD1a-, CD11b-, and HLA-DR+ [9-13].

Recently, a population of CD36+ DC has been identified in normal human skin. These cells are usually—though not exclusively—located around dermal blood vessels [14-18]; few of them are found in the basal epidermal layers [19,20]. They are CD1a-, CD11b-, CD11c-, CD14-, and HLA-DR+, and seem to be capable of initiating T-cell-mediated delayed-type hypersensi-

tivity immune responses in vivo [17]. By electron microscopy, they have been preliminarily characterized as dendritic in shape and containing a folded nucleus, many mitochondria, and some lysosomes [21].

In the clinically normal epidermis of the subjects infected by human immunodeficiency virus (HIV), CD36+ DC are well represented, and it has been suggested that they play a more relevant role in mediating cutaneous immune responses in HIV+ people than in normal subjects [22].

The oral mucosa of HIV+ subjects may be affected by several diseases, which often herald full-blown acquired immunodeficiency syndrome (AIDS) [23-25]. Alterations in the number of CD1a+ Langerhans cells have been demonstrated in one of these oral diseases (hairy leukoplakia [HL]), but only in the lesional mucosa [26,27]. It remains to be found whether CD36+ DC exist in the lamina propria and epithelium of oral mucosa, which is their fine structure, and whether they are altered in number or immune phenotype in HIV+ subjects compared with HIV- people. To address this issue, we have investigated by immunohistochemistry and electron microscopy the clinically healthy oral mucosa of HIV- and HIV+ subjects, and by immunohistochemistry also areas of HL in HIV+ subjects.

MATERIALS AND METHODS

Patients and Biopsies Punch biopsies were obtained from 29 HIV+ patients (21 men and 8 women, median age 27 years, range 20-50 years) and eight HIV- subjects (three men and five women, median age 34 years, range 22-60 years). Twenty-four of these patients belong to a previously described group of subjects with HL [23-25].

Both lesional and perilesional lingual mucosa were biopsied in HL patients; other biopsies were obtained either from clinically healthy lingual mucosa of HIV+ and HIV- subjects or from appar-

Manuscript received July 31, 1990; accepted for publication February 4, 1991.

Research supported by the Italian Ministries of University and Scientific and Technologic Research (40% and 60% University Funds) and of Health (National Health Service, USL Florence 10/D). Preliminary results were presented at the 20th Annual Meeting of the European Society for Dermatological Research (Turin, June 9-12, 1990).

Reprint requests to: Dr. Nicola Pimpinelli, Clinica Dermatologica II, Via della Pergola 58, I-50121 Firenze, Italy.

Abbreviations:

- APAAP: alkaline phosphatase anti-alkaline phosphatase
- DC: dendritic cells
- HIV: human immunodeficiency virus
- HL: hairy leukoplakia
- MoAb: monoclonal antibody(ies)
- UEA-I: Ulex Europaeus Agglutinin I
- UV: ultraviolet

Table I. Monoclonal Antibodies Used and Quantitative Assessment of Immunostained Cells^a

MoAb	Source	CD	Epithelium ^b		Lamina Propria ^c	
			HL	HIV+/HIV- ^d	HL	HIV+/HIV- ^e
OKM5	OD ^f	CD36	0	2-5/2-4	6-9	13-20/13-22
anti-HLA DR	BD ^g	—	0	0-2/8-13	0-3	3-5/12-15
OKT6	OD	CD1a	1-3	9-16/11-21	8-23 ^h	-/-
OKM1	OD	CD11b	1-4	0/0	6-9	5-9/2-8
Leu M5	BD	CD11c	5-8	0/0	8-12	6-12/4-10
Leu M3	BD	CD14	3-7	0/0	6-11	5-8/3-8

^a See [4].

^b Immunostained cells in the epidermis overlying 100 basal cells.

^c Immunostained cells per 100 cells.

^d HIV+: either oral mucosa from HIV infected subjects without HL (n = 5) or perilesional, clinically healthy mucosa from patients with HL (n = 24); HIV-: clinically healthy oral mucosa from HIV- subjects (n = 8).

^e Almost exclusively found in perivascular location, clustered with T cells (for further details, see [27]).

^f OD, Ortho Diagnostic Systems, Raritan, NJ.

^g BD, Becton & Dickinson, Sunnyvale, CA.

ently healthy gingiva of HIV- subjects. Each tissue specimen was in part formalin-fixed and paraplast-embedded for routine histologic examination, in part embedded in ornithine carbonyl transferase (OCT) ("Tissue Tek," Miles Scientific, Naperville, IL), snap frozen, and stored at -80°C until sectioning and preparation for immunohistochemistry. Part of the biopsies of clinically healthy lingual mucosa from three HIV+ subjects were also prepared for electron microscopy.

Immunohistochemistry Cryostat sections (6 µm) were air-dried, fixed in acetone for 10 min, and processed with enzyme-labeled antibodies and fluorochrome-labeled antibodies.

Enzyme-Labeled Antibodies: Sections were processed according to indirect peroxidase [28] and alkaline phosphatase anti-alkaline phosphatase (APAAP) methods [29]. Normal human lymph nodes were stained in parallel as positive controls. Sections incubated with isotype-matched mouse MoAb at the same concentration instead of primary MoAb were used as negative controls. The step section method was used to evaluate results; serial sections of each tissue specimens were carefully evaluated by two of us (NP and LB). For a quantitative analysis, the stained cells were counted in five consecutive microscopic fields (×250), both in the lamina propria and in the epithelium. The results in the lamina propria were expressed as the number of stained cells per 100 observed cells; those in the epithelium were expressed as the number of stained cells overlying 100 basal cells. Only cells whose nuclei were contained in the plane of the section were considered. The results were scored independently by the two authors, and the resulting figures were averaged. The antibodies used are listed in Table I; their specificities have been reviewed elsewhere [4]. To rule out the possibility that OKM5 staining of DC was associated with vascular staining, serial sections were incubated with biotin-conjugated Ulex Europaeus Agglutinin-I (UEA-I), a marker for endothelial cells, and processed according to an indirect immunoperoxidase technique [28].

Fluorochrome-Labeled Antibodies: Cryostat sections were processed according to a double-label, indirect immunofluorescence technique [21] in 13 of 29 HIV+ subjects and four of eight HIV- subjects. The following sequence of MoAb and fluorochrome-conjugated antisera was used: 1) OKM5 MoAb; 2) biotin-conjugated goat anti-mouse (Amersham, Buckinghamshire, UK); 3) streptavidin-conjugated Texas Red (Amersham); 4) mouse Ig to block the secondary antibody; 5) FITC-conjugated anti-HLA-DR MoAb (Ortho Diagnostic Systems, Raritan, NJ). In negative controls, the primary MoAb was replaced with an isotype-matched mouse MoAb. No specific fluorescence was detected in skin sections incubated with any of the fluorochrome-conjugated antisera used alone.

Electron Microscopy The tissue was fixed with 2.5% formaldehyde and 2.0% glutaraldehyde in 0.1 M cacodylate buffer, pH 7.4, followed by 1.0% OsO₄ in 0.1 M phosphate buffer, pH 7.4, and

embedded in Epon 812. Ultrathin sections were stained with uranyl acetate and bismuth tartrate and observed in a Siemens Elmiskop I and a 102, at 80 kV.

RESULTS

Light Microscopy

Enzyme-Labeled Antibodies: We have found CD36+ DC in both the lamina propria and epithelium of the oral mucosa. No substantial differences in the number and distribution of these cells were found between the different groups of specimens, except for HL, where CD36+ DC were practically absent from the epithelium.

In the lamina propria, CD36+ DC were regularly distributed around blood capillaries (Fig 1 and 2A); these cells were differentiated from endothelial ones because of both their dendritic shape and their unreactivity with UEA-I in serial sections (Fig 2B). The number of HLA-DR+ DC, both in areas of HL and in the clinically healthy mucosa of HIV+ subjects, was much lower than that of CD36+ DC (Fig 3), whereas these numbers were similar to each other in HIV- subjects. No CD1a+ DC were found in the lamina propria of clinically healthy mucosa of either HIV- or HIV+ subjects; in areas of HL, CD1a+ DC were found in perivascular location, associated with T cells (data shown in [27]). The numbers of CD11b+, CD11c+, and CD14+ cells were fairly constant and always very low among all the examined specimens. These cells were interspersed between collagen bundles, independent of capillaries; no CD36+ or HLA-DR+ cells were found in this location.

In the epithelium, CD36+ DC were usually scarce in the specimens of clinically healthy mucosa of HIV- and HIV+ subjects; they were localized in both the basal and suprabasal layers (Fig 1 and 4). The number of intrac epithelial HLA-DR+ DC was much lower in HIV+ subjects than in HIV- subjects (Fig 3), although the numbers of CD1a+ and CD36+ DC were similar between the two groups of subjects. In HL, the finding of CD36+ cells in the epithelium was absolutely exceptional. Quantitative data are given in Table I.

Fluorochrome-Labeled Antibodies: In both the epithelium and lamina propria, CD36+ DC regularly co-expressed HLA-DR antigen in HIV- subjects; conversely, in HIV+ subjects the DC staining positively for both CD36 and HLA-DR was less than 40% of the DC staining positively for CD36 only.

Electron Microscopy We took advantage of the clear-cut compartmentalization of CD1a+ and CD36+ DC between the epithelium and lamina propria of the clinically healthy mucosa of HIV+ subjects (see Table I) to investigate the fine structure of DC around blood capillaries of the oral mucosa. In this location, where only CD36+ DC were recognized by light microscopical immunohistochemistry, cells dendritic in shape were also identified by electron microscopy.

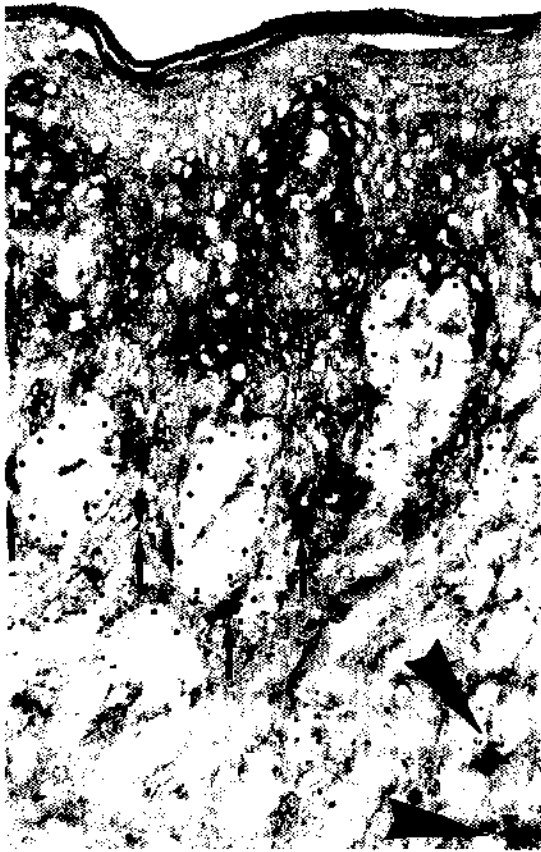

Figure 1. Dendritic cells stained by anti-CD36 monoclonal antibody are shown in the epithelium (*arrows*) and in the lamina propria (*arrowheads*) of the clinically healthy lingual mucosa of an HIV+ subject (APAAP, magnification $\times 160$).

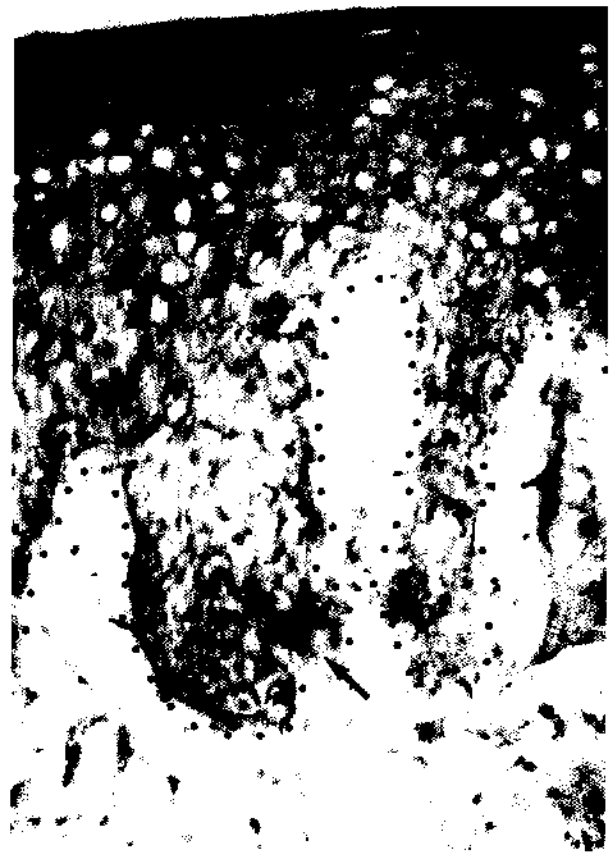

Figure 3. No cells stained by anti-HLA-DR monoclonal antibody can be recognized in the lamina propria of the clinically healthy lingual mucosa of a HIV+ subject; only one stained cell is visible in the epithelium (*arrow*) (APAAP, magnification $\times 160$).

These cells had an oval nucleus, with pale chromatin except for a thin peripheral rim (Fig 5). They contained some cisternae of rough endoplasmic reticulum, a few smooth tubules and vesicles, a prominent Golgi apparatus, and numerous dense, round, membrane-bound bodies, about 1 μm in diameter (presumably lysosomes). Few of these latter bodies were near the Golgi apparatus; instead, most were gathered outside the Golgi region. The content of these bodies was either homogeneous or included one or a few round densities, mostly located at the periphery (Fig 5).

Areas of focal adhesion to the extracellular matrix were sometimes observed at the surface of these cells. These areas consisted of thin, dense patches at the inner side of the plasma membrane, into which thin cytoplasmic filaments converged, and of focal, linear

densities in the extracellular space adjacent to the plasma membrane (Fig 6).

DISCUSSION

In this study, DC expressing CD36 antigen were found in the lamina propria and epithelium of the oral mucosa in both HIV- and HIV+ subjects. The numbers of these cells were not significantly different between the biopsies of the HIV- subjects and the clinically healthy mucosa of HIV+ subjects. On the contrary, the expression of HLA-DR by CD36+ DC was much lower in HIV+



Figure 2. A, Perivascular dendritic cells stained by anti-CD36 monoclonal antibody (*arrow*) in the lamina propria of the tongue of an HIV+ subject (APAAP, magnification $\times 400$); B, UEA-1+ vessels (*arrowhead*) are shown in a serial section of the same specimen (immuno-peroxidase, magnification $\times 400$).



Figure 4. CD36+ DC in the basal epithelial layer of the tongue of an HIV- subject (*arrows*) (APAAP, magnification $\times 630$).

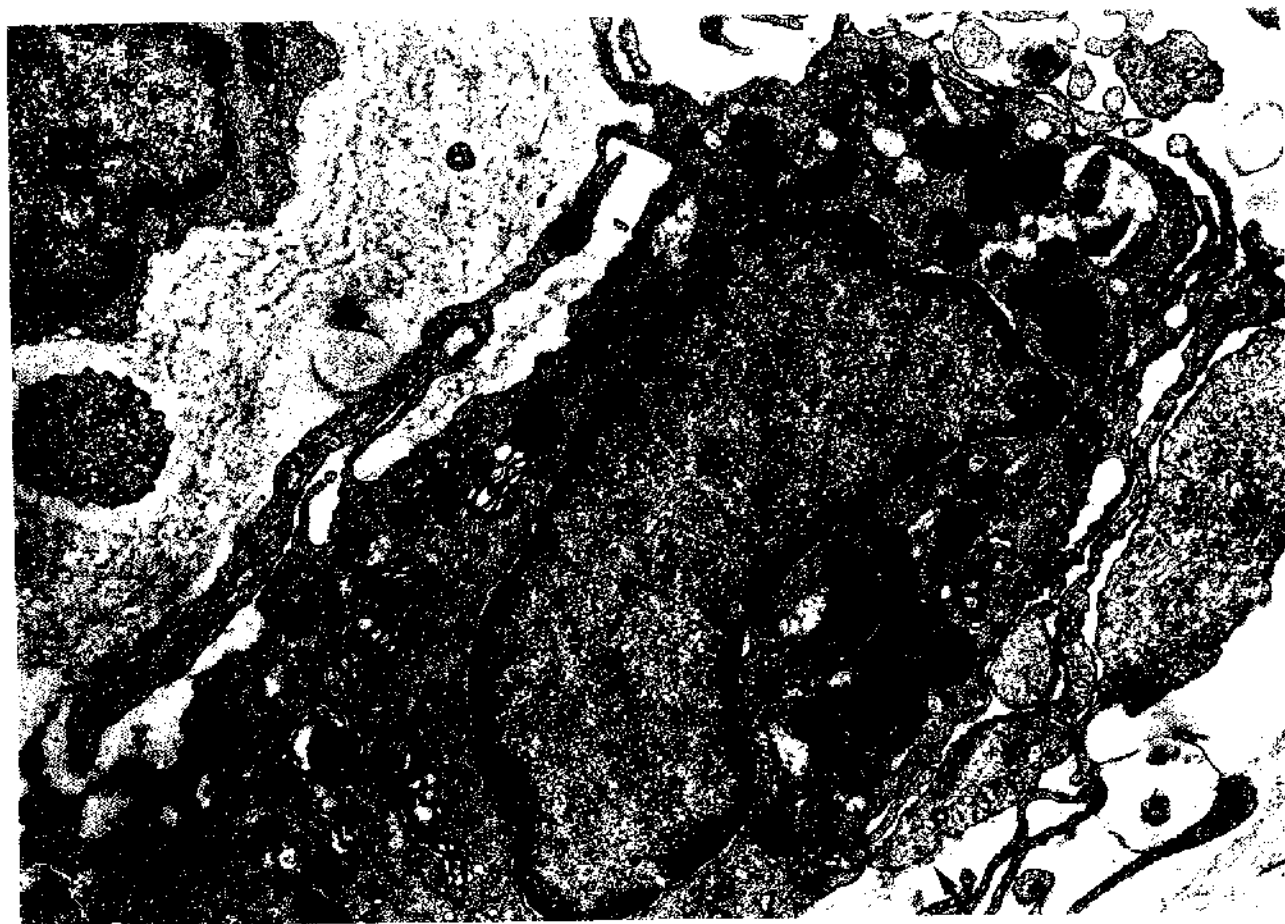


Figure 5. Dendritic cell close to a blood capillary in the clinically healthy mucosa of an HIV+ subject. Part of an endothelial cell (E) is included in the photomicrograph. Note the prominent Golgi apparatus (GO) and the clusters of dense bodies (*) outside the Golgi region. A focal adhesion to the extracellular matrix is indicated by the arrow (Electron microscopy, magnification $\times 17,000$).

subjects compared to HIV- subjects. In HL, CD36+ DC were practically absent from the epithelium, but present in the lamina propria.

To the best of our knowledge, this is the first report of CD36+ DC in oral tissues. In the oral mucosa, as well as in the skin, these cells are usually located around blood vessels in the lamina propria, and few of them are found within the epithelium. It may be proposed that these cells participate in local immune responses, similarly to their counterpart in the skin [17].

We were not able to identify cells of the oral mucosa strictly corresponding to the "perivascular dendritic macrophages" in the skin described by Sontheimer [30] and defined, in addition to shape and location, as being CD36-, CD11b+, and HLA-DR+ [21,30]. However, we cannot exclude that this discrepancy is due to modulation of the expression of membrane antigens within a single cell type.

In the lamina propria of oral mucosa, CD1a+ DC were virtually absent, which differs from what is a common finding (including ours) in the dermis. CD11b+ cells, CD11c+ cells, and CD14+ cells were found only independent of capillaries; in this location, no cell reacted with anti-CD36 or anti-HLA-DR antibodies differently from what was observed in the dermis of clinically normal skin [16,18]. Because of their immune phenotype and localization, these cells may be interpreted as a counterpart of dermal fixed macrophages [31].

On the basis of shape and location, we identify the perivascular DC observed by electron microscopy as the same cells that stained positively for CD36 antigen by light microscopy. The perivascular

DC described here differ in ultrastructure from Langerhans cells and interdigitating reticulum cells in having much less developed, smooth endoplasmic reticulum, more cisternae of rough endoplasmic reticulum, much more lysosomes, and focal adhesions to the extracellular matrix. These features make the cells described here like macrophages [32,33]. This is in keeping with the assumption that CD36+ cells in the skin and oral mucosa [34] may be engaged into active phagocytosis, at least toward melanin. Sontheimer et al [21] described only occasional lysosomes in the CD36+ perivascular DC of the skin. We cannot state at present if this discrepancy depends on a difference in the ultrastructure of these cells between different locations (skin versus oral mucosa) or on differences in the electron microscopy methods. In fact, we used routine preparatory methods, whereas Sontheimer et al [21] used methods suitable for immunoelectron microscopy, which affect the ultrastructure of cells otherwise than routine methods.

In the epidermis of clinically normal skin of HIV+ subjects, CD36+ DC are present in numbers equal to or higher than those found in HIV- subjects [22], whereas CD1a+ DC (Langerhans and indeterminate cells) have been reported to be diminished in number compared to HIV- subjects [35-40]. However, the decreased number of Langerhans cells in the clinically normal epidermis of HIV+ subjects has not been confirmed by recent reports on wide numbers of subjects [41,42]. On the basis of some of these results, it has been proposed that CD36+ DC play a relevant role as epithelial antigen-presenting cells in the skin of HIV+ subjects [22]. In the epithelium of the clinically healthy oral mucosa of HIV+ subjects, both CD36+ DC (this research) and CD1a+ cells [26,27,43] are similar

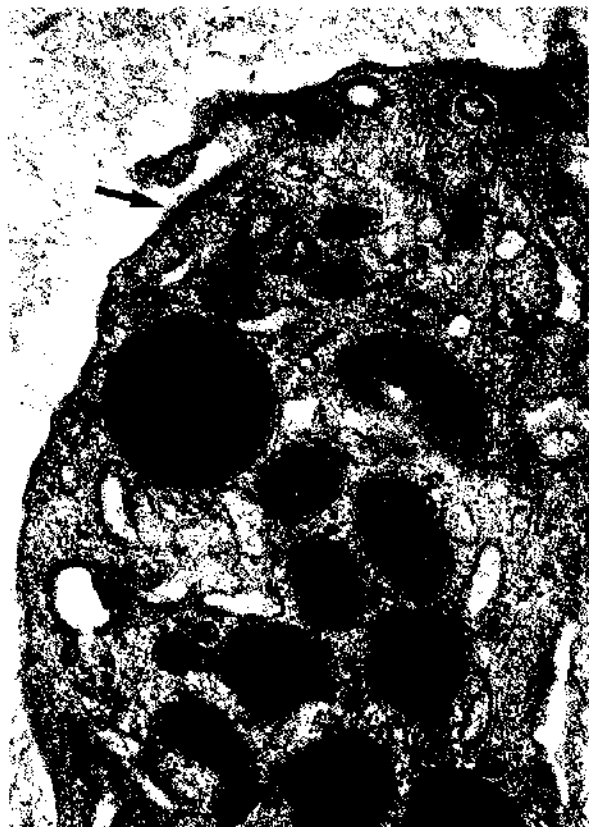

Figure 6. A perivascular dendritic cell showing a focal adhesion to the extracellular matrix (arrow); the thin filaments, the dense patch on the inner side of the plasma membrane, and the linear density in the extracellular space adjacent to the plasma membrane are clearly visible (electron microscopy, magnification $\times 37,000$).

in number to HIV⁻ subjects. Consequently, our data cannot be assumed to support the hypothesis that CD36⁺ DC of the oral mucosa play a more relevant role as epithelial antigen-presenting cells in HIV⁺ subjects than in HIV⁻ subjects.

The difference between the numbers of CD36⁺ DC and of HLA-DR⁺ DC in the lamina propria of the oral mucosa of HIV⁺ subjects indicates that only part of CD36⁺ DC was HLA-DR⁺ in HIV⁺ subjects, in contrast to those in HIV⁻ subjects (which seemed to be regularly HLA-DR⁺ on the basis of the corresponding numbers and of double-labeling immunofluorescence studies). A reduction in the expression of HLA-DR antigens has been found also for CD1a⁺ DC in HIV⁺ subjects ([27]; see also Table I). On the contrary, there are only minor differences between the numbers of CD1a⁺ and of HLA-DR⁺ DC in the oral epithelium of HIV⁻ subjects; these differences may be interpreted as due to more (CD1a) or less (HLA-DR) surface membrane-bound staining, similar to what is regularly observed in skin sections.

Because minor alterations in the immune phenotype may hint at a biologically meaningful functional impairment of antigen-presenting cells [44,45], the difference in the expression of HLA-DR antigens between the CD36⁺ DC of HIV⁺ and those of HIV⁻ subjects could imply that in the former subjects these cells are less efficient in antigen presentation than in the latter. Further insults, ineffective if isolated, could be crucial in determining a major alteration in the differentiation of these cells and consequently in local cell-mediated immune responses. Hairy leukoplakia might be a good example of a condition of greatly hampered differentiation of antigen-presenting

cells in immune deficient subjects, as shown here for CD36⁺ DC, and in a previous report on CD1a⁺ DC [27].

REFERENCES

1. Talle MA, Rao PF, Westberg E, Allegar N, Makowski M, Mittler RS, Goldstein G: Patterns of antigenic expression on human monocytes as defined by monoclonal antibodies. *Cell Immunol* 78:83-99, 1983
2. Shen HH, Talle MA, Goldstein G, Chess L: Functional subsets of human monocytes defined by monoclonal antibodies: a distinct subset of monocytes contains the cells capable of inducing the autologous mixed lymphocyte culture. *J Immunol* 130:698-705, 1983
3. Todd RF, Schlossman SF: Utilization of monoclonal antibodies in the characterization of monocyte macrophage differentiation antigens. In: Bellanti JA, Herscovitz HB (eds.). *The Reticuloendothelial System*, Vol. 6. Plenum Press, New York, 1984, pp 87-112
4. Chan JKC, Ng CS, Hui PK: A simple guide to the terminology and application of leukocyte monoclonal antibodies. *Histopathology* 12:461-480, 1988
5. Asch AS, Barnwell J, Silverstein RL, Nachman RL: Isolation of the thrombospondin membrane receptor. *J Clin Invest* 79:1054-1061, 1987
6. Smith JB, Knowlton R: Activation of suppressor T cells in human autologous mixed lymphocyte culture. *J Immunol* 123:419-421, 1979
7. Pazderka F, Angeles A, Kovithavongs T, Dossetor JB: Induction of suppressor cells in autologous mixed lymphocyte culture (AMLC) in humans. *Cell Immunol* 75:122-133, 1983
8. James SP, Yenokida GG, Greff AS, Elson CO, Strober W: Immunoregulatory function of T cells activated in the autologous mixed lymphocyte reaction. *J Immunol* 127:2605-2609, 1981
9. Cooper KD, Fox P, Neises G, Katz SI: Effects of ultraviolet radiation on human epidermal cell alloantigen presentation: initial depression of Langerhans cell-dependent function is followed by appearance of T6-Dr⁺ cells that enhance epidermal alloantigen presentation. *J Immunol* 134:129-137, 1985
10. Cooper KD, Neises G, Katz SI: Antigen presenting OKM5⁺ melanophages appear in human epidermis after ultraviolet radiation. *J Invest Dermatol* 86:363-370, 1986
11. Baadsgaard O, Wulff HC, Wantzin GL, Cooper KD: UV action spectrum for induction of T6-Dr⁺ cells in human epidermis: ultraviolet radiation of the UVB and UVC bands but not the UVA band are potent inducers of the appearance of T6-Dr⁺ antigen presenting cells in human epidermis. *J Invest Dermatol* 89:113-118, 1987
12. Baadsgaard O, Cooper KD, Lisby S, Wulff HC, Wantzin GL: Dose response and time course for induction of T6-Dr⁺ human epidermal cell population by in vivo UV-A, UV-B, and UV-C irradiation. *J Am Acad Dermatol* 17:792-800, 1987
13. Baadsgaard O, Fox DA, Cooper KD: Human epidermal cells from ultraviolet light-exposed skin preferentially activate autoreactive CD4⁺2H4⁺ suppressor-inducer lymphocytes and CD8⁺ suppressor/cytotoxic lymphocytes. *J Immunol* 140:1738-1744, 1988
14. Headington JT: The dermal dendrocyte. In: Callen JP, Dahl MV, Golitz LE (eds.). *Advances in Dermatology*, Vol. I. Yearbook Medical Publisher, Chicago, Illinois, 1986
15. Cerio R, Griffiths CEM, Cooper KD, Nickoloff BJ, Headington JT: Characterization of factor XIIIa and dermal dendritic cells in normal and inflamed skin. *Br J Dermatol* 121:421-431, 1989
16. Headington JT, Cerio R: Dendritic cells and the dermis: 1990. *Am J Dermatopathol* 12:217-220, 1990
17. Tse J, Cooper KD: Cutaneous dermal Ia⁺ cells are capable of initiating delayed type hypersensitivity responses. *J Invest Dermatol* 94:267-272, 1990
18. Weber-Marthieson K, Sterry W: Organization of the monocyte/macrophage system of normal human skin. *J Invest Dermatol* 95:83-89, 1990
19. Smolle J, Ehall R, Kerl H: Inflammatory cell types in normal human epidermis: an immunohistochemical and morphometric study. *Acta Derm Venereol (Stockh)* 65:479-484, 1985
20. Soyer HP, Smolle J, Kerl H: Distribution patterns of the OKM5 anti-

- gen in normal and diseased human epidermis. *J Cutan Pathol* 16:60-65, 1989
21. Sontheimer RD, Matsubara T, Seelig Jr LL: A macrophage phenotype for a constitutive, class II antigen-expressing, human dermal perivascular dendritic cell. *J Invest Dermatol* 93:154-159, 1989
 22. Foster CA, Volc-Platzter B, Rappersberger K, Gillitzer R, Waldig I, Stingl G: Epidermal OKM5+ cells and T cells in HIV-1 negative and positive individuals (abstr). *J Invest Dermatol* 93:299, 1989
 23. Ficara G, Barone R, Gaglioti D, Milo D, Riccardi R, Romagnoli P, Zorn M: Oral hairy leukoplakia among HIV-positive intravenous drug abusers: a clinicopathologic and ultrastructural study. *Oral Surg Oral Med Oral Pathol* 65:421-426, 1988
 24. Ficara G, Barone R, Gaglioti D, Di Pietro M, Riccardi R, Addler-Storzhz K, Shillitoe E: Oral hairy leukoplakia: clinicopathological ultrastructural and DNA hybridization findings in I.V. drug abusers (abstr). *Oral Surg Oral Med Oral Pathol* 66:571A, 1988
 25. Barone R, Ficara G, Gaglioti D, Orsi A, Mazzotta F: Prevalence of oral lesions among HIV-infected intravenous drug abusers and other risk groups. *Oral Surg Oral Med Oral Pathol* 69:169-173, 1990
 26. Daniels TE, Greenspan D, Greenspan JS, Lennette E, Schiodt M, Petersen V, de Souza Y: Absence of Langerhans cells in oral hairy leukoplakia, an AIDS-associated lesion. *J Invest Dermatol* 89:178-182, 1987
 27. Riccardi R, Pimpinelli N, Borgognoni L, Ficara G, Gaglioti D, Milo D, Romagnoli P: Morphology and membrane antigen of non-lymphoid accessory cells in oral hairy leukoplakia. *Hum Pathol* 21:897-904, 1990
 28. Hsu SH, Raine L, Fanger H: Use of avidin-peroxidase complex (ABC) in immunoperoxidase techniques. A comparison between ABC and unlabeled antibody (PAP) procedures. *J Histochem Cytochem* 29:1349-1353, 1981
 29. Cordell JL, Folini B, Erber WN, Stein H, Mason DY: Immunoenzymatic labeling of monoclonal antibodies using immune complexes of alkaline phosphatase and monoclonal anti-alkaline phosphatase (APAAP complexes). *J Histochem Cytochem* 32:219-226, 1984
 30. Sontheimer RD: Perivascular dendritic macrophages as immunobiologic constituents of the human dermal microvascular unit. *J Invest Dermatol* 93:965-1015, 1989
 31. Drijkoningen M, De Wolf-Peeters C, Van der Steen K, Moerman P, Desmet V: Epidermal Langerhans cells and dermal dendritic cells in human fetal and neonatal skin: an immunohistochemical study. *Pediatr Dermatol* 4:11-17, 1987
 32. Hoefsmit ECM, Kamperdijk EWA, Hendriks HR: Lymph node macrophages. In: Carr I, Daems WT (eds.). *The Reticuloendothelial System*, Vol I. Plenum Press, New York/London, 1980, pp 417-468
 33. Carr I: *The Macrophages. A Review of Ultrastructure and Function*. Academic Press, London, 1973
 34. Weiss JS, James WD, Cooper KD: Melanophages in inflammatory skin disease demonstrate the surface phenotype of OKM5+ antigen-presenting cells and activated macrophages. *J Am Acad Dermatol* 19:633-641, 1988
 35. Belsito DV, Sanchez MR, Baer RL, Valentine F, Thorbecke GJ: Reduced Langerhans cell Ia antigen and ATPase activity in patients with acquired immunodeficiency disease. *N Engl J Med* 310:1279-1282, 1984
 36. Armstrong JA, Dawkins RL, Horne R: Retroviral infection of accessory cells and the immunological paradox in AIDS. *Immunol Today* 6:97-98, 1985
 37. Oxholm P, Helweg-Larsen S, Permin H: Immunohistological skin investigations in patients with the acquired immunodeficiency syndrome. *Acta Pathol Microbiol Scand (sect A)* 94:113-116, 1986
 38. Tschachler E, Groh V, Popovic M, Mann DL, Konrad K, Safai B, Eron L, Di Marzo Veronese F, Wolff K, Stingl G: Epidermal Langerhans cells. A target for HTLV-III/LAV infection. *J Invest Dermatol* 88:233-237, 1987
 39. Romani N, Pichler E, Kofler H, Larcher C, Dierich M, Fritsch P, Schuler G: The fate of epidermal Langerhans cells in HIV-1 infection (abstr). *J Invest Dermatol* 89:450, 1987
 40. Dreno B, Milpied B, Bignon JD, Stalder JF, Litoux P: Prognostic value of Langerhans cells in the epidermis of HIV patients. *Br J Dermatol* 118:481-486, 1988
 41. Kanitakis J, Marchand C, Su H, Thivolet J, Zambruno G, Schmitt D, Gazzolo L: Immunohistochemical study of normal skin of HIV-1-infected patients shows no evidence of infection of epidermal Langerhans cells by HIV. *AIDS Res Hum Retroviruses* 5:293-302, 1989
 42. Manganoni AM, Groh V: Langerhans cells in HIV-1 infection: immunophenotypic characteristics of apparently healthy skin and their correlation with the stage of the disease. *Ital Gen Rev Dermatol* 26:169-176, 1989
 43. Becker J, Ulrich P, Kunze R, Gelderblom H, Langford A, Reichart P: Immunohistochemical detection of HIV structural proteins and distribution of T-lymphocytes and Langerhans cells in the oral mucosa of HIV-infected patients. *Virchows Arch* 412:413-419, 1988
 44. Clement LT: The class II major histocompatibility complex antigen deficiency syndrome: consequences of absent class II major histocompatibility antigens for lymphocyte differentiation and function. *J Invest Dermatol* 94:1185-1215, 1990
 45. Macatonia SE, Lau R, Patterson S, Pinching AJ, Knight SC: Dendritic cell infection, depletion and dysfunction in HIV-infected individuals. *Immunology* 71:38-45, 1990