



UNIVERSITÀ
DEGLI STUDI
FIRENZE

FLORE

Repository istituzionale dell'Università degli Studi di Firenze

Treatment timing for rapid maxillary expansion

Questa è la Versione finale referata (Post print/Accepted manuscript) della seguente pubblicazione:

Original Citation:

Treatment timing for rapid maxillary expansion / T. Baccetti; L. Franchi; C. G. Cameron; J. A. McNamara. -
In: ANGLE ORTHODONTIST. - ISSN 0003-3219. - STAMPA. - 71:(2001), pp. 343-350.

Availability:

The webpage <https://hdl.handle.net/2158/313827> of the repository was last updated on 2016-11-15T18:43:04Z

Terms of use:

Open Access

La pubblicazione è resa disponibile sotto le norme e i termini della licenza di deposito, secondo quanto stabilito dalla Policy per l'accesso aperto dell'Università degli Studi di Firenze (<https://www.sba.unifi.it/upload/policy-oa-2016-1.pdf>)

Publisher copyright claim:

La data sopra indicata si riferisce all'ultimo aggiornamento della scheda del Repository FloRe - The above-mentioned date refers to the last update of the record in the Institutional Repository FloRe

(Article begins on next page)

Treatment Timing for Rapid Maxillary Expansion

Tiziano Baccetti, DDS, PhD^a; Lorenzo Franchi, DDS, PhD^a; Christopher G. Cameron, DDS, MS^b; James A. McNamara Jr., DDS, PhD^c

Abstract: The aim of this study was to evaluate the short-term and long-term treatment effects of rapid maxillary expansion in 2 groups of subjects treated with the Haas appliance. Treatment outcomes were evaluated before and after the peak in skeletal maturation, as assessed by the cervical vertebral maturation (CVM) method, in a sample of 42 patients compared to a control sample of 20 subjects. Posteroanterior cephalograms were analyzed for the treated subjects at T₁ (pretreatment), T₂ (immediate post-expansion) and T₃ (long-term observation), and were available at T₁ and at T₃ for the controls. The mean age (years: months) at T₁ was 11:10 for both the treated and the control groups. The mean ages at T₃ also were comparable (20:6 for the treated group and 17:8 for the controls). Following expansion and retention (2 months on average), fixed standard edgewise appliances were placed. The study included transverse measurements on dentoalveolar structures, maxillary and mandibular bases and other craniofacial regions (nasal, zygomatic, orbital, and cranial). Treated and control samples were divided into 2 groups according to individual skeletal maturation. The early-treated and early-control groups had not reached the pubertal peak in skeletal growth velocity at T₁ (CVM 1 to 3), whereas the late-treated and late-control groups were during or slightly after the peak at T₁ (CVM 4 to 6). The group treated before the pubertal peak showed significantly greater short-term increases in the width of the nasal cavities. In the long-term, maxillary skeletal width, maxillary intermolar width, lateronasal width, and lateroorbitale width were significantly greater in the early-treated group. The late-treated group exhibited significant increases in lateronasal width and in maxillary and mandibular intermolar widths. Rapid Maxillary Expansion treatment before the peak in skeletal growth velocity is able to induce more pronounced transverse craniofacial changes at the skeletal level. (*Angle Orthod* 2001;71:343–350.)

Key Words: Rapid maxillary expansion, Haas appliance, Posteroanterior cephalograms, Cervical vertebral maturation method

INTRODUCTION

When evaluating the efficacy of an orthopedic therapeutic procedure such as rapid maxillary expansion (RME), a few aspects deserve particular consideration from a clinical point of view:

- The amount of correction of the initial disharmony;
- The differentiation between dentoalveolar and skeletal changes;
- The effectiveness of the treatment outcome in relation to treatment timing.

Previous short-term investigations have demonstrated that rapid maxillary expansion is able to eliminate a transverse discrepancy between the dental arches due to maxillary constriction.¹⁻⁹ Treatment-induced widening of the maxilla leads to the correction of posterior crossbites,^{10,11} to the coordination of the maxillary and mandibular dental arches prior to orthopedic or functional treatment of Class II and Class III malocclusions¹²⁻¹⁴ and to a gain in arch perimeter in patients with tooth-size/arch-size discrepancies.^{14,15} The few long-term RME studies have shown that increments in maxillary transverse dimension are relatively stable.^{16,17}

In our opinion, an issue that has not yet attained sufficient attention in the literature is the role of treatment timing in the determination of craniofacial modifications fol-

^a Research Associate, Department of Orthodontics, The University of Florence, Florence, Italy; Thomas M. Graber Visiting Scholar, Department of Orthodontics and Pediatric Dentistry, School of Dentistry, The University of Michigan, Ann Arbor, Mich.

^b Graduate Orthodontic Program, The University of Michigan, Ann Arbor Michigan, and private practice of orthodontics, Toronto, Ontario, Canada.

^c Thomas M. and Doris Graber Endowed Professor of Dentistry, Department of Orthodontics and Pediatric Dentistry, School of Dentistry; Professor of Cell and Developmental Biology, School of Medicine; and Research Scientist, Center for Human Growth and Development, The University of Michigan, Ann Arbor, Mich.

Corresponding author: Tiziano Baccetti, DDS, PhD, Università degli Studi di Firenze, Via del Ponte di Mezzo, 46-48, 50127, Firenze, Italy. (e-mail: condax@tin.it).

Accepted: February 2001. Submitted: January 2001.

© 2001 by The EH Angle Education and Research Foundation, Inc.

lowing RME therapy. Available information related to the ideal time for treatment of maxillary transverse deficiency by means of an orthopedic device mainly consists of studies of the growth and maturation of the intermaxillary sutural system. Melsen¹⁸ used autopsy material to histologically examine the maturation of the mid-palatal suture at different developmental stages. In the "infantile" stage (up to 10 years of age), the suture was broad and smooth, whereas in the "juvenile" stage (from 10 to 13 years) it had developed into a more typical squamous suture with overlapping sections. Finally, during the "adolescent" stage (13 and 14 years of age) the suture was wavier with increased interdigitation. In their 1982 study, Melsen and Melsen¹⁹ also included observations of the "adult" stage of the suture that noted synostoses and numerous bony bridge formations across the suture. From these histological data, the inference is that patients who show an advanced stage of skeletal maturation at the midpalatal suture may have difficulty undergoing orthopedic maxillary expansion. Clinical support for the histologic findings by Melsen is derived from the results of a study by Wertz and Dreskin⁷ who noted greater and more stable orthopedic changes in patients under the age of 12 years.

Implant studies^{20,21} have demonstrated that the transverse growth pattern of the maxilla follows distance and velocity curves similar to those for body height with similar times of growth spurt and growth completion. Thus, treatment outcomes of rapid maxillary expansion need to be evaluated with respect to stages in skeletal maturation in order to detect possible differences between subjects treated before and after the pubertal peak.

It is well known that skeletal maturation exhibits great individual variations. Skeletal maturity can be assessed by means of a series of biologic indicators: increase in statural height;^{22,23} skeletal maturation of the hand and wrist;²⁴⁻²⁶ dental development and eruption;^{5,27,28} menarche, breast and voice changes;²⁹ and cervical vertebral maturation.^{30,31} Franchi and Baccetti³² and Franchi and co-workers³³ analyzed the validity of 6 stages of cervical vertebral maturation (Cvs1 through Cvs6) as a biological indicator for skeletal maturity in 24 subjects (Figure 1). The cervical vertebral maturation (CVM) method was able to detect the greatest increment in mandibular and craniofacial growth during the interval from cervical vertebral stage 3 to stage 4 (Cvs3-Cvs4), when the peak in statural height also occurred. The prevalence rate of examined subjects who presented with the peak in statural height and in mandibular growth at this interval was 93.5%. The CVM method has been used previously for the appraisal of optimal treatment timing for the correction of Class II malocclusion by means of functional appliances such as the twin block.³⁴

The aim of this study is to evaluate differences in the dentoskeletal short-term and long-term effects of RME therapy in subjects treated before and after the pubertal growth spurt as evaluated by means of the cervical vertebral

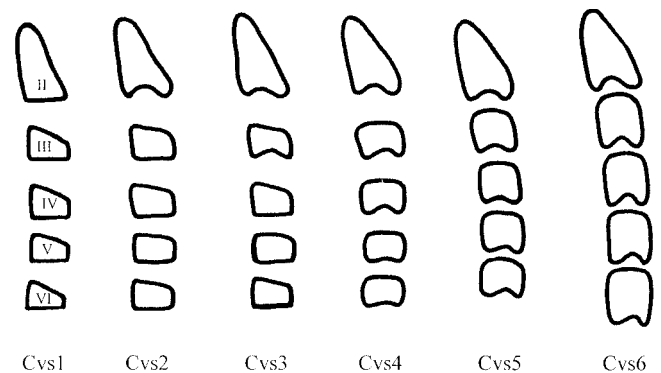


FIGURE 1. Cervical vertebral maturation method. *Stage 1 (Cvs 1):* the inferior borders of the bodies of all cervical vertebrae are flat. The superior borders are tapered from posterior to anterior. *Stage 2 (Cvs 2):* A concavity develops in the inferior border of the second vertebra. The anterior vertical height of the bodies increases. *Stage 3 (Cvs 3):* A concavity develops in the inferior border of the third vertebra. *Stage 4 (Cvs 4):* A concavity develops in the inferior border of the fourth vertebra. Concavities in the lower borders of the fifth and of the sixth vertebrae are beginning to form. The bodies of all cervical vertebrae are rectangular. *Stage 5 (Cvs 5):* Concavities are well-defined in the lower borders of the bodies of all 6 cervical vertebrae. The bodies are nearly square and the spaces between the bodies are reduced. *Stage 6 (Cvs 6):* All concavities have deepened. The vertebral bodies are now higher than they are wide. (From O'Reilly and Yanniello,³¹ modified.)

maturation method in order to assess ideal treatment timing for orthopedic maxillary expansion.

SUBJECTS AND METHODS

Subjects

Treated Group: The RME sample for this study was derived from the long-term records of patients who had undergone Haas-type RME and nonextraction edgewise appliance therapy in a single orthodontic practice. The records obtained included pretreatment (T_1), immediate post-RME screw fixation (T_2), and post-treatment (T_3) (minimum 5 years) posteroanterior (PA) and lateral cephalograms. The PA cephalometric radiographs were taken according to a standardized technique similar in principle to that used by Broadbent.³⁵

The patients originally were judged by the practitioner to have transverse maxillary deficiency as part of their overall orthodontic problem. These patients underwent Haas-type rapid maxillary expansion with 2 turns a day (0.25 mm per turn) until the expansion screw reached 10.5 mm (about 21 days). The Haas expander was kept on the teeth as a passive retainer for an average of 65 days (range: 42-75 days). Immediately after the Haas expander was removed, fixed standard edgewise appliances were applied.

Of the original 50 patients for whom long-term records were available, 7 patients had inadequate radiographs of either poor quality due to poor exposure or excessive head rotation at the time of exposure. One patient had the RME

removed prematurely. Consequently, 8 patients were removed from the study. Of the remaining 42 patients, 25 were female and 17 were male. The subjects were selected irrespective of the treatment outcome.

In this study, the treated group was divided into 2 groups according to skeletal maturity as evaluated by means of the CVM method^{32,33} (Figure 1) on lateral cephalograms at T₁. The Early-Treated Group (ETG) consisted of 29 subjects (18 females, 11 males) presenting with cervical vertebral stage 1 through 3 (Cvs 1–3). These 3 stages represent the time before peak in skeletal maturity. Mean age for ETG was 11 years at T₁ and 19 years and 9 months at T₃. The Late Treated Group (LTG) consisted of 13 subjects (10 females, 3 males) showing cervical vertebral stage 4 through 6 (Cvs 4–6). These 3 stages represent the time at or after the peak in skeletal maturity. Mean age for LTG was 13 years and 7 months at T₁ and 21 years and 9 months at T₃.

Control Group: Twenty subjects (11 males and 9 females) who did not undergo orthodontic treatment were selected from the longitudinal records of the University of Michigan Elementary and Secondary School Growth Study.³⁶

The control group was divided into 2 groups according to the CVM method as well: Early Control Group (ECG, 11 subjects, 2 females and 9 males, Cvs at T₁ 1–3) and Late Control Group (LCG, 9 subjects, 7 females and 2 males, Cvs at T₁ 4–6). Observations for the control group were available at T₁ (mean age for ECG 11 years and 3 months; mean age for LCG 12 years and 4 months) and at T₃ (mean age for ECG 17 years and 5 months; mean age for LCG 17 years and 7 months). All of the individuals in both the treatment and control groups were Caucasian.

The possible effect of between-groups gender differences on the analysis of results is very much limited when using the CVM method as an indicator of skeletal maturity, as the method is valid for pooled samples of males and females.³³

Cephalometric Analysis

Posteroanterior cephalograms were analyzed for each patient at pretreatment, immediate post-RME screw fixation, and post-treatment times. Serial posteroanterior cephalograms were hand-traced using 0.5 mm lead on 0.003 mm matte acetate tracing paper. All tracings were performed by one investigator and subsequently verified by another investigator. The traced PA cephalograms were analyzed by means of a digitizing tablet (Numonics, Landsdale, Penn) and digitizing software (DFP Plus 2.02, Dentofacial Software, Toronto, Ontario, Canada).

Figures 2 and 3 show the skeletal and dental landmarks used in the PA tracings, respectively. The RME group had a magnification of 9.0%, whereas the control group subjects had a 12.92% magnification. All linear cephalometric mea-

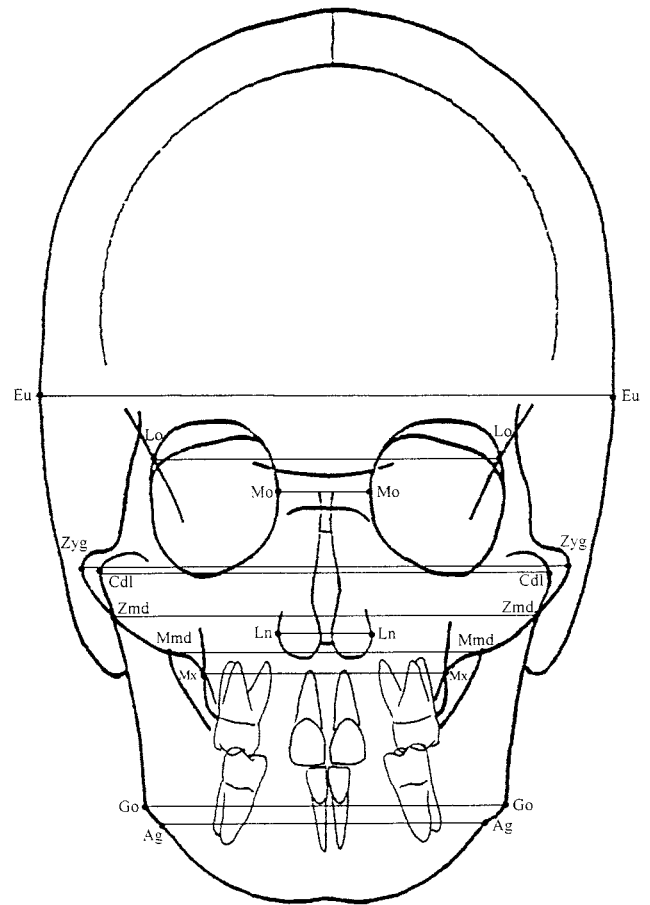


FIGURE 2. Cephalometric analysis on posteroanterior film: skeletal landmarks and measurements.

asures were converted to a 9.0% enlargement in order to standardize the data.

The following bilateral cephalometric landmarks and corresponding definitions were used:

Skeletal Landmarks

Euryon (Eu)—the most lateral point of the cranial vault.

Medioorbitale (Mo)—the most medial point of the orbital orifice.

Lateroorbitale (Lo)—the intersection of the lateral wall of the orbit and the greater wing of the sphenoid (the oblique line).

Zygomatic (Zyg)—the most lateral point of the zygomatic arch.

Zygomandibulare (Zmd)—the intersection between the lower margin of the zygomatic bone and the lateral contour of the mandibular ramus.

Condylar lateral (Cdl)—the point located at the lateral pole of the condylar head.

Maxillomandibulare (Mmd)—the intersection between the lower margin of the maxilla and the medial contour of the mandibular ramus.

Maxillare (Mx)—the point located at the depth of the

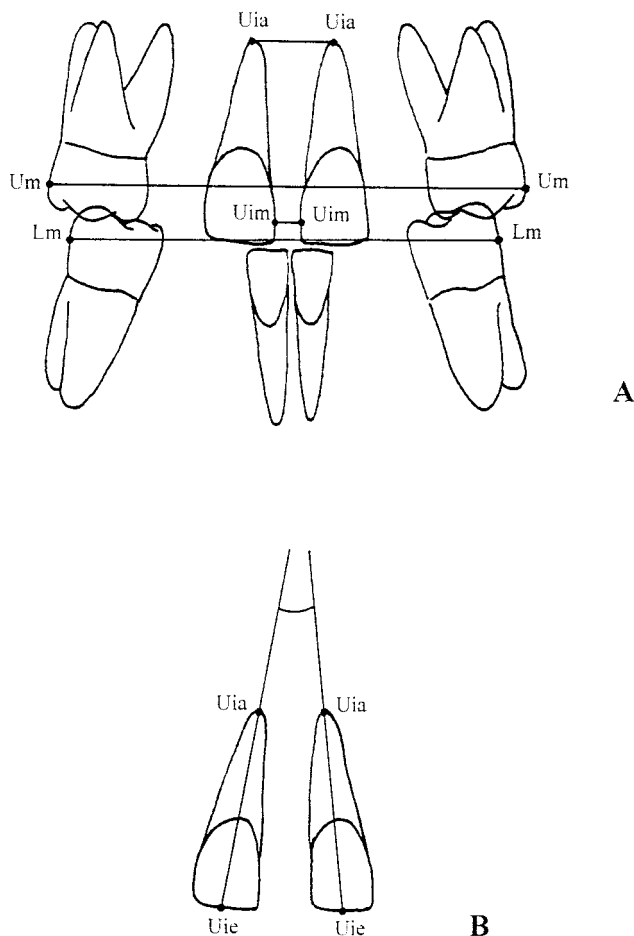


FIGURE 3. Cephalometric analysis on posteroanterior film: (a) dental linear measurements; (b) angular measurement for incisor inclination.

concavity of the lateral maxillary contour, at the junction of the maxilla and the zygomatic buttress.

Lateronasal (Ln)—the most lateral point of the nasal cavity.

Gonion (Go)—the point located at the gonial angle of the mandible.

Antegonion (Ag)—the point located at the antegonial notch.

Dental Landmarks

Upper molar (Um)—the most prominent lateral point on the buccal surface of the upper first molar.

Lower molar (Lm)—the most prominent lateral point on the buccal surface of the lower first molar.

Upper incisor mesial (Uim)—the most mesial point of the upper central incisor crown.

Upper incisor apex (Uia)—the tip of the root apex of the upper central incisor.

Upper incisor edge (Uie)—the point located on the incisal edge of the upper central incisor, centered mediolaterally.

From the digitized PA cephalograms, 15 width measure-

ments (11 skeletal and 4 dental) were derived for each patient at each observation time by connecting bilateral cephalometric landmarks (Figures 2 and 3). The maxillary incisal angle was added to the previous transverse linear measurements (Figure 3).

To analyze the error of the method, 10 randomly selected PA cephalometric radiographs were retraced and redigitized. A combined error of landmark location, tracing, and digitization was determined. The error standard deviation for each dimension was calculated from the double determinations with the aid of Dahlberg's formula. For the measures used here, the mean value of the method error was 0.7 ± 0.3 mm.

Statistical Analysis

Descriptive statistics were obtained for each cephalometric measurement at T_1 , T_2 , and T_3 for the treated group, and at T_1 and T_3 for the control group. It is important to point out that the time interval between T_1 and T_2 for the treatment group did not exceed thirty days, which virtually eliminates growth as a variable. Therefore, for comparison purposes, it was assumed that the measurements for the control group at T_2 coincided with the measurements of the control group at T_1 .

A Mann-Whitney U-test ($P < .05$) was performed to evaluate the significance of the following comparisons:

- $T_2 - T_1$ changes in ETG vs $T_2 - T_1$ changes in LTG
- $T_3 - T_1$ changes in ETG vs $T_3 - T_1$ changes in ECG
- $T_3 - T_1$ changes in LTG vs $T_3 - T_1$ changes in LCG

Statistical computations were performed by means of computer software (SPSS for Windows, release 10.0.0, SPSS, Inc, Chicago, Ill).

RESULTS

Comparison of treatment effects in ETG vs LTG ($T_2 - T_1$ changes in ETG vs $T_2 - T_1$ changes in LTG) (Table 1)

No statistically significant differences were found between the 2 groups with the exception of a larger increase in lateronasal width in the early-treated group (+1.1 mm). Clinically favorable and similar changes in the transverse dentoalveolar measurements occurred in both groups. Though not significant, the increase in maxillary width was greater in the early-treated group (+0.6 mm).

Overall treatment changes in ETG ($T_3 - T_1$ changes in ETG vs $T_3 - T_1$ changes in ECG) (Table 2)

In the long-term, expansion therapy produced permanent increases in the transverse dimensions of both the dentoalveolar and skeletal components of the maxilla and circummaxillary structures. There were significantly greater increments in the early-treated group compared to the controls for the following transverse measurements: lateroorbitale width (+0.6 mm), maxillary width (+3.0 mm), la-

TABLE 1. Comparison of Changes in Early Treated Group vs Late Treated Group After the Active Phase of Expansion ($T_2 - T_1$)

Variables		Early Treated Group (N = 29)			Late Treated Group (N = 13)			U-value	P-value	Significance
		Median	Max	Min	Median	Max	Min			
Euryon width	mm	0.1	3.9	-2.1	-0.2	2.6	-1.7	183.0	.893	NS
Laterorbitale width	mm	-0.1	2.9	-3.3	-0.3	3.2	-1.9	174.0	.707	NS
Medioorbitale width	mm	0.3	2.7	-4.2	0.0	1.6	-2.4	159.5	.435	NS
Bizygomatic width	mm	0.4	1.3	-1.3	0.3	1.9	-1.3	184.0	.914	NS
Zygomandibulare width	mm	0.5	7.5	-9.7	-0.3	3.9	-2.2	165.0	.536	NS
Maxillomandibulare width	mm	0.4	7.5	-12.4	0.2	3.6	-5.2	184.0	.914	NS
Maxillary width	mm	3.4	7.1	0.5	2.8	5.2	0.2	136.0	.159	NS
Lateronasal width	mm	3.3	5.5	0.6	2.2	5.0	1.5	102.0	.018	^a
Condylar width	mm	-0.7	4.5	-6.1	-0.7	5.1	-6.7	184.5	.914	NS
Bigonial width	mm	0.1	1.3	-1.7	0.0	1.4	-1.5	184.0	.914	NS
Antegonial width	mm	0.4	2.6	-1.8	0.0	2.0	-1.9	159.0	.435	NS
Maxillary incisor apex width	mm	5.6	9.3	2.0	5.5	11.8	2.3	188.0	1.000	NS
Maxillary incisor mesial width	mm	3.9	7.6	1.5	3.8	5.6	0.0	171.0	.648	NS
Maxillary first molar width	mm	9.3	10.1	7.2	8.9	10.3	6.9	131.0	.122	NS
Mandibular first molar width	mm	0.7	13.6	-0.5	0.2	0.9	-0.3	137.0	.167	NS
Maxillary incisal angle	deg	-3.7	6.8	-14.2	-4.0	2.0	-13.3	175.0	.727	NS

T_2 indicates immediate post-rapid maxillary expansion screw fixation; T_1 pre-treatment; N, number of patients; and NS, not significant.

^a $P < .05$

TABLE 2. Comparison of Overall Changes ($T_3 - T_1$) in Early Treated Group vs Early Control Group

Variables		Early Treated Group (N = 29)			Early Control Group (N = 11)			U-value	P-value	Significance RME - CTRL
		Median	Max	Min	Median	Max	Min			
Euryon width	mm	3.0	9.0	0.5	2.0	5.0	0.1	100.0	.074	NS
Laterorbitale width	mm	3.2	9.2	1.1	2.6	4.0	0.4	76.0	.010	^a
Medioorbitale width	mm	2.7	6.6	-9.3	2.3	5.6	-0.1	153.0	.858	NS
Bizygomatic width	mm	10.2	17.4	3.6	11.6	13.4	6.2	157.0	.952	NS
Zygomandibulare width	mm	6.8	21.4	2.4	8.0	13.1	4.1	122.0	.267	NS
Maxillomandibulare width	mm	9.1	22.4	5.0	6.9	12.5	0.7	120.0	.241	NS
Maxillary width	mm	4.3	8.3	-0.6	1.3	3.4	-1.6	54.0	.001	^b
Lateronasal width	mm	4.5	8.7	1.5	2.2	3.1	0.8	10.0	.000	^c
Condylar width	mm	9.4	15.3	-2.4	7.8	10.7	1.4	125.0	.308	NS
Bigonial width	mm	8.8	15.8	2.1	9.1	9.9	4.3	152.0	.835	NS
Antegonial width	mm	5.8	12.0	-0.4	5.7	9.6	2.0	154.0	.881	NS
Maxillary incisor apex width	mm	0.1	3.0	-4.0	-1.1	1.2	-1.9	109.0	.131	NS
Maxillary incisor mesial width	mm	-0.2	1.0	-1.8	-0.2	0.7	-0.8	126.0	.323	NS
Maxillary first molar width	mm	3.2	8.0	0.1	0.5	2.3	-1.2	14.0	.000	^c
Mandibular first molar width	mm	0.7	8.0	-2.9	0.4	2.4	-2.2	124.0	.294	NS
Maxillary incisal angle	deg	0.7	8.3	-10.4	1.4	6.4	-6.8	137.0	.511	NS

T_3 indicates long-term observation; T_1 , pre-treatment; N, number of patients; RME, rapid maxillary expansion; CTRL, control; and NS, not significant.

^a $P < .05$.

^b $P < .01$.

^c $P < .001$.

teronasal width (+2.3 mm), and maxillary first molar width (+2.7 mm).

Overall treatment changes in LTG ($T_3 - T_1$ changes in LTG vs $T_3 - T_1$ changes in LCG) (Table 3)

The late-treated group presented with significantly greater increments for lateronasal width (+1.5 mm) and for both maxillary (+3.5 mm) and mandibular first molar widths (+2.3 mm) when compared to corresponding controls. Significant long-term changes in the late-treated group, there-

fore, involved primarily dentoalveolar structures, with no permanent increase in the skeletal width of the maxilla.

DISCUSSION

The objective of the present study on posteroanterior cephalograms was a short-term and long-term evaluation of the differences in treatment outcomes when contrasting RME therapy starting before the pubertal peak in skeletal

TABLE 3. Comparison of Overall Changes ($T_3 - T_1$) in Late Treated Group vs Late Control Group

Variables		Late Treated Group (N = 13)			Late Control Group (N = 9)			U-value	P-value	Significance RME - CTRL
		Median	Max	Min	Median	Max	Min			
Euryon width	mm	0.9	6.6	0.0	1.2	4.0	-0.6	57.0	.948	NS
Laterorbitale width	mm	1.3	5.5	0.2	1.4	4.7	-0.3	58.0	1.000	NS
Medioorbitale width	mm	0.6	3.8	-3.7	0.3	5.7	-2.4	56.0	.896	NS
Bizygomatic width	mm	3.2	8.9	0.8	2.2	8.7	0.1	46.0	.431	NS
Zygomandibulare width	mm	3.1	8.0	1.4	4.5	12.5	3.3	31.0	.071	NS
Maxillomandibulare width	mm	4.3	6.8	2.9	3.6	8.1	1.2	46.0	.431	NS
Maxillary width	mm	1.8	4.5	-0.7	0.9	1.8	-0.1	32.0	.082	NS
Lateronasal width	mm	2.2	7.3	0.0	0.7	3.6	-0.6	21.0	.011	^a
Condylar width	mm	3.0	8.9	-7.5	3.8	6.9	-4.7	53.0	.744	NS
Bigonial width	mm	1.3	5.0	-0.7	1.9	7.9	-0.4	42.0	.292	NS
Antegonial width	mm	-0.2	5.4	-1.6	0.9	5.9	-2.4	52.0	.695	NS
Maxillary incisor apex width	mm	0.6	3.0	-1.5	-0.6	0.6	-2.1	31.0	.071	NS
Maxillary incisor mesial width	mm	-0.1	0.2	-1.5	0.0	0.4	-0.7	57.0	.948	NS
Maxillary first molar width	mm	3.5	8.0	1.4	0.0	1.9	-1.9	3.0	.000	^c
Mandibular first molar width	mm	1.4	6.2	-2.0	-0.9	2.5	-1.3	19.0	.007	^b
Maxillary incisal angle	deg	-2.1	5.8	-5.3	-2.1	1.7	-4.3	56.0	.896	NS

T_3 indicates long-term observation; T_1 , pre-treatment; N, number of patients; RME, rapid maxillary expansion; CTRL, control; and NS, not significant.

^a $P < .05$.

^b $P < .01$.

^c $P < .001$.

growth to RME therapy performed during or slightly after the peak as assessed by means of the cervical vertebral maturation method.

To our knowledge, the present investigation attempts for the first time to assess the role of skeletal maturity in the results of rapid maxillary expansion by means of a long-term appraisal of craniofacial changes in the transverse dimension on frontal cephalograms. The issue of timing in dentofacial orthopedics is a fundamental aspect for an adequate treatment planning and for a reasonable anticipation of therapeutic outcomes both short-term and long-term.^{34,37} In the present study, the Cervical Vertebral Maturation (CVM) method^{32,33} was utilized to identify the stage of individual skeletal maturation at the start of treatment.

In the short-term, RME therapy with the Haas expander produced clinically significant changes in the nasomaxillary complex of both treatment groups (Table 1). In both groups, increments for maxillary intermolar width were about 9 mm, about 5.5 mm for maxillary incisor apex width and about 4 mm for maxillary incisor mesial width. It must be considered that the expansion protocol was standardized for all of the patients included in the study (activation of the screw up to 10.5 mm). The Haas expander appears to induce a reproducible amount of expansion at the dentoalveolar level at any development stage. At the skeletal level, however, the early-treated group presented with significantly greater increases for lateronasal width (1.1 mm more than the late-treated group), and with greater, though not statistically significant, increases for maxillary width (0.6 mm more than the late-treated group).

The analysis of the changes in the long term revealed that in both the early and late-treated groups, RME therapy produced a net significant gain over the controls of 2.7 mm and 3.5 mm in maxillary intermolar width, respectively (Tables 2 and 3). This increase, however, was associated with a significant widening of the maxilla at the skeletal level only in the early-treated group. Changes in maxillary width exceeded normal growth by 3.0 mm (Table 2). The amount of the increase in the skeletal transverse measurement for the maxilla in the late-treated group was only 0.9 mm more than normal controls in the long term. The gain in maxillary transverse dimension apparently was achieved with different mechanisms at the 2 different stages in skeletal maturation. The gain was skeletal in nature in the group treated with RME before the peak in skeletal maturation, while it was more dentoalveolar in nature in the group treated during or after the peak in skeletal maturation. Compared to controls, lateronasal width showed a larger increase in the early-treated group (2.3 mm) than in the late-treated group (1.5 mm).

The effects of maxillary separation by means of the Haas expander appear to reach anatomical skeletal regions far from the midpalatal suture only when treatment is delivered before the peak in skeletal growth velocity. This is witnessed by the significantly larger increments in lateroorbitale width in the early-treated group when compared to controls (Table 2). As reported by Wertz,⁵ with increased age the fulcrum of maxillary separation tends to be displaced more inferiorly, nearer to the activating force. In children, the fulcrum may be as high as the frontomaxillary suture,

whereas in adolescents the fulcrum is much lower. These differential, age-dependent effects may be attributed to the increased resistance to maxillary separation by the circummaxillary structures because of increased calcification in the sutural skeletal structures.

Results show that RME treatment is able to induce significantly more favorable skeletal changes in the transverse plane when it is initiated before the pubertal peak in skeletal growth. This clinical finding agrees with histological data previously noted by Melsen,¹⁸ which demonstrated a higher level of response to mechanical stimuli in the midpalatal suture in preadolescent patients due to a lesser degree of interdigitation between the 2 halves of the maxilla. Wertz and Dreskin⁷ also noted greater and more stable orthopedic changes in patients under the age of 12 years.

The present study evaluated a sample of treated subjects in the circumpubertal period (age range at the start of treatment was 9 to 15 years). The question remains as to whether rapid maxillary expansion is more efficient when active therapy is delivered at an earlier developmental stage when both the midpalatal and circummaxillary sutures undergo biological changes.^{5,18,19}

CONCLUSIONS

The application of the Cervical Vertebral Maturation method for the assessment of differences in the outcome of RME therapy in relation to treatment timing revealed that RME therapy with the Haas expander induces clinically significant and reproducible transverse changes at the dentoalveolar level in patients treated before or after the peak in skeletal growth velocity. Patients treated before the pubertal peak exhibit significant and more effective long-term changes at the skeletal level in both maxillary and circummaxillary structures. When RME treatment is performed after the pubertal growth spurt, maxillary adaptations to expansion therapy shift from the skeletal level to the dentoalveolar level.

ACKNOWLEDGMENTS

The authors are extremely grateful to Dr Tomas A. Herberger for providing the patient records for the treated sample analyzed in this study. We also thank Elizabeth Kutcipal for her technical help on this project and Michael Powell for his editorial assistance.

REFERENCES

1. Thörne NAH. Experiences on widening the median maxillary suture. *Trans Europ Orthod Soc.* 1956;32:279–290.
2. Haas AJ. Rapid expansion of the maxillary dental arch and nasal cavity by opening the mid-palatal suture. *Angle Orthod.* 1961;31:73–90.
3. Krebs A. Midpalatal suture expansion studies by the implant method over a seven year period. *Trans Europ Orthod Soc.* 1964;40:131–142.
4. Davis WM, Kronman JH. Anatomical changes induced by splitting of the midpalatal suture. *Angle Orthod.* 1969;39:126–132.
5. Wertz RA. Skeletal and dental changes accompanying rapid midpalatal suture opening. *Am J Orthod.* 1970;58:41–66.
6. Haas AJ. Palatal expansion: just the beginning of dentofacial orthopedics. *Am J Orthod.* 1970;57:219–255.
7. Wertz R, Dreskin M. Midpalatal suture opening: a normative study. *Am J Orthod.* 1977;71:367–381.
8. da Silva Filho OG, Montes LA, Torelly LF. Rapid maxillary expansion in the deciduous and mixed dentition evaluated through posteroanterior cephalometric analysis. *Am J Orthod Dentofacial Orthop.* 1995;107:268–275.
9. Berger JL, Pangrazio-Kulbersh V, Borgula T, Kaczynski R. Stability of orthopedic and surgically assisted rapid palatal expansion over time. *Am J Orthod Dentofacial Orthop.* 1998;114:638–645.
10. Haberson VA, Myers DR. Midpalatal suture opening during functional posterior crossbite correction. *Am J Orthod.* 1978;74:310–313.
11. Hesse KL, Årtun J, Joondeph DR, Kennedy DB. Changes in condylar position and occlusion associated with maxillary expansion for correction of functional unilateral posterior crossbite. *Am J Orthod Dentofacial Orthop.* 1997;111:410–418.
12. Baccetti T, McGill JS, Franchi L, McNamara JA Jr, Tollaro I. Skeletal effects of early treatment of Class III malocclusion with maxillary expansion and face-mask therapy. *Am J Orthod Dentofacial Orthop.* 1998;113:333–343.
13. Tollaro I, Baccetti T, Franchi L, Tanasescu CD. Role of posterior transverse interarch discrepancy in Class II, Division 1 malocclusion during the mixed dentition phase. *Am J Orthod Dentofacial Orthop.* 1996;110:417–422.
14. McNamara JA Jr, Brudon WL. *Orthodontic and Orthopedic Treatment in the Mixed Dentition.* Ann Arbor, Mich: Needham Press; 1993.
15. Adkins MD, Nanda RS, Currier GF. Arch perimeter changes on rapid palatal expansion. *Am J Orthod Dentofacial Orthop.* 1990;97:194–199.
16. Krebs A. Midpalatal suture expansion studies by the implant method over a seven year period. *Trans Europ Orthod Soc.* 1964;40:131–142.
17. Haas AJ. Long-term posttreatment evaluation of rapid palatal expansion. *Angle Orthod.* 1980;50:189–217.
18. Melsen B. Palatal growth studied on human autopsy material. A histologic microradiographic study. *Am J Orthod.* 1975;68:42–54.
19. Melsen B, Melsen F. The postnatal development of the palato-maxillary region studied on human autopsy material. *Am J Orthod.* 1982;82:329–342.
20. Björk A. Sutural growth of the upper face studied by the implant method. *Acta Odontol Scand.* 1966;24:109–127.
21. Björk A, Skieller V. Growth of the maxilla in 3 dimensions as revealed radiographically by the implant method. *Brit J Orthod.* 1997;4:53–64.
22. Nanda R. The rates of growth of several facial components measured from serial cephalometric roentgenograms. *Am J Orthod.* 1955;41:658–673.
23. Hunter CJ. The correlation of facial growth with body height and skeletal maturation at adolescence. *Angle Orthod.* 1966;36:44–54.
24. Greulich WW, Pyle SI. *Radiographic Atlas of Skeletal Development of the Hand and Wrist.* Stanford, Conn: Stanford University Press; 1959.
25. Björk A, Helm S. Prediction of the age of maximum pubertal growth in body height. *Angle Orthod.* 1967;37:134–143.
26. Taranger J, Hägg U. Timing and duration of adolescent growth. *Acta Odontol Scand.* 1980;38:57–67.
27. Hellman M. The process of dentition and its effects on occlusion. *Dental Cosmos.* 1923;65:1329–1344.
28. Lewis A, Garn S. The relationship between tooth formation and other maturational factors. *Angle Orthod.* 1960;30:70–77.

29. Tanner JM. *Growth at Adolescence*. 2nd ed. Oxford: Blackwell Scientific Publications; 1962.
30. Lamparski D. *Skeletal Age Assessment Utilizing Cervical Vertebrae*. Pittsburgh, Penn: The University of Pittsburgh; 1972.
31. O'Reilly M, Yanniello GJ. Mandibular growth changes and maturation of cervical vertebrae—a longitudinal cephalometric study. *Angle Orthod*. 1988;58:179–184.
32. Franchi L, Baccetti T. *New emphasis on the role of mandibular skeletal maturity in dentofacial orthopedics*. In: McNamara JA Jr, ed. *The Enigma of the Vertical Dimension*. Craniofacial Growth Series, Vol 36, Ann Arbor, Mich: Center for Human Growth and Development, The University of Michigan; 2000;253–275.
33. Franchi L, Baccetti T, McNamara JA Jr. Mandibular growth as related to cervical vertebral maturation and body height. *Am J Orthod Dentofacial Orthop*. 2000;118:335–340.
34. Baccetti T, Franchi L, Ratner Toth L, McNamara JA Jr. Treatment timing for twin block therapy. *Am J Orthod Dentofacial Orthop*. 2000;118:159–170.
35. Broadbent BH. A new x-ray technique and its application to orthodontia. *Angle Orthod*. 1931;1:45–66.
36. Riolo ML, Moyers RE, McNamara JA Jr, Hunter WS. *An Atlas of Craniofacial Growth: Cephalometric Standards from The University School Growth Study, The University of Michigan*. Ann Arbor, Mich: Monograph 2, Craniofacial Growth Series; The Center for Human Growth and Development, The University of Michigan; 1974.
37. Bishara SE, Justus R, Graber TM. Proceedings of the Workshop discussions on early treatment held by the College of Diplomates of the American Board of Orthodontics in Quebec City, Canada, on July 13–17, 1997. *Am J Orthod Dentofac Orthop*. 1998;113:5–6.