



UNIVERSITÀ
DEGLI STUDI
FIRENZE

FLORE

Repository istituzionale dell'Università degli Studi di Firenze

The sialoglycoconjugates in the oviducts of fertile and postmenopausal women.

Questa è la Versione finale referata (Post print/Accepted manuscript) della seguente pubblicazione:

Original Citation:

The sialoglycoconjugates in the oviducts of fertile and postmenopausal women / G. GHERI; I. NOCI; C.F. GHERI; D. VICHI; G.D. ZAPPOLI THYRION; M. MARINI; A.M. BUCCOLIERO; E. SGAMBATI. - In: MATURETAS. - ISSN 0378-5122. - STAMPA. - 58:(2007), pp. 269-284.

Availability:

This version is available at: 2158/325875 since: 2017-07-31T16:10:11Z

Terms of use:

Open Access

La pubblicazione è resa disponibile sotto le norme e i termini della licenza di deposito, secondo quanto stabilito dalla Policy per l'accesso aperto dell'Università degli Studi di Firenze (<https://www.sba.unifi.it/upload/policy-oa-2016-1.pdf>)

Publisher copyright claim:

(Article begins on next page)



The sialoglycoconjugates in the oviducts of fertile and postmenopausal women

Gherardo Gheri^a, Ivo Noci^b, Chiara F. Gheri^c, Debora Vichi^a,
Giorgia D. Zappoli Thyron^d, Mirca Marini^a,
Anna M. Buccoliero^c, Eleonora Sgambati^{a,*}

^a Department of Anatomy Histology and Forensic Medicine, Policlinic of Careggi, Viale Morgagni, 85, 50134 Florence, Italy

^b Department of Gynecology, Perinatology and Human Reproduction, Policlinic of Careggi, Viale Morgagni, 85, 50134 Florence, Italy

^c Department of Human Pathology and Oncology, Policlinic of Careggi, Viale Morgagni, 85, 50134 Florence, Italy

^d Department of Medicine, University of Florence, Policlinic of Careggi, Viale Pieraccini, 18, 50134 Florence, Italy

Received 3 May 2007; received in revised form 18 August 2007; accepted 28 August 2007

Abstract

Objectives: The aim of the study was to investigate the distribution of the sialoderivatives of the glycoconjugates in the oviduct of normally menstruating and postmenopausal women.

Methods: Biopsies of ampullary and isthmic portions of the oviduct were obtained from fertile women, in proliferative and secretive phases, and from postmenopausal subjects. The study was carried out using digoxigenin-labelled lectins (MAA, SNA and PNA) in addition to the use of enzymatic and chemical treatments to characterize the different glycosidic linkages of the sialoderivatives and to obtain information on their structure.

Results: No appreciable difference in sialoderivatives distribution was observed among the oviducts, particularly at the epithelium luminal surface, of the fertile women in the two menstrual cycle phases or among those of the fertile and some postmenopausal women, independently from age. Moreover, no appreciable difference of distribution was observed between the ampullary and the isthmic portions in both the study groups.

Conclusions: In the fertile women sialoderivatives present at the luminal surface of the epithelial cells could play a role in sperm capacitation and mobility, and facilitate the transit of the egg and of the early embryo along the oviducts. The similar distribution of sialoderivatives in the oviduct epithelium of some postmenopausal women of different age, compared to the fertile ones, suggests a maintaining of some functions of the organ, independently from the age of the woman. This could be due, in some cases, to the influence of remaining still sufficient sex hormonal levels.

© 2007 Elsevier Ireland Ltd. All rights reserved.

Keywords: Sialoglycoconjugates; Oviducts; Fertile women; Postmenopausal women

* Corresponding author. Tel.: +39 055 410084; fax: +39 055 4379500.

E-mail address: sgambati@unifi.it (E. Sgambati).

1. Introduction

The glycoconjugate oligosaccharides in the epithelium of the oviduct during the estrogenic and progesterone phases of normally menstruating women have been studied by Schulte et al. [1], Wu et al. [2], Kiss et al. [3] and by our research group [4].

The investigation of our group [4] was also extended to the oligosaccharidic content in postmenopausal women.

The sialoderivatives expressed in the oviduct have been studied in some mammals such as rabbit [5], hamster [6] and rat [7]. They seem to play a fundamental role in sperm function, specifically in adherence to the epithelium, and in sperm capacitation.

The sialic acids are a large family of nine carboxylated sugars. These terminal carboxylated sugars confer a negative charge to the cell surface and are responsible, as specific ligands, of the intercellular and/or intermolecular recognition phenomena [5]. The sialic acids manifest structural diversities and different properties [1,8] for addition of one or more O-acetyl esters to hydroxyl groups [9] and for their linkage to the penultimate sugar with three different configurations, α 2-3, α 2-6 and α 2-8.

Lectins histochemical method is a useful tool to study the sialic acids. For this purpose two methodologies have been developed. In the first methodology, direct, biotinylated lectins, as *Maackia amurensis* II lectin (MAL II) and *Sambucus nigra* agglutinin (SNA), are employed to identify sialic acids linked, respectively, α 2-3 and α 2-6 to galactose or galactosamine [5,10,11]. In the second methodology, indirect, horseradish peroxidase (HRP)-conjugated PNA combined with sialidase digestion and differential oxidation is used to investigate the expression of Sia-D-Gal(β 1 \rightarrow 3)-D-GalNAc and the structure of sialic acids [5].

Only scanty data are available in literature on the sialoderivatives in the human oviduct [1,4,12]. Therefore, in the present study, we wanted to investigate the distribution of various types of sialoderivatives in the oviduct of fertile women (in different menstrual phases) and of postmenopausal women. The aim was to evaluate the influence of different hormonal milieus on the sialic acids expression, and the role of these carbohydrates in the human oviduct. For this purpose the two types of mentioned methodologies were per-

formed, but using digoxigenin-labelled lectins MAA, SNA and PNA.

2. Materials and methods

2.1. Study groups

Nine normally menstruating women subjected to hysterectomy for benign pathology were studied. Based on menstrual records and endometrial histology at the time of the study, four of these patients were in follicular phase and five in luteal phase (Table 1).

In addition, 10 asymptomatic postmenopausal women (48–75 years old), who had a diagnosis of prolapsus uteri, were studied. These patients were admitted between December 1997 and May 2003 to the Department of Gynaecology, Perinatology and Human Reproduction of the University of Florence for vaginal hysterectomy (Table 1). The indication for surgery was urinary incontinence or perineal discomfort.

Table 1
Clinical profiles of the women and the examined oviductal tracts

Biopsy no.	Examined tract (s)	Age	Endometrial dating
Fertile women			
02/17335	A	42	Early proliferative
03/17850	A & I	40	Early proliferative
99/17822	A & I	45	Middle proliferative
03/21850	A & I	48	Late proliferative
02/27822	A & I	41	Early secretive
97/19913	A	52	Middle secretive
03/24111	A & I	53	Middle secretive
02/27824	A & I	44	Late secretive
97/21298	A	49	Late secretive
Postmenopausal women			
97/16677	A	48	1 years
97/21945	A	52	1 years
97/21661	A & I	57	5 years
97/19216	A & I	57	4 months
97/16060	I	59	5 years
97/21299	I	62	9 years
97/16355	A & I	63	23 years
97/16866	A & I	63	14 years
97/17091	A & I	68	24 years
97/13074	A & I	75	23 years

A: ampullary portion; I: isthmic portion.

None of these patients had had hormonal therapy for at last 5 years. Furthermore, none was affected by diabetes or hypertension.

2.2. Sample collection

Fragments were collected from endometrium and oviducts (pars ampullaris and/or isthmic portion). Immediately after removal the specimens were fixed in 10% formalin for at least 24 h and embedded in paraffin. 5 μ m thick paraffin sections were cut from each specimen and some sections were stained with haematoxylin-eosin to get a general overview.

This study was carried out with the approval of the Local Ethical Committee. Consent was obtained from all patients recruited.

2.3. Lectin histochemistry

2.3.1. Lectin labeling

Digoxigenin-labelled lectins MAA, SNA and PNA were used [13].

After hydration, the sections were treated with 10% blocking reagent in Tris Buffered Saline (TBS, Tris-HCl 0.05 M, NaCl 0.15 M, pH 7.5) for 30 min, two times washed in TBS for 10 min and rinsed in Buffer 1 (MgCl₂ 1 mM, MnCl₂ 1 mM, CaCl₂ 1 mM in TBS, pH 7.5) for 10 min. The sections were incubated for 1 h at room temperature in digoxigenin-labelled lectins (Roche Diagnostics GmbH, Mannheim, Germany), dissolved in Buffer 1. The optimal concentration for each lectin, which allowed the maximum staining with minimum background, was as following: PNA (*Arachis Hypogaea*, binding specificity D-Gal(β 1 \rightarrow 3)-D-GalNAc) 10 μ l/1 ml, SNA (*Sambucus Nigra*, binding specificity Neu5Ac(α -2 \rightarrow 6)Gal/GalNAc) 1 μ l/1 ml and MAA (*Maackia Amurensis*, binding specificity Neu5Ac(α -2 \rightarrow 3)Gal) 5 μ l/1 ml. The sections were rinsed three times in TBS for 10 min, incubated with antidigoxigenin dissolved in TBS (1 μ l/1 ml) for 1 h and washed three times in TBS for 10 min. Staining of the sites containing bound lectin-digoxigenin was obtained incubating the slides with Buffer 2 (Tris-HCl 0.1 M, MgCl₂ 0.05 M, NaCl 0.1 M, pH 9.5) containing NBT/X-phosphate (20 μ l/1 ml) for 10 min at room temperature. The specimens were rinsed in distilled water, dehydrated using graded

ethanol solutions, cleared in xylene and mounted in Permount.

2.3.2. Enzymatic and chemical treatments

In some experiments sialic acid was removed by pretreating the sections for 18 h at 37 °C in a solution of sodium acetate buffer 0.25 M, pH 5.5, containing 0.1 unit/ml sialidase (neuraminidase Type X from *Clostridium perfringens* (Sigma Chemical Co., St. Louis, MO)), 5.5 mM CaCl₂ and 154 mM NaCl, before staining with digoxigenin-labelled PNA. Deacetylation was performed incubating the sections with 0.1% KOH in 70% ethanol for 30 min at room temperature. This treatment, detaching all the acetyl substituents, renders sialic acid residues, which contain also acetylic groups on C₄ of the pyranose ring, susceptible to sialidase digestion [14].

For differential oxidation, both 1 mM aqueous periodic acid (1 mM PO, mild oxidation) and 44 mM aqueous periodic acid (44 mM PO, strong oxidation) were used for 15 min at room temperature. Mild oxidation abolishes the staining with sialidase/PNA or KOH/sialidase/PNA when sialic acid does not contain C₇- and/or C₈- and/or C₉-O-acetyl groups in the side chain. Strong oxidation blocks the subsequent staining with sialidase/PNA or KOH/sialidase/PNA except for C₉ acetylated sialic acids linked via α 2,3 bound to the penultimate β -galactose [15].

2.3.3. Controls

Controls for lectin specificity included substitution of lectin-conjugates with the respective unconjugated lectins or preincubation of lectins with the corresponding hapten sugars: 0.1 M α 2,3 sialyllactose for MAA, 0.1 M α 2,6 sialyllactose for SNA, 0.2 M D-galactose for PNA (Sigma Chemical Co., St. Louis, MO).

Control of sialidase digestion was made by incubation of sections with enzyme-free buffer [16]. The efficacy of digestion was tested by treating adjacent sections, with and without prior deacetylation, with the enzyme solution and then submitting them to MAA and SNA labelling [5]. Some control sections were treated with desulphation procedure, i.e. placing them in 0.15N HCl in methanol for 5 h at 60 °C and then in KOH in 70% ethanol for 15 min at room temperature [17].

All the slides were stained with the same batch to eliminate inter-batch variation.

2.3.4. Evaluation of reactivity location

A grid, 1 mm × 1 mm, divided in 100 fields, was used for the evaluation of the staining location. An investigator, blinded to the tissue identity, examined 20 fields, selected at random, for each section (5 sections for each specimen). The epithelial secreting cells, the epithelial ciliated cells, the lamina propria and the endothelial cells of the vessels were examined.

2.3.5. Evaluation of reactivity intensity

In each field of each section examined for the staining location, a quantitative analysis was also performed to evaluate the intensity of reactivity in the epithelial secreting cells, in the epithelial ciliated cells, in the lamina propria and in the vessels endothelium. For this purpose the optical density was measured using a computerized image analyzer program (Image-Pro Plus v. 4.5, Media Cybernetics). The staining intensity was measured and expressed in arbitrary units standardized from 0 to 250, being 0 the maximum of the staining and 250 no staining. Five measurements for each field were repeated.

2.3.6. Statistical analysis

To compare the data of the reactive components, the *t*-test for paired samples was used. The following differences were evaluated: (1) differences in PNA reactivity, with and without treatments, in specimens of the same case; (2) differences between the PNA reactivity with deacetylation-neuraminidase treatment and the MAA and SNA reactivity, in specimens of the same case; (3) differences in lectin reactivity between the ampulla and isthmus for each lectins and in specimens of the same case; (4) differences in lectin reactivity among fertile women, in the same phase and among different phase, comparing cases each other; (5) differences in lectin reactivity among postmenopausal women, comparing cases each other; (6) differences among fertile and postmenopausal women, comparing cases each other.

Probability of less than 5% ($P < 0.05$) was considered statistically significant.

Reproducibility of the measurements was assessed comparing the measurements made by one observer at different times and the measurements of two observers. Intra-observer coefficient of variation was 1.5% and inter-observer coefficient of variation was 5.2%.

3. Results

3.1. Morphological remarks

On the basis of morphological remarks, made in this study and in our previous study [4], the epithelium of the ampullary and isthmic portions of the oviduct showed a decrease in number of ciliated cells comparing the postmenopausal women with the fertile ones. These cells often appeared in clusters, and in some cases were lacking of cilia. In addition, Hafez [18], using electron microscopy, observed also little evidence of secretory activity in the oviductal epithelium of the postmenopausal women.

3.2. Lectin reactivity

No difference, if not specified in the following results, in location and intensity of lectins reactivity (with and without treatments), was seen among the oviducts of the fertile women in the two phases of the menstrual cycle or between the ampullary and the isthmic portions of the oviducts both in the fertile and the postmenopausal women.

3.3. MAA and SNA reactivity location (Table 2)

3.3.1. Epithelial cells

MAA reacted with the luminal surface of the secreting cells and with the cilia and the luminal surface of the ciliated cells in all the examined oviducts, both in the fertile and postmenopausal women (Figs. 1 and 2).

SNA reactivity was observed at the cilia and at the luminal surface of the ciliated cells in the two study groups (Figs. 3 and 4). In the oldest women, when the cilia were no more observable or rudiments of them were present, the luminal surface still reacted.

3.3.2. Lamina propria

MAA and SNA reactivity in the lamina propria was not observed in all the women (Figs. 1–4).

3.3.3. Endothelial cells

In the fertile women, the endothelium of the vessels reacted with MAA lectin in all the studied cases, but two (Fig. 1). In postmenopausal women MAA binding to the endothelial cells was constantly detected, with the exception of the two oldest women (Fig. 2).

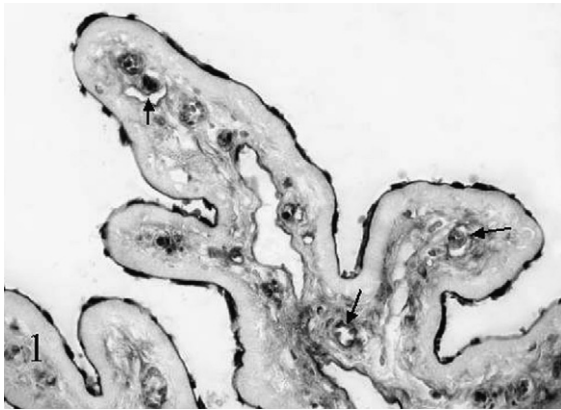


Fig. 1. MAA; biopsy no. 03/17850; fertile woman in early proliferative phase; ampullary portion. Strong reactivity is observable at the luminal surface of all the epithelial cells. Lesser reactivity is observable in the lamina propria and in the endothelial cells (arrows) ×400.

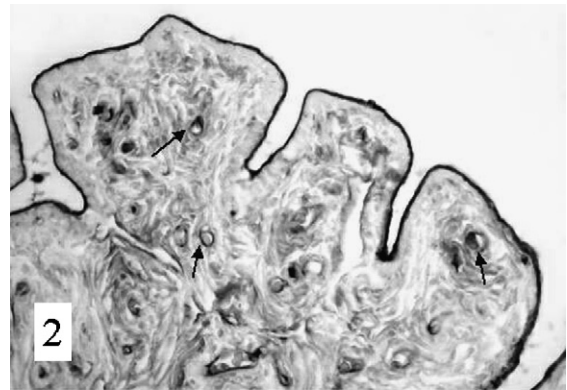


Fig. 2. MAA; biopsy no. 97/16060; postmenopausal woman; distal part of the isthmus. Strong reactivity is seen at the luminal surface of the epithelial cells and in the endothelial cells (arrows). The lamina propria shows moderate reactivity ×400.

Table 2
MAA and SNA reactivity location in the oviduct

	Epithelial cells				Lamina propria				Endothelial cells				
	MAA		SNA*		MAA		SNA		MAA		SNA		
	A	I	A	I	A	I	A	I	A	I	A	I	
Fertile women													
02/17335	+	–	+	–	0	–	+	–	+	–	+	–	
03/17850	+	+	+	+	+	+	+	+	+	+	+	+	
99/17822	+	+	+	+	+	+	+	+	+	+	+	+	
03/21850	+	+	+	+	+	+	+	+	+	+	+	+	
02/27822	+	+	+	+	0	0	0	0	0	0	+	+	
97/19913	+	–	+	–	+	–	+	–	+	–	+	–	
03/24111	+	+	+	+	0	0	0	0	+	+	+	+	
02/27824	+	+	+	+	0	0	0	0	0	0	+	+	
97/21298	+	–	+	–	0	–	0	–	+	–	+	–	
Postmenopausal women													
97/16677	+	–	+	–	0	–	0	–	+	–	+	–	
97/21945	+	–	+	–	+	–	+	–	+	–	+	–	
97/21661	+	+	+	+	0	0	0	0	+	+	+	+	
97/19216	+	+	+	+	+	+	+	+	+	+	+	+	
97/16060	–	+	–	+	–	+	–	+	–	+	–	+	
97/21299	–	+	–	+	–	+	–	0	–	+	–	+	
97/16355	+	+	+	+	+	+	+	+	+	+	+	+	
97/16866	+	+	+	+	+	+	0	0	+	+	+	+	
97/17091	+	+	+	+	+	+	+	+	0	0	0	0	
97/13074	+	+	+	+	+	+	+	+	0	0	0	0	

A: ampullary portion; I: isthmic portion; 0: no reactivity; +: reactivity; –: lack of ampullary or isthmic portion; *: only the ciliated cells.

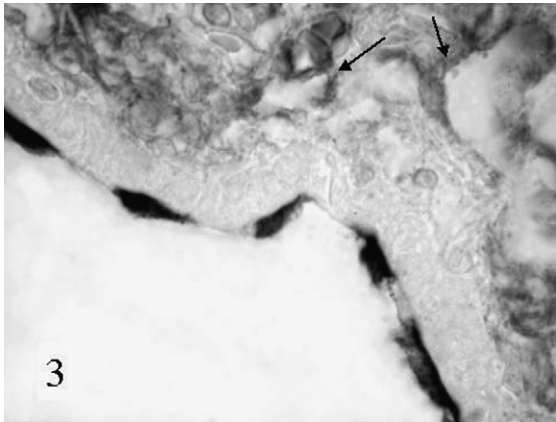


Fig. 3. SNA; biopsy no. 03/17850; fertile woman in early proliferative phase; isthmic portion. Reactivity is present at the cilia and at the luminal surface of the ciliated cells, in the lamina propria and in the endothelial cells (arrows) $\times 1000$.

SNA binding was observed in all examined fertile and postmenopausal women (Figs. 3 and 4), with the exception of the two oldest patients.

3.4. PNA and PNA reactivity location with enzymatic and chemical treatments

3.4.1. Epithelial cells (Tables 3 and 4)

In the fertile women, PNA reactivity was detected at the cilia and at the luminal surface of the ciliated cells

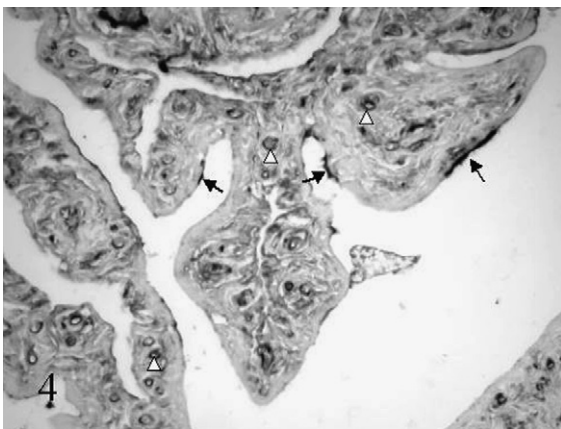


Fig. 4. SNA; biopsy no. 97/16060; postmenopausal woman; isthmic portion. The cilia and the luminal surface of few ciliated cells (arrows) and the endothelial cells (white arrows heads) show strong reactivity. The lamina propria moderately reacts $\times 400$.

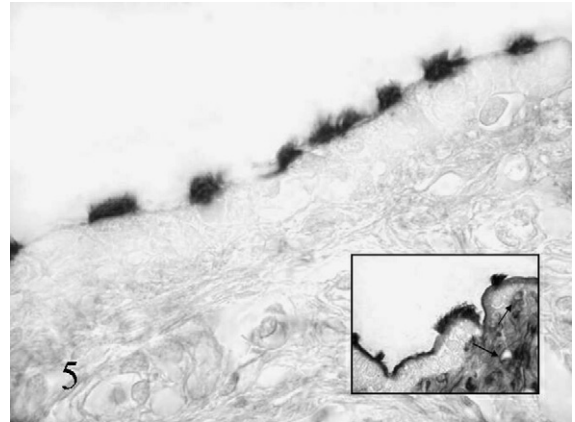


Fig. 5. PNA; biopsy no. 03/21850; fertile woman in late proliferative phase; isthmic portion. Reactivity is observable at the cilia and at the luminal surface of the ciliated cells $\times 1000$. Insert: neuraminidase-PNA. Reactivity is observable at the cilia and at the luminal surface of the ciliated cells, at the luminal surface of the secreting cells, in the lamina propria and in the endothelial cells (arrows) $\times 170$.

(Fig. 5). Following neuraminidase and deacetylation-neuraminidase treatments, reactivity was observed at the luminal surface of the secreting cells and at the cilia and the luminal surface of the ciliated cells (insert Fig. 5).

In the postmenopausal patients PNA reactivity was observed at the luminal surface of the secreting cells in three subjects, and at the cilia and at the luminal surface of the ciliated cells in all the patients (Fig. 7). After neuraminidase and deacetylation-neuraminidase treatments, reactivity was observable in both the epithelial cells in all the subjects (insert Fig. 7).

After mild oxidation followed by neuraminidase treatment, and by deacetylation-neuraminidase, PNA reactivity, was detected in the epithelial cells of both the study groups (Figs. 6 and 8). Strong oxidation-neuraminidase, with or without deacetylation, abolished PNA reactivity both in the fertile and the postmenopausal women (inserts Figs. 6 and 8).

3.4.2. Lamina propria (Tables 5 and 6)

Absence of PNA reactivity was constantly detected in fertile women (Fig. 5). Following neuraminidase and deacetylation-neuraminidase treatments, reactivity appeared in the lamina propria (insert Fig. 5). After mild oxidation-neuraminidase treatment, and mild oxidation-deacetylation-

Table 3
Fertile women. PNA reactivity location in the oviductal epithelial cells

	PNA		Neu-PNA		KOH-Neu-PNA		1 mM PO-Neu-PNA		44 mM PO-Neu-PNA		1 mM PO-KOH-Neu-PNA		44 mM PO-KOH-Neu-PNA	
	S	C	S	C	S	C	S	C	S	C	S	C	S	C
02/17335														
A	0	+	+	+	+	+	+	+	0	0	+	+	0	0
03/17850														
A	0	+	+	+	+	+	+	+	0	0	+	+	0	0
I	0	+	+	+	+	+	+	+	0	0	+	+	0	0
99/17822														
A	0	+	+	+	+	+	+	+	0	0	+	+	0	0
I	0	+	+	+	+	+	+	+	0	0	+	+	0	0
03/21850														
A	0	+	+	+	+	+	+	+	0	0	+	+	0	0
I	0	+	+	+	+	+	+	+	0	0	+	+	0	0
02/27822														
A	0	+	+	+	+	+	+	+	0	0	+	+	0	0
I	0	+	+	+	+	+	+	+	0	0	+	+	0	0
97/19913														
A	0	+	+	+	+	+	+	+	0	0	+	+	0	0
03/24111														
A	0	+	+	+	+	+	+	+	0	0	+	+	0	0
I	0	+	+	+	+	+	+	+	0	0	+	+	0	0
02/27824														
A	0	+	+	+	+	+	+	+	0	0	+	+	0	0
I	0	+	+	+	+	+	+	+	0	0	+	+	0	0
97/21298														
A	0	+	+	+	+	+	+	+	0	0	+	+	0	0

A: ampullary portion; I: isthmic portion; S: secreting cells; C: ciliated cells; 0: no reactivity; +: reactivity.

neuraminidase, reactivity was abolished, but two cases (Fig. 6).

In the postmenopausal women, no PNA reactivity was detected, but two cases (Fig. 7). After neuraminidase treatment, PNA reactivity was observed in the ampullary portion in five women and in the isthmic portion in four subjects. After deacetylation-neuraminidase treatment, in all cases PNA reactivity appeared, but two cases (insert Fig. 7). After mild oxidation-neuraminidase and mild oxidation-deacetylation-neuraminidase, PNA reactivity was abolished in some cases (Fig. 8).

After strong oxidation-neuraminidase or strong oxidation-deacetylation-neuraminidase, PNA reactivity was abolished in all the fertile women and in some postmenopausal subjects (inserts Figs. 6 and 8).

3.4.3. Endothelial cells (Tables 7 and 8)

In the fertile women, no PNA reactivity was observed in the endothelial cells of the vessels (Fig. 5). After neuraminidase and deacetylation-neuraminidase treatments, PNA reactivity appeared in the vessels in all the patients (insert Fig. 5).

In the postmenopausal women, no PNA reactivity was observed (Fig. 7). After neuraminidase and deacetylation-neuraminidase treatments, appearance of PNA reactivity was observed in the vessels in all the women, with the exception of the ampullary portion in the two oldest subjects (insert Fig. 7).

After mild and strong oxidation-neuraminidase with or without deacetylation, PNA reactivity was abolished in both the study groups (Fig. 6 and insert, Fig. 8 and insert).

Table 4
Postmenopausal women. PNA reactivity location in the oviductal epithelial cells

	PNA		Neu-PNA		KOH-Neu-PNA		1 mM PO-Neu-PNA		44 mM PO-Neu-PNA		1 mM PO-KOH-Neu-PNA		44 mM PO-KOH-Neu-PNA	
	S	C	S	C	S	C	S	C	S	C	S	C	S	C
97/16677														
A	0	+	+	+	+	+	+	+	0	0	+	+	0	0
97/21945														
A	0	+	+	+	+	+	+	+	0	0	+	+	0	0
97/21661														
A	0	+	+	+	+	+	+	+	0	0	+	+	0	0
I	0	+	+	+	+	+	+	+	0	0	+	+	0	0
97/19216														
A	0	+	+	+	+	+	+	+	0	0	+	+	0	0
I	0	+	+	+	+	+	+	+	0	0	+	+	0	0
97/16060														
I	+	+	+	+	+	+	+	+	0	0	+	+	0	0
97/21299														
I	0	+	+	+	+	+	+	+	0	0	+	+	0	0
97/16355														
A	+	+	+	+	+	+	+	+	0	0	+	+	0	0
I	+	+	+	+	+	+	+	+	0	0	+	+	0	0
97/16866														
A	0	+	+	+	+	+	+	+	0	0	+	+	0	0
I	0	+	+	+	+	+	+	+	0	0	+	+	0	0
97/17091														
A	+	+	+	+	+	+	+	+	0	0	+	+	0	0
I	+	+	+	+	+	+	+	+	0	0	+	+	0	0
97/13074														
A	0	+	+	+	+	+	+	+	0	0	+	+	0	0
I	0	+	+	+	+	+	+	+	0	0	+	+	0	0

A: ampullary portion; I: isthmic portion; S: secreting cells; C: ciliated cells; 0: no reactivity; +: reactivity.

3.5. Statistical analysis of lectin reactivity intensity

3.5.1. Differences in PNA reactivity with and without treatments

Epithelial cells: In all the fertile women, PNA reactivity intensity after neuraminidase treatment was significantly higher compared to PNA reactivity intensity in the ciliated cells ($P < 0.01$) and, in the postmenopausal women, in the secreting cells of the cases 97/16060, 97/16355, 97/17091 ($P < 0.01$), and in the ciliated cells of the cases 97/21661, 97/19216, 97/16060, 97/17091, 97/13074 ($P < 0.05$). In the fertile women PNA reactivity intensity after deacetylation-neuraminidase treatment was signifi-

cantly higher, compared to PNA reactivity intensity after neuraminidase, in secreting and ciliated cells of the all the cases ($P < 0.05$), and in the postmenopausal women in the secreting cells of the cases 97/16677, 97/21945, 97/21661, 97/19216, 97/21299 and in the ciliated cells of the cases 97/16677, 97/21299 ($P < 0.05$).

Lamina propria: In the postmenopausal women PNA reactivity intensity after neuraminidase treatment was higher compared to PNA reactivity intensity in the lamina propria of the case 97/13074 ($P < 0.05$). In fertile women, PNA reactivity intensity after deacetylation-neuraminidase treatment was higher with respect to PNA reactivity intensity after neuraminidase in the cases 02/17335, 03/17850, 99/17822,

Table 5
Fertile women. PNA reactivity location in the oviductal lamina propria

	PNA	Neu-PNA	KOH-Neu-PNA	1 mM PO-Neu-PNA	44 mM PO-Neu-PNA	1 mM PO-KOH-Neu-PNA	44 mM PO-KOH-Neu-PNA
02/17335							
A	0	+	+	0	0	0	0
03/17850							
A	0	+	+	+	0	+	0
I	0	+	+	+	0	+	0
99/17822							
A	0	+	+	+	0	+	0
I	0	+	+	+	0	+	0
03/21850							
A	0	+	+	0	0	0	0
I	0	+	+	0	0	0	0
02/27822							
A	0	+	+	0	0	0	0
I	0	+	+	0	0	0	0
97/19913							
A	0	+	+	0	0	0	0
03/24111							
A	0	+	+	0	0	0	0
I	0	+	+	0	0	0	0
02/27824							
A	0	+	+	0	0	0	0
I	0	+	+	0	0	0	0
97/21298							
A	0	+	+	0	0	0	0

A: ampullary portion; I: isthmic portion; 0: no reactivity; +: reactivity.

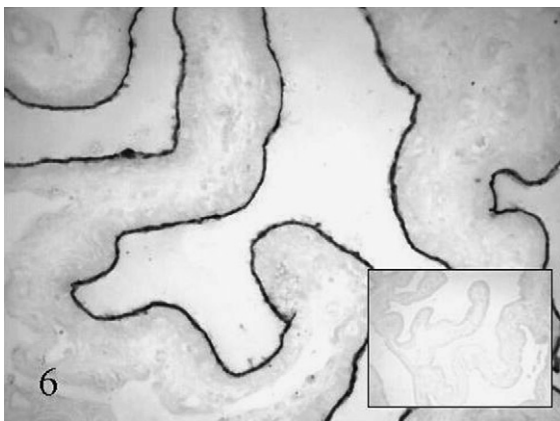


Fig. 6. Mild oxidation-KOH-neuraminidase-PNA; biopsy no. 03/21850; fertile woman in late proliferative phase; ampullary portion. The luminal surface of the epithelial cells shows reactivity $\times 200$. Insert: strong oxidation-KOH-neuraminidase-PNA. Reactivity is completely lost $\times 20$.

02/27824, 97/21298 ($P < 0.01$), and in the postmenopausal women in the cases 97/16355, 97/17091, 97/13074 ($P < 0.05$).

Endothelial cells: In the postmenopausal women PNA reactivity intensity after deacetylation-neuraminidase was higher compared to PNA reactivity intensity after neuraminidase in the cases 97/16060, 97/21299, 97/16355, 97/16866, 97/13074 ($P < 0.05$).

3.5.2. Differences between the PNA reactivity with deacetylation-neuraminidase treatment and the MAA and SNA reactivity

Epithelial cells: In the fertile women PNA reactivity intensity after deacetylation-neuraminidase was higher in the epithelial cells of the cases 99/17822, 03/24111, 02/27824 compared to the MAA reactivity intensity, and of the cases 99/17822, 03/24111 with respect to SNA reactivity intensity ($P < 0.05$).

Table 6
Postmenopausal women. PNA reactivity location in the oviductal lamina propria

	PNA	Neu-PNA	KOH-Neu-PNA	1 mM PO-Neu-PNA	44 mM PO-Neu-PNA	1 mM PO-KOH-Neu-PNA	44 mM PO-KOH-Neu-PNA
97/16677							
A	0	0	+	0	0	0	0
97/21945							
A	0	+	+	+	+	+	+
97/21661							
A	0	0	0	0	0	0	0
I	0	0	+	0	0	0	0
97/19216							
A	0	+	+	+	+	+	+
I	0	0	+	0	0	0	+
97/16060							
I	+	+	+	+	0	+	0
97/21299							
I	0	0	+	0	0	0	0
97/16355							
A	0	+	+	+	+	+	+
I	0	+	+	+	+	+	+
97/16866							
A	0	0	0	0	0	0	0
I	0	0	+	0	0	0	0
97/17091							
A	0	+	+	+	+	+	+
I	0	+	+	+	+	+	+
97/13074							
A	+	+	+	+	+	+	+
I	+	+	+	+	+	+	+

A: ampullary portion; I: isthmic portion; 0: no reactivity; +: reactivity.

Lamina propria: In the fertile women PNA reactivity intensity after deacetylation-neuraminidase was higher compared to MAA and SNA reactivity intensity in the cases 03/17850, 99/17822 ($P < 0.05$). In the postmenopausal women it was higher compared to MAA and SNA reactivity intensity in the cases 97/16355, 97/17091, 97/13074, and lower compared to MAA in the case 97/21299 ($P < 0.05$).

Endothelial cells: In the fertile women PNA reactivity intensity after deacetylation-neuraminidase was higher, compared to MAA reactivity intensity in the cases 02/17335, 03/17850, 03/17822, 97/19913, 03/24111, 97/21298 ($P < 0.05$). Comparing to SNA it was higher in the cases 03/17850, 03/17822, 97/19913, 03/24111, 97/21298, and lower in the case 02/17335 ($P < 0.05$).

3.5.3. Differences in lectin reactivity between fertile women

In the endothelial cells MAA reactivity intensity was higher in the cases 03/21850, 03/24111 with respect to the others. SNA reactivity intensity was higher in the cases 02/17335, 03/17850, 99/171822, 03/21850, 02/27822, 03/24111 ($P < 0.01$). In the lamina propria PNA reactivity intensity after neuraminidase treatment was higher in the cases 03/21850, 02/27822, 97/19913, 03/24111 ($P < 0.01$).

3.5.4. Differences in lectin reactivity between postmenopausal women

Epithelial cells: PNA reactivity intensity was higher in the ciliated cells of the cases 97/21945, 97/16355, 97/16866 compared to the others ($P < 0.05$). PNA

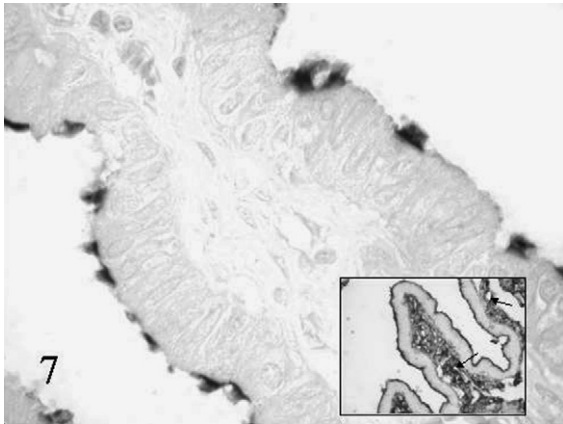


Fig. 7. PNA; biopsy no. 97/21945; postmenopausal woman; ampullary portion. Strong reactivity is observable at the cilia and at the luminal surface of the ciliated cells $\times 400$. Insert: KOH-neuraminidase-PNA. The luminal surface of all the epithelial cells, the lamina propria and the endothelial cells (arrows) show reactivity $\times 70$.

reactivity intensity after neuraminidase treatment and mild oxidation-neuraminidase was higher in the secreting cells of the cases 97/16060, 97/16866, 97/17091, 97/13074, and in the ciliated cells of the cases 97/21945, 97/21661, 97/19216, 97/16060, 97/16355, 97/16866, 97/17091, 97/13074 ($P < 0.05$). PNA reactivity intensity after deacetylation-neuraminidase treatment and deacetylation-neuraminidase-mild oxi-

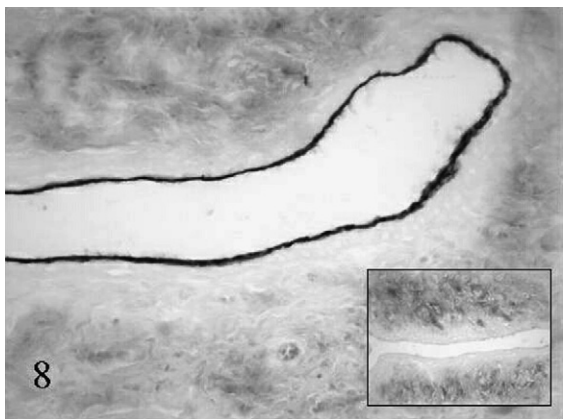


Fig. 8. Mild oxidation-KOH-neuraminidase-PNA; biopsy no. 97/13074; postmenopausal woman; isthmic portion. Reactivity is showed at the luminal surface of the epithelial cells and in the lamina propria $\times 400$. Insert: strong oxidation-KOH-neuraminidase-PNA. Reactivity is seen only in the lamina propria $\times 40$.

dation was lower in the secreting cells of the case 97/16355 with respect to the others ($P < 0.05$).

Lamina propria: MAA reactivity intensity was lower in the cases 97/16866, 97/17091, and SNA reactivity intensity in the case 97/17091 ($P < 0.05$). PNA reactivity intensity was lower in the case 97/13074, and after deacetylation-neuraminidase treatment in the cases 97/16677, 97/21661, 97/21299, 97/16866 ($P < 0.01$).

Endothelial cells: PNA reactivity intensity after neuraminidase treatment was lower in the cases 97/16060, 97/21299, 97/16355, 97/16866, 97/13074 ($P < 0.05$).

3.5.5. Differences between fertile and postmenopausal women

Epithelial cells: PNA reactivity intensity in the ciliated cells of all the postmenopausal cases was higher with respect to the fertile ones ($P < 0.05$). PNA reactivity intensity after neuraminidase treatment and mild oxidation neuraminidase was higher in the secreting cells of the postmenopausal cases 97/16060, 97/16866, 97/17091, 97/13074, and in the ciliated cells of the postmenopausal cases 97/21945, 97/21661, 97/19216, 97/16060, 97/16355, 97/16866, 97/17091, 97/13074 compared to all the fertile cases ($P < 0.05$).

Lamina propria: MAA reactivity intensity in all the cases of the fertile women was higher compared to the cases 97/16866, 97/17091 of the postmenopausal women ($P < 0.05$); SNA reactivity intensity was higher only compared to the case 97/17091 ($P < 0.05$). PNA reactivity intensity after neuraminidase treatment was lower in the fertile cases 02/17335, 03/17850, 99/17822, 02/27824, 97/21298 with respect to the postmenopausal cases showing reactivity ($P < 0.05$). After mild oxidation-neuraminidase it was lower in the postmenopausal cases showing reactivity, compared to the fertile ones ($P < 0.05$). PNA reactivity intensity after deacetylation-neuraminidase treatment in the fertile cases was higher with respect to the postmenopausal cases 97/16677, 97/211661, 97/21299, 97/16866 ($P < 0.01$).

Endothelial cells: MAA reactivity intensity was lower in the fertile cases 02/17335, 03/17850, 99/17822, 97/19913, 97/21298, and SNA reactivity intensity in the cases 97/19913, 02/27824, 97/21298 compared to the postmenopausal women ($P < 0.01$). PNA reactivity intensity after neuraminidase treatment was higher in the fertile cases with respect to

Table 7
Fertile women. PNA reactivity location in the vessels endothelial cells of the oviduct

	PNA	Neu-PNA	KOH-Neu-PNA	1 mM PO-Neu-PNA	44 mM PO-Neu-PNA	1 mM PO-KOH-Neu-PNA	44 mM PO-KOH-Neu-PNA
02/17335							
A	0	+	+	0	0	0	0
03/17850							
A	0	+	+	0	0	0	0
I	0	+	+	0	0	0	0
99/17822							
A	0	+	+	0	0	0	0
I	0	+	+	0	0	0	0
03/21850							
A	0	+	+	0	0	0	0
I	0	+	+	0	0	0	0
02/27822							
A	0	+	+	0	0	0	0
I	0	+	+	0	0	0	0
97/19913							
A	0	+	+	0	0	0	0
03/24111							
A	0	+	+	0	0	0	0
I	0	+	+	0	0	0	0
02/27824							
A	0	+	+	0	0	0	0
I	0	+	+	0	0	0	0
97/21298							
A	0	+	+	0	0	0	0

A: ampullary portion; I: isthmic portion; 0: no reactivity; +: reactivity.

postmenopausal ones 97/16060, 97/21299, 97/16355, 97/16866, 97/13074 ($P < 0.05$).

3.6. Controls

Sections incubated with lectins and their corresponding hapten sugars and sections incubated with unconjugated lectins, were unstained. Sections incubated with enzyme-free buffer, did not show any change in lectin binding. Results of the efficacy of enzymatic digestion were as expected. Desulphation procedure did not prove to affect the subsequent lectins-binding.

4. Discussion

Direct and indirect demonstration of the heterogeneity of sialoderivatives has been shown in the epithelium

of the ampulla and isthmus in rabbit oviduct under hormonal treatment using lectin histochemistry [5]. Such different expression of sialoderivatives has been considered to play an important role for gamete transport and maturation, fertilization and early embryo development. Moreover, it has been experimentally demonstrated in hamster [6] that adherence between sperm and oviduct involves a specific interaction with a sialic acid-like moiety. The same behaviour was experimentally seen in rat, i.e. free and protein-bound sialic acid was seen as a candidate monosaccharide playing a role in the binding of spermatozoa to oviductal epithelial cells [7].

In our study, lectin histochemistry demonstrated that the human oviduct epithelium was characterized by a large amount of sialoderivatives in both the fertile and the postmenopausal women. It is noteworthy that no significant difference in sialic acids distribution was

Table 8
Postmenopausal women. PNA reactivity location in the vessels endothelial cells of the oviduct

	PNA	Neu-PNA	KOH-Neu-PNA	1 mM PO-Neu-PNA	44 mM PO-Neu-PNA	1 mM PO-KOH-Neu-PNA	44 mM PO-KOH-Neu-PNA
97/16677							
A	0	+	+	0	0	0	0
97/21945							
A	0	+	+	0	0	0	0
97/21661							
A	0	+	+	0	0	0	0
I	0	+	+	0	0	0	0
97/19216							
A	0	+	+	0	0	0	0
I	0	+	+	0	0	0	0
97/16060							
I	0	+	+	0	0	0	0
97/21299							
I	0	+	+	0	0	0	0
97/16355							
A	0	+	+	0	0	0	0
I	0	+	+	0	0	0	0
97/16866							
A	0	+	+	0	0	0	0
I	0	+	+	0	0	0	0
97/17091							
A	0	0	0	0	0	0	0
I	0	+	+	0	0	0	0
97/13074							
A	0	0	0	0	0	0	0
I	0	+	+	0	0	0	0

A: ampullary portion; I: isthmic portion; 0: no reactivity; +: reactivity.

observed between the ampullary and isthmic portions, in both the study groups, and among the fertile women in different hormonal phases. These findings are concordant with the results obtained in some mammal specie, such as rat [7], but not in other, such as rabbit [5].

In particular, in both the study groups our findings showed the presence of sialic acid linked $\alpha(2-3)$ to galactose [5,11] at the luminal surface of both the secreting and the ciliated cells and at the cilia of the ciliated cells, and of sialic acid linked $\alpha(2-6)$ to galactose or galactosamine [5,10] only at cilia and at luminal surface of the ciliated cells.

In all the fertile women and in the most of postmenopausal ones, sialic acid linked to D-galactose- $(\beta 1-3)$ -N-acetyl-D-galactosamine was present at the

luminal surface of the secreting cells and at the cilia and at the luminal surface of the ciliated cells. In some cases of postmenopausal women a lesser amount and in other absence of sialic acid linked to this dimer were observed in the ciliated cells. It is to hypothesize that sialic acid linked to D-galactose- $\beta(1-3)$ -N-acetyl-D-galactosamine may play a role in maintaining the functionality of the cilia. Schulte and Spicer [8] and Ito et al. [19] suggested that sialic acid keeps the cilia separated one from another in order to maintain the ciliary motility. Therefore, in some postmenopausal women the lacking of this carbohydrate could impair these functions.

Sialic acid containing acetylic groups on C₄ of pyranose ring [14] was detected at the epithelial cells of all the fertile women, but only of some postmenopausal

women. Sialic acid with C₇ and/or C₈ and/or C₉-O-acetylic groups in the side chain was observed in the epithelial cells of all the patients both in the fertile and postmenopausal women [15].

The lamina propria, in some fertile and postmenopausal women, was characterized by the presence of sialic acid linked $\alpha(2,3)$ and $\alpha(2,6)$. In all the fertile women, the lamina propria showed the presence of sialic acid linked to D-galactose-(β 1-3)-N-acetyl-D-galactosamine, but only in some cases of sialic acid with acetylic groups on C₄, and on C₇ and/or C₈ and/or C₉. In the oviduct of the postmenopausal women, sialic acids linked to the dimer, with or without acetylic groups, showed discontinuous behaviour.

With few exceptions, sialic acids linked $\alpha(2,3)$, $\alpha(2,6)$ and linked to D-galactose-(β 1-3)-N-acetyl-D-galactosamine were detected in the endothelial cells of the vessels of both the fertile and postmenopausal women. In some postmenopausal women sialic acid with acetylic groups on C₄ was also present.

The different content of sialoderivatives, at the epithelium luminal surface, in the lamina propria and in the endothelial cells of the vessels in the oviduct of some postmenopausal women, with respect to the fertile ones, might indicate altered glycosylation of the glycocalix of the epithelial cells, of the collagen fibres of the stroma and of the plasma membrane of the endothelial cells. This alteration could be related to morphofunctional alterations occurring during the ageing of the organ.

SNA and MAA staining, both in the oviduct of the fertile and of the postmenopausal women, appeared sometimes more intense comparing with that obtained with PNA after treatments. On the other hand, direct and indirect methods can identify sialic acids differently linked to various sugar residues [5,13]. Furthermore, in many cases higher PNA reactivity intensity after deacetylation-neuraminidase treatment compared to MAA and SNA reactivity was found. It is to be noted that sialic acid can be linked to other sialic acids making differently long chains. Probably these polysialic acid chains might interfere with SNA and MAA binding which recognize sialic acid and its linkages $\alpha(2,3)$ and $\alpha(2,6)$ to the penultimate sugar residues galactose and/or galactosamine. No direct lectin method is nowadays available to demonstrate these chains.

It is to be considered that all these findings regarded a limited number of cases both in the fertile and in the postmenopausal women groups. However, patients, in both the study groups, showed a wide age range, and the fertile women were in various hormonal phases. Therefore, we think that our main findings arising from few cases can be representative of findings from a higher number of cases.

Differently from the oviductal secretory cells of other mammals [5,20], our results showed that no sign of sialic acid secretion was detected, lacking lectin reactivity in cytoplasm granules of these cells. This suggests that sialic acid is absent in the oviductal fluid. Therefore, it does not take part in any function normally attributed to this fluid, such as: enhancing sperm capacitation and binding to zona pellucida; facilitating sperm penetration and increasing its viscosity; immunological protection of the eggs, spermatozoa and early embryos [21–24]. Instead, the presence of different sialoderivatives has been a constant finding at the luminal surface of the oviductal epithelial cells without any significative difference between the oviduct portions or during the phases of the menstrual cycle. Several investigations have shown the importance of sialic acid in the oviduct of different mammal's species to keep spermatozoa, to capacitate and to enhance the motility of the male gamete. This is due to the presence of sialylated groups at the apical surface of the oviductal epithelial cells and at the head membrane of the spermatozoa. These groups are characterized by the presence of negative charges, so the spermatozoa can bind to the oviductal epithelial cells thanks to the presence of Ca²⁺ ions [5–7,23]. In other mammals, such as horse and bovine, these functions are attributed to other oligosaccharides [25–29]. Anyway, an important role especially in the preovulatory phase attributed to these oligosaccharides is to hold spermatozoa with a sperm-epithelial binding in the formation of an isthmic reservoir. Since we did not detect, also in preovulatory phase, any difference in the type and/or cellular distribution of sialic acids between ampulla and isthmus in the humans, we cannot hypothesize a sure role of sialic acid in determining the reservoir function. On the other hand, also Cortes et al. [7] observed in rat the same distribution of sialoglycoconjugates in the ampulla and isthmus and no change was seen along the estrous cycle. However, previously they observed that sperm binding to the oviduct epithelium was limited to the isthmic segment and to

proestrous and estrous [30]. The authors made various hypotheses. In fact, it is possible that the sperm binding is limited to the isthmus, because it is the first segment encountered by spermatozoa when they arrive in the oviduct. The sialoglycoproteins really involved in binding might be too small, with respect to others, to be revealed. In addition, sex hormones could influence the ability of the sperm cells to bind to the oviductal epithelium. Therefore, similar hypotheses could be extended also in the human oviduct. However, we cannot exclude a role of the sialoderivatives in capacitating. In fact it is well known that the sperm capacitating is consequent to the attachment of the sperm to the luminal surface of the oviductal epithelium [31–34].

Another role played by this oligosaccharide could be to enhance sperm mobility and facilitate the transit of the egg and of the early embryo along the oviducts. The progression of the spermatozoa and of the egg is regulated by the cilia movement. The presence of sialic acid with its negative charges, could play a role, as previously mentioned, in maintaining the functionality of the cilia, keeping them separated one from another.

In conclusion, the main finding of this study was the presence of sialoderivatives at the luminal surface of the epithelial cells in the oviduct of the fertile women, with the same distribution in different hormonal phases and in both the ampullary and isthmic portions. This suggests a role of sialic acids in sperm capacitating and mobility and in facilitating the transit of the egg and the early embryo along the oviduct. Moreover, the similar distribution of sialoderivatives in the oviducts of some postmenopausal women, suggests that in these cases some functions of the oviduct are maintained. Surprisingly, the oviducts showing these features came from women of very different age. It is to hypothesize that some postmenopausal women, independently from the age, might present a still sufficient hormonal level that could maintain an almost normal distribution of sialoderivatives.

References

- [1] Schulte BA, Rao KP, Kreutner A, Thomopoulos GN, Spicer SS. Histochemical examination of glycoconjugates of epithelial cells in the human Fallopian tube. *Lab Invest* 1985;52:207–19.
- [2] Wu TJ, Lee S, Jih MH, Liu JT, Wan YY. Differential distribution of glycoconjugates in human reproductive tract. *Fertil Steril* 1993;59:60–4.
- [3] Kiss H, Walter I, Lehner R, Egarter C, Breitenecker G, Bock P. Lectin histochemistry of fallopian tube epithelial cells. *J Reprod Med* 1998;43:535–40.
- [4] Gheri G, Noci I, Sgambati E, Borri P, Taddei G, Gheri Bryk S. Ageing of the human oviduct: lectin histochemistry. *Histol Histopathol* 2001;16:21–8.
- [5] Gabrielli MG, Bondi AM, Materazzi G, Menghi G. Differential location and structural specificities of sialic acid- β -D-Gal sequences belonging to sialoderivatives of rabbit oviduct under hormonal treatment. *Histol Histopathol* 2004;19:1175–86.
- [6] Demott RP, Lefebvre R, Suarez SS. Carbohydrates mediate the adherence of hamster sperm to oviductal epithelium. *Biol Reprod* 1995;52:1395–403.
- [7] Cortés PP, Orihuela PA, Zúniga LM, Velásquez LA, Croxatto HB. Sperm binding to oviductal epithelial cells in the rat: role of sialic acid residues on the epithelial surface and sialic acid-binding sites on the sperm surface. *Biol Reprod* 2004;71:1262–9.
- [8] Schulte BA, Spicer SS. Histochemical methods for characterizing secretory and cell surface sialoglycoconjugates. *J Histochem Cytochem* 1985;33:427–38.
- [9] Varki A. Sialic acids as ligands in recognition phenomena. *FASEB J* 1997;11:248–55.
- [10] Shibuya N, Goldstein IJ, Broekaert W-F, Nsimba-Lubaki M, Peeters B, Peumans WJ. The ederberry (*Sambucus nigra* L.) bark lectin recognizes the Neu5Ac(α 2,6)Gal/GalNAc sequence. *J Biol Chem* 1987;262:1596–601.
- [11] Wang WC, Cummings RD. The immobilized leucoagglutinin from the seeds of *Maackia amurensis* binds with high affinity to complex-type asn-linked oligosaccharides containing terminal sialic acid linked α 2,3 to penultimate galactose residues. *J Biol Chem* 1988;263:4576–85.
- [12] Schultka R, Cech S. Application of “mild” periodic oxidation to the ultrahistochemical detection of sialic acid-compounds in human Fallopian tube epithelium. *Acta Histochem* 1990;88:65–9.
- [13] Madrid JF, Aparicio R, Sáez FJ, Hernández F. Lectin cytochemical characterization of the N- and O-linked oligosaccharides in the human rectum. *Histochem J* 2000;32:281–9.
- [14] Moschera J, Pigman W. The isolation and characterization of rat sublingual mucus-glycoprotein. *Carbohydr Res* 1975;40:53–67.
- [15] Roberts JP. Histochemical detection of sialic acid residues using periodate oxidations. *Histochem J* 1977;9:97–102.
- [16] Plendl J, Schonleber B, Schmahl W, Schumacher V. Comparison of the unmasking of lectin receptors by neuraminidase and by enzyme-free buffer alone. *J Histochem Cytochem* 1989;37:1743–4.
- [17] Martínez-Menarguez JA, Ballesta J, Aviles M, Madrid JF, Castellás MT. Influence of sulphate groups in the binding of peanut agglutinin. Histochemical demonstration with light- and electron-microscopy. *Histochem J* 1992;24:207–16.
- [18] Hafez ESE. Scanning electron microscopy of female reproductive organs during menopause and related pathologies. In: Fioretti P, Martini L, Melis GB, Yen SSC, editors. The menopause: clinical, endocrinological and pathophysiological

- aspects, serono symposium. London and New York: Academic Press; 1982. p. 201–17.
- [19] Ito T, Newkirk C, Strum JM, McDowell EM. Changes in glycoconjugates revealed by lectin staining in the developing airways of syrian golden hamster. *Anat Rec* 1990;228:151–62.
- [20] Desantis S, Acone F, Corriero A, et al. Distribution of sialoglycoconjugates in the oviductal isthmus of the horse during anoestrus, oestrus and pregnancy: a lectin histochemistry study. *Eur J Histochem* 2004;48:403–12.
- [21] Way AL, Schuler AM, Killian GJ. Influence of bovine ampullary and isthmic oviductal fluid on sperm-egg binding and fertilization in vitro. *J Reprod Fertil* 1997;109:95–101.
- [22] Rodriguez C, Killian G. Identification of ampullary and isthmic oviductal fluid proteins that associate with the bovine sperm membrane. *Anim Reprod Sci* 1998;54:1–12.
- [23] Leese HJ, Tay JI, Reischl J, Downing SJ. Formation of Fallopian tubal fluid: role of a neglected epithelium. *Reproduction* 2001;121:339–46.
- [24] Killian GJ. Evidence for the role of oviduct secretions in sperm function, fertilization and embryo development. *Anim Reprod Sci* 2004;82:141–53.
- [25] Suarez SS. The oviductal sperm reservoir in mammals: mechanism of formation. *Biol Reprod* 1998;58:1105–7.
- [26] Suarez SS, Igotz G. Fucosylated glycoproteins from oviductal epithelium bind PDC-109 and maybe involved in creating the reservoir of sperm in the bovine oviduct. In: 34th Annual Meeting Society for the Study of Reproduction. 2001.
- [27] Ho HC, Suarez SS. Hyperactivation of mammalian spermatozoa: function and regulation. *Reproduction* 2001;122:519–26.
- [28] Suarez SS. Formation of a reservoir of sperm in the oviduct. *Reprod Dom Anim* 2002;37:140–3.
- [29] Suarez SS, Pacey AA. Sperm transport in the female reproductive tract. *Hum Reprod Update* 2006;12:23–37.
- [30] Orhiuela PA, Ortiz ME, Croxatto HB. Sperm migration into and through the oviduct following artificial insemination at different stages of estrous cycle in the rat. *Biol Reprod* 1999;60:908–13.
- [31] Kervancioglu ME, Djahanbakhch O, Aitken RJ. Epithelial cell coculture and the induction of sperm capacitation. *Fertil Steril* 1994;61:1103–8.
- [32] Pacey AA, Davies N, Warren MA, Barrat CL, Cooke ID. Hyperactivation may assist human spermatozoa to detach from intimate association with the endosalpinx. *Hum Reprod* 1995;10:2603–9.
- [33] Murray SC, Smith TT. Sperm interaction with Fallopian tube apical membrane enhances sperm motility and delays capacitation. *Fertil Steril* 1997;68:351–7.
- [34] Kervancioglu ME, Saridogan E, Aitken RJ, Djahanbakhch O. Importance of sperm-to-epithelial cell contact for the capacitation of human spermatozoa in fallopian tube epithelial cell cocultures. *Fertil Steril* 2000;74:780–4.