



UNIVERSITÀ  
DEGLI STUDI  
FIRENZE

## FLORE

# Repository istituzionale dell'Università degli Studi di Firenze

### **C-kit expression in uterine leiomyosarcomas: an immunocytochemical study of 29 cases of malignant smooth muscle tumors of the uterus.**

Questa è la Versione finale referata (Post print/Accepted manuscript) della seguente pubblicazione:

*Original Citation:*

C-kit expression in uterine leiomyosarcomas: an immunocytochemical study of 29 cases of malignant smooth muscle tumors of the uterus / Raspollini M.R.; Villanucci A.; Amunni G.; Paglierani M.; Taddei A.; Taddei G.L. - In: JOURNAL OF CHEMOTHERAPY. - ISSN 1120-009X. - STAMPA. - 15:(2003), pp. 81-84.

*Availability:*

The webpage <https://hdl.handle.net/2158/336654> of the repository was last updated on 2016-11-28T19:55:53Z

*Terms of use:*

Open Access

La pubblicazione è resa disponibile sotto le norme e i termini della licenza di deposito, secondo quanto stabilito dalla Policy per l'accesso aperto dell'Università degli Studi di Firenze (<https://www.sba.unifi.it/upload/policy-oa-2016-1.pdf>)

*Publisher copyright claim:*

La data sopra indicata si riferisce all'ultimo aggiornamento della scheda del Repository FloRe - The above-mentioned date refers to the last update of the record in the Institutional Repository FloRe

(Article begins on next page)

# C-kit Expression in Uterine Leiomyosarcomas: An Immunocytochemical Study of 29 Cases of Malignant Smooth Muscle Tumors of the Uterus

M.R. RASPOLINI<sup>1</sup> - A. VILLANUCCI<sup>2</sup> - G. AMUNNI<sup>2</sup> - M. PAGLIERANI<sup>1</sup>  
A. TADDEI<sup>3</sup> - G.L. TADDEI<sup>1</sup>

<sup>1</sup>Dipartimento di Patologia Umana e Oncologia, <sup>2</sup>Dipartimento di Ginecologia, Perinatologia e Medicina della Riproduzione, <sup>3</sup>Dipartimento di Area Critica Medica-Chirurgica-Sezione Chirurgia Generale e D.C., Università degli Studi di Firenze, Florence, Italy.

*Correspondence:* Prof. Gian Luigi Taddei. Dipartimento di Patologia Umana e Oncologia, Università degli Studi di Firenze, viale G.B. Morgagni 85, 50134 Firenze, Italy.  
Tel.: +39055-4478100; +39055-4478138. Fax: +39055-4379868; +39055-430795. E-mail: gl.taddei@unifi.it

## Summary

Uterine malignant stromal tumors are rare neoplasms characterized by fatal prognosis. At the moment no effective systemic treatment is available for metastases or recurrent disease. The drugs employed in advanced neoplasms are ifosfamide, doxorubicin or epidoxorubicin, but the clinical response to chemotherapy is poor. Recent studies have shown that cells in gastrointestinal stromal tumors express a growth factor receptor with tyrosine kinase activity termed *c-kit*. Lately reports of efficacy of a specific anticancer drug with imatinib (STI571) based on specific molecular abnormalities of proto-oncogene *c-kit* present in gastrointestinal stromal tumors induced us to identify the *c-kit* phenotype also in uterine leiomyosarcomas. These data may be useful for treating metastatic uterine leiomyosarcomas with increased *c-kit* kinase activity.

**Key words:** Antigen CD117, chemotherapy, *c-kit*, imatinib (STI571), uterine leiomyosarcomas.

**Abbreviations:** CDDP: cisplatin, CR: complete response, EPI: epidoxorubicin, GIST: gastrointestinal stromal tumor, HE: hematoxylin-eosin, IFO: ifosfamide, PR: partial response, P: progression, SD: stable disease, VP16: etoposide.

## INTRODUCTION

There is no efficacious therapy for advanced solid stromal tumors, but recent clinical results obtained in some metastatic gastrointestinal stromal tumors with introduction of STI571, a phenylaminopyrimidine derivative, suggest a change in appropriately targeted cancer therapies<sup>1</sup>. STI571 is a small molecule that selectively inhibits the enzymatic activity of several tyrosine kinases as the growth factor receptor with tyrosine kinase activity termed *c-kit* gene<sup>2,3</sup>. This receptor, the product of

the proto-oncogene *c-kit*, can be detected by immunohistochemical staining for CD117<sup>4</sup>. The physiologic ligand is the cytokine stem cell factor (SCF), also called mast cell growth factor or Steel factor<sup>5</sup>. This receptor is important for the development and maintenance of hematopoietic stem cells, mast cells, germ cells, melanocytes and interstitial cells of Cajal<sup>6</sup>. Mutations of *c-kit* that cause constitutive activation of the tyrosine kinase function of *c-kit* are detectable in most gastrointestinal stromal tumors<sup>7</sup>. These mutations (insertion, deletion and/or point mutations) cause ligand-independent

phosphorylation and activation of the KIT-tyrosine kinase and consequently uncontrolled cell proliferation. In following up initial observations of *c-kit* expression in these malignant gastrointestinal stromal tumors and from preliminary analyses in recent studies<sup>8,9</sup>, we evaluated the presence of *c-kit* over-expression in malignant stromal uterine tumors in a search for highly targeted cancer therapy for these tumors which have had a fatal prognosis up to now.

## PATIENTS AND METHODS

### *Patients*

We examined slides from 29 patients aged between 39 and 76 years (median 55.17 ys) in whom malignant smooth muscle tumors of the uterus had been diagnosed between 1984 and 2001, with known follow-up, from the pathology files of our Department. All patients were staged retrospectively, according to a modified staging system of the International Federation of Gynecology and Obstetrics (FIGO) for carcinomas and mixed mesodermal tumors. We derived staging information from operative notes and pathology reports. Total abdominal hysterectomy, bilateral salpingo-oophorectomy, and removal of as much tumor as possible in cases with pelvic and/or abdominal spread, was the standard surgical procedure. Peritoneal cytology, omentectomy, and/or peritoneal biopsy were performed to rule out extrauterine disease. A total of 14 cases were stage I or II, i.e., no disease extension beyond uterus, and 15 cases were stage III or IV A, i.e. disease with regional spread. Adjuvant chemotherapy following surgery was made in advanced stages and in 4 FIGO stage I or II cases according to the presence of negative prognostic factors (age >50 years, presence of vascular space involvement, high mitotic count)<sup>10</sup>. Eighteen patients, after surgical treatment, received combination chemotherapy consisting of ifosfamide (1500 mg/m<sup>2</sup>, days 1-3) and epidoxorubicin (80 mg/m<sup>2</sup>, day 1) for 6 cycles. The response to chemotherapy was evaluated according to WHO method<sup>11</sup>: complete response (CR), partial response (PR), stable disease (SD), progression (P).

All 29 patients, at the time of diagnosis, were free of distant metastases (FIGO stage IV B). During the follow-up period, local recurrences and distant metastases were observed via pelvic examination, routine chest X-ray, ultrasonography and computed tomography. Twenty-one patients suffered from recurrences or metastases, and these patients received therapy for disease. Two patients underwent surgical treatment to resect the relapsing masses followed by chemotherapy with IFO and EPI or with CDDP and VP16; 2 cases underwent radiation therapy for recurrences and the remaining patients

with recurrences received adjuvant therapy with EPI or ifosfamide i.v. for 2 weeks (1000 mg/day) in the event of previous treatment with EPI or for those patients with short progression-free. Nine patients were alive in June 2002: 1 patient (stage I) is alive with disease after 62 months, 1 patient (stage III) is living with no evident disease after 42 months, the last 7 patients (stage I) are living with no evident disease after follow-up ranging from 6 to 74 months (median 38.42 months). Twenty patients died during the follow-up period due to disease progression: 6 patients (stage I or II) suffered from recurrences or metastases after a progression-free interval from 6 to 30 months (median 16.66 months) and they died between 8 and 54 months later (median 32 months); 14 patients (stage III or IV) suffered from recurrences or metastases after a progression-free interval from 0 to 28 months (7.35 median months) and they died from 0 to 48 months (median 15.28 months) later. The progression-free interval of all 29 uterine leiomyosarcomas was from 0 to 74 months (median 19.68 months).

### *Tissue specimens and immunohistochemistry*

Tissue specimens were obtained by surgical resection in all cases and fixed in 10% formalin before being processed in paraffin. Hematoxylin-eosin (HE) stained sections from each histological specimen were reviewed by two pathologists to confirm the histological diagnosis. We used a monoclonal antibody *c-kit* oncoprotein clone T 595 (Novocastra, Newcastle, UK) to prove CD 117 antigen in uterine leiomyosarcoma cells. The immunohistochemical study was performed using the streptavidin-biotin-peroxidase method (LAB VISION; Fremont, CA) with diaminobenzidine as chromogen and hematoxylin as counterstain. Incubation of primary antibody was carried out for 2 h at r.t. at a 1:20 dilution, following microwave antigen retrieval that was performed on dewaxed and rehydrated sections totally immersed in tris-EDTA-citrate buffer (ph 7.8) for 30 minutes. A section of strongly positive CD 117 GIST was used as positive control tissue. Negative control was performed by substituting the primary antibody with non-immune mouse serum. Brown staining of the cell membrane and cytoplasm was considered positive. The positive result of immunohistochemistry reaction of antibody specific against CD 117 oncoprotein was assessed with a semi-qualitative method.

## RESULTS

In 12 cases (41.37%) the investigated antibody (*C-kit*) showed distinct plasma membrane and cytoplasm immunoreactivity in stromal elements (*Figure*

1). Of the 12 *c-kit* positive patients, 5 were had stage I or II disease and 7 stage III disease. The *c-kit* negative cases showed a positive inside control represented by mast cells.

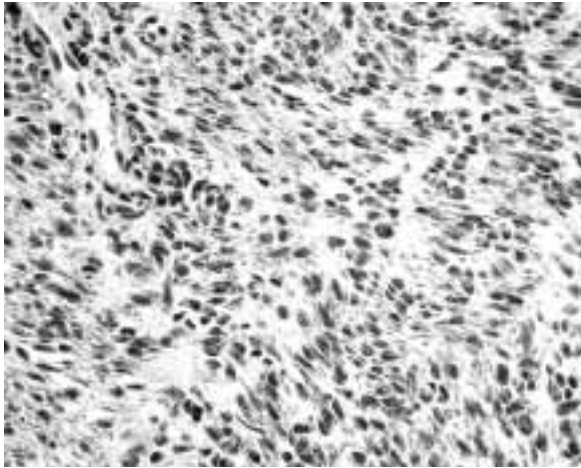


FIGURE 1 - The antibody investigated (*c-kit*) shows distinct plasma membrane and cytoplasm immunoreactivity in uterine leiomyosarcoma cells.

#### *Relation of C-kit immunohistochemistry in uterine leiomyosarcoma to clinicopathological variables*

The progression-free interval of the 14 patients with *c-kit* expression was 16.58 months, while the progression-free interval of the 15 patients without *c-kit* expression was 21.88 months. These differences between *c-kit* positive and *c-kit* negative cases hold when we analyze disease extension separately (local disease and regional spread). The progression-free interval of the 5 patients with *c-kit* expression with stage I or II disease is 29.4 months and the progression-free interval of the 7 patients with *c-kit* expression with stage III or IV disease is 7.42 months. The progression-free interval of the 9 patients without *c-kit* expression with stage I or II disease is 31 months and the progression-free interval of the 8 patients without *c-kit* expression with stage III or IV disease is 11.62 months. The overall survival of the 8 patients with *c-kit* expression who died was 16.37 months and the overall survival of the 4 living patients with *c-kit* expression is 33.25 months. The overall survival of the 12 patients without *c-kit* expression who died was 17.91 months and the overall survival of the 5 living patients without *c-kit* expression is 48 months.

Also the differences in overall survival between *c-kit* positive cases and *c-kit* negative cases remain when we analyze separately for stage I or II disease

and stage III or IV disease.

Another element emerging from our data is that the 12 patients who are *c-kit* positive are older (average age 57.33 years) than the 17 patients who are *c-kit* negative (average age 53.64 years). These data do not change when we analyze disease extension (local or regional spread). The average age of patients with *c-kit* positive stage I or II disease is 52.6 years compared to 39 years for the *c-kit* negative patients with local disease. The average age of patients with *c-kit* positive stage III or IV disease is 60.7 years compared with 58.1 years for *c-kit* negative patients with regional spread.

## DISCUSSION

Malignant mesenchymal tumors of the uterus are uncommon neoplasias that occur mainly in middle-aged and older women, deriving from smooth muscle and endometrial stroma. These tumors are characterized by their nearly absolute resistance to chemotherapy<sup>12</sup> and radiation treatment<sup>13</sup> and for their bad prognosis. Surgery is the primary treatment modality for malignant mesenchymal tumors of the uterus, but they are an incurable malignancy for patients with metastatic or unresectable disease. Twenty out of 29 of our patients with uterine leiomyosarcomas, died between 0 and 54 months (median 20.3 months). The overall progression-free disease interval of the 29 patients was 19.68 months, 30.42 months for those with stage I or II disease and 9.66 months for patients with stage III or IV disease. For this reason, new treatments for these tumors are needed.

Clinical results obtained with novel targeted cancer therapies suggest that the major molecular mechanisms that drive tumor growth need to be identified for the rational selection of appropriately targeted cancer therapies based on specific molecular abnormality in neoplastic cells<sup>14,15</sup>. About 90% of malignant gastrointestinal stromal tumors harbor a mutation in *c-kit*<sup>16,17</sup> leading to *c-kit* receptor autophosphorylation and ligand-independent activation. This new therapy with STI571 is needed only when this receptor, the product of the proto-oncogene *c-kit*, can be detected by immunohistochemical staining for CD117. There are no immunohistochemistry studies of *c-kit* mutation in malignant stromal uterine neoplasms. In the present study, we have demonstrated immunohistochemically that uterine leiomyosarcomas also express *c-kit* (CD117). The progression-free interval of the 14 patients with *c-kit* expression was 16.58 months, while the progression-free interval of the 15 patients without *c-kit* expression was 21.88 months. Our data show a trend of poorer prognosis for *c-kit* positive cases, in agreement with Taniguchi *et al.*<sup>7</sup>, who assert that

mutation-positive GISTs showed more frequent recurrences and resulted in higher mortality than the mutation-negative GISTs during the comparable follow-up periods. In addition, the presence of *c-kit* expression in uterine leiomyosarcomas in older women is in agreement with Mayerhofer *et al.*<sup>10</sup> who showed that higher age is a negative prognostic factor.

On the basis of some studies<sup>8,9</sup>, which report good clinical response in patients with advanced gastrointestinal stromal tumor with rapid symptomatic benefit and improved performance status, and on the basis of our immunohistochemical analysis on 29 uterine leiomyosarcomas, we suggest that therapy using imatinib (STI571), based on the molecular mechanisms involved in tumor growth may improve the prognosis for patients with advanced mesenchymal uterine tumors which are *c-kit* positive. However, the above results indicate the need for investigations and clinical trials on a large number of patients with metastatic uterine leiomyosarcomas.

## REFERENCES

- <sup>1</sup> Dimetri GD. Targeting c-kit mutations in solid tumors: scientific rationale and novel therapeutic options. *Semin Oncol* 2001; 28 (suppl 17): 19-26.
- <sup>2</sup> Heinrich M, Griffith D J, Druker B J, Wait C L, Ott K A, Ziegler A J. Inhibition of C-kit receptor tyrosine kinase activity by STI 571, a selective tyrosine kinase inhibitor. *Blood* 2000; 96: 925-932.
- <sup>3</sup> Joensuu H, Dimitrijevic S. Tyrosine kinase inhibitor imatinib (STI571) as an anticancer agent for solid tumours. *Ann Med* 2001; 33: 451-455.
- <sup>4</sup> Miettinen M, Sarlomo-Rikala M, Sobin LH, Lasota J. Gastrointestinal stromal tumors and leiomyosarcomas in the colon. A clinicopathologic, immunohistochemical and molecular genetic study of 44 cases. *Am J Surg Pathol* 2000; 24 (10): 1339-1352.
- <sup>5</sup> Flanagan JG, Leder P. The kit ligand: a cell surface molecule altered in steel mutant fibroblasts. *Cell* 1990; 63: 185-194.
- <sup>6</sup> Wang L, Vargas H, French SW. Cellular origin of gastrointestinal stromal tumors. A study of 27 cases. *Arch Pathol Lab Med* 2000; 124: 1471-1475.
- <sup>7</sup> Taniguchi M, Nishida T, Hirota S, *et al.* Effect of c-kit mutation on prognosis of gastrointestinal stromal tumors. *Cancer Res* 1999; 59: 4297-4300.
- <sup>8</sup> Joensuu H, Robert P J, Sarlomo-Rikala M, *et al.* Effect of the tyrosine kinase inhibitor STI571 in a patient with a metastatic gastrointestinal stromal tumor. *N Engl J Med* 2001; 344 (14): 1052-1056.
- <sup>9</sup> Van Oosterom AT, Judson I, Verweij J, *et al.* Safety and efficacy of imatinib (STI571) in metastatic gastrointestinal stromal tumours: a phase I study. *Lancet* 2001; 358: 1421-23.
- <sup>10</sup> Mayerhofer K, Obermairn A, Windbichler G, *et al.* Leiomyosarcoma of the uterus: a clinicopathologic multicenter study of 71 cases. *Gynecol Oncol* 1999; 74: 196-201.
- <sup>11</sup> De Vita VT, Hellman S, Rosemberg SA. *Cancer, Principles and Practice of Oncology*. 5th Edition, Lippincott - Raven, Philadelphia - New York, 1997: 333- 347
- <sup>12</sup> Gadducci A, Landoni F, Sartori E, *et al.* Uterine leiomyosarcoma: analysis of treatment failures and survival. *Gynecol Oncol* 1996; 62 (1): 25-32.
- <sup>13</sup> De Paco G, Stefanon B, Raspagliesi F. *Neoplasie del corpo dell'utero* in Bonadonna G, Robustelli della Cuna G. *Medicina oncologica*. (6th edition), Masson, Milano-Paris-Barcellona, 1999.
- <sup>14</sup> Druker BJ, Talpaz M, Resta DJ, *et al.* Efficacy and safety of a specific inhibitor of the BCR-ABL tyrosine kinase in chronic myeloid leukemia. *N Engl J Med* 2001; 344: 1031-1037.
- <sup>15</sup> Druker BJ, Sawyers CL, Kantarjian H, *et al.* Activity of a specific inhibitor of the BCR-ABL tyrosine kinase in the blast crisis of chronic myeloid leukemia and acute lymphoblastic leukemia with the philadelphia chromosome. *N Eng J Med* 2001; 344: 1038-1042.
- <sup>16</sup> Lasota J, Jasinski M, Sarlomo-Rikala M, Miettinen M. Mutation in exon 11 of c-kit occur preferentially in malignant versus benign gastrointestinal stromal tumors and do not occur in leiomyomas or leiomyosarcomas. *Am J Pathol* 1999; 154: 53-60.
- <sup>17</sup> Lux ML, Rubin BP, Biase TL, *et al.* Kit extracellular and kinase domain mutations in gastrointestinal stromal tumors. *Am J Pathol* 2000; 156: 791-795.