



UNIVERSITÀ  
DEGLI STUDI  
FIRENZE

## FLORE

# Repository istituzionale dell'Università degli Studi di Firenze

### **Occurrence of diffuse, poorly differentiated hepatocellular carcinoma during pegylated interferon plus ribavirin combination therapy for**

Questa è la Versione finale referata (Post print/Accepted manuscript) della seguente pubblicazione:

*Original Citation:*

Occurrence of diffuse, poorly differentiated hepatocellular carcinoma during pegylated interferon plus ribavirin combination therapy for chronic hepatitis C / M. Capanni; E. Lorefice; M. C. Benini; M. R. Biagini; A. Tozzi; E. Salvadori; S. Colagrande; C. Surrenti; S. Milani. - In: JOURNAL OF CHEMOTHERAPY. - ISSN 1120-009X. - ELETTRONICO. - 20:(2008), pp. 380-384.

*Availability:*

The webpage <https://hdl.handle.net/2158/345191> of the repository was last updated on

*Terms of use:*

Open Access

La pubblicazione è resa disponibile sotto le norme e i termini della licenza di deposito, secondo quanto stabilito dalla Policy per l'accesso aperto dell'Università degli Studi di Firenze (<https://www.sba.unifi.it/upload/policy-oa-2016-1.pdf>)

*Publisher copyright claim:*

La data sopra indicata si riferisce all'ultimo aggiornamento della scheda del Repository FloRe - The above-mentioned date refers to the last update of the record in the Institutional Repository FloRe

(Article begins on next page)

---

**CASE REPORT**

---

**Occurrence of Diffuse, Poorly Differentiated Hepatocellular Carcinoma During Pegylated Interferon Plus Ribavirin Combination Therapy for Chronic Hepatitis C**

M. CAPANNI<sup>1</sup> - E. LOREFICE<sup>1</sup> - M.C. BENINI<sup>1</sup> - M.R. BIAGINI<sup>1</sup> - A. TOZZI<sup>1</sup>  
E. SALVADORI<sup>2</sup> - S. COLAGRANDE<sup>2</sup> - C. SURRENTI<sup>1</sup> - S. MILANI<sup>1</sup>

<sup>1</sup>Liver Center and Gastroenterology Unit, Department of Clinical Pathophysiology, University of Florence, Florence, Italy.

<sup>2</sup>Radiodiagnostic Section, Department of Clinical Pathophysiology, University of Florence, Florence, Italy.

*Corresponding author:* Dr. Marco Capanni, PhD, MD, Liver Center and Gastroenterology Unit, Department of Clinical Pathophysiology, University of Florence, Viale Pieraccini 6, 50139 Florence, Italy. Tel. +39 0554271411, Fax +39 0557946324, E-mail: marco\_cap@katamail.com

**Summary**

**Interferon therapy is indicated for the treatment of chronic hepatitis C and prevention of hepatocellular carcinoma. We describe the case of a 66-year-old Italian woman who received pegylated interferon  $\alpha$ -2a plus ribavirin combined therapy for HCV-related chronic liver disease. Preliminary hematochemical, ultrasound and biptic investigations did not show liver cirrhosis or hepatocarcinoma. After 24 weeks of treatment transaminase serum levels were in the normal range and circulating HCV-RNA was undetectable by PCR qualitative assay. On week 46 a serious adverse event occurred, with rapid transaminase increase, severe hyperpyrexia, and abdominal pain, leading to interruption of interferon and ribavirin. Liver biopsy was repeated and it revealed poorly differentiated hepatocellular carcinoma. Only palliative care could be performed and the patient died of liver failure within 2 months. The present case underlines that hepatocellular carcinoma can be misdiagnosed in spite of laboratory and instrumental follow-up. More sensitive tools are needed for tumor detection, to avoid IFN impairment of the liver, even though it eradicates HCV.**

**Key words:** Chronic hepatitis C, hepatocellular carcinoma, pegylated interferon  $\alpha$ -2a, ribavirin.

**INTRODUCTION**

Chronic infection by hepatitis C virus (HCV) is the most common cause of hepatocellular carcinoma (HCC) in many countries<sup>1-3</sup>. A large cohort study<sup>4</sup> carried out in Italy showed a significant presence of HCC among patients affected by viral hepatitis. Specifically, HCV-related liver cirrhosis accounts for about 4% risk per year of developing HCC<sup>5-6</sup>, and the tumor incidence in North America, Europe and Japan is increasing, mainly as a consequence of HCV diffusion during the previous decades<sup>1</sup>. Although the mechanisms by which the virus promotes hepatocarcinogenesis are not completely clear yet, interferon (IFN) therapy seems of benefit in preventing HCC, owing to

antimitogenic and antioxidative properties, both in sustained virological responders and in transient biochemical responders<sup>7-9</sup>. Since tumor diffusion significantly limits an effective removal of lesions<sup>4</sup>, procedures for disclosing primary nodules in cirrhotics have been carefully standardized by major scientific societies<sup>10</sup>. Nevertheless, early diagnosis of HCC is often arduous in clinical practice. Herein we present a recent case in which widespread HCC was unexpectedly latent until triggered during antiviral therapy for chronic hepatitis C, after escaping all preliminary investigations that the patient had undergone. A second element of interest is represented by the particular imaging features of HCC, which appeared in a diffuse, disseminated form with hypovascular pattern.

## CASE REPORT

A 66-year-old Italian woman was referred to our Department for chronic hepatitis C, virus genotype 1b, diagnosed in 1992. On the basis of anamnestic data, no history of blood transfusions, intravenous drug use or alcohol consumption was recorded, and duration of illness was unknown. Immunoserologic blood tests excluded coinfections by hepatitis B virus (namely HBs and HBe antigens, anti-HBs, anti-HBe, and anti-HBc antibodies were negative), and by human immunodeficiency virus. The patient showed good clinical state, with body mass index 18.9 Kg/m<sup>2</sup>, and was free of symptoms suggesting liver impairment. In November 2003 ultrasound-guided liver biopsy indicated moderate necroinflammatory activity, portal fibrosis and early periportal bridging fibrosis, namely A2 F2 chronic hepatitis, according to the Metavir scoring system<sup>11</sup>. Neither hepatocellular steatosis, nor iron storage were seen within the specimen, which measured 11 mm in length and contained 7 portal tracts. Serum alanine transaminase (ALT) and aspartate transaminase (AST) were 214 and 180 IU/L, respectively, and viral load was >500,000 IU/mL. Abdominal ultrasound disclosed unhomogeneously increased liver echotexture, without parenchymal nodules.

The patient fulfilled inclusion criteria for combination therapy with pegylated IFN (PEG-IFN) and ribavirin (RBV)<sup>12</sup>, and was scheduled to receive PEG-IFN  $\alpha$ -2a 180  $\mu$ g weekly s.c. and RBV 1,000 mg daily *per os* for 48 weeks.

After 24 weeks of therapy serum transaminases lowered to the level of within normal range (namely <40 IU/L), and circulating HCV-RNA was undetectable by Cobas Amplicor polymerase chain reaction (PCR) qualitative assessment (sensitivity: 100 IU/mL).

On week 46 the patient was hospitalized in our Department because of serious disease with continuous fever, persistent abdominal pain, rapid weight loss, and asthenia. HCV viral load was still below 100 IU/mL, but ALT and AST increased up to 441 and 1,321 IU/L, respectively, hence PEG-IFN plus RBV administration was withdrawn. Blood cultures, urinalysis, and autoantibodies resulted negative, alpha-fetoprotein serum level was in the normal range (namely <10 IU/mL), chest X-ray, abdominal X-ray, and upper digestive endoscopy investigations did not show pathologic findings. Abdominal ultrasonography and contrast-enhanced abdominal computed tomography (CT) scan identified unhomogeneous liver texture, with partial thrombosis of portal, suprahepatic and inferior caval veins, mild splenomegaly, and ascites. Laboratory tests excluded specific coagulation diseases, and anticoagulant heparin therapy did not provide significant improvement. Since anti-cytomegalovirus (CMV) IgM antibodies were positive, with blood CMV-DNA equivalent to 1,690 genomes/mL by nested PCR assay, we started specific antiviral treatment with the nucleoside analogue gancyclovir 5 mg/Kg b.i.d. i.v. for 3 weeks, till CMV clearance was accomplished. Nev-

ertheless the patient's condition did not improve.

Abdominal CT scan was performed again 2 months after the previous one and this time it revealed multicentric, infiltrative nodules of the liver, of various sizes, mostly smaller than 1 cm (Figure 1), hypo-attenuating in all phases of the examination with unchanged thrombosis in portal, suprahepatic and inferior caval veins (Figure 2). A further ultrasound-guided random liver biopsy collected a sample of 29 mm in length, leading to diagnosis of poorly differentiated HCC. Only palliative care was achievable and the patient died of liver failure within 2 months.

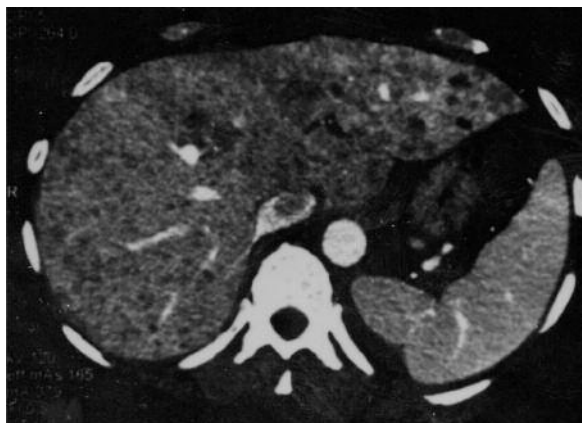

FIGURE 1 - Contrast-enhanced abdominal CT scan showing innumerable, hypo-attenuating various-sized focal lesions of the liver.

## DISCUSSION

Although IFN therapy for chronic hepatitis C, both with standard and pegylated drugs, is commonly thought to prevent or delay HCC<sup>5,7-9,13</sup>, in the present case severity of disease unexpectedly increased during treatment and concomitantly with viral clearance. On the grounds of its local diffuseness, the tumor was seemingly pre-existing, however neither laboratory tests nor ultrasound investigation had diagnosed it previously, and despite unhomogeneous liver echotexture with hypo- and hyperechoic scattered areas, nevertheless focal lesions were not identifiable. Alpha-fetoprotein serum level was normal, but this diagnostic tool has low sensitivity since only 60% of tumors actually produce enough of this marker to be detected<sup>14</sup>. On the other hand, the liver biopsy before treatment reported moderate fibrosis, without histological features of cirrhosis or nodular proliferation. The small sample obtained on that occasion could explain a serious underestimation of disease, since biopsies shorter than 15 mm in length are susceptible to over 35% risk of diagnostic inaccuracies<sup>15</sup>.

Cirrhosis and HCC are the ultimate stages of long-lasting hepatic damage by viruses or other injuries,

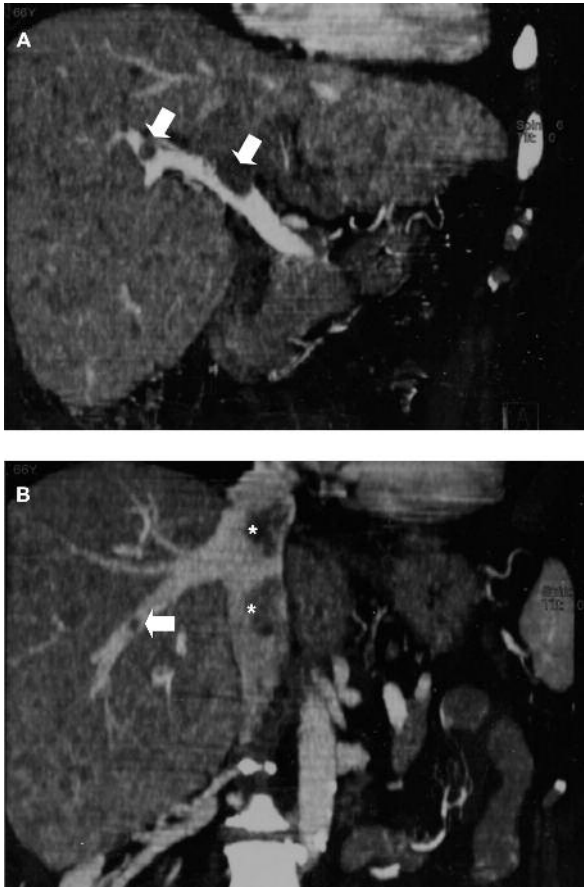


FIGURE 2 - Contrast enhanced abdominal CT scan images (coronal reconstruction). A) Various localizations of portal vein thrombosis (arrows). B) Thrombosis of the middle suprahepatic vein (arrow), and inferior caval vein (asterisks).

which induce progression of liver fibrosis and parenchymal disruption<sup>11,16</sup>. Although advanced hepatic alterations should be identified by imaging techniques, ultrasonography may lack specificity and sensitivity to discriminate diffuse parenchymal abnormalities in the absence of portal hypertension<sup>17</sup>, as in the first ultrasound examination of this case. Previously the patient felt rather well, without suffering from any symptoms till she was administered PEG-IFN and RBV. Liver impairment occurred only after portal thrombosis and ascites had occurred, but HCC remained misdiagnosed for a longer time, probably because of its anomalous appearance. Moreover, the active CMV infection acted as a confounding factor and concealed the actual cause of hepatic failure.

The latest abdominal CT scan showed multicentric nodules, heterogeneous in size, shape and attenuation pattern, prevalently hypo-attenuating in all phases of the examination. Such a pattern appeared not specific for liver malignancy, since even benign lesions can mimic the described pattern on CT, and similar find-

ings have been reported in multiple hepatic abscesses due to CMV infection after orthotopic liver transplantation<sup>18</sup>, or caused by various opportunistic pathogens in patients with acquired immunodeficiency syndrome<sup>19</sup>. Most premalignant lesions in chronic liver disease such as regenerative and dysplastic nodules are multiple and hypovascular<sup>20-21</sup>.

Several papers report primary tumors with different presenting symptoms in cirrhotic or even non-cirrhotic livers<sup>22-26</sup>. In the present case clinical discomfort, including fever and abdominal pain, could suggest not only HCC and portal thrombosis, but also viral or fungal superinfections, other than adverse events due to IFN intake<sup>12</sup>. Only a further liver biopsy accomplished the diagnosis of poorly differentiated HCC, which was consistent with neoplastic portal thrombosis.

A paper by Yamaura *et al.*<sup>27</sup> reviewed 24 cases, including one admitted to the authors' Hospital, of Japanese patients with HCC detected after IFN treatment and virological response. All patients, except one, were sustained virological responders, namely with non-detectable circulating HCV-RNA for at least 24 weeks after the end of treatment<sup>12</sup>. The HCC sizes at detection ranged from 10 to 90 mm, mean 30.6 mm. In order to exclude the possibility of microscopic HCC before IFN treatment, the authors discriminated between patients ( $n = 13$ ) with >2-year time interval, and patients ( $n = 11$ ) with <2-year time interval from antiviral therapy to tumor diagnosis<sup>27</sup>. However, the former group had larger HCC mean size (37.1 vs. 22.2 mm), with diameter >25 mm in 8/13, and previously covert neoplastic lesions cannot be excluded in everyone, since the tumor volume doubling time is likely to range from 90 to 204 days<sup>2</sup>.

The present case shows interesting peculiarities in comparison with other literature reports, because the tumor appeared just after disappearance of viral load, when IFN was still ongoing, in a patient who had not many risk factors for HCC, aside from HCV infection<sup>6</sup>. From the CT imaging, it should be emphasized that the given pattern is unusual, in particular for a widely disseminated and poorly differentiated HCC: most of these tumors can be detected on arterial phase as hyper-enhancing areas. It is well known that HCC nodules enhance in proportion to the degree of contrast agent uptake and the hepatic arterial supply. On the other hand the surrounding hepatic parenchyma is mainly supplied by the portal inflow (70-75%). When the arterial supply is not sufficient to enhance the nodule more than the surrounding parenchyma, the HCC will be less attenuating. Moderately or poorly differentiated HCCs are almost solely supplied by the hepatic artery, due to the disappearance of the portal tracts in the sclerotic derangement<sup>28-30</sup>. On the contrary, in some cases of moderately or well differentiated HCC, nodules will present as persistently less attenuating in all the various phases<sup>31</sup>. Such tumors are believed to have an arterial supply insufficient to improve the degree of the enhancement more than the surrounding parenchyma. Probably they possess the same degree

of hepatic artery and portal venous supply compared with the surrounding liver parenchyma.

The hepatocarcinogenesis in this case had almost certainly begun prior to antiviral treatment, and the possibility that subclinical tumor was present before IFN therapy is presumed under such circumstances<sup>2</sup>. Recently Kobayashi *et al.*<sup>32</sup> performed a retrospective study of 1,124 patients treated with IFN for HCV-related chronic hepatitis, reporting that HCC developed after virus clearance in 3.5% of sustained virological responders. Nonetheless, as regards the present case, in light of early HCC occurrence during antiviral therapy, the most likely hypothesis is that multiple neoplastic foci already existed and it was not possible to visualize them because of limitations of the instruments used. In this patient the development of HCC seems not to have been inhibited by IFN administration. On the other hand, HCV might retain its pro-oncogenic potential despite a complete block of its replication machinery. Recent studies indicate that the virus genome is able to trigger the host genes regulating cell proliferation and differentiation, along various pathways and signaling cascades<sup>33-35</sup>.

The present case exemplifies the contention that HCC in HCV-related chronic liver disease may be present even during or shortly after successful antiviral treatment. Therefore neoplastic degeneration should always be suspected when the patient's condition dramatically worsens, and imaging techniques show atypical features. Conventional screening modalities before PEG-IFN and RBV are susceptible to misdiagnosis, and patients run the risk of undergoing useless intake of poorly tolerated drugs. Novel tools are needed to enhance detection of HCC, and to avoid impairment of the liver by IFN therapy, even though the viral infection is removed.

## REFERENCES

- Heathcote EJ. Prevention of hepatitis C virus-related hepatocellular carcinoma. *Gastroenterology* 2004; 127 (5 Suppl 1): S294-S302.
- Kasahara A. Development of hepatocellular carcinoma after sustained response to interferon therapy: how long should sustained responders with risk factors be followed? *J Gastroenterol* 2005; 40 (2): 220-222.
- Oikawa T, Ojima H, Yamasaki S, *et al.* Multistep and multicentric development of hepatocellular carcinoma: histological analysis of 980 resected nodules. *J Hepatol* 2005; 42 (2): 225-229.
- Izzo F, Cremona F, Ruffolo F, *et al.* Detection of hepatocellular cancer during screening of 1125 patients with chronic hepatitis virus infection. *J Chemother* 1997; 9 (2): 151-152.
- Mazzella G, Accogli E, Sottili S, *et al.* Alpha interferon treatment may prevent hepatocellular carcinoma in HCV-related liver cirrhosis. *J Hepatol* 1996; 24 (2): 141-147.
- Fattovich G, Stroffolini T, Zagni I, Donato F. Hepatocellular carcinoma in cirrhosis: incidence and risk factors. *Gastroenterology* 2004; 127 (5 Suppl 1): S35-S50.
- Roffi L, Redaelli A, Colloredo G, *et al.* Outcome of liver disease in a large cohort of histologically proven chronic hepatitis C: influence of HCV genotype. *Eur J Gastroenterol Hepatol* 2001; 13 (5): 501-506.
- Hino K, Okita K. Interferon therapy as chemoprevention of hepatocarcinogenesis in patients with chronic hepatitis C. *J Antimicrob Chemother* 2004; 53 (1): 19-22.
- Imai Y, Kasahara A, Tanaka H, *et al.* Interferon therapy for aged patients with chronic hepatitis C: improved survival in patients exhibiting a biochemical response. *J Gastroenterol* 2004; 39 (11): 1069-1077.
- Bruix J, Sherman M, Llovet JM, *et al.* Clinical management of hepatocellular carcinoma. Conclusions of the Barcelona-2000 EASL conference. European Association for the Study of the Liver. *J Hepatol* 2001; 35 (3): 421-430.
- Poynard T, Bedossa P, Opolon P. Natural history of liver fibrosis progression in patients with chronic hepatitis C. The OBSVIRC, METAVIR, CLINIVIR, and DOSVIRC groups. *Lancet* 1997; 349 (9055): 825-832.
- Fried MW, Shiffman ML, Reddy KR, *et al.* Peginterferon alfa-2a plus ribavirin for chronic hepatitis C virus infection. *N Engl J Med* 2002; 347 (13): 975-982.
- Chuang WL, Yu ML, Dai CY, Chang WY. Treatment of chronic hepatitis C in southern Taiwan. *Intervirology* 2006; 49 (1-2): 99-106.
- Sitzmann JV. Hope for a cure through earlier detection of hepatocellular cancer. *Ann Surg Oncol* 1999; 6 (2): 133-134.
- Bedossa P, Dargere D, Paradis V. Sampling variability of liver fibrosis in chronic hepatitis C. *Hepatology* 2003; 38 (6): 1449-1457.
- Kamel IR, Bluemke DA. Imaging evaluation of hepatocellular carcinoma. *J Vasc Interv Radiol* 2002; 13 (9 Pt 2): S173-S184.
- Simonovsky V. The diagnosis of cirrhosis by high resolution ultrasound of the liver surface. *Br J Radiol* 1999; 72 (853): 29-34.
- MacDonald GA, Greenson JK, DelBuono EA, *et al.* Minimicroabscess syndrome in liver transplant recipients. *Hepatology* 1997; 26 (1): 192-197.
- Alvarez OA, Vanegas F, Maze GL, *et al.* Polymicrobial cholangitis and liver abscess in a patient with the acquired immunodeficiency syndrome. *South Med J* 2000; 93 (2): 232-234.
- Takayasu K, Furukawa H, Wakao F, *et al.* CT diagnosis of early hepatocellular carcinoma: sensitivity, findings, and CT-pathologic correlation. *AJR Am J Roentgenol* 1995; 164 (4): 885-890.
- Choi BI, Han JK, Hong SH, *et al.* Dysplastic nodules of the liver: imaging findings. *Abdom Imaging* 1999; 24 (3): 250-257.
- Okuda K, Kondo Y, Nakano M, *et al.* Hepatocellular carcinoma presenting with pyrexia and leukocytosis: report of five cases. *Hepatology* 1991; 13 (4): 695-700.
- Huang GT, Sheu JC, Lee HS, *et al.* Icteric type hepatocellular carcinoma: revisited 20 years later. *J Gastroenterol* 1998; 33 (1): 53-56.
- Dereure O, Guilhou JJ. Multifocal hepatocellular carcinoma presenting as prurigo: two cases. *Br J Dermatol* 2000; 143 (6): 1331-1332.
- Luo JC, Hwang SJ, Wu JC, *et al.* Clinical characteristics and prognosis of hepatocellular carcinoma patients with paraneoplastic syndromes. *Hepatogastroenterology* 2002; 49 (47): 1315-1319.
- Kishino T, Mori H, Nishikawa K, *et al.* Hepatocellular carcinoma containing sarcomatous lesions in a normal liver, accompanied by secondary Budd-Chiari syndrome. *J Clin Gastroenterol* 2004; 38 (3): 296-297.
- Yamaura T, Matsumoto A, Rokuhara A, *et al.* Development of small hepatocellular carcinoma in a patient with chronic hepatitis C after 77 months of a sustained and complete response to interferon therapy. *J Gastroenterol Hepatol* 2002; 17 (11): 1229-1235.
- Ueda K, Terada T, Nakanuma Y, Matsui O. Vascular supply in adenomatous hyperplasia of the liver and hepatocellular

carcinoma: a morphometric study. *Hum Pathol* 1992; 23 (6): 619-626.

<sup>29</sup>Hayashi M, Matsui O, Ueda K, *et al.* Correlation between the blood supply and grade of malignancy of hepatocellular nodules associated with liver cirrhosis: evaluation by CT during intraarterial injection of contrast medium. *AJR Am J Roentgenol* 1999; 172 (4): 969-976.

<sup>30</sup>Honda H, Tajima T, Kajiyama K, *et al.* Vascular changes in hepatocellular carcinoma: correlation of radiologic and pathologic findings. *AJR Am J Roentgenol* 1999; 173 (5): 1213-1217.

<sup>31</sup>Hwang GJ, Kim MJ, Yoo HS, Lee JT. Nodular hepatocellular carcinomas: detection with arterial-, portal-, and delayed-phase images at spiral CT. *Radiology* 1997; 202 (2): 383-388.

<sup>32</sup>Kobayashi S, Takeda T, Enomoto M, *et al.* Development of hepatocellular carcinoma in patients with chronic hepatitis C who had a sustained virological response to interferon therapy:

a multicenter, retrospective cohort study of 1124 patients. *Liver Int* 2007; 27 (2): 186-191.

<sup>33</sup>Erhardt A, Hassan M, Heintges T, Haussinger D. Hepatitis C virus core protein induces cell proliferation and activates ERK, JNK, and p38 MAP kinases together with the MAP kinase phosphatase MKP-1 in a HepG2 Tet-Off cell line. *Virology* 2002; 292 (2): 272-284.

<sup>34</sup>Koskinas J, Petraki K, Kavantzis N, *et al.* Hepatic expression of the proliferative marker Ki-67 and p53 protein in HBV or HCV cirrhosis in relation to dysplastic liver cell changes and hepatocellular carcinoma. *J Viral Hepat* 2005; 12 (6): 635-641.

<sup>35</sup>Deng L, Nagano-Fujii M, Tanaka M, *et al.* NS3 protein of hepatitis C virus associates with the tumour suppressor p53 and inhibits its function in an NS3 sequence-dependent manner. *J Gen Virol* 2006; 87 (Pt 6): 1703-1713.