



UNIVERSITÀ
DEGLI STUDI
FIRENZE

FLORE

Repository istituzionale dell'Università degli Studi di Firenze

Expression of cyclo-oxygenase-2 in macrophages associated with cutaneous melanoma at different stages of progression

Questa è la Versione finale referata (Post print/Accepted manuscript) della seguente pubblicazione:

Original Citation:

Expression of cyclo-oxygenase-2 in macrophages associated with cutaneous melanoma at different stages of progression / Bianchini, Francesca; Massi, Daniela; Marconi, C.; Franchi, Alessandro; Baroni, G.; Santucci, Marco; Mugnai, G.; Calorini, Lido. - In: PROSTAGLANDINS & OTHER LIPID MEDIATORS. - ISSN 1098-8823. - ELETTRONICO. - 83:(2007), pp. 320-328. [10.1016/j.prostaglandins.2007.03.003]

Availability:

This version is available at: 2158/351187 since: 2020-10-23T12:57:48Z

Published version:

DOI: 10.1016/j.prostaglandins.2007.03.003

Terms of use:

Open Access

La pubblicazione è resa disponibile sotto le norme e i termini della licenza di deposito, secondo quanto stabilito dalla Policy per l'accesso aperto dell'Università degli Studi di Firenze (<https://www.sba.unifi.it/upload/policy-oa-2016-1.pdf>)

Publisher copyright claim:

(Article begins on next page)

Expression of cyclo-oxygenase-2 in macrophages associated with cutaneous melanoma at different stages of progression

Francesca Bianchini^a, Daniela Massi^b, Chiara Marconi^a, Alessandro Franchi^b,
Gianna Baroni^b, Marco Santucci^b, Antonella Mannini^a,
Gabriele Mugnai^a, Lido Calorini^{a,*}

^a Department of Experimental Pathology and Oncology, University of Florence, Viale G.B. Morgagni 50, I-50134 Florence, Italy

^b Department of Human Pathology and Oncology, University of Florence, Florence, Italy

Received 5 January 2007; received in revised form 2 March 2007; accepted 7 March 2007

Available online 13 March 2007

Abstract

The biological significance of the almost constant presence of macrophages in the tumoral microenvironment is an issue debated by several authors. The major difficulty in understanding the role played by tumor-associated macrophages (TAMs) in tumor progression is due to the contrasting effects of TAMs found in different studies. In addition, there is a limited information on which of the many biological activities expressed by TAMs are critical in inducing stimulatory or inhibitory effect on tumor growth.

The aim of our study was: (a) to explore to what extent cyclo-oxygenase-2 (COX-2) in TAMs associated with human melanoma is expressed at different stages of tumor progression; and (b) to explore whether COX-2 expression in TAMs is stimulated by melanoma cells. In order to answer this question, we determined COX-2 positive TAMs associated with cutaneous melanocytic nevi, *in situ*, invasive and metastatic melanoma. In addition, we investigated whether COX-2 is expressed in peritoneal thioglycollate-elicited macrophages after co-cultivation with murine B16 melanoma cells. We found that COX-2-positive TAMs, as revealed by immunohistochemical analysis, were rare in common nevi and “dysplastic nevi”, but present in a high percentage in *in situ* and thin melanoma. COX-2-positive TAMs were also found in more advanced tumors and metastatic melanoma, although at a significantly lower percentage in these latter. The *in vitro* protocol revealed that COX-2 was expressed in peritoneal macrophages upon contact with B16 murine melanoma cells, but not with normal murine fibroblasts. On the whole, the results of *in vivo* and *in vitro* studies suggest that COX-2 expressed in TAMs appears to act as an effective biomarker of melanoma progression, and melanoma cells themselves might stimulate COX-2 in macrophages.

© 2007 Elsevier Inc. All rights reserved.

Keywords: Cyclo-oxygenase-2 (COX-2); Tumor-associated macrophages (TAMs); Human melanomas; Immunohistochemical analysis; F10-M3 murine melanoma cells; Thioglycollate-elicited murine macrophages

1. Introduction

Tumor associated macrophages (TAMs), besides their well-documented tumoricidal activity [1,2], may promote tumor cell invasiveness and metastatic diffusion under certain conditions [3–6]. These contrasting effects might be

* Corresponding author. Tel.: +39 055 4598207; fax: +39 055 4598900.
E-mail address: lido.calorini@unifi.it (L. Calorini).

explained on the basis of the different functions expressed by TAMs under the influence of signals generated by host inflammatory cells as well as tumor cells themselves [7–9]. Among the various inflammatory mediators generated by TAMs, a particular attention has been devoted to arachidonic acid metabolites, which are known to influence several biological responses, involved in tumor progression [10], such as inflammatory and immune reactions, haemostasis and angiogenesis [11]. COX-2, an inducible isoform of COX particularly expressed in various types of tumors [12–16], largely contributes to the generation of tumoral arachidonic acid metabolites. This finding opened the way to investigating whether COX-2 might represent a target for inhibiting tumor growth by the use of appropriate inhibitors of COX-2. Indeed, the incidence of human colorectal carcinoma [12,17–20], as well as the number and size of polyps in Apc delta716 knockout mice [21] were reduced by treatment with aspirin, a typical inhibitor of COX. In spite of the finding that COX-2 may be expressed in macrophages, it has not been yet clarified to what extent TAMs contribute to the high level of COX-2 found in tumors, and, in particular, in malignant melanoma.

In this study, we determined COX-2-positive TAMs associated with human melanoma at different stages of progression. Our experimental material consisted in: 5 cutaneous melanocytic nevi (2 benign common acquired nevi and 3 so-called atypical, “dysplastic nevi”); 4 *in situ* melanoma; 11 invasive cutaneous melanoma representative of different pT categories; and 7 metastatic melanoma (5 dermal/subcutaneous metastases, 1 lymph nodal and 1 lung metastases) (from the archive of the Department of Human Pathology and Oncology, University of Florence). Histopathological slides were reviewed for the presence of ulceration, histotype, Breslow thickness and Clark’s level.

We, also, investigated whether melanoma cells promoted the expression of COX-2 in macrophages by using an *in vitro* experimental model, represented by co-cultures of B16 murine melanoma cells and thioglycollate-elicited macrophages collected from the peritoneal cavities of syngeneic mice.

2. Materials and methods

2.1. Immunohistochemical analysis

Immunohistochemistry was carried out on 4 μ m-thick paraffin sections. All sections were deparaffined in Bio-Clear (Bio-Optica, Mi, Italy) and hydrated with grade ethanol concentrations and water. To block endogenous peroxidase activity, slides were treated with 3.0% hydrogen peroxidase in distilled water for 10 min. Antigen retrieval was routinely performed by microwave pretreatment (Microwave MicroMED T/T Mega, Milestone, Bg, Italy) in TEC (Tris–EDTA–citrate buffer pH 8) for 30 min. After blocking non-specific antigen with normal horse serum (UltraVision, Lab-Vision, Fremont, CA), serial sections from all specimens were analyzed with monoclonal antibody against CD68 (clone PGM-1, Dako) and a monoclonal antibody against COX-2 (clone COX-229, Zymed, San Francisco, CA). The primary antibody was used at a dilution 1:50 at room temperature for 1 h, followed by incubation with peroxidase conjugated polymer (Chemmate Dako Envision Detection Kit rabbit-mouse) for 30 min. The reaction products were visualized with 3-amino-9-ethylcarbazole (AEC, Lab-Vision) for 10 min. The nuclei were counterstained with Mayer’s haematoxylin. For negative control, a slide was prepared from the same tissue block and a pre-immune serum was used instead of the primary antibody. As positive control we used an intestinal adenocarcinoma specimen. The control sections were treated in parallel with the samples in the same run.

COX-2 immunostaining in the cytoplasm of tumor cells was independently reviewed by two observers and semi-quantitatively scored as – negative, + focal, ++ moderate, and +++ diffuse, as previously described [22]. The number of CD68 positive cells and COX-2 positive TAMs was recorded by careful evaluation of serial sections from each specimen (microscopic field at 400 \times magnification). The percentage of COX-2 positive CD68 cells was also determined.

2.2. Cells and culture conditions

In the present study, we used a clone isolated from murine B16-F10 melanoma cells (F10-M3 cells) [23] and primary cultures of murine skin fibroblasts isolated in our laboratory from C57Bl/6 mice. Cells were cultivated in Dulbecco’s Modified Eagle Medium (DMEM 4500) supplemented with 10% fetal calf serum (FCS), at 37 °C in a 10% CO₂ humidified atmosphere. Cells were propagated using a solution of trypsin–EDTA.

2.3. Co-cultures of macrophages with tumor cells or normal fibroblasts

Macrophage cultures were established from peritoneal exudates collected from 6 to 8 week old C57Bl/6 mice, that had been injected intraperitoneally with 1 ml of 3% thioglycollate broth (SIGMA) 3–4 days before, as previously described [24]. Co-cultures were prepared by seeding tumor cells or normal skin fibroblasts on macrophage monolayers at 1:1 ratio and at the density of 250×10^3 cells/cm². Co-cultures were washed with PBS and then incubated for 24 h in a medium containing 250 µg/ml bovine serum albumin (BSA), at 37 °C in a 10% CO₂ humidified atmosphere. In some experiments, co-cultures were grown in a medium supplemented with murine recombinant IFN γ (25 U/ml) (Peprotech) and LPS (10 ng/ml) (SIGMA), two classical agents of macrophage activation [25].

2.4. RNA isolation and polymerase chain reaction (PCR)

Total RNA was extracted from macrophages freed from tumor cells, tumor cells and fibroblasts using RNA total isolation system (Promega), and the amount and purity of the RNA was determined spectrophotometrically. Complementary cDNA was synthesized from 1 µg of total RNA using 4 U/µl of M-MLV reverse transcriptase (Promega). Aliquots of 5 µl of the cDNA were used for PCR amplification. The specific primers used for identification of β_2 -microglobulin and murine COX-2 were: β_2 -microglobulin (sense tgc-tat-cca-gaa-aac-ccc-tc; antisense gtc-atg-ctt-aac-tct-gca-gg) [26], and COX-2 (AAC TCC CAT GGG TGT GAA GGG; antisense CCA AAG ATA GCA TCT GGA CGA G) [27]. All PCR reactions were conducted using 0.1 U/µl of Go-Taq polymerase (Promega) and carried out on a Perkin Elmer thermal cycler. Ten microliters of each PCR products were visualized by electrophoresis in a 2% agarose gel, containing 0.5 mg/ml of ethidium bromide. cDNA products were evaluated on the basis of a standard PCR marker (Promega).

2.5. Western blotting analysis

Cells were washed twice with ice cold PBS containing 1 mM Na₄VO₃. Cells were lysed in 100 µl of cell lysis buffer containing 20 mM Tris/HCl (pH 7.4), 150 mM NaCl, 100 mM HEPES, 1% Triton-X100, 10 mM glycerophosphate, 100 mM PMSF, 100 µM AEBSF, 5 mM bestain, 2 mM leupeptin, 1 mM pepstatin, 80 µM aprotinin, 1.5 mM E-64. Aliquots of supernatants containing equal amounts of protein (65 µg) in Laemmli buffer were separated on 10% (v/v, SDS/PAGE gel). Transfer of fractionated proteins from the gel to a PVDF nitrocellulose membrane was carried out using an electroblotting apparatus (Bio-Rad). Blots were blocked with 2.5% (w/v) bovine serum albumin (BSA) in T-PBS (0.1%, v/v, Tween-20 in PBS) for 1 h at room temperature. Subsequently, membrane was probed at 4 °C overnight with COX-2 rabbit anti mouse monoclonal antibody (BIOMOL) diluted 1:1000 with 2.5% (w/v) BSA in T-PBS. After washing in T-PBS buffer, the membrane was incubated, for 1 h at room temperature, with horseradish peroxidase-conjugated anti-rabbit IgG antibody (SIGMA), diluted 1:16,000 with 2.5% (w/v) BSA in T-PBS. Immunoreactive bands were visualized by the ECL detection system (Amersham, USA).

2.6. Statistical analysis

The relationship between COX-2 expression and clinico-pathological variables was assayed by the two-tailed Fisher's exact test or by the two-tailed Pearson's Chi-squared method. A $p < 0.05$ was considered statistically significant.

3. Results

3.1. In vivo investigation

COX-2 immunoreactivity was focally detected in adnexal structures, such as hair follicles and eccrine glands, but absent in normal epidermis adjacent to either nevi or melanoma lesions. COX-2 was absent in melanocytes of benign common nevi and "dysplastic nevi", but expressed by melanoma cells of primary and metastatic lesions. Immunoreactivity of melanoma cells for COX-2 did not correlate with thickness or any other clinico-pathological variables of the lesions. As reported in Table 1 and shown in Fig. 1, a small percentage of TAMs (CD-68 positive cells) expressed COX-2 in common nevi and "dysplastic nevi", while high percentages of COX-2 positive TAMs were detected in *in situ*, thin melanoma and advanced tumors. However, COX-2 positive TAMs were more represented in

Table 1
Immunohistochemical analysis of COX-2 expression in melanoma at different stages of progression

Case no.	Age/sex	Site	Diagnosis ^a	Histotype ^b	Thickness (mm)/level	Ulceration	COX-2+ tumor cells ^c	CD68+ cells ^d	COX-2+ TAMs ^d	COX-2+ / CD68+ cells in percent ^e
1	28/f	Neck	CN				–	31.8	2	6.2
2	41/f	Neck	CN				–	28.4	0	0
3	34/m	Trunk	DN				–	49	1	2.0
4	46/f	Abdomen	DN				–	66.4	18.8	28.3
5	35/f	Back	DN				–	48.6	1.2	2.4
6	84/m	Back	MIS	SSM	–/I		+	51	40.3	79.0
7	68/m	Trunk	MIS	SSM	–/I		–	22.4	12	53.5
8	54/f	Shoulder	MIS	SSM	–/I		–	28	20.7	73.9
9	63/f	Neck	MIS	SSM	–/I		+	23.2	18.8	81.0
10	74/m	Back	MM	SSM	0.70/III	Absent	+	56	38	67.8
11	46/m	Trunk	MM	SSM	0.60/III	Absent	–	84.6	62.2	61.2
12	60/m	Shoulder	MM	SSM	0.20/II	Absent	+	77	50	64.9
13	30/f	Shoulder	MM	SSM	0.65/III	Absent	++	87	75	57.7
14	62/f	Arm	MM	SSMn	1.30/IV	Absent	–	60.6	0	0
15	72/m	Back	MM	SSM	1.10/IV	Absent	+	66.4	0	0
16	57/f	Back	MM	SSM	1.20/IV	Absent	++	61.6	40	64.9
17	79/f	Arm	MM	SSM	1.90/IV	Present	+	83.6	25	29.9
18	54/m	Temporal	MM	SSM	3.80/IV	Present	++	90.2	61.8	68.5
19	68/m	Foot	MM	NM	5.00/IV	Absent	++	50	4	8
20	71/m	Face	MM	SSM	3.50/IV	Present	++	69	42.3	61.3
21	57/m	Arm	Met				–	18	0	0
22	89/f	Leg	Met				+++	39	3.2	8.2
23	75/f	Leg	Met				–	17.4	0	0
24	82/m	Trunk	Met				–	25	0	0
25	71/m	Leg	Met				+++	20.3	0	0
26	55/f	Lymph node	Met				++	96	0	0
27	66/m	Lung	Met				+++	82	0	0

^a CN: common acquired nevus; DN: dysplastic nevus; MIS: *in situ* melanoma; MM: primary malignant melanoma; Met: melanoma metastasis.

^b SSM: superficial spreading melanoma; SSMn: superficial spreading melanoma arising on a nevus; NM: nodular melanoma.

^c Staining: +++ diffuse; ++ moderate; + focal; – negative expression.

^d CD68+ cells and COX-2+ TAMs are mean of number of positive cells found in 5 areas (microscopic field: 0.16 mm², at 400× magnification) of each specimen.

^e COX-2+ CD68 cells are expressed as percentage of COX-2+ TAMs / CD68 cells.

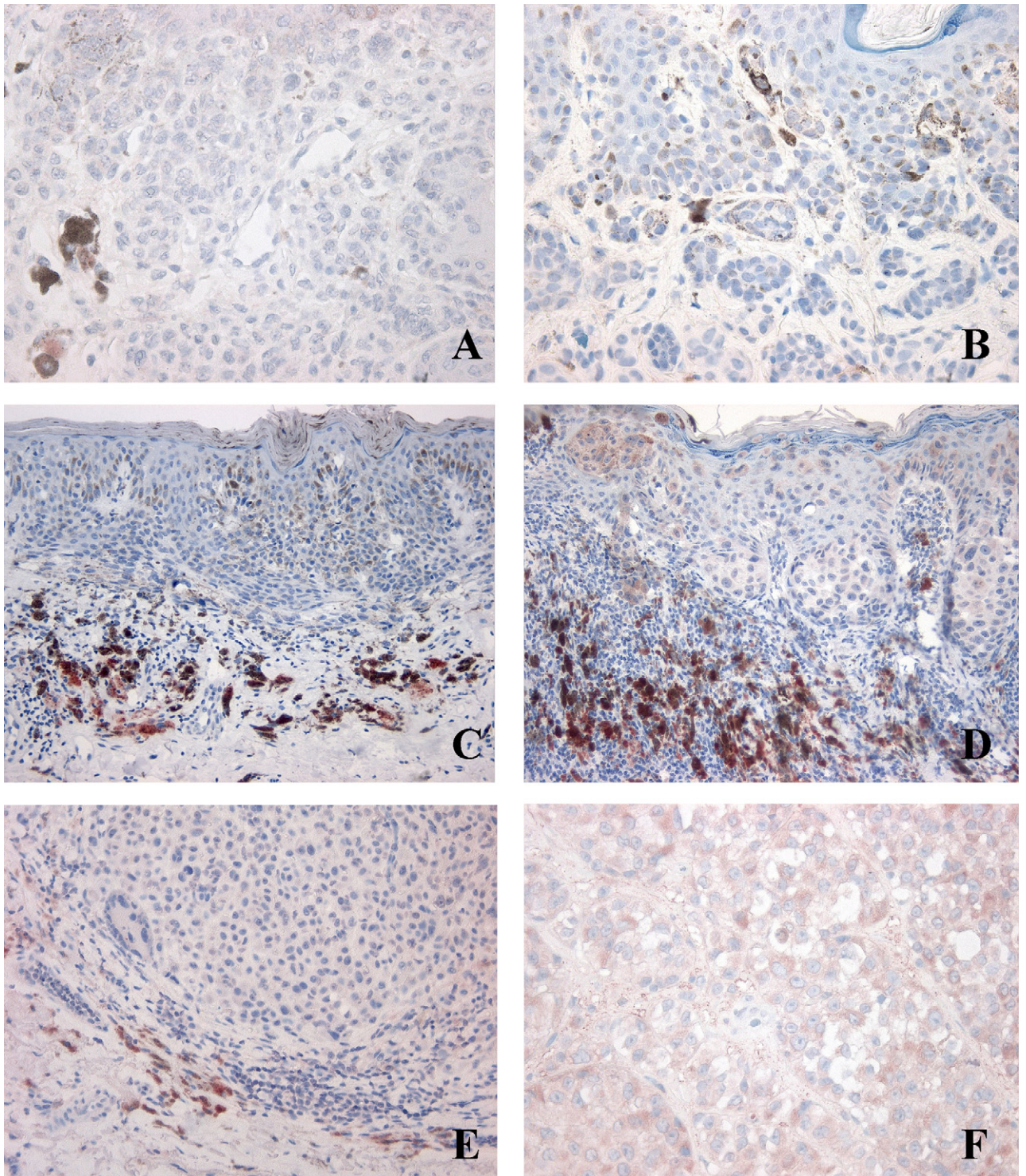


Fig. 1. Immunohistochemical analysis of COX-2 expression in human melanoma cells and in TAMs in a representative common nevus (A), dysplastic nevus (B), *in situ* melanoma (level I) (C), thin melanoma (levels II and III) (D), advanced melanoma (level IV) (E) and metastatic melanoma (F).

in situ and thin melanoma (radial growth phase of melanoma, levels I–III) than in advanced tumors (vertical growth phase of melanoma, level IV) and metastatic melanoma (relation significantly different at $p = 0.001$). COX-2 positive TAMs were found to be preferentially distributed at the periphery of tumors, rather than in the context of the tumoral mass. Moreover, in lesions containing the highest number of COX-2 positive TAMs, these latter were found to cluster at the advancing edge of the tumor.

3.2. *In vitro* investigation

As shown in Fig. 2 (panels A and B), mouse thioglycollate-elicited macrophages expressed mRNA and protein for COX-2 after stimulation with IFN γ /LPS. mRNA and protein for COX-2 were also expressed in elicited macrophages co-cultivated with F10-M3 murine melanoma cells. This effect was still more evident in elicited macrophages co-cultivated with F10-M3 melanoma cells in the presence of IFN γ /LPS. mRNA and protein for COX-2 were not expressed in F10-

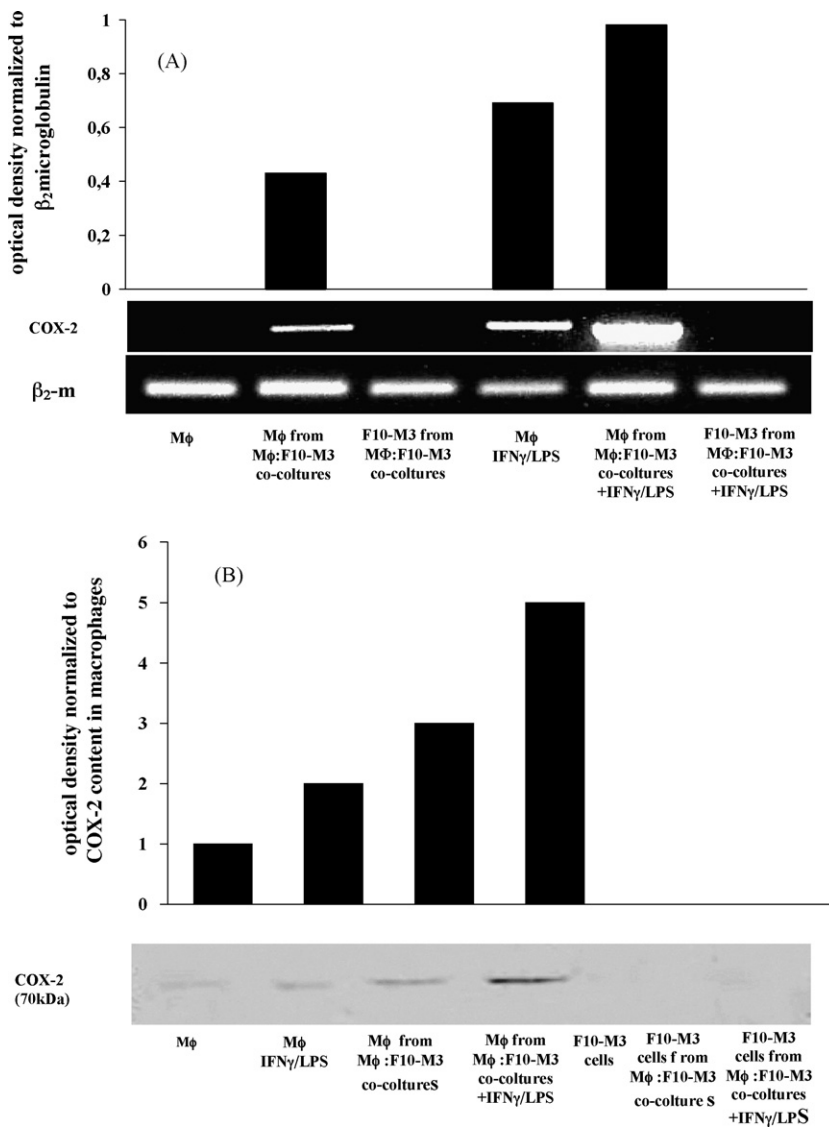


Fig. 2. Change in mRNA (panel A) and protein (panel B) for COX-2 in thioglycollate-elicited macrophages (M ϕ) co-cultivated with F10-M3 murine melanoma cells, in the presence or in the absence of IFN γ /LPS.

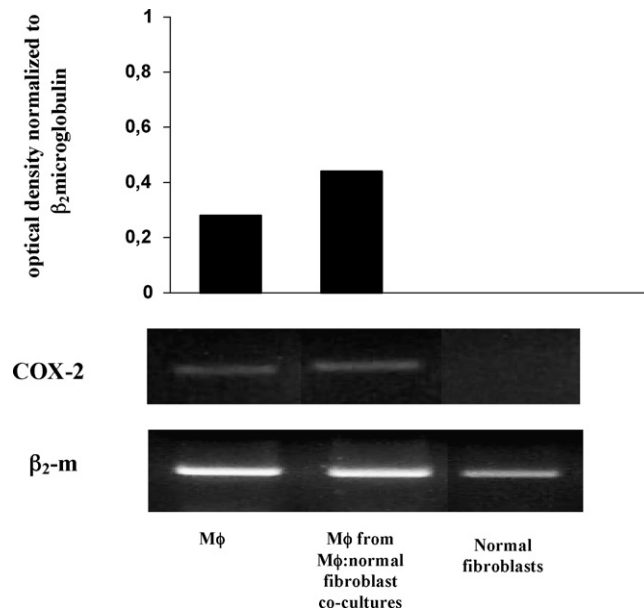


Fig. 3. Expression of mRNA for COX-2 in thioglycollate-elicited macrophages (M ϕ) co-cultivated with normal murine fibroblasts.

M3 cell cultures as well as in tumor cells removed from the co-cultures (Fig. 1, panels A and B). As shown in Fig. 3, macrophages did not express COX-2 when they were co-cultivated with normal murine fibroblasts, indicating that COX-2 promoting activity of melanoma cells is rather specific. Moreover, COX-2 was not expressed by macrophages co-cultivated with tumor cells in transwell chambers as well as by macrophages grown in tumor cell-conditioned media (data not shown). This finding rules out the possibility that soluble factors play a role in COX-2 expression by macrophages co-cultivated with tumor cells.

4. Discussion

Our study revealed that *in situ* and thin melanoma contained a particular high percentage of COX-2-positive TAMs, which declined in advanced and metastatic melanoma. COX-2-positive TAMs were preferentially located at the invasive front of the tumor, an observation, also, reported for TAMs associated with colon carcinoma [28]. Our study, also, showed that COX-2 expression in melanoma cells at a different stage of progression was not different. This finding is consistent with a recent publication by Denkert et al. (2001) [22]. Moreover, *in vitro* experiments demonstrated that murine inflammatory macrophages expressed COX-2 (mRNA and protein) upon contact with syngeneic F10-M3 murine melanoma cells. The specificity of this phenomenon is demonstrated by the finding that COX-2 was not expressed in macrophages co-cultivated with normal murine fibroblasts.

In conclusion, our data suggest that COX-2 expressed in TAMs, and not in tumor cells, appears to act as an effective biomarker of melanoma progression, and melanoma cells themselves might stimulate COX-2 in macrophages. The biological relevance of this phenomenon is indicated by the particular high concentration of COX-2-positive TAMs at the advancing edge of the early melanoma lesions, where remarkable interactions between macrophages and tumor cells are possible [29]. However, it is difficult to identify the precise effect of the accumulation of COX-2-expressing TAMs *in situ* and thin melanoma. It is possible, that the high number of COX-2 positive TAMs might account for the COX-2 over-expression that was reported in pre-malignant lesions, such as Barrett's esophagus, oral leukoplakia, gastric and cervical dysplasia [30], and colorectal polyps [31]. Moreover, an involvement of COX-2 in malignant transformation is sustained by the finding that COX-2 inhibitors prevent the development of mammary tumors in rat treated with 7,12-dimethylbenz(a)anthracene [32], and reduce the occurrence of colorectal adenomas in patients with familial adenomatous polyposis [33–35]. PGE₂, the main product of COX-2, is the more probable candidate in promoting malignant properties associated with COX-2 expression. In fact, PGE₂ was found to suppress proliferation of T and B lymphocytes and activity of Natural Killer cells [36,37], which are essential for host defence against

tumor progression. Therefore, COX-2 expressed in TAMs may provide an attractive therapeutic target for prevention or treatment of melanoma.

Acknowledgements

This study was funded by grants from MURST 40% – Cofin 2004, Progetto di Ricerca di Ateneo Quota ex-60%, Ente Cassa di Risparmio di Firenze (ECRF). The authors thank Prof. S. Ruggieri for his useful criticism during the preparation of this manuscript.

References

- [1] Fidler IJ, Schroit AJ. Recognition and destruction of neoplastic cells by activated macrophages: discrimination of altered self. *Biochim Biophys Acta* 1988;948:151–73.
- [2] Whitworth PW, Pak CC, Esagro J, et al. Macrophages and cancer. *Cancer Metastasis Rev* 1990;8:319–51.
- [3] Elgert KD, Alleve DG, Mullins DW. Tumor-induced immune dysfunction: the macrophage connection. *J Leukoc Biol* 1998;64:275–90.
- [4] Hsu MY, Meier F, Herlyn M. Melanoma development and progression: a conspiracy between tumor and host. *Differentiation* 2002;70:522–36.
- [5] Pollard JW. Tumour-educated macrophages promote tumour progression and metastasis. *Nat Rev Cancer* 2004;4:71–8.
- [6] Sica A, Schioppa T, Mantovani A, Allavena P. Tumour-associated macrophages are a distinct M2 polarised population promoting tumour progression: potential targets of anti-cancer therapy. *Eur J Cancer* 2006;42:717–27.
- [7] Crowther M, Brown NJ, Bishop ET, Lewis CE. Microenvironmental influence on macrophage regulation of angiogenesis in wounds and malignant tumors. *J Leukoc Biol* 2001;70:478–90.
- [8] Stout RD, Jiang C, Matta B, et al. Macrophages sequentially change their functional phenotype in response to changes in microenvironmental influences. *J Immunol* 2005;175:342–9.
- [9] Lewis CE, Pollard JW. Distinct role of macrophages in different tumor microenvironments. *Cancer Res* 2006;66:605–12.
- [10] Fidler IJ. The pathogenesis of cancer metastasis: the “seed and soil” hypothesis revisited. *Nat Rev* 2003;3:1–6.
- [11] Funk CD. Prostaglandin and leukotrienes: advances in eicosanoid biology. *Science* 2001;294:1871–4.
- [12] Fosslien E. Molecular pathology of cyclooxygenase-2 in neoplasia. *Ann Clin Lab Sci* 2000;30:3–21.
- [13] Tucker ON, Dannenberg OJ, Yang EK, et al. Cyclooxygenase-2 expression is upregulated in human pancreatic cancer. *Cancer Res* 1999;59:987–90.
- [14] Wolff H, Saukkonen K, Anttila S, et al. Expression of cyclooxygenase-2 in human lung carcinoma. *Cancer Res* 1998;58:4997–5001.
- [15] Chan G, Boyle JO, Yang EK, et al. Cyclooxygenase-2 expression is upregulated in squamous cell carcinoma of the head and neck. *Cancer Res* 1999;59:991–4.
- [16] Denkert C, Weichert W, Pest E, et al. Overexpression of the embryonic-lethal abnormal vision-like protein HuR in ovarian carcinoma is a prognostic factor and is associated with increased cyclooxygenase 2 expression. *Cancer Res* 2004;64:189–95.
- [17] Thun MJ, Namboodiri MM, Heath Jr CW. Aspirin use and reduced risk of fatal colon cancer. *N Engl J Med* 1991;325:1593–6.
- [18] Schreinemachers DM, Everson RB. Aspirin use and lung, colon and breast cancer incidence in a prospective study. *Epidemiology* 1994;5:138–46.
- [19] Taketo MM. Cyclooxygenase inhibitors in tumorigenesis (Part I). *J Natl Cancer Inst* 1998;90:1529–36.
- [20] Taketo MM. Cyclooxygenase inhibitors in tumorigenesis (Part II). *J Natl Cancer Inst* 1998;90:1609–15.
- [21] Oshima M, Dinchuk JE, Kargman SL, et al. Suppression of intestinal polyposis in APC Δ 716 knockout mice by inhibition of prostaglandin endoperoxide synthase-2 (COX-2). *Cell* 1996;87:803–9.
- [22] Denkert C, Kobel M, Berger S, et al. Expression of cyclooxygenase 2 in human malignant melanoma. *Cancer Res* 2001;61:303–8.
- [23] Gattoni-Celli S, Calorini L, Simile MM, Ferrone S. Modulation by MHC class I antigens of the biology of melanoma cells. Non-immunological mechanisms. *Melanoma Res* 1993;3:285–9.
- [24] Ceconi O, Calorini L, Mannini A, et al. Enhancement of lung-colonizing potential of murine tumor cell lines co-cultivated with activated macrophages. *Clin Exp Metastasis* 1997;15:94–101.
- [25] Gordon S. Alternative activation of macrophages. *Nat Rev* 2003;3:23–35.
- [26] Orlic D, Anderson S, Biesecker LG, et al. Pluripotent hematopoietic stem cells contain high levels of mRNA for c-kit, GATA-2, p45 NF-E2, and c-myb and low levels or no mRNA for c-fms and the receptors for granulocyte colony-stimulating factor and interleukins 5 and 7. *Proc Natl Acad Sci U S A* 1995;92:4601–5.
- [27] Pouliot M, Clish CB, Petasis NA, et al. Lipoxin A(4) analogues inhibit leukocyte recruitment to *Porphyromonas gingivalis*: a role for cyclooxygenase-2 and lipoxins in periodontal disease. *Biochemistry* 2000;25:4761–8.
- [28] Bamba H, Ota S, Kato A, et al. High expression of cyclooxygenase-2 in macrophages of human colonic adenoma. *Int J Cancer* 1999;83:470–5.
- [29] Condeelis J, Segall JE. Intravital imaging of cell movement. *Nat Rev Cancer* 2003;3:921–30.
- [30] Blanke CD, Masferrer JL. Chemotherapy with Cyclooxygenase-2 inhibitors in the treatment of malignant disease: pre-clinical rationale and preliminary results of clinical trials. In: Dannenberg AJ, DuBois RN (editors) *Prog Exp Tum Res*, Kurger, Basel, 2003. vol. 37, pp. 243–260.
- [31] Eberhart CE, Coffey RJ, Radhika A, et al. Up-regulation of cyclooxygenase 2 gene expression in human colorectal adenomas and adenocarcinomas. *Gastroenterology* 1994;107:1183–8.
- [32] Abou-Issa HM, Alshafie GA, Seibert K, et al. Dose-response effects of the COX-2 inhibitor, celecoxib, on the chemoprevention of mammary carcinogenesis. *Anticancer Res* 2001;21:3425–32.
- [33] Bertagnolli MM, Eagle CJ, Zauber AG, et al. Celecoxib for the prevention of sporadic colorectal adenomas. *N Engl J Med* 2006;355:873–84.

- [34] Arber N, Eagle CJ, Spick J, et al. Celecoxib for the prevention of colorectal adenomatous polyps. *N Engl J Med* 2006;355:885–95.
- [35] Baron JA, Sandler RS, Bresalier RS, et al. A randomized trial of rofecoxib for the chemoprevention of colorectal adenomas. *Gastroenterology* 2006;131:1674–82.
- [36] Calder PC. Polyunsaturated fatty acids, inflammation, and immunity. *Lipids* 2001;36:1007–24.
- [37] Young MRY. Eicosanoids and the immunology of cancer. *Cancer Metastasis Rev* 1994;13:337–48.