



UNIVERSITÀ
DEGLI STUDI
FIRENZE

FLORE

Repository istituzionale dell'Università degli Studi di Firenze

Is the percentage of stenosis of the internal carotid artery a reliable measure of the risk of ischemic stroke? A morphometric study by

Questa è la Versione finale referata (Post print/Accepted manuscript) della seguente pubblicazione:

Original Citation:

Is the percentage of stenosis of the internal carotid artery a reliable measure of the risk of ischemic stroke? A morphometric study by duplex ultrasound of aortic arch branches in 500 normal adults / C. Macchi; R. M. Lova; B. Miniati; M. Gulisano; C. Pratesi; A. A. Conti; G. F. Gensini. - In: JOURNAL OF CARDIOVASCULAR SURGERY. - ISSN 0021-9509. - STAMPA. - 43:(2002), pp. 71-76.

Availability:

The webpage <https://hdl.handle.net/2158/351232> of the repository was last updated on

Terms of use:

Open Access

La pubblicazione è resa disponibile sotto le norme e i termini della licenza di deposito, secondo quanto stabilito dalla Policy per l'accesso aperto dell'Università degli Studi di Firenze (<https://www.sba.unifi.it/upload/policy-oa-2016-1.pdf>)

Publisher copyright claim:

La data sopra indicata si riferisce all'ultimo aggiornamento della scheda del Repository FloRe - The above-mentioned date refers to the last update of the record in the Institutional Repository FloRe

(Article begins on next page)

VASCULAR SECTION

ORIGINAL ARTICLES

J CARDIOVASC SURG 2002;43:71-6

Is the percentage of stenosis of the internal carotid artery a reliable measure of the risk of ischemic stroke? A morphometric study by duplex ultrasound of aortic arch branches in 500 normal adults

C. MACCHI*, R. MOLINO LOVA*, B. MINIATI*, M. GULISANO**
C. PRATESI***, A. A. CONTI*°, G. F. GENSINI*°

Background. The percentage of stenosis has been considered for the last 20 years, and still continues to be, the main criterion of choice between a surgical and a medical treatment of the atherosclerotic lesions of the aortic arch branches, particularly as regards the internal carotid artery. On the other side, it has been demonstrated that the risk of adverse acute cerebrovascular events, besides being related to the characteristics of the plaque, such as softness, subintimal haemorrhage or surface ulcer, is strictly related to the actual residual lumen of the internal carotid artery. The pre-eminent role of the percentage of stenosis in the choice of the treatment, hence, presumes a narrow range of variation of the original calibre of the vessel, yet to be proven.

Methods. Five-hundred normal adults underwent the measurement of the internal calibre of the aortic arch branches by duplex ultrasound in order to find out their actual range of variation.

Results. The range of variation of the internal calibre of the aortic arch branches, expressed as the ratio between the maximum and the minimum value found for each vessel, was very wide in all cases (from 180% for the right common carotid artery to 340% for the right vertebral artery). With reference to the internal carotid arteries, the range of variation was 219% for the right internal carotid artery and 241% for the left internal carotid arteries.

Conclusions. Due to the wide range of variation of the original calibre of the aortic arch branches, the percentage of stenosis alone cannot be considered an accurate measure of the severity of the stenosis, and hence a reliable criterion of choice of the treatment.

KEY WORDS: Carotid stenosis, etiology - Carotid stenosis, diagnosis - Carotid stenosis, surgery - Atherosclerosis - Brain ischemia.

The normal calibre of aortic arch branches is reported in the literature as an extremely discor-

dant datum. For instance, the normal calibre of the innominate artery is reported as 11 mm,¹ 12 mm,² 13 mm,³ 14 mm,⁴ and 15 mm.⁵

Besides its purely academic interest, the knowledge of the calibre of aortic arch branches in normal adults and, mainly, of its actual range of variation, has important clinical implications, particularly as far as the internal carotid artery is concerned.

Stroke represents, in fact, an important cause of death and a major cause of disability in the Western World, with atherosclerotic stenosis of the internal carotid artery accounting for most ischemic strokes.^{6,7} In the last 20 years several randomized controlled trials, such as the North American Symptomatic Carotid Endarterectomy Trial (NASCET),^{8,9} the European Carotid Surgery Trial (ECST)¹⁰ and the Asymptomatic Carotid Atherosclerosis Study (ACAS),¹¹ have tried to evaluate the efficacy and safety of carotid endarterectomy in preventing ischemic strokes. Published results suggest that carotid endarterectomy does prevent ischemic strokes in symptomatic patients with "severe" stenosis, provided the surgical morbidity is acceptable.^{8,10} For symptomatic patients with "mild" stenosis there is no apparent benefit from the procedure,¹⁰ while for symptomatic patients with "moderate" stenosis the balance of surgical risk and benefit remains unclear.^{8,10} Furthermore, despite ACAS¹¹ results, according to which carotid endarterectomy should be beneficial to asymp-

Authors' address: C. Macchi, Via Padule 115, 50039 Vicchio (FI), Italy.

tomatic patients with "severe" stenosis, the approach to asymptomatic patients is still controversial.¹² In all these trials the patients were classed into three different categories (mild, moderate and severe) on the basis of the determination of the percentage of stenosis, by comparing the diameter of the residual lumen at the point of maximal stenosis with the diameter of the internal carotid artery well beyond the bulb,^{8, 9, 11} or with the diameter of the presumed and unseen carotid bulb,¹⁰ measured from angiograms taken in multiple orthogonal projections.¹³ More recent papers, based upon duplex ultrasound¹⁴ or *en bloc* carotid endarterectomy specimens,¹⁵ have shown that the residual lumen, expressed as a cross-sectional area¹⁴ or as a diameter,¹⁵ is the most accurate measure of the severity of the stenosis.

Therefore, if the range of variation of the original calibre of the vessels is narrow, we can, reasonably, assume that the residual lumen, which is, actually, an absolute value and not a percentage, is related to the percentage of stenosis measured from angiograms, but if the range of variation of the original calibre of the vessels is very wide, this assumption is no longer correct, and the results of the above mentioned trials should be reviewed.

The investigation of the actual range of variation of the calibre of aortic arch branches in normal adults was the aim of the present paper.

Materials and methods

Five-hundred consecutive Caucasian subjects, 250 males and 250 females, aged from 35 to 88 years (mean $64.3 \pm \text{S.D. } 13.2$) free from vascular diseases underwent the measurement of the internal calibre of the aortic arch branches by duplex ultrasound. Anthropometric characteristics of the study population are reported in Table I. No subject had been suffering from hypertension, diabetes mellitus or other systemic diseases in the last 10 years. No history of previous adverse cerebrovascular events was present.

All subjects gave their written consent for processing and using personal medical data in scientific papers, in accordance to the Italian Law.

Duplex ultrasound investigations were performed by two physicians in all cases in the morning, after a light breakfast, by an Acuson 128XP System, using a 7.5 MHz probe, with the subject in the supine posi-

TABLE I.—Main anthropometric data.

Subjects	Parameters	Age (years)	Weight (kg)	Height (cm)	BSA (m ²)
500	Mean	64.30	67.28	170.93	1.78
	SD	13.22	9.96	7.38	0.16
	min	35	45	150	1.41
	max	88	94	191	2.20
250 males	Mean	65.67	73.93	176.04	1.90
	SD	12.88	8.24	6.07	0.13
	min	35	58	150	1.58
	max	88	94	191	2.20
250 females	Mean	62.94	60.64	165.81	1.67
	SD	13.44	6.51	4.42	0.10
	min	39	45	155	1.41
	max	82	76	176	1.91

BSA= body surface area.

tion. The internal calibre of aortic arch branches was measured in the appropriate longitudinal section (antero-posterior, lateral or oblique), as the largest obtainable value, and checked against the value calculated from the smallest obtainable circumference in the transverse section, at the following levels: for the innominate artery 10 mm proximally to its bifurcation, for the subclavian artery 5 mm distally to the origin of the vertebral artery, for the common carotid artery 10 mm proximally to the bulb, for the internal carotid artery 15 mm distally to the bulb, as in the NASCET⁹ and in the ACAS,¹¹ for external carotid artery 15 mm distally to the bulb, and for the vertebral artery 10 mm proximally to its entrance into the C6 foramen transversus.

Interobserver variations were controlled in a random sample of 100 subjects. Intraobserver variations were controlled in a further random sample of 100 subjects.

Observed and expected 50th, 25th and 75th percentiles were used to check the distribution of variables. Expected values were calculated as the mean, for 50th percentile, and as the mean \pm 0.67 standard deviation for 25th and 75th percentiles. Student "t"-test for independent data was used for males *versus* females comparisons and for right side *versus* left side comparisons. One-way χ^2 test (goodness-of-fit) was used to check the side asymmetry of examined vessels. Pearson "r" coefficient was used to check the correlation between variables, and "r²" coefficient was used to evaluate the amount of variance of the dependent variable related to regression.¹⁶

TABLE II.—*Calibre of examined vessels.*

Subjects	Parameters	IA (mm)	RSA (mm)	LSA (mm)	RCCA (mm)	LCCA (mm)	RICA (mm)	LICA (mm)	RECA (mm)	LECA (mm)	RVA (mm)	LVA (mm)
500	Mean	10.64	6.43	5.99	6.85	6.95	4.85	4.82	3.82	3.78	3.08	3.26
	SD	1.94	0.78	0.89	0.86	1.01	0.69	0.69	0.62	0.59	0.63	0.57
	min	6.7	4.5	3.9	5	4.9	3.1	2.9	2.5	2.5	1.5	1.7
	max	17.5	9.5	8.5	9	10.3	6.8	7	6	5.3	5.1	4.9
	Ratio	261	211	218	180	210	219	241	240	212	340	288
250 males	Mean	11.51	6.62	6.30	7.13	7.35	4.91	4.82	4.05	3.97	3.19	3.26
	SD	1.91	0.85	0.85	0.84	1.01	0.54	0.62	0.61	0.52	0.67	0.56
	min	8.1	4.8	4.5	5.4	5.9	3.1	3.5	2.8	2.8	1.5	1.8
	max	17.5	9.5	8.5	9	10.3	6.3	7	6	5.3	5.1	4.9
	Ratio	216	198	189	167	175	203	200	214	212	340	272
250 females	Mean	9.76	6.24	5.68	6.56	6.55	4.78	4.81	3.60	3.58	2.97	3.26
	SD	1.53	0.65	0.83	0.79	0.83	0.81	0.76	0.54	0.59	0.57	0.59
	min	6.7	4.5	3.9	5	4.9	3.3	2.9	2.5	2.5	1.7	1.7
	max	13.2	7.5	7.2	8.6	8.6	6.8	6.4	5.3	5.2	4.4	4.5
	Ratio	197	167	185	172	176	206	221	212	208	259	265

IA=innominate artery; RSA=right subclavian artery; LSA=left subclavian artery; RCCA=right common carotid artery; LCCA=left common carotid artery; RICA=right internal carotid artery; LICA=left internal carotid artery; RECA=right external carotid artery; LECA=left external carotid artery; RVA=right vertebral artery; LVA=left vertebral artery. Ratio=(max/min)%.

TABLE III.—*Side asymmetry.*

Subjects	Parameters	Right > left	%	Left > right	%	Right = left	%	Significance (*)
500	Subclavian artery	337	67.4	122	24.4	41	8.2	p < 0.001
	Common carotid artery	211	42.2	246	49.2	43	8.6	p = N.S.
	Internal carotid artery	256	51.2	213	42.6	31	6.2	p = N.S.
	External carotid artery	232	46.4	211	42.2	57	11.4	p = N.S.
	Vertebral artery	195	39.0	278	55.6	27	5.4	p < 0.001
250 males	Subclavian artery	169	67.6	60	24.0	21	8.4	p < 0.001
	Common carotid artery	88	35.2	138	55.2	24	9.6	p < 0.005
	Internal carotid artery	129	51.6	103	41.2	18	7.2	p = N.S.
	External carotid artery	107	42.8	102	40.8	41	16.4	p = N.S.
	Vertebral artery	101	40.4	130	52.0	19	7.6	p = N.S.
250 females	Subclavian artery	168	67.2	62	24.8	20	8.0	p < 0.001
	Common carotid artery	123	49.2	108	43.2	19	7.6	p = N.S.
	Internal carotid artery	127	50.8	110	44.0	13	5.2	p = N.S.
	External carotid artery	125	50.0	109	43.6	16	6.4	p = N.S.
	Vertebral artery	94	37.6	148	59.2	8	3.2	p < 0.001

*) The reported significance of the test is limited to side prevalence of the examined vessels (see text for further details)

Results

Interobserver variations were limited to 23% and in no case the measurement of the calibre varied by more than 0.2 mm. Intraobserver variations were limited to 12% and in no case the measurement of the calibre varied by more than 0.1 mm. No abnormal origin or course of the examined vessels was reported.

No differences were found between observed and expected values for 50th, 25th and 75th percentiles, so

that we could assume a normal distribution of the examined variables.

The calibre of examined vessels is reported in Table II.

Innominate artery, right subclavian artery, left subclavian artery, right common carotid artery, left common carotid artery, right external carotid artery, left external carotid artery and right vertebral artery, all were significantly larger (p<0.001) in males than in females. No significant difference was present as

regard as right internal carotid artery, left internal carotid artery and left vertebral artery.

Right subclavian artery was significantly larger than left subclavian artery in the group as a whole ($p < 0.001$), in the males subgroup ($p < 0.001$) and in the females subgroup ($p < 0.001$), right vertebral artery was significantly smaller than left vertebral artery in the group as a whole ($p < 0.001$) and in the females subgroup ($p < 0.001$) but not in the males subgroup, while right common carotid artery was significantly smaller than left common carotid artery ($p < 0.01$) only in the males subgroup. No significant side difference was found as regard as the internal and external carotid arteries in the group as a whole, in the males subgroup and in the females subgroup.

Side asymmetry is shown in Table III. The reported significance of the test is limited to side prevalence of the examined vessels. Taking into account even the subjects with the same bilateral calibre, the test is highly significant ($p < 0.001$) in all cases, due to the small amount of subjects with symmetric arteries. The degree of asymmetry of the vessels, expressed as the percentage of subjects showing different bilateral calibre, ranged from 83.6% (100-16.4%) for the external carotid artery in the males subgroup to 96.8% (100-3.2%) for the vertebral artery in the females subgroup.

A weak correlation was found between the calibre of each vessel and age, weight, height and body surface area, but "r²" coefficient showed that only a small amount of variance of the dependent variable was actually related to regression.

Discussion and conclusions

Our results clearly show a very wide range of variation of the calibre and a very high degree of side asymmetry of aortic arch branches in normal adults. Implications following from these results, obviously, go beyond the purely academic interest, particularly as far as the internal carotid artery is concerned.

If the brain could change its flow according to the functional status, like the muscles or the heart, ischemia would be strictly related to the percentage of stenosis. But this is not the case. With a normal circle of Willis, even a complete occlusion of one internal carotid artery may not cause cerebral ischemia, while a partial occlusion of the vessel by an atherothrombotic lesion may produce emboli that lodge in distal cerebral arteries, causing an ipsilat-

eral ischemic stroke.^{10, 17-19} The risk of ischemic stroke, therefore, is not related to the degree of stenosis itself, but is related to the thromboembolic risk of the atherosclerotic lesion. The characteristics of the atheromatous plaque, as softness of the plaque bulk, subintimal haemorrhage and surface ulcer or roughness, are factors known to be decisive in the production of emboli.^{3, 20, 21} Stenosis, on its own, causes an increase of velocity of the blood stream and, if the plaque surface is rough, even a turbulent flow,²²⁻²⁴ which acts against the atheromatous plaque, worsening the production of emboli. When the stenosis is very tight, the slowing down effect of viscosity becomes substantial,²³ producing the characteristic Doppler²³ and angiographic²⁵ picture of "near occlusion".

Though carotid endarterectomy, introduced by Eastcott²⁶ in 1954 and further technically improved by the intraoperative measurement of carotid back pressure²⁷ and by the use of shunts,²⁸ seems to be the logical approach to the problem, the results of the trials are not as brilliant as one would expect. In synthesis, published results from the NASCET⁸ and from the ECST¹⁰ suggest that carotid endarterectomy is beneficial to symptomatic patients with 70-99% (=severe) stenosis, and published results from the ECST¹⁰ suggest that there is no difference between surgical and medical treatment in symptomatic patients with 0-29% (=mild) stenosis. A wide margin of uncertainty remains about the treatment of symptomatic patients with a 30-69% (=moderate) stenosis. Furthermore despite ACAS¹¹ results, according to which carotid endarterectomy should be beneficial to asymptomatic patients with >60% stenosis, the approach to asymptomatic patients is still controversial.¹²

It had already been demonstrated¹⁷ that TIAs, which are the first symptoms of plaque embolism, if plotted against the angiographic residual lumen, show a peak corresponding to a residual lumen <2 mm. More recent papers, based upon ultrasound tomography¹⁴ or *en bloc* carotid endarterectomy specimens,¹⁵ have shown that the residual lumen, expressed as a cross-sectional area¹⁴ or as a diameter,¹⁵ is the most accurate measure of the severity of the stenosis, and that the risk of stroke becomes high when the residual lumen has a cross-sectional area <3 mm¹⁴ or a diameter <2 mm.¹⁵

Our data clearly show that, due to the wide range of variation of the original calibre of aortic arch

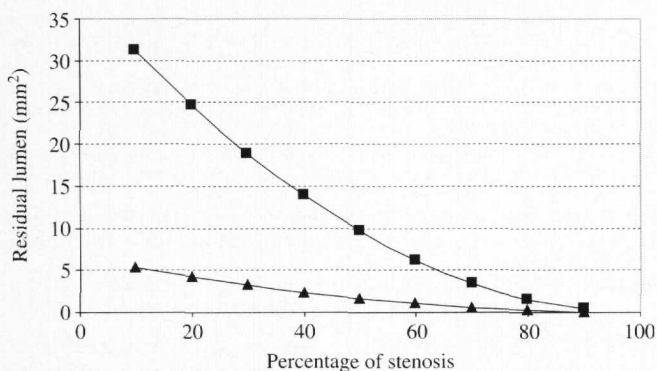


Fig. 1.—Residual area of internal carotid arteries plotted against the percentage of stenosis, calculated for the maximum (squares) and the minimum (triangles) calibre found for the vessel.

branches, the residual lumen is not directly related to the percentage of stenosis.

Figure 1 shows the residual area of internal carotid arteries plotted against the percentage of stenosis, calculated for the maximum and the minimum calibre found for the vessel. It is apparent that for the same percentage of stenosis the residual lumen is remarkably different. And it is apparent, as well, that even a 30-69% (= moderate) stenosis can reduce the residual lumen to critical values in small internal carotid arteries.

Actually, NASCET⁸ and ACAS¹¹ trialists considered the problem of the "small distal arteries". For cases of "near occlusion", identified at angiography by means of delayed filling time, reduced distal lumen and intracranial collateral vessels, they, arbitrarily, assigned 95% as the degree of stenosis.¹³ However, it is not clear how they classed the stenosis of a "small" internal carotid artery without the angiographic pattern of reduced perfusion. More recently, in the presence of a "small" internal carotid artery, it has been proposed to recalculate the percentage of stenosis considering as denominator the calibre of the contralateral healthy vessel,²⁹ but our results clearly show that this choice is not correct, due to the high degree of side asymmetry of aortic arch branches.

Eventually, as regards the side asymmetry of internal carotid arteries, it has been recently demonstrated³⁰ that there is an association of unilaterally absent or hypoplastic A1 segment of anterior cerebral artery with ipsilateral decrease in internal carotid artery calibre, and this can be seen on MR angiograms.

Conclusions

In conclusion, due to the wide range of variation of the calibre of all aortic arch branches, the percentage of stenosis alone cannot be considered an accurate measure of the severity of the stenosis, and hence a reliable criterion of choice of the treatment. Furthermore, the presence of small internal carotid arteries should be considered *per se* a risk factor, both if bilateral, due to the fact that even a low percentage stenosis can reduce the residual lumen till critical values,¹⁴ and if unilateral, due to the fact that this condition is often associated to an unbalanced circle of Willis.³⁰

References

1. Adachi B. Das Arteriensystem der Japaner. Kioto: Maruzen, 1928.
2. Testut L, Latarjet A. Trattato di anatomia umana normale. Torino: UTET, 1959.
3. Franceschi CL, Franco G, Luizi F, Tanitte M. Précis d'échotomographie vasculaire. Paris: Editions Vigot, 1986.
4. Davies DV, Davies A. Gray's anatomy. London: Longmans, 1962.
5. Ghigi C. Anatomia umana normale. Bari: ILUCE, 1946.
6. Fisher CM. Occlusion of internal carotid artery. Arch Neurol Psychiatry 1951;65:346-77.
7. Estol CF, Dr. C. Miller Fisher and the history of carotid artery disease. Stroke 1996;27:559-66.
8. North American Symptomatic Carotid Endarterectomy Trial Collaborators. Beneficial effect of carotid endarterectomy in symptomatic patients with high grade carotid stenosis. N Engl J Med 1991;325:445-53.
9. North American Symptomatic Carotid Endarterectomy Trial (NASCET) Steering Committee. North American Symptomatic Carotid Endarterectomy Trial: methods, patients characteristics, and progress. Stroke 1991;22:711-20.
10. European Carotid Surgery Trialists' Collaborative Group: MRC European Carotid Surgery Trial: interim results for symptomatic patients with severe (70-99%) or with mild (0-29%) carotid stenosis. Lancet 1991;337:1235-43.
11. Executive Committee for the Asymptomatic Carotid Atherosclerosis Study. Endarterectomy for asymptomatic carotid artery stenosis. JAMA 1995;273:1421-8.
12. Barnett HJM, Eliasziw M, Meldrum HE, Taylor DW. Do the facts and figures warrant a 10-fold increase in the performance of carotid endarterectomy on asymptomatic patients? Neurology 1996;46:603-8.
13. Fox Allan J. How to measure carotid stenosis. Radiology 1993; 186:316-8.
14. Macchi C, Catini C, Giannelli F. The original calibre of the carotid artery as a possible risk factor for complication of atherosclerosis. It J Anat Embryol 1993;4:259-68.
15. Suwanwela N, Can U, Furie KL, Southern JF, Macdonald NR, Ogilvy CS *et al*. Carotid Doppler ultrasound criteria for internal carotid artery stenosis based on residual lumen diameter calculated from *en bloc* carotid endarterectomy specimens. Stroke 1996;27:1965-9.
16. Glantz Stanton A. Primer of biostatistics. New York: McGraw-Hill, Inc, 1992.
17. Pessin MS, Duncan GW, Mohr JP, Poskanzer DC. Clinical and angiographic features of carotid transient attacks. N Engl J Med 1977;296:358-62.
18. Toole JF, Janeway R, Choi K. Transient ischemic attacks due to

- atherosclerosis: a prospective study of 160 patients. *Arch Neurol* 1975;32:5-12.
19. Moore WS, Hall HD. Importance of emboli from carotid bifurcation in pathogenesis of cerebral ischemic attacks. *Arch Surg* 1970;101:708-16.
 20. Ammar AD, Wilson RL, Travers H, Lin JJ, Fara SJ, Chang FC. Intraplaque hemorrhage: its significance in cerebrovascular disease. *Am J Surg* 1984;148:840-3.
 21. Bartynski WS, Darbuoze P, Nemir P Jr. Significance of ulcerated plaque in transient cerebral ischemia. *Am J Surg* 1984;141:353-7.
 22. Brice JG, Dowsett DJ, Lowe RD. Haemodynamic effects of carotid artery stenosis. *Brit J Med* 1964;11:1363-6.
 23. Franceschi CL. L'investigation vasculaire par ultrasonographie Doppler. Paris: Ed. Masson, 1979.
 24. Langlois Y, Roederer GO, Chan A, Phillips DJ, Beach KW, Martin D *et al*. Evaluating carotid artery disease. *Ultrasound Med Biol* 1983;9:51-63.
 25. Morgenstern LB, Fox AJ, Sharpe BL, Eliaziv M, Barnett HJ, Grotta JC. The risks and benefits of carotid endarterectomy in patients with near occlusion of the carotid artery. North American Symptomatic Carotid Endarterectomy Trial (NASCET) Group. *Neurology* 1997;48:911-5.
 26. Eastcott HHG, Pickering GW, Rob CG. Reconstruction of internal carotid artery in a patient with intermittent attacks of hemiplegia. *Lancet* 1954;2:994-6.
 27. Hays RJ, Levinson SA, Wylie EJ. Intraoperative measurement of carotid back pressure as a guide to operative management for carotid endarterectomy. *Surgery* 1972;72:953-60.
 28. Hughes RK, Bustos M, Byrne JP jr. Internal carotid artery pressure. A guide for use of shunt during carotid repair. *Arch Surg* 1974;109:494-5.
 29. Dix JE, McNulty BJ, Kallmes. Frequency and significance of a small distal ICA in carotid artery stenosis. *Am J Neuroradiol* 1998;19:1215-8.
 30. Kane AG, Dillon WP, Barkovich AJ, Norman D, Dowd CF, Kana TT. Reduced calibre of the internal carotid artery: a normal finding with ipsilateral absence or hypoplasia of the A1 segment. *Am J Neuroradiol* 1996;17:1295-301.