



UNIVERSITÀ  
DEGLI STUDI  
FIRENZE

## FLORE

# Repository istituzionale dell'Università degli Studi di Firenze

### **Antigenic phenotype of radial growth phase melanomas with or without a vertical growth phase portion.**

Questa è la Versione finale referata (Post print/Accepted manuscript) della seguente pubblicazione:

*Original Citation:*

Antigenic phenotype of radial growth phase melanomas with or without a vertical growth phase portion / L. Brogelli; P. Carli; U. Reali; N. Pimpinelli; S. Moretti. - In: TUMORI. - ISSN 0300-8916. - STAMPA. - 74:(1988), pp. 157-162.

*Availability:*

The webpage <https://hdl.handle.net/2158/352646> of the repository was last updated on

*Terms of use:*

Open Access

La pubblicazione è resa disponibile sotto le norme e i termini della licenza di deposito, secondo quanto stabilito dalla Policy per l'accesso aperto dell'Università degli Studi di Firenze (<https://www.sba.unifi.it/upload/policy-oa-2016-1.pdf>)

*Publisher copyright claim:*

La data sopra indicata si riferisce all'ultimo aggiornamento della scheda del Repository FloRe - The above-mentioned date refers to the last update of the record in the Institutional Repository FloRe

(Article begins on next page)

## ANTIGENIC PHENOTYPE OF RADIAL GROWTH PHASE MELANOMAS WITH OR WITHOUT A VERTICAL GROWTH PHASE PORTION

Laura Brogelli,<sup>1</sup> Paolo Carli,<sup>1</sup> Umberto Maria Reali,<sup>2</sup>  
Nicola Pimpinelli<sup>1</sup> and Silvia Moretti<sup>1</sup>

<sup>1</sup> *Clinica Dermatologica II dell'Università degli Studi di Firenze* and <sup>2</sup> *Servizio di Chirurgia  
Plastica Dermatologica, Istituto di Clinica Dermosifilopatica, Università di Firenze*

The expression of 4 melanoma-associated antigens and of class I and II HLA antigens was investigated in 12 superficial spreading melanomas (SSM) and in 8 SSM with a vertical growth pattern portion (SS+NM) by the use of monoclonal antibodies and an indirect immunoperoxidase procedure. Monoclonal antibodies 225.28, 763.74, CL. 203, VF19-LL217, Q5-13, W6-32 and anti-HLA-DR, were used. Each antigen was more frequently expressed by SS+NM on the whole than by SSM and also by the radial growth pattern portions of SS+NM than by SSM. Vertical growth pattern portions of SS+NM were not antigenically similar to radial growth pattern portions in the same tumors. The high frequency of antigen expression in radial growth pattern melanomas seems to be associated with the appearance of a more invasive cell population.

When hybridoma technology was applied to human melanoma cell lines, immunologic heterogeneity was demonstrated in addition to already known diversities in biochemical and biologic properties (1, 2, 5-7, 10). Surgically removed melanomas were also later found to be heterogeneous (13, 14). Such a variability of the antigenic phenotype prevented an immediate clinical use of monoclonal antibodies but suggested interesting tools for the interpretation of tumor progression (5). The expression of distinct antigens in melanoma cell lines was thus associated with different stages of melanocytic differentiation (12), and immunohistologic investigations of surgically removed human melanomas showed some principles of antigen expression, in spite of its heterogeneity.

Brocker et al. (3) found that some antigens were associated with a poor or a good prognosis, independently of tumor thickness. Ruiter et al. (17) and Brocker et al. (4) demonstrated the association of major histocompatibility antigens with histomorphologic prognostic factors (thickness and level).

We investigated the antigen expression of superficial spreading melanomas (SSM) as such, clinically appearing as plaques, and of SSM with a vertical growth portion, clinically appearing as plaques plus nodule(s) (SS+NM), to inquire about the relationship between the antigenic phenotype and the pattern of growth of primary malignant melanoma in vivo.

*Acknowledgments:* Dr. L. Brogelli was supported by a contribution of the Associazione Italiana per la Ricerca sul Cancro (A.I.R.C.), Milan. This work was supported by a grant from the Italian Minister of Education (University funds, 60%). The authors thank Dr. Soldano Ferrone, New York Medical College, Valhalla, New York, for kindly providing monoclonal antibodies 225.28, 763.74, CL.203, VF19.LL217, Q5-13 and W6-32.

*Address for reprint requests:* Dr. Laura Brogelli, Clinica Dermatologica II, Via della Pergola 58, 50121 Firenze, Italia.

Received October 2, 1987.

Table 1 - Staining results: percentage of stained cells per section.

No.	Thickness, ( $\mu$ m) Level	Antibody							
		225.28	763.74	CL.203	VF19-LL217	Q5-13	W6-32	HLA-DR	
SSM									
1	0.55 II	0-10	0-10	0-10	0-10	0-10	51-80	0-10	
2	0.38 II	0-10	51-80	0-10	0-10	0-10	51-80	0-10	
3	0.55 II	0-10	0-10	0-10	0-10	ND	51-80	11-30	
4	0.47 III	0-10	0-10	0-10	11-30	0-10	0-10	0-10	
5	0.95 III	0-10	31-50	0-10	0-10	11-30	> 80	0-10	
6	4.20 IV	31-50	31-50	0-10	0-10	11-30	51-80	0-10	
7	4.75 IV	0-10	0-10*	51-80	31-50	0-10*	> 80	ND	
8	3.90 IV	ND	> 80	51-80	51-80	31-50	> 80	31-50	
9	1.10 III	> 80	> 80	11-30	11-30	31-50	> 80	0-10	
10	1.65 III	11-30	11-30	0-10*	0-10*	0-10	> 80	0-10	
11	1.75 IV	11-30	11-30	0-10	0-10	0-10	> 80	0-10	
12	1.40 IV	0-10	11-30	0-10*	31-50	0-10	> 80	0-10	
SS+NM									
13	5.60 III	r	11-30	11-30	51-80	0-10	31-50	> 80	31-50
		v	51-80	51-80	0-10	0-10	51-80	> 80	0-10
14	3.20 IV	r	11-30	11-30	11-30	11-30	ND	ND	11-30
		v	11-30	11-30	0-10	0-10	ND	ND	0-10
15	4.25 III	r	0-10	11-30	0-10	ND	0-10	31-50	0-10
		v	11-30	11-30	0-10	0-10	31-50	31-50	0-10
16	3.10 IV	r	0-10	0-10	0-10	11-30	31-50	11-30	11-30
		v	51-80	> 80	0-10	0-10	31-50	> 80	31-50
17	3.50 III	r	0-10	0-10	11-30	11-30	11-30	11-30	31-50
		v	11-30	11-30	0-10	0-10	11-30	11-30	0-10
18	1.90 IV	r	11-30	31-50	51-80	11-30	31-50	11-30	31-50
		v	> 80	> 80	11-30	0-10*	51-80	11-30	11-30
19	5.20 III	r	> 80	> 80	11-30	11-30	11-30	> 80	31-50
		v	31-50	> 80	31-50	0-10	0-10	31-50	0-10
20	2.08 IV	r	51-80	> 80	0-10	0-10	0-10	> 80	0-10
		v	> 80	> 80	31-50	0-10	11-30	> 80	11-30

ND: not done; \*: clusters of stained cells; r: radial growth phase; v: vertical growth phase.

### Material and methods

**Tumors.** Twenty primary malignant melanomas were examined. They were divided into two groups on the basis of clinical features. In the first group there were 12 malignant melanomas clinically appearing as plaques (SSM). In the second group there were 8 malignant melanomas appearing as plaques plus nodule(s) (SS+NM). At microscopic examination, SSM showed a radial growth phase pattern, whereas SS+NM had a radial growth phase pattern associated with a vertical growth phase pattern, following criteria proposed by Clark et al. (9). Among SSM, there were 3 level II, 4 level III and 5 level IV tumors, according to Clark. Among SS+NM, 3 tumors were level III and 5 were level IV. All the melanomas we examined were more than 0.75 mm thick, except for 4 SSM. Representative portions were included in OCT and cut in 5  $\mu$ m-thick sections.

**Monoclonal antibodies.** Four monoclonal antibodies against melanoma-associated antigens (MAA) (225.28 and 763.64 against HMW-MAA; CL.203; VF19-LL217) were kindly provided by Dr. S. Ferrone, Department of Microbiology and Immunology, New York Medical College, Valhalla, New York (U.S.A.). Anti-class I W6-32 and anti-class II O5-13 were also supplied by Dr. S. Ferrone. Anti-HLA-DR was purchased from Becton and Dickinson (Mountain View, California, U.S.A.).

**Immunoperoxidase technique.** An indirect immunoperoxidase technique, amplified by streptavidin-biotin-peroxidase complex (Amersham, Buckinghamshire, U.K.), was used. Acetone-chloroform-fixed cryostat sections were incubated with monoclonal antibodies for 30 min. Sections were then incubated with goat biotinylated Fab-anti-mouse serum (Amersham) and with streptavidin-biotin-peroxidase complex (Amersham). Peroxidase reaction was performed using 3-amino-9-ethyl-carbazole and  $H_2O_2$  in acetate buffer. Counterstain was done with Mayer's hematoxylin. Negative controls were run in parallel; the positive reaction of some monoclonal antibodies with normal cells served as an internal control.

**Evaluation.** The percentage of stained cells in each section was evaluated by two independent observers. Sections were indicated as positive when at least 10% of cells that could be identified as tumor cells or clusters of them were stained. Four positivity classes were assessed: 11% - 30%, 31% - 50%, 51% - 80%, > 80% of stained cells per section.

### Results

The staining results of each case are listed in Table 1. The number of positively stained SSM and SS+NM (more than 10% or clusters of positive cells) is reported in Table 2 (figs. 1 and 2).

Each antigen tested was expressed by a higher number of SS+NM than of SSM (table 2). The radial growth phase of SS+NM was also more frequently positive for each antigen than the radial growth phase SSM, although differences were less marked. This was observed also when SS+NM were matched with SSM of the same Clark levels. All SS+NM were Clark's level III or IV, and they were compared to the 9 SSM of the same Clark levels: all antigens were present in lower percentages of SSM than were the plaques of SS+NM. Only the epitope of the HMW-MAA marked by the monoclonal antibody 763.74 was represented in the same percentage of SSM or of radial growth portions of SS+NM.

The positivity of the radial growth phase was not necessarily associated with the positivity of the vertical growth phase in a single SS+NM, and vice-versa. In fact, one phase was sometimes positive while the other one was negative in a single SS+NM, and when both phases were positive, the percentage of stained cells in one phase was usually different from the other one. The HMW-MAA was expressed in a smaller number of radial growth phases than vertical growth phases; for monoclonal antibodies CL.203 and VF10-LL217 the opposite was true. Class I and class II antigens were almost equally represented in both growth phases. In addition, each monoclonal antibody stained variable percentages of cells in positive lesions, among SSM and SS+NM.

### Discussion

We investigated the expression of 4 MAA and of class I and class II HLA antigens in 12 malignant melanomas clinically appearing as plaques (SSM) and in 8 malignant melanomas clinically appearing as plaques plus nodule(s) (SS+NM); monoclonal antibodies and an indirect immunoperoxidase procedure were used. Different frequencies of antigen expression between the two groups were observed. Each antigen was more frequently expressed in SS+NM than in SSM, even when tumors with the same Clark levels were considered and when only the radial growth area of both types of tumors was taken into account.

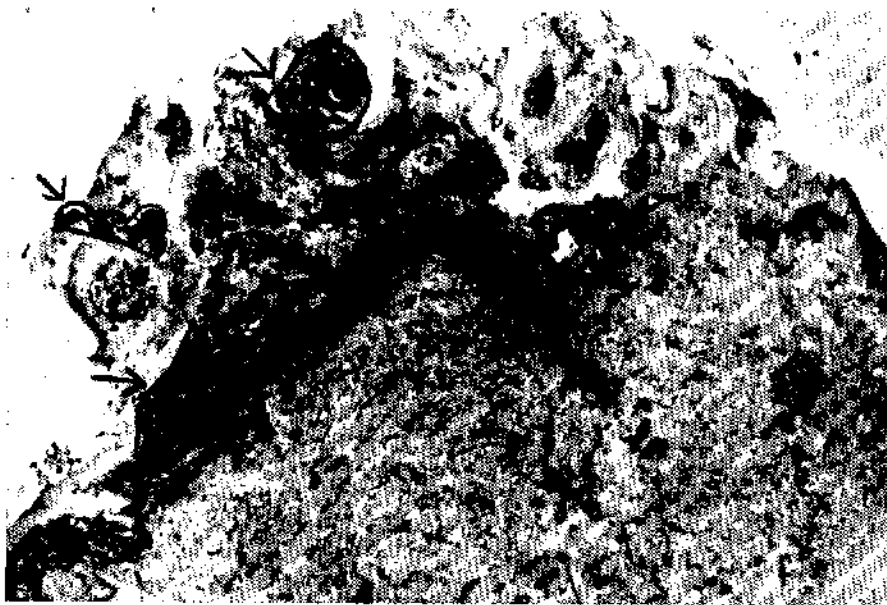

Fig. 1 - An example of SSM stained with 225.28; black areas consist of stained cells, except for the portions indicated by arrows where there are pigmented non-stained cells ( $\times 80$ ).




Fig. 2 - An example of SS+NM stained with 763.74; the radial growth phase portion shows a lower percentage of stained cells than the vertical growth phase portion. The different intensity of staining is also remarkable ( $\times 250$ ).

Class II HLA determinants (in our study recognized by anti-HLA-DR or by Q5-13 monoclonal antibodies) were rarely present on SSM and, in contrast, frequently expressed on SS+NM, both in radial and vertical growth areas. These antigens are usually considered to be associated with tumor progression in melanoma (4, 16, 17). Brocker et al. (3) found that HLA-DR antigen was associated with tumor thickness and level of invasion; they also observed that patients with HLA-DR+ primary melanomas had earlier metastases than patients with HLA-DR- tumors, irrespective of tumor thickness. Ruiter et al. (17) demonstrated that class II HLA antigens were rare in nevi and were frequent in thick primary melanomas and in metastases (16, 17).

In our series of melanomas, HLA-DR antigen was present in 86% of tumors showing, in addition to a radial growth phase, a vertical growth phase, which has been considered by Clark as an expression of a more aggressive behavior (8). HLA-DR antigen was expressed only in 19% of melanomas with just a radial growth phase. The difference between the two groups of tumors persisted also when tumors of comparable Clark levels were taken into account. Therefore, the difference in HLA-DR expression between SSM and SS+NM does not seem to be related only to the level of invasion of tumors, but also to

Table 2 - Positive lesions (&gt; 10 % stained cells per section).

	225.28	763.74	CL.203	VF19-LL217	Q5-13	W6-32	HLA-DR
SSM <sup>1</sup>							
(12)	4/11 36%	9/12 75%	5/12 42%	6/12 50%	5/11 45%	11/12 92%	2/11 19%
SS+NM <sup>2</sup> (8)							
whole	8/8 100%	8/8 100%	6/8 75%	5/7 71%	7/7 100%	7/7 100%	7/8 86%
vert	8/8 100%	8/8 100%	3/8 37%	1/8 12%	6/7 86%	7/7 100%	3/8 37%
rad	5/8 62%	6/8 75%	5/8 62%	5/7 71%	5/7 71%	7/7 100%	6/8 75%
SSM III/IV <sup>3</sup>							
(9)	4/8 50%	8/9 89%	5/9 55%	5/9 55%	5/9 55%	8/9 88%	1/8 12%

<sup>1</sup> All SSM (II, III and IV level).

<sup>2</sup> All SS+NM (III and IV level).

<sup>3</sup> Among SSM, 9 III or IV level SSM are separated because they closely matched SS+NM as regards level.

the clinico-pathologic type of melanomas (SSM versus SS+NM).

Less marked differences in frequency of antigen expression were observed as regards the 4 MAA studied. They were all expressed by a higher number of SS+NM than of SSM.

Class I antigens were demonstrated in almost every tumor, in accord with Ruiter et al. (17).

We found that the antigenic phenotype of the radial growth phase of SS+NM was different from the phenotype of the radial growth phase of SSM and also from the phenotype of the vertical growth phase of SS+NM in our series of melanomas. In fact, the 11M7-MAA was represented in a smaller number of radial growth phases than of vertical growth phases in SS+NM, and when it was present in the radial growth phase it was usually expressed in a lower percentage of cells. The opposite was true for monoclonal antibodies CL.203 and VF19-LL217.

There is some evidence that tumor progression is a stepwise phenomenon that may reflect the sequential appearance within the tumor of subpopulations with new characteristics leading to growing invasiveness and to competence for metastasis (15). Such a hypothesis is at present supported by histopathologic and immunopheno-

typic studies also in malignant melanoma (8, 11). Our results may be in accord with the idea of tumor progression also as a feature of melanoma. In fact, they show different patterns of antigen expression in melanoma, which are associated with different patterns of tumor growth, i.e., radial growth phase in SSM and radial growth plus vertical growth phase in SS+NM.

#### Fenotipo antigenico di melanomi a diffusione superficiale con o senza una porzione a crescita verticale

È stata indagata l'espressione di 4 MAA e degli antigeni HLA di I e II classe in 12 melanomi a diffusione superficiale (SSM) e in 8 SSM con una porzione a crescita verticale (SS+NM), impiegando anticorpi monoclonali e una tecnica di immunoperossidasi indiretta. Sono stati usati gli anticorpi monoclonali 225.28, 763.74, CL203, VF19LL217, Q5-13, W6-32 e anti-HLA-DR. Tutti gli antigeni erano espressi da un maggior numero di SS+NM che di SSM, anche quando si prendevano in considerazione le sole aree a crescita radiale. Le aree a crescita verticale dei SS+NM esprimevano gli antigeni con diversa frequenza e in diverse percentuali di cellule rispetto alle aree a crescita radiale degli stessi tumori. L'alta frequenza di espressione di antigeni nelle aree di melanoma a crescita radiale sembra associata alla comparsa di una popolazione cellulare dotata di maggiore aggressività.

#### References

1. Albino A.P., Lloyd O.K., Houghton A.N., Oettgen H.F., Old L.J.: Heterogeneity in surface antigen and glycoprotein expression of cell lines derived from different melanoma metastases of the same patient. *J. Exp. Med.*, 154: 1764-1778, 1981.
2. Barranco S.C., Ho D.H.W., Drewinko B., Rousdahl M.M., Humphrey R.M.: Differential sensitivities of human melanoma cells grown in vitro to arabinosyl cytosine. *Cancer. Res.*, 32: 2753-2756, 1972.
3. Brocker E.B., Suter L., Bruggen J., Ruiter D.J., Macher E., Sorg C.: Phenotypic dynamics of tumor progression in human malignant melanoma. *Int. J. Cancer*, 36: 29-35, 1985.

4. Brocker E.B., Suter L., Sorg C.: HLA-DR antigen expression in primary melanomas of the skin. *J. Invest. Dermatol.*, 82: 244-247, 1984.
5. Bruggen J., Macher E., Sorg C.: Expression of surface antigens and its relation to parameters of malignancy in human malignant melanoma. *Cancer Immunol. Immunother.*, 10: 121-127, 1981.
6. Bruggen J., Sorg C.: Detection of phenotypic differences on human malignant melanoma lines and their variant sublines with monoclonal antibodies. *Cancer Immunol. Immunother.*, 15: 200-205, 1983.
7. Burchiel S.W., Martin J.C., Imai K., Ferrone S., Warner N.L.: Heterogeneity of HLA-A, B, Ia-like, and melanoma-associated antigen expression by human melanoma cell lines analyzed with monoclonal antibodies and flow cytometry. *Cancer Res.*, 42: 4110-4115, 1982.
8. Clark W.H., Elder D.E., Guerry D., Epstein M.N., Greene M.H., Van Horn M.: A study of tumor progression: the precursor lesions of superficial spreading and nodular melanoma. *Hum. Pathol.*, 15: 1147-1165, 1984.
9. Clark W.H., Elder D.E., Van Horn M.: The biologic forms of malignant melanoma. *Hum. Pathol.*, 17: 443-450, 1986.
10. Fidler I.J., Kripke M.L.: Metastasis results from pre-existing variant cells within a malignant tumor. *Science*, 197: 893, 1977.
11. Herlyn M., Balaban C., Benicelli J., Du Pont Guerry IV, Halaban R., Herlyn D., Elder D.E., Maul G.C., Steplewski Z., Nowell P.C., Clark W.R., Koprowski H.: Primary melanoma cells of the vertical growth phase: similarities to metastatic cells. *J. Natl. Cancer Inst.*, 74: 283-289, 1985.
12. Houghton A.N., Eisinger M., Albino A.P., Cairncross J.G., Old L.J.: Surface antigens of melanocyte and melanoma. Markers of melanocyte differentiation and melanoma subsets. *J. Exp. Med.*, 156: 1755-1776, 1982.
13. Natali P.G., Cavaliere R., Bigotti A., Nicotra M.R., Russo C., Ng A.N., Giacomini P., Ferrone S.: Antigenetic heterogeneity of surgically removed primary and autologous metastatic human melanoma lesions. *J. Immunol.*, 130: 1462-1466, 1983.
14. Natali P.G., Bigotti A., Cavaliere R., Liao S.K., Taniguchi M., Matsui M., Ferrone S.: Heterogeneous expression of melanoma-associated antigens and HLA antigens by primary and multiple metastatic lesions removed from patients with melanoma. *Cancer Res.*, 45: 2883-2889, 1985.
15. Nowell P.C.: Mechanisms of tumor progression. *Cancer Res.*, 46: 2203-2207, 1986.
16. Ruiter D.J., Bhan A.K., Harrist T.J., Sober A.J., Mihm M.C.: Major histocompatibility antigens and mononuclear inflammatory infiltrate in benign nevocellular proliferations and malignant melanoma. *J. Immunol.*, 129: 2808-2815, 1982.
17. Ruiter D.J., Bergman W., Velyaart K., Scheffer E., van Vloten W.A., Russo C., Ferrone S.: Immunohistochemical analysis of malignant melanomas and nevocellular nevi with monoclonal antibodies to distinct monomorphic determinants of HLA antigens. *Cancer Res.*, 44: 3930-3935, 1984.