



UNIVERSITÀ
DEGLI STUDI
FIRENZE

FLORE

Repository istituzionale dell'Università degli Studi di Firenze

Ultrasound-guided hysteroscopic management of endometrial osseous metaplasia.

Questa è la Versione finale referata (Post print/Accepted manuscript) della seguente pubblicazione:

Original Citation:

Ultrasound-guided hysteroscopic management of endometrial osseous metaplasia / M. Coccia; C. Becattini; G. Bracco; G. Scarselli. - In: ULTRASOUND IN OBSTETRICS & GYNECOLOGY. - ISSN 0960-7692. - STAMPA. - 8(2):(1996), pp. 134-136.

Availability:

The webpage <https://hdl.handle.net/2158/352938> of the repository was last updated on

Terms of use:

Open Access

La pubblicazione è resa disponibile sotto le norme e i termini della licenza di deposito, secondo quanto stabilito dalla Policy per l'accesso aperto dell'Università degli Studi di Firenze (<https://www.sba.unifi.it/upload/policy-oa-2016-1.pdf>)

Publisher copyright claim:

La data sopra indicata si riferisce all'ultimo aggiornamento della scheda del Repository FloRe - The above-mentioned date refers to the last update of the record in the Institutional Repository FloRe

(Article begins on next page)

Ultrasound-guided hysteroscopic management of endometrial osseous metaplasia

M. E. Coccia, C. Becattini, G. L. Bracco and G. Scarselli

Department of Gynecology and Obstetrics, University of Florence, Italy

Key words: ENDOMETRIAL OSSEOUS METAPLASIA, ENDOMETRIAL OSSIFICATION, HYSTEROSCOPY, ULTRASOUND

ABSTRACT

In the past, most cases of osseous metaplasia of the endometrium were diagnosed following removal of bone from the endometrium by dilatation and curettage and frequently subsequently treated by hysterectomy. Nowadays, management involves a suggested diagnosis by transvaginal ultrasound examination, confirmation by hysteroscopy and hysteroscopic removal of ectopic intrauterine bone. This is usually carried out under laparoscopic guidance. However, the degree of visual control provided by combined transabdominal and transrectal ultrasonography may prove sufficiently accurate for hysteroscopic guidance. In this report we describe a case of endometrial osseous metaplasia successfully managed by ultrasound-guided hysteroscopy. The advantages of our approach include reduced invasiveness, reduced costs and simultaneous visualization of the abdominal and intrauterine cavities. One limitation, however, is represented by the greater operator dependence of ultrasound guidance as compared to laparoscopy, the former requiring extensive training and state-of-the-art equipment.

We suggest that ultrasound guidance for hysteroscopic removal of extensive osseous metaplasia may represent a potentially safer and more effective alternative to laparoscopy and would therefore encourage further clinical evaluation of this technique.

INTRODUCTION

Osseous metaplasia of the uterus is a rare entity that results from the transformation of non-osseous connective tissue into mature bone. It occurs in approximately 0.3 per 1000 women. Endometrial ossification is frequently associated with a history of recurrent abortions, and its clinical presentation may include vaginal bleeding, leukorrhea and pelvic pain^{1,2}.

In the past, most cases required diagnostic dilatation and curettage (D & C) for removal of bone tissue from the endometrium, and hysterectomy was frequently then re-

quired. Nowadays the diagnosis can be suggested by the finding of a strongly echogenic band within the uterus at transvaginal ultrasound examination, and subsequently be confirmed by hysteroscopic visualization of bony spicules within the endometrium. Treatment by hysteroscopic removal of ectopic intrauterine bone under laparoscopic guidance has recently been proposed³.

This report describes a case of endometrial osseous metaplasia managed by hysteroscopy under simultaneous ultrasound guidance.

CASE REPORT

A 29-year-old woman, gravida 2, para 1, abortus 1, presented at our clinic with foul-smelling leukorrhea and metrorrhagia. She had a history of intermittent vaginal bleeding and infection dating back to a D & C performed 3 months earlier, following a premature delivery for intrauterine death at 25 weeks. Past medical history revealed that she had menarche at the age of 16 followed by regular periods, with menstrual flow lasting 4–5 days. At the age of 19 she underwent voluntary abortion at 6 weeks by D & C.

On admission, pelvic examination revealed an anteverted uterus of normal size. On examination of the cervix, a spicule measuring 16 × 10 × 8 mm was removed with a tissue-biopsy forceps. Histopathology demonstrated osseous metaplasia. A detailed clinical history suggested no evidence of abnormal calcium metabolism, thyroid or parathyroid disease, renal calculi or excessive vitamin D consumption. Complete blood count, urinalysis, serum electrolytes and liver function tests were normal. At transvaginal ultrasound examination a central echogenic band was found, which occupied the entire uterine cavity and partially included the cervix and discrete areas of the myometrium (Figure 1). Hysteroscopic examination showed numerous solid white spicules covering the endometrial surface almost completely and extending to the cervical

canal (Figure 2). Hysteroscopic resection of the bone tissue was performed. The entire procedure was carried out under ultrasound guidance with Aloka SSD-620 equipment, by means of two probes alternately: a 5.5-MHz transvaginal probe, which was used transabdominally over the suprapubic area, and a 5.5-MHz transrectal probe. This approach permitted clear visualization of the uterine cavity, which appeared to be extensively occupied by a hyperechogenic area. The bony fragments were removed progressively by means of biopsy forceps and a resectoscope, with the use of short bursts of electrosurgical energy (Figure 3). This was followed by gentle curettage. During the procedure the ultrasound images confirmed a progressive reduction of the hyperechogenic areas. In particular, ultrasound guidance allowed visualization and removal of three small hyperechogenic areas embedded in the myometrium and thus not visible at hysteroscopy. At the end of the procedure, ultrasound examination showed only minimal bone residues deeply embedded in the myometrium (Figure 4). Microscopic examination of the various tissue specimens demonstrated extensive osseous metaplasia of the endometrium

and endocervix (Figure 5). No postoperative complications occurred and the patient was discharged 2 days later.

An ultrasound scan, performed after 1 month, showed a normal-appearing endometrial echo and two minimal submucosal hyperechogenic areas (7 mm and 9 mm in diameter) interpreted as residual calcifications. Follow-up




Figure 1 Longitudinal transvaginal scan of the uterus, showing a central echogenic band, which occupied the entire uterine cavity

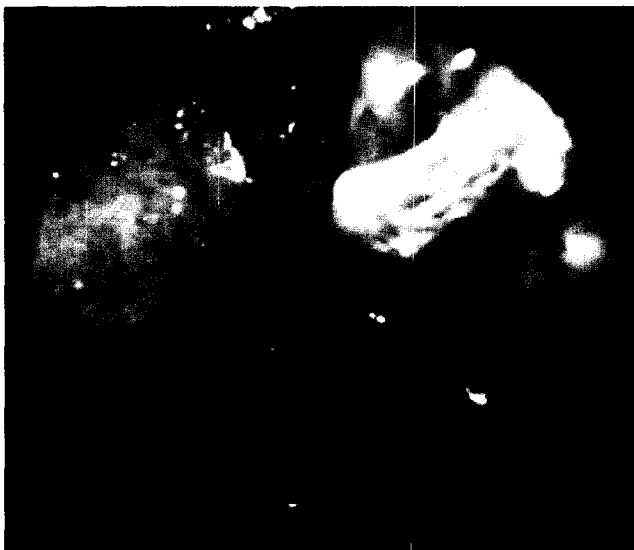

Figure 2 Hysteroscopic examination, showing numerous solid white spicules covering the endometrial surface almost completely

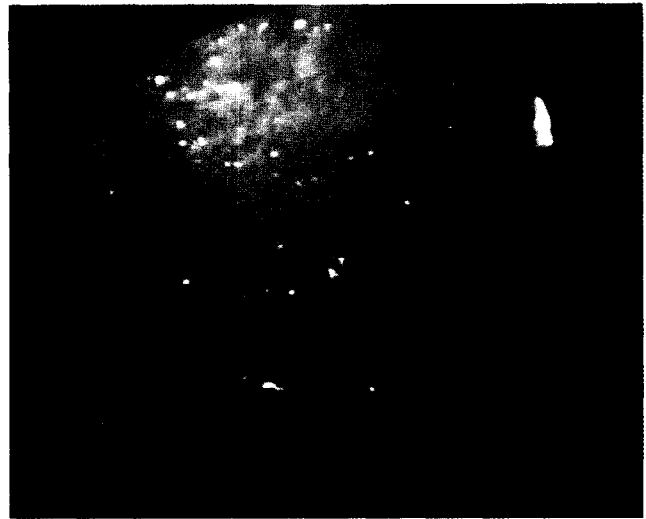


Figure 3 Hysteroscopic visualization of the uterine cavity at the end of the procedure




Figure 4 Ultrasonogram showing a marked reduction of the hyperechogenic area during surgery




Figure 5 Fragments of extensive osseous metaplasia after hysteroscopic removal

ultrasound examinations at 4 and 18 months were unchanged. To date, the patient enjoys good health and has regular menses.

DISCUSSION

In spite of numerous theories on the subject, the etiology of osseous metaplasia remains controversial. As early as 1884 Virchow attributed the formation of bone in the endometrium to spontaneous differentiation of fibroblasts into osteoblasts⁴. The direct implantation of fetal parts was first proposed as being responsible for heterotopic uterine bone formation by Newton and Abel⁵ and this was supported subsequently by others⁶. Although this might be true in cases of second-trimester abortions, this theory cannot account for cases where abortion occurred in the very early stages of pregnancy, when no fetal bone tissue is present. In these cases, chronic inflammation and tissue destruction associated with repeated abortions may play a significant role in the pathogenesis of endometrial ossification, by producing a metaplastic change^{7,8}.

This may have been the case in our patient, who had a recent history of a spontaneous abortion at 25 weeks. Ultrasound examination plays a primary role in the diagnostic work-up of patients with osseous metaplasia. The characteristic hyperechogenic pattern is strongly suggestive of osseous tissue within the uterus, and should prompt confirmation by hysteroscopic examination. Several methods have resulted in successful treatment of osseous metaplasia, including D & C, hysterectomy and, recently, hysteroscopic treatment. However, in cases with extensive osseous metaplasia and bony sheets embedded in the myometrium, satisfactory hysteroscopic removal proves difficult. In such cases the utility of laparoscopic control during the procedure has been reported, resulting in greater accuracy and prevention of complications such as uterine perforation³. To our knowledge, ultrasound control of the hysteroscopic management of osseous metaplasia has been reported in the literature only as an additional aid to laparoscopy. However, in this report we show that the degree of visual control provided by combined transabdominal

and transrectal ultrasonography proves sufficiently accurate for hysteroscopic guidance. In expert hands, a clear visualization of the number, dimension and site of the bone spicules, as well as of the hysteroscopic instruments, can be obtained. The advantages of our approach include reduced invasiveness, reduced costs and simultaneous visualization of the abdominal and intrauterine cavities. In addition, the ultrasound guidance allows complete visualization of the whole thickness of the uterine wall, and therefore, as shown by our case, identification of bone fragments or other masses present within the myometrial layer, which are not detected by hysteroscopy, nor by laparoscopy. One limit, however, is represented by the greater operator dependence of ultrasound guidance as compared to laparoscopy, the former requiring extensive training of personnel and state-of-the-art equipment.

In conclusion, ultrasound guidance for hysteroscopic surgery represents a promising tool and may prove safer than laparoscopy; future clinical work is necessary to define the potential role of ultrasound guidance.

REFERENCES

1. Chervenak, F. A., Hussein, K. A. and Neuwirth, R. S. (1982). Symptomatic intrauterine retention of fetal bones. *Obstet. Gynecol.*, **59**, 585-615
2. Al-Shawaf, T., Brown, J. and Keegan, C. (1992). Retention of fetal bones 8 years following termination of pregnancy. *Ultrasound Obstet. Gynecol.*, **2**, 61-3
3. Bruce, D., Rodriguez, B. A. and Adamson, G. D. (1993). Hysteroscopic treatment of ectopic intrauterine bone. *J. Reprod. Med.*, **38**, 515-20
4. Virchow, R. (1884). Ueber Metaplasia. *Virchows Arch. Abt. Pathol. Anat.*, **97**, 410
5. Newton, C. W. III and Abel, M. R. (1972). Iatrogenic fetal implants. *Obstet. Gynecol. Surv.*, **46**, 686
6. Houlne, P., Kerneis, J. P., Michon, G. and Gordeef, A. (1958). Apropos d'un cas d'ossification de l'endocol uterin. *Comptes Rendus Soc. Française Gynecol.*, **28**, 467
7. Gerbie, A. B., Greene, R. R. and Reis, R. A. (1958). Heteroplastic bone and cartilage in the female genital tract. *Obstet. Gynecol.*, **83**, 573
8. Bhatia, N. N. and Hoshiko, M. G. (1982). Uterine osseous metaplasia. *Obstet. Gynecol.*, **60**, 256-9