



UNIVERSITÀ
DEGLI STUDI
FIRENZE

FLORE

Repository istituzionale dell'Università degli Studi di Firenze

Diagnosis of primary hyperparathyroidism: bias of imaging evaluation in the absence of accurate clinical evaluation

Questa è la Versione finale referata (Post print/Accepted manuscript) della seguente pubblicazione:

Original Citation:

Diagnosis of primary hyperparathyroidism: bias of imaging evaluation in the absence of accurate clinical evaluation / M.DeFeo; S.Colagrande; C.Biagini; L.Vaggelli; M.Serio; M.Brandi. - In: CLINICAL CASES IN MINERAL AND BONE METABOLISM. - ISSN 1724-8914. - STAMPA. - (2005), pp. 61-63.

Availability:

The webpage <https://hdl.handle.net/2158/355840> of the repository was last updated on 2016-06-09T11:23:30Z

Terms of use:

Open Access

La pubblicazione è resa disponibile sotto le norme e i termini della licenza di deposito, secondo quanto stabilito dalla Policy per l'accesso aperto dell'Università degli Studi di Firenze (<https://www.sba.unifi.it/upload/policy-oa-2016-1.pdf>)

Publisher copyright claim:

La data sopra indicata si riferisce all'ultimo aggiornamento della scheda del Repository FloRe - The above-mentioned date refers to the last update of the record in the Institutional Repository FloRe

(Article begins on next page)

Diagnosis of primary hyperparathyroidism: bias of imaging evaluation in the absence of accurate clinical evaluation

Maria Laura De Feo
Stefano Colagrande¹
Carlo Biagini
Luca Vaggelli²
Mario Serio
Maria Luisa Brandi³

Endocrine, ¹Radiology and ²Nuclear Medicine Units, Department of Clinical Physiopathology and ³Department of Internal Medicine, University of Florence, Florence, Italy

Address for correspondence:
Maria Luisa Brandi, M.D., Ph.D.
Department of Internal Medicine
University of Florence
Viale G. Pieraccini 6, 50139 Florence, Italy
Ph. +39 055 4296585
Fax +39 055 4296586
E-mail: m.brandi@dmi.unifi.it

KEY WORDS: hyperparathyroidism, ultrasound, scintigraphy.

Introduction

The diagnosis of primary hyperparathyroidism (pHPT) is based on the finding of normal/high blood calcium levels associated to inadequately high/normal parathyroid hormone (PTH) circulating levels. The majority of cases of pHPT are currently represented by asymptomatic/paucisymptomatic forms of the disease, with little or no progression (1). Moreover, pHPT is characterized by recurrent kidney stones and osteoporosis, disorders frequently observed in the normal population, independently from parathyroid diseases. Surgery is indicated in cases of symptomatic pHPT, while in mild forms of the disease a conservative approach may be chosen (2).

Imaging localization of enlarged parathyroid glands is used in the preoperative detection and spatial assessment of a pathologic parathyroid glands (3). When clinical and biochemical results do not fully support the diagnosis of pHPT, imaging studies may lead to false diagnosis.

In the present report we describe the clinical history of two patients suspected to be affected by pHPT, whose imaging data were superimposable, but final diagnosis was different.

Case 1

A 63-year-old woman was referred to the Mineral Metabolic Unit by her family doctor with a history of recurrent kidney stones and persistent pHPT, having previously undergone surgery on the basis of clinical and imaging findings suggesting the presence of a parathyroid adenoma.

In the past history of the patient, diagnosis of normocalcemic

symptomatic pHPT was made by her family doctor, which requested a scintigraphy with ⁹⁹Tc-MIBI and a neck-thoracic CT. Biohumoral data showed elevated circulating PTH (1-84) levels (88 pg/ml; N.V. = 10-70 pg/ml), normal blood total calcium (9.2 mg/dl; N.V. = 8.8-10.4 mg/dl) and increased urine calcium excretion (385 mg/die; N.V. = 100-300 mg/die). Hip and lumbar bone densities showed the presence of osteoporosis (neck BMD: T-score -2.5, lumbar BMD: T-score = -2.7); a previous exam (5 years earlier) showed the presence of osteopenia (lumbar T-score = -2.2).

The scintigraphy showed a large mediastinic non homogenous area of uptake visualized also in delayed (2 hours) images (Fig. 1b), suspecting the presence of pathologic parathyroid tissue. CT-scan confirmed the presence of a conspicuous mass (diameter 4x5x5 cm) in the mediastinum, with the upper extremity contiguous to the inferior pole of the right lobe of the thyroid gland (Fig. 1c). Post-contrastographic enhancement was very poor. Without hypotheses on the nature of the mass its localization well-matched with a pathologic ectopic parathyroid gland.

The patient underwent surgery for removal of the suspected parathyroid adenoma. At surgery, no evidence of pathologic PT gland(s) could be found and histopathology of the mass showed evidence of sarcoid lymphonodal mass, with persistent pHPT after surgery.

During a recent ultrasound (US) kidney evaluation, the radiologist examined the neck, where a large nodular lesion was found caudally to the inferior pole of the right lobe of the thyroid, extending into the anterior mediastinum, and its parathyroid origin was suggested (Fig. 1a).

A careful clinical evaluation led to the following data. The patient had no family history of kidney stones, osteoporosis, fractures or other related diseases. She underwent menopause when she was 54 year-old. A vague abdominal pain and depression were present for many years. The patient never complained of respiratory symptoms. She was not assuming any chronic medical therapy.

Biohumoral data showed absence of activation of the indexes of bone turnover. Routine blood and urine testing and creatinine clearance were in the normal range.

Measurement of blood and urine calcium on three different days on a diet containing 1 gr/day of calcium and 100 mEq/day of sodium, showed serum levels of ionized calcium in the normal range (4.5-4.7 mg/dl, N.V. = 4.2-5.3), total serum calcium in the low-normal range (8.7-9.2 mg/dl) and urinary calcium higher than normal (380-500 mg/day). Serum phosphorus levels were 3.5 mg/dl (N.V. = 2.5-4.5) with normal total serum protein (7.0 mg/dl; N.V. = 6-8) and modestly elevated circulating PTH levels (70-90 pg/ml). Both 25(OH) vitamin D and 1,25(OH)₂ vitamin D levels were in the normal range (respectively 22 ng/ml; N.V. = 12-55 ng/ml and 42 pg/ml; N.V. = 20-70 pg/ml). Urinary oxalate levels were normal.

Therefore, the results of the biohumoral exams did not confirm the suspect of pHPT, and primary hypercalciuria was considered the most likely cause of kidney stones, with increased bone loss and secondary hyperparathyroidism. Indeed, the presence of a mixed, absorptive and renal hypercalciuria was

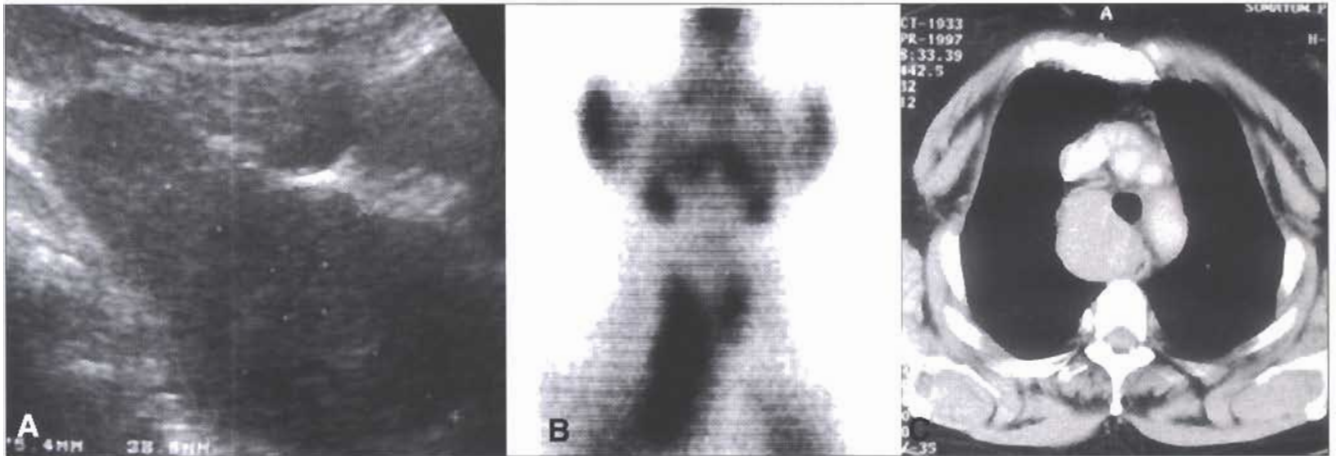


Figure 1 - Patient 1: sarcoidotic lymph node. A) Ultrasound: at the infrajugular right parasagittal site is present a scarcely echoic, huge mass with sharp edges. B) ⁹⁹Tc-MIBI Scintigraphy: image obtained 90 min after injection of the tracer; a "hot" spot is shown in the upper mediastinum-low neck. C) Computed tomography: on the right side of esophagus and trachea, a scarcely contrast- enhanced mass is present.

confirmed in this patient by specific testing and PTH circulating levels returned to normal after four months of appropriate medical therapy and dietary intervention.

Case 2

A 43 year old man was evaluated for a two year history of recurrent kidney stones with the suspect of pHPT. Measurement of blood and urine calcium in three different days on a diet containing 1 gr/day of calcium and 100 mEq/day of sodium showed circulating total calcium and PTH (1-84) levels at the upper limits (respectively, 10.4 and 10.8 mg/dl and 68 and 73 pg/ml). Blood levels of ionized calcium were frankly elevated (5.5-5.7 mg/dl, N.V. 4.2-5.3 mg/dl), serum phosphorus levels were low (1.9-2.2 mg/dl, N.V. = 2.5-4.5 mg/dl), and total serum protein levels were in the normal range. Urine calcium excretion was increased (450-530 mg/24 hr) and biochemical data showed activation of the indexes of bone turnover. Lumbar bone density showed the presence of osteoporosis (lumbar BMD: T-score = -2.63).

All the above data supported the diagnosis of normocalcemic symptomatic pHPT.

Imaging studies were requested in order to detect and define the morphovolumetric assessment of the pathologic PT gland(s), before surgical removal.

⁹⁹Tc-MIBI scintigraphy showed a mediastinic uptake area, also detected in delayed (2 hours) images (Fig. 2b). US and CT-scan demonstrated a 3.5x4x4 cm mediastinic mass contiguous to the inferior pole of the left lobe of the thyroid gland (Fig. 2a and 2c). Post-contrastographic CT-scan showed a strong enhancement. No hypotheses on the characterization of the mass were suggested, however, its localization was suitable with a pathologic ectopic parathyroid gland.

The patient underwent surgery for removal of the suspected parathyroid adenoma. Surgical and histopathologic data confirmed the presence of the parathyroid adenoma. Biochemical testing two and eight weeks after surgery, revealed normal PTH levels (50-45 pg/ml) with normocalcemia (9-9.3 mg/dl), normophosphoremia (3.8-4 mg/dl), and normocalciuria (240 and 200 mg/24 hours).

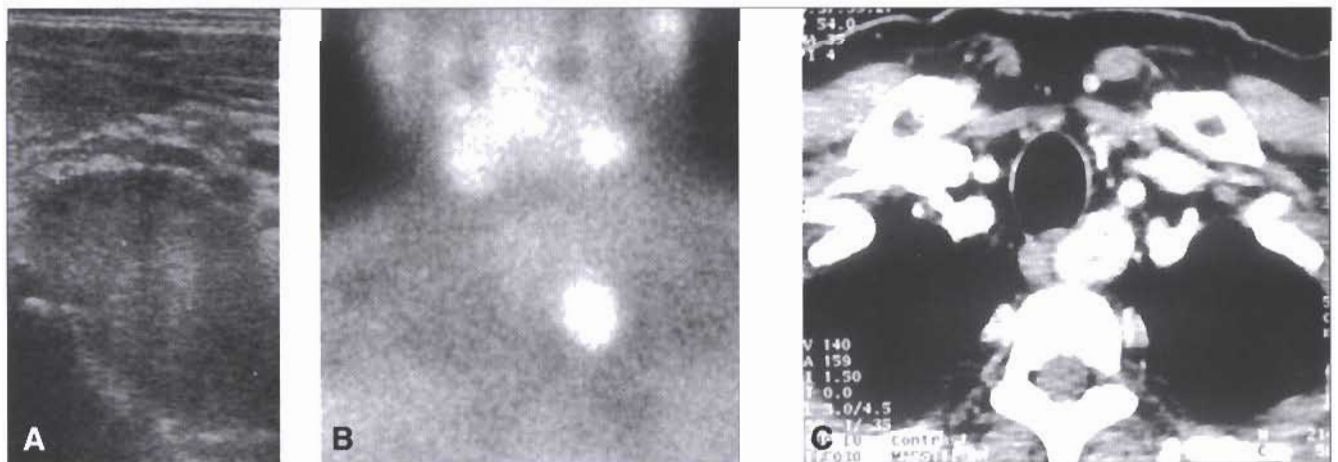


Figure 2 - Patient 2: parathyroid adenoma. A) Ultrasound: at the infrajugular left parasagittal site a scarcely echoic mass, with sharp edges is present. B) ⁹⁹Tc-MIBI Scintigraphy: image obtained 90 min. after injection of the tracer; a "hot" spot is shown in the left upper mediastinum-low neck. C) Computed tomography: a strongly contrast-enhanced spherical mass was visible in the left side of the esophagus between the trachea and a vertebral body.

Discussion

The diagnosis of pHPT is based on the finding of normal/high serum calcium levels inadequately associated to circulating PTH values at the upper limit or higher than normal (4). The clinical presentation of pHPT is variable, with asymptomatic/paucisymptomatic normocalcemic cases being now more frequent than classic symptomatic cases (1). The presence of depression and abdominal symptoms is often reported by these patients.

Modest increase in circulating PTH levels are a common finding in postmenopausal women due to widespread screening for menopausal osteoporosis. Often these PTH modifications reveal normocalcemic asymptomatic pHPT without specific indication for surgery.

Cases of pHPT with recurrent kidney stones often show serum total calcium levels in the upper limit of normal (10.0 and 10.5 mg/dl), high ionized calcium levels, modest increases of PTH, and hypercalciuria. The finding of modest increases of circulating PTH in the presence of normal ionized calcium and total serum calcium level in the low-normal range is not indicative for pHPT. The presence of hypercalciuria suggests the possibility of idiopathic hypercalciuria (IH).

The diagnosis of pHPT relies only on clinical and laboratory data, even though often pHPT patients are referred to specialized Centers with poor clinical and biochemical evaluation, but with an unnecessary and expensive imaging documentation. Indeed, imaging studies have a primary role only in the presurgical detection and spatial assessment of a pathologic parathyroid tissue.

Imaging of pathologic parathyroid nodules can be difficult due to the differences in size (from undetectable by US, CT or MR techniques to large nodules) and the variability in the location of the glands in the neck or mediastinum (due to the embryologic origin). Moreover, the presence of nodules in the neck is a common finding during routine US examination, and the imaging techniques currently available cannot provide specific diagnostic criteria useful for the recognition of parathyroid tissue (3). The combination of US and dual phase ^{99m}Tc -MIBI, both having a high sensitivity and specificity, leads to an improvement of sensitivity, negative predictive value, and accuracy, with no decrease of the high specificity and positive predictive value with respect to each single technique (4). In fact, scintigraphic positivity is able to clarify the cases of lack of US characterization, while US is able to detect small glands that can be missed by scintigraphy due to small dimensions, low metabolic activity or presence of necrotic or cystic areas. It is important to emphasize that dual phase ^{99m}Tc -MIBI scintigraphy has high (4-6) accuracy in differentiating thyroid vs parathyroid nodules. However, ^{99m}Tc -MIBI scintigraphy can be considered a generic "cellular activity marker" and its positivity can be due to many pathologies such as mammary cancer, lymphomas, flogistic lymph nodes, and Hurtle cell adenoma (5). On the other hand US and CT provide high sensitivity in locating the pathologic glands also if ectopic (neck and mediastinum). A strong enhancement on post-contrastographic CT, indicating the presence of a high vascularity is present only in some cases of PT pathologic glands and nodules of different

nature can exhibit similar enhancement ratio. Therefore the intensity of CT enhancement cannot be considered an unambiguous characterization criteria for parathyroid enlarged gland. On the basis of these considerations imaging procedure, while representing a fundamental tool for the surgeon, can lead to wrong diagnostic conclusions when clinical and laboratory data are not evaluated by experienced specialists in Mineral Metabolism.

Patient 1 is a clear example of these limitations. In fact, a history of recurrent kidney stones with hypercalciuria, high PTH levels, osteoporosis, depression and abdominal pain could be evocative of pHPT. However, the absence of increased serum ionized calcium levels associated to normal phosphorus and total calcium level in the low-normal range in a patient suffering from renal stones for the past 25 years has to pose the suspect of IH. In this condition PTH increase is secondary to hypercalciuria which causes kidney stone disease and osteoporosis (7,8). The information derived from imaging techniques did not help the primary care physician to reach a correct diagnosis. On the contrary the recognition of a mediastinal mass led to major thoracic surgery for a sarcoidotic lymph node, that could have been treated conservatively.

In patient 2 the clinical and laboratory data showed an unequivocal diagnosis of symptomatic pHPT, as indicated by high circulating ionized calcium levels and inappropriately elevated PTH levels. In this case imaging findings guided the surgeon to the ablation of pathologic PT tissue.

In conclusion, the diagnosis of pHPT must be based on clinical and laboratory data. Imaging studies do not add useful diagnostic information, having, however, a role in the presurgical detection of enlarged parathyroid gland(s). The use of imaging studies to clear doubts in clinical diagnosis of pHPT may indeed lead to wrong therapeutical choices.

References

1. Marx SJ. Hyperparathyroid and hypoparathyroid disorders. *The New England Journal of Medicine*. 2000;343:1863-1875.
2. Clark OH. Asymptomatic primary hyperparathyroidism: is parathyroidectomy indicated? *Surgery*. 1994;116:947-953.
3. Weber AL, Randolph G, Aksoy FG. The thyroid and parathyroid glands. CT and MR imaging and correlation with pathology and clinical findings. *Radiology Clinics North America*. 2000;38:1105-1129.
4. De Feo ML, Colagrande S, Biagini C, Tonarelli A, Bisi G, Vaggelli L, Borrelli D, Cicchi P, Tonelli F, Amorosi A, Serio M, Brandi ML. Parathyroid glands: combination of ^{99m}Tc MIBI scintigraphy and US for demonstration of parathyroid glands and nodules. *Radiology*. 2000;214:393-402.
5. Taillefer R. ^{99m}Tc Sestamibi Parathyroid Scintigraphy. *Nuclear Medicine Annual 1995*, New York, Raven Press, 55-79.
6. Giordano A, Rubello D, Casara D. New trends in parathyroid scintigraphy. *European Journal of Nuclear Medicine*. 2001;28:1409-1420.
7. Weisinger JR, Alonzo E, Carlini RG, Paz-Martinez V, Martinis R, Bellorin-Font E. Bone disease in hypercalciuria: a new form of osteodystrophy? *Nephrology Dialysis Transplantation*. 1998;13:88-90.
8. Adams JS, Song CF, Kantorovich V. Rapid recovery of bone mass in hypercalciuric, osteoporotic men treated with hydrochlorothiazide. *Annals of Internal Medicine*. 1999;130:658-660.