



UNIVERSITÀ
DEGLI STUDI
FIRENZE

FLORE

Repository istituzionale dell'Università degli Studi di Firenze

Vascular and connective tissue features in 5 italian patients with homocystinuria

Questa è la Versione finale referata (Post print/Accepted manuscript) della seguente pubblicazione:

Original Citation:

Vascular and connective tissue features in 5 italian patients with homocystinuria / Evangelisti L; Lucarini L; Attanasio M; Porciani MC; Romano E; Prisco D; Gensini G; Abbate R; Pepe G. - In: INTERNATIONAL JOURNAL OF CARDIOLOGY. - ISSN 0167-5273. - STAMPA. - 134:(2009), pp. 251-254.

Availability:

This version is available at: 2158/369052 since:

Terms of use:

Open Access

La pubblicazione è resa disponibile sotto le norme e i termini della licenza di deposito, secondo quanto stabilito dalla Policy per l'accesso aperto dell'Università degli Studi di Firenze (<https://www.sba.unifi.it/upload/policy-oa-2016-1.pdf>)

Publisher copyright claim:

(Article begins on next page)

Vascular and connective tissue features in 5 Italian patients with homocystinuria

Lucia Evangelisti^{a,*}, Laura Lucarini^a, Monica Attanasio^a, Maria Cristina Porciani^a,
Eloisa Romano^a, Domenico Prisco^a, Gian Franco Gensini^{a,b},
Rosanna Abbate^a, Guglielmina Pepe^a

^a Department of Medical and Surgical Critical Care, University of Florence; Regional Marfan Centre, Azienda Ospedaliero-Universitaria Careggi, Florence; Center for the Study at Molecular and Clinical Level of Chronic, Degenerative and Neoplastic Disease to Develop Novel Therapies, University of Florence, Florence, Italy

^b Fondazione Don Carlo Gnocchi ONLUS, Centro S. Maria agli Ulivi-IRCCS, Florence, Italy

Received 20 September 2007; accepted 11 December 2007

Available online 15 February 2008

Abstract

Homocystinuria is a metabolic disorder associated with defects in genes encoding for methionine metabolism enzymes. Vascular and connective tissue manifestations such as deep venous thrombosis, ectopia lentis and skeletal alterations are the major clinical features.

We investigated the clinical manifestations of 5 Italian homocystinuric patients, performed mutation screening analysis on cystathionine beta-synthase (CBS) gene and searched for genotype/phenotype correlations.

We detected mild cardiovascular and skin connective tissue stigmas in these patients, never reported in homocystinuric patients before. We found 1 novel and 7 known mutations. Our patients carried no other mutation associated with venous thrombosis. Our data stress the importance of extending the clinical investigation for connective tissue manifestations in homocystinuric patients to all the organs/systems involved in Marfan syndrome, also suggesting long term follow-ups for cardiovascular manifestations.

© 2008 Elsevier Ireland Ltd. All rights reserved.

Keywords: Connective tissue manifestations; CBS gene; Homocystinuria; Vascular clinical manifestations

Homocystinuria (MIM# 236200) is a rare metabolic disorder (1:344.000) mainly due to cystathionine beta-synthase (CBS) deficiency which causes increased urinary homocysteine (Hcy) and methionine excretion [1]. Major clinical manifestations involve eyes, skeleton, central nervous and vascular systems. Ocular and skeletal manifestations are shared by both homocystinuria and Marfan syndrome (MFS) patients, while aortic dilatation and valve prolapse and regurgitation, have been reported only in Marfan patients.

Patients are diagnosed during infancy, mostly after the onset of ectopia lentis (EL) [1,2], or because of venous thrombosis in later age. The homotetramer CBS (EC 4.2.1.22; chr.21q22.3) (Fig. 1), enzyme in the transsulfuration pathway, converts the potentially toxic Hcy into cysteine [3]. A continuously updated CBS website (http://www.uchsc.edu/sm/cbs/cbs_data/cbsmain.htm) lists 140 mutations in 624 patient alleles [4]. Homocystinuria can also be due to mutations in 5–10, Methylenetetrahydrofolate reductase (MTHFR;

MIM#236250)[5], methionine synthase reductase (MTRR) [6] and methionine synthase (MTR)[7] genes.

We investigated 5 homocystinuric Italian patients and an echocardiographic study/examination was performed according to the guidelines of the American Society of Echocardiography [8]. Controls were selected among apparently healthy Italian subjects with no history of sudden death, without venous thrombosis, cardiovascular, skeletal or eyes Marfan or homocystinuric manifestations. Biochemical and genetic factors predisposing to thrombotic events were evaluated as previously reported [9–12]. Genomic DNA mutation analysis of CBS gene (Table 1) was performed [13].

Clinical characteristics and molecular data of the 5 patients (4 males and 1 female) are shown in Table 2. In 3 cases (Pts #1,3,4) the diagnosis was made after the first thrombotic event, in the other 2 cases (Pts#1,5) upon detection of EL.

All values for biochemical and genetic factors turned out to be in a normal range except for the following: two individuals who were homozygous for MTHFR: c.677C>T(Pt#3) and c.1298A>G(Pt#1); 2 were heterozygous for: MTRc.2756A>G (Pt#5) and MTHFRc.1298A>G(Pt#4); only one was double heterozygote for MTRc.2756A>G and MTHFRc.677C>T (Pt#2).

We found 6 heterozygous missense mutations (p.Pro49-Leu, p.Arg125Gln, p.Ile278Thr, p.Ala157Pro, p.Gly307Ser,

* Corresponding author. Department of Medical and Surgical Critical Care, University of Florence; Viale Morgagni 85, 50134 Florence, Italy. Tel.: +39 055 7949420; fax: +39 055 7949418.

E-mail address: lucia.evangelisti@gmail.com (L. Evangelisti).

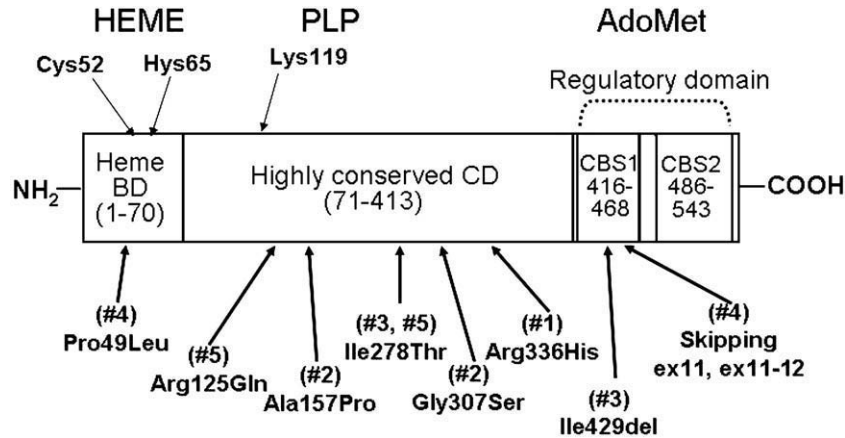


Fig. 1. The protein domains of human CBS. In the upper side are the binding sites for Heme, pyridoxal 5'-phosphate (PLP) and *S*-adenosyl-L-methionine (AdoMet). In the lower side the mutations described in this paper together with the identification number of patients are reported. (BD: Binding Domain; CD: Catalytic Domain).

p.Arg336His); 1 in frame deletion (p.Ile429del), 1 mRNA splicing mutation that alters intron 12 splice donor site (c.1357+1G>A).

Table 1
Primers used for mutation screening analysis of the human *cbs* gene.

Exon	name	Sequence (5'→3')	Size (bp)	Annealing temperature [°C]	Number of cycles
1	1S	ggAACCCACAgCATCCgA	311	62	40
	1AS	ggTTATggATCAGCCCTCTT			
2	2S	TgTCTgCCAagggCTggTAC	272	60	35
	2AS	CCTTgCCTAAagggATCCATC			
3	3S	AAgCCcgTCCCCACCCCT	338	64	35
	3AS	ATgCggCTgCAGCTCAGC			
4+5	4S	AACCggCATCggggTgTgC	450	64	35
	5AS	CCgAgACCCTCCTAggggAAT			
6	6S	CACCTggggCCTggAgAC	232	66	35
	6AS	TACACTCCCAGgCAGCCAg			
7	7S	gCAACgAggggCTgCTCCAA	309	62	40
	7AS	ACAgCTTTCAGCTCAGAAgC			
8	8S	AggCAGTTgTTAAagggCggT	319	62	40
	8AS	TTggggCCCagggTCAgC			
9	9S	TCTggggTCCTACCCgCCTA	291	62	40
	9AS	TgCAGgTCggTggCTgACT			
10	10S	gACATgCTCCCATgCgTgC	279	62	40
	10AS	Kruger at al 2003			
11	11S	AgCACTTgggggTCTCTgC	298	62	35
	11AS	AgggCCAgCACAggCCAC			
12	12S	ggTCCCTgTggCCTCCTg	297	64	40
	12AS	gTgACACTgACGgggTggA			
13	13S	CAGAgAgCgCTCCTCCCTg	267	66/64/62	3/3/32
	13AS	CCTgTTTgAgCTgCCTgTAGg			
14	14S	TCCCAGgTTCggCTgCCAC	280	64	40
	14AS	CATggCAGAggCAAggCCTT			
15	15S	gAgTTgggAggggCCTg	258	62	35
	15AS	AggACCCTggAAggCCTC			
16	16S	CgCAGCAGCCACCCAgC	236	62	40
	16AS	TAgggCTCAGgAAAgCgAAG			
17	17S	gTCTCCCCTgTTAACACAT	281	64	40
	17AS	CAAACgCTCCgCCAgC			

Patient #2 leads the novel c.469G>C nucleotide CBS substitution in exon 4 corresponding to the p.Ala157Pro change localized in a highly conserved region (catalytic domain) at the dimer interface of the tetrameric protein structure. We found c.469G>C mutation in 3 out of 300 controls, so by definition this mutation has to be considered as a polymorphism. Moreover, this substitution would induce a bend in the protein structure but its pathogenic role remains to be defined for the relatively high frequency in controls (1%). Alternatively, a second mutation could be present in the promoter region not investigated.

Patient #3 leads another mutation, carried by an Argentinean patient [14], recently published on-line that consists in a deletion of three nucleotides (c.1286_1288delTCA) causing a deletion of amino acid Ile429, the mutation being positioned in a non conserved domain. This mutation, however, is not present in 50 South American [14] and 300 Italian controls (this report).

The other 6 mutations are already reported in the database as pathogenic mutations.

The parents of patient #5 underwent hcy dosage and CBS mutation analysis. The father carried mutation p.Ile278Thr and mildly increased hcy level (23 $\mu\text{mol/L}$; n.v. < 19) while the mother, presenting mutation p.Arg125Gln, had normal hcy levels (9.8 $\mu\text{mol/L}$; n.v. < 13), both in heterozygous state.

Eight polymorphisms, 5 novel and 3 already published in the CBS database, were found (Table 2).

In our patients we detected heart and skin manifestations never reported in homocystinuric patients such as mild heart valve prolapse and/or regurgitation, and striae distensae suggesting, for the first time, that these patients can develop cardiovascular manifestations.

MacLean et al. [15] suggested that clinical homocystinuric manifestations related to the connective tissue may be correlated to the decrease of CBS production causing both an increase of hcy levels and a decrease of cysteines. The decrease of cysteines may affect the qualitative and quantitative synthesis of connective tissue proteins causing EL and other connective tissue manifestations. This hypothesis is

Table 2

Clinical data, heterozygous CBS mutations, polymorphisms of CBS and other genes implicated in the hcy metabolism found in 5 homocystinuric patients.

ID ^o	Age of presentation (EL or venous thrombosis)/age of diagnosis	Sex/age	Clinical manifestations					tHcy $\mu\text{mol/L}$	Location of Mutations and polymorphisms in CBS and in other metabolism hcy genes (exon, Nucleotide change, Aminoacid Change, type of mutation)
			Vascular involvement	Cardiac involvement	Eye involvement	Skeletal involvement	Other features		
1	15/30	M/30	DVT	No involvement	–Ectopia lentis –Myopia	–Kyphoscoliosis –Pectus excavatum	Striae	193.6	Exon9, c.9852G>A, p.Arg336His, Missense Exon6, c.6955C>T (0.65/0.35), p.Tyr233Tyr, SNP IVS11, c.1224+141G>A Novel IVS12, c.1358-30C>T (0.76/0.24) SNP IVS13, c.1467+32A>G Novel MTHFR c.1298 ^a >G (GG)
2	16/16	M/21	No involvement	–Mitral valve prolapse with mild valvular regurgitation* –Tricuspid valve prolapse§ –Moderate pulmonary valve regurgitation	–Myopia –Iridodonesis	–Osteochondrosis –Pectus excavatum –Kyphoscoliosis –Mild elbow valgus –Arachnodactyly	Striae	196	Exon 4, c.6516G>C, p.Ala157Pro, Missense novel Exon 8, c.9208G>A, p.Gly307Ser, Missense IVS13, c.1467+32A>G Novel MTR c.2756A>G (AG) MTHFR c.677C>T (CT)
3	14/36	M/44	DVT 3 superficial venous thrombosis	–Mitral valve prolapse with mild valvular regurgitation*	No involvement	–Pectus excavatum –Arachnodactyly	Striae	222	Exon 8, c.9122T>C, p.Ile278Thr, Missense Exon 12, c.1286_1288delTCA, p.Ile429del, Splice IVS3, c.451+30A>G Novel Exon 6, c.6955C>T (0.65/0.35), p.Tyr233Tyr, SNP Exon 10, c.11686C>T (0.55/0.45) SNP IVS12, c.1358-30C>T (0.76/0.24) SNP IVS13, c.1467+32A>G Novel MTHFR c.677C>T (TT)
4	15/24	M/30	DVT With pulmonary embolism	–Mitral valve prolapse with mild regurgitation* –Tricuspid valve prolapse with mild regurgitation§ –mild pulmonary valve regurgitation	–Myopia –Iridodonesis	–Pectus excavatum –Mild kyphoscoliosis –Arachnodactyly –Flatfoot –Armspan>Height	Striae	229	Exon 1, c.146C>T, p.Pro49Leu, Missense IVS12, c.1357+1G>A Missense, Exon12 skipping IVS13, c.1467+32A>G Novel IVS13, c.1467+38A>G Novel MTHFR c.1298A>G (AG)
5	4/22	F/27	No involvement	–Mild mitral valve prolapse*	–Myopia –Ectopia lentis	–Pectus carenatum	Striae Varicose vein	342	Exon 3, c.5873G>A, p.Arg125Gln, Missense Exon 8, c.9122T>C, p.Ile278Thr, Missense MTR c.2756A>G (AG)

DVT: deep vein thrombosis; SNP: single-nucleotide polymorphism; IVS: intron variable sequence; *=[18]; §=[19].

based on the association of connective tissue alterations with a group of missense mutations located in the CBS C-terminal region and affecting the domain interacting with *S*-adenosylmethionine (AdoMet), so an increase of AdoMet cannot further stimulate CBS production. Our 2 patients with a mutation in CBS regulatory domain, carried mild cardiovascular, skeletal and cutaneous stigmas, confirming the MacLean's hypothesis [15]. Overall, the presence of a mild connective tissue involvement, including heart valve alterations and striae distensae in all 5 patients, suggests that the connective tissue pathology in homocystinuria is relevant in relation to the cardiovascular manifestations which may become more severe with aging. Recently Hubmacher et al. [16] demonstrated that high Hcy levels in homocystinuric patients can modify fibrillin-1 via disulfide bonds by rendering protein domains significantly more susceptible to proteolytic degradation. This impairment could cause the clinical manifestations, overlapping with MFS, present in these patients. These results support our hypothesis on the pathological molecular mechanism underlying the association between c.677C>T homozygous MTHFR polymorphism, mild homocysteinemia and more severe aortic manifestations in Marfan syndrome [17] thus strengthening the link between increased Hcy and damage to connective tissue proteins rich in cysteines, as fibrillin 1.

Our data emphasizes the importance of extending the clinical investigation for connective tissue manifestations present in Marfan syndrome to homocystinuric patients. Moreover, the detection of cardiovascular manifestations suggests long term follow-ups for each patient.

Acknowledgements

We wish to thank the patients and their families for their collaboration.

References

- [1] Mudd SH, Skovby F, Levy HL, et al. The natural history of homocystinuria due to cystathionine beta-synthase deficiency. *Am J Hum Genet* 1985;37(1):1–31.
- [2] Cruysberg JR, Boers GH, Trijbels JM, Deutman AF. Delay in diagnosis of homocystinuria: retrospective study of consecutive patients. *BMJ* 1996 Oct 26;313(7064):1037–40.
- [3] Scott JW, Hawley SA, Green KA, et al. CBS domains form energy-sensing modules whose binding of adenosine ligands is disrupted by disease mutations. *J Clin Invest* 2004;113(2):274–84.
- [4] Meier M, Oliveriusova J, Kraus JP, Burkhard P. Structural insights into mutations of cystathionine beta-synthase. *Biochim Biophys Acta* 2003;1647(1–2):206–13.
- [5] Goyette P, Frosst P, Rosenblatt DS, Rozen R. Seven novel mutations in the methylenetetrahydrofolate reductase gene and genotype/phenotype correlations in severe methylene tetrahydrofolatereductase deficiency. *Am J Hum Genet* 1995;56(5):1052–9.
- [6] Zavadakova P, Fowler B, Zeman J, et al. CblE type of homocystinuria due to methionine synthase reductase deficiency: clinical and molecular studies and prenatal diagnosis in two families. *J Inherit Metab Dis* 2002;25(6):461–76.
- [7] Watkins D, Ru M, Hwang HY, et al. Hyperhomocysteinemia due to methionine synthase deficiency, cblG: structure of the MTR gene, genotype diversity, and recognition of a common mutation, P1173L. *Am J Hum Genet* 2002;71(1):143–53.
- [8] Sahn DJ, DeMaria A, Kisslo J, et al. Recommendations regarding quantitation in M-mode echocardiography: results of a survey of echocardiographic measurements. *Circulation* 1978;58:1072–83.
- [9] Gori AM, Sofi F, Corsi AM, et al. Predictors of vitamin B6 and folate concentrations in older persons: the InCHIANTI study. *Clin Chem* 2006 Jul;52(7):1318–24.
- [10] Marcucci R, Alessandrello Liotta A, Cellai AP, et al. Cardiovascular and thrombophilic risk factors for idiopathic sudden sensorineural hearing loss. *J Thromb Haemost* 2005;3(5):929–34.
- [11] Marcucci R, Bertini L, Giusti B, et al. Thrombophilic risk factors in patients with central retinal vein occlusion. *Thromb Haemost* 2001;86(3):772–6.
- [12] Frusconi S, Giusti B, Rossi L, et al. Improvement of low-density microelectronic array technology to characterize 14 mutations/single-nucleotide polymorphisms from several human genes on a large scale. *Clin Chem* 2004;50(4):775–7.
- [13] Giusti B, Lucarini L, Pietroni V, et al. Dominant and recessive COL6A1 mutations in Ullrich scleroatonic muscular dystrophy. *AnnNeurol* 2005;58(3):400–10.
- [14] Urreiziti R, Asteggiano C, Bermudez M, et al. The p.T191M mutation of the CBS gene is highly prevalent among homocystinuric patients from Spain, Portugal and South America. *J Hum Genet* 2006;51(4): 13–5 305.
- [15] Maclean KN, Gaustadnes M, Oliveriusova J, et al. High homocysteine and thrombosis without connective tissue disorders are associated with a novel class of cystathionine beta-synthase (CBS) mutations. *Hum Mutat* 2002;19(6):641–55.
- [16] Hubmacher D, Tiedemann K, Bartels R, et al. Modification of the structure and function of fibrillin-1 by homocysteine suggests a potential pathogenetic mechanism in homocystinuria. *J Biol Chem* 2005;280(41):34946–55.
- [17] Giusti B, Porciani MC, Brunelli T, et al. Phenotypic variability of cardiovascular manifestations in Marfan Syndrome. Possible role of hyperhomocysteinemia and C677T MTHFR gene polymorphism. *Eur Heart J* 2003;24(22):2038–45.
- [18] Freed LA, Levy D, Levine RA, et al. Prevalence and clinical outcome of mitral-valve prolapse. *N Engl J Med* 1999 Jul 1;341(1):1–7.
- [19] Brown AK, Anderson V. Two dimensional echocardiography and the tricuspid valve. Leaflet definition and prolapse. *Br Heart J* 1983 May;49(5):495–500.