



UNIVERSITÀ
DEGLI STUDI
FIRENZE

FLORE

Repository istituzionale dell'Università degli Studi di Firenze

Seladin-1 and testicular germ cell tumours: new insights into cisplatin responsiveness.

Questa è la Versione finale referata (Post print/Accepted manuscript) della seguente pubblicazione:

Original Citation:

Seladin-1 and testicular germ cell tumours: new insights into cisplatin responsiveness / N.Nuti; P.Luciani; E.Marinari; E.Erdei; M.Bak; C.Deledda; F.Rosati; B.Mazzinghi; G.Danza; H.Stoop; L.Looijenga; A.Peri; M.Serio; C.Krausz. - In: JOURNAL OF PATHOLOGY. - ISSN 0022-3417. - STAMPA. - 219:(2009), pp. 491-500.

Availability:

The webpage <https://hdl.handle.net/2158/376191> of the repository was last updated on 2019-07-23T09:12:07Z

Terms of use:

Open Access

La pubblicazione è resa disponibile sotto le norme e i termini della licenza di deposito, secondo quanto stabilito dalla Policy per l'accesso aperto dell'Università degli Studi di Firenze (<https://www.sba.unifi.it/upload/policy-oa-2016-1.pdf>)

Publisher copyright claim:

La data sopra indicata si riferisce all'ultimo aggiornamento della scheda del Repository FloRe - The above-mentioned date refers to the last update of the record in the Institutional Repository FloRe

(Article begins on next page)

Original Paper

Seladin-1 and testicular germ cell tumours: new insights into cisplatin responsiveness

Francesca Nuti,¹ Paola Luciani,² Eliana Marinari,¹ Edit Erdei,³ Mihaly Bak,⁴ Cristiana Deledda,² Fabiana Rosati,² Benedetta Mazzinghi,⁵ Giovanna Danza,² Hans Stoop,⁶ Leendert HJ Looijenga,⁶ Alessandro Peri,² Mario Serio² and Csilla Krausz^{1*}

¹Andrology Unit, University of Florence, Italy

²Endocrine Unit, University of Florence, Italy

³National Institute of Health, Andrology Division, Budapest, Hungary

⁴National Institute of Oncology, Budapest, Hungary

⁵Excellence Center for Research, Transfer and High Education DENOthe, University of Florence, Italy

⁶Department of Pathology, Josephine Nefkens Institute, Erasmus MC-University Medical Center, Rotterdam, The Netherlands

*Correspondence to:

Csilla Krausz, Department of Clinical Physiopathology, Andrology Unit, University of Florence, Viale Pieraccini 6, 50139 Florence, Italy.
E-mail: c.krausz@dfc.unifi.it

No conflicts of interest were declared.

Abstract

The molecular basis for the exquisite sensitivity of testicular germ cell tumours of adolescents and adults (TGCTs), ie seminomas and non-seminomatous germ cell tumours, to chemo/radiotherapy has not been fully clarified so far. It has been suggested that it may be dependent on factors involved in the regulation of apoptosis. Seladin-1 is a multi-functional protein involved in various biological processes, including apoptosis. The aim of our study was to assess the expression of seladin-1 in different histological types of TGCTs, known to have varying treatment sensitivity, in order to establish whether this protein may influence cisplatin responsiveness *in vitro*. Seladin-1 expression levels, both at the mRNA and at the protein level, were higher in the adjacent normal parenchyma than in the pathological counterparts. In tumoural tissues, the level of expression differed among TGCT histological types. The highest tumour-expression level was found in teratoma, whereas the lowest was detected in seminoma, corresponding to the different chemo/and radiosensitivities of these tumour types. In common with other cancers, in TGCT-derived cell lines seladin-1 showed anti-apoptotic properties through inhibition of caspase-3 activation. We confirmed our results using a non-seminomatous cell line model (NT2) before and after differentiation with retinoic acid. Significantly higher seladin-1 expression was observed in the differentiated derivatives (teratoma) and an inverse relationship was found between seladin-1 expression and the amount of cleaved caspase-3. Seladin-1 silencing or overexpression in this cell line supports involvement of seladin-1 in cisplatin responsiveness. Seladin-1 silencing was associated with greater cisplatin responsiveness demonstrated by decreased cell viability and increased expression of apoptotic markers. In contrast, overexpression of seladin-1 was associated with a higher survival rate and a clear anti-apoptotic effect. In conclusion, we have demonstrated for the first time an important role for seladin-1 in the biology of TGCTs and provided new insights into cisplatin responsiveness of these tumours.

Copyright © 2009 Pathological Society of Great Britain and Ireland. Published by John Wiley & Sons, Ltd.

Keywords: TGCT; testicular cancer; seladin-1; cisplatin; male infertility; apoptosis

Received: 19 December 2008

Revised: 10 July 2009

Accepted: 2 September 2009

Introduction

TGCTs (testicular germ cell tumours of adolescents and adults) are the most frequently occurring tumours in young men, with a peak of incidence between the ages of 15 and 34 years. They account for up to 60% of all malignancies diagnosed at this age, with an incidence of 6–7 per 100 000 men. Despite a high cure rate, TGCTs represent the most frequent cause of death from solid tumours in this age group and show an annual increase in incidence of 2–5% [1]. TGCTs are a heterogeneous group of neoplasms derived from

the germ cell lineage [2–4] and usually occurring within the gonads. Based on histological, biochemical, and clinical characteristics, TGCTs are divided into seminomas and non-seminomatous tumours [5]. Seminomas are composed of uniform tumour cells, resembling primordial germ cells/gonocytes [6,7]. In contrast, non-seminomatous TGCTs may contain one or more histological subtypes, representing various differentiation lineages and stages of embryonic development. Embryonal carcinoma cells form the stem cell component and are able to differentiate towards extra-embryonic tissues (yolk-sac carcinoma

and choriocarcinoma) or embryonic tissues (immature and mature teratoma) [8,9]. The rapid growth and progression of TGCTs cause early lymph node metastases and/or distant metastases. About 25% of seminoma patients [10] and up to 60% of non-seminomatous patients have metastatic disease at the time of diagnosis [11–13].

Seminomas are radio- and chemo-sensitive tumours, virtually completely curable at each stage [14]. Non-seminomatous TGCTs are usually treated with surgery and chemotherapy, with varying cure rates depending on the disease stage and histological composition [15]. The cure rate is close to 99% in the early stages, whereas it may be as low as 50% in advanced disease stages with a poor prognosis. Therefore, despite the fact of successful treatment of TGCTs with cisplatin-based combination chemotherapy, 10–20% of patients diagnosed with metastatic disease will not achieve a sustained complete remission after initial treatment, due either to incomplete response or to tumour relapse [16,17].

The molecular basis for the exquisite sensitivity of TGCTs to cisplatin is not yet known and a number of hypotheses have been suggested [18]. Among them, an attractive hypothesis is that TGCTs are so readily curable because of a low threshold for induction of apoptosis. However, studies published so far on this topic have yielded contradictory results [18] and encourage further research in this direction. For example, the expression of the anti-apoptotic protein seladin-1 (selective Alzheimer's disease indicator-1) in the different histological types of TGCT is unknown so far, but might be of interest.

Seladin-1, encoding 3 β -hydroxysterol Δ 24-reductase (DHCR24) [19], catalyses the reduction of the Δ 24 double bond in desmosterol to produce cholesterol, which is down-regulated in brain regions affected by Alzheimer's disease [20]. Expression of seladin-1 is widespread in human tissues [20], with the highest levels being observed in the adrenal gland, prostate, lung, and fetal liver. In addition, seladin-1 is expressed in the brain and in various endocrine organs, such as adrenal cortex [21–24], testis, and ovary [20,22,25]. Seladin-1 effectively inhibits caspase-3 activity, a key mediator of apoptosis, and protects neuronal cells from apoptotic death [20,26,27], thus suggesting its involvement in the regulation of cell survival and death.

Seladin-1 expression has been investigated in different tumours including adrenal gland, prostate, ovarian, and pituitary tumours, and melanomas [21,23–25, 28–30]. In some of these tumours seladin-1 is over-expressed, whereas in others it is reduced compared with the corresponding normal tissue. A potential role for seladin-1 in the metastatic process has been observed in prostate cancer [29,30] and in melanoma [28]. High levels of seladin-1 in prostate cancer tissues are associated with local invasiveness and disease recurrence [30], whereas in melanoma seladin-1 expression is up-regulated in metastases compared

with primary tumours, thus suggesting a role for this protein in tumour progression.

Seladin-1 is highly expressed in the normal testis, probably due to the presence of steroid-producing cells [20]. However, it is unknown whether seladin-1 plays any role in germ cells or if it is involved in the pathogenesis of germ cell-derived tumours. In order to obtain further insights into the biology of TGCTs, we recorded the expression pattern of seladin-1 in different TGCTs and in a related cell line model (NT2). Furthermore, we investigated the role of this protein in cisplatin responsiveness, by modulating its expression levels in this cell line.

Materials and methods

Patients

Thirty-four patients undergoing surgery for TGCTs ($n = 8$ seminomas, $n = 4$ teratomas, $n = 4$ embryonal carcinomas, $n = 4$ choriocarcinomas, $n = 4$ mixed embryonal carcinomas and seminomas, $n = 6$ mixed embryonal carcinomas and teratomas, and $n = 4$ mixed embryonal carcinomas and choriocarcinomas) were included in this study. From each patient, tissue from the tumour and from the tumour-free, normal parenchyma was immediately frozen in liquid nitrogen and stored at -80°C , pending RNA and protein extraction. It is worth noting that the tumour-free parenchyma was not atrophic. However, we cannot exclude differences in the number of intratubular germ cells among different subjects. Therefore, the term 'normality' as used here indicates the absence of tumour or the precursor lesion, and not necessarily the presence of normal spermatogenesis.

Cell culture and differentiation

NTERA-2 cl.D1 [NT2/D1] or NT2 cells, a pluripotent human embryonal carcinoma cell line, was kindly provided by Dr LHJ Looijenga. NT2 cells were cultured in monolayer as described previously in DMEM (4.5 g/l glucose, sodium pyruvate, and glutamax) supplemented with 10% FBS (Hyclone), penicillin/streptomycin (Sigma-Aldrich). NT2 cells differentiate upon treatment with all-*trans* retinoic acid (RA) and begin to show a neuronal morphology after 4 weeks of 10 μM RA treatment [31].

Induction of apoptosis by cisplatin

NT2 cells were treated with 10 μM cisplatin (Pfizer srl) for 2 h at 37°C prior to harvesting 24–48 h later, according to Muller *et al* [32,33].

MTS-tetrazolium salt assay

The Promega CellTiter 96 Aqueous Non-Radioactive Cell Proliferation Assay was used to measure the cytotoxicity of cisplatin by determining the number of

viable cells in culture. The MTS [3-(4,5-dimethylthiazol-2-yl)-5-(3-carboxymethoxyphenyl)-2-(4-sulphophenyl)-2H-tetrazolium] assay is based on the ability of viable cells to convert a soluble tetrazolium salt into a formazan product. After exposure, the MTS/PMS reagent was added and cell cultures were incubated at 37 °C for 30 min. At the end of the incubation period, absorbance was recorded at 490 nm (Microplate Reader, Bio-Rad). The results were expressed in terms of mean \pm SE viable cells per well in three different experiments.

Small interfering RNA (siRNA) inhibition of seladin-1 expression

siRNAs targeting seladin-1 and negative control (siCONTROL non-targeting) were as previously described [34]. NT2 cells were grown to confluence between 70% and 80%, and washed with pre-warmed (37 °C) PBS. siRNAs targeting seladin-1 or control siRNAs (100 nM) were mixed with Lipofectamine 2000 (Invitrogen srl, Milan, Italy) and administered to the cells (24 h), following the manufacturer's instructions. For seladin-1 expression studies, treatment with cisplatin (10 μ M) was performed for an additional 24–48 h after silencing.

Seladin-1 overexpression

A cDNA sequence of 1657 bp containing the entire ORF of seladin-1 was obtained by RT-PCR performed on total RNA derived from human fetal neuroepithelial cells (FNCs), which express this protein [35], using the forward primer 5'-agtacaggaggcgcgaa-3' and the reverse primer 5'-agtgaaggaagatgcctga-3'. This sequence was cloned in pcDNA4/HisMax vector (Invitrogen, Carlsbad, CA, USA), a plasmid vector for high-level expression in mammalian cells of seladin-1 as a fusion to the N-terminal poly-histidine tag. This construct was sequenced and designated pcDNA-Sel.

Cells were transfected with pcDNA-Sel using Lipofectamine 2000 (Invitrogen, Carlsbad, CA, USA) on cells plated at 90% confluence in DMEM supplemented with 10% FBS without antibiotics. Forty-eight hours after transfection, the cells were selected with 100 μ g/ml zeocin for a total of 5 weeks. Moreover, NT2 cells were stably transfected with the empty vector pcDNA for control.

RNA extraction and quantitative real-time RT-PCR

Total RNA was obtained from tissues and NT2 cells using an RNeasy mini kit (Qiagen Inc, Valencia, CA, USA). Total RNA (400 ng) was reverse-transcribed in 80 μ l of final volume using the TaqMan Universal Master Mix (Applied Biosystems). The profile of the one-step, reverse-transcription reaction was 10 min at 25 °C, 30 min at 48 °C, and 5 min at 95 °C. TaqMan primers, probe, and thermal cycling conditions for

seladin-1 [23] and for OCT4 and NANOG [36] were as previously described.

Protein extraction and western blot analysis

Total proteins were extracted from 34 testis tumours and from normal testicular samples. Frozen tissues were ground in liquid nitrogen, re-suspended in lysis buffer [20 mM Tris-HCl (pH 7.4), 150 mM NaCl, 0.2 mM EDTA, 1% Triton X-100] containing protease inhibitors (1 mM AEBSF, 0.3 μ M aprotinin, 10 μ g/ml pepstatin; Sigma, Milan, Italy), and homogenized by potter. Total proteins were extracted from NT2 cells before and after differentiation and/or cisplatin treatment. The cells were lysed for 30 min at 4 °C in lysis buffer and centrifuged at 12 000 g for 3 min at 4 °C; the supernatant was used for western blot analysis, after protein quantification by Biorad protein assay (Bradford). For western blot, a rabbit polyclonal anti-seladin-1 antibody (1 : 1000), specific for the N-terminal of 60 kD seladin-1 protein (Sigma, Italy), and three rabbit polyclonal antibodies specific for cleaved caspase-3 (Asp175) (Cell Signaling Technology, Beverly, MA, USA), PARP, and neuronal enolase (Santa Cruz Biotechnology, Inc) were used.

Immunohistochemistry

Immunohistochemical analysis was performed on 3 μ m thick sections from formalin-fixed and paraffin-embedded specimens. All sections were deparaffinized in xylene and hydrated with graded ethanol. To block endogenous peroxidase activity, slides were treated with 3.0% hydrogen peroxidase in distilled water for 5 min. Antigen retrieval was routinely performed by immersing the sections in 0.01 M Tris/0.01 M EGTA (pH 8.0) buffer at high temperature in a pressure cooker. To block endogenous biotin (Vector Blocking Agent Kit SP 2001), the sections were treated with avidin and biotin solutions and subsequently stained with a polyclonal antibody against seladin-1 (Sigma) at 1 : 400 dilution in PBS/BSA 0.22% and incubated for 2 h at room temperature.

Primary antibody bound to antigen was detected with a standard (avidin) streptavidin-biotin-peroxidase technique and visualized with 3,3'-diaminobenzidine as a chromogen. Nuclei were counterstained with Mayer's haematoxylin. Sections of an adrenal cortical adenoma, showing strong immunopositivity for seladin-1, were used as positive controls, whereas negative controls were performed by replacing the primary antibody with a non-immune serum at the same concentration. Control sections were treated in parallel with the samples under investigation in the same run.

Results

Seladin-1 tissue expression pattern

We measured the mRNA expression level of seladin-1 by quantitative real-time RT-PCR in 20 TGCTs of

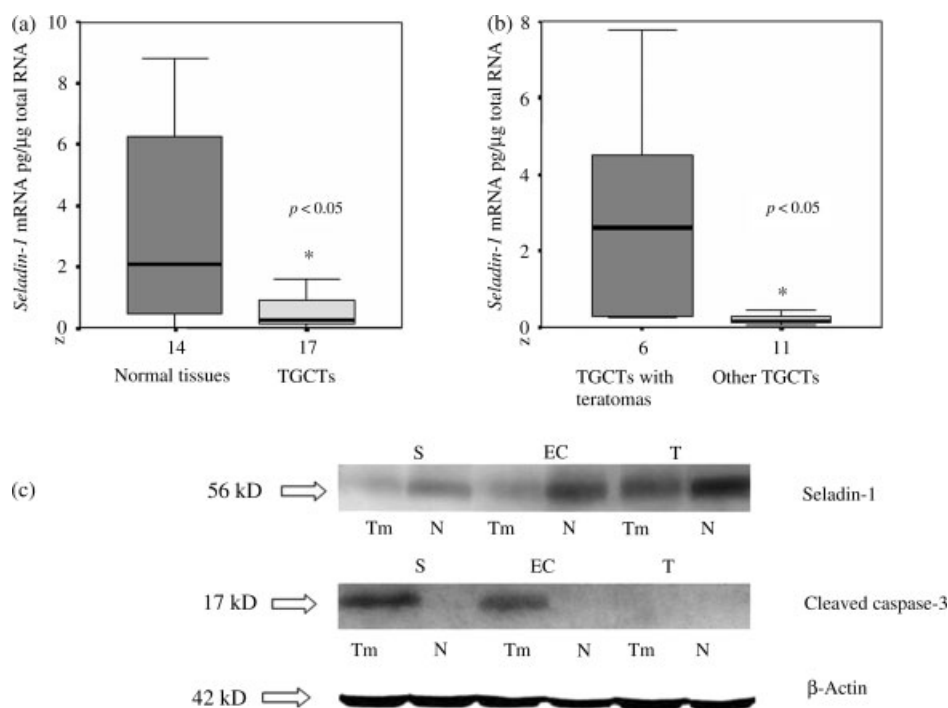


Figure 1. Seladin-1 expression and apoptosis in TGCTs. (a) Comparison of *seladin-1* mRNA levels in normal testis versus TGCTs, determined by real-time RT-PCR. Note the significantly lower expression level in the tumours compared with the normal tissue. (b) Comparison of *seladin-1* mRNA levels in teratomas versus other histological types of TGCTs. Note the significantly higher level of expression in the first compared with the second. (c) Western blot analysis of seladin-1 and cleaved caspase-3 in TGCTs and in matched adjacent normal testicular parenchyma. β -Actin was used as a loading control. The histologies as well as the size of the proteins are indicated. TGCTs = testicular germ cell tumours; S = seminoma; EC = embryonal carcinoma; CC = choriocarcinoma; T = teratoma; Tm = tumour part; N = normal tissue

different histological types and in the adjacent normal parenchyma. The level of seladin-1 expression was significantly reduced in TGCTs compared with the 'normal' part of the testis (Figure 1a, $p = 0.029$). The lowest expression level was found in seminomas, followed by embryonal carcinomas and teratomas. The expression level of seladin-1 was significantly higher in teratomas than in all the other histological types ($p = 0.021$) (Figure 1b). Western blot analysis for seladin-1 was performed in 34 TGCTs and in their adjacent normal parenchyma. The amount of protein was in agreement with the corresponding amount of mRNA (Figure 1c).

Immunohistochemistry was performed on a tissue microarray containing different TGCT histotypes. Both carcinoma *in situ* (CIS) and seminomas showed weak positive staining for seladin-1, whereas choriocarcinomas and teratomas showed strong positivity, thus confirming the mRNA and western blot data (Figure 2). Twenty-four primary spermatocytic seminomas were also stained and were all positive for seladin-1 (see Figure 2f). In normal testis, strong immunopositivity was observed in Leydig cells, whereas no staining in Sertoli cells and a weak signal were found in spermatogonia and in later stages of spermatogenesis (Figure 3). Analysis of fetal testis at different stages (16 and 36 weeks) of development showed no staining in the early stage (similarly to CIS and seminomas), whereas a high degree of expression was observed in the germinal components at the

later stage. Immunostaining for seladin-1 was present in Leydig cells in all cases (Figure 3).

Seladin-1 expression in the NT2 cell line

In order to confirm the data obtained in testis tissue samples, seladin-1 expression was analysed in the NT2 cell line before and after differentiation induced by RA. Differentiation was confirmed by an increase of γ -enolase (a specific neuronal marker) protein levels and a significant decrease of *OCT4* and *NANOG* (specific stem cell markers) mRNA expression compared with the undifferentiated cells (*OCT4*, $p = 0.039$; *NANOG*, $p = 0.023$) (Supporting information, Supplementary Figure 1). *Seladin-1* mRNA increased significantly ($p = 0.017$) after 28 days of RA treatment (Figure 4a). The expression of seladin-1 at the protein level followed the same pattern (Figure 4b).

Seladin-1 expression and apoptosis

Since seladin-1 is known to inhibit the activation of caspase-3, which is a key mediator of apoptosis, we analysed the amount of cleaved caspase-3 in the same set of TGCTs and in the NT2 cell line under the various growth conditions. The expression level of cleaved caspase-3 showed an opposite pattern to that of seladin-1 in tissues (Figure 1c) and cells (Figure 4b), supporting the idea of an anti-apoptotic role for this protein also in TGCTs. Similarly, the

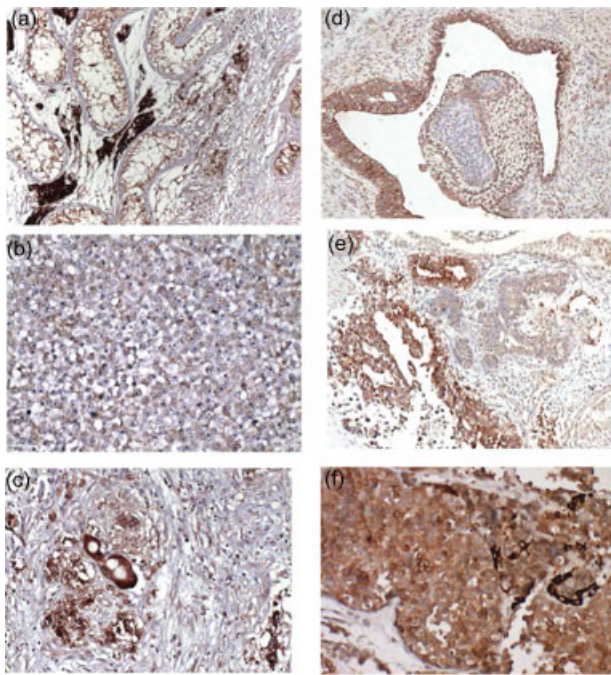


Figure 2. Seladin-1 protein expression evaluated by immunohistochemistry on tissue sections of primary TGCTs and normal testicular parenchyma. Representative examples are shown of (a) testicular parenchyma containing a seminiferous tubule with carcinoma *in situ* (left part of the image), embryonal carcinoma (right part of the image), and Leydig cells (dark cells between the seminiferous tubules); (b) seminoma; (c) choriocarcinoma; (d, e) teratoma containing predominantly epithelial structures; and (f) spermatocytic seminoma showing more intense staining than seminoma

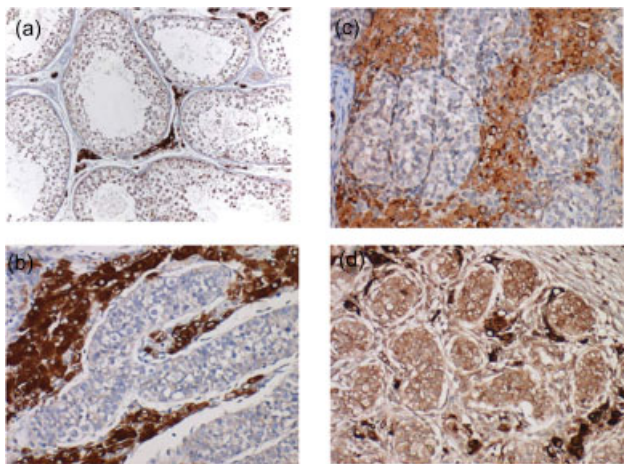


Figure 3. Seladin-1 protein expression evaluated by immunohistochemistry on tissue sections: (a) normal adult testis showing strong staining of Leydig cells around seminiferous tubules. Spermatogonia also show positivity. (b, c) Embryonic testis of 16 weeks of gestation showing again a high level of expression in Leydig cells, but absence of staining within the seminiferous tubules. (d) Embryonic testis of 36 weeks of gestation, showing both staining in the Leydig cells and in germ cells within the seminiferous tubules

protein expression level of cleaved PARP decreased in NT2 differentiated cells (Figure 4b) compared with the undifferentiated cells, confirming an anti-apoptotic effect.

Seladin-1 expression and sensitivity to cisplatin

NT2 undifferentiated cells

As expected, 24 and 48 h after the treatment of undifferentiated NT2 cells with cisplatin (10 μ M, for 2 h at 37 $^{\circ}$ C), we observed an induction of apoptosis (increased cleaved PARP and caspase-3; Figure 5a) and a significant reduction of cell viability (Supporting information, Supplementary Figure 2). Conversely, seladin-1 protein expression showed an inverse trend and reduced levels were observed both at 24 h and at 48 h after cisplatin treatment (Figure 5a).

NT2 differentiated cells

In accordance with clinical observations, cisplatin treatment in differentiated NT2 cells did not lead to induction of apoptosis, indicating that differentiated cells are less sensitive to this drug (Figure 5b). Also in these cells, seladin-1 expression decreased after cisplatin treatment, although the residual level of expression after cisplatin remained higher compared with the undifferentiated cells (Figure 5b). This phenomenon was also evident at the mRNA expression level (Supporting information, Supplementary Figure 3).

Seladin-1 silencing and overexpression in undifferentiated NT2 cells

Silencing

Seladin-1 siRNA and control siRNA were transfected into NT2 by lipofection. Real-time RT-PCR and western blot analysis showed that the amounts of transcript and protein were markedly decreased in NT2 after 24 h from administration of seladin-1 targeting siRNA (siNT2), but not in cells transfected with control siRNA (Figure 6a). Similarly, an increased expression level of cleaved PARP and cleaved caspase-3 (Figure 6b) was observed in siNT2, but not in c-siNT2 treated cells. Moreover, cell viability was significantly lower 48 h after treatment with cisplatin in siNT2 compared with c-siNT2 (Figure 6c, $p = 0.005$), indicating the involvement of seladin-1 in the apoptotic response of these cells to cisplatin.

Overexpression

In undifferentiated NT2 cells overexpressing seladin-1 (NT2Sel-1; Figure 7a), a moderate decrease in cleaved caspase-3 levels, without any change in cleaved PARP levels, was observed after cisplatin administration (Figure 7b). Cell viability in the same conditions was significantly higher in NT2 cells overexpressing seladin-1 (NT2Sel-1) than in cells transfected with the empty vector (NT2pcDNA; Figure 7c), further supporting a role for seladin-1 in cisplatin responsiveness.

Discussion

TGCTs represent a histologically heterogeneous group of neoplasms derived from the germ cell lineage.

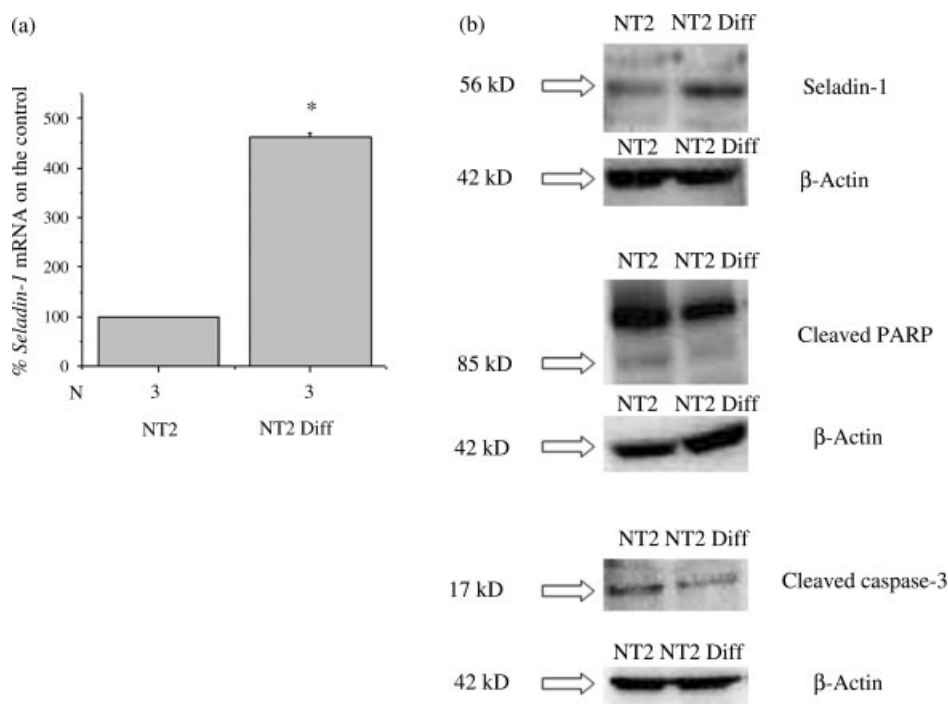


Figure 4. Seladin-1 expression and apoptosis in the TGCT-derived cell line NT2 cells before and after differentiation with retinoic acid (RA). (a) Real-time RT-PCR quantification of the seladin-1 transcript, showing up-regulation upon differentiation. (b) Western blot analysis of seladin-1, cleaved caspase-3, and cleaved PARP under both growth conditions, confirming increase of protein as suggested by mRNA analysis, and decrease of cleaved caspase-3 and cleaved PARP levels in the differentiated cells. β -Actin was used as a loading control. NT2 = NTERA2 cells; NT2 Diff = NTERA2 cells differentiated with 10 μ M retinoic acid for 28 days

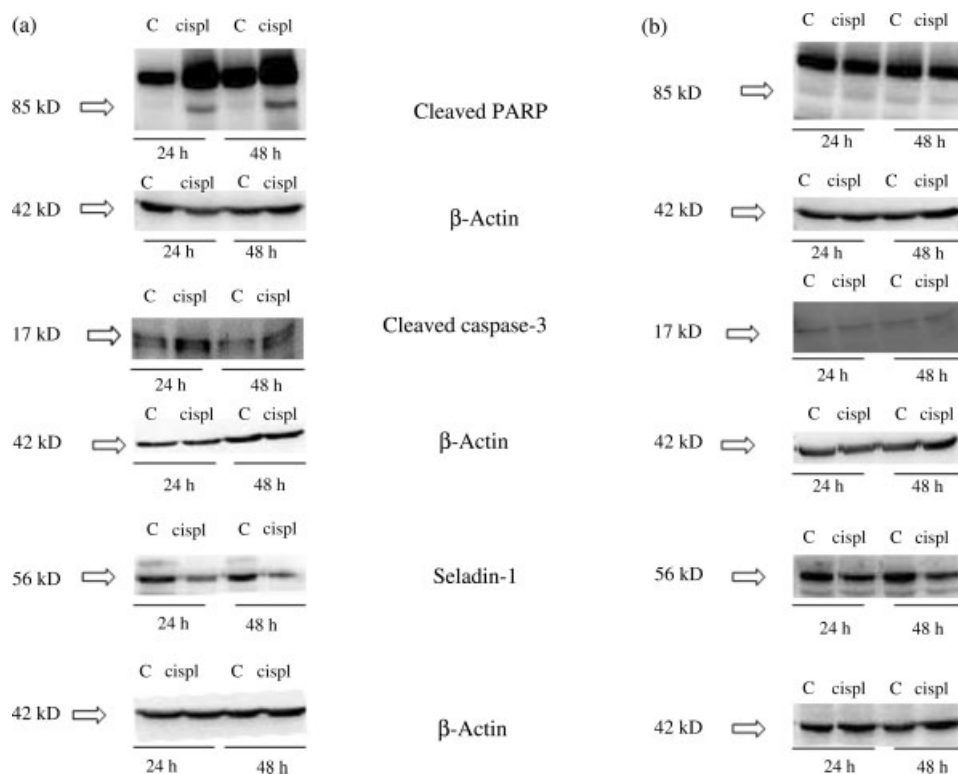


Figure 5. Cisplatin treatment in NT2 cells: Western blot analysis of cleaved PARP, cleaved caspase-3, and seladin-1 in the various growth conditions: (a) undifferentiated and (b) differentiated NT2 cells. Note the difference in cleaved PARP and caspase-3, associated with changes in seladin-1 protein levels. β -Actin was used as a loading control. cispl = 10 μ M cisplatin for 2 h at 37 °C

In contrast with the majority of solid tumours, most TGCTs can be cured by chemotherapy. Understanding the molecular basis of this particular characteristic

of TGCTs is of relevance, not only to allow better clinical management of patients with TGCTs, but also because it may provide new clues for more effective

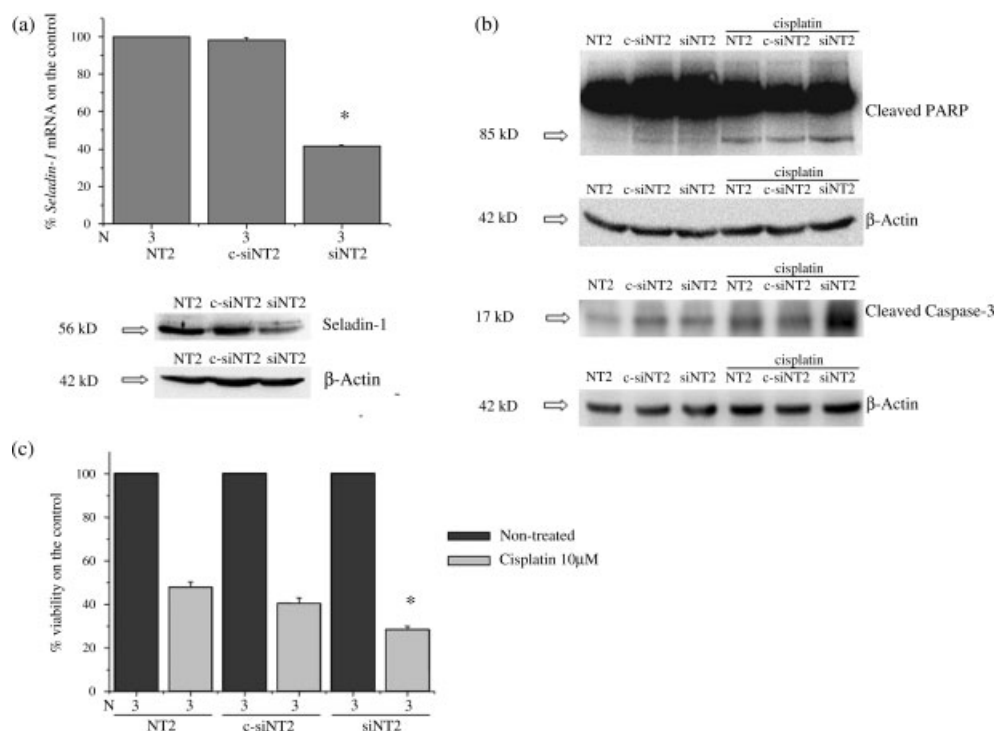


Figure 6. Seladin-1 silencing in NT2 cells. (a) Real-time RT-PCR and western blot quantification of the seladin-1 transcript and protein after seladin-1 silencing. NT2 undifferentiated cells were transfected with siRNAs targeting seladin-1 (siNT2) or control siRNAs (c-siNT2). Note the specific down-regulation, both at the mRNA and at the protein level using the specific siRNA. (b) Western blot analysis of cleaved PARP and cleaved caspase-3 after seladin-1 silencing in NT2 cells treated with cisplatin. The seladin-1 silenced cells show increased cleaved PARP and caspase-3 after cisplatin exposure. (c) MTS-tetrazolium salt assay in NT2, c-siNT2, and siNT2 cells after 48 h exposure to cisplatin. The results are expressed in terms of mean \pm SE (standard error) viable cells per well in three different experiments. Note the specific decrease in viability in the seladin-1 silenced cells

treatment of other solid cancers. It is widely accepted that there are many factors contributing to the unique chemosensitivity of TGCTs, including an inability to detoxify cisplatin and to repair DNA damage, and an intact apoptotic cascade not disrupted by anti-apoptotic stimuli [18].

In the present study, we focused on the expression of seladin-1 in different TGCT histological types and in a cell line model (NT2), before and after differentiation into teratoma. We also evaluated the role of seladin-1 in cisplatin responsiveness by silencing or overexpressing this gene. Seladin-1 was originally described as a gene with anti-apoptotic activity that is down-regulated in vulnerable brain regions in patients affected by Alzheimer's disease.

Seladin-1 mRNA is ubiquitously expressed in human adult and fetal tissues, with the exception of blood cells [20]. In neoplastic tissues and cell lines, its expression varies and both down- and up-regulation have been reported, compared with the corresponding normal counterparts. A high expression level has been observed in prostate [29,30], liver, lung [20], ovarian cancer [25], and metastatic melanoma [28], and in cell lines derived from cerebral tumours and from neuroblastoma [26]. Conversely, seladin-1 is down-regulated in adrenal cancer compared with adenoma and normal adrenal tissue [23].

Our study shows that *seladin-1* gene expression, both at the mRNA and at the protein level, differs

among different TGCT histotypes and shows the highest level in tumour-free normal tissues, regardless of the adjacent tumour type. This finding is not surprising if we consider the role of seladin-1 in steroidogenesis. Seladin-1 is the enzyme (DHCR24) that converts desmosterol into cholesterol [19] and is thus a key enzyme for steroidogenesis. In keeping with this function, immunohistochemical staining for seladin-1 was very strong in Leydig cells, which produce the steroid hormone testosterone. In contrast, no obvious staining of seladin-1 was identified in Sertoli cells. In the ovary — another organ which synthesizes steroid hormones — the normal ovarian tissue showed the highest expression level when compared with ovarian epithelial carcinoma and granulosa cell tumours [25]. Besides in Leydig cells, seladin-1 is also expressed during the early stages of spermatogenesis. This finding appears to be in agreement with the anti-apoptotic function of this protein. The immunostaining of fetal testes at different developmental stages is in line with the up-regulation of seladin-1 during normal germ cell development in humans. This finding opens up new perspectives for this gene as a potential candidate gene for spermatogenesis.

Despite their common cellular origin, different TGCT histological types show sharp differences in their biology and the differential expression of seladin-1 may reflect these differences. The seladin-1 expression pattern is clearly in accordance with

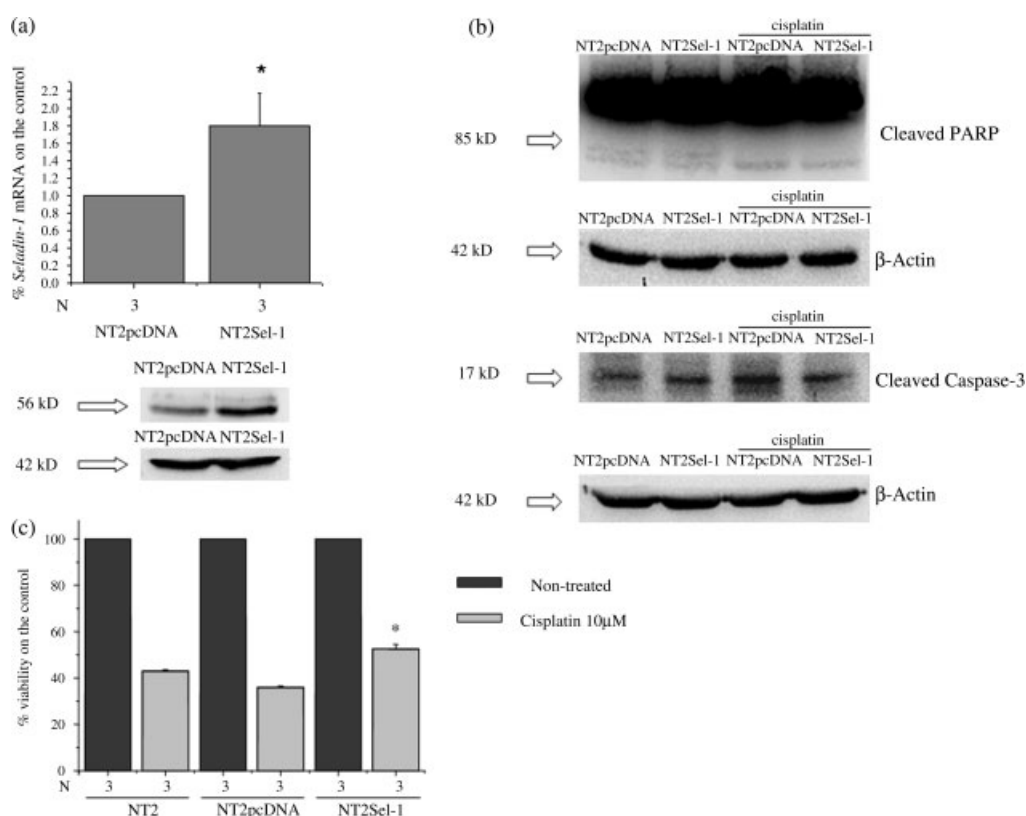


Figure 7. Seladin-1 overexpression in NT2. (a) Real-time RT-PCR and western blot quantification of seladin-1 in NT2 cells stably transfected with seladin-1 (NT2Sel-1) or with the empty vector pcDNA as a control (NT2pcDNA). Note the up-regulation of seladin-1 at the mRNA level. (b) Western blot analysis of cleaved PARP and cleaved caspase-3 in NT2pcDNA and NT2Sel-1 before and after cisplatin administration to the cells. The seladin-1 overexpressed cells show a moderate decrease in cleaved caspase-3 levels, without any change in cleaved PARP levels. (c) MTS-tetrazolium salt assay in NT2, NT2pcDNA, and NT2Sel-1 48 h after treatment with cisplatin. The results are expressed in terms of mean \pm SE viable cells per well in three different experiments. Note the specific increase in viability in the seladin-1 overexpressed cells

the different chemo/radiosensitivities of the major histotypes. The highest expression level was found in teratoma, whereas the lowest was in seminoma. The negligible expression of this anti-apoptotic protein in seminoma is in agreement with the strong tendency of this tumour type to undergo apoptosis both in *in vitro* cell cultures and following radiotherapy. By contrast, overexpression of seladin-1 in teratoma reflects the chemotherapy resistance of this histological type and is similar to the pattern found in cell lines from chemoresistant metastatic melanoma [28]. It is interesting to note that spermatocytic seminomas, which are TGCTs with a separate pathogenesis from seminoma, show strong expression of seladin-1. Our finding is in line with previous reports showing important differences between the set of genes overexpressed in seminoma compared with spermatocytic seminoma [37,38]. Genes that are overexpressed in spermatocytic seminoma are mainly related to spermatogenesis (especially those involved in the induction of meiosis), whereas seminoma shows up-regulation of genes involved in stem cell renewal. Our finding provides further evidence for the hypothesis that spermatocytic seminoma originates from a later maturation stage than seminomas.

In TGCTs, as in other cancers, seladin-1 exerts its anti-apoptotic role through the inhibition of caspase-3

activation. We observed an inverse relationship between seladin-1 expression and cleaved caspase-3 in both tissue specimens and our cell line model (NT2 cells). In order to explore further the link between seladin-1 and chemosensitivity/resistance, we performed functional studies in NT2 cells following administration of cisplatin. We observed a modulation of seladin-1 expression by cisplatin both in undifferentiated (embryonal carcinoma) and differentiated (teratoma) cells. In both cell types, cisplatin was able to down-regulate seladin-1 expression, although this effect was associated with up-regulation of apoptotic markers only in undifferentiated cells. The different behaviours of the two cell types may be explained by the different baseline expression levels of seladin-1, which is significantly higher in differentiated cells. In fact, even if cisplatin treatment is able to reduce seladin-1 expression in these cells, its level remains much higher compared with undifferentiated cells. It is therefore likely that the high residual expression level of seladin-1 in teratoma cells is able to counteract the effect of cisplatin.

Our functional studies based on seladin-1 silencing and overexpression showed clear evidence of the involvement of seladin-1 in cisplatin responsiveness in NT2 cells. Seladin-1 silencing was associated with a higher responsiveness to cisplatin in terms of

both decreased cell viability and increased expression of apoptotic markers. Conversely, overexpression of seladin-1 induced a higher survival rate and a clear anti-apoptotic effect.

In conclusion, the present study shows for the first time that the *seladin-1* gene is highly expressed in specific histological elements of non-seminomatous TGCTs compared with seminoma and this may account for differences in the propensity of TGCTs to undergo apoptosis following anti-tumoural therapy. The experiments performed on NT2 cells clearly show that this protein interferes with the apoptotic response to cisplatin treatment through the inhibition of caspase-3 activation. In view of these results, further studies on chemoresistant cell lines and tumours should reveal whether seladin-1 might be targeted to develop pharmacological strategies to enforce caspase-3 activation and thus to improve further the therapeutic outcome of testis cancer.

Acknowledgements

We thank F Gensini, S Marchiani, and M Muratori for their technical assistance and M Mangoni for her clinical input. We are grateful to Dr P Ewing for careful editing of the article. This work was supported by a grant from the Associazione Italiana per la Ricerca sul Cancro (to FN) and the Italian Ministry of Education and Research (grant PRIN 2007–2009 to CK).

References

- Adami HO, Bergstrom R, Mohner M, Zatonski W, Storm H, Ekblom A, *et al.* Testicular cancer in nine northern European countries. *Int J Cancer* 1994;**59**:33–38.
- Skakkebaek NE, Berthelsen JG, Giwercman A, Muller J. Carcinoma-*in-situ* of the testis: possible origin from gonocytes and precursor of all types of germ cell tumours except spermatocytoma. *Int J Androl* 1987;**10**:19–28.
- Weissbach I, Bussar-Maatz R. [Pathogenesis, diagnosis and therapy of testicular tumors]. *Urologe A* 1996;**35**:163–172.
- Oosterhuis JW, Looijenga LH. Testicular germ-cell tumours in a broader perspective. *Nature Rev Cancer* 2005;**5**:210–222.
- Ulbright TM. Germ cell tumors of the gonads: a selective review emphasizing problems in differential diagnosis, newly appreciated, and controversial issues. *Mod Pathol* 2005;**18**(Suppl 2):S61–S79.
- Jorgensen N, Rajpert-De Meyts E, Graem N, Muller J, Giwercman A, Skakkebaek NE. Expression of immunohistochemical markers for testicular carcinoma *in situ* by normal human fetal germ cells. *Lab Invest* 1995;**72**:223–231.
- Looijenga LH, de Leeuw H, van Oorschoot M, van Gurp RJ, Stoop H, Gillis AJ, *et al.* Stem cell factor receptor (c-KIT) codon 816 mutations predict development of bilateral testicular germ-cell tumours. *Cancer Res* 2003;**63**:7674–7678.
- Looijenga LH, Oosterhuis JW. Pathogenesis of testicular germ cell tumours. *Rev Reprod* 1999;**4**:90–100.
- Chaganti RS, Houldsworth J. Genetics and biology of adult human male germ cell tumors. *Cancer Res* 2000;**60**:1475–1482.
- Porcaro AB, Antonioli SZ, Maffei N, Beltrami P, Bassetto MA, Curti P. Management of testicular seminoma advanced disease. Report on 14 cases and review of the literature. *Arch Ital Urol Androl* 2002;**74**:81–85.
- Al Ghamdi AM, Jewett MA. Stage I nonseminomatous germ cell tumors: the case for management by risk stratification. *Can J Urol* 2005;**12**(Suppl 1):62–65; discussion 103–104.
- Peckham M. Testicular cancer. *Acta Oncol* 1988;**27**:439–453.
- Perrotti M, Ankem M, Bancilla A, de Carvalho V, Amenta P, Weiss R. Prospective metastatic risk assignment in clinical stage I nonseminomatous germ cell testis cancer: a single institution pilot study. *Urol Oncol* 2004;**22**:174–177.
- Classen J, Souchon R, Hehr T, Bamberg M. Treatment of early stage testicular seminoma. *J Cancer Res Clin Oncol* 2001;**127**:475–481.
- Shelley MD, Burgon K, Mason MD. Treatment of testicular germ-cell cancer: a cochrane evidence-based systematic review. *Cancer Treat Rev* 2002;**28**:237–253.
- Jones RH, Vasey PA. Part II: testicular cancer — management of advanced disease. *Lancet Oncol* 2003;**4**:738–747.
- Oosterhof GO, Verlind J. Testicular tumours (nonseminomatous). *BJU Int* 2004;**94**:1196–1201.
- Masters JR, Koberle B. Curing metastatic cancer: lessons from testicular germ-cell tumours. *Nature Rev* 2003;**3**:517–525.
- Waterham HR, Koster J, Romeijn GJ, Hennekam RC, Vreken P, Andersson HC, *et al.* Mutations in the 3beta-hydroxysteroid delta24-reductase gene cause desmosterolosis, an autosomal recessive disorder of cholesterol biosynthesis. *Am J Hum Genet* 2001;**69**:685–694.
- Greeve I, Hermans-Borgmeyer I, Brellinger C, Kasper D, Gomez-Isla T, Behl C, *et al.* The human DIMINUTO/DWARF1 homolog seladin-1 confers resistance to Alzheimer's disease-associated neurodegeneration and oxidative stress. *J Neurosci* 2000;**20**:7345–7352.
- Sarkar D, Imai T, Kambe F, Shibata A, Ohmori S, Siddiq A, *et al.* The human homolog of Diminuto/Dwarf1 gene (hDiminuto): a novel ACTH-responsive gene overexpressed in benign cortisol-producing adrenocortical adenomas. *J Clin Endocrinol Metab* 2001;**86**:5130–5137.
- Wu C, Miloslavskaya I, Demontis S, Maestro R, Galaktionov K. Regulation of cellular response to oncogenic and oxidative stress by seladin-1. *Nature* 2004;**432**:640–645.
- Luciani P, Ferruzzi P, Arnaldi G, Crescioli C, Benvenuti S, Nesi G, *et al.* Expression of the novel adrenocorticotropin-responsive gene selective Alzheimer's disease indicator-1 in the normal adrenal cortex and in adrenocortical adenomas and carcinomas. *J Clin Endocrinol Metab* 2004;**89**:1332–1339.
- Luciani P, Gelmini S, Ferrante E, Lania A, Benvenuti S, Baglioni S, *et al.* Expression of the antiapoptotic gene seladin-1 and octreotide-induced apoptosis in growth hormone-secreting and nonfunctioning pituitary adenomas. *J Clin Endocrinol Metab* 2005;**90**:6156–6161.
- Fuller PJ, Alexiadis M, Jobling T, McNeilage J. Seladin-1/DHCR24 expression in normal ovary, ovarian epithelial and granulosa tumours. *Clin Endocrinol (Oxford)* 2005;**63**:111–115.
- Peri A, Serio M. Neuroprotective effects of the Alzheimer's disease-related gene seladin-1. *J Mol Endocrinol* 2008;**41**:251–261.
- Benvenuti S, Luciani P, Cellai I, Deledda C, Baglioni S, Saccardi R, *et al.* Thyroid hormones promote cell differentiation and up-regulate the expression of the seladin-1 gene in *in vitro* models of human neuronal precursors. *J Endocrinol* 2008;**197**:437–446.
- Di Stasi D, Vallacchi V, Campi V, Ranzani T, Daniotti M, Chiodini E, *et al.* DHCR24 gene expression is upregulated in melanoma metastases and associated to resistance to oxidative stress-induced apoptosis. *Int J Cancer* 2005;**115**:224–230.
- Hendriksen PJ, Dits NF, Kokame K, Veldhoven A, van Weerden WM, Bangma CH, *et al.* Evolution of the androgen receptor pathway during progression of prostate cancer. *Cancer Res* 2006;**66**:5012–5020.
- Bonaccorsi L, Luciani P, Nesi G, Mannucci E, Deledda C, Dichiera F, *et al.* Androgen receptor regulation of the seladin-1/DHCR24 gene: altered expression in prostate cancer. *Lab Invest* 2008;**88**:1049–1056.
- Andrews PW. Retinoic acid induces neuronal differentiation of a cloned human embryonal carcinoma cell line *in vitro*. *Dev Biol* 1984;**103**:285–293.
- Mueller S, Schittenhelm M, Honecker F, Malenke E, Lauber K, Wesselborg S, *et al.* Cell-cycle progression and response of germ cell tumors to cisplatin *in vitro*. *Int J Oncol* 2006;**29**:471–479.

33. Burger H, Nooter K, Boersma AW, van Wingerden KE, Looijenga LH, Jochemsen AG, *et al.* Distinct p53-independent apoptotic cell death signalling pathways in testicular germ cell tumour cell lines. *Int J Cancer* 1999;**81**:620–628.
34. Luciani P, Deledda C, Rosati F, Benvenuti S, Cellai I, Dichiarà F, *et al.* Seladin-1 is a fundamental mediator of the neuroprotective effects of estrogen in human neuroblast long-term cell cultures. *Endocrinology* 2008;**149**:4256–4266.
35. Benvenuti S, Luciani P, Vannelli GB, Gelmini S, Franceschi E, Serio M, *et al.* Estrogen and selective estrogen receptor modulators exert neuroprotective effects and stimulate the expression of selective Alzheimer's disease indicator-1, a recently discovered antiapoptotic gene, in human neuroblast long-term cell cultures. *J Clin Endocrinol Metab* 2005;**90**:1775–1782.
36. Romagnani P, Annunziato F, Liotta F, Lazzeri E, Mazinghi B, Frosali F, *et al.* CD14+CD34low cells with stem cell phenotypic and functional features are the major source of circulating endothelial progenitors. *Circ Res* 2005;**97**:314–322.
37. Looijenga LH, Hersmus R, Gillis AJ, Pfundt R, Stoop HJ, van Gurp RJ, *et al.* Genomic and expression profiling of human spermatocytic seminomas: primary spermatocyte as tumorigenic precursor and DMRT1 as candidate chromosome 9 gene. *Cancer Res* 2006;**66**:290–302.
38. Looijenga LH, Stoop H, Hersmus R, Gillis AJ, Wolter Oosterhuis J. Genomic and expression profiling of human spermatocytic seminomas: pathogenetic implications. *Int J Androl* 2007;**30**:328–335; discussion 335–326.

SUPPORTING INFORMATION ON THE INTERNET

The following supporting information may be found in the online version of this article.

Figure S1. Expression level before and after differentiation with retinoic acid of (a) γ enolase, (b) OCT4, and (c) NANOG.

Figure S2. MTS-tetrazolium salt assay in NT2 cells 24–48 h after treatment with cisplatin.

Figure S3. Real-time RT-PCR quantification of the seladin-1 transcript in undifferentiated and differentiated NT2 cells 48 h after treatment with cisplatin.