



UNIVERSITÀ
DEGLI STUDI
FIRENZE

FLORE

Repository istituzionale dell'Università degli Studi di Firenze

The value of lung ultrasound monitoring in H1N1 acute respiratory distress syndrome

Questa è la Versione finale referata (Post print/Accepted manuscript) della seguente pubblicazione:

Original Citation:

The value of lung ultrasound monitoring in H1N1 acute respiratory distress syndrome / A.Peris; G.Zagli; F.Barbani; L.Tutino; S.Biondi; S.di Valvasone; S.Batacchi; M.Bonizzoli; R.Spina; M.Miniati; S.Pappagallo; V.Giovannini; G.F.Gensini. - In: ANAESTHESIA. - ISSN 0003-2409. - STAMPA. - 65:(2010), pp. 294-297.

Availability:

The webpage <https://hdl.handle.net/2158/394744> of the repository was last updated on

Terms of use:

Open Access

La pubblicazione è resa disponibile sotto le norme e i termini della licenza di deposito, secondo quanto stabilito dalla Policy per l'accesso aperto dell'Università degli Studi di Firenze (<https://www.sba.unifi.it/upload/policy-oa-2016-1.pdf>)

Publisher copyright claim:

La data sopra indicata si riferisce all'ultimo aggiornamento della scheda del Repository FloRe - The above-mentioned date refers to the last update of the record in the Institutional Repository FloRe

(Article begins on next page)



CASE REPORT

The value of lung ultrasound monitoring in H1N1 acute respiratory distress syndrome

A. Peris,¹ G. Zagli,² F. Barbani,³ L. Tutino,³ S. Biondi,³ S. di Valvasone,³ S. Batacchi,² M. Bonizzoli,² R. Spina,² M. Miniati,⁴ S. Pappagallo,⁵ V. Giovannini⁶ and G. F. Gensini⁷

1 Chief, 2 Specialist in Anaesthesia and Intensive Care, 3 Specialist Trainee in Anaesthesia and Intensive Care, Anaesthesia and Intensive Care Unit, Emergency Department, 4 Professor, Department of Critical Care Medicine and Surgery, 7 Chief, Department of Critical Care Medicine & Surgery and Dean of Faculty of Medicine, Careggi Teaching Hospital, Florence, Italy

5 Chief of Anaesthesia and Intensive Care Unit, General Hospital, Empoli, Italy

6 Director of Regional Health System, Florence, Italy

Summary

We present the case of a healthy young male who developed acute respiratory failure as a result of infection with influenza A/H1N1 of swine-origin and in whom ventilatory support was optimised and recovery of lung function was monitored by the use of sequential chest ultrasound examinations. The potential pivotal role of bedside lung ultrasonography in H1N1-induced respiratory failure is discussed.

Correspondence to: Dr Giovanni Zagli

E-mail: giovanni.zagli@unifi.it

Accepted: 16 November 2009

Case Report

Patients affected by the novel swine-origin influenza A/H1N1 virus can develop an acute alveolar interstitial syndrome. A recent survey of Spanish Intensive Care Units (ICUs) showed that patients requiring ICU admission had a young median age and a relatively high case-mortality rate [1]. We present the case of a young healthy male who developed H1N1-induced Acute Respiratory Distress Syndrome (ARDS) and in whom management was guided by daily lung ultrasonography.

A 39-year-old man was referred to the Emergency Room of a peripheral hospital with a fever (38.5 °C), arthralgia and severe dyspnoea. Over the previous 4 days he had been complaining of mild fever, abdominal pain, nausea, and diarrhoea. He was a heavy cigarette smoker with no significant co-morbidities in his past medical history.

At presentation in the Emergency Room the patient was disoriented. He had a systemic arterial pressure of 135/70 mmHg, a heart rate of 140 beats.min⁻¹, a respiratory rate of 35 breaths.min⁻¹, and S_pO₂ of 77%

Arterial blood gas analysis demonstrated: pH 7.46; P_aO₂ 5.3 kPa with a F_IO₂ 0.3 (P_aO₂/F_IO₂ ratio of 17.6 (140 if P_aO₂ expressed in mmHg)); P_aCO₂ 4.6 kPa; base excess 1.5 mmol.l⁻¹ and bicarbonate 25 mmol.l⁻¹. Computed tomography (CT) of the chest showed multiple, bilateral areas of increased lung density (Fig. 1). The patient was sedated, underwent tracheal intubation and his lungs were mechanically ventilated. After 2 h of mechanical ventilation with a F_IO₂ of 1.0 and using high inspiratory pressure levels (plateau pressure 47 cmH₂O, positive-end expiratory pressure (PEEP) 20 cmH₂O), and with no response to recruitment manoeuvres, blood gas analysis showed a P_aO₂ of 21 kPa (P_aO₂/F_IO₂ ratio of 21 (160 if P_aO₂ expressed in mmHg)). According to the local protocol for the management of patients with ARDS, the patient was subsequently transferred to our hospital which is the designated referral centre for extracorporeal membrane oxygenation.

Following transfer and admission to our ICU, a pulmonary artery catheter was inserted; measurements showed a pulmonary artery wedge pressure of 14 mmHg, confirming the presence of ARDS. A protective lung

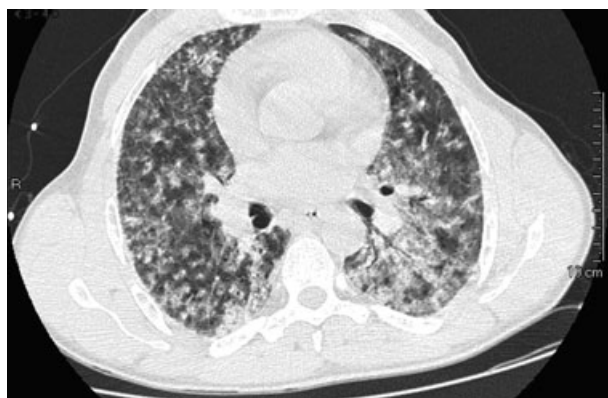

Figure 1 The first CT-scan image performed at the peripheral (referring) hospital.

ventilation strategy was undertaken [2, 3]. The level of PEEP level was maintained at 2 cmH₂O above the lower inflection point (10 cmH₂O) of the pressure–volume curve established for the patient’s lungs. Inspiratory pressure was set to obtain a tidal volume of 6 ml.kg⁻¹ of predicted body weight with a maximum plateau pressure of 28 cmH₂O (Evita XL; DrägerMedical, DE, Lübeck, Germany). The patient’s Sequential Organ Failure Assessment (SOFA) score was assessed and was found to be 12. He required noradrenaline (0.8 µg.kg⁻¹.min⁻¹) to maintain an adequate blood pressure and was treated according to our internal standard protocol based on the current guidelines of the Surviving Sepsis Campaign [4]. Blood and tracheal aspirate samples were obtained and cultured. Antigen tests for *Streptococcus pneumoniae* and *Legionella pneumophila* and Polymerase Chain Reaction (PCR) for common viral infections and tuberculosis were performed. Empiric antimicrobial therapy with levofloxacin and piperacillin/tazobactam was administered. Heart failure and severe pulmonary hypertension were excluded by pulmonary artery pressure measurements and transthoracic echocardiography. The patient’s details, clinical characteristics, and lung ultrasonography/CT images were all stored in the ICU-database (FileMaker Pro 5.5v2; FileMaker, Inc, Santa Clara, CA, USA). Informed, written consent for data publication was obtained following the patient’s recovery and prior to his discharge.

Given the suspicion of H1N1 infection, reverse transcriptase PCR testing for H1N1 was obtained at admission in accordance with published guidelines [5]. The results of tests on pharyngeal swabs and subglottic and tracheal aspirates were positive for the presence of the H1N1 virus. On the first day following ICU admission, analysis of the patient’s blood revealed that his procalcitonin (3.2 ng.ml⁻¹), alanine aminotransferase (65 U.l⁻¹),

lactate dehydrogenase (600 U.l⁻¹), and C-reactive protein (65 mg.dl⁻¹) levels were all elevated. His leucocyte count was normal; however his platelet count was decreased (48×10^9 .l⁻¹).

No other infections were diagnosed from cultures, PCR or antigen tests. Antiviral therapy was started using enteral oseltamivir 75 mg twice daily. Because of poor gastric emptying, inhaled zanamivir (10 mg twice a day) was added to improve antiviral bioavailability. Empiric antimicrobial therapy was maintained in order to minimise the risk of pulmonary bacterial co-infection. Fluid administration and diuresis were tightly regulated to achieve both acceptable haemodynamic parameters and fluid restriction according to current recommendations [6].

Beside lung ultrasonography was performed three times a day by the ultrasound-certified intensivist on duty. Videos of the procedures were stored on magneto-optical disks for re-evaluation after every new lung ultrasound scan.

With the patient in the semirecumbent position, images were acquired by means of a multifrequency (3.5–5 MHz) convex probe (Mylab TM 30CV; ESAOTE, Genova, Italy) placed perpendicular to the chest wall, using the intercostal spaces as acoustic windows. Lateral and anterior views were obtained from the base to the apex of the chest. The posterior axillary line was followed during the lateral transverse scans; quadrants defined by the intercostal spaces and the parasternal, mid-clavicular, and anterior axillary lines were scanned on the anterior chest wall. The estimation of disease-free areas and the evaluation of recruitment manoeuvres and the optimal level of PEEP were conducted according to Bouhemad and co-workers [7]. The evolution of the pulmonary lesions was followed over time using ultrasound images which showed lung consolidation with contiguous B-lines (Fig. 2a), the presence of B-lines with defined spacing (Fig. 2b), and finally recovery of normal lung structure (Fig. 2c) [8]. Recovery of normal pleural gliding was also considered to be a sign of responsiveness to therapy.

The first lung ultrasound examination (Fig. 2) confirmed bilateral acute alveolar interstitial syndrome [8] with areas of consolidation, and multiple B-lines. Pleural thickening, generalised gliding reduction with no lung pulse, and a small left-sided pleural effusion were also seen. Alveolar recruitment manoeuvres, and adjustments of the ventilation parameters adjustments ($F_{I}O_2$ /PEEP reduction) were based on sequential lung ultrasonography examinations (Fig. 3a & b respectively).

As the patient’s condition improved, the dose of noradrenaline was tapered and withdrawn, and his respiratory function gradually returned to normal with nearly complete resolution of the acute alveolar interstitial

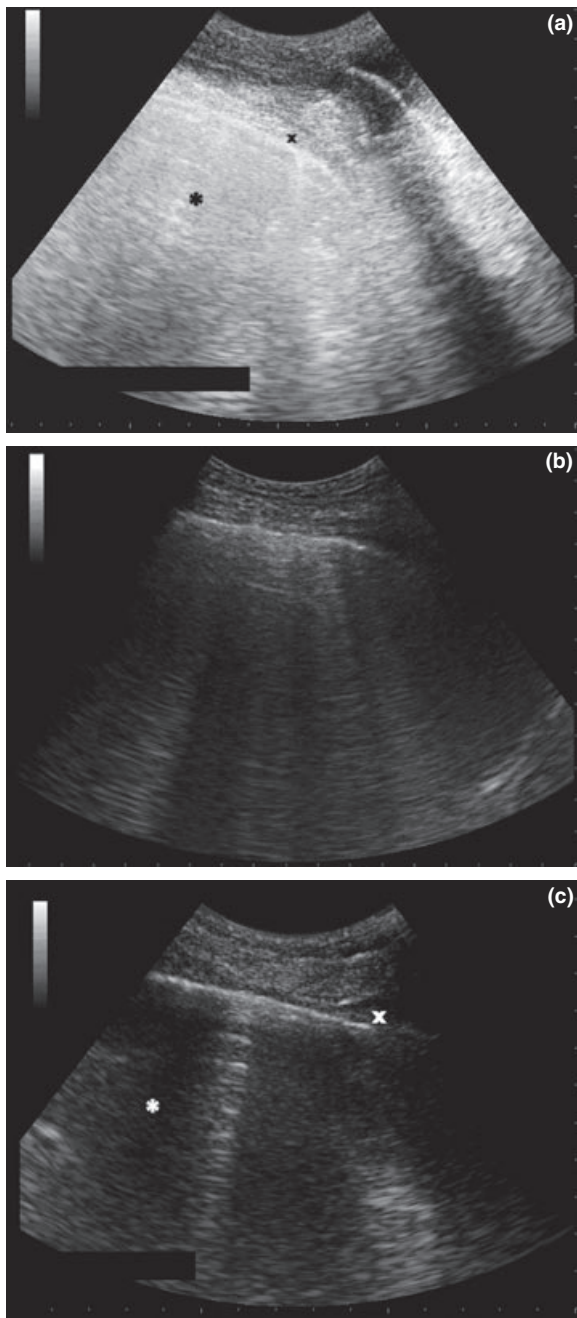


Figure 2 (a) The first ultrasound image of the patient’s lungs: consolidation and contiguous B-lines; * = alveolar interstitial syndrome; X = pleural thickening. (b) This illustrates the presence of B-lines with defined spacing. (c) The recovered lung after tracheal extubation. X = normal pleura; * = pattern of normal lung parenchyma.

syndrome demonstrated on the initial lung ultrasound scans. His plasma procalcitonin level and platelet count returned to normal, while his lactate dehydrogenase remained elevated and his plasma alanine aminotransferase

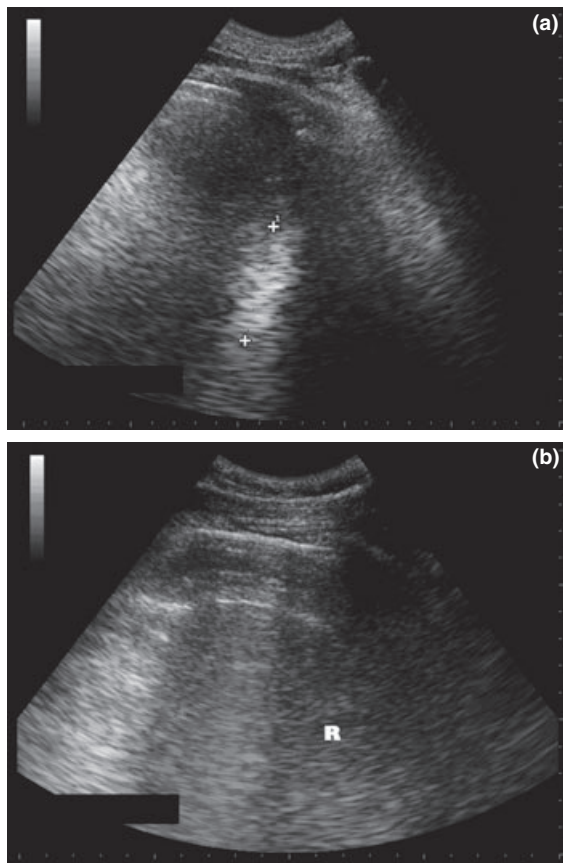


Figure 3 (a) Ultrasound scan showing lung consolidation before recruitment (+...+). (b) The same acoustic window as in A, but following a recruitment manoeuvre. R = residual area of alveolar consolidation.

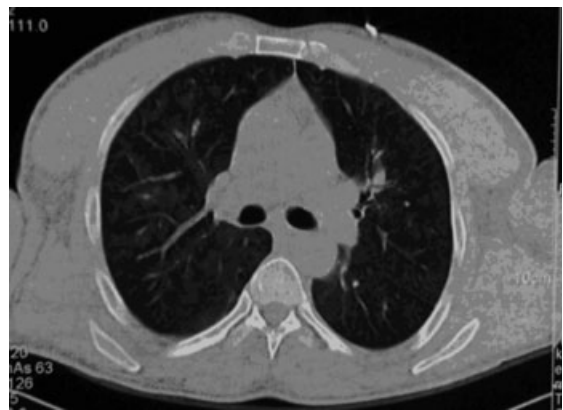

Figure 4 Chest CT-scan image after tracheal extubation.

level increased slightly (up to 120 U.L⁻¹). It was felt that the latter was possibly as a consequence of his multi-drug therapy. An ultrasound examination of the abdomen was negative.

Patient samples of pharyngeal swabs and subglottic and tracheal aspirates were taken daily to follow the status of the H1N1 infection using reverse transcriptase PCR. All were negative from the fifth day until his discharge from ICU. The patient's trachea was successfully extubated on the sixth day following ventilatory weaning trials. His Tobin index (respiratory frequency/tidal volume in litres) at this time was 35 [9]. He was discharged on day eight with lung parenchyma that was nearly normal (Figs 2c and 4).

Discussion

The major novelty of the present report is the use of sequential lung ultrasonography to guide lung recruitment manoeuvres and optimal $F_{I}O_2$ /PEEP levels during invasive ventilation [7, 10]. This process was continued through the acute phase of this patient's illness until his discharge from ICU.

Bedside lung ultrasonography has been proposed as a safe, reliable and simple technique in the evaluation and management of chest disorders [10, 11]. Computerised tomography is the reference method for evaluating acute lung injury, but transportation of critically ill patients to the radiology department requires transient disconnection of the patient's lungs from the ventilator and has been associated with a high risk of complications and instability [12, 13]. In addition, transporting patients infected with H1N1 outside of the ICU negative-pressure rooms may contribute to spreading the infection. In contrast, lung ultrasonography can be obtained at the bedside in the ICU without the need to disconnect the patient's lungs from the ventilator. Moreover, daily lung ultrasonography can avoid routine chest radiographs, the use of which may be limited in critically ill patients [14].

Lung ultrasonography cannot, however, be used as a standalone technique to diagnose acute lung injury as it cannot differentiate cardiogenic pulmonary oedema from oedema caused by increased vascular permeability. Once the aetiology of lung oedema is established, lung ultrasonography can be applied to follow the time course of the disorder as shown in the present report.

We noted with interest our patient's history of heavy cigarette smoking which may have represented a risk factor for H1N1-associated ARDS [15]. To our knowledge, no data are available with regards to the prevalence of H1N1 pneumonia in smokers. Rapid surveillance may be warranted to establish whether a vaccination strategy is recommended among heavy smokers.

In conclusion, our management of this patient suggests that bedside lung ultrasonography can be successfully used

to monitor the evolution of H1N1-associated ARDS. Such ultrasonic techniques could help limit the need for radiological imaging in critically ill patients.

References

- 1 Rello J, Rodriguez A, Ibanez P, et al. Intensive care adult patients with severe respiratory failure caused by Influenza A (H1N1)v in Spain. *Critical Care* 2009; **13**: R148.
- 2 Ventilation with lower tidal volumes as compared with traditional tidal volumes for acute lung injury and the acute respiratory distress syndrome. The Acute Respiratory Distress Syndrome Network. *The New England Journal of Medicine* 2000; **342**: 1301–8.
- 3 Brower RG, Lanken PN, MacIntyre N, et al. Higher versus lower positive end-expiratory pressures in patients with the acute respiratory distress syndrome. *The New England Journal of Medicine* 2004; **351**: 327–36.
- 4 Dellinger RP, Levy MM, Carlet JM, et al. Surviving Sepsis Campaign: international guidelines for management of severe sepsis and septic shock: 2008. *Intensive Care Medicine* 2008; **34**: 17–60.
- 5 World Health Organization. *CDC protocol of realtime RT-PCR for influenza A (H1N1)*. Geneva: WHO, 2009.
- 6 Fowler RA, Adhikari NK, Scales DC, Lee WL, Rubenfeld GD. Update in critical care 2008. *American Journal of Respiratory and Critical Care Medicine* 2009; **179**: 743–58.
- 7 Bouhemad B, Liu ZH, Arbelot C, et al. Ultrasound assessment of antibiotic-induced pulmonary reaeration in ventilator-associated pneumonia. *Critical Care Medicine* 2009; **23**: 23.
- 8 Lichtenstein DA, Lascols N, Meziere G, Gepner A. Ultrasound diagnosis of alveolar consolidation in the critically ill. *Intensive Care Medicine* 2004; **30**: 276–81.
- 9 Tobin MJ, Perez W, Guenther SM, et al. The pattern of breathing during successful and unsuccessful trials of weaning from mechanical ventilation. *The American Review of Respiratory Disease* 1986; **134**: 1111–8.
- 10 Arbelot C, Ferrari F, Bouhemad B, Rouby JJ. Lung ultrasound in acute respiratory distress syndrome and acute lung injury. *Current Opinion in Critical Care* 2008; **14**: 70–4.
- 11 Schmidt GA. ICU ultrasound. The coming boom. *Chest* 2009; **135**: 1407–8.
- 12 Voigt LP, Pastores SM, Raoof ND, Thaler HT, Halpern NA. Review of a large clinical series: intrahospital transport of critically ill patients: outcomes, timing, and patterns. *Journal of Intensive Care Medicine* 2009; **24**: 108–15.
- 13 Waydhas C. Intrahospital transport of critically ill patients. *Critical Care* 1999; **3**: R83–9.
- 14 Graat ME, Kroner A, Spronk PE, et al. Elimination of daily routine chest radiographs in a mixed medical-surgical intensive care unit. *Intensive Care Medicine* 2007; **33**: 639–44.
- 15 Kark JD, Lebiush M, Rannon L. Cigarette smoking as a risk factor for epidemic a(h1n1) influenza in young men. *The New England Journal of Medicine* 1982; **307**: 1042–6.