



UNIVERSITÀ  
DEGLI STUDI  
FIRENZE

## FLORE

# Repository istituzionale dell'Università degli Studi di Firenze

### **Hybrid treatment of aortic arch aneurysms.**

Questa è la Versione finale referata (Post print/Accepted manuscript) della seguente pubblicazione:

*Original Citation:*

Hybrid treatment of aortic arch aneurysms / N. Troisi; G. Pratesi; A. Fargion; W. Dorigo; R. Pulli; M. Acquafresca; C. Pratesi. - In: JOURNAL OF CARDIOVASCULAR SURGERY. - ISSN 0021-9509. - STAMPA. - 51:(2010), pp. 377-382.

*Availability:*

The webpage <https://hdl.handle.net/2158/402347> of the repository was last updated on 2020-05-15T14:05:48Z

*Terms of use:*

Open Access

La pubblicazione è resa disponibile sotto le norme e i termini della licenza di deposito, secondo quanto stabilito dalla Policy per l'accesso aperto dell'Università degli Studi di Firenze (<https://www.sba.unifi.it/upload/policy-oa-2016-1.pdf>)

*Publisher copyright claim:*

La data sopra indicata si riferisce all'ultimo aggiornamento della scheda del Repository FloRe - The above-mentioned date refers to the last update of the record in the Institutional Repository FloRe

(Article begins on next page)

## Hybrid treatment of aortic arch aneurysms

N. TROISI<sup>1</sup>, G. PRATESI<sup>2</sup>, A. FARGION<sup>1</sup>, W. DORIGO<sup>1</sup>, R. PULLI<sup>1</sup>, M. ACQUAFRESCA<sup>3</sup>, C. PRATESI<sup>1</sup>

**Aim.** Aim of this study was to retrospectively analyze the experience of a single center in the hybrid treatment of aortic arch aneurysms.

**Methods.** From January 2005 to August 2008 a hybrid treatment for complex aortic aneurysms (aortic arch, thoracoabdominal aorta or thoracic and abdominal segments at the same time) was performed in 34 patients. In 11 cases a hybrid exclusion of an aortic arch aneurysm was carried out. Perioperative results in terms of morbidity and mortality were assessed. Follow-up examination consisted of computed tomography scan and chest X-ray at discharge, 6 and 12 months, and yearly thereafter. Mid-term survival and graft-related complications were analyzed.

**Results.** All the patients were males with a mean age of 74 years, range 68-81. Intraoperative technical success was achieved in all the cases. At 30 days one patient died for an acute stroke. The overall 30-day mortality rate was 9.1%. One frenic nerve paralysis and one acute respiratory failure with pneumonia were observed with an overall 30-day major morbidity rate of 18.2%. During follow-up (mean duration 19.3 months, range 1-36) no death, reintervention, conversion, aneurysm-related complication or graft thrombosis were recorded.

**Conclusion.** Hybrid approaches to the treatment of complex aortic lesions involving the arch can be successfully used. However, perioperative complications remain still not irrelevant and long-term efficacy has to be proved.

**KEY WORDS:** Aortic aneurysm, thoracic - Aortic aneurysm, therapy - Aorta, thoracic.

Conventional open surgical repair of aneurysms involving the aortic arch require cardiopulmonary

Received on January 9, 2009.

Accepted for publication on December 15, 2009.

Corresponding author: Nicola Troisi, MD, Department of Vascular Surgery, University of Florence, viale Morgagni 85, 50134 Florence, Italy. E-mail: nicola.troisi@alice.it

<sup>1</sup>Department of Vascular Surgery  
University of Florence, Florence, Italy

<sup>2</sup>Department of Vascular Surgery  
University of Tor Vergata, Rome, Italy

<sup>3</sup>Department of Radiology, Careggi Hospital  
Florence, Italy

bypass and deep hypothermic circulatory arrest;<sup>1, 2</sup> significant morbidity and mortality rates associated with these techniques have kindled interest in the development of alternative treatment modalities.<sup>3, 4</sup>

Endovascular repair is getting used to be a valuable therapeutic alternative in treating high-risk patients with aortic aneurysms. However, a large number of patients with an aortic arch aneurysm is excluded from an endovascular approach because of unfavorable anatomies, particularly for an inadequate proximal landing zone.<sup>5</sup>

The problem to obtain an adequate proximal landing zone and to rescue the supra-aortic vessels represents at the same time a necessity and a challenge for the surgeon. For this reason, many centers investigated the feasibility of different combined open and endovascular approaches in the surgical management of aortic arch aneurysms. These hybrid approaches with open surgical debranching of the supra-aortic vessels followed by the endovascular exclusion of the aneurismal lesion seem to be a suitable and new option in the armamentarium of the surgeon. However, the literature reports significant perioperative morbidity and mortality rates, particularly when a complete surgical debranching of the aorta is necessary.<sup>6-10</sup>

The association of open and endovascular techniques allowed to treat a broader group of patients

who suffered from an aortic arch aneurysm, whose comorbidities made conventional open repair difficult or impossible.

Aim of this study was to retrospectively analyze perioperative and mid-term results of our experience in the hybrid treatment of aortic arch aneurysms.

### Materials and methods

From January 2005 to August 2008, a hybrid treatment for complex aortic aneurysms (aortic arch, thoracoabdominal aorta or abdominal and thoracic segments at the same time) was performed in 34 cases. Eleven patients underwent combined open and endovascular exclusion of their aortic arch aneurysms (32%).

Data concerning all the interventions were prospectively collected in a dedicated database, containing all main pre-, intra- and postoperative clinical, anatomical and technical parameters.

Preoperatively, all the patients underwent an extensive assessment of clinical history and a physical examination, a two-view chest X-ray, an electrocardiogram, laboratory tests including complete blood count, coagulative parameters and blood chemistries and a Duplex ultrasound scanning, reserving the digital subtraction angiography in double projection in selected cases. Moreover, pulmonary functional capacity and response to bronchodilators were investigated and the presence of carbon dioxide retention through arterial blood gas analysis was evaluated.

Patients underwent also a computed tomography (CT) angiography of entire aorta to evaluate the presence of other aortic lesions and to determine the type of repair (assessment of criteria of feasibility for endovascular repair). Finally, all the patients gave their written consent to the procedure.

All the patients of our series were unsuitable for standard endovascular repair, because of the absence of an adequate landing zone (defined as at least 1.5 cm of normal aorta above the beginning of the aneurismal sac).

In all the cases a staged approach was performed (first the surgical debranching followed by the endovascular one).

All the interventions were performed in the operative room under general anesthesia. Somatosensory evoked potentials were used to monitor cerebral status during surgical open intervention and to indicate

TABLE I.—*Preoperative demographic data and comorbidities.*

	N. patients (%)
Age >80 years	2 (18,2%)
Smoking	11 (100%)
Hypertension	9 (81,8%)
Hypercholesterolemia	6 (54,5%)
Diabetes mellitus	2 (18,2%)
Coronary artery disease	5 (45,5%)
Chronic obstructive pulmonary disease	7 (63,6%)
Cerebrovascular disease	3 (27,3%)
Renal chronic failure (serum creatinin value $\geq$ 1.5 mg/dL)	0

when a shunt was necessary. A selective criterion for shunt insertion was used, defined as a reduction of N20/P25 waves higher than 75%.<sup>11</sup>

Heparin and antibiotic prophylaxis were routinely administered in all the cases. After the operations all patients were routinely admitted to the Intensive Care Unit for a postoperative monitoring of cardiac and respiratory functions of at least 24 hours.

Follow-up examination consisted of CT scan and two-view chest X-ray at discharge, at 6 and 12 months, and yearly thereafter.

Statistical analysis was performed by means of SPSS 15.0 for Windows (SPSS Inc., Chicago, IL, USA). General characteristics (demographic data), risk factors, preoperative diagnostic assessment features and intraoperative details were analysed. Perioperative results (<30 days) in terms of technical success, mortality and morbidity were assessed. Mid-term results in terms of survival and graft-related complications were analyzed.

### Results

Patients were all males (11 cases), with a mean age of 74 years (range 68-81); demographic data and comorbidities are listed in Table I.

In all the patients the indication for treatment was the presence of an aortic arch aneurysms larger than 5.5 cm; preoperative mean aneurysm maximum diameter was 61 mm (range 56-68).

On the basis of the American Society of Anesthesiologists (ASA) classification there were two (18.2%) class II patients, eight (72.7%) class III patients and one (9.1%) class IV patient. All the patients were

TABLE II.—*Intraoperative findings.*

	Ishimaru classification	Surgical revascularization	Endovascular exclusion	Delay (days)	N. stent graft
#1	Zone 1	Carotid to carotid and carotid to left subclavian bypass	Staged	17	2
#2	Zone 2	Carotid to left subclavian bypass	Staged	14	2
#3	Zone 2	Left subclavian dislocation	Staged	9	1
#4	Zone 0	Ascending aorta to innominate and left carotid bypass and left carotid to left subclavian bypass	Staged	19	3
#5	Zone 1	Subclavian to subclavian bypass with carotid trasposition	Staged	14	2
#6	Zone 0	Ascending aorta to left common carotid and left subclavian bypass	Staged	18	2
#7	Zone 2	Carotid to left subclavian bypass	Staged	11	1
#8	Zone 1	Carotid to carotid and carotid to left subclavian bypass	Staged	16	2
#9	Zone 2	Carotid to left subclavian bypass	Staged	15	1
#10	Zone 0	Ascending aorta to innominate and left subclavian bypass and left carotid trasposition	(dead patient)	—	—
#11	Zone 0	Ascending aorta to innominate and left carotid bypass and left carotid to left subclavian bypass	Staged	11	3
Tot	—	—	10/10 staged	14.4 (mean)	1.9 (mean)

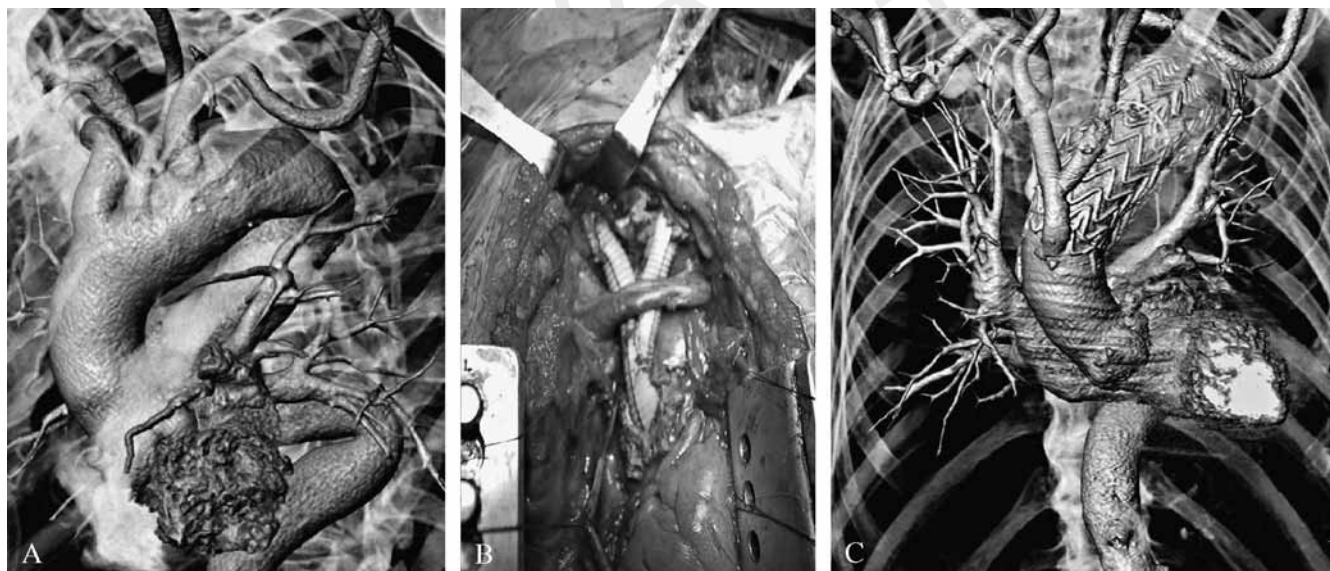


Figure 1.—An aortic arch aneurysm involving zone 0: A) preoperative evaluation, B) intraoperative image, C) CT scan at discharge.

asymptomatic and no intervention was performed in urgency.

#### *Perioperative (<30 days) results*

Different supra-aortic surgical reconstructions were performed to create an appropriate proximal landing zone (Table II). Four patients (36.4%) with

an involvement of zone 0 (according to Ishimaru classification<sup>5</sup>) required a median sternotomy; in these patients graft material used to perform bypasses was Dacron woven, whilst in the remaining ones graft material was standard polytetrafluoroethylene (Figure 1).

Table III shows the involvement of the supra-aortic vessels in the execution of the bypasses. Mean

TABLE III.—*Supra-aortic vessels involved in the bypasses.*

	N. (%)
Ascending aorta	4 (36.4%)
Innominate artery	3 (27.3%)
Right common carotid artery	2 (18.2%)
Right subclavian artery	1 (9.1%)
Left common carotid artery	11 (100%)
Left subclavian artery	11 (100%)

number of bypasses for each patient was 1.7 (range 0-3).

Intraoperative technical and clinical success was obtained in all the patients. After the surgical procedure one patient, with an involvement of zone O and classified in IV class ASA, developed an acute major stroke and died in third postoperative day. The overall 30-day mortality rate was 9.1%. In the perioperative period (<30 days) one frenic nerve paralysis and one acute respiratory failure with pneumonia were observed with an overall 30-day major morbidity rate of 18.2%.

In all the patients a staged endovascular exclusion of the aortic arch aneurysm was performed with a mean delay of 14.4 days (range 9-19). Intraoperative findings are showed in Table II. Intraoperative technical and clinical success was obtained in all the 10 patients. The final completion angiography showed the complete exclusion of the aneurysm in absence of type I/III endoleak. One patient (10%) had a type II endoleak. After the endovascular procedure in the perioperative period (<30 days) no death, conversion or major complication was recorded.

#### *Mid-term results*

During follow-up (mean duration 19.3 months, range 1-36) no death, reintervention, conversion, aneurysm-related complication or graft thrombosis were recorded.

Follow-up imaging demonstrated the complete exclusion of the treated aortic arch aneurysms in absence of any device-related complications. In particular, all the CT reconstructions showed the good patency of supra-aortic revascularizations with the complete exclusion of the lesion, in absence of endoleaks, migrations and stent fractures. Type II endoleak diagnosed at completion angiography was completely and spontaneously resolved at six-month follow-up. No other adverse event was assessed.

## **Discussion**

Aortic arch aneurysms represent a life-threatening condition if they remain untreated. The natural history of aortic arch aneurysms are similar to that of thoracic aortic aneurysms, with a progressive expansion up to the rupture.<sup>12</sup> Risk of rupture for untreated thoracic aortic aneurysms, including also aneurismal lesions of the arch, is of 14% at two years.<sup>13</sup>

Open conventional surgery consists of reconstruction of the aortic arch with the placement of an interposition graft and reimplantation of the supra-aortic vessels; this treatment requires cardiopulmonary bypass and deep hypothermic circulatory arrest. Despite the improvements in anesthesiological and surgical techniques, many series have demonstrated that open conventional surgery is still associated to high perioperative mortality and morbidity rates.<sup>1-4</sup> Mortality remains of about 10% and the risk of stroke, nevertheless brain protection and selective cerebral perfusion, ranges between 3% and 19%.<sup>1-3</sup> Moreover, operative time is very long and hemorrhagic complications are very usual.<sup>2</sup>

In the last few years, with the introduction and improvement of endovascular techniques, a renewed interest in this field has been observed and different therapeutic strategies have been proposed,<sup>5-10, 14-16</sup> in order to reduce perioperative morbidity and mortality rates. For this reason, the branched techniques and the hybrid procedures have emerged.

Branched techniques for the treatment of aortic arch aneurysms have been reported all over the world in a very small number of cases;<sup>14, 15</sup> this therapeutic option ("totally endovascular") has obvious advantages, above all in high-surgical risk patients, but it is still experimental, high complex and available only in few centres. It is strongly limited by anatomical characteristics of the lesions and skillness of the surgical equip; furthermore, long-term results, particularly in relation to possible intracomponent modifications, are still unknown.

On the other hand, the combination of surgical and endovascular procedures ("hybrid techniques") offers the possibility to exclude complex aneurysms from the flow without the surgical replacement of the aortic arch. The main problem of this approach is the necessity to obtain an adequate proximal landing zone for the deployment of the graft and for the accurate exclusion of the aneurismal sac from the blood flow, maintaining a normal cerebral perfusion; according to the

Ishimaru classification,<sup>5</sup> various surgical interventions as first step of a combined procedure have been proposed in Literature, ranging from the total debranching of supra-aortic vessels with sternotomy to the dislocation of the left subclavian artery.<sup>5-10, 16, 17</sup>

Buth *et al.*<sup>17</sup> firstly reported in 1998 a successful hybrid treatment of an aortic arch aneurysm; preliminary encouraging results persuaded many centers to investigate the feasibility of hybrid techniques in order to reduce perioperative risks.

In Literature there was no general agreement on the results of this procedure. Saleh *et al.*<sup>8</sup> reported their experience in the hybrid "staged" treatment of 15 patients suffered from of an aortic arch aneurysm; in their series intraoperative technical and clinical success were achieved in all the cases and after two months one patient died for pulmonary complications after the endovascular step, with an overall mortality of 6.7%.

Melissano *et al.*<sup>9, 18</sup> in two different papers described the results of the treatment of 64 aortic arch aneurysms (in 27 cases a totally endovascular procedure and in the remaining 37 ones a hybrid treatment); in this large group of patients the intraoperative technical and clinical success were of 85.9% and 79.7%, respectively, and the overall 30-day mortality rate was of 6.3%. Moreover, the rate of type I endoleak diagnosed at 30 days was of 12.5%.

Recently, Chan *et al.*<sup>10</sup> reported discouraging perioperative results with the hybrid treatment of aortic arch aneurysms; even if the authors reported no perioperative mortality and they concluded that hybrid procedures in treating aortic arch pathology are safe and effective, they reported at 30 days three major cardiac complications (one of these was a cardiac arrest requiring a resuscitation), five major pulmonary complications (two of these required a temporary tracheostomy) and three debilitating strokes. Moreover, three patients of their series returned to the operative room for a major bleeding.

In our series we described perioperative outcomes similar to those reported in Literature, with overall 30-day mortality and morbidity rates of 9.1% and 18.2%, respectively. In particular, we did report no type I endoleak and we recorded a major stroke with the successive death in one patient requiring a sternotomy for the involvement of the zone 0, with a higher 30-day mortality rate in this zone (1/4 patients, 25%). Some authors<sup>9</sup> analyzed their results according to the different landing zones on the basis of Ishimaru

classification<sup>5</sup> and they reported poorer outcomes in patients with an involvement of zone 0 (2/14 strokes following by death, 14.3%) and zone 1 (4/12 type I endoleaks, 33.3%); they suggested to reserve hybrid treatment when zone 1 is involved only in patients unfit for sternotomy.

Finally, several studies<sup>7-10, 18</sup> reported encouraging mid-term results, with low rates of graft-related complications and a good free-reintervention survival; however, the longer follow-up described in Literature was of 28 months.<sup>9</sup> So, further studies with larger series and longer follow-ups are needed to establish the efficacy of hybrid techniques in the long-term period and it could be worthwhile to have in the future the results of a multicentric study comparing the hybrid vs. conventional repair of aortic arch aneurysms.

## Conclusions

Hybrid approaches to the treatment of complex aortic lesions involving the arch can be successfully used. These techniques allow a broader group of patients suffered from an aortic arch aneurysm to be treated, even if perioperative complications remain still not irrelevant, above all in patients requiring a sternotomy. Moreover, further studies are needed to evaluate the long-term efficacy of these new emerging techniques.

## References

1. Westaby S, Katsumata T. Proximal aortic perfusion for complex arch and descending aortic disease. *J Thorac Cardiovasc Surg* 1998;115:162-7.
2. Svensson LG. Progress in ascending and aortic arch surgery: minimally invasive surgery, blood conservation, and neurological deficit prevention. *Ann Thorac Surg* 2002;74:S1786-8.
3. Appoo JJ, Augoustides JG, Pochettino A, Savino JS, McGarvey ML, Cowie DC *et al.*; Improving Clinical Outcomes Through Clinical Research Investigators. Perioperative outcome in adults undergoing elective deep hypothermic circulatory arrest with retrograde cerebral perfusion in proximal aortic arch repair: evaluation of protocol-based care. *J Cardiothorac Vasc Anesth* 2006;20:3-7.
4. Safi HJ, Miller CC 3rd, Estrera AL, Villa MA, Goodrick JS, Porat E *et al.* Optimization of aortic arch replacement: two-stage approach. *Ann Thorac Surg* 2007;83:S815-8.
5. Ishimaru S. Endografting of the aortic arch. *J Endovasc Ther* 2004;11(Suppl 2):162-71.
6. Criado FJ, Clark NS, Barnatan MF. Stent graft repair in the aortic arch and descending thoracic aorta: a 4-year experience. *J Vasc Surg* 2002;36:1121-8.
7. Bergeron P, Mangialardi N, Costa P, Coulon P, Douillez V, Serreo E *et al.* Great vessel management for endovascular exclusion of aor-

- tic arch aneurysms and dissections. *Eur J Vasc Endovasc Surg* 2006;32:38-45.
8. Saleh HM, Inglese I. Combined surgical and endovascular treatment of aortic arch aneurysms. *J Vasc Surg* 2006;44:460-6.
  9. Melissano G, Civilini E, Bertoglio L, Calliari F, Setacci F, Calori G *et al*. Results of endografting of the aortic arch in different landing zones. *Eur J Vasc Endovasc Surg* 2007;33:561-6.
  10. Chan YC, Cheng SWK, Ting AC, Ho P. Supra-aortic hybrid endovascular procedures for complex thoracic aortic disease: single center early to midterm results. *J Vasc Surg* 2008;48:571-9.
  11. Amantini A, Bartelli M, de Scisciolo G, Lombardi M, Macucci M, Rossi R *et al*. Monitoring of somatosensory evoked potentials during carotid endarterectomy. *J Neurol* 1992;239:241-7.
  12. Juvonen T, Ergin MA, Galla JD, Lansman SL, Nguyen KM, McCullough IN *et al*. Prospective study of the natural history of thoracic aortic aneurysms. *Ann Thorac Surg* 1997;63:1533-45.
  13. Perko MJ, Norgaard M, Herzog TM, Olsen PS, Schroeder TV, Pettersson G. Unoperated aortic aneurysms: a survey of 170 patients. *Ann Thorac Surg* 1995;59:1204-9.
  14. Chuter TA, Schneider DB, Reilly LM, Lobo EP, Messina LM. Modular branched stent graft for endovascular repair of aortic arch aneurysm and dissection. *J Vasc Surg* 2003;38:859-63.
  15. Brar R, Ali T, Morgan R, Loftus I, Thompson M. Endovascular repair of an aortic arch aneurysm using a branched-stent graft. *Eur J Vasc Endovasc Surg* 2008;36:545-9.
  16. Riesenman PJ, Tamaddon HS, Farber MA. Surgical bypass procedures to facilitate endovascular repair of aortic arch pathology. *J Cardiovasc Surg* 2008;49:461-9.
  17. Buth J, Penn O, Tielbeek A, Mersman M. Combined approach to stent-graft treatment of an aortic arch aneurysm. *J Endovasc Surg* 1998;5:329-32.
  18. Melissano G, Bertoglio L, Civilini E, Marone EM, Calori G, Setacci F *et al*. Results of thoracic endovascular endografting in different aortic segments. *J Endovasc Ther* 2007;14:150-7.