



UNIVERSITÀ
DEGLI STUDI
FIRENZE

FLORE

Repository istituzionale dell'Università degli Studi di Firenze

Cilostazol in the prevention of adverse events after femoro-popliteal endovascular procedures: a systematic review and a proposal of a

Questa è la Versione finale referata (Post print/Accepted manuscript) della seguente pubblicazione:

Original Citation:

Cilostazol in the prevention of adverse events after femoro-popliteal endovascular procedures: a systematic review and a proposal of a new protocol / R. Pulli; W. Dorigo; C. Pratesi. - In: ITALIAN JOURNAL OF VASCULAR AND ENDOVASCULAR SURGERY. - ISSN 1824-4777. - STAMPA. - 18:(2011), pp. 161-165.

Availability:

The webpage <https://hdl.handle.net/2158/605858> of the repository was last updated on

Terms of use:

Open Access

La pubblicazione è resa disponibile sotto le norme e i termini della licenza di deposito, secondo quanto stabilito dalla Policy per l'accesso aperto dell'Università degli Studi di Firenze (<https://www.sba.unifi.it/upload/policy-oa-2016-1.pdf>)

Publisher copyright claim:

La data sopra indicata si riferisce all'ultimo aggiornamento della scheda del Repository FloRe - The above-mentioned date refers to the last update of the record in the Institutional Repository FloRe

(Article begins on next page)

Cilostazol in the prevention of adverse events after femoropopliteal endovascular procedures: a systematic review and a proposal of a new protocol

R. PULLI, W. DORIGO, C. PRATESI

*Department of Vascular Surgery
University of Florence, Florence, Italy*

Cilostazol is a phosphodiesterase type III inhibitor with well-known vasodilator and antiplatelet properties. It was tested above all in patients affected by peripheral artery disease (PAD) and it has been included in the suggested pharmacological treatments of these patients in stage II of Fontaine classification.¹

A meta-analysis of eight randomized controlled trials demonstrated that the treatment with cilostazol for 12 up to 24 weeks significantly increased maximal and pain-free walking distance by 50% and 67%, respectively, and improved quality of life measures in patients with PAD.²

More recently it was supposed to have also a role in improving the results after endovascular femoropopliteal revascularizations. Aim of this paper was to systematically review all the articles published in this field and, at the end, to suggest a new protocol of treatment in patient undergone peripheral endovascular procedures.

Materials and methods

Two independent reviewers systematically searched EMBASE, SCOPUS and PubMed for stud-

Received on May 24, 2011.

Accepted for publication on May 25, 2011.

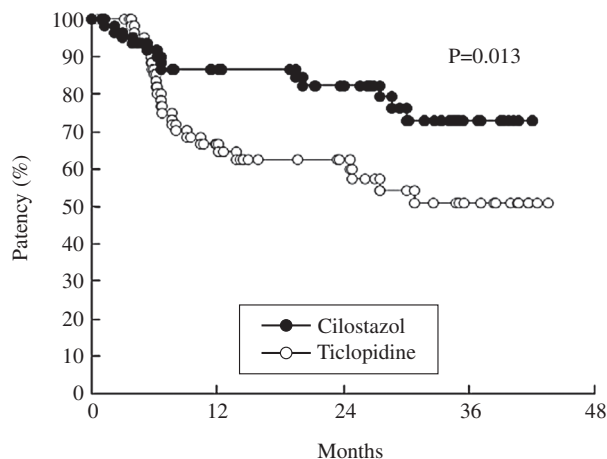
Corresponding author: R. Pulli, Department of Vascular Surgery, University of Florence, Florence, Viale Morgagni 85, 50134, Florence, Italy. E-mail: rpulli@unifi.it

ies comparing cilostazol vs control after peripheral endovascular procedures (keywords: cilostazol, endovascular treatment, restenosis, primary and secondary patency). References of the included studies were systematically scanned to retrieve additional papers.

These studies were divided into prospective and retrospective. Particular attention was paid to the reported outcomes. Freedom from intervention in target lesion (TLR) and in target vessel (TVR) were the most common tools appraised. The patency (primary and secondary) and restenosis rates were also analyzed. Secondary considered outcomes were freedom from major adverse cardiovascular events (MACEs) and freedom from major bleeding.

Freedom from reintervention was defined as the absence of both perioperative and follow-up interventions (open or endovascular) on the same targeted vessel.

Primary patency was defined as **uninterrupted patency** without procedures performed on or at the margin of the treated segment, while secondary patency was defined as restored patency through the original treated segment; restenosis was defined as the occurrence of recurrent lesions at the level of the primary intervention detected at instrumental follow-up methods, requiring or not reintervention.



Ticlopidine	64	42	40	32
Cilostazol	63	54	51	45

Figure 1.—Patency rate in Cilostazol and Control group (from Iida *et al.*, with permission).

MACEs were defined as any death, myocardial infarction, stroke, percutaneous or surgical repeated revascularization, and leg amputation occurring during follow-up; major bleeding was defined as any bleeding requiring hospitalization.

Results

Prospective studies

Two prospective randomized studies were identified.^{3, 4} Both were open label studies carried out among Japanese people. The sample size was small and the study setting was quite similar in both researches (Table I). In the paper of Iida *et al.*³ the authors treated patients in Stage II, III and IV of Fontaine’s classification. Most lesions were in TASC C and D classes and involved the superficial femoral artery with variable run-off status. Previous open surgery or endovascular procedures in the same area

were exclusion criteria. Stent implantation was used in about 90% of cases. Bleeding complication rate was low. All these characteristics did not differ between the two groups of treatments. Primary patency, considered the primary end-point of the study, was reported significantly higher in the Cilostazol group than in control group (Figure 1). In details, patency rates at 12, 24, and 36 months were 87%, 82%, and 73% in the Cilostazol group and 65%, 60%, and 51% in control group (P=0.013). Freedom from target lesion revascularization (secondary end point) at 12, 24, and 36 months was significantly higher in the Cilostazol group than in the control group (88%, 82%, and 82% vs 73%, 70%, and 58%; p=0.036) as well.

In the second study, from Soga *et al.*,⁴ only claudicants were included and in spite of a low incidence of chronic occlusion, the majority of the lesions were classified in C and D TASC classes. Stenting was performed in 36 patients (Cilostazol group, 16; Control group, 20; P=0.36), and the use of different commercially available stents was similar between the two groups. Any major bleeding was recorded in both groups. During the 2-year observation period restenosis was found in 43 (55.1%) patients (cilostazol, 43.6% [17 of 39]; control, 70.3% [26 of 37]; P=0.02), and 8 had complete occlusion (cilostazol, 5.1% [2 of 39]; control, 16.2% [6 of 37]; P=0.12). After 24 months, the freedom from TLR and TVR was significantly higher in the cilostazol group than in the control group (87.2% vs. 67.6%, P=0.05; 84.6% vs. 62.2%, P=0.04, respectively) (Figure 2). The freedom from MACE was also significantly higher in the cilostazol group compared with the control group (79.5% vs. 48.7%, P=0.006). There were no significant differences in death, MI, stroke, and leg amputation between the 2 groups; however, repeated revascularization rate was significantly lower in the cilostazol group than in the control group (18.0% [7 of 39] vs. 43.6% [17 of 39], P=0.014).

A summary of the primary end-points of both studies is reported in Table II.

TABLE I.—Prospective randomized open label studies found in literature.

Authors	Year	Pts	Setting	Comparison	Follow-up	Bias
Iida <i>et al.</i> ³	2008	127	De novo fem-pop lesions	Cilostazol 200 mg/d (63) or Ticlopidine 200 mg/d (64) in addition to ASA 100 mg/d	3 years	Low
Soga <i>et al.</i> ⁴	2009	80	De novo fem-pop lesions	Cilostazol 200 mg/d (40) for 2 yrs or Ticlopidine 200 mg/d (40) for 4 weeks in addition to ASA 100 mg/d	2 years	High

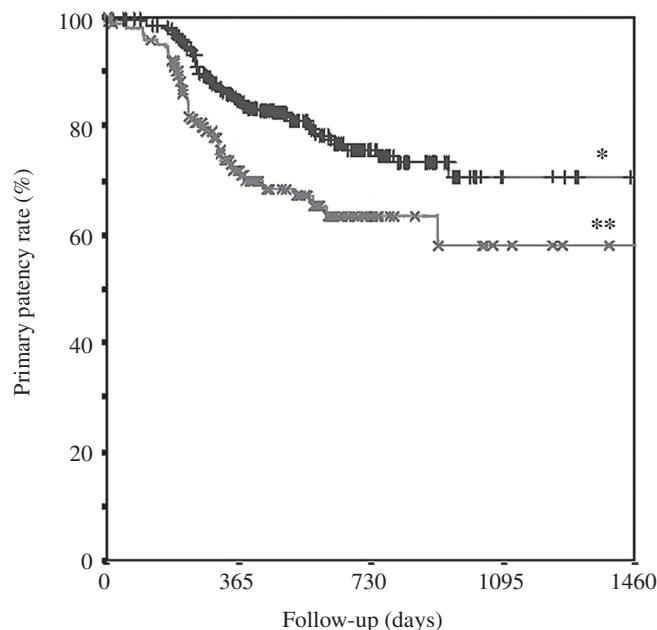


Figure 2.—Estimated (Kaplan-Meier curve) primary patency in J-SMART Registry in patients treated or not with cilostazol P<0.001 (Modified from Suzuki *et al.*). *Cilostazol. **Noncilostazol.

Retrospective studies

From the same Japanese Authors we identified two other retrospective studies.^{5,6} These studies were published very recently and involved several Japanese institutions in multicenter researches. Soga *et al.*⁵ included in their study 511 patients treated with nitinol stent in superficial femoral artery (SFA) disease; they were mainly claudicants and equally distributed in Fontaine’s classes. As far as pharmacological therapy is concerned, all patients assumed indefinitely ASA 100 mg/day and at least for one month after the procedure Clopidogrel 75 mg/day or Ticlopidine 200 mg/day. Patients who had received Cilostazol before the procedure continued the same treatment after revascularization. Main outcomes of the study were

primary and secondary patency. At univariate and multivariate analysis the authors found Cilostazol as independent predictor of primary and secondary patency in patients with a successful procedure.

The second study, from Suzuki *et al.*⁶, is an ongoing publication and repeats the above-described research. The authors enrolled 432 patients in a so-called J-SMART registry; all subjects were affected by a *de-novo* lesion in SFA and were treated with the same nitinol stent. Also in this study all patients received aspirin (100 mg/day) indefinitely and cilostazol or ticlopidine (200 mg/day) for at least 4 weeks. They divided their patients on the basis of the presence of restenosis at a minimum follow-up of 6 months; factors investigated included major adverse events (death, major amputation, target lesion revascularization), staging of PAD according to the Rutherford classification, ankle brachial index (ABI) score, lesion patency as evaluated on duplex ultrasonography and stent fracture as assessed on radiography. Re-stenosis was defined as a peak systolic velocity ratio of ≥ 2.4 on Duplex ultrasonography, which was considered indicative of a >50% narrowing. A complete absence of detectable signal was graded as complete occlusion. They found that no cilostazol administration, female gender, younger age, and chronic total occlusion (CTO) were independent predictors for re-stenosis. We reported (with permission) the estimated rate of primary patency in patients treated or not with Cilostazol (Figure 2).

Discussion

Cilostazol is a well-known phosphodiesterase type III inhibitor with vasodilator and antiplatelet properties. Its efficacy in improving walking distance in claudicants has been well demonstrated⁷ and its use in this setting of patients is recommended in TASC II consensus.¹

After endovascular revascularization cilostazol

TABLE II.—Outcome from the two prospective randomized studies.

Authors	Pts	Num	Freedom from reintervention	P	Patency/Restenosis	P	Follow-up
Iida O, 2008 ³	IC 45	63 CIL	82%	0.03	73%	0.01	3 yrs
	IC 50	64 CTR	58%		51%		
Soga Y, 2009 ⁴	IC	40 CIL	84.6%	0.04	70.3%	0.02	2 yrs
		40 CTR	62.2%		43.6%		

CIL: cilostazol group; CTR: control group.

has been tested in coronary artery disease and a systematic review in this field⁸ concluded that cilostazol appears to be effective and safe in reducing the risk of restenosis and repeated revascularization after percutaneous coronary interventions, even if the available evidence is limited by small study effects.

One must consider, however, that we are facing two different fields of application of this drug and that the myocardial district has different physiological and hemodynamic properties from those in lower limb tissues; this fact can explain the effectiveness of drug-eluting stents (DES) in coronary arteries in comparison with systemic therapy, whereas the same results has not been achieved in lower limb revascularizations, yet.⁹ These potential confounding factors and the above cited lack of appositely designed studies represent the main causes of the weakness found when we try to appraise the use of cilostazol after femoro-popliteal revascularization. Very few papers are present in Literature and only two prospective randomized studies investigated the benefit of this drug in improving the outcomes after endovascular procedures in SFA.

The limitations of these studies are well reported by the same Authors: small sample size; open-label randomization. In spite of these limitations, both researches led to the same results: reduction of the rates of restenosis and reintervention in the groups of patients undergoing treatment with cilostazol. The meaning of these results are still debated. In a Letter to editor, Dindyal S *et al.*¹⁰ expressed concerns about the reproducibility of the results achieved in a Japanese community also in the western world. However, awaiting larger randomized clinical trials, this less expensive treatment could be envisaged in selected patients to prevent the development of neointimal hyperplasia. In fact, there are several possible reasons why oral administration of cilostazol reduced restenosis. First, cilostazol is a stronger antiplatelet agent than aspirin, dipyridamole, and ticlopidine.^{11, 12} The TASC II guidelines¹ also recommend oral administration of antiplatelet agents to prevent early occlusion by thrombus at the treated site. A second reason is the reduction of restenosis caused by proliferation of neointima. A clinical study has shown cilostazol-associated suppression of neointimal hyperplasia.¹³ A third reason for the effect of cilostazol may be the reduction in symptoms due to vasodilation induced by continuous relaxation of vascular smooth muscle. Several studies have reported that oral administra-

tion of cilostazol improves the walking distance and symptoms of PAD patients,⁸ and vasodilation may contribute to reduction of repeat revascularization.

In spite of these limited evidences, several questions raise in the evaluation of this topic. First, should cilostazol be administered in all the patients operated on with femoro-popliteal endovascular procedures? If negative, which subgroups of patients mainly would benefit from such a treatment? Which is the confounding role (if it exists) of concomitant medications and drugs? Does the effect of cilostazol substantially change in claudicants rather than in patients with critical limb ischemia? Is it better to administer cilostazol to all our patients or only in patients at higher risk of thrombosis (i.e. in the presence of mild-to-moderate restenosis)? As you can see, the questions are several and, in the absence of further, large and well-designed studies, a certain answer is still impossible. In the attempt of finding a solution to these problems, we will be using in next months in our Institution a new formal protocol of treatment in patients with PAD undergoing endovascular treatment as briefly reported below.

Proposal of a new protocol after femoral endovascular procedures

On the basis of the results of this systematic review, we are going to start with a new protocol of treatment after percutaneous endovascular revascularization in the femoro-popliteal area.

At the moment, we are used to performing a double antiaggregation therapy (ASA 100 mg/day and Clopidogrel 75 mg/day) that starts 1 day before the procedure and continues for at least 6 months. We propose to use Cilostazol (200 mg/day), as adjunctive drug, in a triple antiaggregation arm, in comparison with the standard protocol in the aim to reduce restenosis and improving primary patency at 6 months.

Conclusions

Cilostazol seems to be safe after femoral endovascular revascularization. It has multiple effects, such as inhibition of platelet activation, vasodilation and antiproliferation of vascular smooth muscle cells. These effects may lead to the inhibition of neointimal hyperplasia after stent placement in the femoral

lesions. Few data do exist in Literature to support its effectiveness in the prevention of early and follow-up adverse events. Larger study are needed to determine whether cilostazol can be considered as a first-line oral therapy after endovascular procedures for this kind of lesions.

References

1. Norgren L, Hiatt WR, Dormandy JA, Nehler MR, Harris KA, Fowkes FG *et al.* Inter-Society Consensus for the Management of Peripheral Arterial Disease (TASC II). *Eur J Vasc Endovasc Surg* 2007;33 (Suppl 1):S1-75.
2. Thompson PD, Zimet R, Forbes WP, Zhang P. Meta-analysis of results from eight randomized, placebo-controlled trials on the effect of cilostazol on patients with intermittent claudication. *Am J Cardiol* 2002;90:1314-9.
3. Iida O, Nanto S, Uematsu M, Morozumi T, Kitakaze M, Nagata S. Cilostazol reduces restenosis after endovascular therapy in patients with femoropopliteal lesions. *J Vasc Surg* 2008;48:144-9.
4. Soga Y, Yokoi H, Kawasaki T, Nakashima H, Tsurugida M, Hikichi Y *et al.* Efficacy of cilostazol after endovascular therapy for femoropopliteal artery disease in patients with intermittent claudication. *J Am Coll Cardiol* 2009;53:48-53.
5. Soga Y, Iida O, Hirano K, Yokoi H, Nanto S, Nobuyoshi M. Mid-term clinical outcome and predictors of vessel patency after femoropopliteal stenting with self-expandable nitinol stent. *J Vasc Surg* 2010;52:608-15.
6. Suzuki K, Iida O, Soga Y, Hirano K, Inoue N, Uematsu M *et al.* Long-Term Results of the S.M.A.R.T. Control(TM) Stent for Superficial Femoral Artery Lesions, J-SMART Registry. *Circ J* 2011;75:939-44..
7. Robless P, Mikhailidis DP, Stansby GP. Cilostazol for peripheral arterial disease. *Cochrane Database of Systematic Reviews* 2008, Issue 1. Art. No.: CD003748. DOI: 10.1002/14651858.CD003748.pub3
8. Biondi-Zoccai GGL, Lotrionte M, Anselmino M, Moretti C, Agostoni P, Testa L *et al.* Systematic review and meta-analysis of randomized clinical trials appraising the impact of cilostazol after percutaneous coronary intervention. *Am Heart J* 2008;155:1081-9
9. Schömig A, Kastrati A, Wessely R. Prevention of restenosis by systemic drug therapy: back to the future? *Circulation* 2005;112:2759-61.
10. Dindyal S, Sharma P, Kyriakides C. Regarding "Cilostazol reduces restenosis after endovascular therapy in patients with femoropopliteal lesions". *J Vasc Surg* 2008;48:1357; author reply 1357
11. Kimura Y, Tani T, Kanbe T, Watanabe K. Effect of cilostazol on platelet aggregation and experimental thrombosis. *Arzneimittelforschung*. *Drug Res* 1985;35:1144-9.
12. Ikeda Y, Kikuchi M, Murakami H, Satoh K, Murata M, Watanabe K *et al.* Comparison of the inhibitory effects of cilostazol, acetylsalicylic acid and ticlopidine on platelet functions ex vivo. *Arzneimittelforschung Drug Res* 1987;37:563-6.
13. Kubota Y, Kichikawa K, Uchida H, Maeda M, Nishimine K, Makutani S *et al.* Pharmacologic treatment of intimal hyperplasia after metallic stent placement in the peripheral arteries. *Invest Radiol* 1995;30:532-7.