



UNIVERSITÀ
DEGLI STUDI
FIRENZE

FLORE

Repository istituzionale dell'Università degli Studi di Firenze

The importance of patient selection in the treatment of distal hypospadias using modified Koff procedure

Questa è la Versione finale referata (Post print/Accepted manuscript) della seguente pubblicazione:

Original Citation:

The importance of patient selection in the treatment of distal hypospadias using modified Koff procedure / O. Adorisio; A. Elia; L. Landi; Maria Taverna; V. Malvasio; F. D'Asta; D.A. Danti. - In: JOURNAL OF PEDIATRIC UROLOGY. - ISSN 1477-5131. - STAMPA. - 3:(2010), pp. 139-142.

Availability:

The webpage <https://hdl.handle.net/2158/608220> of the repository was last updated on

Terms of use:

Open Access

La pubblicazione è resa disponibile sotto le norme e i termini della licenza di deposito, secondo quanto stabilito dalla Policy per l'accesso aperto dell'Università degli Studi di Firenze (<https://www.sba.unifi.it/upload/policy-oa-2016-1.pdf>)

Publisher copyright claim:

La data sopra indicata si riferisce all'ultimo aggiornamento della scheda del Repository FloRe - The above-mentioned date refers to the last update of the record in the Institutional Repository FloRe

(Article begins on next page)



ELSEVIER

The importance of patient selection in the treatment of distal hypospadias using modified Koff procedure

Ottavio Adorisio^{a,*}, Antonio Elia^{b,1}, Luca Landi^{b,2}, Maria Taverna^{b,1},
Valeria Malvasio^{b,1}, Federica D'Asta^{b,1}, Dante Alfredo Danti^{b,3}

^a Pediatric Surgery Unit, "Bambino Gesù" Children's Hospital, Via della Torre di Palidoro, Palidoro, 00050 Rome, Italy

^b Pediatric Urology Unit, "Anna Meyer" Children's Hospital, Viale Pieraccini 24, 50144 Florence, Italy

Received 26 March 2009; accepted 26 June 2009

Available online 4 August 2009

KEYWORDS

Koff procedure;
Hypospadias;
Urethral advancement

Abstract *Objective:* We present our experience in the treatment of distal hypospadias using a modified Koff procedure, emphasizing the importance of patient selection for a good outcome. *Materials and methods:* In 2003–2008, 90 patients, mean age 52.1 months, underwent surgical repair of distal hypospadias using urethral advancement according to Koff, modified with a Ψ incision on the tip of the glans. Meatal defect was glanular in six (8%), subglanular in 24 (26%) and coronal in 60 (66%) cases. Mild chordee was present in 19 patients (21%). Follow-up was 8–66 months. All patients were evaluated in terms of cosmetic results, and early and late postoperative complications. *Results:* All patients showed excellent cosmetic results with urethral meatus on the tip. There was only one postoperative fistula due to extensive use of electrocautery during urethral mobilization that was surgically corrected 8 months after appearance. One patient had a postoperative meatal stenosis treated conservatively. No cases of residual chordee were detected. *Conclusions:* Successful use of the modified Koff procedure depends on careful selection of patients. Good candidates are those with distal or mid-shaft hypospadias, presenting with: (1) absence or low degree of ventral chordee; (2) distal plate of urethra well developed; (3) distance between meatus and tip of glans at most 10–12 mm; and (4) glanular morphology preserved.
© 2009 Journal of Pediatric Urology Company. Published by Elsevier Ltd. All rights reserved.

* Corresponding author. Tel.: +39 347 5512447; fax: +39 06 68593373.

E-mail addresses: o.adorisio@yahoo.it (O. Adorisio), a.elia@meyer.it (A. Elia), l.landi@meyer.it (L. Landi), maria.taverna@meyer.it (M. Taverna), v.malvasio@meyer.it (V. Malvasio), f.dasta@meyer.it (F. D'Asta), a.danti@meyer.it (D. Alfredo Danti).

¹ Tel.: +39 055 5662414.

² Tel.: +39 055 5662437.

³ Tel.: +39 055 5662530.

Introduction

Hypospadias is the most common urethral anomaly in boys with an incidence of one out of every 300 boys [1]. More than 200 methods of original surgery have been suggested for the treatment of hypospadias, each termed differently. Some methods do not produce appreciable cosmetic or functional results, leading to many complications, so that

the possibility of fistula occurrence is 5–15% and there is also the chance of recurrence [2].

Urethral advancement for treatment of hypospadias has been advocated since 1898. In 1986, Koff established the technical principles of urethral advancement [3]. According to our experience, urethral advancement is an excellent surgical option in cases of distal or mid-shaft hypospadias that does not require any sutures, reducing the incidence of fistulae, but its application must be reserved to selected cases that meet certain criteria (Fig. 1):

- absence or mild degree of chordee
- meatus at most 10–12 mm from the tip of the glans
- mild degree or total absence of distal chordee
- a well-developed glans.

Materials and methods

From January 2003 to June 2008, 90 male patients with a mean age of 52.1 months (range 18–72 months) underwent surgical repair of distal hypospadias. Meatal defect was glanular in six cases (8%), subglanular in 24 (26%) cases and coronal in 60 cases (66%). All patients presented with well-developed glans and distal urethral plate. We routinely created an artificial erection in every patient in order to evaluate the presence of ventral curvature. Chordee was present in 19 patients (21%) and was mild in all of them. The remaining 71 patients (79%) did not show any degree of chordee.

A traction suture was used on the tip of the glans. A circumcision incision was made about 4–5 mm proximal to the corona dorsally, while ventrally the incision was made proximal to the urethral meatus preserving the distal urethral plate.

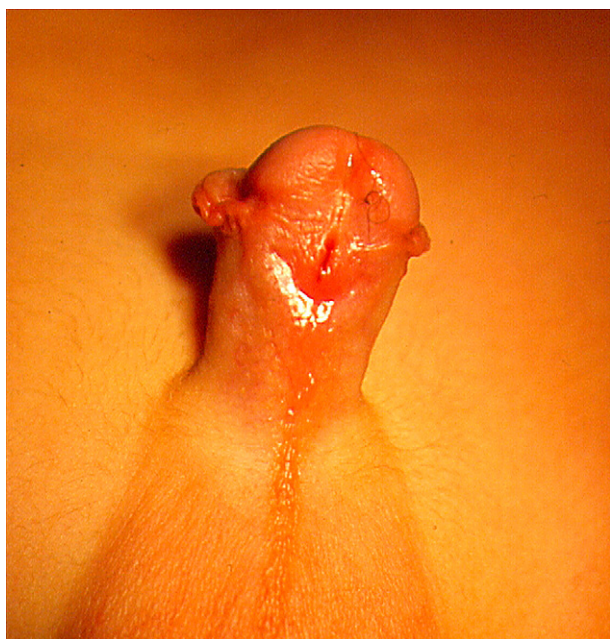

Figure 1 Preoperative photograph, showing characteristics of patients included in the study.

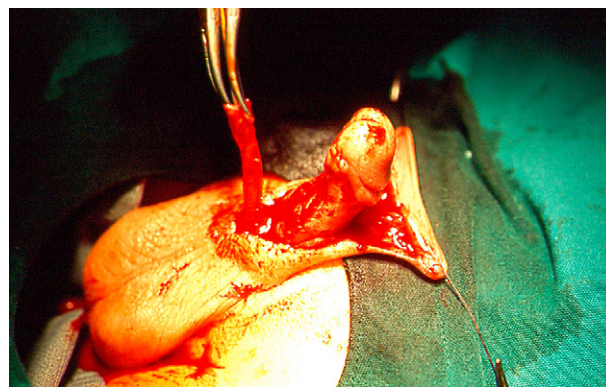


Figure 2 Urethral mobilization after degloving.

The penile skin was degloved down to the penoscrotal junction, releasing any fibrous tissues responsible for curvature. The dissection began proximally in the avascular plane between the corpora cavernosa and the corpus spongiosum. Dissection was maintained above the tunica albuginea covering each corpus cavernosum. Any kind of chordee was removed during degloving and urethral mobilization (Fig. 2).

The urethral meatus along with fanned out and divergent distal corpus spongiosum was surrounded by sharp dissection and mobilized. The avascular plane between the corpora cavernosa and corpus spongiosum was developed and maintained proximally using the indwelling catheter for gentle counter-traction. A 'Ψ' incision on the distal portion of the glans associated to a deep incision of the distal urethral plate was performed (Fig. 3), in order to place the urethra inside (Figs. 4 and 5).

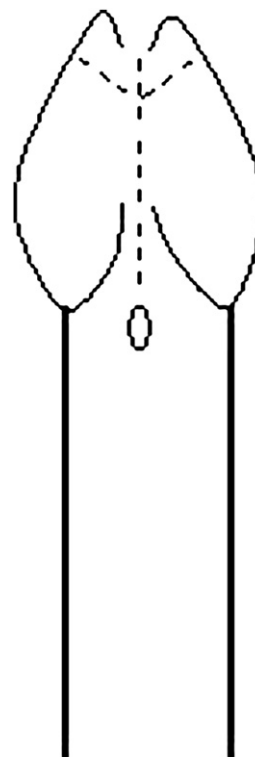


Figure 3 Ψ incision of the glans.

All patients were operated under general anaesthesia plus caudal block. All patients received oral administration of antibiotic for 6 days. Urethral catheter was removed after 4 days.

Results

Follow-up ranged from 8 to 66 months. Mean follow up was 36 ± 15 months. Early postoperative period was characterized in 30 patients (33%) by mild penile oedema that solved spontaneously in a few days. Only one patient (1.1%) showed a postoperative fistula due to extensive use of electrocautery during urethral mobilization that was surgically corrected 8 months after its appearance. One postoperative meatal stenosis (1.1%) was detected and treated conservatively with calibrations. On physical examination we checked position of the meatus, residual curvature and global cosmetic results. No recurrent penile curvature was noted. All patients showed a straight penis. During follow up, all parents were also asked about erection effects, and no cases of residual or de-novo chordee have been reported. All patients showed excellent cosmetic results with urethral meatus on the tip of the glans.

Discussion

Hypospadias is one of the most common genital anomalies. The meatus can be located at any point from just off the tip of the glans to the perineum. In 65% of all cases the hypospadias is located distally. Of these, 15% are glanular, 50% coronal, 30% subcoronal, and 5% are of the mega-meatus intact prepuce type [1].

Many techniques have been described to correct anterior hypospadias. Despite the satisfactory cosmetic appearance achieved using a ventral penile skin flap, as in the Mathieu procedure [4] and its modifications [5,6], or obtaining a neo-urethra as in the Duplay technique, most of these techniques may lead to a precarious blood supply

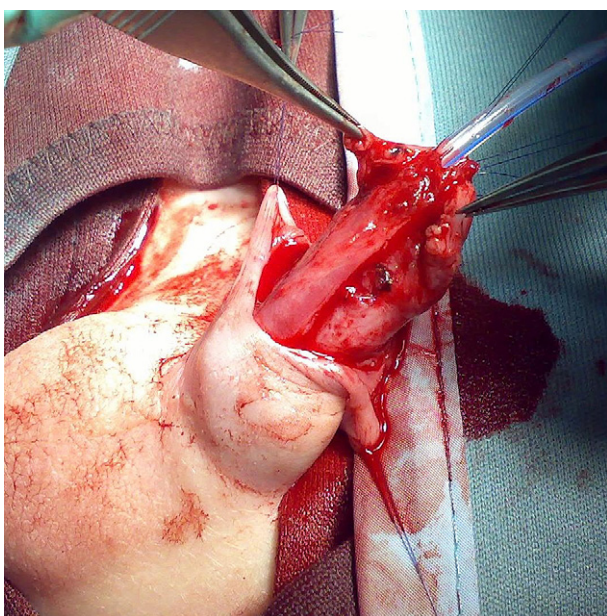


Figure 4 The neo-urethra positioned in the new gland.

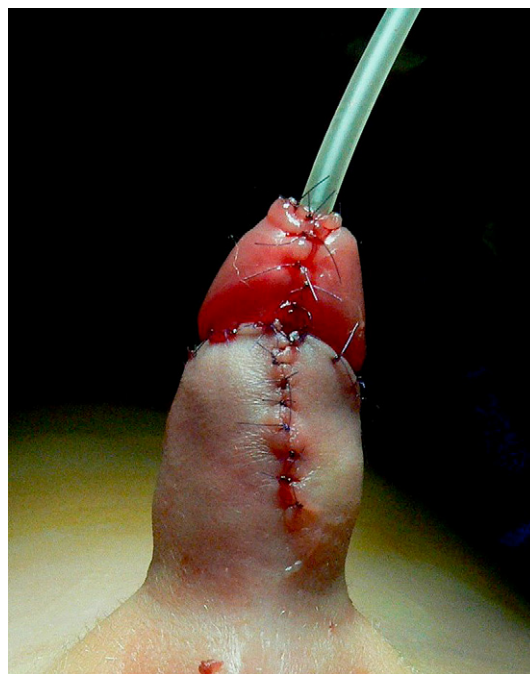


Figure 5 Final result.

[7,8]. For these reasons the most frequent complications are fistulae, meatal regression and stenosis [9,10].

The main advantage of urethral advancement according to Koff is the absence of sutures resulting in a lower incidence of fistulae. This technique, based on a procedure first described by Beck [11], allows the correction of almost all coronal and subcoronal hypospadias with no formation of a tubularized urethra or use of any flap.

The urethra is mobilized partly down to the penoscrotal junction or bulbar region [12–16]. After mobilization, the urethra is placed over the corpora cavernosa through the ventrally incised glans.

One of the advantages of this method is correcting hypospadias without a new urethra. With this technique, anastomosis does not take place and there is no suture line. Therefore, there is no chance of fistula. However in our series of patients we observed one case of fistula (1.1%) due to extensive use of electrocautery during urethral mobilization. This complication was treated surgically 8 months after its appearance.

For these reasons dissection of urethra from the corpora cavernosa must be performed carefully, maintaining the integrity of the corpus spongiosum and its vascular supply.

The most frequent complication of this technique is meatal stenosis. From our experience, to avoid this complication a Ψ incision of the glanular tissue is useful, where the distal portion of the urethra may be placed. This allows prevention of meatal stenosis, obtaining a wide orifice. Paparel *et al.* [17], in a series of 26 patients, reported an incidence of 19.2% for meatal stenosis, while two out 21 patients (9.5%) treated by Koff [3] manifested complications. Two other works by Atan *et al.* [18] and Hamdy *et al.* [19] reported respectively 23% and 5% of meatal stenosis after application of the Koff procedure. In our series only one postoperative stenosis (1.1%) was seen and was treated conservatively with calibrations.

Proper urethral mobilization, deep interbalanitic incision and wide dissection of the glans laterally are essential to avoid other complications such as curvature, glanular disruption and meatal retractions.

Distance between meatus and the tip of the glans must not exceed 10–12 mm because urethral advancement may produce tension on the corpus spongiosum leading to a ventral curvature. During follow up, all parents were asked about erection after surgical correction, and no case of residual curvature of the penis has been reported. This may be due to the fact that patients who did not meet our criteria were excluded from the study.

We found that complete penile urethral length mobilization allows tension-free urethral anastomosis in cases of anterior hypospadias.

Mollaeian *et al.* [20], despite using a similar technique, reported two cases of persistent curvature owing to inappropriate case selection, while application of the Y–V technique to those patients with anterior hypospadias seems to be effective with good cosmetic results and fewest complications [16].

Conclusions

From our experience, urethral advancement according to Koff is a valuable technique for surgical correction of distal forms of hypospadias. In order to avoid meatal stenosis a Ψ incision may be useful. The absence of sutures leads to a low risk of fistulae. Final result depends however on the careful selection of patients.

Financial disclosure and conflict of interest

I certify that all conflicts of interest, including specific financial interests and relationships and affiliations relevant to the subject matter or materials discussed in the manuscript (eg, employment/affiliation, grants or funding, consultancies, honoraria, stock ownership or options, expert testimony, royalties, or patents filed, received, or pending), are the following: None.

Funding/support and role of the sponsor

None.

References

- [1] Seibold J, Boehmer A, Verger A, Merseburger AS, Stenzl A, Sievert KD. The meatal mobilization technique for coronal/subcoronal hypospadias repair. *BJU Int* 2007;100:164–7.
- [2] Duckett JW. Hypospadias. In: Walsh PC, Retika AB, Vaughan ED, editors. *Campbell's urology*. 7th ed. Pennsylvania: W.B. Saunders; 1998. p. 2093–116.
- [3] Koff SA. Mobilisation of the urethra in the surgical treatment of hypospadias. *J Urol* 1981;125:394.
- [4] Mathieu P. Traitement en un temps de l'hypospadias balanique et juxtabalanique. *J Chir* 1932;39:481.
- [5] Barcat J. Current concepts of treatment. In: Horton CE, editor. *Plastic and reconstructive surgery of the genital area*. Boston: Little Brown and Co.; 1973.
- [6] Mustarde JC. One-stage correction of distal hypospadias and other people's fistulae. *Br J Plast Surg* 1965;18:413.
- [7] Duckett JW. MAGPI (meatoplasty and glanuloplasty): a procedure for subcoronal hypospadias. *Urol Clin North Am* 1981;8:513.
- [8] Meyer-Junghanel L, Petersen C, Mildenerger H. Experience with repair of 120 hypospadias using Mathieu's procedure. *Eur J Pediatr Surg* 1995;5:355.
- [9] Atala A. Urethral mobilization and advancement for midshaft to distal hypospadias. *J Urol* 2002;168:1738.
- [10] Unluer ES, Miroglu C, Ozdiler E, Ozturk R. Long term results of the MAGPI (meatal advancement and glanuloplasty) operations in distal hypospadias. *Int Urol Nephrol* 1991;213:581.
- [11] Beck C. A new operation for balanic hypospadias. *N Y Med J* 1898;67:147.
- [12] Baran NK. Urethral advancement for distal hypospadias repair in circumcised patients. *Plast Reconstr Surg* 1982;70:496.
- [13] Caione P, Capozza N, De Gennaro M, Creti G, Zaccara A, Lais A. Distal hypospadias repair by urethral sliding advancement and Y–V glanuloplasty. *J Urol* 1991;146:644.
- [14] Haberialik A, Schmidt B, Uray E, Mayr J. Hypospadias repair using a modification of Beck's operation: follow-up. *J Urol* 1997;157:2308.
- [15] Dindar H, Cakmak M, Yucesan S, Barlas M. Distal penile hypospadias repair in children, with complete mobilization of pendulous urethra and triangular glandular flap. *Br J Urol* 1995;75:94.
- [16] Roodsari SS, Mollaeian M, Hiraifar M. Urethral advancement and glanuloplasty with V flap of the glans in the repair of anterior hypospadias. *Asian J Surg* 2006;29:180.
- [17] Paparel P, Mure PY, Garignon C, Mouriquand P. Translation uréthrale de Koff: à propos de 26 hypospades présentant une division distale du corps spongieux. *Prog Urol* 2001;11:1327.
- [18] Atan A, Yildiz M, Aydoğanlı L, Başar H, Basar M, Akalin Z. Urethral sleeve advancement in repairment of distal hypospadias. *Arch Ital Urol Androl* 1996;68:103.
- [19] Hamdy H, Awadhi MA, Rasromani KH. Urethral mobilization and meatal advancement: a surgical principle in hypospadias repair. *Pediatr Surg Int* 1999;15:240.
- [20] Mollaeian M, Sheikh M, Tarlans S, Shojaei H. Urethral mobilization and advancement with distal triangular urethral plate flap for distal and select cases of mid shaft hypospadias: experience with 251 cases. *J Urol* 2008;180:290.