



UNIVERSITÀ
DEGLI STUDI
FIRENZE

FLORE

Repository istituzionale dell'Università degli Studi di Firenze

Iterative surgical resection of a recurrent gallbladder carcinoma with long-term survival: report of a case.

Questa è la Versione finale referata (Post print/Accepted manuscript) della seguente pubblicazione:

Original Citation:

Iterative surgical resection of a recurrent gallbladder carcinoma with long-term survival: report of a case / Scaringi S; Nesi G; Bargellini T; Batignani G; Tonelli F.. - In: IN VIVO. - ISSN 0258-851X. - STAMPA. - 24:(2010), pp. 215-217.

Availability:

This version is available at: 2158/632685 since:

Terms of use:

Open Access

La pubblicazione è resa disponibile sotto le norme e i termini della licenza di deposito, secondo quanto stabilito dalla Policy per l'accesso aperto dell'Università degli Studi di Firenze (<https://www.sba.unifi.it/upload/policy-oa-2016-1.pdf>)

Publisher copyright claim:

(Article begins on next page)

Iterative Surgical Resection of a Recurrent Gallbladder Carcinoma with Long-term Survival: Report of a Case

STEFANO SCARINGI, GABRIELLA NESI, TATIANA BARGELLINI,
GIACOMO BATIGNANI and FRANCESCO TONELLI

University of Florence Careggi University Hospital, Italy

Abstract. *Gallbladder carcinoma is a rare, but often lethal disease. Unfortunately, at the time of diagnosis, patients usually have advanced disease (T3-T4) and long-term survival is dismal, ranging from 5 to 12% in the literature. However, this cancer can be successfully treated when the tumour is organ-confined (T1-T2 tumours), as happens in the case of incidental diagnosis at the time of cholecystectomy for gallstones. Here we describe a patient with recurrent gallbladder carcinoma who, treated with iterative surgical resection, is alive and disease-free at 5 years after the final surgical procedure.*

Gallbladder carcinoma is a rare, but often lethal disease. It represents the fifth most common gastrointestinal malignancy and the most common biliary tract cancer. Considering the ineffectiveness of chemotherapy and radiotherapy as first-line treatment, surgery remains the only chance for cure. Unfortunately, at the time of diagnosis, patients usually have advanced disease (T3-T4) and, despite technological improvements in hepato-biliary surgery, only 15-47% are candidates for resection (1-3). Overall long-term survival is dismal, ranging from 5 to 12% in the literature (4). However, this cancer can be successfully treated when the tumour is organ-confined (T1-T2 tumours), as happens in the case of incidental diagnosis at the time of cholecystectomy for gallstones. Conversely, when recurrence takes place, prognosis is very poor, and no survival beyond 5 years is reported (5).

We describe the case of a patient affected with recurrent gallbladder carcinoma who, treated with iterative surgical resection, is alive and disease-free at 5 years after the final surgical procedure.

Correspondence to: Stefano Scaringi, MD, University of Florence Careggi University Hospital, Italy. e-mail: stefano.scaringi@unifi.it

Key Words: Gallbladder carcinoma, metachronous metastasis, long-term survival.

Case Report

A 73-year-old woman presented in October 2001 with abdominal pain. For 3 months she had been suffering from steady pain, episodically acute, located in the upper right abdominal quadrant, which gradually subsided after a few hours. It was associated with vomiting, but with no fever or jaundice. She did not complain of loss of appetite or weight, nor changes in bowel habits. Her past history was unremarkable.

On physical examination, the abdomen was tender to palpation in the epigastric and upper right quadrant. Murphy's sign was negative. The leukocyte count, serum bilirubin, alkaline phosphatase and amylase were within normal values. Sonography showed multiple gallstones without thickening of the gallbladder wall or dilatation of the common bile duct. One week later, elective laparoscopic cholecystectomy was carried out. The gallbladder was not opened during the procedure, but extracted through an endobag. No frozen sections were performed. Pathological examination revealed the presence of a polypoid tumour of 2 cm in diameter, located in the fundus of the gallbladder, corresponding to a poorly differentiated adenocarcinoma infiltrating the muscle layer (pT2/Nx/Mx) (Figure 1A).

Liver resection of the gallbladder bed and lymph node dissection of the hepatic pedicle was proposed but the patient refused, accepting, however, adjuvant chemotherapy with fluorouracil and leucovorin, according to the de Gramont schedule (6). This was interrupted after 4 cycles because herpes zoster had occurred. The patient was followed up every six months with clinical examination, CT scan and biological markers. In October 2002, CT showed a single 4-cm lesion in the inferior splenic pole, suggestive of metastasis (Figure 2-A). Biological markers were in the normal range. The patient underwent splenectomy and lymph node dissection of the hepatic pedicle. The postoperative course was uneventful; pathology revealed metastasis of poorly differentiated adenocarcinoma matching the primary tumour of the gallbladder (Figure 2B). Lymph nodes of the hepatic pedicle were free of disease. No further adjuvant treatment was administered.

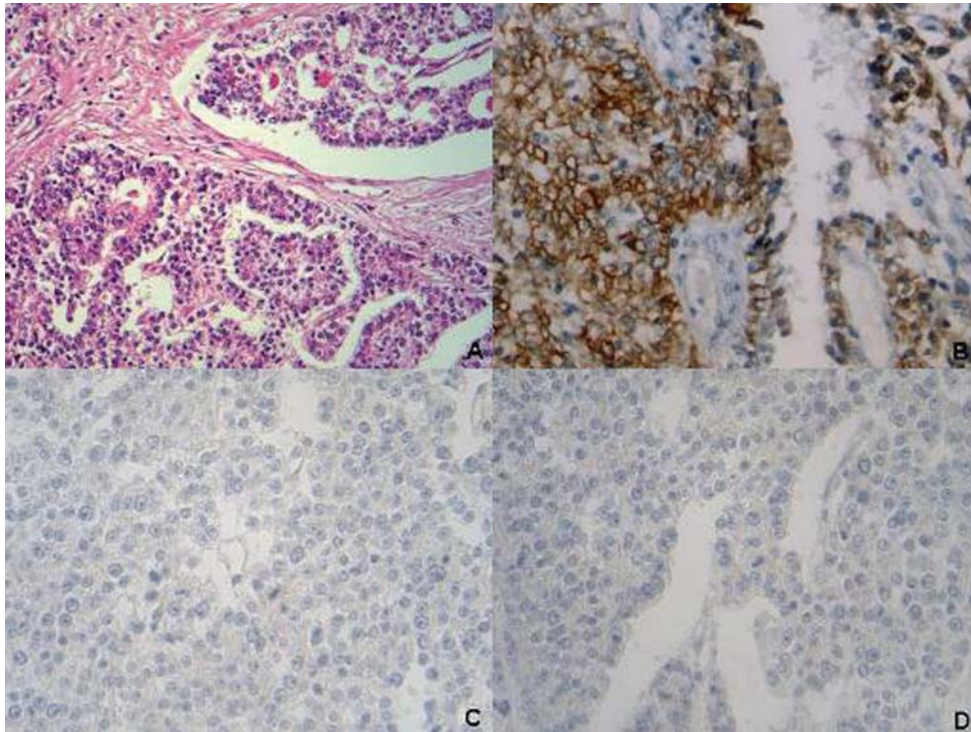


Figure 1. A: Poorly differentiated adenocarcinoma infiltrating the muscle layer; B: intense immunoreactivity with cytokeratin-7; C-D: markers of neuroendocrine tumours, chromogranin and synaptophysin, are negative.

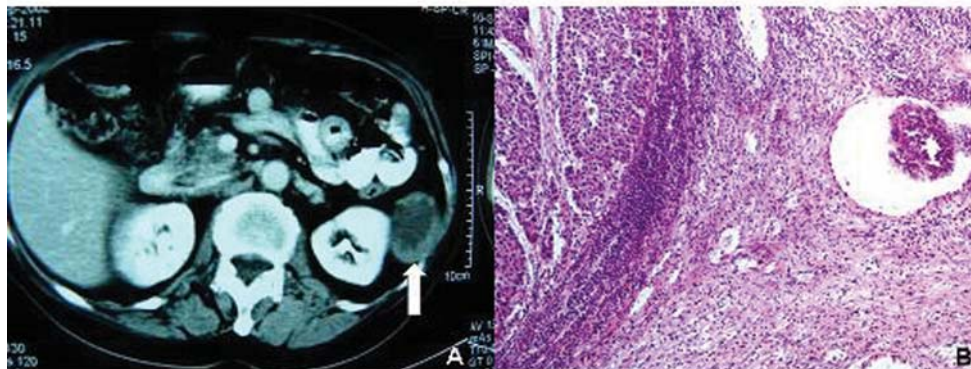


Figure 2. A: CT scan showing the metastasis at the inferior splenic pole (white arrow); B: parenchymal intravascular emboli with integrity of the splenic capsule.

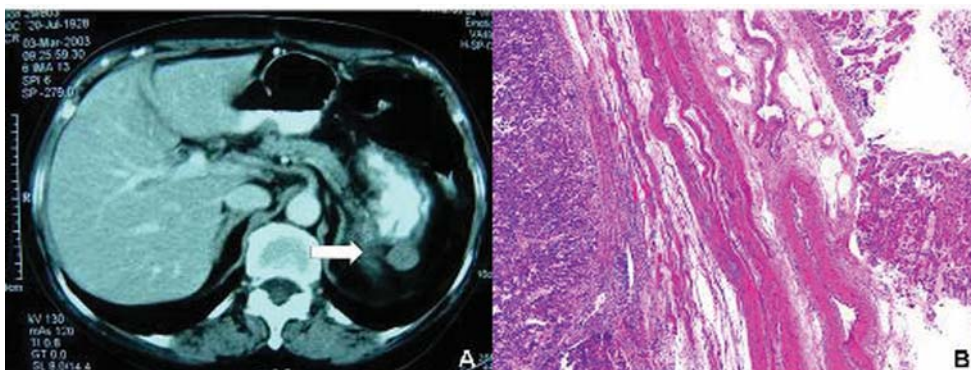


Figure 3. A: CT scan showing the recurrence involving the pancreatic tail and the greater curvature of the stomach (white arrow); B: poorly differentiated adenocarcinoma infiltrating the external layer of the gastric wall.

In March 2003, a CT scan showed a solitary lesion of 2.5 cm in diameter involving the pancreatic tail and the greater curvature of the stomach, indicative of recurrence (Figure 3A). The patient was then subjected to distal pancreatectomy en-bloc with sleeve gastrectomy and omentectomy. Portal-sites were not excised. Pathology confirmed metastasis of poorly differentiated adenocarcinoma infiltrating the external layer of the gastric wall (Figure 3B). Five years later the patient is alive without evidence of recurrence.

Discussion

Long-term survival of a patient with metachronous metastasis of primary gallbladder carcinoma is an uncommon event, never previously reported in the literature.

Gallbladder carcinoma is a tumour with an aggressive biological behaviour and poor prognosis. Patients are often diagnosed at advanced stage and surgical resection is the only possibility of cure, with survival rates ranging from 5% to 12% at 5 years (4, 7). Nevertheless, a different assessment should be made for tumours diagnosed incidentally after laparoscopic cholecystectomy. They often present at an early stage (T1/T2) with a 5-year survival of 85% for T1 tumours operated with simple cholecystectomy, and 61% for T2 tumours, if promptly re-operated and liver resection performed (usually segments IVb-V), along with lymph node dissection of the hepatic pedicle (8, 9). Notably, the presence of nodal metastasis at this site is the most important factor to influence survival, as reported by Lin *et al.* (9). Moreover, a recent review described how the presence of residual disease and the ability to achieve R0 represent significant prognostic factors (10).

In the current case, pathology revealed a T2 primary tumour, while the nodal dissection of the hepatic pedicle, performed at the time of the second operation, gave no evidence of metastasis. We hypothesise that these features influenced the patient's outcome positively. It is worth emphasising that the splenic recurrence was a true vascular metastasis rather than a peritoneal implantation, as proven by the presence of parenchymal intravascular emboli and the integrity of the splenic capsule. However, the physiopathological mechanisms of tumour vascular spread to the spleen, in the absence of portal hypertension, still remain unclear. Indeed, no report has been found in the literature concerning splenic metastasis from T2 gallbladder carcinomas.

On histological examination, poorly differentiated carcinomas of the gallbladder may exhibit various growth patterns. In some instances, neoplastic cells form cords and nests, or they infiltrate simply as individual cells. A diffuse sheet-like component may be seen, as in our case. Immunohistochemically, stains for cytokeratin 7 (Figure 1B), and carcino-embryonic antigen show intense immunoreactivity in a dominant population of tumour cells. Several mucin-

related glycoproteins, such as MUC1 and MUC5AC, are also normally expressed, although they may be focal, while general markers of neuroendocrine differentiation, such as neuron-specific enolase (NSE), chromogranins and synaptophysin, are invariably negative (Figure 1-C,D).

As regards treatment of gallbladder carcinoma, it is common opinion that adjuvant therapy plays a marginal role. In a recent review, chemotherapy was considered only palliative in non-resectable or metastatic tumours, and the authors concluded that no single or combined regimens should be recommended as a standard of care (5).

This report suggests that surgical resection of solitary metachronous metastasis should not be excluded as therapeutic approach, even for gallbladder carcinoma, which should not represent a predetermined condition in case of organ confined tumours (T1-T2).

References

- 1 Bartlett DL, Fong Y, Fortner JG, Brennan MF and Blumgart LH: Long-term results after resection for gallbladder cancer. Implications for staging and management. *Ann Surg* 224(5): 639-646, 1996.
- 2 Benoist S, Panis Y and Fagniez PL: Long-term results after curative resection for carcinoma of the gallbladder. French University Association for Surgical Research. *Am J Surg* 175(2): 118-122, 1998.
- 3 Fong Y, Jarnagin W and Blumgart LH: Gallbladder cancer: comparison of patients presenting initially for definitive operation with those presenting after prior noncurative intervention. *Ann Surg* 232(4): 557-569, 2000.
- 4 Cubertafond P, Gainant A and Cucchiari G: Surgical treatment of 724 carcinomas of the gallbladder. Results of the French Surgical Association Survey. *Ann Surg* 219(3): 275-280, 1994.
- 5 Verslype C, Prenen H and Van CE: The role of chemotherapy in biliary tract carcinoma. *HPB (Oxford)* 10(3): 164-167, 2008.
- 6 de GA, Bosset JF, Milan C, Rougier P, Bouche O, Etienne PL *et al*: Randomized trial comparing monthly low-dose leucovorin and fluorouracil bolus with bimonthly high-dose leucovorin and fluorouracil bolus plus continuous infusion for advanced colorectal cancer: a French intergroup study. *J Clin Oncol* 15(2): 808-815, 1997.
- 7 Wilkinson DS: Carcinoma of the gall-bladder: an experience and review of the literature. *Aust N Z J Surg* 65(10): 724-727, 1995.
- 8 Kondo S, Takada T, Miyazaki M, Miyakawa S, Tsukada K, Nagino M *et al*: Guidelines for the management of biliary tract and ampullary carcinomas: surgical treatment. *J Hepatobiliary Pancreat Surg* 15(1): 41-54, 2008.
- 9 Lin HT, Liu GJ, Wu D and Lou JY: Metastasis of primary gallbladder carcinoma in lymph node and liver. *World J Gastroenterol* 11(5): 748-751, 2005.
- 10 Pilgrim C, Usatoff V and Evans PM: A review of the surgical strategies for the management of gallbladder carcinoma based on T stage and growth type of the tumour. *Eur J Surg Oncol* 35(9): 903-907, 2009.

Received January 19, 2010

Accepted February 3, 2010