Dedifferentiated peripheral chondrosarcoma: a clinicopathologic,immunohistochemical, and molecular analysis of

Virchows Arch (2012) 460:335–342
DOI 10.1007/s00428-012-1206-2

ORIGINAL ARTICLE

Dedifferentiated peripheral chondrosarcoma: a clinicopathologic, immunohistochemical, and molecular analysis of four cases

Alessandro Franchi · Gianna Baroni · Iacopo Sardi · Laura Giunti · Rodolfo Capanna · Domenico Campanacci

Received: 14 November 2011 / Revised: 17 January 2012 / Accepted: 31 January 2012 / Published online: 16 February 2012

Abstract Peripheral dedifferentiated chondrosarcoma (DCS) is an exceedingly rare aggressive surface bone neoplasm in which a high-grade sarcoma arises within an osteochondroma. Four such examples were identified in our files, representing 11.1% of all DCS treated at our hospital in the years 1995–2010, and were the object of the present study. The patients were two men and two women ranging in age between 30 and 64 years, with tumors located in the pelvis ($n = 2$), in the scapula ($n = 1$), and the tibia ($n = 1$). Radiologically, there was evidence of a preexisting osteochondroma associated with aggressive osteolytic areas at the base and periphery of the exostosis, extending to the bone segment of origin and to the soft tissues. Immunohistochemical analysis of cell cycle regulators showed consistent loss in the expression of p16 and overexpression of cyclin D1, and to a lesser extent of RB and p53, in the anaplastic compartments of peripheral DCS in comparison with the well-differentiated cartilaginous components, while no significant expression of MDM2 was observed in any of the cases studied. Moreover, PDGFRα was absent in both tumor components, and PDGF-Rβ was strongly and diffusely positive in all the cases. Finally, no mutations were identified in exons 4–9 of the TP53 gene in both cases, showing positivity for p53 in the anaplastic component. In conclusion, our study shows that alterations of genes implicated in the regulation of the G1 to the S phase cell cycle checkpoint contribute to the process of dedifferentiation in peripheral secondary chondrosarcoma (CS), although the molecular mechanisms seem at least in part to differ from those involved in the process of dedifferentiation of central CS. PDGFRβ could represent a potential target for treatments with receptor tyrosine kinase inhibitors in peripheral DCS.

Keywords Dedifferentiated chondrosarcoma · Peripheral · Immunohistochemistry · Cell cycle regulators · p53 gene · PDGF receptors

A. Franchi (✉) · G. Baroni
Division of Anatomic Pathology, Department of Critical Care Medicine and Surgery, University of Florence Medical School, Viale G.B. Morgagni 85, 50134 Florence, Italy
e-mail: franchi@unifi.it

I. Sardi · L. Giunti
Division of Onco-Haematology, Azienda Ospedaliera Universitaria Meyer, Florence, Italy

R. Capanna · D. Campanacci
Division of Orthopedic Oncology, Azienda Ospedaliera Universitaria Careggi, Florence, Italy

Introduction

Dedifferentiated chondrosarcoma (DCS) is a well-known entity defined as a well-differentiated cartilage tumor juxtaposed with abrupt transition to a high-grade non-cartilaginous sarcoma. The process of dedifferentiation usually takes place in central chondromas or low-grade secondary chondrosarcoma (CS), but in rare instances, a high-grade non-cartilaginous sarcoma may originate in a low-grade peripheral CS secondary to a preexisting osteochondroma [1, 2]. The incidence of peripheral DCS has ranged between 8.9% and 13.7% of all DCS [1, 3], and they approximately represented 5.5% of all cases of CS arising in preexisting exostoses [2]. Tumors occurred both in patients with multiple hereditary exostoses (multiple osteochondromas) or in

preexisting osteochondromas, the most common location being the pelvis [2]. Dedifferentiation takes place either synchronously, when both components are present side by side in the same lesion, or metachronously, when a high-grade sarcoma is diagnosed at the same site of a previously excised osteochondroma or secondary peripheral CS [2]. Overall, the prognosis is poor, although a better cure rate has been obtained with a combination of surgery and chemotherapy [2].

In the attempt to further characterize the clinicopathologic features of these rare tumors, here, we describe the features of four cases of peripheral DCS arising in osteochondroma. Moreover, we carried out an analysis of the status of a number of regulators involved in the G1-S checkpoint, including p53, MDM-2, cyclin D1, p16, and RB oncoproteins, to determine whether aberrations of these regulatory pathways may be involved in the process of dedifferentiation in these tumors. Finally, we studied the expression of PDGF receptors α and β, which have recently been identified as possibly implicated in the growth of CS, in both tumor components.

Materials and methods

Patients

Thirty-six patients diagnosed with DCS in the years 1995–2010 were identified in the files of the Section of Anatomic Pathology of the Department of Critical Care Medicine and Surgery, University of Florence. Of these, four tumors (11.1%) had developed in a preexisting osteochondroma. Patient charts, radiographs, histological slides, and paraffin blocks were retrieved in each case. Patient details are summarized in Table 1.

Immunohistochemistry

A panel of well-characterized antibodies was used, which included mouse monoclonal antibodies to p53 (clone DO-7, pre-diluted; Ventana Medical Systems, Inc., Tucson, AZ), MDM-2 (clone IF2; Histo-Line Laboratories, Milan, Italy), p16 (clone 16P04, pre-diluted; Cell Marque), RB (clone 1F8, 1:50 dilution; NeoMarkers, Fremont, CA), cyclin D1 (clone SP4, pre-diluted; Ventana Medical Systems, Inc.), PDGFRα (sc-338, 1:200 dilution; Santa Cruz Biotechnology, Santa Cruz, CA), and PDGFRβ (sc-339, 1:100 dilution; Santa Cruz Biotechnology).

Immunohistochemistry was performed using a Ventana BenchMark® XT automated staining system (Ventana Medical Systems). For antigen retrieval, slides were heated with Cell Conditioning Solution 1 (CC1) for 30 min. Endogenous biotin was blocked with the appropriate kit. Primary antibodies against p53, p16, and cyclin D1 were then applied for 32 min at 37°C in a BenchMark® XT stainer and revealed with the iVIEW DAB detection kit, yielding a brown reaction product. After the staining run was complete, the slides were removed from the autostainer, counterstained with hematoxylin, dehydrated, and mounted with permanent mounting medium.

For RB, PDGFRα, and PDGFRβ immunohistochemical analyses, antigen retrieval was routinely performed in thermostat bath, PT Link Dako, at 97°C with EDTA (pH 9.0) for 15 min. The sections were placed in the Dako Autostainer Link 48 (Dako, Glostrup, Denmark) and the primary antibodies then applied for 60 min at 20°C. Bound antibodies were visualized using the Envision™ FLEX and DAB with chromogen.

For negative controls, primary antibodies were substituted with PBS.

TP53 gene sequencing

Ten serial sections (thickness, 5 μm) were obtained from one paraffin-embedded tissue block from the lesions of patients 2 and 4. Tissue fragments were microdissected using stereomicroscopic visualization from blank deparaffinized slides in order to separate the chondrogenic and

Table 1 Summary of the clinicopathologic features of four cases of dedifferentiated peripheral chondrosarcomas

Patient	Age	Sex	Site	Chondrogenic component	Anaplastic component	Treatment	Outcome
1	64	F	Proximal tibia	G2	Osteosarcoma	Resection and reconstruction with modular prosthesis	Lost at follow-up
2	33	M	Pelvis (iliac wing)	G1	Undifferentiated pleomorphic sarcoma	Wedge resection without reconstruction	Lost at follow-up
3	30	F	Pelvis (anterior pelvic arch)	G1	Undifferentiated pleomorphic sarcoma	Anterior pelvic arch resection without reconstruction. Local recurrence treated with resection and modular prosthesis	Local recurrence on femoral head after 8 months. Synchronous inguinal lymph node and L4 metastasis
4	55	M	Scapula	G1	Undifferentiated pleomorphic sarcoma	Partial scapular resection	Multiple local recurrences and pulmonary metastases after 4 months

dedifferentiated areas of the tumor. Post-microdissected slides were evaluated to confirm accurate sample microdissection. DNA was extracted from the microdissected paraffin-embedded tissues using a manual protocol [4]. Polymerase chain reaction (PCR) primers for exons 4–9, encoding the DNA-binding domain of the TP53 gene, were designed to obtain fragments of no more than 300 bp. Amplification reactions were performed with 60 ng of DNA, 10 ng of each primer, 200 μM dNTPs, 1× PCR reaction buffer, and 2.5 U Taq polymerase in a final volume of 25 μl. PCR products were sequenced directly on both strands using an ABI PRISM 3130XL Genetic Analyzer (Perkin-Elmer Applied Biosystems, Foster City, CA, USA).

Results

Clinical features

The clinical features of the patients, including treatment and follow-up, are summarized in Table 1. The patients were two men and two women ranging in age between 30 and 64 years. No patient was affected by multiple hereditary exostoses (multiple osteochondromas). Three patients reported a mass present for several years (4, 9, and 30, respectively), with recent (2–24 months) increase in dimension and onset of pain in one instance. Two lesions were located in the pelvis, one in the scapula, and one in the tibia. Radiologically, there was evidence of a preexisting osteochondroma consisting of a large lesion arising on the bone surface with irregular peripheric calcifications and ossifications, associated with aggressive osteolytic areas at the base and periphery of the exostosis, extending to the bone segment of origin. A soft tissue mass could be detected by CT scan or MRI (Fig. 1).

Histopathology

Histologically, all tumors had the characteristic biphasic pattern of dedifferentiated CS and appeared to originate from a preexisting osteochondroma (synchronous dedifferentiation). The cartilaginous component consisted of areas of well-differentiated grade 1 CS in three lesions and grade 2 in the remaining one, with diffuse aspects of calcification and ossification. The dedifferentiated component showed features of a high-grade fibroblastic osteosarcoma in patient 1 (Fig. 2), while it consisted of a high-grade undifferentiated pleomorphic sarcoma in the other three cases (Figs. 3, 4 and 5).

Immunohistochemistry

The results of the immunohistochemical studies are summarized in Table 2 and illustrated in Fig. 6.

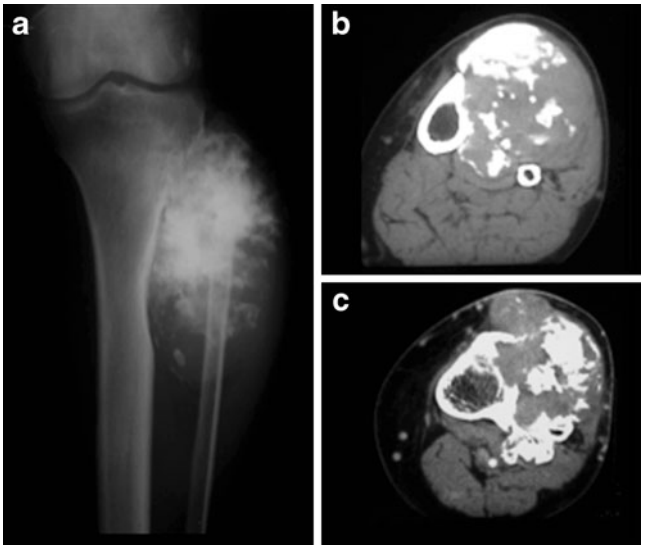

Fig. 1 Sixty-four-year-old woman (patient 1) with history of proximal tibia osteochondroma. She complained of recent progressive swelling and pain. **a** Antero-posterior radiographic view showed a cauliflower-shaped mass, with ossification and calcifications, arising from the proximal tibia and scalloping the lateral cortex of the tibia from outside. **b**, **c** The CT scan confirmed the base of implant of the preexisting osteochondroma on the tibia showing the typical extroflession of the cortex. Diffuse and irregular osteolysis of the ossifications within the mass, aggressive erosion of the external surface of the tibial cortex, and the presence of a soft tissue mass were signs of aggressiveness consistent with dedifferentiation

Overall, dedifferentiation was consistently accompanied by the loss of p16 nuclear expression since this protein was expressed in the chondrogenic component but not in the anaplastic component in all the cases. In addition, RB positivity was observed in the anaplastic component in three of four cases, while this oncoprotein was not detectable in the chondrogenic areas. Diffuse cyclin D1 nuclear immunoreactivity was present in the high-grade anaplastic component of all cases, while only one lesion displayed focal positivity in well-differentiated cartilaginous areas. On the other hand, there was a limited difference in the expression of p53 in the two components since it was detected in the anaplastic component in only two of four cases, while the chondrosarcomatous areas were negative. Finally, no significant expression of MDM2 was observed in any of the cases studied. While PDGFRα was absent in both tumor components of dedifferentiated peripheral chondrosarcomas, PDGFRβ was strongly and diffusely positive in all the cases.

For comparison, we immunostained a series of ten central conventional chondrosarcomas (six grade 1, three grade 2, and one grade 3). All these tumors stained diffusely for p16, RB1, PDGFRα, and PDGFRβ, while p53 and cyclin D1 were expressed only in one grade 2 and in the grade 3 chondrosarcomas. MDM2 was negative in all cases.

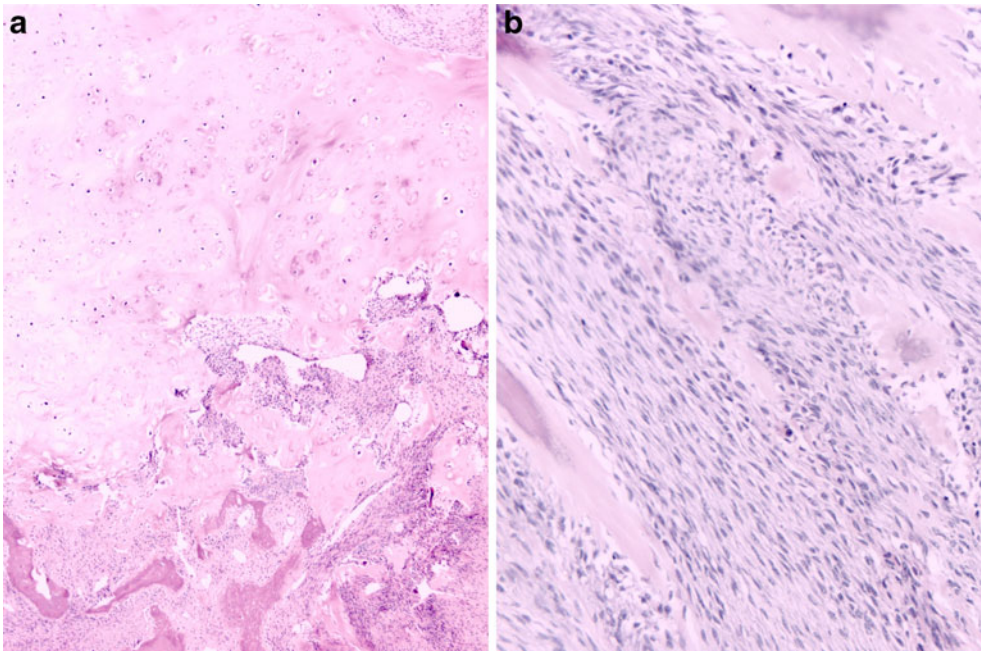

Fig. 2 In patient 1, the high-grade component of the lesion showed histological features of fibroblastic osteosarcoma. **a** Low-power view of the lesion with both low-grade and high-grade components. **b** High-power view of the osteosarcomatous component

TP53 gene status

Both cases showing positivity for p53 in the anaplastic component were analyzed for the status of exons 4–9 of the TP53 gene. In case 4, we were able to analyze both the chondrogenic and the anaplastic components, while in case 2 we succeeded in amplifying and screening mutations only in samples from the anaplastic component. PCR amplification and subsequent DNA sequencing revealed no mutations in the exons examined.

Discussion

The present report confirms that approximately 10% of DCS occur at the bone surface, developing in a peripheral CS exosteochondroma. The most commonly affected sites are the pelvis and the long bones of the lower leg (femur and tibia), reflecting the distribution of secondary peripheral CS [1, 2]. The age at presentation is lower than in central DCS, and the most common presenting sign is a recent increase in a mass that had been present for several years. At imaging, the typical features of a peripheral CS are associated with signs of local aggressiveness consisting in diffuse and irregular osteolysis within the mass or at the base of implant and the presence of tumor extension in the soft tissues.

At variance with central DCS, the high-grade component of peripheral DCS more often showed a histological appearance of a high-grade spindle cell and pleomorphic sarcoma, variably classified as fibrosarcoma or malignant fibrous histiocytoma. However, immunohistochemical analysis demonstrated the frequent expression of myogenic markers, including actins and desmin, in the high-grade anaplastic component [5].

The development of metastatic disease is a frequent event which is associated with a dismal prognosis. The treatment of choice is surgery with wide margins, but some benefit in overall survival has been reported when patients presenting with localized disease were treated with a combination of surgery and chemotherapy [2].

The biology of the process of dedifferentiation occurring in CS has been studied more in depth in central lesions, while only limited information is available regarding the molecular characterization of peripheral DCS. Inactivation of the EXT1 and/or the EXT2 genes is a well-known event in the development of osteochondromas [6], but it is likely not involved in the pathogenesis of secondary peripheral CS [7]. An immunohistochemical analysis of cell signaling pathways that are known to have an important role in normal chondrocyte proliferation showed that the FGF signaling pathway is more frequently active than in the chondrogenic component of conventional secondary peripheral CS, whereas PTHLH signaling seems to be low/downregulated [5]. This suggests that these changes may be of importance in the transformation of CS toward DCS. Moreover, a comparison between the chondrogenic and anaplastic components showed relevant differences in the expression of molecules related to cell cycle regulation, such as cyclin D1 and p53 [5]. Abnormalities in the checkpoints controlling cell cycle contribute to tumorigenesis and progression in several human malignancies; therefore, in the present study, we further explored the status of other players involved in the control of the G1/S checkpoint. We observed a consistent difference in the

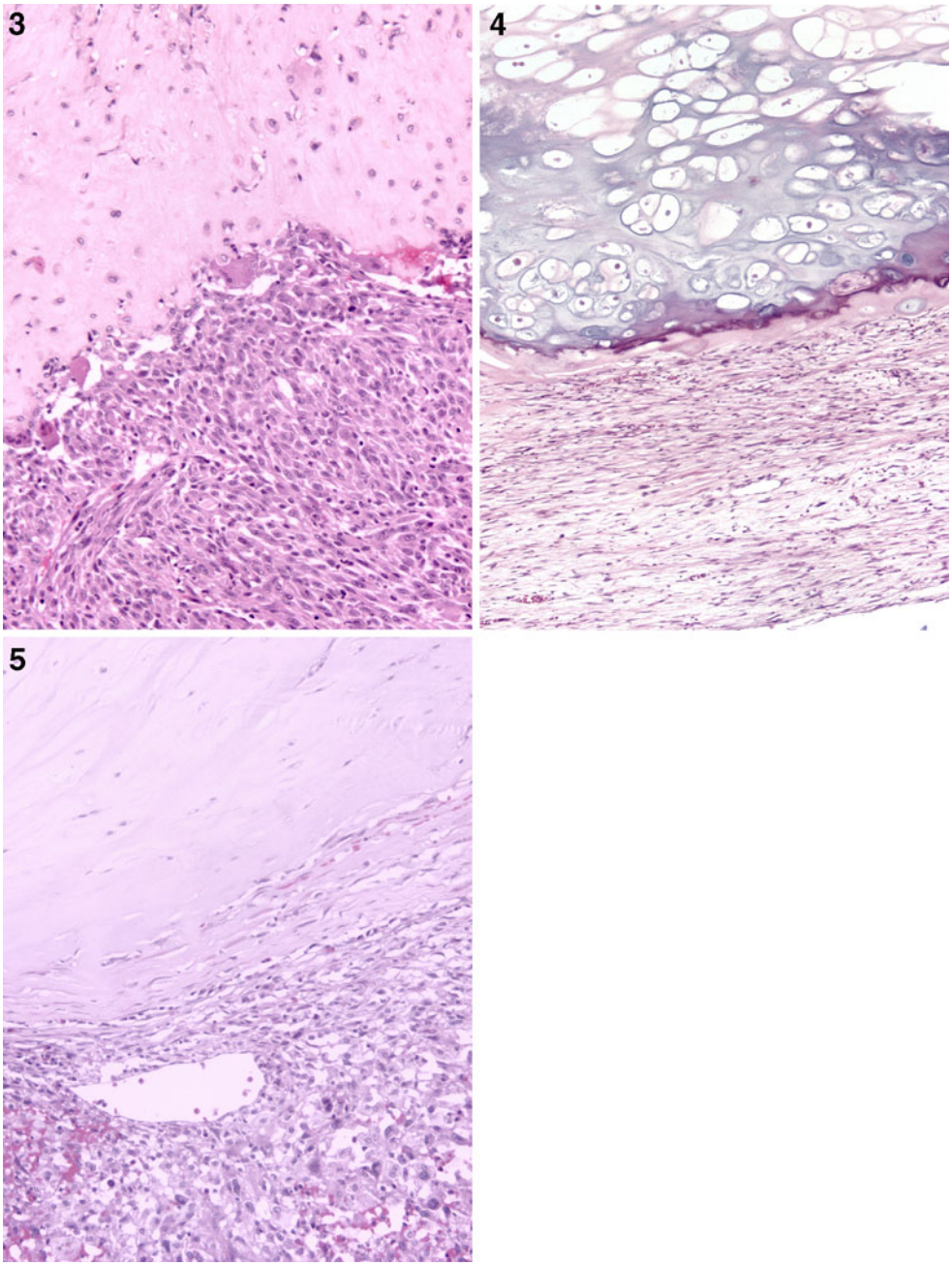

Figs. 3–5 In the remaining patients, the tumor consisted of a low-grade well-differentiated chondrosarcoma (*top*) and a high-grade pleomorphic sarcoma (*bottom*). There is a sharp separation between the two components

expression of p16 and cyclin D1, and to a lesser extent of RB and p53, between the well-differentiated and anaplastic compartments of peripheral DCS.

According to our results and to previous reports, it appears that the molecular abnormalities present in peripheral DCS differ from those occurring in central DCS.

Table 2 Summary of the results of the immunohistochemical studies

Pt	P53		MDM-2		P16		RB		Cyclin D1		PDGF-R α		PDGF-R β	
	CC	AC	CC	AC	CC	AC	CC	AC	CC	AC	CC	AC	CC	AC
1	−	−	−	−	+	−	−	−	−	+	−	−	+	+
2	−	+	−	−	+	−	−	+	−	−	−	−	+	+
3	−	−	−	−	+	−	−	+	−	+	−	−	+	+
4	−	+	−	−	+	−	−	+	−	+	−	−	+	+

CC chondrogenic component, *AC* anaplastic component

Indeed, several studies have shown that the process of dedifferentiation taking place in central CS is consistently accompanied by an alteration of the p53 pathway. Strong nuclear immunostaining has been observed in the high-grade non-cartilaginous component, but not in the low-grade cartilaginous one [8–10]. In addition, point mutations of the p53 gene have been identified in the high-grade component of central DCS, and this has also been associated with LOH at 17p [8, 10–12]. In one case, a p53 mutation consisting of a 6-bp deletion starting at the second base of codon 250 in exon 7 was detected in both the cartilaginous and the anaplastic components [11].

At partial variance with these findings, in the present study, we observed that two of the four tumors (50%) showed immunohistochemical positivity in the anaplastic component, but molecular analysis did not reveal any alteration of exons 4–9 of the TP53 gene in these cases. A discordance between the results of immunohistochemical analysis showing p53 positivity and those of DNA analysis showing no detectable gene alterations has been repeatedly reported with variable frequency in bone and soft tissue sarcomas [13–16]. Several mechanisms are known to be involved in the stabilization of wild-type p53 protein resulting in nuclear accumulation and immunohistochemical

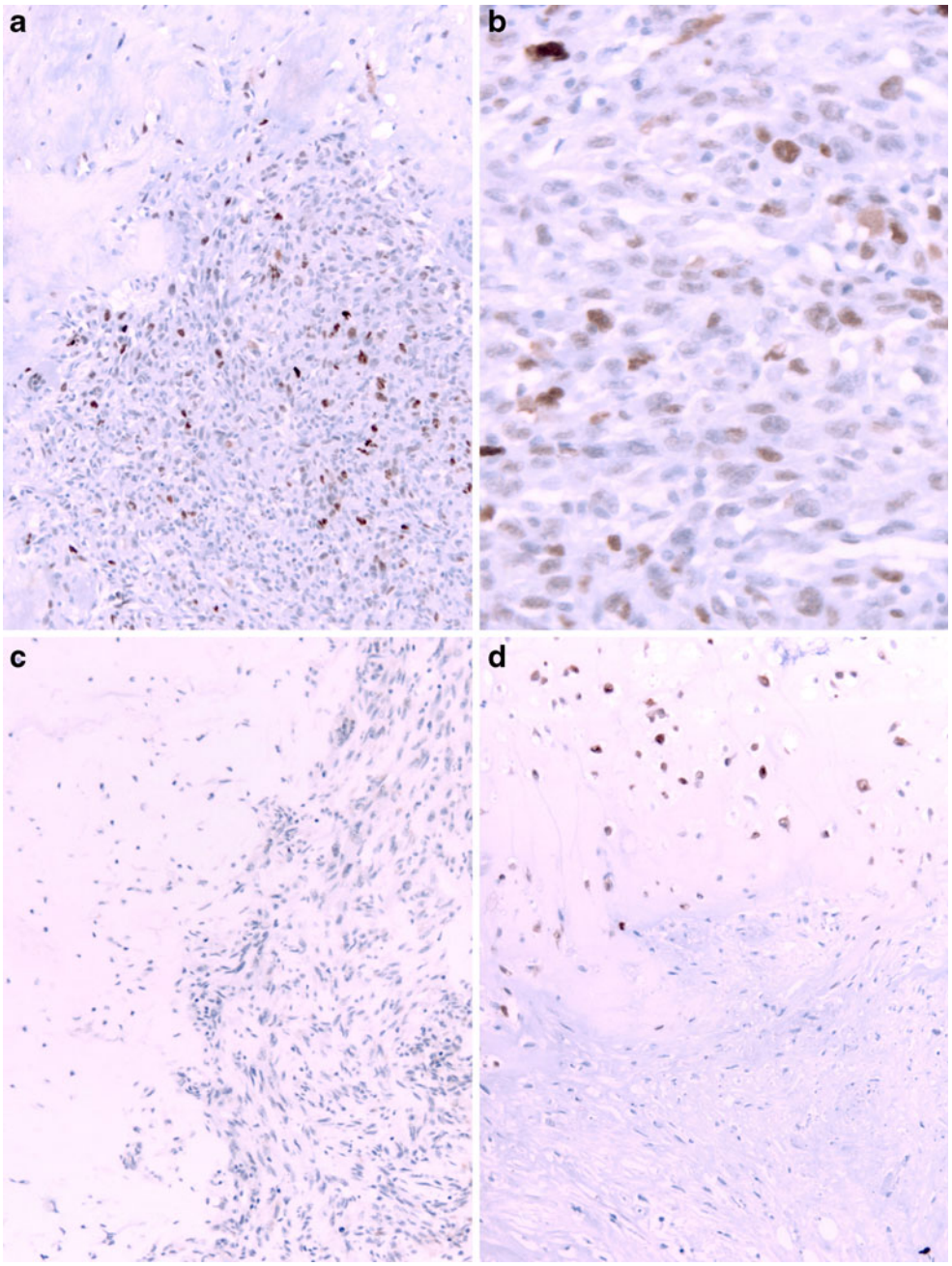

Fig. 6 Representative images of the immunohistochemical stains from case 4. Nuclear positivity for p53 is visible only in the anaplastic component of the tumor (*bottom*), while the well-differentiated chondrosarcomatous areas are negative (*top*) (**a**). A higher power detail of the immunostaining for p53 in the high-grade component is shown in **b**. Similarly, RB (**e**) and cyclin D1 (**f**) were present in the anaplastic component of the lesion (*bottom*), while the well-differentiated component was negative (*top*). P16 (**d**) was detectable only in the well-differentiated chondrosarcomatous areas (*top*) and not in the high-grade sarcaomatous areas (*bottom*). MDM2 (**c**) and PDGFRα (**g**) were negative in both components, while PDGFRβ was intensely and diffusely positive (**h**)

Fig. 6 (continued)

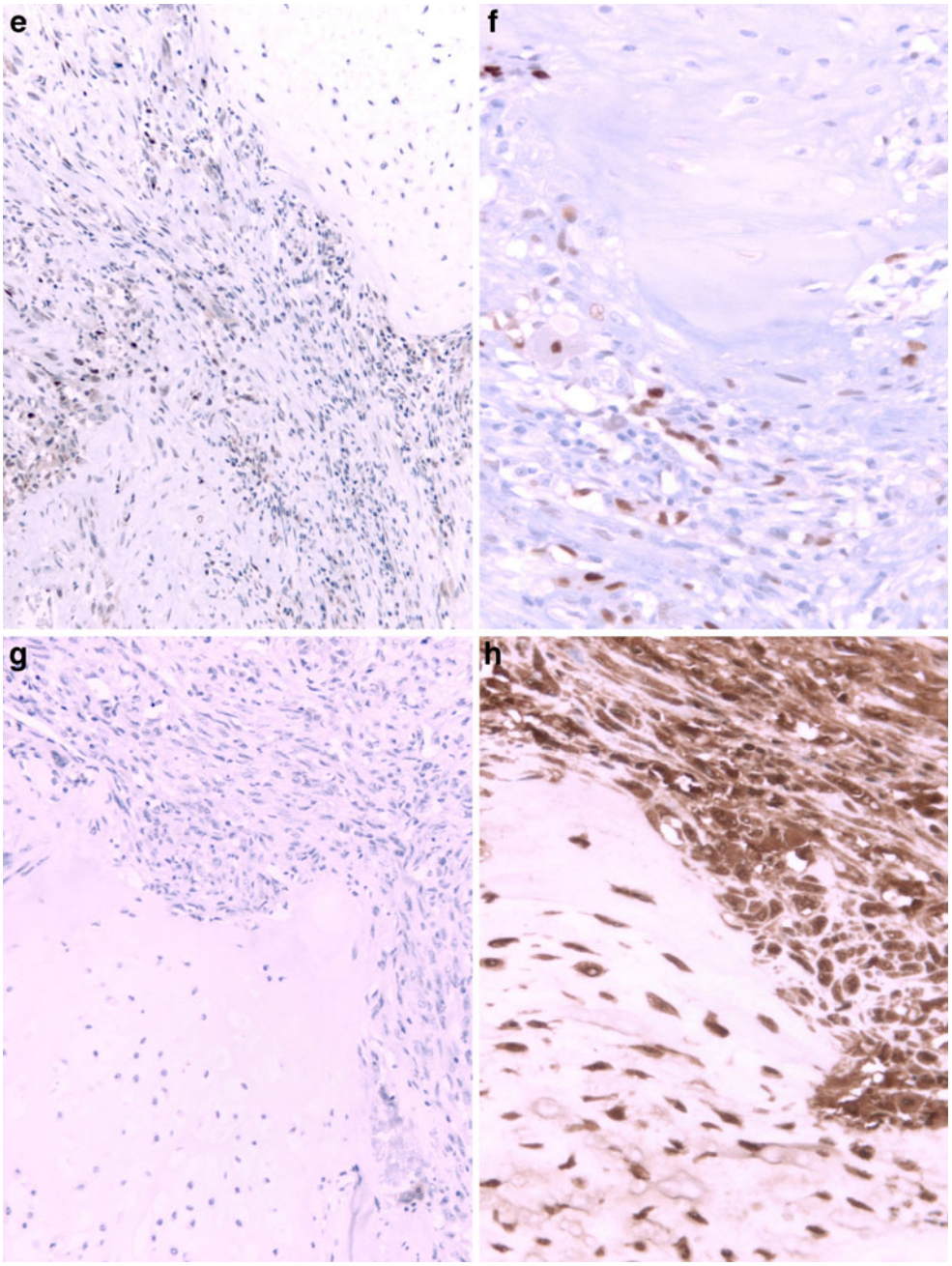

positivity, including DNA damage in cells and binding to viral oncogene products or to the MDM2 gene product [17]. This latter mechanism, however, seems to be unlikely in peripheral DCS since we did not observe any significant immunoreactivity for MDM2 in our series. Therefore, although the number of cases analyzed is small, the data obtained indicate that a molecular alteration of the p53 gene is unlikely to be involved in the growth and dedifferentiation of peripheral CS arising in osteochondromas. However, we cannot exclude the presence of TP53 mutations outside exons that were screened in this study.

Other molecular abnormalities previously identified in central DCS include genetic and epigenetic alterations of other genes involved in cell cycle control, including the RB p16INK4, FHIT, and E-cadherin genes [18, 19]. Interestingly, p16INK4 promoter methylation was observed in both the low-grade and the high-grade compartments of central DCS, while in our study, p16 expression was maintained in the well-differentiated component of the tumor. Therefore, inactivation of cell cycle genes involved in the G1/S arrest seems to be an early event in the development of central DCS, while it appears to occur later in the process of dedifferentiation of peripheral CS.

Recent studies [20, 21] have investigated the status of platelet-derived growth factor (PDGF) receptors and their ligands in conventional CS as they could represent possible

candidates for molecular therapies with receptor tyrosine kinase (RTK) inhibitors. The immunohistochemical and biochemical analyses showed that CS co-expressed PDGFRα and PDGFRβ, with the latter showing greater protein expression and phosphorylation levels. Conversely, no activating mutations were found [21]. These findings are in keeping with the existence of an autocrine/paracrine loop which could play an important role in the development of conventional central CS. To our knowledge, the status of PDGFRs has not been previously investigated in DCS. In the present study, all four cases of peripheral DCS were intensely and diffusely positive for PDGFRβ in both components, while PDGFRα was not detectable. These findings may suggest that PDGFRβ could represent a potential target for treatments with RTK inhibitors in peripheral DCS.

In summary, our study shows that alterations of genes implicated in the regulation of the G1 to the S phase cell cycle checkpoint contribute to the process of dedifferentiation in peripheral secondary CS, although the molecular mechanisms seem at least in part to differ from those involved in the process of dedifferentiation of central CS.

Conflict of interest statement We declare that we have no conflict of interest.

References

1. Bertoni F, Present D, Bacchini P, Picci P, Pignatti G, Gherlinzoni F, Campanacci M (1989) Dedifferentiated peripheral chondrosarcomas. A report of seven cases. Cancer 63:2054–2059
2. Staals EL, Bacchini P, Mercuri M, Bertoni F (2007) Dedifferentiated chondrosarcomas arising in preexisting osteochondromas. J Bone Joint Surg Am 89:987–993
3. Frassica FJ, Unni KK, Beabout JW, Sim FH (1986) Dedifferentiated chondrosarcoma. A report of the clinicopathological features and treatment of seventy-eight cases. J Bone Joint Surg Am 68:1197–1205
4. Coombs NJ, Gough AC, Primrose JN (1999) Optimisation of DNA and RNA extraction from archival formalin-fixed tissue. Nucleic Acids Res 27:e12
5. Rozeman LB, de Bruijn IH, Bacchini P, Staals EL, Bertoni F, Bovée JV, Hogendoorn PC (2009) Dedifferentiated peripheral chondrosarcomas: regulation of EXT-downstream molecules and differentiation-related genes. Mod Pathol 22:1489–1498
6. Bovée JVMG, Cleton-Jansen AM, Wuyts W, Caethoven G, Taminiau AH, Bakker E, Van Hul W, Cornelisse CJ, Hogendoorn PC (1999) EXT mutation analysis and loss of heterozygosity in sporadic and hereditary osteochondromas and secondary chondrosarcomas. Am J Hum Genet 65:689–698
7. de Andrea CE, Reijnders CM, Kroon HM, de Jong D, Hogendoorn PC, Szuhai K, Bovée JV (2012) Secondary peripheral chondrosarcoma evolving from osteochondroma as a result of outgrowth of cells with functional EXT. Oncogene. doi:10.1038/onc.2011.311
8. Wadayama B, Toguchida J, Yamaguchi T, Sasaki MS, Yamamuro T (1993) p53 expression and its relationship to DNA alterations in bone and soft tissue sarcomas. Br J Cancer 68:1134–1139
9. Simms WW, Ordonez NG, Johnston D, Ayala AG, Czerniak B (1995) p53 expression in dedifferentiated chondrosarcoma. Cancer 76:223–227
10. Terek RM, Healey JH, Garin-Chesa P, Mak S, Huvos A, Albino AP (1998) p53 mutations in chondrosarcoma. Diagn Mol Pathol 7:51–56
11. Bovée JV, Cleton-Jansen AM, Rosenberg C, Taminiau AH, Cornelisse CJ, Hogendoorn PC (1999) Molecular genetic characterization of both components of a dedifferentiated chondrosarcoma, with implications for its histogenesis. J Pathol 189:454–462
12. Grote HJ, Schneider-Stock R, Neumann W, Roessner A (2000) Mutation of p53 with loss of heterozygosity in the osteosarcomatous component of a dedifferentiated chondrosarcoma. Virchows Arch 436:494–497
13. Cordon-Cardo C, Latres E, Drobnjak M, Oliva MR, Pollack D, Woodruff JM, Marechal V, Chen J, Brennan MF, Levine AJ (1994) Molecular abnormalities of mdm2 and p53 genes in adult soft tissue sarcomas. Cancer Res 54:794–799
14. Mousses S, McAuley L, Bell RS, Kandel R, Andrulis IL (1996) Molecular and immunohistochemical identification of p53 alterations in bone and soft tissue sarcomas. Mod Pathol 9:1–6
15. Yoo J, Lee HK, Kang CS, Park WS, Lee JY, Shim SI (1997) p53 gene mutations and p53 protein expression in human soft tissue sarcomas. Arch Pathol Lab Med 121:395–399
16. Taubert H, Würl P, Bache M, Meye A, Berger D, Holzhausen HJ, Hinze R, Schmidt H, Rath FW (1998) The p53 gene in soft tissue sarcomas: prognostic value of DNA sequencing versus immunohistochemistry. Anticancer Res 18:183–187
17. Momand J, Zambetti GP, Olson DC, George D, Levine AJ (1992) The mdm-2 oncogene product forms a complex with the p53 protein and inhibits p53-mediated transactivation. Cell 69:1237–1245
18. Yamaguchi T, Toguchida J, Wadayama B, Kanoe H, Nakayama T, Ishizaki K, Ikenaga M, Kotoura Y, Sasaki MS (1996) Loss of heterozygosity and tumor suppressor gene mutations in chondrosarcomas. Anticancer Res 16:2009–2015
19. Röpke M, Boltze C, Neumann HW, Roessner A, Schneider-Stock R (2003) Genetic and epigenetic alterations in tumor progression in a dedifferentiated chondrosarcoma. Pathol Res Pract 199:437–444
20. Sulzbacher I, Birner P, Trieb K, Mühlbauer M, Lang S, Chott A (2001) Platelet-derived growth factor-alpha receptor expression supports the growth of conventional chondrosarcoma and is associated with adverse outcome. Am J Surg Pathol 25:1520–1527
21. Lagonigro MS, Tamborini E, Negri T, Staurengo S, Dagrada GP, Miselli F, Gabanti E, Greco A, Casali PG, Carbone A, Pierotti MA, Pilotti S (2006) PDGFRalpha, PDGFRbeta and KIT expression/activation in conventional chondrosarcoma. J Pathol 208:615–623