



UNIVERSITÀ  
DEGLI STUDI  
FIRENZE

## FLORE

# Repository istituzionale dell'Università degli Studi di Firenze

### **Comparison of Wirsung-jejunal duct-to-mucosa and dunking technique for pancreatojejunostomy after pancreatoduodenectomy**

Questa è la Versione finale referata (Post print/Accepted manuscript) della seguente pubblicazione:

*Original Citation:*

Comparison of Wirsung-jejunal duct-to-mucosa and dunking technique for pancreatojejunostomy after pancreatoduodenectomy / Batignani G; Fratini G; Zuckermann M; Bianchini E; Tonelli F. - In: HEPATOBILIARY & PANCREATIC DISEASES INTERNATIONAL. - ISSN 1499-3872. - STAMPA. - 4(3):(2005), pp. 450-455.

*Availability:*

The webpage <https://hdl.handle.net/2158/652806> of the repository was last updated on

*Terms of use:*

Open Access

La pubblicazione è resa disponibile sotto le norme e i termini della licenza di deposito, secondo quanto stabilito dalla Policy per l'accesso aperto dell'Università degli Studi di Firenze (<https://www.sba.unifi.it/upload/policy-oa-2016-1.pdf>)

*Publisher copyright claim:*

La data sopra indicata si riferisce all'ultimo aggiornamento della scheda del Repository FloRe - The above-mentioned date refers to the last update of the record in the Institutional Repository FloRe

(Article begins on next page)

# Comparison of Wirsung-jejunal duct-to-mucosa and dunking technique for pancreatojejunostomy after pancreatoduodenectomy

Giacomo Batignani, Geri Fratini, Michele Zuckermann, Elisa Bianchini and Francesco Tonelli

Florence, Italy

**BACKGROUND:** Pancreato-enteric reconstruction after pancreatoduodenectomy (PD) is still a source of debate because of the high incidence of complications. Among the various types of pancreato-jejunostomies we don't know yet which is the best in terms of anastomotic failure and related complications rates. Wirsung-jejunal duct-to-mucosa anastomosis (WJ) and "dunking" pancreato-jejunal anastomosis (DPJ) are the two most used ones worldwide but conflicting results are reported. To determine which is the safer anastomosis and to define when an anastomosis should be preferred, we retrospectively reviewed two groups of patients who underwent WJ or DPJ.

**METHODS:** Twenty-three patients underwent PD with WJ ( $n=17$ ) with dilated (WJD) ( $n=9$ ) or not-dilated Wirsung's duct (WJND) ( $n=8$ ) or with a DPJ ( $n=6$ ) over a 3-year period at a single institution.

**RESULTS:** The complications rate was high in all groups of patients (33.3% in WJD, 37.5% in WJND and 66.7% in DPJ). A pancreatic fistula developed in one patient in each group (11.1% in WJD, 12.5% in WJND and 16.7% in DPJ). All these patients were managed conservatively. Anastomotic disruption took place in the WJ patients especially in the WJND group ( $n=2$ ) compared to the WJD ( $n=1$ ) (25% vs 11.1%) or DPJ groups (0%); these three patients required a re-operation. Overall, the anastomotic defects were higher in patients who underwent WJND (37.5%), compared to WJD (22.2%) and to DPJ (16.7%). However, no statistical differences were found among the groups. Delayed gastric emptying (DGE) and

total parenteral nutrition (TPN) along with anastomotic defects were responsible for a prolonged hospital stay.

**CONCLUSIONS:** Our results were not able to demonstrate any statistical difference between the two different techniques in preventing anastomotic failure. WJ can represent a valid choice in case of a dilated duct and a firm, fibrotic enlarged gland that could not be properly invaginated in a small jejunal loop. DGE may occur in those patients who experienced an anastomotic failure and required a TPN regimen with a prolonged hospital stay.

(*Hepatobiliary Pancreat Dis Int* 2005; 4: 450-455)

**KEY WORDS:** pancreatoduodenectomy; pancreas; jejunal; anastomosis; Wirsung

## Introduction

Pancreato-enteric anastomosis still represents the "Achille's heel" of pancreatoduodenectomy (PD). The dehiscence of this anastomosis is, in fact, a well-known life-threatening complication which has led surgeons to perform different types of anastomosis, or to avoid it, suturing and abandoning the pancreatic stump. This latter technique, however, is more frequently complicated by pancreatic fistula than after pancreato-jejunal anastomosis with a similar fistula related mortality rate.<sup>[1]</sup>

There are several anastomotic techniques used to restore the pancreato-enteric continuity and, among them, the most used are the single layer between the pancreatic capsule and the jejunum (either termino-terminal or termino-lateral), the so-called "dunking" technique (telescoping the pancreas into the jejunum), the pancreato-gastrostomy in a single or double layer and the duct-to-mucosa (Wirsung-jejunum or gastric anastomosis). Whatever the choice is complications rate may range from 30% to 50% with an overall mortality rate between 1.4% and 10%.<sup>[2-6]</sup>

**Author Affiliations:** Unità di Chirurgia, Dipartimento di Fisiopatologia Clinica (Batignani G, Fratini G, Zuckermann M and Tonelli F) and Dipartimento di Statistica (Bianchini E), Università degli Studi di Firenze, Florence, Italy

**Corresponding Author:** Prof. Giacomo Batignani, Professore Associato di Chirurgia Generale, Unità di Chirurgia-Dipartimento di Fisiopatologia Clinica, Università degli Studi di Firenze, Viale GB Morgagni, 85, 50134-Firenze, Italy (Tel: 39-055-4289000; Fax: 39-055-4361770; EMail: giacomo.batignani@unifi.it)

© 2005, Hepatobiliary Pancreat Dis Int. All rights reserved.

Whilst some reports show the Wirsung-jejunal duct-to-mucosa anastomosis (WJ) to bear the same incidence in terms of anastomotic dehiscence when compared to other anastomoses,<sup>[7-11]</sup> other authors reported better outcomes with a lower complications rate in case of a WJ accomplished with a dilated Wirsung's duct.<sup>[7,12]</sup>

To further investigate this assumption we retrospectively reviewed a group of patients who underwent PD and WJ performed with dilated and not dilated pancreatic duct comparing these two groups to a third, in whom an invaginated "dunking" pancreato-jejunosomy (DPJ) was used, in terms of morbidity and mortality.

**Methods**

Between January 2001 and December 2003, a series of 23 patients (18 males /5 females), with a mean age of 56 years (range 27-77) underwent a PD for the disorders listed in Table 1.

Data have been retrospectively collected from a low volume centre for hepato-bilio-pancreatic surgery; the standard treatment for periapillary tumors until the whole 2001 has been the Whipple procedure (WPD), since then all the patients received a pylorus-preserving PD (PPPD); the anastomotic technique was chosen time by time according to the preference of the same surgeon who performed all the operations.

Eight patients received WPD with distal gastric resection, while the other 15 patients underwent PPPD. Six patients underwent DPJ, 4 of them had a normal pancreas and not dilated duct whereas 2 had a dilated duct with a firm, fibrotic gland. The other 17 patients received WJ, 9 of them showed a fibrotic pancreatic stump with a dilated duct (>3 mm.), while the other 8 patients had a normal residual pancreas without a dilated Wirsung's duct.

A pancreatic fistula was defined by the presence of amylase rich (over 1000 IU/L) drainage fluid (>30 ml/24 h) at day 7.

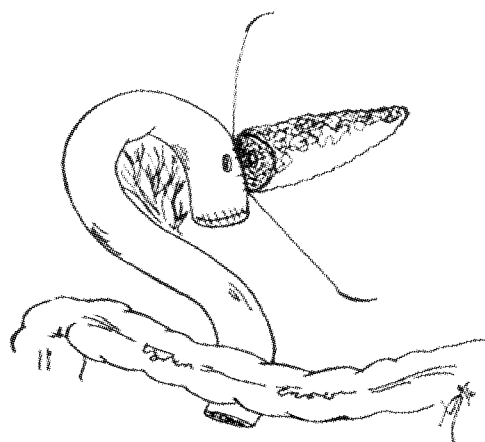
The anastomotic dehiscence is eventually confirmed by abdominal computed tomography (CT) showing the complete anastomotic breakdown with an associated local fluid collection.

**Technique for Wirsung-jejunal duct-to-mucosa anastomosis**

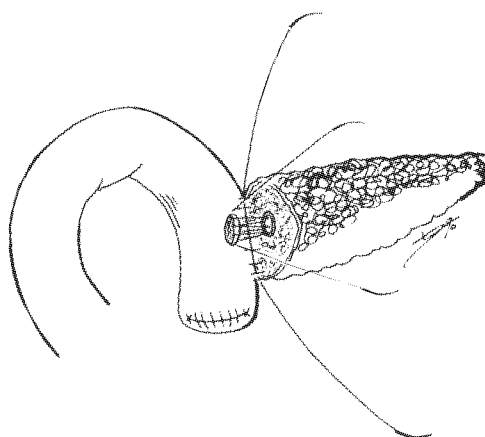
After the removal of specimen, the transected jejunal loop was placed through the mesocolon and laterally approximated to the pancreatic stump using 3-0 doubled polypropylene suture (Prolene, Ethicon S. p. A., Pratica di Mare, Italy). The needle was passed through the sero-muscular layer of the jejunum and pancreatic capsule and then tied. The posterior external layer of the anastomosis was accomplished by a continuous running

**Table 1.** Patients, type of gastro-duodenal resection and tumor pathology

Type of anastomosis	WJD	WJND	DPJ	Total
Number of patients	9	8	6	23
Type of resection				
Whipple procedure	1	5	2	8
Pylorus preserving PD	8	3	4	15
Pathology of the tumor				
Pancreatic	5	2	2	9
Ampullary	3	2	1	6
Periapillary NOS	1	1	1	3
Gastric	0	1	0	1
Duodenal Carcinoid	0	0	1	1
Neuroendocrine	0	2	1	3

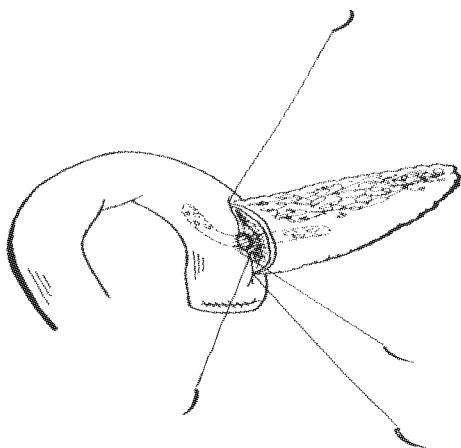


**Fig. 1.** The posterior external layer of the pancreato-jejunal anastomosis has been accomplished by the means of a 3-0 polypropylene double armed continuous running suture between the pancreatic capsule and the jejunal seromuscular layer.

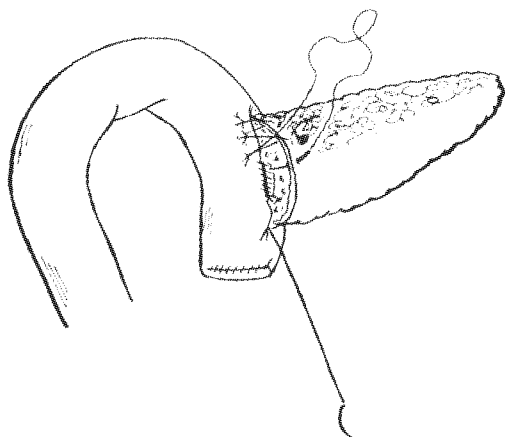


**Fig. 2.** The posterior inner layer between the Wirsung's duct and the jejunum (full thickness) has been made using the parachuting technique leaving loose loops of the 7-0 polypropylene double armed suture until the end of the posterior layer then pulled.

suture (Fig. 1). A tiny hole was made in the sero-mus-



**Fig. 3.** A PVC catheter has been left across the anastomosis between the Wirsung and the jejunum where it is left free into the lumen. The anastomosis is completed anteriorly again leaving loose loops until the end of the inner anastomosis, then pulled and tied.



**Fig. 4.** Completion of the external anterior layer between jejunal sero-muscular layer and the pancreatic capsule using the same 3-0 polypropylene double armed suture used for the posterior external layer by the means of a continuous running suture.

colar layer and in the mucosa. A 7-0 polypropylene (Prolene, Ethicon S. p. A., Pratica di Mare, Italy) double armed (1/2 circle needle) was passed into the jejunum (full thickness) and the Wirsung's duct with microsurgical technique. Magnifying loupes (3.5 X) can be very helpful during this phase. The posterior layer was accomplished without initial knot, leaving loose loops until completion of the technique (Fig. 2), then the suture was pulled bringing together the two walls (parachuting technique). At this point the Wirsung's duct was stented with a small PVC catheter (6-8 Fr), which was passed through the jejunal hole into the intestinal lumen and left loose. The anterior layer was then started using the other needle, which was passed through in the same manner as described above, leaving also in this case loose loops until the end of the continuous running suture (Fig. 3). At this point the suture was pulled using a vascular hook if necessary, and

then tied. Fibrin glue (Tissucol, Immuno S. p. A., Austria) was subsequently sprayed on the cut surface of the pancreas and around the Wirsung-jejunal suture.

The external layer was completed with a 3-0 polypropylene (Prolene, Ethicon S. p. A., Pratica di Mare, Italy) running suture (Fig. 4), which was eventually tied.

Biliary-enteric anastomosis was then performed on the same jejunal loop, at the distance of approximately 20 cm from the pancreatic anastomosis, using a 5-0 polydioxanone (PDS, Ethicon S. p. A., Pratica di Mare, Italy) continuous running parachuting suture according to Dmitrewski and Buckels.<sup>[13]</sup> Gastro-jejunal or duodeno-jejunal anastomosis has been performed 50 to 60 cm further down the biliary anastomosis in a single layer using a 3-0 polydioxanone (PDS, Ethicon S. p. A., Pratica di Mare, Italy) continuous running suture.

Two silicon drains are inserted through separated stab wounds and left one posteriorly to the anastomosis in the lesser and left sac and the other anteriorly and infra-hepatically.

#### Technique for "dunking" anastomosis

The jejunal loop was anastomized to the pancreatic stump in a termino-terminal fashion in two layers, invaginating the jejunum over the pancreatic stump. The posterior external layer was done using 3-0 polypropylene (Prolene, Ethicon S. p. A., Pratica di Mare, Italy), interrupted stitches between the jejunal sero-muscular layer and the pancreatic capsule while the internal layer between the resected jejunum (full thickness) and the resected pancreatic capsule, using 3-0 polydioxanone (PDS, Ethicon S. p. A., Pratica di Mare, Italy), interrupted stitches and leaving a 6 to 8 Fr PVC stent into the Wirsung duct. The anastomosis was completed anteriorly telescoping the jejunum over the pancreatic stump with 3-0 prolene interrupted stitches (sero-muscular to pancreatic capsule). The same techniques were used as described above for the duct-to-mucosa technique, for the biliary, gastric or duodenal anastomosis, and for the drains.

#### Perioperative treatment

All patients were given low molecular weight heparin 0.4 ml/d, gabesate mesilate 1 gr iv/24 h, octreotide 6 mg iv/24 h, H<sub>2</sub>-receptor antagonists (e. g., ranitidine 50 mg, iv, qd) and ceftizoxime 2 g, iv, bid, for 48 hours starting the first dose 2 hours prior to the skin incision.

Total parenteral nutrition (TPN) was instituted in all those patients who developed any anastomotic defect and a delayed gastric emptying syndrome (DGES).

#### Statistical analysis

Statistical evaluation was carried out using Fischer's exact test of independence for I × J tables. A *P* value less than 0.05 was considered statistically significant.

**Table 2.** Complications according to the types of pancreato-jejunal anastomosis in 23 patients after pancreaticoduodenectomy

Type of anastomosis	WJD	WJND	DPJ
Patients	9	8	6
Wound infection	0	0	1
Pneumonia	2	1	1
Cardiac	0	0	1
Urinary infections	0	0	1
Mild pancreatitis	1	1	0
Intra-abdominal abscess	0	1	0
Total (%)	3 (33.3)	3 (37.5)	4 (66.7)

**Table 3.** Local complications related to the types of pancreato-jejunal anastomosis in 23 patients after pancreaticoduodenectomy

Type of anastomosis	WJD	WJND	DPJ	Total
Patients	9	8	6	23
Pancreatic fistula	1 (11.1%)	1 (12.5%)	1 (16.7%)	3 (16%)
Anastomotic dehiscence	1 (11.1%)	2 (25%)	0	3 (16%)
Death	0	0	0	0
Total	2(22.2%)	3 (37.5%)	1 (16.7%)	6 (26%)

**Table 4.** Delayed gastric emptying, total parenteral nutrition and hospital stay in 23 patients after pancreaticoduodenectomy

Type of anastomosis	WJD	WJND	DPJ
Patients	9	8	6
Delayed gastric emptying*	1	1	0
Number of patients on post-operative TPN	2	3	1
Mean duration of TPN (days)	19.2	31.5	4.1
Mean Post-operative hospital stay (days)	24.6	39.2	14.6

\* : in patients who underwent a PPPD.

## Results

As shown in Table 2, the highest rate of general complications (not affecting the pancreato-jejunal anastomosis) occurred in the DPJ group (66.7%) compared to the WJ group (35%) (*P* value = n. s.).

Two post-operative mild pancreatitis, regressed by support therapy alone, occurred in each WJ group while one intra-abdominal abscess took place in the WJND group (4%).

In Tables 3 and 4, the complications related to pancreato-jejunal anastomosis are shown.

Six of 23 patients (26%) eventually developed a pancreato-jejunal anastomotic defect; three anastomotic dehiscences occurred (16% of the total), requiring a re-laparotomy to better drain in one patient, to overstitch the pancreatic stump and the jejunum in another patient, and to perform the completion of the pancreatectomy in the remainder. Two of these 3 major leakages took place in the WJND group (25%), and 1 in the WJD group

(12.5%). In the DPJ group no major leakages occurred.

A pancreatic fistula occurred in 3 patients (16% of the total) who did not require re-laparotomy, and it was treated by continuous lavages and aspirations through the drain inserted at the time of surgery in one patient, or through a drain newly placed percutaneously under CT guide in the other 2 patients.

In the WJND group occurred a higher incidence rate of overall anastomotic defects (37.5%), compared with the WJD group (22.2%) or with the DPJ group (16.5%) (*P* value = n. s.).

No statistically significant correlations were found comparing the DPJ group to the whole WJ group and to the WJD and WJND groups in terms of general complications and anastomotic defects (*P* value always >0.1).

In-hospital and/or 30-day mortality was 0 in this series of patients.

DGE was observed in 2 patients (9%), who underwent PPPD and also developed an anastomotic dehiscence. DGE spontaneously resolved with naso-gastric tube drainage and total parenteral nutrition (TPN). The mean duration of TPN was higher in the WJND group and contributed to a longer hospital stay.

## Discussion

Pancreato-jejunal anastomosis bears probably the highest risk of failure of all abdominal anastomoses, with its related serious complications. This may be partly due to the fact that it is an anastomosis between a solid organ and a hollow viscus and to the harmful liquid content which is the pancreatic juice with its enzyme activated by the presence of bile or even by the gut content and microbial flora. For these reasons and for the uncertainty of patency of the anastomosis, some authors have tried to solve the problem avoiding it, suturing and abandoning the pancreatic stump or injecting synthetic polymers which solidify after injection. These techniques however are often complicated with a pancreatic fistula with a rate ranging between 50%-100%,<sup>[1,7]</sup> even if others report better results with a 4%-7% complications rate<sup>[14-16]</sup> using synthetic polymers to occlude the Wirsung's duct, before suturing the pancreatic stump. Even the pure pancreatic fistula is not as dangerous as the pancreato-jejunal anastomotic breakdown, probably because of a minor activation of pancreatic enzymes, it usually requires several weeks to heal and may develop further complications such as infections, pseudocysts or pseudoaneurysms. Furthermore, the long-term fibrosis generated by the exclusion techniques may impair the endocrine function as well.<sup>[18]</sup> Total pancreatectomy is another solution useful to avoid a pancreato-jejunal anastomosis; this option may be indicated in patients affected by severe diabetes or, as a rescue, after a massive anastomotic disruption. Exclusion techniques and total pancrea-

tectomy result in total loss of exocrine and endocrine function and they require a pancreatic enzyme substitutive therapy and insulin administration throughout the life in most of the patients.

Other well-known techniques use either the stomach to be anastomosed to the pancreatic remnant in a single or double layer with or without telescoping the gland, or the jejunum, suturing it on an isolated Roux-en-Y loop, to divert the bile flow away from the pancreatic anastomosis.<sup>[17-19]</sup> The existence of so many descriptions of different techniques which deal with the treatment of the pancreatic stump after PD indicate that, probably, there is no a single one which is clearly superior to the others in terms of dehiscence, fistulas formation and related deaths.<sup>[7]</sup> Furthermore, other important factors must be considered for the risk of a possible pancreato-jejunal anastomotic dehiscence, such as the presence of diabetes, preoperative biliary drainage, sequence of anastomoses along the reconstructive time and the duration of surgery. All these aspects resulted in as significant independent risk factors in a prospective trial.<sup>[20]</sup>

Ferguson and Wangesteen<sup>[21]</sup> were the first to report a new interesting experimental technique for pancreato-jejunal anastomosis, directly approximating the jejunal mucosa to the Wirsung's duct epithelium, subsequently described by Madden.<sup>[22]</sup> Since then other modifications have been suggested, such as the two layers technique, the use of fibrin glue<sup>[23]</sup> and the use of ultrasonic shears.<sup>[24]</sup>

Our technique is similar to those reported by others<sup>[27,28]</sup> but different because the Wirsung-jejunal anastomosis, even though continuous, is full-thickness into the jejunum. The anastomosis is performed over a stent which is found to be useful during the suture making. The use of fibrin glue may be helpful to seal some accessory ducts unavoidably opened on the cut surface. The same results are probably achieved using the ultrasonically activated shears.<sup>[24]</sup> The reported incidence of leakage is however different among previous reports with conflicting results. If on one hand, some authors reported better results for WJ compared to DPJ,<sup>[1, 25, 26]</sup> others,<sup>[11]</sup> in a prospective randomised study, did not.

In our study we divided the patients with an anastomotic defect into those with a pancreatic fistula and those with a major breakdown of the pancreato-jejunal anastomosis, requiring a reoperation.

All the reoperated patients belonged to the WJ groups, especially those from the WJND group, when compared to the WJD group (25% vs. 11.1% respectively). These results appeared to be conflicting with those reported by others,<sup>[25,26]</sup> even though they were not statistically significant and could be attributed to the different technique used for the WJ anastomosis (i. e. continuous running suture full thickness for the jejunum); others, in fact, anastomosing only the jejunal

mucosa reported good results with this continuous anastomosis.<sup>[27,28]</sup>

It is note worthy to underline that the present study is not able to demonstrate the superiority of WJ anastomosis compared to DPJ in terms of morbidity.

In this study, TPN was given in two patients with DGE, who also showed an anastomotic defect.

No in-hospital or 30-day deaths occurred in our patients.

Even if this study entailed only a small number of patients, the WJ with a continuous running suture in patients with not-dilated duct would have increased the length, the difficulty (a microsurgical experience is necessary) and eventually the costs when compared to the DPJ, without evident benefits.

We agree with Sikora and Posner,<sup>[7]</sup> Marcus et al<sup>[29]</sup> and Suzuki et al<sup>[30]</sup> using the selective duct to mucosa technique when the Wirsung's duct is dilated (> 5 mm) and in presence of a firm fibrotic pancreas, whereas the dunking technique appears to be safer and then should be preferred, in presence of a friable pancreas with a not-dilated Wirsung's duct.

Although the low number of patients in our serie does not allow any definitive conclusion, we could not find any evidence supporting either the WJ or the DPJ as the safer anastomotic technique after PD. Considering that DPJ is always feasible in all situations (small or dilated duct, friable or firm, fibrotic pancreas), it should be the procedure of choice. The WJ after PD in case of a normal, not dilated Wirsung's duct is a more time-consuming and demanding technique, necessarily requiring a microsurgical skillset, but it could be alternatively adopted in presence of a dilated Wirsung's duct, especially in case of an enlarged gland that does not fit well in the jejunum to be invaginated. Clinical trials are however lacking in this field.

Furthermore it is interesting to see the correlation between DGE in PPPD and pancreato-jejunal anastomotic failure, responsible for a prolonged TPN regimen and in-hospital stay.

**Funding:** None.

**Ethical approval:** Not needed.

**Contributors:** BG proposed the study and wrote the first draft. BE analyzed the data. All authors contributed to the design and interpretation of the study and to further drafts. BG is the guarantor.

**Competing interest:** No benefits in any form have been received or will be received from a commercial party related directly or indirectly to the subject of this article.

## References

- 1 Bartoli FG, Arnone GB, Ravera G, Bachi V. Pancreatic fistula and relative mortality in malignant disease after pancreatoduodenectomy. Review and statistical meta-analysis regarding 15 years of literature. *Anticancer Res* 1991;11:1831-1848.

- 2 Poon RTP, Lo SH, Fong D, Fan ST, Wong J. Prevention of pancreatic anastomotic leakage after pancreaticoduodenectomy. *Am J Surg* 2002;183:42-52.
- 3 Yeo CJ, Cameron JL, Sohn TA, Lillemoe KD, Pitt HA, Talamini MA, et al. Six hundred fifty consecutive pancreaticoduodenectomies in the 1990s: pathology complications, and outcomes. *Ann Surg* 1997;226:257-260.
- 4 Miedema BW, Sarr MG, van Heerden JA, Nagorney DM, McIlrath DC, Ilstrup D. Complications following pancreatoduodenectomy. Current management. *Arch Surg* 1992;127:945.
- 5 Fernandez del Castillo C, Rattner DW, Warshaw AL. Standards for pancreatic resection in the 1990s. *Arch Surg* 1995;130:295.
- 6 Baumel H, Huguier M, Manderscheid JC, Fabre JM, Houry S, Fagot H. Results of resection for cancer of the exocrine pancreas: a study from the French Association of Surgery. *Br J Surg* 1994;81:102-107.
- 7 Sikora SS, Posner M. Management of the pancreatic stump following pancreatoduodenectomy. *Br J Surg* 1995; 82: 1590-1597.
- 8 Crist DW, Cameron JL. Current status of pancreatoduodenectomy for periampullary carcinoma. *Hepatogastroenterology* 1989;36:478-485.
- 9 Grace PA, Pitt HA, Longmire WP. Pancreatoduodenectomy with pylorus preservation for adenocarcinoma of the head of the pancreas. *Br J Surg* 1986;73:647-650.
- 10 Braasch JW, Rossi RL, Watkins E Jr, Deziel DJ, Winter PF. Pyloric and gastric preserving pancreatic resection. Experience with 87 patients. *Ann Surg* 1986;204:411-418.
- 11 Bassi C, Falconi M, Molinari E, Mantovani W, Butturini G, Gumbs AA, et al. Duct-to-mucosa versus end-to-side pancreatojejunostomy reconstruction after pancreaticoduodenectomy: results of a prospective randomized trial. *Surgery* 2003;134:766-771.
- 12 Hosotani R, Doi R, Imamura M. Duct-to-mucosa pancreatojejunostomy reduces the risk of pancreatic leakage after pancreatoduodenectomy. *World J Surg* 2002;26:99-104.
- 13 Dmitrewski J, Buckels JA. A simple modification of choledochostomy using continuous pull through suture. *Surg Gynecol Obstet* 1992;175:573-574.
- 14 Marzell AP, Stierer M. Partial pancreaticoduodenectomy (Whipple procedure) for pancreatic malignancy: occlusion of a non-anastomosed pancreatic stump with fibrin sealant. *HPB Surg* 1992;5:251-259.
- 15 Di Carlo V, Chiesa R, Pontiroli AE, Carlucci M, Staudacher C, Zerbi A, et al. Pancreatoduodenectomy with occlusion of the residual stump with Neoprene injection. *World J Surg* 1989;13:105-111.
- 16 Tran K, Van Eijck C, Di Carlo V, Hop WC, Zerbi A, Balzano G, et al. Occlusion of the pancreatic duct versus pancreatojejunostomy: a prospective randomised trial. *Ann Surg* 2002; 236:422-428.
- 17 Khan AW, Agarwal AK, Davidson BR. Isolated roux loop duct-to-mucosa pancreatojejunostomy avoids pancreatic leaks in pancreaticoduodenectomy. *Dig Surg* 2002;19:199-204.
- 18 Kingsnorth AN. Safety and function of isolated Roux loop pancreatojejunostomy after Whipple pancreatico-duodenectomy. *Ann R Coll Surg Engl* 1994;76:175-179.
- 19 Toogood GJ, Wilson TG, Padbury RTA. A modification of isolated Roux loop reconstruction after pancreaticoduodenectomy. *ANZ J Surg* 1999;69:363-364.
- 20 Srivastava S, Sikora SS, Pandey CM, Kumar A, Safena R, Kapoor VK. Determinants of pancreaticoenteric anastomotic leak following pancreaticoduodenectomy. *ANZ J Surg* 2001; 71:511-515.
- 21 Ferguson DJ, Wangenstein OH. Experimental anastomosis of the pancreatic duct. *Ann Surg* 1950;132:1066-1074.
- 22 Madden JL. Technique for pancreaticoduodenectomy. *Surg Gynecol Obstet* 1964;118:247-264.
- 23 Tashiro S, Murata E, Hiraoka T, Nakakuma K, Watanabe E, Miyauchi Y. New technique for pancreatojejunostomy using a biological adhesive. *Br J Surg* 1987;74:392-394.
- 24 Tanaka T, Matsugu Y, Fukuda Y. Use of ultrasonically activated shears improves the safety of pancreatojejunostomy after pancreaticoduodenectomy. *Arch Surg* 2002;137:1258-1261.
- 25 Howard JM. Pancreatojejunostomy: leakage is a preventable complication of Whipple resection. *J Am Coll Surg* 1997;184:454-457.
- 26 Matsumoto Y, Fuji H, Miura K, Inoue S, Sekikawa T, Aoyama H, et al. Successful pancreatojejunal anastomosis for pancreatoduodenectomy. *Surg Gynecol Obstet* 1992;175:555-562.
- 27 Ohwada S, Iwazaki S, Nakamura S, Ogawa T, Tanahashi Y, Ikeya T, et al. Pancreatojejunostomy-Securing technique: Duct-to-mucosa anastomosis by continuous running suture and parachuting using monofilament absorbable thread. *J Am Coll Surg* 1997;185:190-194.
- 28 Tsuji M, Kimura H, Konishi K, Yabushita K, Maeda K, Kuroda Y. Management of continuous anastomosis of pancreatic duct and jejunal mucosa after pancreaticoduodenectomy: historical study of 300 patients. *Surgery* 1998;123:617-621.
- 29 Marcus SG, Cohen H, Ranson JH. Optimal management of the pancreatic remnant after pancreaticoduodenectomy. *Ann Surg* 1995;221:635-648.
- 30 Suzuki Y, Fujino Y, Tanioka Y, Hiraoka K, Takada M, Ajiki T, et al. Selection of pancreatojejunostomy techniques according to pancreatic texture and duct size. *Arch Surg* 2002; 137:1044-1047.

Received January 26, 2005

Accepted after revision May 27, 2005