



UNIVERSITÀ  
DEGLI STUDI  
FIRENZE

## FLORE

# Repository istituzionale dell'Università degli Studi di Firenze

### **The original caliber of the carotid artery as a possible risk factor for complications of atherosclerosis.**

Questa è la Versione finale referata (Post print/Accepted manuscript) della seguente pubblicazione:

*Original Citation:*

The original caliber of the carotid artery as a possible risk factor for complications of atherosclerosis / C.Macchi;C.Catini;F.Giannelli. - In: ITALIAN JOURNAL OF ANATOMY AND EMBRYOLOGY. - ISSN 1122-6714. - STAMPA. - 98:(1993), pp. 259-268.

*Availability:*

The webpage <https://hdl.handle.net/2158/681364> of the repository was last updated on

*Terms of use:*

Open Access

La pubblicazione è resa disponibile sotto le norme e i termini della licenza di deposito, secondo quanto stabilito dalla Policy per l'accesso aperto dell'Università degli Studi di Firenze (<https://www.sba.unifi.it/upload/policy-oa-2016-1.pdf>)

*Publisher copyright claim:*

La data sopra indicata si riferisce all'ultimo aggiornamento della scheda del Repository FloRe - The above-mentioned date refers to the last update of the record in the Institutional Repository FloRe

(Article begins on next page)

\* Institute of Gerontology and Geriatric Medicine  
\*\* Department of Human Anatomy and Histology  
University of Florence (Italy)

## The Original Caliber of the Carotid Artery as a Possible Risk Factor for Complications of Atherosclerosis

Claudio Macchi \*, Claudio Catini \*\*, Fabrizio Giannelli \*

*Key words:* carotid caliber, atherosclerosis, Doppler ultrasonography, cerebrovascular events.

### SUMMARY

Seventy subjects (35 men, 35 women; age range: 65 to 86 years) with an isolated 80% extracranial atherosclerotic stenosis of a single internal carotid artery were studied. Each subject was examined by color Doppler ultrasonography. The size of the carotids and the Doppler flow velocities of both healthy and diseased internal carotid arteries were measured. The original arterial calibers were also estimated, and the Doppler flow velocity was determined at the level of and proximal to the stenotic lesion. The symptomatology and occurrence of cerebrovascular events (territory and extent) were documented in all subjects with respect to the other parameters. By comparing the sizes of the common, internal, and external carotid arteries in every patient, it was observed that their calibers were consistently proportional to one another.

In both the men and the women, significant, inversely proportional relationships were observed between the original vessel caliber and the extent of stenosis in the affected internal carotid artery, as well as between the original vessel caliber and the hemodynamic significance of the stenosis. Moreover, a correlation was observed among the original arterial caliber, the presence or absence of symptoms, and the frequency and extent of cerebrovascular events, in both the men and the women. In both sexes, the functional of the compensatory circulation was found to correlate with arterial caliber ( $p < 0.01$ ). The correlation between the degree of stenosis and the gravity of the symptomatology, as well as the occurrence of cerebrovascular events, was observed to increase significantly when the residual luminal area (of the stenotic artery) was less than 2.5 mm<sup>2</sup>. This relationship tended to hold more for men than for women; however, the difference was not statistically significant.

## INTRODUCTION

In the assessment of arterial stenoses, the qualitative data that derive from the use of various methods are variably precise. The degree to which they are capable of visualizing the actual pathology depends on the sensitivity of the methodology and equipment used (Macchi, 1985; Pizzetti *et al.*, 1992). The degree of stenosis (Kassam *et al.*, 1985) is expressed by qualitatively by an approximate (slight, moderate, significant, or completely occluded) term or precisely by a quantitative (in terms of percentage) assessment (Franceschi, 1980; von Reutern *et al.*, 1992). Such judgments are always made in relation to the original vessel lumen; the area of the residual lumen per se is not considered.

A quantitative assessment of the residual lumen is nonetheless essential, especially in the afferent cerebral vessels, where the variability of the dimensions of arteries less than one centimeter in caliber carries significantly different implications for the hemodynamic evaluation of the stenosis (Macchi *et al.*, 1993). For example, an 80% stenosis, which is probably hemodynamically significant in an artery 3 mm in diameter, may be functionally irrelevant in a 6 mm artery. In fact, in the former case, the cross-sectional area of the residual lumen is 1.4 mm<sup>2</sup>, while in the second it is 5.6 mm<sup>2</sup>; in other words, it is four times as large.

Furthermore, one must consider that the cross-sectional area of the residual lumen is the sole reproducible and quantifiable parameter that has any use for long-term comparisons. It can be used to monitor the progression of the obstructive lesion, inasmuch as the hemodynamic importance of the stenosis can be approximately estimated on the basis of imprecise quantitative and indirect qualitative data.

It must also be recognized that the hemodynamic effects of the stenosis are also influenced by the surface characteristics of the lesion (Brice *et al.*, 1964; Berguer *et al.*, 1974; Flanigan *et al.*, 1977; Brown *et al.*, 1982). However, if it is true that the irregularity, friability, and degree of ulceration of the atherosclerotic lesion play a determinant role (Moore *et al.*, 1968; Edwards *et al.*, 1979; Bartynski *et al.*, 1981; Ammar *et al.*, 1984; Macchi *et al.*, 1991), the hemodynamic importance of the stenosis still remains unconsidered, both in terms of the reduction of distal perfusion and the greater damage inflicted at the level of the stenotic lesion by the increased flow velocity and turbulence (Langlois *et al.*, 1983; Ku *et al.*, 1985).

Clinically, the prognostic importance of the residual lumen of an artery affected by a stenotic process is particularly evident in the afferent cerebral bed. In this region, the circle of Willis, which is characterized by wide anatomical and functional variability (Sedzimir, 1959; Mortillaro *et al.*, 1963; Fazio *et al.*, 1970; Fazio *et al.*, 1985), may be recruited as part of a compensatory collateral circuit, especially in rapidly evolving stenoses.

The aim of our study was to establish the relationship between the original arterial caliber and the clinical manifestations of the atherosclerotic process using a qualitative/quantitative evaluation of the degree of hemodynamic compromise by lesions of the internal carotid artery. We set out to determine whether: arterial

caliber may be considered a risk factor for the occurrence of the cerebrovascular events associated with carotid atherosclerosis; the relationship between arterial caliber and the progression of atherosclerosis; whether there is a limit beyond which the area of the residual lumen constitutes a risk for cerebrovascular events; and whether there is a difference between the two sexes.

#### PATIENTS AND METHODS

Seventy subjects (35 men, 35 women; age range: 65 to 86) with stenotic lesions of one internal carotid artery were studied. The subjects were selected from among patients who presented exclusively with an isolated 80% stenosis (the other segments examined were not involved) of the extracranial course of the internal carotid artery at its origin (or in a segment that could be visualized by our methodology). Each patient was examined by color Doppler ultrasonography. The following parameters were determined bilaterally in the arterial segments: diameter, circumference, area, and flow velocity (using pulsed wave Doppler with frequency analysis) of the common, internal (both involved and uninvolved) and external carotid arteries, at their origin and one centimeter distal to it.

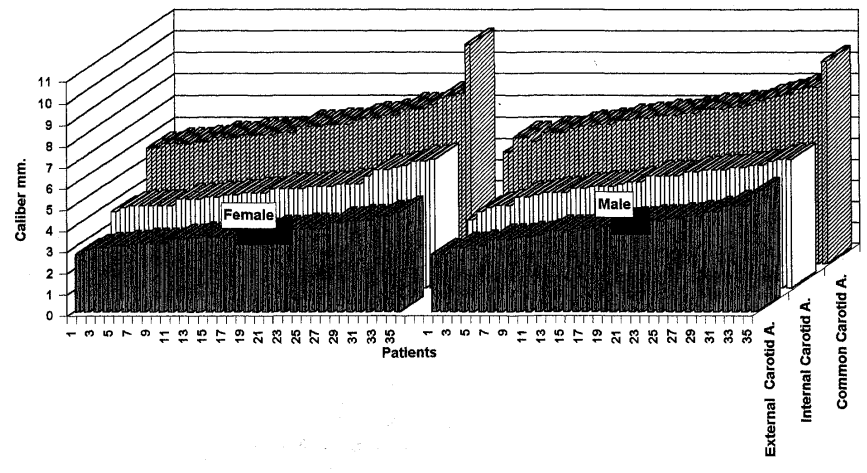
Aside from estimating the original (that is, before the development of the stenotic lesions) vessel dimensions, the diameter, circumference, area, and flow velocity (using pulsed wave Doppler with frequency analysis) were determined in the stenotic internal carotid arteries at the level of the stenosis (residual lumen), and immediately proximal and immediately distal to it. In each of the 70 subjects considered, the flow velocity was measured and analyzed at the levels of the anterior and middle cerebral and anterior communicating arteries, as well as at the level of the ophthalmic branches (using continuous wave Doppler ultrasonography).

In assessing the hemodynamic significance of the stenoses (at the level of and distal to them), the hemodynamic efficiency of the regions perfused, and possible compensatory circuits (through the anterior communicating artery and branches of the ophthalmic artery), we took into consideration both quantitative and qualitative data: average velocity, the frequency spectrum, the response to dynamic compressive maneuvers (Macchi 1985; Macchi and Catini, 1993). Doppler flow velocity was measured by continuous and pulsed wave frequency analysis. In all subjects, the symptomatology and cerebrovascular events (territory and extent) were correlated with the other observed parameters.

We used an Acuson mod. 128 × P color Doppler ultrasonographic apparatus, a Meda-Sonics mod D9 continuous wave Doppler ultrasonography apparatus, and an Eme mod TC2 64 (pulsed wave Doppler with frequency analysis) transcranial Doppler ultrasonographic apparatus. *Table I* graphically presents the relationship between the diameters of the three vessels in all cases. *Table II* reports the single vessel diameter with respect to sex and age.

TABLE I

CALIBERS: CAROTID ARTERIES



**TABLE II**

**Calibers: Carotid Arteries**

Sex	Age	Ext. Carot.	Inter. Carot.	Com. carot.	Sex	Age	Ext. Carot.	Inter. Carot.	Com. carot.
F	67	2,7	3,6	5,5	M	66	2,7	3,2	5,3
F	60	2,9	3,8	5,5	M	70	2,7	3,6	6
F	71	3	3,9	5,7	M	68	3	3,8	6
F	86	3	3,9	5,7	M	76	3	3,9	5,8
F	67	3,1	3,9	5,7	M	68	3,1	3,9	6,2
F	78	3,1	3,9	5,8	M	84	3,1	4,3	6,2
F	72	3,2	3,9	5,8	M	69	3,4	4,3	6,2
F	69	3,2	4,2	6	M	80	3,4	4,4	6,4
F	80	3,2	4,2	6	M	69	3,4	4,5	6,5
F	83	3,2	4,2	6	M	71	3,5	4,5	6,5
F	70	3,4	4,3	6,1	M	73	3,5	4,5	6,6
F	81	3,4	4,3	6,1	M	69	3,6	4,7	6,6
F	77	3,5	4,4	6,1	M	74	3,8	4,7	6,8
F	73	3,5	4,4	6,1	M	66	3,8	4,8	6,8
F	82	3,5	4,5	6,2	M	70	3,8	4,8	6,9
F	82	3,5	4,5	6,2	M	65	3,9	4,8	6,9
F	67	3,5	4,5	6,5	M	66	3,9	4,9	7
F	68	3,6	4,7	6,5	M	73	3,9	5	7
F	68	3,6	4,7	6,5	M	73	4	5	7
F	65	3,6	4,7	6,6	M	81	4	5,3	7,1
F	77	3,8	4,7	6,6	M	85	4,2	5,3	7,1
F	76	3,8	4,8	6,6	M	78	4,2	5,3	7,3
F	80	3,8	4,8	6,8	M	75	4,3	5,3	7,3
F	66	3,9	4,8	6,9	M	79	4,3	5,5	7,3
F	78	3,9	4,9	6,9	M	77	4,3	5,5	7,4
F	69	3,9	4,9	7	M	82	4,4	5,6	7,4
F	84	3,9	4,9	7	M	77	4,4	5,6	7,5
F	85	4,2	5,3	7,3	M	78	4,5	5,6	7,7
F	65	4,2	5,6	7,3	M	67	4,5	5,7	7,8
F	70	4,3	5,6	7,3	M	72	4,7	5,7	7,9
F	77	4,3	5,7	7,5	M	70	4,7	5,8	8
F	84	4,3	5,8	7,8	M	67	5	5,8	8,2
F	81	4,5	6	7,9	M	84	5	6	8,3
F	70	4,5	6	8	M	65	5	6,1	8,3
F	81	4,7	6,1	10,3	M	79	5,6	6,1	9,5

## RESULTS

A significant relationship was demonstrated among the calibers of the common, internal, and external carotid arteries in each patient (*Tab. III*). No statistically significant correlation emerged between vessel caliber and quality of the atherosclerotic lesion. However, significant, inverse relationships between the original vessel caliber and the degree of stenosis in the affected carotid artery and between the original vessel caliber and the hemodynamic significance of the stenosis were observed.

A significant correlation was observed in both men and women among the original arterial caliber, the presence or absence of symptoms, and the frequency and gravity of cerebrovascular events. An extremely important piece of data emerged from a comparison of the original arterial calibers with the functional viability of the anterior communicating arteries and the intra- and extra-cranial anastomoses through branches of the ophthalmic artery. In both sexes, a lesser functional viability of the compensatory circuits corresponded to smaller arterial caliber ( $p < 0.01$ ).

The relationship between the extent of stenosis and the gravity of the symptomatology, as well as the occurrence of cerebrovascular events, quadrupled for residual luminal areas (in the stenotic internal carotid arteries) less than  $2.5 \text{ mm}^2$ , with a statistically insignificant predominance of men to women. *Table IV* graphically expresses the relationships between the cross-sectional areas of the affected arteries.

## DISCUSSIONS AND CONCLUSIONS

It seems self-evident that greater hemodynamic compromise is associated with a higher degree of arterial stenosis (Blackshear *et al.*, 1980; Franceschi, 1980; Macchi, 1985) and more serious symptomatology and cerebrovascular events (Lusby *et al.*, 1982; Weinberger *et al.*, 1983). Nevertheless, the correlation between adverse outcomes and stenotic lesions with a residual luminal area less than  $2.5 \text{ mm}^2$  is extremely interesting. Although this value must be interpreted with caution and understood as an approximation,  $2.5 \text{ mm}^2$  establishes a level beyond which even an asymptomatic stenosis may represent a serious risk to the patient.

The fact that there is a predominance of males to females may be explained by the larger number of risk factors in males, which may cause more serious vascular abnormalities at the intracranial level; this, in turn, may effect the prognosis. In our case series, however, we have chosen to use a direct two-dimensional echotomographic method to examine only the extracranial course of the carotid arteries of subjects with an isolated lesion of one internal carotid artery.

In any case, the most important finding is represented by the correlation among the arterial caliber, the original arterial caliber (in the stenotic artery), the

TABLE III

Relationship between the caliber of the Common Carotid A. and the Internal Carotid A.

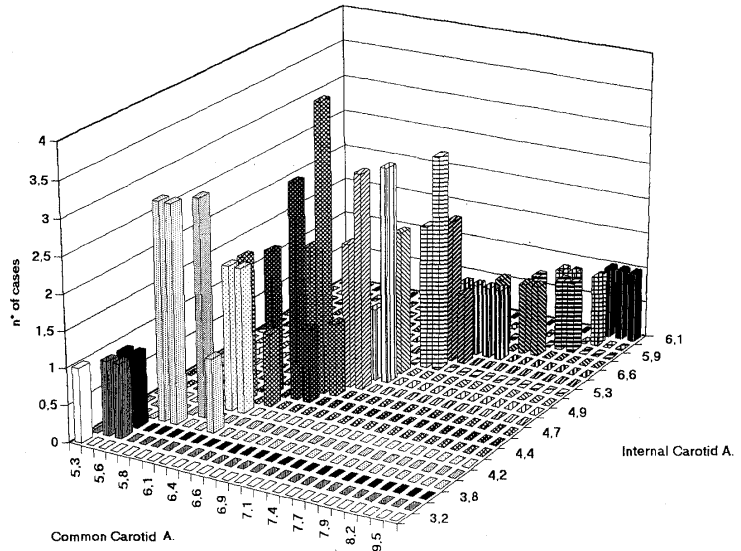
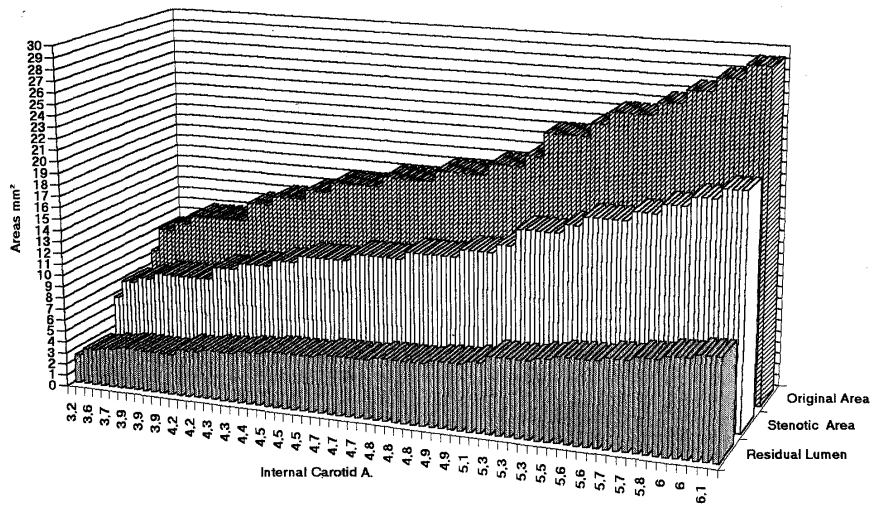


TABLE IV

Relationship between AREAS (Residual Lumen, Stenotic Area, Original Area)



presence or absence of symptoms, and the frequency and seriousness of the cerebrovascular events. On the other hand, the considerable qualitative overlap of the arteriosclerotic lesions in all cases orients us toward a consideration of the unaffected arterial lumen. It appears that, at equivalent degrees of stenosis subjects with narrower vessel lumens are more subject to clinically important cerebrovascular complications.

In the case of hemodynamically significant stenosis, the statistically significant correlation between arterial caliber and functional viability of the compensatory circulation also appears to be of great importance. On the one hand, this confirms the dimensional homogeneity of the arterial vessels in a single subject; on the other hand, it confirms that, in an inversely proportional manner, the arterial luminal area is a possible risk factor for the occurrence of cerebrovascular events.

The clinical importance of these findings may be summarized briefly. First, in the vascular assessment, defining the percentage of stenosis in an artery involved by an arteriosclerotic process is alone insufficient unless the residual luminal area is also determined. Second, patients with smaller arteries are at higher risk of cerebrovascular complications from carotid arteriosclerosis. They therefore require greater attention and closer follow-up. In conclusion, it may be confirmed that the arterial diameter may constitute a risk factor in the clinical manifestations of arteriosclerosis.

*Arrived 20/11/93. Accepted 22/12/93.*

#### REFERENCES

- Ammar AD, Wilson RL, Travers H, Lin JJ, Fara SJ, Chang FC. 1984. Intraplaque Hemorrhage: its significance in cerebrovascular disease. *Amer J Surg*, 148: 840-843.
- Bartynski WS, Darbouze P, Nemir P Jr. 1984. Significance of ulcerated plaque in transient cerebral ischemia. *Amer J Surg*, 141: 353-357.
- Blackshe AR WM Jr, Phillips DJ, Chikos PM, Harley JD, Thiele BL, Strandness DE Jr. 1980. Carotid artery velocity patterns in normal and stenotic vessels. *Stroke*, 11: 67-71.
- Brice JG, Dowsett DJ, Lowe RD, 1964: Haemodynamic effects of carotid artery stenosis. *Brit Med J*, II: 1363-1366.
- Brown PM, Johnston. 1982. The difficulty of quantifying the severity of carotid stenosis. *Surgery*, 92: 468-473.
- Berguer R, Hwang NH. 1974. Critical arterial stenosis: a theoretical and experimental solution. *Ann Surg*, 180: 39-50.
- Edwards JH, Kircheff II, Riles T, Imparato A. 1979. Angiographically undetected ulceration of the carotid bifurcation as a cause of embolic stroke. *Radiology*, 132: 369-373.
- Flanigan PD, Tullis JP, Streeter VL, Whitehouse WM, Frey WG, Stanley JC. 1977. Multiple subcritical arterial stenoses: effect on poststenotic pressure and flow. *Ann Surg*, 186: 663-668.
- Franceschi C. 1980. *L'indagine vascolare con ultrasonografia doppler*. Ed Masson Italia Milano.
- Kassam M, Johnston KW, Cobbold RSC. 1985. Quantitative estimation of spectral broad-

dening for the diagnosis of carotid arterial disease: method and in vitro results. *Ultrasound Med Biol*, 11: 425-433.

Ku DN, Giddens DP, Zarins Ck, Glagov S. 1985. Pulsatile flow and atherosclerosis in the human carotid bifurcation. Positive correlation between plaque location and flow and oscillating shear stress. *Arteriosclerosis*, 5: 293-302.

Langlois Y, Roederer GO, Chan A, Phillips DJ, Beach KW, Martin D, Chikos PM, Strandness DE Jr. 1983. Evaluating carotid artery disease. *Ultrasound Med Biol* 9: 51-63.

Lusby RJ, Woodcock JP, Machleder HI, Ferrel LD, Jeans WD, Skidmore R, Sheddon EJ, Baird RN. 1982. Transient ischaemic attacks: the static and dynamic morphology of the carotid artery bifurcation. *Brit J Surg* 69: S41-S44.

Macchi C. 1985. La Patologia dei tronchi sovraortici nel paziente anziano: diagnostica ragionata. *La Rivista del Medico Pratico* 115, *Gerontologia*, 7: 35-45.

Macchi C, Catini C. 1993. The anatomy and clinical significance of the colateral circulation between the internal and external carotid arteries through the ophthalmic artery. *It J Anat Embryol* 98, 1: 23-29.

Macchi C, Simoni R, Gori G. 1991. Diagnosi e prevenzione dell'ictus nel paziente anziano mediante l'utilizzo di nuove metodiche. *Diagnosis* 3, 2: 105-109.

Macchi C, Giannelli F, Catini C. 1993. The measurement of the calibers of the branches of the aortic arch: a statistical investigation of 430 living subjects using ultrasonic tomography. *It J Anat Embryol* 98, 2: 69-79.

Pizzetti F, Macchi C, Giardini S, Gori G, Simoni R. 1992. La Chirurgia della carotide extracranica nella prevenzione dell'ictus. *Senior* 3: 16-26.

von Reutern M, Budingen HS. 1992. *Sonografia doppler extra ed intracranica*. Centro Scientifico Editore Torino, 154-164.

Weinberger J, Robbins A. 1983. Neurologic symptoms associated with nonobstructive plaque at carotid bifurcation. Analysis by real-time B-mode ultrasonography. *Arch Neurol*. 40: 489-492.

*Address for correspondence:*

prof. CLAUDIO CATINI  
Dipartimento Anatomia  
Umana ed Istologia  
Policlinico di Careggi,  
50134, Firenze