



UNIVERSITÀ
DEGLI STUDI
FIRENZE

FLORE

Repository istituzionale dell'Università degli Studi di Firenze

The anatomy and clinical significance of the collateral circulation between the internal and external carotid arteries through the

Questa è la Versione finale referata (Post print/Accepted manuscript) della seguente pubblicazione:

Original Citation:

The anatomy and clinical significance of the collateral circulation between the internal and external carotid arteries through the ophthalmic artery / C.Macchi;C.Catini. - In: ITALIAN JOURNAL OF ANATOMY AND EMBRYOLOGY. - ISSN 1122-6714. - STAMPA. - 98:(1993), pp. 23-29.

Availability:

The webpage <https://hdl.handle.net/2158/681367> of the repository was last updated on

Terms of use:

Open Access

La pubblicazione è resa disponibile sotto le norme e i termini della licenza di deposito, secondo quanto stabilito dalla Policy per l'accesso aperto dell'Università degli Studi di Firenze (<https://www.sba.unifi.it/upload/policy-oa-2016-1.pdf>)

Publisher copyright claim:

La data sopra indicata si riferisce all'ultimo aggiornamento della scheda del Repository FloRe - The above-mentioned date refers to the last update of the record in the Institutional Repository FloRe

(Article begins on next page)

University of Florence, Italy

* Institute of Gerontology and Geriatric Medicine

** Department of Human Anatomy and Histology

The Anatomy and Clinical Significance of the Collateral Circulation between the Internal and External Carotid Arteries through the Ophthalmic Artery

Claudio Macchi* - Claudio Catini**

Key words: ophthalmic and carotid arteries, collateral circles.

SUMMARY

Complete occlusion of the internal carotid artery is not necessarily associated with total disruption of cerebral blood flow distal to the site of the arterial obstruction. In fact, the flow of blood may be sufficient to maintain cerebral perfusion. This is accomplished by the shunting of blood from the external to the internal carotid artery by means of collateral circuits. While several major branch arteries of the external carotid artery may be recruited in this process, the ophthalmic artery is often the final common pathway before the anastomosis with the internal carotid artery.

With the aim of elucidating these collateral circles, digital subtraction angiography was used to examine 100 patients with total occlusion of the internal carotid artery. These data were compared with those obtained using Doppler ultrasound, duplex scanning, and transcranial Doppler. Forty patients were excluded because there was no demonstrable collateral circulation, because the collateral circulation used the communicating arteries, or because the ophthalmic artery arose from the middle meningeal artery.

Dynamic data were obtained by compressing the branches of the two external and common carotid arteries, and the blood vessels were identified by comparison with previous anatomic studies. We have constructed a precise map of the intra- and extracranial circles that connect the internal and external carotid arteries through the pathways that include the ophthalmic artery. This map demonstrates why apparently identical vascular occlusions may have divergent sympto-

matologies and clinical outcomes, which may range from the complete absence of symptoms to cerebral infarction.

INTRODUCTION

It is commonly observed that the clinical manifestations of complete occlusion of the internal carotid artery are extremely variable. On the one hand, it may cause infarction of cerebral tissue in that arterial distribution; at the other extreme, there may be no neurological manifestations whatsoever. Undoubtedly, this reflects differences among the various etiologies of arterial occlusion. However, the presence of a collateral circulation between the patent external and occluded internal carotid arteries is critical to the maintenance of cerebral blood perfusion by the latter.

In this respect, the ophthalmic artery is a particularly significant branch of the internal carotid artery. Several other investigators have reported their observations on the clinical significance of the collateral circulation between the internal and external carotid arteries (ICA and ECA, respectively) through the ophthalmic artery (Dauzat, *et al.*, 1986; Hennerici, 1991; von Reutern, 1992; Franceschi, 1992). It has been reported that, in the even of ICA occlusion, these collateral circles can preserve cerebral blood flow by shunting the flow of arterial blood from the ECA to a point in the ICA distal to the occlusion (Vogeslang, 1962; Dauzat, *et al.*, 1986; Franceschi, 1992; von Reutern, 1992).

Nonetheless, there is a considerable degree of discordance among descriptions of the anatomy of the ophthalmic artery and its branches, as well as its anastomoses with the branches of the ECA (Chiarugi, 1912; Chiarugi and Bucciante, 1975; Pernkopf, 1963; Testut and Latarjet, 1972; Testut and Jacob, 1974; Sobotta and Becher, 1974; Spalteholz and Spanner, 1977; Gray, 1973 and 1989). What is more, the nomenclature is confusing: the same artery is often assigned different names, even in the same study.

We have studied 100 patients who had presented with occlusion of a single carotid artery. They were examined by digital subtraction angiography, Doppler ultrasound, duplex scanning, and transcranial Doppler. By comparing our findings with previous anatomic (Chiarugi, 1912; Chiarugi and Bucciante, 1975; von Lanz, 1955; Hayreh, 1962; Pernkopf, 1963; Gray, 1973 and 1989; Testut and Jacob, 1974; Testut and Latarjet, 1972; Sobotta and Becher, 1974; Spalteholz and Spanner, 1977), angiographic (Vogeslang, 1962; Zulch, 1969; Hass, 1968; Wiedner, 1976; Huber, 1979), and ultrasonographic (Aaslid, 1986; Dauzat, *et al.*, 1986; Hennerici, 1991; Franceschi, 1992; von Reutern, 1992) studies, we have mapped the circulation of the intra- and extracranial circles between the ICA and ECA through the ophthalmic artery. In particular, we have defined the anastomoses among the branches of the ophthalmic artery and the branches of the ECA.

SUBJECTS AND METHODS

Subjects

One hundred patients (46 men and 54 women; age range, 48 to 86) with an extracranial occlusion of a single internal carotid artery (ICA) were identified by Doppler and color Doppler ultrasonography. The vascular structures were further studied by digital subtraction angiography and transcranial Doppler. Using manual compression, dynamic tests were performed during Doppler ultrasound examination of the following arteries: the common carotids (CCA), the contralateral internal carotid, the facial, the mental, and branches of the superficial temporal artery. In order to avoid the eventual complication of plaque embolization, compression of the CCAs was performed only after it had been confirmed that the compression points were patent and free of atherosclerotic disease.

Of the 100 patients, 40 were excluded. Sixteen patients were excluded on the basis of the presence of a compensatory circuit through the anterior or posterior communicating artery; 20 were excluded because they had no demonstrable collateral circulation; and 4 were excluded because the ipsilateral ophthalmic artery arose from the middle meningeal artery, rather than the ICA. Since the ophthalmic artery has been reported to arise from the middle meningeal artery in 4 to 5% of normal subjects, it cannot be determined whether the collateral circulation is a result of the ICA occlusion or congenital.

The remaining 60 patients were found to have collateral circles between the ECA and ICA through the ophthalmic artery.

Materials

The carotid angiographies were performed by digital subtraction using a Philips DVI 2 system. The Doppler ultrasound studies were performed using continuous wave Doppler (Meda Sonic D9) and transcranial pulse wave Doppler (EME, Tc2 64) ultrasound systems. Color Doppler studies were performed with a color duplex machine by Acuson (models 128 and 128 XP).

RESULTS

Of the 60 patients who were studied, the ICA of 16 patients was found to be supplied by the ECA through a collateral circle that comprised the facial, angular, and ophthalmic arteries. In 13 patients, the ECA communicated with the ophthalmic artery by means of the superficial temporal artery, which anastomosed with either the supraorbital or supratrochlear artery. The supraorbital anastomosis was predominant. Two patients demonstrated a collateral circulation through the maxillary and infraorbital arteries by means of the angular artery.

In one instance, the compensatory circulation was supplied by the contralateral

ECA by means of anastomoses between the contralateral supratrochlear and dorsal nasal arteries. In another case, the collateral circle comprised the maxillary, infraorbital, and medial and lateral branches of the palpebral arteries.

The collateral circulation of 27 patients was found to reflect a combination of the preceding findings.

Of the 20 patients who were excluded because of the apparent absence of a collateral circulation, 9 were completely asymptomatic. Although they were not angiographically demonstrable, the lack of symptomatology suggests that they nonetheless had an unusual compensatory collateral circle, such as suggested in *Figure 2*.

Figure 1 illustrates the extracranial ramifications of the main branches of the ECA and their anastomoses with the ophthalmic artery and its branches. Most significant among them are the superficial temporal, facial, and infraorbital arteries. They anastomose with the ophthalmic artery by means of the supraorbital, supratrochlear, and angular arteries. The supratrochlear artery, which arises from the ophthalmic artery at the level of its nasal branch, anastomoses not only with the ipsilateral supraorbital artery, but the contralateral supratrochlear artery.

In addition to the collateral circles illustrated in *Figure 1*, *Figure 2* schematically illustrates the intracranial collateral circles through which the ECA and ICA communicate.

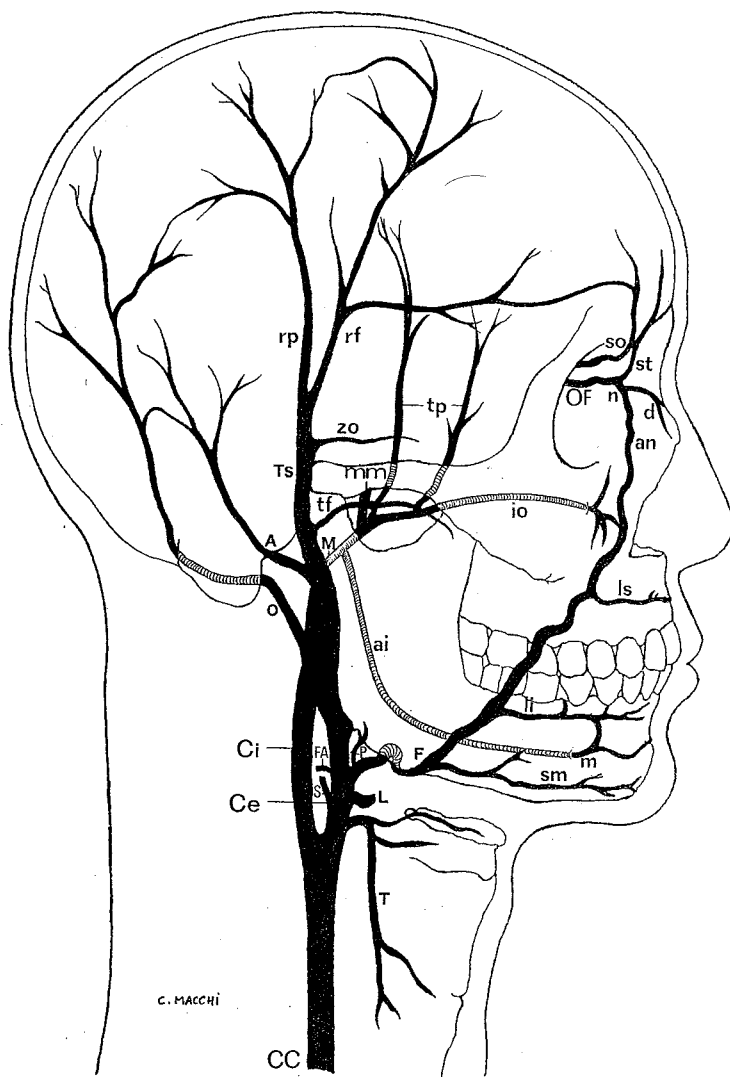
Of note, there is a very rich anastomotic circle that allows communication among the palpebral and lacrimal arteries, branches of the maxillary artery (including the middle meningeal, infraorbital, and deep temporal arteries), and the transverse facial artery. There is a similar rich anastomotic network between the sphenopalatine and dorsal nasal arteries.

DISCUSSION AND CONCLUSIONS

The findings of this study confirm that small arteries of little apparent significance play a significant role in the maintenance of the cerebral circulation in the face of an occlusion of the internal carotid artery. Blood flow through the ICA can be supplied distal to the occlusion by retrograde blood flow through the ophthalmic artery, which receives blood from the ECA through a variety of collateral circuits. Although the arteries are frequently small, the flow of blood can be sufficient to sustain cerebral circulation.

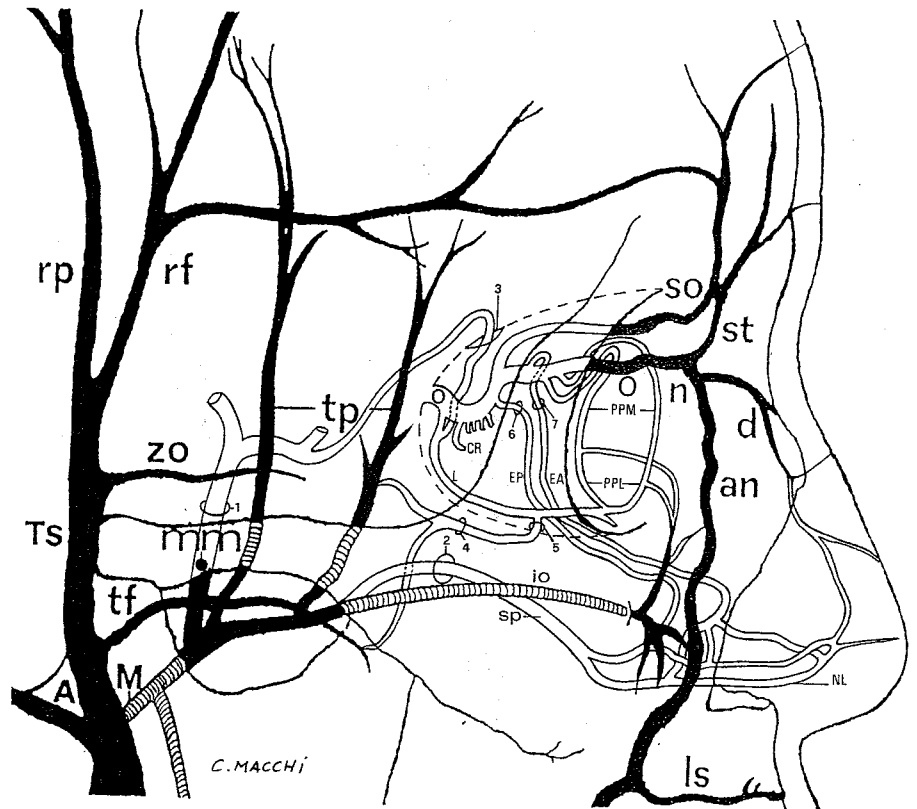
In the presence of an occlusion of the ICA, the variability of neurological signs and symptoms may be explained by the variability in the efficiency and extensiveness of the collateral circles, even in patients affected by the same vascular pathology. Familiarity with these collateral circles may contribute to the prognostic assessment and the determination of the appropriate therapeutic intervention.

Fig. 1



- | | | | |
|----|-----------------------------|----|--|
| CC | Common carotid artery | o | Occipital artery |
| Ce | External carotid artery | A | Posterior Auricular artery |
| Ci | Internal carotid artery | io | Infraorbital artery |
| OF | Ophthalmic artery | tf | Transverse Facial artery |
| T | Superior thyroid artery | TS | Superficial Temporal artery |
| L | Lingual artery | zo | Zygomatico-orbital artery |
| F | Facial artery | rp | parietal branch of the Superficial Temporal artery |
| FA | Ascending Pharyngeal artery | rf | frontal branch of the Superficial Temporal artery |
| P | Ascending palatine artery | tp | Deep Temporal arteries |
| S | Sternocleidomastoid artery | so | Supraorbital artery |
| sm | Submental artery | st | Supratrochlear artery |
| m | Mental artery | n | Nasal branch of the Ophthalmic artery |
| M | Maxillary artery | d | Dorsal Nasal artery |
| ai | Inferior Alveolar artery | an | Angular artery |
| li | Inferior Labial artery | | |
| ls | Superior Labial artery | | |
| mm | Middle Meningeal artery | | |

Fig. 2



- | | | | |
|-----|---------------------------------------|----|--|
| O | Ophthalmic artery | ZO | Zygomatico-orbital artery |
| CR | Central artery of the retina | TS | Superficial Temporal artery |
| L | Lacrimal artery | rp | Parietal branch of the Superficial Temporal artery |
| EP | Posterior Ethmoidal artery | rf | Frontal branch of the Superficial Temporal artery |
| EA | Anterior Ethmoidal artery | tf | Transverse Facial artery |
| PPL | Lateral Palpebral arteries | M | Maxillary artery |
| PPM | Medial Palpebral arteries | A | Posterior Auricular artery |
| io | Infraorbital artery | NL | Lateral Nasal artery |
| sp | Sphenopalatine artery | 1 | Spinosum foramen |
| n | Nasal branch of the Ophthalmic artery | 2 | Sphenopalatine foramen |
| so | Supraorbital artery | 3 | Orbital Superior fissure |
| st | Supratrochlear artery | 4 | Zygomatico-temporal foramen |
| d | Dorsal Nasal artery | 5 | Zygomatico-orbital foramen |
| an | Angular artery | 6 | Ethmoidal posterior foramen |
| ls | Superior Labial artery | 7 | Ethmoidal anterior foramen |
| tp | Deep Temporal arteries | | |
| mm | Middle Meningeal artery | | |

REFERENCES

- Aaslid R, ed., 1986. *Transcranial Doppler Sonography*. Vienna: Springer.
- Chiarugi G, 1912. *Istituzioni di Anatomia dell'Uomo*. Milan: Società Editrice Libreria.
- Chiarugi G, Bucciante L, 1975. *Istituzioni di Anatomia dell'Uomo*. Milan: Vallardi.
- Dauzat M, Laroche JP, DeBray JM, Juhel P, Becker F, Cesari JB, Jonnart L, Domergue A, Carette G, Duvauferrier R, Heyden D, Maugin D, Vongouth S, Davinroy M, 1986. *Pratique de l'Ultrasonographie Vasculaire (Doppler-Echographie)*. Paris: Vigot.
- Franceschi C, 1992. *L'Indagine Vascolare con Ultrasonographia Doppler*. Milan: Masson.
- Gray's Anatomy, 1973. London: Longman Group, Ltd.; and 1989.
- Hass WK, Fields WS, North RR, Kricheff I, Chase NE, Bauer RB, 1968. Joint study of extracranial arterial occlusion. II. Arteriography. Techniques, sites, and complications. *J Amer Med Ass* 203: 961-8.
- Hayreh SS, Dass R, 1962. The ophthalmic artery. I. Origin and intracranial and intracanalicular course. *Brit J Ophthalm* 46: 65-8.
- Hayreh SS, 1962. The ophthalmic artery. III. Branches. *Brit J Ophthalm* 46: 212-47.
- Hennerici M, Neurburg HD, 1991. *Diagnostica Vascolare con Ultrasuoni*. Rome: Il Pensiero Scientifico, Editore.
- Krayenbühl H, Yasargil MG, 1979. In: Huber P, ed. *Zerebrale Angiographie für Klinik und Praxis*. Stuttgart: Thieme.
- Lang J, Bushe KA, Buschmann W, Linnert D. Kopf, teil B. Gehirn- und Augenschädel, 1979. In: von Lanz T, Wachsmut W. *Praktische Anatomie. ein Lehr- und Hilfsbuch der Anatomischen Grundlagen ärztlichen Handelns*. Berlin: Springer.
- von Lanz T, Wachsmuth W, 1955. *Praktische Anatomie. Ein Lehr- und Hilfsbuch der Anatomischen Grundlagen ärztlichen Handelns. Bd I/2 Hals*. Berlin: Springer.
- Pernkopf E, 1963. *Atlante di Anatomia Sistemática e Topografica dell'Uomo*. Padua: Piccini Editore.
- von Reutern GH, Budingen JH, 1992. *Sonografia Doppler Extra ed Intracranica*. Turin: Centro Scientifico Editore.
- Sobotta J, Becher H, 1974. *Atlante di Anatomia dell'Uomo*. Florence: USES.
- Spalteholz W, Spanner R, 1977. *Atlante di Anatomia Umana*. Milan: Vallardi.
- Testut L, Jacob O, 1974. *Trattato di Anatomia Topografica*. Turin: UTET.
- Testut L, Latarjet A, 1972. *Trattato di Anatomia Umana*. Turin: UTET.
- Vogeslang H, 1962. Über cine-angiographisch selten nachzuweisende anastomose zwischen dem a. carotis interna- und dem a. carotis externa-kreislauf-variante des blut-zufflusses zur a. meningea media über anatomosen von der a. ophthalmica. *Nervenarzt*, 32: 518-20.
- Wiedner F, Schreyer H, 1976. Seltene anomalien zerebralen gefäße (einseitige aplasie der a. carotis interna, persistenz der a. hypoglossia). *Fortschr. Röntgenstr*, 124: 245-9.
- Zülch KJ, 1969. Allgemeine prinzipien bei der entstehung der kollateralkreisläufe der Hirnarterien. *Der Radiologie*, 9: 369-406.

Address:
Prof. CLAUDIO CATINI
Dipartimento di Anatomia
Umana Normale ed Istologia
Policlinico di Careggi
Firenze