



UNIVERSITÀ
DEGLI STUDI
FIRENZE

FLORE

Repository istituzionale dell'Università degli Studi di Firenze

Diagnostic value of preoperative DNA measurement on FNA in benign and malignant thyroid neoplasm.

Questa è la Versione finale referata (Post print/Accepted manuscript) della seguente pubblicazione:

Original Citation:

Diagnostic value of preoperative DNA measurement on FNA in benign and malignant thyroid neoplasm / Perigli G; Cicchi P; Cianchi F; Artusi R; Olivari D; Caldini A; Cortesini C.. - In: JOURNAL OF EXPERIMENTAL & CLINICAL CANCER RESEARCH. - ISSN 0392-9078. - STAMPA. - 17:(1998), pp. 113-116.

Availability:

The webpage <https://hdl.handle.net/2158/770076> of the repository was last updated on

Terms of use:

Open Access

La pubblicazione è resa disponibile sotto le norme e i termini della licenza di deposito, secondo quanto stabilito dalla Policy per l'accesso aperto dell'Università degli Studi di Firenze (<https://www.sba.unifi.it/upload/policy-oa-2016-1.pdf>)

Publisher copyright claim:

La data sopra indicata si riferisce all'ultimo aggiornamento della scheda del Repository FloRe - The above-mentioned date refers to the last update of the record in the Institutional Repository FloRe

(Article begins on next page)

Diagnostic Value of Preoperative DNA Measurement on FNA in Benign and Malignant Thyroid Neoplasm

G. Perigli, P. Cicchi, F. Cianchi, R. Artusi, D. Olivari, A. Caldini, C. Cortesini¹

Dept. of General Surgery, University of Florence; Service of Lab. Analysis, Ospedale Careggi, Florence, Italy

Despite remarkable advances in the management of thyroid neoplasms were obtained, two problems still remain unsolved.

One is the extent of glandular removal in "low-risk" differentiated carcinomas, singled out by a series of well-known parameters such as patient's age, type of growth, local extent, remote spread, tumour size (1).

Unfortunately, these data are not always available prior to surgery and they cannot be accurately ascertained during it. The second is the true nature of the so-called "follicular tumours" which are borderline neoplasms not attributable with certainty to the benign or malignant condition by either cytology or pathology (2).

Since the development of flow cytometry has made possible to easily determine ploidy and cell proliferation, we have decided to determine if this technique, applied on fresh FNA material, could contribute to solve the two problems, by adding a new biological parameter to the pathological and clinical ones. Non fixed material obtained by needle aspiration would have the twofold advantage of allowing the analysis preoperatively and avoiding the doubts on the use of fixed and embedded specimen. In fact, this is held responsible for the discordant data provided by the method when it is assumed as an indicator of biological aggressivity in endocrine neoplasms, particularly those of the thyroid (3-4-5-6).

To further check the validity of flow cytometric analysis on FNA material we decided to exactly repeat the procedure on the removed surgical specimen.

Materials and Methods

The study included a continuous series of 29 thyroid nodules diagnosed as neoplasms.

Selection and subsequent surgical treatment was carried out at the Endocrine Surgery Unit of the University Surgery Clinic in Florence. Each nodule was submitted to clinical and sonographic examination using a 10 MHz probe, and FNA traditional standard techniques were echo-guided in the small sized nodules. For DNA analysis, needle aspiration was subsequently repeated and

material was suspended in a phosphate-buffered physiological solution (PBS) at +4°C and preserved at -80°C.

On the just removed surgical specimen, both the fragments for histologic and for DNA analysis were taken from the same necrosis-free area. At cytofluorometric analysis, the samples were mechanically separated in PBS and the cell suspension was filtered, washed and centrifuged. The cells were resuspended in a 0,1% solution of sodium citrate which contained 50 mcg/ml propidium iodide, 0,01% Nonidat P40 and 5 mcg/ml ribonuclease (RNAase). After incubation with dye for 1 to 2 hours in the dark, at room temperature, the bond was stabilised for 15-30 min at 0°C. Analysis was carried out using an Epics Elite Cytofluorimeter (Coulter) equipped with an Argon laser with emission at 488 nm, standardised with frozen human thymocytes.

For each sample the data relative to scatter and red fluorescence of 15-20.000 cells were memorised.

The fluorescence histograms were analysed by Multicycle (Phoenix) computer program.

Ploidy was classified according to Shankey (7): anomalies were referred as a DNA-index (DNA-I). Information regarding the cellular cycle were expressed as percentage of cells in S phase (S-phase %). Cyto- and histomorphological evaluations were made using traditional techniques and criteria.

On the basis of hystological diagnosis, the neoplasms were subdivided into three groups: carcinomas, Hürthle cell adenomas and follicular adenomas.

Results

Cytological diagnosis of the 29 nodules resulted in 18 carcinomas, 6 follicular hyperplasias, 3 follicular adenomas and 2 Hürthle cell adenomas.

On the other hand, definitive hystological examination showed 17 carcinomas (12 typical papillary, 3 follicular variants of the papillary, 1 with Hürthle cells and 1 anaplastic), 7 follicular adenomas and 5 Hürthle cell adenomas. Thus, only one cytological false positive and no false negative were reported.

Table I shows DNA-I and S phase %, determined on FNA and fresh surgical material of the 17 carcinomas.

Aneuploidy was found in one case among the aspirated samples and in two cases among the surgical ones. In the latter group, a high S-phase % was revealed only in one case and was never found in the former one. The most significant prognostic factors for each carcinoma have been synthesised on the right side of Table I (1-8).

Table II summarises the same features for Hürthle cell adenomas and follicular adenomas. Aneuploidy was found in two cases among the aspirated samples and in three cases among the surgical ones of Hürthle cell adenomas. It was found in two cases among the aspirated samples and in two cases among the surgical ones of the follicular adenomas. An abnormal S-phase % was never found in the aspirated samples. Whereas, four Hürthle cell adenomas and one follicular adenoma showed a high S-phase percentage among surgical specimens.

Figure 1 and 2 synthesise the DNA-I of each hystopathological group, while figure 3 and 4 report their cellular kinetic pattern. In all cases, values from aspirated and surgical samples were compared.

Discussion

Cytofluorometry on FNA seems to be both an appropriate and reliable analysis for preoperative identification of DNA-I and S-phase percentage in thyroid nodules which need surgical removal. This was suggested by the significant relationship between values obtained from the aspirated and the surgical material, both "freshly" analysed. Unfortunately, since many of the aspirates were not evaluable (4 out of 17 carcinomas, 4 out of 12 adenomas) some limits are evident as for method applicability. In fact, the sample adequacy, at the moment of its needle drawing, can be evaluated only approximately on the basis of the opalescence of the solution in which the cells are dispersed. In those cases that were not completely satisfactory, the aspiration was not repeated so as to avoid any further trauma on the nodule, that may make hystomorphologic examination more difficult, especially in adenomas.

In the only case of anaplastic carcinoma, necrotic-haemorrhagic phenomena were so wide that a complete analysis could not be carried out, even on the surgically

Tab. I - DNA-I, S-PHASE % and clinico-pathological features in carcinomas

CARCINOMAS												
Pt	FNA		Surg. Specimen		Cytology	Age	Pathology					
	DNA-I	S-Phase (%)	DNA-I	S-Phase (%)			H type/Caps/Growth/Extension/Size					
E G	1	2,8	1	1,5	Differ Ca	66	P	No	Inf	Extr	1	
P S	n.e.	n.e.	1	1,5	Differ Ca	32	P	Yes	Exp	Intr	1	
P S	1	1,0	1	0,8	Differ Ca	32	P	Yes	Exp	Intr	3,8	
B L	n.e.	n.e.	1	5,3	Susp Differ Ca	26	P	Yes	Exp	Intr	1,2	
S A	1	1,4	1	2	Differ Ca	32	P	Yes	Exp	Intr	3	
A R	1	2,5	1	0,9	Susp Differ Ca	47	P	No	Inf	Extr N+	5	
P R	1	1,4	1	1,3	Differ Ca	69	P	Yes	Exp	Intr	0,8	
C G	1	2,6	1	1	Differ Ca	47	P	Part	Exp	Intr	1,5	
M A	1	1,9	1	1,5	Susp Differ Ca	44	P	No	Inf	Intr	1,5	
G R	1	2,2	1	3,3	Differ Ca	70	P	No	Inf	Extr N+	1,2	
V M	1	2,5	1	2,6	Differ Ca	24	P	Yes	Exp	Intr N+	0,8	
R K	1	0,8	1	0,8	Differ Ca	50	P v.F	Yes	Exp	Intr	2	
C C	n.e.	n.e.	1	1,2	Differ Ca	33	P v.F	No	Exp	Intr N+	2,5	
B S	1	0,4	1	1,8	Differ Ca	40	P v.F	No	Inf	Extr N+	2	
B T	1	2,5	1,2	2,3	Differ Ca	80	P	No	Inf	Extr	5	
L B	1,5	2,6	1,5	2,4	Susp Hürthle C Ca	53	Hü	No	Inf	Extr	1,5	
R G	n.e.	n.e.	1	n.e.	Poor Differ Ca	61	Ppd	No	Inf	Extr	6	

Pt: patients, n.e.: not evaluable, Cytology: Ca: carcinoma, Susp: suspect, Differ: differentiated; Pathology: H type: hystologic type, P: papillar carcinoma, PvF: follicular variant of papillar carcinoma, Hü: Hürthle-cell carcinoma, Ppd: papillar carcinoma with poor differentiated areas; Caps: capsulated: yes, no, part: partially; Growth: Inf: infiltrating, Exp: expanding; Extension: Extr-Intr: extra or intra thyroidal, N+ : laterocervical nodes metastasis ; Size expressed in centimeters.

Tab. II - DNA-I, S-PHASE % and clinico-pathological features in adenomas

ADENOMAS							
Pt	Age	FNA		Surg. Specimen		Cytology	Pathology
		DNA-I	S-Phase (%)	DNA-I	S-Phase (%)		
TL	63	1,5	n.e.	1,6	3,2	Follicular Tumour	Hürthle Cell Adenoma
LC	64	1,6	n.e.	1,6	6,8	Follicular Tumour	Hürthle Cell Adenoma
FF	39	n.e.	n.e.	1,9	3,9	Hürthle Tumour	Hürthle Cell Tumour
EL	39	1	2,9	1	3,6	Follicular Tumour	Hürthle Cell Adenoma
TG	39	n.e.	n.e.	1	1,8	Hürthle Tumour	Hürthle Cell Adenoma
TM	59	1,7	n.e.	1,11	1,6	Differentiated Ca	Microfollicular Adenoma
BO	36	1,2	3,5	1,3	3,5	Foll. Hyperplasia	Trabecular Adenoma
PR	41	1	0,8	1	0,8	Foll. Hyperplasia	Micro/Macro follicular Adenoma
IV	38	1	2,0	1	0,4	Foll. Hyperplasia	Micro/Macro follicular Adenoma
PL	63	n.e.	n.e.	1	1,4	Foll. Hyperplasia	Micro/Macro follicular Adenoma
PA	41	1	1,9	1	1	Foll. Hyperplasia	Trabecular Adenoma
CA	58	n.e.	n.e.	1	1	Foll. Hyperplasia	Micro/Macro follicular Adenoma

Pt: patients; n.e.: not evaluable, Cytology: C: Cell, Ca: carcinoma, Foll: Follicular; Pathology: Micro/Macro: micro and macrofollicular adenoma.

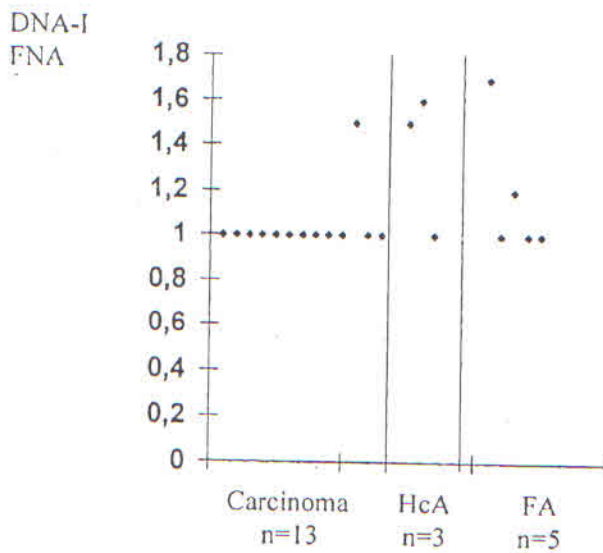


Fig. 1 - DNA-index evaluates on FNA samples. HcA: Hürthle cell adenoma; FA: follicular adenoma.

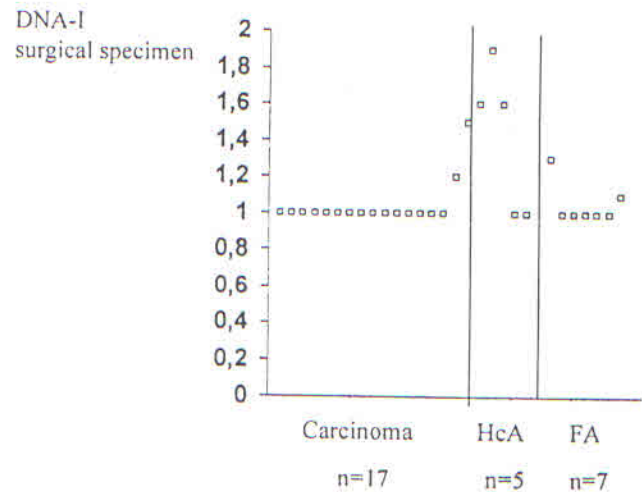


Fig. 2 - DNA-index evaluated on surgical specimen. HcA: Hürthle cell adenoma; FA: follicular adenoma.

removed tissue. Such a problem can be more serious in adenomas where necrotic-haemorrhagic alterations are associated with oedematous inhibition, the extent of which could determine a concentration of cells below the values necessary for evaluation. With regard to our study we unexpectedly discovered only 2 aneuploid car-

cinomas (only one resulted aneuploid also in the aspirated sample) but with a low S-phase %. The only carcinoma with high S-phase percentage was euploid.

Therefore, aneuploidy was observed, before surgery, only in 1 out of 17 carcinomas. This information did not modify the type of treatment, i.e. total thyroidectomy,

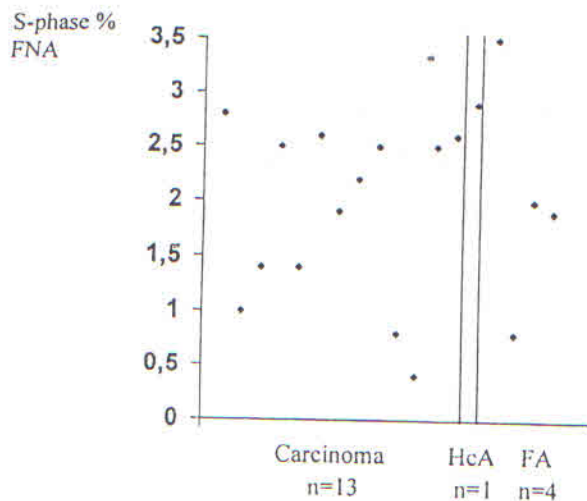


Fig. 3 - S-phase evaluated on FNA samples. HcA: Hürthle cell adenoma; FA: follicular adenoma.

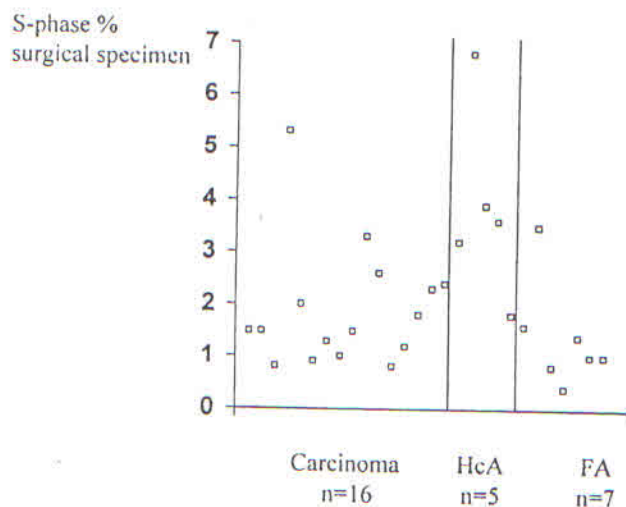


Fig. 4 - S-phase evaluated on surgical specimen. HcA: Hürthle cell adenoma; FA: follicular adenoma.

which was due to the presence of unfavourable traditional prognostic factors. A more surprising result was the high frequency of aneuploidy and the high S-phase percentage values found in adenomas, particularly in the Hürthle cell ones, without any association with capsula and vascular invasion, pathognomonic of malignancy.

With regard to the Hürthle cell adenomas, a high affinity of the oxyphilous cells for the specific nuclear dye, i.e. propidium iodide, has been hypothesised to explain this datum. However, the same impairment has been reported even in common follicular adenomas, thus it is likely that this finding is not due to a technical artefact. A comparison between cytofluorometric and cytogenetic studies may provide any further contribution to explain this problem. In adenomas, just as in carcinomas, DNA analysis, preoperatively determined, did not influence the surgical management, i.e. lobectomy. Only for aneuploid adenomas a frozen biopsy was mandatory to confirm the benign nature of the lesion.

In conclusion, our study is consistent with previous ones (2-5) which confirm the limited diagnostic value of DNA analysis in endocrine neoplasms.

Moreover, its prognostic potential, even widely described (3-5), does not seem to add much to the already proven clinical-morphologic risk factors.

References

1. Cicchi P, Perigli G, Artusi R, Cortesini C. La loboistmectomia extracapsulare nel trattamento del carcinoma differenziato della

tiroide. *Chirurgia*, 7: 899, 1994.

2. McLeod MK. The measurement of DNA content and ploidy analysis in thyroid neoplasm. *Otolaryngol CI of North Am*, 23: 271, 1990.
3. Bengtsson A, Malmaeus J, Grimelius L, Johanssen H, Pontén J, Rastad J, Åkerström G. Measurement of nuclear DNA content in thyroid diagnosis. *World J Surg*, 8: 481, 1984.
4. Shellhout LJDH, Cornelisse CJ, Goslings BH, Hamming JF, Kuipers-Dijkshoorn NJ, Van de Velde CJH, Fleuren GJ. Frequency and degree of aneuploidy in benign and malignant thyroid neoplasms. *Int J Cancer*, 45: 16, 1990.
5. Grant CS, Hay ID, Ryan JJ, Bergstrahl EJ, Rainwater LH, Goellner JK. Diagnostic and prognostic utility of flow cytometric DNA measurements in follicular thyroid tumors. *World J Surg*, 14: 283, 1990.
6. Bäckdahl M, Wallin G, Lowagen T, Auer G, Granberger PO. Fine needle biopsy cytology and DNA analysis. Their place in the evaluation and treatment of patients with thyroid neoplasms. *Surg Clin North Am*, 67: 197, 1987.
7. Shankey TV et al. Guidelines for implementation of clinical DNA cytometry. *Cytometry*, 14: 472, 1993.
8. Carengiu ML, Zampi G, Pupi A, Castagnoli A, Rosai J. Papillary carcinoma of the thyroid. A clinicopathological study of 241 cases treated at the University of Florence, Italy. *Cancer*, 1985; 55: 805.

Presented at S.I.C.O. 1st National Symposium: "Guidelines for Diagnosis and Treatment of Thyroid Carcinoma", Rome 1997

Giuliano Perigli MD
Istituto Clinica Chirurgica Generale e D.C.
Viale Morgagni, 85 - 50134 Firenze