



UNIVERSITÀ  
DEGLI STUDI  
FIRENZE

## FLORE

# Repository istituzionale dell'Università degli Studi di Firenze

### **Coronally advanced flap versus connective tissue graft in the treatment of multiple gingival recessions: a split-mouth study with a**

Questa è la Versione finale referata (Post print/Accepted manuscript) della seguente pubblicazione:

*Original Citation:*

Coronally advanced flap versus connective tissue graft in the treatment of multiple gingival recessions: a split-mouth study with a 5-year follow-up / Pini-Prato GP;Cairo F;Nieri M;Franceschi D;Rotundo R;Cortellini P. - In: JOURNAL OF CLINICAL PERIODONTOLOGY. - ISSN 0303-6979. - ELETTRONICO. - 37:(2010), pp. 644-650. [10.1111/j.1600-051X.2010.01559.x]

*Availability:*

This version is available at: 2158/773990 since:

*Published version:*

DOI: 10.1111/j.1600-051X.2010.01559.x

*Terms of use:*

Open Access

La pubblicazione è resa disponibile sotto le norme e i termini della licenza di deposito, secondo quanto stabilito dalla Policy per l'accesso aperto dell'Università degli Studi di Firenze (<https://www.sba.unifi.it/upload/policy-oa-2016-1.pdf>)

*Publisher copyright claim:*

(Article begins on next page)

# Coronally advanced flap *versus* connective tissue graft in the treatment of multiple gingival recessions: a split-mouth study with a 5-year follow-up

Giovan Paolo Pini-Prato<sup>1</sup>, Francesco Cairo<sup>1</sup>, Michele Nieri<sup>1</sup>, Debora Franceschi<sup>1</sup>, Roberto Rotundo<sup>1</sup> and Pierpaolo Cortellini<sup>2,3</sup>

<sup>1</sup>Department of Periodontology, University of Florence, Florence, Italy; <sup>2</sup>Accademia Toscana di Ricerca Odontostomatologica (ATRO), Florence, Italy; <sup>3</sup>European Research Group on Periodontology (ERGOPERIO), Berne, Switzerland

Pini-Prato GP, Cairo F, Nieri M, Franceschi D, Rotundo R, Cortellini P. Coronally advanced flap *versus* connective tissue graft in the treatment of multiple gingival recessions: a split-mouth study with a 5-year follow-up. *J Clin Periodontol* 2010; 37: 644–650. doi: 10.1111/j.1600-051X.2010.01559.x

## Abstract

**Aim:** The aim of this long-term study was to compare the clinical outcomes of coronally advanced flap (CAF) alone *versus* coronally advanced flap plus connective tissue graft (CAF+CTG) in the treatment of multiple gingival recessions using a split-mouth design over 5 years of follow-up.

**Materials and Methods:** A total of 13 patients (mean age 31.4 years) showing multiple bilateral gingival recessions were treated. On one side, CAF+CTG was used, while in the contra-lateral side, a CAF alone was applied. Clinical outcomes were evaluated at the 6-month, 1-year and 5-year follow-ups.

**Results:** A total of 93 Miller class I, II and III gingival recessions were treated. In the CAF+CTG-treated sites, the baseline gingival recession was  $3.6 \pm 1.3$  mm, while in the CAF-treated sites, it was  $2.9 \pm 1.3$  mm ( $p = 0.0034$ ). No difference in terms of the number of sites with complete root coverage (CRC) was reported (OR = 0.49,  $p = 0.1772$ ) at the 6-month follow-up. At the 5-year follow-up, CAF+CTG-treated sites showed a higher percentage of sites with CRC (52%) than CAF-treated sites (35%) (OR = 3.94;  $p = 0.0239$ ). An apical relapse of the gingival margin in CAF-treated sites was observed while a coronal improvement of the margin was noted in CAF+CTG-treated sites between the 6-month and the 5-year follow-ups.

**Conclusions:** CAF+CTG provided better CRC than CAF alone in the treatment of multiple gingival recessions at the 5-year follow-up.

Key words: aesthetics; connective tissue graft; coronally advanced flap; long-term follow-up; multiple gingival recessions; root coverage

Accepted for publication 3 February 2010

The treatment of buccal gingival recession for aesthetics or root sensitivity is a frequent demand in patients with high

standards of oral hygiene (American Academy of Periodontology 1996). Several root coverage procedures have been tested to move the position of the gingival margin coronally including pedicle flaps, free soft tissue grafts, combination of pedicle flaps plus grafts or barrier membranes (Pini-Prato et al. 1995). Irrespective of the surgical approach, the ultimate goal of a root coverage procedure is the complete coverage of the recession defect and an optimal integration of the covering tissue with

the adjacent soft tissue (Cairo et al. 2008, 2009).

Localized gingival recessions have been successfully treated with the coronally advanced flap (CAF) (Allen & Miller 1989, Pini-Prato et al. 2000, Nieri et al. 2009). Improvements in clinical outcomes have been reported by adding a connective tissue graft to the coronally advanced flap (CAF+CTG). This approach is associated with a greater probability of obtaining complete root coverage (CRC) in the treatment of

## Conflict of interest and source of funding statement

*Conflict of interest:* The authors certify that there is no conflict of interest concerning the contents of the study. This study has been self-supported by the authors.

*Sources of funding:* none.

localized recession compared with other techniques (Cairo et al. 2008, Cortellini et al. 2009). Although a large number of clinical trials have been published on the treatment of localized gingival recession, few data are available on the long-term results of these approaches (Cairo et al. 2008).

Multiple recessions have been treated with both the CAF and the bilaminar technique (Bernimoulin et al. 1975, Zabalegui et al. 1999). Recent surgical advances include a CAF procedure without releasing incisions (Zucchelli & De Sanctis 2000). A randomized clinical trial comparing CAF with or without vertical-releasing incisions does not report differences in terms of the mean amount of root coverage between the two approaches (Zucchelli et al. 2009).

Short- and long-term data comparing CAF alone *versus* CAF+CTG in the treatment of multiple gingival recessions are not currently available. The Consensus Report of the European Workshop on Periodontology strongly suggests the need for long-term results with at least 5 years of follow-up (Palmer & Cortellini 2008).

The aim of this 5-year long-term study was to compare the clinical outcomes of CAF alone *versus* CAF+CTG in the treatment of multiple gingival recessions.

## Materials and Methods

### Study population

This was a controlled not randomized clinical trial. A total of 13 patients requiring treatment of multiple recessions for aesthetics and/or dental hypersensitivity were consecutively selected in a private periodontal practice by two expert operators (G. G. P. and P. C.). All patients were aged  $\geq 18$  years and had no systemic disease.

Periodontal entry criteria were as follows:

- Presence of at least two multiple bilateral Miller I, II and III recession defects (Miller 1985) in the maxillary arch.
- Absence of clinical signs of active periodontal disease.
- Full mouth plaque score and full mouth bleeding score  $< 15\%$  (four sites/tooth),
- Absence of a history of periodontal surgery in the experimental sites in the last 5 years.

Exclusion criteria were as follows:

- Prosthetic crown or restoration involving the cemento-enamel junction (CEJ) area.
- Presence of dental/root abrasion  $\leq 1$  mm at the CEJ level.
- Non-identifiable CEJ.

Before any procedure, each participant signed an informed consent in accordance with the Helsinki Declaration of 1975 as revised in 2000. Professional oral hygiene procedures were performed on each patient. In addition, patients received oral hygiene instructions (roll technique) to eliminate the wrong habits related to the aetiology of the recession at least 3 months before surgery.

### Clinical measurements

At baseline, 6-month, 1- and 5-year follow-up visits, the following measurements were taken using a PCP UNC 15 periodontal probe:

- Recession depth (Rec) on the mid-buccal site.
- Probing depth (PD) on the mid-buccal site.
- Clinical attachment level calculated as PD+Rec.

CEJ was used as the reference point for the assessment of each periodontal parameter.

### Surgical procedures

An envelope flap design was used to treat the recession defects (Zucchelli & De Sanctis 2000). Following local anaesthesia, an intrasulcular incision was performed involving at least one tooth mesial and at least one tooth distal to the teeth with gingival recessions. Oblique incisions were traced at the interdental soft tissue level to achieve a coronal rotation of the surgical papilla. The flap was then raised up to the mucogingival junction (MGJ) with a periosteal elevator and mobilized with a sharp horizontal periosteal incision beyond the MGJ. Any muscular tension was relieved. Exposed root surfaces were carefully treated with gentle root planing. The anatomic interdental papillae were then carefully de-epithelialized. The split-full-split thickness flap was then passively positioned above the CEJ of the involved teeth

and interrupted or sling sutures were positioned to achieve optimal buccal flap adaptation.

In the CAF+CTG-treated site, a CTG was harvested from the palate using the trap door technique (Langer & Langer 1985), adapted to cover each exposed root about 1 mm beyond the CEJ, and stabilized with resorbable sutures. In some cases, small releasing incisions were also performed to facilitate the coronal displacement of the flap. The flap was then coronally sutured using sling or interrupted sutures. The graft was completely covered by the flap in all cases.

### Post-surgical protocol

Patients were instructed to avoid any mechanical trauma and tooth-brushing for 3 weeks in the surgical area. Chlorhexidine rinses were prescribed twice daily for 1 min. Seven days after the surgery, sutures were removed and prophylaxis was performed. About 3 weeks after surgery, patients were instructed to resume mechanical tooth-cleaning. Patients were recalled 3 and 6 months after surgery for professional oral hygiene procedures and every 6 months over time (5 years). All patients complied with the supportive periodontal therapy programme.

### Statistical analysis

Statistical analysis was performed with JMP<sup>®</sup> 7.0 SAS Institute Inc. and MLWin (2.02).

Descriptive statistics were presented as mean  $\pm$  standard deviation [minimum; maximum] for quantitative variables and frequency and percentage for qualitative variables.

Multilevel analyses were performed on three levels: (1) operator, (2) patient and (3) site. Models were adjusted considering baseline recession depth (Rec 0).

The interaction between Rec 0 and the type of surgical procedure (CAF or CTG+CAF) was considered in the models. If this interaction was not significant, it was eliminated from the models.

The outcome variables of the models were recession reduction (Rec Red) and CRC at 6-month and 5-year follow-up examinations. When CRC was the outcome variable, a logistic multilevel method with second-order penalized quasi-likelihood was used. Two multi-

Table 1. Descriptive statistics

Mean recession $\pm$ standard deviation (mm)				
	CAF sites	Rec Red for CAF sites: [minimum; maximum]	CTG sites	Rec Red for CAF+CTG sites [minimum; maximum]
Baseline	2.9 $\pm$ 1.3	–	3.6 $\pm$ 1.3	–
6 months	0.4 $\pm$ 0.5	2.6 $\pm$ 1.3 [0.5; 6.0]	0.6 $\pm$ 0.5	3.0 $\pm$ 1.3 [0.5; 6.0]
1 year	0.6 $\pm$ 0.6	2.3 $\pm$ 1.1 [0.0; 5.0]	0.5 $\pm$ 0.5	3.1 $\pm$ 1.3 [0.5; 6.0]
5 years	0.8 $\pm$ 0.8	2.2 $\pm$ 1.2 [0.0; 5.0]	0.4 $\pm$ 0.5	3.2 $\pm$ 1.3 [0.5; 6.0]

CAF sites, sites treated with a coronally advanced flap alone; CAF+CTG sites, sites treated with a coronally advanced flap plus a connective tissue graft; Rec Red, recession red; CRC, complete root coverage.

level analyses were also performed to test the possible difference between the CAF and the CTG+CAF group in terms of gingival recession depth and Miller class III defects at baseline.

## Results

### Descriptive statistics

A total of 13 patients (10 females and three males) showing multiple gingival recessions were treated by two different operators. The mean age was  $31.4 \pm 7.6$  years [24; 51]. Three patients were smokers. Seven patients were treated by operator 1 (G. P. P.) while six were treated by operator 2 (P. C.).

A total of 93 gingival recessions were treated. All recessions were located at maxillary teeth.

A total of 49 gingival recessions were treated using CAF: five central incisors, nine lateral incisors, 12 cuspids, 11 first pre-molars, nine second pre-molars and three first molars; 36 were Miller class I, six class II and seven class III.

A total of 44 gingival recessions were treated using CAF+CTG: four central incisors, seven lateral incisors, 11 cuspids, 12 first pre-molars, nine second pre-molars and one first molar; 27 were Miller class I, 10 class II and 7 class III.

In the CAF-treated sites, the baseline gingival recession (Rec 0) was  $2.9 \pm 1.3$  mm [0.5; 7.0] while the final gingival recession (Rec 5) was  $0.8 \pm 0.8$  mm [0.0; 3.0] (Table 1). CRC was observed in 57% of the sites at the 6-month follow-up, in 37% of the sites at the 12-month follow-up and in 35% at the 5-year follow-up (Fig. 1).

In the CAF+CTG-treated sites, the baseline gingival recession (Rec 0) was  $3.6 \pm 1.3$  mm [0.5; 6.0] while the final gingival recession (Rec 5) was  $0.4 \pm 0.5$  mm [0.0; 1.0] (Table 1). CRC was observed in 34% of the sites at the

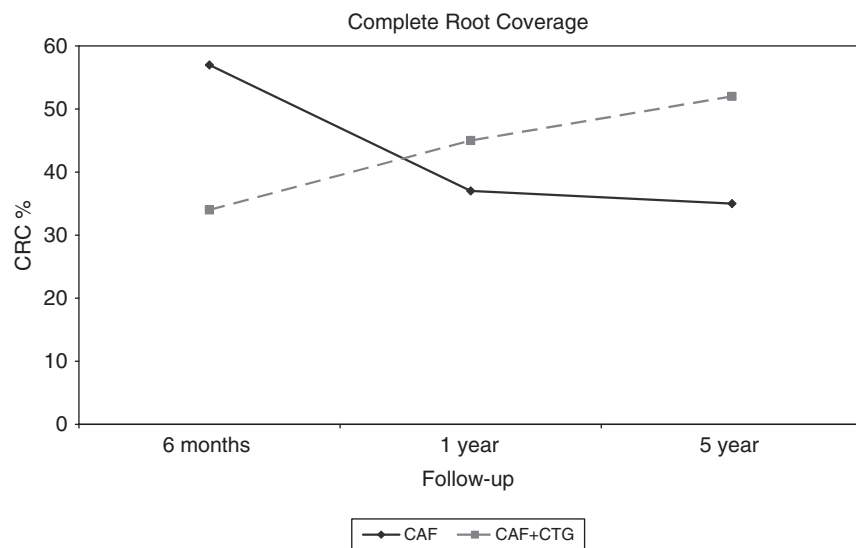


Fig. 1. Changes of complete root coverage at different times of observation for both therapies.

6-month follow-up, in 45% of the sites at the 12-month follow-up and in 52% at the 5-year follow-up (Fig. 1).

### Inferential statistics

Multilevel analysis showed statistically significant differences in terms of Rec 0 on comparing the two groups, with significantly higher Rec 0 (0.7 mm) for the CAF+CTG group than the CAF group ( $p = 0.0034$ ). No statistical difference ( $p = 0.7982$ ) was found between CAF+CTG and CAF groups for the presence of Miller class III recession defects at baseline. No statistically significant difference was detected between two groups in terms of Rec Red at the 6-month follow-up ( $p = 0.1747$ ) (Table 2). The interaction between the surgical procedure and Rec 0 was not significant at the 6-month follow-up. No difference in terms of CRC was reported (OR =

0.49, 95% CI: 0.17; 1.39,  $p = 0.1772$ ) (Table 3).

At the 5-year follow-up, a significant interaction between higher Rec 0 and therapy was reported ( $p = 0.0106$ ) (Table 4). Rec 0 was more severe and Rec Red was better using CAF+CTG (Fig. 2).

A significant difference in terms of CRC was reported comparing the two approaches favouring CAF+CTG (OR 3.94, 95% CI: 1.20; 12.94,  $p = 0.0239$ ) (Table 5). Figures 3–9 show one treated patient.

## Discussion

To date, a robust body of evidence reports positive outcomes following the use of CAF and CAF+CTG in the treatment of localized gingival recessions (Cairo et al. 2008), while few studies are currently available on the

Table 2. Rec Red at 6 months' follow-up

Term	Estimate	SE	p-value
Intercept	-0.012	0.142	
		<i>Site level</i>	
Therapy	-0.114	0.084	0.1747
Rec0	0.873	0.035	<0.0001
		<i>Variances</i>	
$\sigma_v^2$	0.007	0.018	
$\sigma_u^2$	0.048	0.030	
$\sigma_e^2$	0.147	0.023	

Theoretic model:

$$\text{Rec Red 6 months}_{ijk} = \beta_{0ijk} + \beta_1 \text{Therapy}_{ijk} + \beta_2 \text{Rec 0}_{ijk} + v_k + u_{jk} + e_{ijk}$$

In the model "therapy" is 0 for CAF and 1 for CAF+CTG.

The subscript *k* refers to the operator level, the subscript *j* refers to the patient level and the subscript *i* refers to the site level.  $\beta_{0ijk}$  is the "intercept". " $\sigma_v^2$ ", " $\sigma_u^2$ " and " $\sigma_e^2$ " indicate the variances at the operator, patient and site levels, respectively.

CAF, coronally advanced flap; CAF+CTG, coronally advanced flap plus connective tissue graft.

Table 3. CRC at 6 months' follow-up

Term	Estimate	SE	p-value
Intercept	1.980	1.416	
		<i>Site level</i>	
Therapy	-0.722	0.535	0.1772
Rec 0	-0.585	0.258	0.0234
		<i>Variances</i>	
$\sigma_v^2$	2.179	2.631	
$\sigma_u^2$	1.919	1.234	

Theoretic model:

$$\text{Logit}(\pi_{ijk}) = \beta_{0ijk} + \beta_1 \text{Therapy}_{ijk} + \beta_2 \text{Rec 0}_{ijk} + v_k + u_{jk}$$

In the model "therapy" is 0 for CAF and 1 for CAF+CTG.  $\pi_{ijk}$  is the probability of CRC in the *i*-site. The subscript *k* refers to the operator level, the subscript *j* refers to the patient level and the subscript *i* refers to site level.  $\beta_{0ijk}$  is the "intercept". " $\sigma_v^2$ " and " $\sigma_u^2$ " indicate the variances at the operator and patient levels, respectively.

CAF, coronally advanced flap; CAF+CTG, coronally advanced flap plus connective tissue graft; CRC, complete root coverage.

Table 4. Rec Red at 5 years' follow-up

Term	Estimate	SE	p-value
Intercept	0.209	0.206	
		<i>Site level</i>	
Therapy	-0.141	0.286	0.6220
Rec 0	0.661	0.059	<0.0001
Therapy × Rec 0	0.207	0.081	0.0106
		<i>Variances</i>	
$\sigma_v^2$	0.000	0.000	
$\sigma_u^2$	0.123	0.061	
$\sigma_e^2$	0.228	0.036	

Theoretic model:

$$\text{Rec Red 5 years}_{ijk} = \beta_{0ijk} + \beta_1 \text{Therapy}_{ijk} + \beta_2 \text{Rec 0}_{ijk} + \beta_3 \text{Therapy} \times \text{Rec 0}_{ijk} + v_k + u_{jk} + e_{ijk}$$

In the model "therapy" is 0 if CAF and 1 if CAF+CTG.

The subscript *k* refers to the operator level, the subscript *j* refers to the patient level and the subscript *i* refers to the site level.  $\beta_{0ijk}$  is the "intercept". " $\sigma_v^2$ ", " $\sigma_u^2$ " and " $\sigma_e^2$ " indicate the variances at the operator, patient and site levels, respectively.

CAF, coronally advanced flap; CAF+CTG, coronally advanced flap plus connective tissue graft.

use and the outcomes of CAF for the treatment of multiple gingival recessions (Zucchelli & De Sanctis 2005, Zucchelli et al. 2009). Short- and long-term data comparing CAF alone *versus* a combination of CAF+CTG are lacking and only one study reported the 5-year long-term results of the multiple approach (Zucchelli & De Sanctis 2005). The recent Consensus Report of European Workshop on Periodontology strongly advised that long-term results with at least 5 years of follow-up are needed to evaluate the stability of the clinical outcomes (Palmer & Cortellini 2008). Therefore, the purpose of this long-term split-mouth study was to compare the clinical outcomes of CAF *versus* CAF+CTG in the treatment of multiple gingival recessions up to 5 years of follow-up. Clinical measurements were re-assessed at 6-month, 1-year and 5-year follow-up examinations.

Six months after surgery, no statistically significant difference between CAF+CTG and CAF was reported in terms of Rec Red and CRC. Because no comparative data between CAF *versus* CAF+CTG are available for multiple recessions, the results of the treatment of localized recession should be used as a possible term of comparison. If Rec Red is the outcome variable, the results of this study are similar to those found for localized recessions; in fact, 6 months after surgery, there were no differences between the sites treated by means of the two approaches (Da Silva et al. 2004, Cortellini et al. 2009). On the other hand, if CRC is considered as the outcome variable, the results of this study do not show differences between the two approaches, while clinical trials (Da Silva et al. 2004, Cortellini et al. 2009) and a systematic review (Cairo et al. 2008) indicate a higher number of sites showing CRC in CTG+CAF sites than in CAF sites in the treatment of localized recessions.

A different trend was noted over time at the 1- and 5-year follow-up (Fig. 10). A slight coronal shift of the gingival margin occurred in the CAF+CTG while a slight apical shrinkage of the margin was observed in the CAF group.

The progressive coronal improvement of the gingival margin level and the increased percentage of sites with CRC observed in the CAF+CTG-treated sites at the final follow-up was due to a creeping attachment effect over

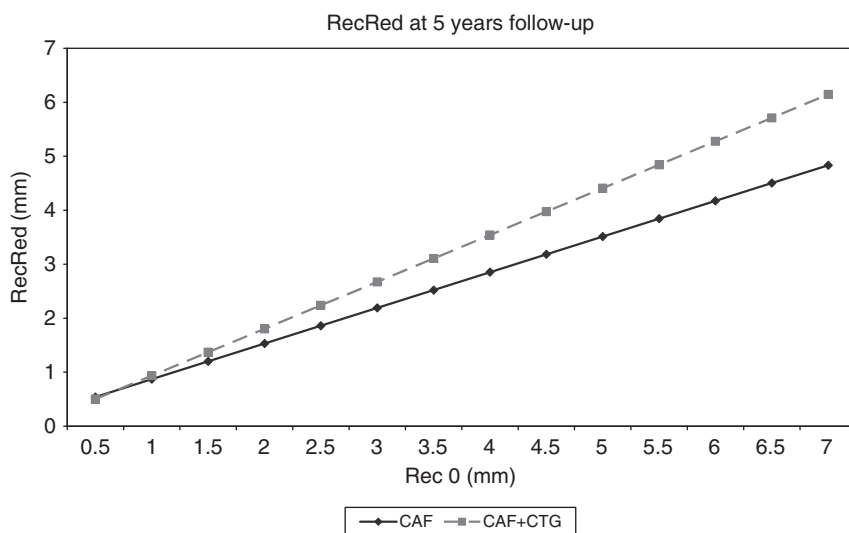


Fig. 2. Changes of recession reduction in relation to baseline recession (Rec 0).

Table 5. CRC at 5 years' follow-up

Term	Estimate	SE	p-value
Intercept	1.337	1.305	
	<i>Site level</i>		
Therapy	1.371	0.607	0.0239
Rec0	-0.775	0.281	0.0058
	<i>Variances</i>		
$\sigma_v^2$	1.953	2.365	
$\sigma_u^2$	1.535	1.028	

Theoretic model:

$$\text{Logit}(\pi_{ijk}) = \beta_{0jk} + \beta_1 \text{Therapy}_{ijk} + \beta_2 \text{Rec } 0_{ijk} + v_k + u_{jk}$$

In the model "therapy" is 0 for CAF and 1 for CAF+CTG.  $\pi_{ijk}$  is the probability of CRC for the *i*-site. The subscript *k* refers to the operator level, the subscript *j* refers to the patient level and the subscript *i* refers to the site level.  $\beta_{0jk}$  is the "intercept". " $\sigma_v^2$ " and " $\sigma_u^2$ " indicate the variances at the operator and patient levels, respectively.

CAF, coronally advanced flap; CAF+CTG, coronally advanced flap plus connective tissue graft; CRC, complete root coverage.

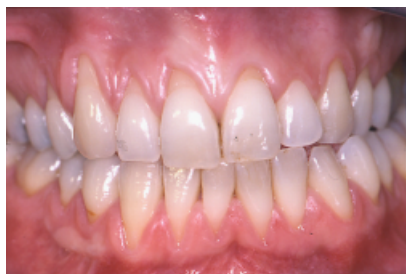

Fig. 3. Pre-treatment view of one treated patient.

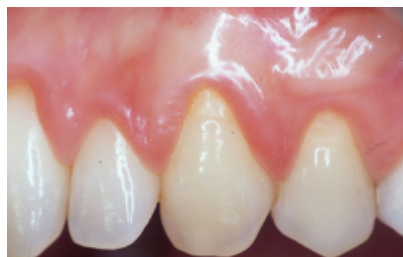

Fig. 4. Baseline. Multiple gingival recessions on the left lateral incisor, canine and first pre-molar scheduled to undergo a coronally advanced flap procedure.

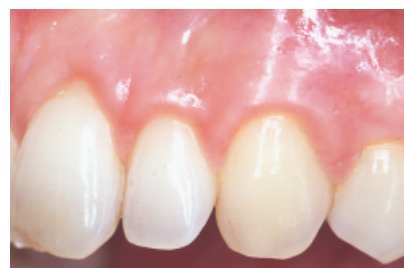

Fig. 5. One-year follow-up. Coronally advanced flap was performed and complete root coverage was achieved at treated teeth.

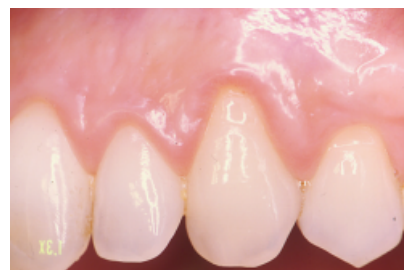

Fig. 6. Five-year follow-up. Apical relapse of the gingival margin on the cuspid and on the first pre-molar.

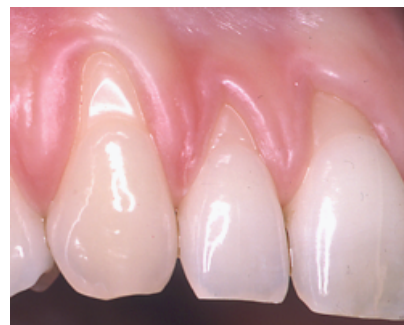

Fig. 7. Baseline. Multiple gingival recessions at the right central, lateral incisor and canine scheduled to undergo CAF+CTG. CAF+CTG, coronally advanced flap plus connective tissue graft.

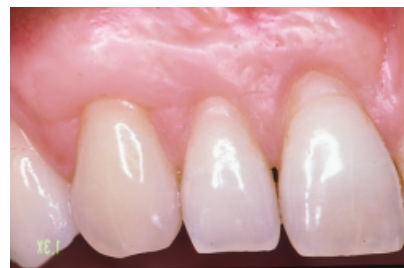

Fig. 8. One-year follow-up. CAF+CTG was performed and partial root coverage was achieved. CAF+CTG, coronally advanced flap plus connective tissue graft.

time (Matter 1980) and may be facilitated by the thick gingival tissue obtained after positioning of a CTG.

On the other hand, an apical shift of the gingival margin of CAF-treated sites was observed at the 5-year follow-up.

This trend might be related to the thinner thickness/amount of keratinized tissue achieved (Cairo et al. 2008), leading to possible apical relapse of the gingival margin during the maintenance phase.

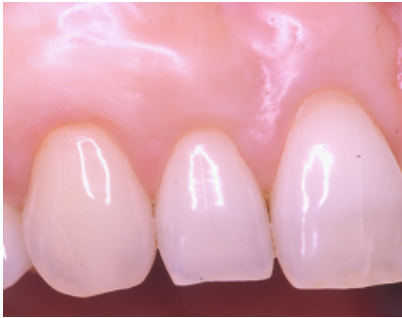

Fig. 9. Five-year follow-up. Coronal displacement of the gingival margin and complete root coverage occurred on the lateral incisor and canine.

This study also supports the observation that recession reduction may be maintained for both treatments over time when proper maintenance is performed during a long period of time (Pini-Prato et al. 1996, Trombelli et al. 2005, Zucchelli & De Sanctis 2005, De Sanctis & Zucchelli 2007).

Inferential statistics showed a significant interaction between baseline recession depth and treatment outcome: the more severe the recession at baseline, the greater the recession reduction using CAF+CTG (Fig. 2). This finding supports the clinical benefit of performing CAF+CTG instead of CAF alone when treating more severe gingival recessions. In addition, it should be noted that the distribution of Miller class III was homogeneous in both groups.

The limits of this study may be related to its non-randomized design. The two operators (G. P. P. and P. P. C.) have treated deeper recessions at baseline by

means of the CTG+CAF technique on the basis of their personal experience and knowledge of the relevant literature. This choice proved to be clinically effective in the long term, with deeper recessions treated by means of CTG+CAF showing greater improvements than those treated by CAF alone.

In conclusion, this 5-year long-term clinical study indicates that:

- (1) No difference between CAF versus CAF+CTG was detected at the 6-month follow-up in the treatment of multiple gingival recessions.
- (2) CAF+CTG achieved better outcomes in terms of CRC than CAF at the 5-year follow-up.
- (3) A coronal displacement of the gingival margin was observed in the CAF+CTG-treated sites, while an apical relapse of the gingival margin was noted in the CAF-treated sites between the 6-month and 5-year follow-ups.

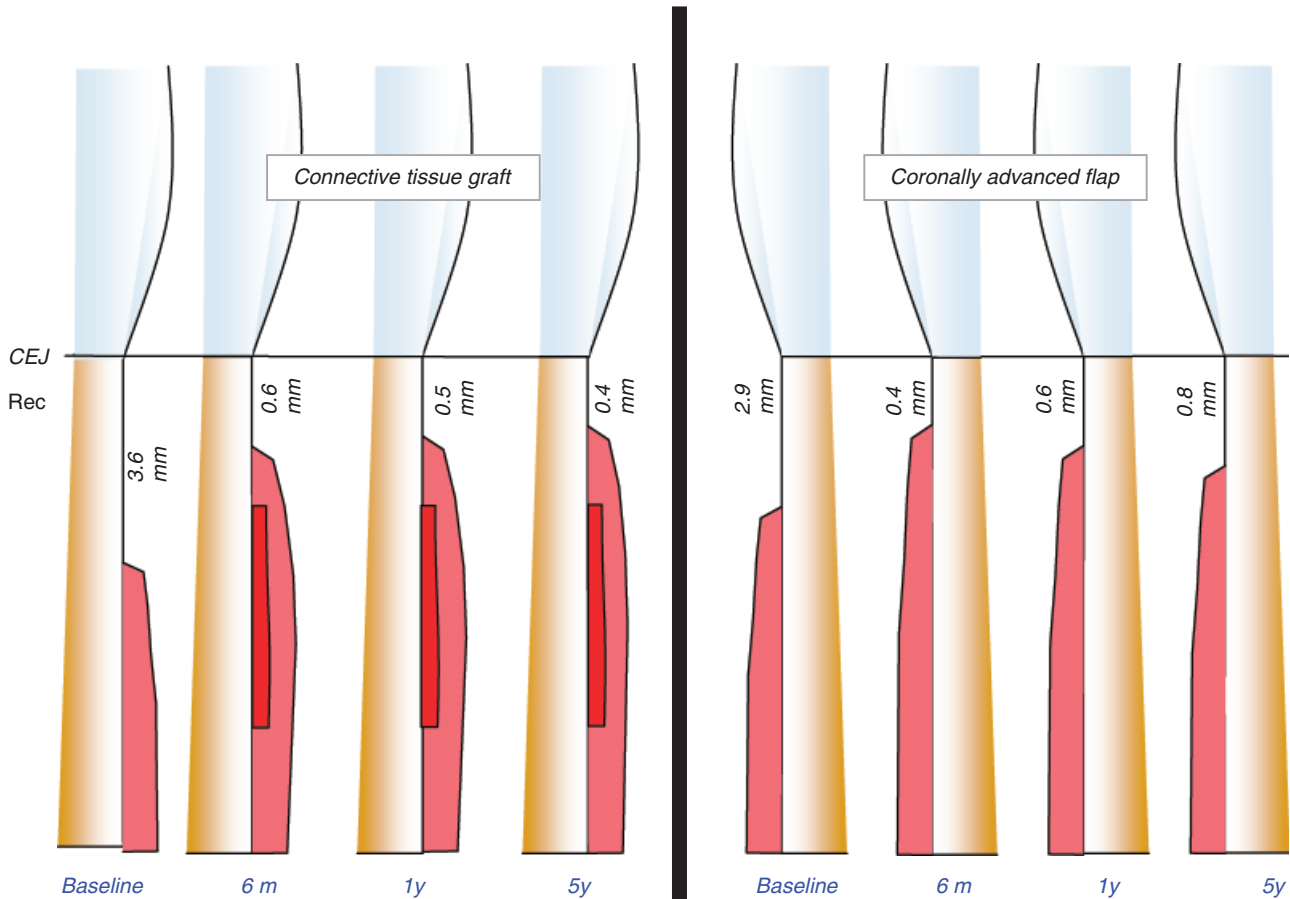


Fig. 10. Drawing compares mean recession reduction of CAF+CTG-treated sites versus CAF-treated sites at different follow-up intervals (6 months; 1 year; and 5 years). CAF+CTG, coronally advanced flap plus connective tissue graft.

## References

- Allen, E. P. & Miller, P. D. (1989) Coronal positioning of existing gingiva: short term results in the treatment of shallow marginal tissue recession. *Journal of Periodontology* **60**, 316–319.
- American Academy of Periodontology. (1996) Consensus report on mucogingival therapy. Proceedings of the World Workshop in Periodontics. *Annals of Periodontology* **1**, 702–706.
- Bernimoulin, J. P., Lüscher, B. & Mühlemann, H. R. (1975) Coronally repositioned periodontal flap. Clinical evaluation after one year. *Journal of Clinical Periodontology* **2**, 1–13.
- Cairo, F., Pagliaro, U. & Nieri, M. (2008) Treatment of gingival recession with coronally advanced flap procedures. A systematic review. *Journal of Clinical Periodontology* **35** (Suppl. 8), 136–162.
- Cairo, F., Rotundo, R., Miller, P. D. & Pini-Prato, G. P. (2009) Root coverage esthetic score: a system to evaluate the esthetic outcome of the treatment of gingival recession through evaluation of clinical cases. *Journal of Clinical Periodontology* **80**, 705–710.
- Cortellini, P., Tonetti, M., Baldi, C., Francetti, L., Rasperini, G., Rotundo, R., Nieri, M., Franceschi, D., Labriola, A. & Pini-Prato, G. P. (2009) Does placement of a connective tissue graft improve the outcomes of coronally advanced flap for coverage of single gingival recessions in upper anterior teeth? A multi-centre, randomized, double-blind, clinical trial. *Journal of Clinical Periodontology* **36**, 68–79.
- Da Silva, R. C., Joly, J. C., De Lima, A. & Tatakis, D. (2004) Root coverage using the coronally positioned flap with or without a subepithelial connective tissue graft. *Journal of Periodontology* **75**, 413–419.
- De Sanctis, M. & Zucchelli, G. (2007) Coronally advanced flap: a modified surgical approach for isolated recession-type defects: three-year results. *Journal of Clinical Periodontology* **34**, 262–268.
- Langer, B. & Langer, L. (1985) Subepithelial connective tissue graft technique for root coverage. *Journal of Periodontology* **56**, 715–720.
- Matter, J. (1980) Creeping attachment of free gingival grafts. A five-year follow-up study. *Journal of Periodontology* **51**, 681–685.
- Miller, P. D. (1985) A classification of marginal tissue recession. *International Journal of Periodontics and Restorative Dentistry* **5**, 8–13.
- Nieri, M., Rotundo, R., Franceschi, D., Cairo, F., Cortellini, P. & Pini-Prato, G. P. (2009) Factors affecting the outcome of the coronally advanced flap procedure: a Bayesian network analysis. *Journal of Periodontology* **80**, 405–410.
- Palmer, R. & Cortellini, P. Group B of European Workshop on Periodontology. (2008) Periodontal tissue engineering and regeneration: consensus report on the sixth workshop on periodontology. *Journal of Clinical Periodontology* **35** (Suppl. 8), 83–86.
- Pini-Prato, G. P., Clauser, C., Cortellini, P., Tinti, C., Vincenzi, G. & Pagliaro, U. (1996) Guided tissue regeneration versus mucogingival surgery in the treatment of human buccal recessions. A 4-year follow-up study. *Journal of Periodontology* **67**, 1216–1223.
- Pini-Prato, G. P., Clauser, C. & Cortellini, P. (1995) Periodontal plastic and mucogingival surgery. *Periodontology 2000* **9**, 90–105.
- Pini-Prato, G. P., Pagliaro, U., Baldi, C., Nieri, M., Saletta, D., Cairo, F. & Cortellini, P. (2000) Coronally advanced flap procedure for root coverage. Flap with tension versus flap without tension: a randomized controlled clinical study. *Journal of Periodontology* **71**, 188–201.
- Trombelli, L., Minenna, L., Farina, R. & Scabbia, A. (2005) Guided tissue regeneration in human gingival recessions. A 10-year follow-up study. *Journal of Clinical Periodontology* **32**, 16–20.
- Zabalegui, I., Sicilia, A., Cambra, J., Gil, J. & Sanz, M. (1999) Treatment of multiple adjacent gingival recessions with the tunnel subepithelial connective tissue graft: a clinical report. *International Journal of Periodontics and Restorative Dentistry* **19**, 199–206.
- Zucchelli, G. & De Sanctis, M. (2000) Treatment of multiple recession-type defects in patients with esthetic demands. *Journal of Periodontology* **71**, 1506–1514.
- Zucchelli, G. & De Sanctis, M. (2005) Long-term outcome following treatment of multiple Miller class I and II recession defects in esthetic areas of the mouth. *Journal of Periodontology* **76**, 2286–2292.
- Zucchelli, G., Mele, M., Mazzotti, C., Marzadori, M., Montebugnoli, L. & De Sanctis, M. (2009) Coronally advanced flap with and without vertical releasing incisions for the treatment of multiple gingival recessions. A comparative controlled randomized clinical trial. *Journal of Periodontology* **80**, 1083–1094.

Address:  
Giovanni Paolo Pini-Prato  
Viale Matteotti, 11  
50100 Firenze  
Florence  
Italy  
E-mail: gpini@tin.it

## Clinical Relevance

*Scientific rationale for the study:* Long-term data comparing CAF alone versus a combination of CAF+CTG in the treatment of multiple gingival recessions are currently not available.

*Principal findings:* This long-term split-mouth study indicated that multiple gingival recessions may be successfully treated with CAF+CTG. At the 5-year follow-up, CAF+CTG provided better clinical outcomes in terms of CRC.

*Practical implications:* The use of CAF+CTG seems to provide greater stability of the gingival margin at the 5-year follow-up in the treatment of multiple gingival recessions.