



UNIVERSITÀ
DEGLI STUDI
FIRENZE

FLORE

Repository istituzionale dell'Università degli Studi di Firenze

Usefulness of ultrasound lung comets as a nonradiologic sign of extravascular lung water.

Questa è la Versione finale referata (Post print/Accepted manuscript) della seguente pubblicazione:

Original Citation:

Usefulness of ultrasound lung comets as a nonradiologic sign of extravascular lung water / Z. Jambrik; S. Monti; V. Coppola; E. Agricola; G. Mottola; M. Miniati; E. Picano.. - In: THE AMERICAN JOURNAL OF CARDIOLOGY. - ISSN 0002-9149. - STAMPA. - 93:(2004), pp. 1265-1270. [10.1016/j.amjcard.2004.02.012]

Availability:

The webpage <https://hdl.handle.net/2158/774187> of the repository was last updated on

Published version:

DOI: 10.1016/j.amjcard.2004.02.012

Terms of use:

Open Access

La pubblicazione è resa disponibile sotto le norme e i termini della licenza di deposito, secondo quanto stabilito dalla Policy per l'accesso aperto dell'Università degli Studi di Firenze (<https://www.sba.unifi.it/upload/policy-oa-2016-1.pdf>)

Publisher copyright claim:

La data sopra indicata si riferisce all'ultimo aggiornamento della scheda del Repository FloRe - The above-mentioned date refers to the last update of the record in the Institutional Repository FloRe

(Article begins on next page)

Usefulness of Ultrasound Lung Comets as a Nonradiologic Sign of Extravascular Lung Water

Zoltan Jambrik, MD, Simonetta Monti, MD, Vincenzo Coppola, MD, Eustachio Agricola, MD, Gaetano Mottola, MD, Massimo Miniati, MD, and Eugenio Picano, MD, PhD

The “comet-tail” is an ultrasound sign detectable with ultrasound chest instruments; this sign consists of multiple comet-tails fanning out from the lung surface. They originate from water-thickened interlobular septa and would be ideal for nonradiologic bedside assessment of extravascular lung water. To assess the feasibility and value of ultrasonic comet signs, we studied 121 consecutive hospitalized patients (43 women and 78 men; aged 67 ± 12 years) admitted to our combined cardiology-pneumology department (including cardiac intensive care unit); the study was conducted with commercially available echocardiographic systems including a portable unit. Transducer frequencies (range 2.5 to 3.5 MHz) were used. In each patient, the right and left chest was scanned by examining predefined locations in multiple intercostal spaces. Examiners blinded to clinical diagnoses noted the presence and numbers of lung comets at each examining site. A patient lung comet score was obtained by summing the number of comets in each of the scanning spaces. Within a few minutes, patients underwent chest x-ray, with specific assessment of ex-

travascular lung water score by 2 pneumologist-radiologists blinded to clinical and echo findings. The chest ultrasound scan was obtained in all patients (feasibility 100%). The imaging time per examination was always <3 minutes. There was a linear correlation between echocardiographic comet score and radiologic lung water score ($r = 0.78$, $p < 0.01$). Inpatient variations ($n = 15$) showed an even stronger correlation between changes in echocardiographic lung comet and radiologic lung water scores ($r = 0.89$; $p < 0.01$). In 121 consecutive hospitalized patients, we found a linear correlation between echocardiographic comet scores and radiologic extravascular lung water scores. Thus, the comet-tail is a simple, non-time-consuming, and reasonably accurate chest ultrasound sign of extravascular lung water that can be obtained at bedside (also with portable echocardiographic equipment) and is not restricted by cardiac acoustic window limitations. ©2004 by Excerpta Medica, Inc.

(Am J Cardiol 2004;93:1265–1270)

The “comet-tail” is an echographic sign detectable with cardiac ultrasound on the chest consisting of multiple comet-tails fanning out from the lung surface.¹ It originates from water-thickened or fibrotic interlobular septa.² Its presence allows a bedside distinction between pulmonary edema and chronic obstructive pulmonary disease.^{1,2} This difference is logical when one considers that the interstitial compartment reaches the lung surface, whereas the bronchial compartment does not. Because the scatterers generating the lung comets can be physically identified with water-thickened interlobular septa,² this sign is theoretically appealing for detecting and quan-

tifying extravascular lung water—a key parameter in the serial evaluation of the cardiologic patient with heart failure.³ This parameter is not quantified by ultrasound diagnosis and remains a technique still defined by the chest x-ray,³ which allows semiquantitative estimation of alveolar and interstitial lung water with extensively validated radiologic scores.^{4,5} The present study hypothesis was that chest ultrasound detection of lung comets may provide a feasible and accurate nonradiologic bedside estimation of extravascular lung water, independently assessed by chest x-ray.

METHODS

Patients: From January to April 2002, 121 consecutive patients (aged 67 ± 12 years; 43 women and 78 men) admitted to our adult cardiology-pneumology department were included in the study. The inclusion criteria were: (1) in-hospital patients (admitted to our department), (2) chest x-ray on admission or repeated chest x-ray, and (3) echocardiogram for specific assessment of lung comets performed within a few minutes of chest x-ray. Exclusion criteria were: (1) time lag between chest x-ray and chest 2-dimensional echocardiogram >1 hour ($n = 2$), and (2) chest X-ray of technically poor quality, making an accurate quanti-

From the Institute of Clinical Physiology, CNR Lab, Pisa, Italy; 2nd Department of Internal Medicine and Cardiology Centre, University of Szeged, Szeged, Hungary; Department of Cardiology, “San Raffaele” University Hospital, Milan, Italy; and Clinica Cardiologica “Montevergine” Mercogliano (Avellino), Italy. Dr. Jambrik is a visiting fellow from the University of Szeged, Szeged, Hungary, and is supported by the “Eötvös” Educational Grant from the Hungarian Government Budapest, Hungary, and by the “Research and Training Fellowship” of the European Society of Cardiology, Nice, France. Manuscript received September 21, 2003; revised manuscript received and accepted February 5, 2004.

Address for reprints: Eugenio Picano, MD, PhD, Institute of Clinical Physiology, CNR Lab, Via Moruzzi 1, 56123 Pisa, Italy. E-mail: picano@ifc.cnr.it.

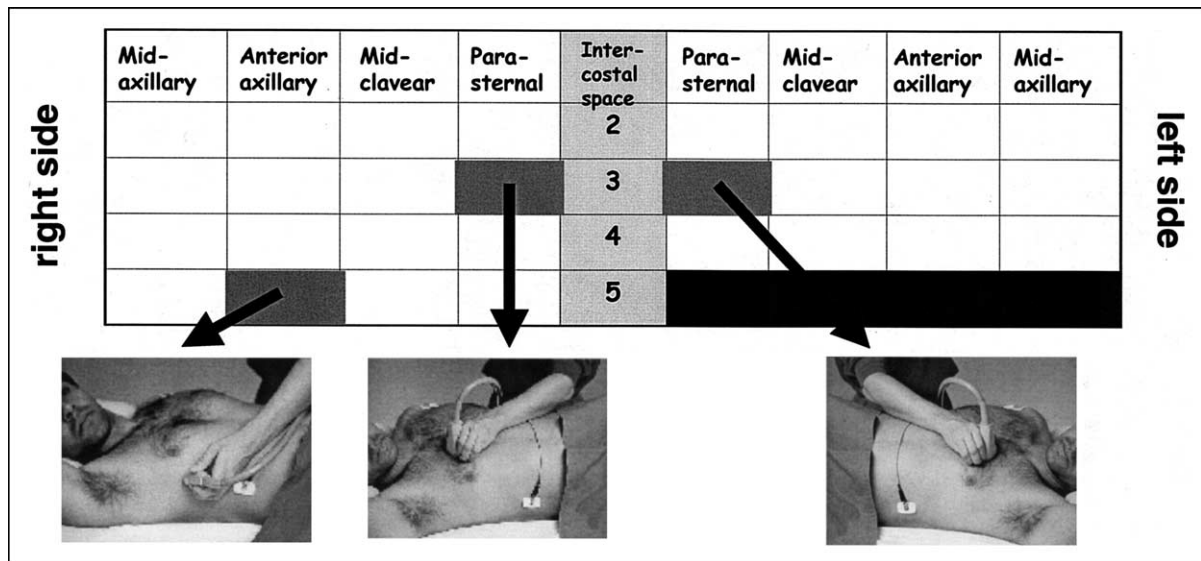


FIGURE 1. Methods of echo lung scanning.

tative scoring impossible (n = 9). An almost simultaneous chest x-ray and chest 2-dimensional echocardiographic evaluation was obtained in 135 paired ultrasound radiologic measurements of 121 consecutive in-hospital patients admitted to our cardiopneumology department. The physical examination was performed on admission by the cardiologist on duty, and, in particular, the presence or absence of pedal edema, pulmonary rales, and jugular venous distension were noted. Experienced physicians, unaware of the other test results and of the clinical presentation, independently read the ultrasound and chest x-ray films. The hospital's institutional review board approved the study, and all patients gave informed consent.

Ultrasound: Commercially available echocardiographic equipment with a 2.5- to 3.5-MHz cardiac transducer was used: Philips-Agilent OptiGo portable, Hewlett-Packard Sonos 5500 (Andover, Massachusetts). The investigator was unaware of the result of the chest radiogram and clinical data of the patient. The echocardiographic examinations were performed with patients in the near-to-supine or supine positions. Ultrasound scanning of the anterior and lateral chest was obtained on the right and left hemithorax, from the second to the fourth (on the right side to the fifth) intercostal spaces, and from parasternal to midaxillary line. The comet-tail sign was defined as an echogenic, coherent, wedge-shaped signal with a narrow origin in the near field of the image. In each intercostal space, the number of comet-tail signs was recorded at the parasternal, midclavarear, anterior axillary, and midaxillary sites (Figure 1). The sum of the comet-tail signs yielded a score denoting the extent of extravascular fluid in the lung. Zero was defined as a complete absence of comet-tail artifact on the investigated area. The intra- and interobserver variabilities of echocardiographic comet lung scores were assessed by 2 independent observers in a set of 20 consecutive patients and was 5.1% and 7.4%. Standard echocardiographic

TABLE 1 Radiologic Scoring of Extravascular Lung Water

	Scores		
Hilar vessels			
Enlarged	1	2	3
Increased in density	2	4	6
Blurred	3	6	9
Kerley lines			
A	4	8	
B	4	8	
C	4	8	
Micronoduli	4	8	
Widening of interlobar fissures	4	8	12
Peribronchial and perivascular cuffs	4	8	12
Extensive perihilar haze	4	8	12
Subpleural effusion	5	10	
Diffuse increase in density	5	10	15

The score assignment of a given sign depends on the entity, stratified into 3 (mild, moderate, or severe) or 2 (mild or severe) degrees as originally described.⁴

measurements were obtained in each patient according to the recommendations of the American Society of Echocardiography.⁶ Measurements included left ventricular ejection fraction, end-diastolic diameter, and systolic pulmonary pressure derived from flow velocity profiles of tricuspid regurgitation, when present.

Chest x-ray: Every patient underwent a chest x-ray examination within 1 hour of the ultrasound investigation. The chest radiograms were recorded by commercially available x-ray machines. The reading of the x-ray image was done by 2 pneumologist-radiologists (SM, MM) blinded to the clinical and echocardiographic findings. A previously validated radiologic score of extravascular lung water was used^{4,5} (Table 1). The intra- and interobserver reproducibilities of radiologic lung water scores among experienced observers were very high, as previously described.^{4,5} In particular, the interobserver correlation was $r = 0.9$ ($p < 0.0001$).

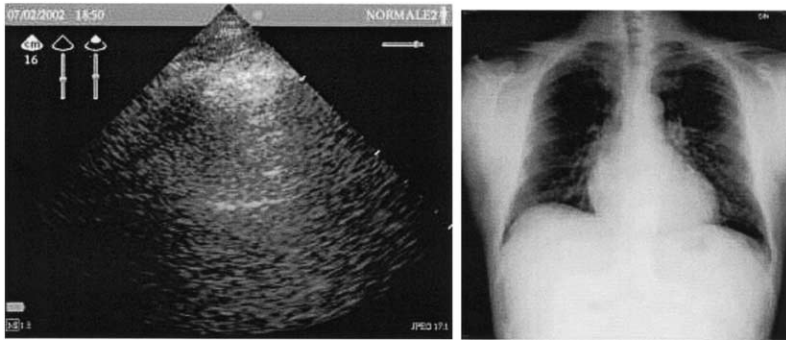


FIGURE 2. Echographic view of the lung (left) and chest x-ray (right) of a patient without extravascular lung water.

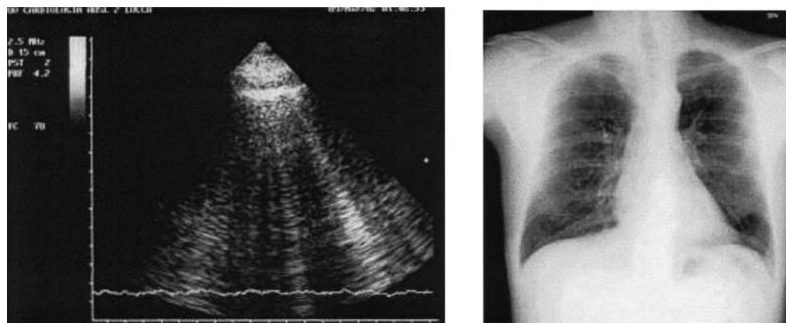


FIGURE 3. Comet-tail artifact (left) and radiogram (right) of a patient with acute interstitial syndrome.

Statistical analysis: Continuous measures are expressed as mean values \pm SD. Continuous variables are analyzed according to Student's *t* test and Pearson's correlation. To find predictors of extravascular lung water assessed by chest x-ray, multivariate regression analysis was performed. Dichotomous variables were compared by chi-square analysis. The statistical analyses of the data were performed with SPSS (version 11.0, SPSS Inc., Chicago, Illinois). A *p* value <0.05 was considered significant.

RESULTS

In all, 135 paired echos (chest x-ray evaluations) were obtained in 121 patients. Thirteen patients were studied twice (at admission and on discharge), and 1 patient was studied 3 times. Reasons for hospital admission were acute coronary syndrome in 10 patients, stable angina in 37, dyspnea in 33, exacerbation of chronic heart failure in 9, and miscellaneous causes (worsening of chronic pulmonary disease after coronary artery bypass surgery, atrial fibrillation, palpitation, pulmonary embolism, atrial myxoma, renal failure, or after general surgery) in the remaining patients.

Echocardiographic and echo lung findings: The feasibility of the chest ultrasound examination for the diagnosis of pulmonary extravascular water was 100%. The time needed for the echo lung examination was <3 minutes (mean 2.8 ± 0.4) in all patients. Lung comets were observed in 82 patients. The mean number of comets per person (comet score) was 17 ± 25 . A typical echo pattern of a patient with and without

comets is shown in Figures 2 and 3. The spatial distribution of comets on the chest is displayed in Figure 4. Comets were more obvious on the right than on the left hemithorax.

Echocardiographic abnormalities outside lung comets consisted of regional wall motion abnormalities in 68 patients, valvular heart disease in 41, and pulmonary hypertension in 65. The mean ejection fraction was $47 \pm 14\%$ and the left ventricular mean end-diastolic diameter was 53 ± 8 mm. When compared with those without comets, patients with comets had significantly lower ejection fractions ($43 \pm 15\%$ vs $54 \pm 10\%$; $p < 0.01$) and significantly higher systolic pulmonary pressures (48 ± 18 vs 35 ± 14 mm Hg; $p < 0.01$) and end-diastolic diameters (55 ± 10 vs 49 ± 6 mm; $p < 0.01$).

Chest x-ray: Twenty-three patients had signs of extravascular lung water: 32 interstitial, 17 alveolar. The mean radiologic score was 8 ± 14 . Thirty-three patients had at least 1 lung abnormality other than extravascular lung water: 10 had chronic obstructive pulmonary disease, 2 had pleuritis, 2 had pulmonary fibrosis, 2 had radiologic signs of pulmonary hypertension, and 18 patients had pleural effusion. A typical example of a patient with and without extravascular lung water is shown in Figures 2 and 3.

Comparison of clinical and chest x-ray findings: Patients with pulmonary rales on physical examination ($n = 20$) had a higher radiologic score than patients without rales (15 ± 18 vs 5 ± 8 , respectively, $p < 0.01$). Patients with jugular venous distention also had higher radiologic scores than patients without it (13 ± 13 vs 4 ± 8 , respectively, $p < 0.01$). Patients with pedal edema had radiologic scores similar to patients without pedal edema (7 ± 11 vs 6 ± 10 , $p = 0.40$).

Comparison of lung echo and chest x-ray findings: In the overall population of 135 cases (121 patients), there was a significant linear correlation between echo comet score and radiologic score of extravascular lung water ($r = 0.78$, $p < 0.01$) (Figure 5). The significant correlation was present also when only the 62 patients evaluated with portable echocardiographic instruments were considered ($r = 0.63$, $p < 0.01$) and when the radiologic score was compared with the comet score of a single intercostal space (no. 6, right side at the third intercostal space on the anterior axillary line), which gave the highest echo comet score in the overall population ($r = 0.64$, $p < 0.01$). The degree of correlation was better in patients admitted to our cardiologic unit ($n = 119$, $r = 0.82$, $p < 0.01$) than in patients admitted to the pneumologic unit ($n = 16$, $r = 0.45$, $p = 0.07$). The correlation was also improved

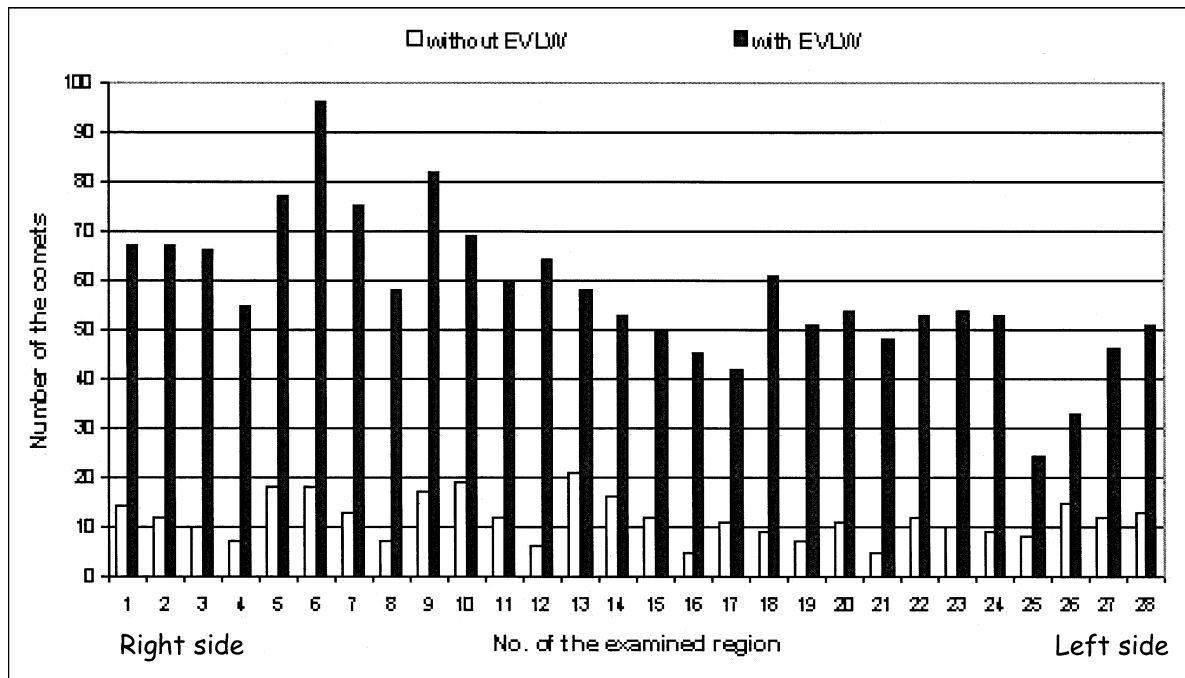


FIGURE 4. Spatial distribution of comet-tail sign on the chest. Numbers of sites (from left to right and from upper row to lower row) as in Figure 1 (from 1 to 16, right side; from 17 to 28, left side). EVLW = extravascular lung water.

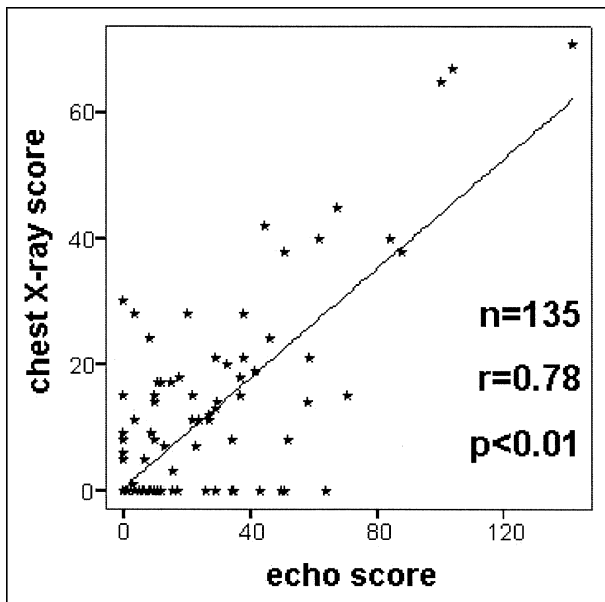


FIGURE 5. Correlation between radiologic score of extravascular lung water and echographically assessed comet score (number of comets).

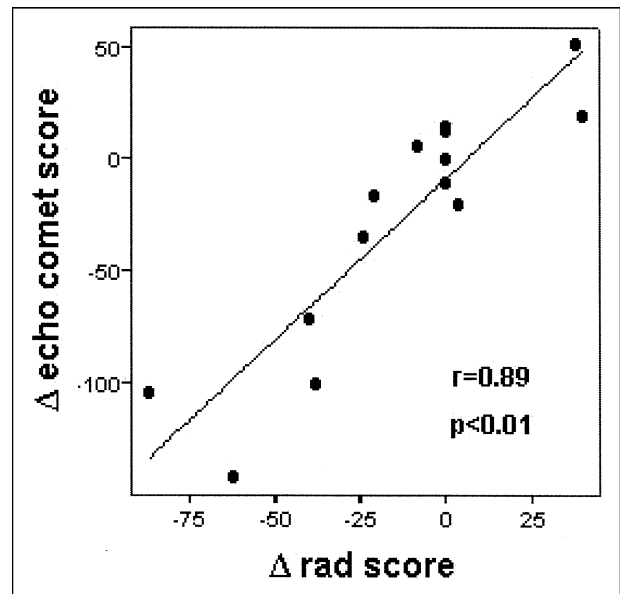


FIGURE 6. The inpatient correlation between changes in the radiologic (rad) score of extravascular lung water (y-axis) and echographically assessed comet score (x-axis).

when inpatient correlations in the 14 patients (15 cases) with >1 examination were analyzed ($r = 0.89$, $p < 0.01$; Figure 6). A frequent source of discrepant results was the presence of lung echo comets in the absence of extravascular lung water on chest x-ray. This false-positive response was often associated with radiologic abnormalities other than extravascular lung water.

At multivariate analysis, the presence of radiologically assessed extravascular lung water was predicted

only by echocardiographically assessed ejection fraction ($p = 0.007$, odds ratio 0.95, 95% confidence interval 0.92 to 0.99) and by echo comet score ($p = 0.001$, odds ratio 1.06, 95% confidence interval 1.03 to 1.10).

DISCUSSION

Previous studies have clarified the likely biophysical mechanism underlying the comet-tail artifact.^{1,2} All diagnostic ultrasound methods are based on the

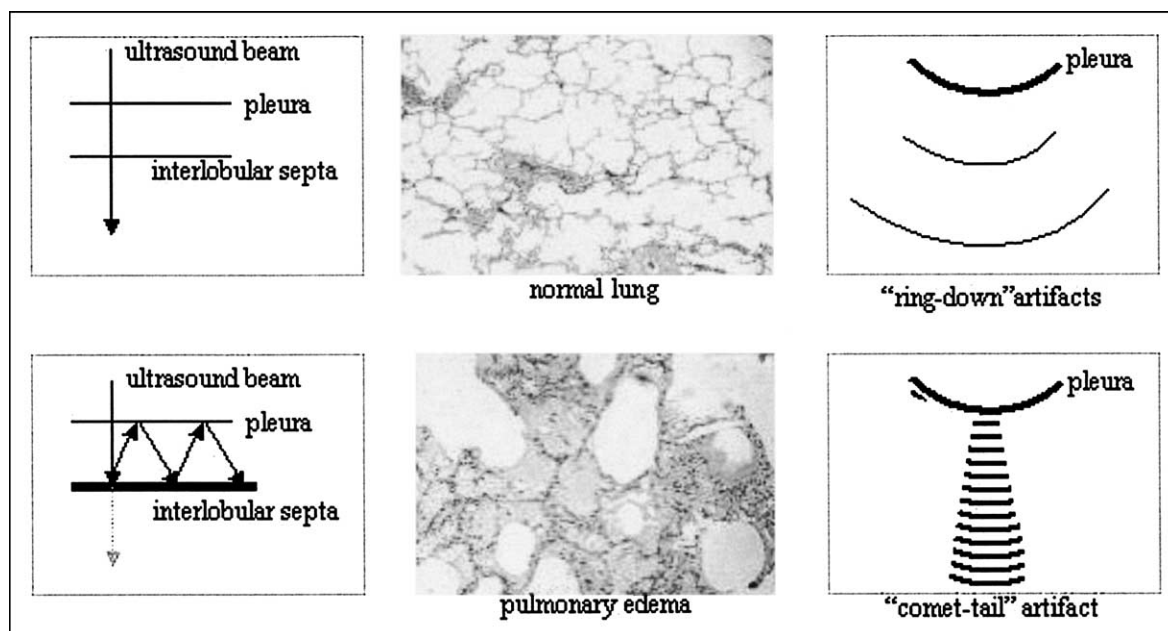


FIGURE 7. The hypothesized physical and anatomic basis of echo lung comets. Reflections of the ultrasound beam by the thickened interlobular septa proved comet-tail artifact in patients with extravascular lung water.

principle that ultrasound is reflected by an interface between media of different acoustic impedance.⁶ In normal conditions, with the transducer positioned on the chest wall, the ultrasound beam finds the lung air (i.e., high impedance and no acoustic mismatch on its pathway through the chest) (Figure 7). In the presence of extravascular lung water, the ultrasound beam finds subpleural interlobular septa thickened by edema (i.e., a low impedance structure surrounded by air and with a high acoustic mismatch). The reflection of the beam creates a phenomenon of resonance. When the beam meets the subpleural end of the thickened septum, the time lag between successive reverberations is interpreted by the transducer as a distance, resulting in a center that behaves like a persistent source, generating a series of very closely spaced pseudointerfaces.^{1,2} The physical basis of the water comets also explains the sources of false-positive comets, which were often found in the presence of radiologic alterations, such as pleuritis, bronchiectasia, or emphysema. In all these conditions, fibrosis in the parietal pleura or interlobular septa may occur, which can lead to reflection of the ultrasound wave, generating echo comets.

Chest x-ray is an essential diagnostic tool for the clinical cardiologist. In patients with chronic heart failure, chest x-ray is especially useful to detect cardiomegaly and pulmonary congestion.⁷ Even in the present echocardiographic era, it is often necessary to have serial chest x-rays to evaluate extravascular lung water to tailor the best treatment in the patient.⁸ When pulmonary interstitial edema is present, the lungs may be clear to auscultation, because the extravascular fluid is confined to the interstitium.³ According to the present study, echocardiography had the potential to

identify and quantify radiologically assessed extravascular lung water. The clinical impact of this information is further increased by the nonionizing nature of the examination,⁹ which can be performed at bedside with a hand-held device and is very simple to interpret, is easily quantified, and is not dependent on cardiac acoustic windows or patient decubitus. Echocardiography is now an essential part of first-line cardiologic evaluation, and lung water comets can further expand its application domain.

Chest x-rays were adopted as a gold standard for assessing extravascular lung water. A more accurate evaluation could have been obtained with more complex, invasive, or technically demanding techniques, or a combination of these, such as electrical impedance tomography,¹⁰ photon transmission,¹¹ computerized tomography,¹² or double-indicator dilution techniques.¹³ However, chest x-ray films remain the standard clinical method for assessing interstitial and alveolar pulmonary edema and evaluation of other aspects of lung pathology.

1. Lichtenstein D, Meziere G, Biderman P, Gepner A, Barre O. The comet-tail artifact. An ultrasound sign of alveolar-interstitial syndrome. *Am J Respir Crit Care Med* 1997;156:1640–1646.
2. Lichtenstein D, Meziere G. A lung ultrasound sign allowing bedside distinction between pulmonary edema and chronic obstructive pulmonary disease: the comet-tail artifact. *Intensive Care Med* 1998;24:1331–1334.
3. Givertz MM, Colucci WS, Braunwald E. Clinical aspects of heart failure: high-output failure, pulmonary edema. In: Braunwald E, Zipes DS, Libby P, eds. *Heart Disease*. 6th Ed. Philadelphia, PA: WB Saunders, 2001:545–546.
4. Giuntini C, Pistolesi M, Miniati M, Fazio F. Theoretical and practical considerations of measuring extravascular lung water. *J Thorac Imaging* 1988;3:36–43.
5. Pistolesi M, Giuntini C. Assessment of extravascular lung water. *Radiol Clin North Am* 1978;15:551–574.
6. Schiller NB, Shah PM, Crawford M, DeMaria A, Devereux R, Feigenbaum H, Gutgesell H, Reicheck N, Sahn D, Schnittger I, Silverman NH, Tajik AJ. Recommendations for quantitation of the left ventricle by two-dimensional echo-

- cardiography. American Society of Echocardiography Committee on Standards, Subcommittee on Quantitation of Two-Dimensional Echocardiograms. *J Am Soc Echocardiogr* 1989;2:358–367.
7. Remme WJ, Swedberg K. European Society of Cardiology. Comprehensive guidelines for the diagnosis and treatment of chronic heart failure. Task force for the diagnosis and treatment of chronic heart failure of the European Society of Cardiology. *Eur J Heart Fail* 2002;4:11–22.
8. Thomas JT, Kelly RF, Thomas SJ, Stamos TD, Albasha K, Parrillo JE, Calvin JE. Utility of history, physical examination, electrocardiogram, and chest radiograph for differentiating normal from decreased systolic function in patients with heart failure. *Am J Med* 2002;112:437–445.
9. Picano E. Sustainability of medical imaging. Education and debate. *BMJ* 2004;328:578–580.
10. Noble TJ, Harris ND, Morice AH, Milnes P, Brown BH. Diuretic induced change in lung water assessed by electrical impedance tomography. *Physiol Meas* 2000;21:155–163.
11. Bergstrom P, Jacobsson L, Lomsky M. Measurement of lung density by photon transmission for monitoring intravascular and extravascular fluid volume changes in the lungs. *Clin Physiol* 1999;19:519–526.
12. Kato S, Nakamoto T, Iizuka M. Early diagnosis and estimation of pulmonary congestion and edema in patients with left-sided heart diseases from histogram of pulmonary CT number. *Chest* 1996;109:1439–1445.
13. Eising GP, Niemeyer M, Gunther T, Tassani P, Pfauder M, Schad H, Lange R. Does a hyperoncotic cardiopulmonary bypass prime affect extravascular lung water and cardiopulmonary function in patients undergoing coronary artery bypass surgery? *Eur J Cardiothorac Surg* 2001;20:282–289.