



UNIVERSITÀ
DEGLI STUDI
FIRENZE

FLORE

Repository istituzionale dell'Università degli Studi di Firenze

Listen to your heart

Questa è la Versione finale referata (Post print/Accepted manuscript) della seguente pubblicazione:

Original Citation:

Listen to your heart / Iacopo Bertolozzi; Angelo Pucci; Pietro Amedeo Modesti. - In: INTERNAL AND EMERGENCY MEDICINE. - ISSN 1828-0447. - STAMPA. - 4:(2009), pp. 133-135. [10.1007/s11739-009-0224-9]

Availability:

The webpage <https://hdl.handle.net/2158/777214> of the repository was last updated on

Published version:

DOI: 10.1007/s11739-009-0224-9

Terms of use:

Open Access

La pubblicazione è resa disponibile sotto le norme e i termini della licenza di deposito, secondo quanto stabilito dalla Policy per l'accesso aperto dell'Università degli Studi di Firenze (<https://www.sba.unifi.it/upload/policy-oa-2016-1.pdf>)

Publisher copyright claim:

La data sopra indicata si riferisce all'ultimo aggiornamento della scheda del Repository FloRe - The above-mentioned date refers to the last update of the record in the Institutional Repository FloRe

(Article begins on next page)

Listen to your heart

Iacopo Bertolozzi · Angelo Pucci ·
Pietro Amedeo Modesti

Received: 7 January 2009 / Accepted: 9 January 2009 / Published online: 19 February 2009
© SIMI 2009

Case report

Iacopo Bertolozzi, Angelo Pucci

A 61-year-old woman came to the Emergency Department of our Hospital for fatigue and breathlessness. She was discharged from the surgery ward 2 days before, after a subtotal colectomy for adenocarcinoma had been performed 10 days before. While explaining her history, she appeared very worried because of not hearing since the day before, the usual clicking noise of her mechanical mitral valve prosthesis. The metallic bileaflet-tilting—disk valve (St Jude Medical, Inc.) had been implanted 10 years before. Anticoagulant therapy (acenocumarol) was interrupted before the colon surgery, and the patient was receiving low-molecular weight heparin (nadroparin 5,700 UI bid).

On physical examination, the heart rate was 100 beats per minute, blood pressure was 90/50 mmHg, and respiratory rate was 18 breaths per minute. Auscultation of the heart revealed an absence of a prosthetic closure sound and a grade III holosystolic murmur in the mitral area. Rales were present at both lung bases. A transthoracic echocardiogram, immediately performed, revealed severely restricted movement of the prosthetic mitral valve leaflets with an increased peak diastolic transmitral pressure gradient (Fig. 1a).

Unfractionated heparin was commenced immediately. The idea of arranging a transfer to another hospital for cardiac surgery was rejected because of the high operative risk and the presence of co-morbidities. The hemodynamic status indeed rapidly and dramatically worsened, with the clinical evidence of cardiogenic shock. Notwithstanding the recent abdominal surgery, systemic thrombolysis was administered (rt-PA 100 mg over 120 min). The patient's hemodynamic status rapidly improved, and a transthoracic echocardiogram, performed at the end of the rt-PA infusion, showed normalization of the transmitral flow pattern (Fig. 1b). The patient was discharged after a 2-week hospitalization on anticoagulant treatment.

Prosthetic valve thrombosis is an infrequent but potentially life-threatening complication with a reported incidence of 0.5–8% of left-sided valves and up to 20% of tricuspid valves [1–3]. Reoperation, the traditional treatment of severe prosthetic thrombosis is associated with significant morbidity and mortality particularly in critical patients [4, 5]. Evidence is growing that fibrinolysis can be considered as the first-line treatment in the absence of contraindications [6]. Although recent (less than 2 weeks) major surgical procedures usually exclude the possibility of fibrinolysis in myocardial infarction [7], this condition is not considered a contraindication for treating obstruction of prosthetic valve in critically ill patients [8] where a totally different balance of risks and benefits exists.

I. Bertolozzi (✉) · A. Pucci
Cardiologia–Cardiostimolazione Carrara, Ospedale di Carrara,
Piazza Sacco e Vanzetti, 1, 54033 Carrara, Italy
e-mail: bertolozzicardio@libero.it

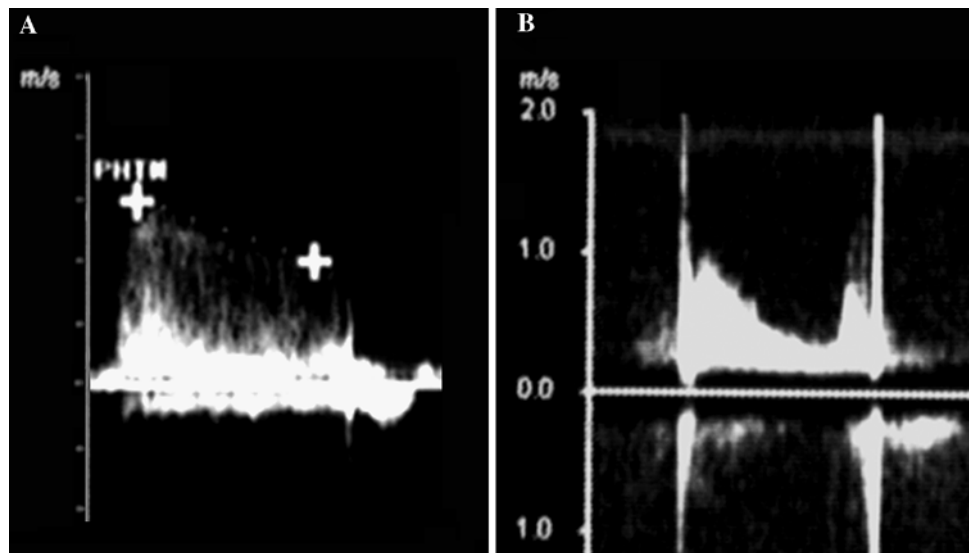
P. A. Modesti
Department of Critical Care Medicine,
University of Florence, Florence, Italy
e-mail: pamodesti@unifi.it

Comment

Pietro Amedeo Modesti

The recent disappearance of the usual clicking noise of the valve prosthesis referred by the patient immediately led to

Fig. 1 Spectral Doppler recordings of prosthetic valve flow at the time of admission (a) reveal the absence of the brief high velocity signals that are associated to both the opening and closure of the valve leaflets (“clicks”) and the evidence of a very high pressure gradient (peak diastolic gradient 34 mmHg). After thrombolysis (b) the Doppler recording of flow through the valve is normalized: clicks are clearly detectable and transvalvular pressure gradient is within normal values (peak diastolic gradient 10 mmHg)



the correct diagnosis. History, patient’s complaints and the physical examination are well recognized as an essential source of information about the patient’s illness. However, self physical examination performed by the patient may sometimes be useful; the lack of the patient hearing the “click clack” indeed represented the first warning of a life-threatening condition. Although the diagnosis can be made by imaging studies, the first sign of prosthesis malfunction is indeed a variation of the sounds produced by the device [9]. In this case, the change of the valve clicking noise was early appreciated by the patient herself. The changes in heart sounds identify prosthetic valve dysfunction before clinical symptoms develop. As a matter of fact, by the time when symptoms are manifest, a high risk condition is already present. Self measurement of body weight, blood pressure, pulse rate and rhythm, self-skin examination are often recommended and thought to protect and assist patients in successful management in clinical practice. Probably in the same way, attention to acute changes in the sound of a mechanical prosthesis can be taught to help the patient in performing self monitoring.

The closing sound of Bjork–Shiley heart valve prosthesis can be heard clearly in the proximity of the patient, one out of three patients even reporting disturbance of those nearby [10]. The disappearance of this loud, high frequency, metallic closing sound may thus be a relief for the relatives but is an emergency for the patient. The absence of this distinct closing sound is abnormal, and implies valve dysfunction. Moreover, the stethoscope may help to discriminate between normal and abnormal murmurs of prosthetic valves. For an aortic prosthetic valve, a systolic ejection murmur can be a normal finding being caused by a mild outflow obstruction that may increase with rising cardiac output. All tilting disc prosthesis has a small regurgitant flow in the closed position to minimize

thrombotic complications, so that a low intensity diastolic murmur may be normal. However, a high intensity diastolic murmur is always a sign of aortic mechanical valve dysfunction. The opposite is true for mitral prosthetic valves where short diastolic murmurs, best heard at the apex with the patient in the left lateral decubitus, are normal, while any high intensity holosystolic murmur is pathological. Always interpret as a pathologic finding, any holosystolic murmur greater than 2/6 in a patient with an artificial mitral valve! These simple criteria have been used to develop digital phonocardiographic devices (Thrombo-Check) to follow the sounds of prosthesis in order to detect alterations of prosthetic valve function before performing imaging studies [11, 12]. Remote transmission of acoustic data could be of help for patients with mechanical valves living in countries with limited healthcare resources.

In our patient the altered sound of prosthetic valve strongly suggested that the cardiac origin of the shortness of breath although anemia is undoubtedly a more common cause of dyspnoea in the postoperative period. When the sound is altered, echocardiography is the imaging diagnostic examination of choice with three possible findings, thrombus formation, fibrous tissue ingrowth (pannus) or endocarditis. In this case, the possibility of thrombosis was high because the patient had no fever, symptoms and signs occurred within a few days, and most importantly, anti-coagulants had been withdrawn. Thrombosis is also the major cause of valve occlusion [4]. Nevertheless, confirmation of the diagnosis of thrombotic obstruction is important because only patients with thrombus will benefit from thrombolytic therapy [13]. No randomised trials comparing surgery and thrombolysis exist because of the small number of cases, and the multiplicity of factors influencing the therapeutic decision. The current ACC/AHA VHD guidelines [8] for critically ill patients with

prosthetic valve thrombosis recommend: emergency operation in left-sided prosthesis in the presence of a large clot burden (recommendation class IIa, level of evidence C) and fibrinolytic therapy in right-sided valves (recommendation class IIa, level of evidence C) and in left-sided prosthesis with a small or large thrombus dimension if surgery is at high risk or not available (recommendation class IIb, level of evidence C).

The patient described in the case was at very high risk both for lytic therapy (recent abdominal surgery) and for emergency valve replacement (high anesthesiologic risk and co-morbidities). The surgical team refused the case so there was only one choice to help the patient, and that was to use thrombolysis; fortunately, all went well. Her good hearing and perspicacity in the interpretation of the absence of sounds were very helpful.

Conflict of interest statement The authors declare that they have no conflict of interest related to the publication of this manuscript.

References

1. Edmunds LH Jr (1982) Thromboembolic complications of current cardiac valvular prostheses. *Ann Thorac Surg* 34:96–106
2. Kontos GJ Jr, Schaff HV, Orszulak TA, Puga FJ, Pluth JR, Danielson GK (1989) Thrombotic obstruction of disc valves: clinical recognition and surgical management. *Ann Thorac Surg* 48:60–65
3. Thorburn CW, Morgan JJ, Shanahan MX, Chang VP (1983) Long-term results of tricuspid valve replacement and the problem of prosthetic valve thrombosis. *Am J Cardiol* 51:1128–1132
4. Deviri E, Sareli P, Wisenbaugh T, Cronje SL (1991) Obstruction of mechanical heart valve prostheses: clinical aspects and surgical management. *J Am Coll Cardiol* 17:646–650
5. Akins CW (1995) Results with mechanical cardiac valvular prostheses. *Ann Thorac Surg* 60:1836–1844
6. Lengyel M, Horstkotte D, Völler H, Mistiaen WP; Working Group Infection, Thrombosis, Embolism and Bleeding of the Society for Heart Valve Disease (2005) Recommendations for the management of prosthetic valve thrombosis. *J Heart Valve Dis* 14:567–575
7. Lengyel M, Fuster V, Keltai M, Roudaut R, Schulte HD, Seward JB, Chesebro JH, Turpie AG (1997) Guidelines for management of left-sided prosthetic valve thrombosis: a role for thrombolytic therapy. Consensus conference on prosthetic valve thrombosis. *J Am Coll Cardiol* 30:1521–1526
8. Bonow RO, Carabello BA, Chatterjee K, de Leon AC Jr, Faxon DP, Freed MD, Gaasch WH, Lytle BW, Nishimura RA, O’Gara PT, O’Rourke RA, Otto CM, Shah PM, Shanewise JS; 2006 Writing Committee Members; American College of Cardiology/American Heart Association Task Force (2008) Focused update incorporated into the ACC/AHA 2006 guidelines for the management of patients with valvular heart disease: a report of the American College of Cardiology/American Heart Association Task Force on Practice Guidelines (Writing Committee to Revise the 1998 Guidelines for the Management of Patients With Valvular Heart Disease): endorsed by the Society of Cardiovascular Anesthesiologists, Society for Cardiovascular Angiography and Interventions, and Society of Thoracic Surgeons. *Circulation* 118(15):e523–661
9. Cáceres-Lóriga FM, Pérez-López H, Santos-Gracia J, Morlans-Hernandez K (2006) Prosthetic heart valve thrombosis: pathogenesis, diagnosis and management. *Int J Cardiol* 110:1–6
10. Schöndube F, Keusen H, Messmer BJ (1983) Physical analysis of the Björk–Shiley prosthetic valve sound. *J Thorac Cardiovasc Surg* 86:136–141
11. Fritzsche D, Schenk S, Eitz T, Mantas J, Horstkotte D, Koerfer R (2007) Patient self-monitoring of prosthetic heart valve function. *J Heart Valve Dis* 16:558–566
12. Fritzsche D, Eitz T, Laczkovics A, Liebold A, Knaut M, Matschke K, Sagie A, Mehlhorn U, Horstkotte D, Koerfer R (2007) Early detection of mechanical valve dysfunction using a new home monitoring device. *Ann Thorac Surg* 83:542–548
13. Khan SS (1998) Guidelines for thrombolytic therapy. *J Am Coll Cardiol* 32:550–551