



UNIVERSITÀ
DEGLI STUDI
FIRENZE

FLORE

Repository istituzionale dell'Università degli Studi di Firenze

Sonographic diagnosis of a large and deep endometrioma of the uterine cervix.

Questa è la Versione finale referata (Post print/Accepted manuscript) della seguente pubblicazione:

Original Citation:

Sonographic diagnosis of a large and deep endometrioma of the uterine cervix / Coccia ME;Rizzello F;Castellacci E;Cammilli F. - In: JOURNAL OF CLINICAL ULTRASOUND. - ISSN 0091-2751. - ELETTRONICO. - 38:(2010), pp. 209-211. [10.1002/jcu.20677]

Availability:

The webpage <https://hdl.handle.net/2158/781231> of the repository was last updated on

Published version:

DOI: 10.1002/jcu.20677

Terms of use:

Open Access

La pubblicazione è resa disponibile sotto le norme e i termini della licenza di deposito, secondo quanto stabilito dalla Policy per l'accesso aperto dell'Università degli Studi di Firenze (<https://www.sba.unifi.it/upload/policy-oa-2016-1.pdf>)

Publisher copyright claim:

La data sopra indicata si riferisce all'ultimo aggiornamento della scheda del Repository FloRe - The above-mentioned date refers to the last update of the record in the Institutional Repository FloRe

(Article begins on next page)

Case Report

Sonographic Diagnosis of a Large and Deep Endometrioma of the Uterine Cervix

Maria Elisabetta Coccia, MD, PhD, Francesca Rizzello, MD, Eleonora Castellacci, MD, Fiamma Cammilli, MD

Department of Gynaecology Perinatology and Human Reproduction, University of Florence, Viale Morgagni, 85, 50100 Florence, Italy

Received 3 February 2009; accepted 5 January 2010

ABSTRACT: We present a rare case of endometriosis of the cervix. Transvaginal sonography showed a 35-mm cyst in the cervix with diffuse, low-level internal echoes. Transvaginal sonography-guided aspiration with a 17-gauge needle was performed, yielding a very thick chocolate-colored fluid. Cytological examination of the fluid revealed the presence of endometrial cells. Symptoms resolved after aspiration and no recurrence has developed. © 2010 Wiley Periodicals, Inc. *J Clin Ultrasound* 00:000–000, 2010; Published online in Wiley InterScience (www.interscience.wiley.com). DOI: 10.1002/jcu.20677

Keywords: endometriosis; ultrasound; transvaginal aspiration; uterus; cervix

Endometriosis is characterized by the presence of endometrial tissue (including glands and stroma) outside the uterus. It is a common condition occurring in 6 to 10% of the general female population.¹ Extrapelvic disease occurs in 12% of patients with endometriosis and endometriosis of the uterine cervix is estimated at 0.1–2.4% of all endometriotic localizations.² This rare localization may be totally asymptomatic or associated with nonspecific findings like postcoital or intermenstrual bleeding.²

In this article, we present a rare case of large cervical endometrioma diagnosed by transvaginal ultrasound (TVUS) and treated by TVUS-guided drainage. Pathogenesis, differential diagnosis, and management options of cervical endometriomas are also discussed.

CASE REPORT

A 33-year-old Caucasian woman complained of dyspareunia and postcoital bleeding for a duration of 8 months. She had a history of infertility and irregular periods. A cervical smear performed 1 year previously was normal. The gynecological examination provoked pain and revealed a mass of approximately 3 cm in diameter, arising from the cervix. The vagina appeared normal. The cervix was deformed by a mass covered with intact mucosa but showed a normal ostium and no evidence of superficial lesions. TVUS was performed using an Aloka 1700 scanner and an endovaginal transducer of 6.5 MHz (Aloka, Tokyo, Japan). TVUS showed a normal uterine body and ovaries, while the posterior lip of the cervix contained a 35-mm round-shaped cyst with homogeneous internal low-level echoes, without papillary proliferations or internal septa, and with a clear demarcation from the adjacent normal cervical tissue (Figure 1). On color Doppler examination, neither intracystic nor peripheral flow was observed. The sonographic appearance was consistent with an endometrioma.³

TVUS-guided transvaginal needle aspiration with a 17-gauge, 35-cm-long needle (Cook, Spencer, IN) yielded a thick, chocolate-like fluid. Neither analgesic drugs nor prophylactic antibiotics were administered during or before the procedure.

Complete drainage was achieved through continuous flushing and re-aspiration using a 60 ml syringe containing 10 ml of a 5% glucose solution. Aspiration continued until the cyst had completely collapsed and a total of 7 mL was collected.

Cytological examination of the aspirated fluid revealed the presence of endometrial cells.

Correspondence to: M. E. Coccia

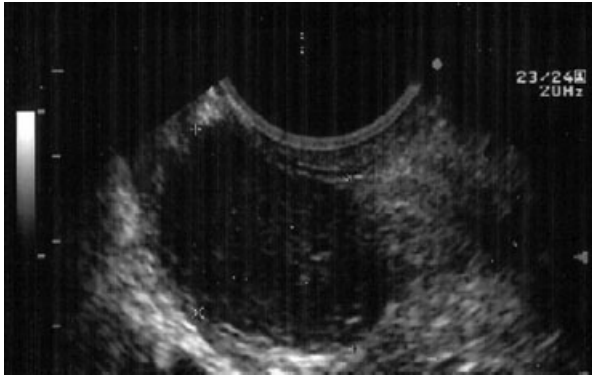


FIGURE 1. Sagittal TVUS scan of the uterine cervix shows a round homogeneous hypoechoic cystic mass (calipers) with low-level internal echoes, without papillary proliferations or internal septa, and with a clear demarcation from the adjacent normal cervical tissue.

On follow-up examinations performed 3, 9, and 12 months later, the patient reported the resolution of dyspareunia and postcoital bleeding and both gynecological examination and TVUS showed a normal cervix.

DISCUSSION

Endometriosis is one of the most common benign gynecological disorders in women of reproductive age. Its etiology still remains unknown.

Sampson's menstrual reflux and implantation theory is widely accepted and explains the anatomic distribution of endometriosis.⁴ Although the ovary is the most commonly involved site (80% of cases), other sites such as the cul-de-sac and uterosacral ligaments are frequently affected.⁵ Other theories were proposed to explain pathogenesis of endometriotic lesions in less common sites like cervix, pleura, lungs, brain, and eyes.

Cervical endometriosis may be asymptomatic or associated with postcoital or intermenstrual bleeding. A higher occurrence of cervical endometriosis has been observed in women with a history of cervical trauma associated with surgical procedures (eg, curettage, biopsy, cauterization, or laser treatments).⁶

Our patient had no history of cervical trauma from either childbirth or pelvic surgery.

Cervical endometriosis occurs in 2 forms: superficial and deep. The 1st involves the superficial cervical stroma immediately subjacent to the epithelium, or occasionally the mucosa. It may appear as a bluish-red or bluish-black lesion, or more often as a microscopic finding associated with abnormal cervical smears.⁷ The deep form is localized in the outer 3rd of the cervical wall and

is usually associated with the involvement of the rectovaginal septum or serosal surface of the supravaginal portion of the cervix.⁸

Colposcopy and directed cervical biopsy can provide an accurate diagnosis of superficial cervical endometriosis. We believe that in case of an abnormal cervical morphology, the TVUS examination has become necessary to suspect "endometrioma" of the cervix. On sonography a cervical endometrioma typically appears as a well-defined nodule or cyst limited to the cervix with low-level internal echoes related to the thick fluid.³ The differential diagnoses include Nabothian cysts, fibromas, abscesses, cervical pregnancies, cervical or endometrial cancer, granulomas, and embryological rests.

On sonographic examination, Nabothian cysts are seen as anechoic structures that are clustered in the midline. They can be solitary or multiple and of various sizes.⁹ When containing internal debris, they may mimic cervical endometrioma. Very limited literature is available to allow a differential diagnosis of these 2 conditions due to the rarity of cervical endometrioma. Mucinous retention cysts, containing blood, should produce a heterogeneous pattern different from the homogeneous "ground-glass" typical of endometriomas.

Expectant management would be appropriate for asymptomatic patients and perimenopausal patients. However, large, deep, cervical cysts that cause symptoms affecting the quality of life should be managed alternatively. The classic strategies of diagnosis and management involve colposcopy and excision. Successful treatment of cervical endometriosis with superficial electrocauterization has been reported; however, this technique is also associated with a high rate of recurrence. There are few reports on the results of more recent treatment modalities, such as cryotherapy or laser treatment.^{10,11}

Aspiration of the cyst was performed in our case, resulting in the prompt resolution of symptoms through a minimally invasive procedure that caused no further damage to the cervix. No recurrence was observed during the 12 months of follow-up.

Long-term efficacy of aspiration of endometrioma is still being debated. Recurrence rate of ovarian endometrioma after aspiration ranges from 10 to 83.3%.¹² There are no data about recurrence rate of cervical endometrioma after aspiration.

Advantages of aspiration of cervical endometrioma include the following: the prompt resolution of pain; no need for surgical treatment with

anesthesia; no need for operation room; no scar of the cervix that can result in infertility.

Our case of deep cervical endometriosis is notable because it involves a large cervical cyst over 3 cm in diameter; most of the cases in the literature involved small, flat, fragile, superficial lesions located on the fibrovascular stroma of the ectocervix. When cervical endometriosis presents as a mass, it can be misdiagnosed and lead to overtreatment. To our knowledge, only 5 cases similar to ours have been reported.¹³⁻¹⁷

It is important for both gynecologists and oncologists to be aware that endometriosis may present as a cervical endometrioma.

REFERENCES

1. Giudice LC, Kao LC. Endometriosis. *Lancet* 2004; 364:1789.
2. Veiga-Ferreira MM, Leiman G, Dunbar F, et al. Cervical endometriosis: facilitated diagnosis by fine needle aspiration cytologic testing. *Am J Obstet Gynecol* 1987;157:849.
3. Mais V, Guerriero S, Ajossa S, et al. The efficiency of transvaginal ultrasonography in the diagnosis of endometrioma. *Fertil Steril* 1993;60:776.
4. Sampson JA. Peritoneal endometriosis due to menstrual dissemination of endometrial tissue into the peritoneal cavity. *Am J Obstet Gynecol* 1927; 14:422.
5. Jenkins S, Olive DL, Haney AF. Endometriosis: pathogenetic implications of the anatomic distribution. *Obstet Gynecol* 1986;67:335.
6. Balachandran I, Gerber M. Presentation of endometriosis of the cervix in cervical smear: a case report and review of literature. *J Low Genit Tract Dis* 2002;6:162.
7. Baker PM, Clement PB, Bell DA, et al. Superficial endometriosis of the uterine cervix: a report of 20 cases of a process that may be confused with endocervical glandular dysplasia or adenocarcinoma in situ. *Int J Gynecol Pathol* 1999;18:198.
8. Phadnis SV, Doshi JS, Ogunnaike O, et al. Cervical endometriosis: a diagnostic and management dilemma. *Arch Gynecol Obstet* 2005;272:289.
9. Fogel SR, Slasky BS. Sonography of nabothian cysts. *AJR Am J Roentgenol* 1982;138:927.
10. Adamian LV, Kulakov VI. Combined treatment of retrocervical, cervical and vaginal endometriosis using CO2 laser, cryosurgery and electrocoagulation. *Akush Ginekol (Mosk)* 1990;7:54.
11. Wozniak J, Szczepanska M, Opala T, et al. Point CO2 laser vaporization in treatment of superficial endometriosis of the uterine cervix. *Ginekol Pol* 1995;66:19.
12. Audebert A. Ovarian endometrioma and infertility: when not to treat? *Gynecol Obstet Fertil* 2005;33:416.
13. Kano H, Kanda H. Cervical endometriosis presented as a polypoid mass of portio cervix uteri. *J Obstet Gynaecol* 2003;23:81.
14. Fukunaga M. Uterus-like mass in the uterine cervix: superficial cervical endometriosis with florid smooth muscle metaplasia? *Virchows Arch* 2001; 438:302.
15. Ganesh AL, Chakravarty B. Spontaneous viable pregnancies in cervical and rectal endometriosis: a report of two cases. *Fertil Steril* 2007;87:697.
16. Yokota N, Yoshida H, Sakakibara H, et al. A severe vaginal hemorrhage caused by cervical endometriosis. *Am J Obstet Gynecol* 2008;199.
17. Iwase A, Goto M, Kurotsuchi S, et al. Successful management of a massive hemorrhage due to rupture of cystic cervical endometriosis by a loop electrosurgical excision procedure. *Fertil Steril* 2008; 89:991.