



UNIVERSITÀ  
DEGLI STUDI  
FIRENZE

## FLORE

# Repository istituzionale dell'Università degli Studi di Firenze

### **Morphometric analysis of treatment effects of the Balters bionator in growing Class II patients.**

Questa è la Versione finale referata (Post print/Accepted manuscript) della seguente pubblicazione:

*Original Citation:*

Morphometric analysis of treatment effects of the Balters bionator in growing Class II patients / C. F. Antunes; R. Bigliuzzi; F. A. Bertoz; C. L. Feijó; L. Franchi; K. F. Jr. - In: ANGLE ORTHODONTIST. - ISSN 0003-3219. - STAMPA. - 83:(2013), pp. 455-459. [10.2319/072512-605.1]

*Availability:*

The webpage <https://hdl.handle.net/2158/810279> of the repository was last updated on 2016-11-30T21:37:07Z

*Published version:*

DOI: 10.2319/072512-605.1

*Terms of use:*

Open Access

La pubblicazione è resa disponibile sotto le norme e i termini della licenza di deposito, secondo quanto stabilito dalla Policy per l'accesso aperto dell'Università degli Studi di Firenze (<https://www.sba.unifi.it/upload/policy-oa-2016-1.pdf>)

*Publisher copyright claim:*

La data sopra indicata si riferisce all'ultimo aggiornamento della scheda del Repository FloRe - The above-mentioned date refers to the last update of the record in the Institutional Repository FloRe

(Article begins on next page)

## Morphometric analysis of treatment effects of the Balters bionator in growing Class II patients

Carina Ferlin Antunes<sup>a</sup>; Renato Bigliuzzi<sup>b</sup>; Francisco Antonio Bertoz<sup>c</sup>;  
Cristina Lúcia Feijó Ortolani<sup>d</sup>; Lorenzo Franchi<sup>e</sup>; Kurt Faltin, Jr.<sup>f</sup>

### ABSTRACT

**Objective:** To investigate the effects of the standard (Class II) Balters bionator in growing patients with Class II malocclusion with mandibular retrusion by using morphometrics (thin-plate spline [TPS] analysis).

**Materials and Methods:** Thirty-one Class II patients (17 male and 14 female) were treated with the Balters bionator (bionator group). Mean age at the start of treatment (T0) was 10.3 years, while it was 13 years at the end of treatment (T1). Mean treatment time was 2 years and 2 months. The control group consisted of 22 subjects (14 male and 8 female) with untreated Class II malocclusion. Mean age at T0 was 10.2 years, while it was 12.2 years at T1. The observation period lasted 2 years on average. TPS analysis evaluated statistical (permutation tests) differences in the craniofacial shape and size between the bionator and control groups.

**Results:** Through TPS analysis (deformation grids) the bionator group showed significant shape changes in the mandible that could be described as a mandibular forward and downward displacement. The control group showed no statistically significant differences in the correction of Class II malocclusion.

**Conclusions:** Bionator appliance is able to induce significant mandibular shape changes that lead to the correction of Class II dentoskeletal disharmony. (*Angle Orthod.* 2013;83:455–459.)

**KEY WORDS:** Functional jaw orthopedics; Class II malocclusion; Morphometric analysis; Thin-plate spline analysis

### INTRODUCTION

Lateral cephalograms have become one of the major diagnostic tools in the study of facial growth changes and modifications induced by orthodontic/orthopedic treatment.<sup>1,2</sup> Conventional cephalometrics enables identification of skeletal, dental, and soft tissue problems in patients with malocclusions in addition to being still widely employed to evaluate angular and linear measures. Although conventional cephalometric analysis (CCA) is individualized, it does not always prove effective in determining accurately the location and mode in which changes in shape and size occur within the craniofacial complex.<sup>3</sup> Thus, CCA has no theoretical foundation, but it is rather governed by conventions involving points and planes, which fail to capture curvilinear forms and changes in these forms.<sup>4</sup>

As science evolved, geometric morphometrics emerged<sup>5</sup> as an alternative method to address these issues and eventually overcome the difficulties posed by CCA. One such alternative is thin-plate spline (TPS) analysis that assesses spatial changes in the shape of

<sup>a</sup> Specialist in Orthodontics, Department of Orthodontics, School of Dentistry, University Paulista, São Paulo, Brazil.

<sup>b</sup> PhD candidate in Orthodontics, Department of Pediatric and Social Dentistry, Dental School of Araçatuba, São Paulo State University “Júlio de Mesquita Filho,” São Paulo; Adjunct Professor, Department of Orthodontics, School of Dentistry, University Paulista, São Paulo, Brazil.

<sup>c</sup> Professor, Department of Pediatric and Social Dentistry, Dental School of Araçatuba, São Paulo State University “Júlio de Mesquita Filho,” São Paulo, Brazil.

<sup>d</sup> Professor, Department of Orthodontics, School of Dentistry, University Paulista, São Paulo, Brazil.

<sup>e</sup> Assistant Professor, Department of Orthodontics, University of Florence, Florence, Italy; Thomas M. Graber Visiting Scholar, Department of Orthodontics and Pediatric Dentistry, School of Dentistry, The University of Michigan, Ann Arbor, Mich.


<sup>f</sup> Chair, Department of Orthodontics, School of Dentistry, University Paulista, São Paulo, Brazil.

Corresponding author: Lorenzo Franchi, DDS, PhD, Department of Orthodontics, Università degli Studi di Firenze, Via del Ponte di Mezzo, 46–48, 50127, Florence, Italy (e-mail: lorenzo.franchi@unifi.it)

Accepted: September 2012. Submitted: July 2012.

Published Online: November 8, 2012

© 2013 by The EH Angle Education and Research Foundation, Inc.



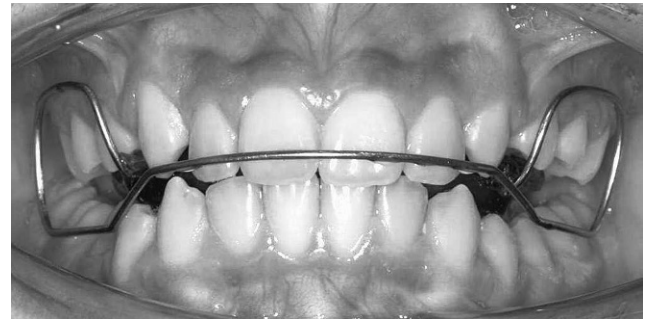**Figure 1.** Standard or Class II Balters bionator.

complex skeletal structures, affording reliable graphic and mathematical representations.<sup>6</sup> TPS does not require any reference or superimposition planes. This morphometric analysis quantitatively evaluates changes in shape, expressing the differences between the configurations of two reference points as a continuous deformation. It also allows the construction of transformation grids that capture differences in form, enabling a more effective visual interpretation.<sup>6,7</sup> Thus, TPS allows precise viewing of the set of changes occurring in facial skeletal structures. These morphometric methods can shed light on the skeletal effects arising from the use of orthopedic appliances in the treatment of malocclusions.<sup>8–11</sup> Among different therapies available to treat Class II malocclusion, the Balters bionator is a functional appliance designed and introduced by Wilhelm Balters in the 1960s.<sup>12,13</sup> The bionator moves the mandible anteriorly so that over time a new postural position of the lower arch is achieved, improving the maxillomandibular relationship.<sup>12–16</sup> While short-term and long-term effects of the bionator appliance on Class II division 1 malocclusion have been previously investigated,<sup>16–18</sup> the CCA methods used in those studies do not allow understanding of the changes in mandibular morphology (shape) that occur with bionator therapy.

The aim of this study, therefore, was to investigate the effects of the standard (Class II) Balters bionator in the treatment of patients with Class II malocclusion with mandibular retrusion using TPS analysis.

## MATERIALS AND METHODS

The cephalometric records of 31 white patients (17 male and 14 female) with Class II malocclusion with mandibular retrusion consecutively treated with the Balters bionator (Figures 1 and 2) (bionator group, BG) were collected from a single orthodontic practice. All



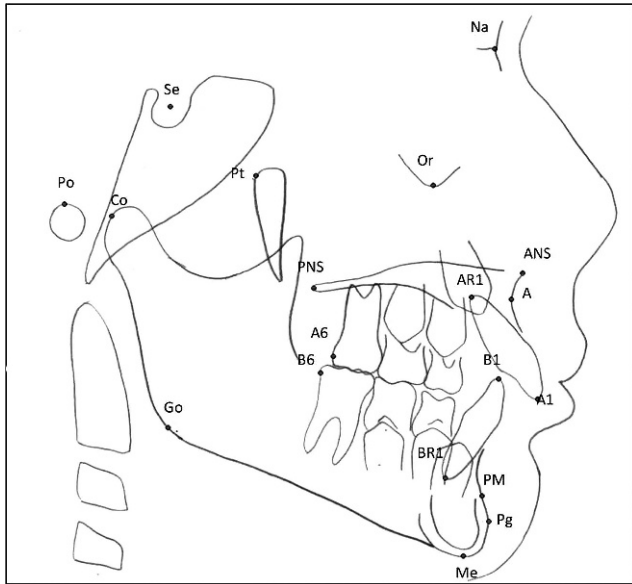
**Figure 2.** Bionator in the oral cavity.

subjects were either in mixed dentition or in early permanent dentition. Inclusion criteria for the sample in this group were based on the following factors: individuals with a diagnosis of Class II malocclusion with mandibular retrusion determined by cephalometric analysis of Ricketts et al.<sup>19</sup> and Schwarz, modified by Faltin et al.,<sup>20</sup> and orthopedic therapy performed exclusively with the standard (Class II) Balters bionator (without coverage of the lower incisors). Lateral cephalograms were available at the start of treatment (T0, mean age 10.3 years  $\pm$  1.2 years) and at the end of treatment with the functional appliance (T1, 13 years  $\pm$  2.1 years). Mean treatment time was 2 years and 2 months. Patient compliance and treatment success were not considered as inclusion criteria so that sample selection was conducted irrespective of clinical results.

The control group (CG) was collected from the same private practice and consisted of 22 white subjects (14 male and 8 female) with untreated Class II division 1 malocclusions. Significant effort was directed toward matching the CG to the BG as closely as possible with respect to dentoskeletal features (Class II with mandibular retrusion) at T0, age at all observation periods, and duration of observation interval (T0–T1). Two lateral cephalograms were available for the subjects of the CG: one at T0 (mean age 10.2 years  $\pm$  1.7 years) and one at T1 (mean age 12.2 years  $\pm$  1.6 years). The observation period lasted an average of 24 months  $\pm$  4 months. Treatment in these subjects was performed at a later time.

All treated and control subjects were either in CS2 or CS3 in cervical vertebral maturation at T0 and in either CS3 or CS4 at T1.<sup>21</sup> Institutional review board approval was obtained before the study (416/10/CEP/ICS/UNIP).

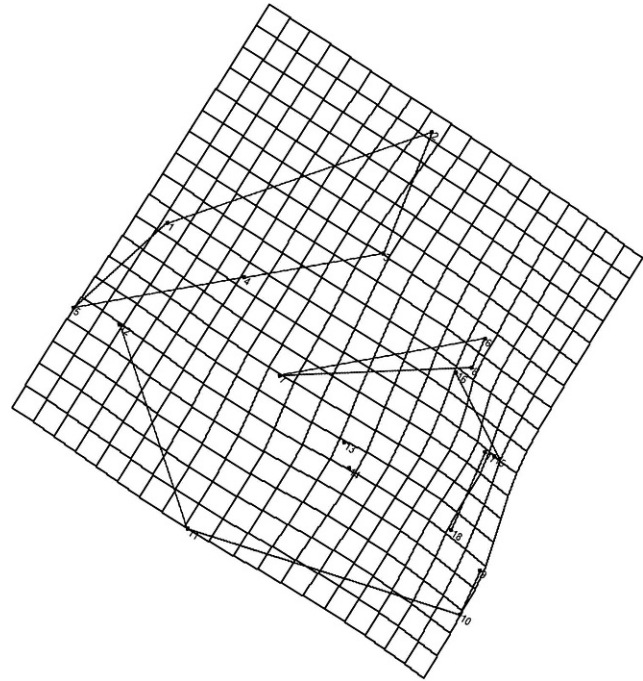
The following homologous landmarks were digitized on the lateral films using TPS software (tpsDig2 version 2.16, Ecology & Evolution, SUNY, Stony Brook, NY): point Na (nasion), point Se (sella turcica), point Po (porion), point Co (center of the condyle), point Pt (superior pterygoid point), point Or (orbitale), point ANS (anterior nasal spine), point PNS (posterior nasal



**Figure 3.** Landmarks used for morphometric analysis.

spine), point A (A), point A1 (incisal of upper central incisor), point B1 (incisal of lower central incisor), point AR1 (apex of the root of the upper central incisor), point BR1 (apex of the root of the lower central incisor), point Pm (protuberance menti), point Pg (pogonion), point Go (gonion), point A6 (distal upper first molar superior), point B6 (distal lower first molar), and point Me (menton) (Figure 3). TPS software (tpsRegr version 1.38, Ecology & Evolution) computed the orthogonal least-squares Procrustes average configuration of craniofacial landmarks in both the BG and CG at T0 and T1, using the generalized orthogonal least-squares procedures described by Rohlf and Slice.<sup>22</sup> This is a superimposition method where shapes defined by the configuration of anatomic homologous landmarks are compared through various optimization criteria. It involves translation (centralization of anatomic landmark configuration), rotation (rotation of all landmark configurations to minimize the distance between them), and scaling (standardization of landmark configuration based on the centroid size). Superimposition parameters are determined so as to minimize the sum of squares of distances between points in each configuration and their corresponding reference points. Any sample specimen or mean sample configuration (consensus) can act as reference. For each anatomic landmark, the Procrustes residual is the difference between the position of the specimens' anatomic landmarks and the position of the homologous anatomic landmark in the consensus. The matrix of Procrustes residuals can be used for any statistical procedure.<sup>8,22</sup>

Statistical analysis of shape differences was performed by means of permutation tests with 1000



**Figure 4.** TPS graphical display of shape differences between T0 and T1 in the bionator group (magnification factor 3 $\times$ ).

random permutations on Goodall F statistics (tpsRegr version 1.38, Ecology & Evolution).

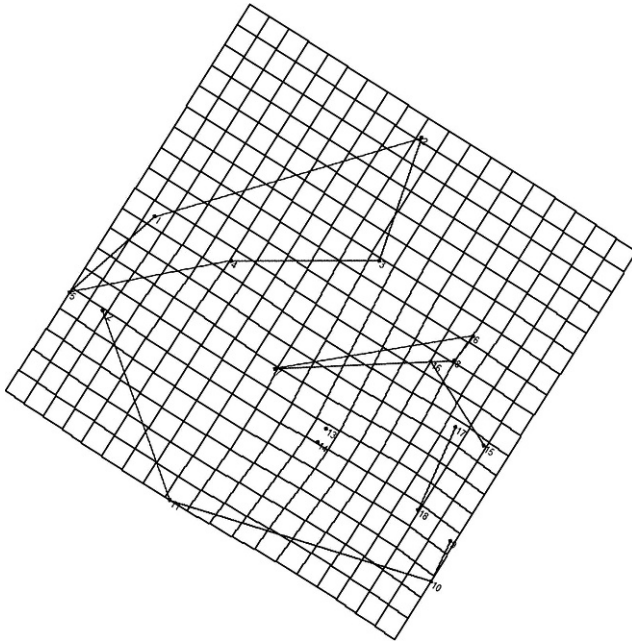
Differences in size (centroid size analysis) at the two developmental phases (T0 through T1) were tested by means of Mann-Whitney *U*-test for longitudinal comparisons. For those comparisons showing significant shape differences, a test for allometry, checking for shape depending on size, was carried out (tpsRegr version 1.38, Ecology & Evolution).

Intraobserver precision was calculated on distances between landmark positions between the first tracing and the second tracing (1 month after the initial one) in all cephalograms in both groups at T0 and T1 by the same operator, using Dahlberg formula.<sup>23</sup> The average method error for landmark identification was 1.2 mm (SD = 0.3).

## RESULTS

No significant shape differences were found between the BG and CG at T0 ( $P = .571$ ). The results from centroid size analysis did not reveal any significant difference in size difference between the BG and CG at T0 ( $P = .125$ ). At T1 significant shape ( $P = .001$ ) and size differences ( $P = .0009$ ) were found between the BG and CG.

The analysis of longitudinal dentoskeletal shape changes in the BG showed significant T0–T1 differences ( $P = .001$ ; Figure 4). This difference could be described graphically by a marked extension in the horizontal axis in the region of the mandibular



**Figure 5.** TPS graphical display of shape differences between T0 and T1 in the control group (magnification factor 3 $\times$ ).

symphysis and in the middle portion of the mandible between the condyle and the symphysis. A slight extension on both the horizontal and vertical axes could be recorded at the gonial angle. A constriction on the horizontal axis in the region of the upper incisors was also evident. The results from centroid size analysis showed significant size differences from T0 to T1 in the BG ( $P = .0001$ ). Allometry was significant for the bionator sample ( $F = 1.59$ ;  $P = .02$ ), thus indicating dependence of size differences on shape differences in the treated group.

In the CG no significant shape differences could be detected ( $P = .098$ ; Figure 5). Centroid size longitudinal analysis showed statistically significant size differences from T0 to T1 in the CG ( $P = .021$ ).

## DISCUSSION

Many studies that investigated the dentoskeletal effects produced by the bionator appliance in patients with Class II, division 1 malocclusion,<sup>16-18</sup> but they all used CCA. CCA cannot analyze adequately the shape detail demonstrated by the cephalogram, and, therefore, it is not capable of fully evaluating craniofacial form (size + shape).<sup>3-5</sup> The univariate analysis of linear measurements mostly reflect variation of size rather than shape. Angles are size independent, but they cover large aspects of the craniofacial complex, failing to describe the information within the included angle.<sup>5</sup> Geometric morphometric analysis (eg, elliptic Fourier analysis, finite element analysis, Euclidean distance matrix analysis, tensor and shape coordinate

analysis) has been used as an alternative method to overcome the analytical limitations of conventional cephalometry.<sup>5,9,10</sup> No previous investigation evaluated the shape changes produced by the Balters bionator by means of geometric morphometric analyses. Geometric morphometric methods are being developed to measure changes in biological size and shape caused by growth and orthopedic treatment. Among these methods, TPS was introduced by Bookstein<sup>6</sup> in 1989. It enables easy, comprehensible viewing of changes in shape while clearly highlighting the region where these changes occur. TPS analysis expresses the difference between two average landmark configurations through transformation grids and continuously models the deformation of a given shape into another using a regression function. It also allows performing statistical analysis of the shape change.

The present study compared the shape and size differences in a Class II sample treated with the bionator vs an untreated Class II control group by using TPS and centroid size analyses. The bionator induced significant shape changes in the mandible that could be described as a mandibular forward and downward displacement. This mandibular displacement was more evident at the mandibular symphysis as it was associated with a mandibular elongation that was depicted by a horizontal extension of the grid in the middle portion of the mandible between the condyle and the symphysis. These changes contributed significantly to the sagittal and vertical correction of the dentoskeletal Class II relationships. The results of the current study differ from those reported by Lux et al.,<sup>9</sup> who, using TPS, found small vertical and anteroposterior skeletal mandibular displacement in the activator compared with control group. Lux et al.<sup>9</sup> found that the correction of the Class II problem was sustained mainly by a strong dentoalveolar component with retroclination of the upper incisors and proclination of the lower incisors. As in Lux et al.,<sup>9</sup> a constriction in the region of the upper incisors indicating a retroclination of these teeth was found. However, it should be emphasized that in the standard Balters bionator used in our study, the buccal shield does not touch the upper incisors and does not have inferior incisal coverage which can play a role in dental compensation rather than orthopedic correction. The dentoalveolar compensation in the BG was probably related to a new neuromuscular pattern (lip closure and improvement of tongue position) induced by the appliance.<sup>24</sup> In the current investigation, allometry (shape depending on size differences) was significant for the BG and no significant shape change could be recorded in the CG. Consequently, no significant improvement in the dentoskeletal Class II relationships was evident in the CG.

Our results are in agreement with McNamara et al.<sup>25</sup> who studied the treatment effects of the Fränkel appliance (the only other nontooth supported functional orthopedic appliance) for about 24 months. They compared their results with matched untreated Class II malocclusions using both conventional and geometric cephalometric analyses (tensor analysis). This study found that the advancement of the mandible along the direction of the facial axis resulted in increases in mandibular length and in vertical facial dimensions with minimal anterior tipping of the lower incisor and significant posterior tipping of the upper incisor. Cevidanes et al.<sup>26</sup> used high-resolution magnetic resonance images to compare 3-dimensional (3D) growth vectors of skeletal displacement and bone remodeling in 25 untreated subjects with Class II malocclusions, 28 subjects with Class II malocclusions who were treated with Fränkel appliance therapy, and 25 subjects with normal occlusions. Three-dimensional geometric morphometrics revealed that Fränkel appliance therapy at the beginning of the adolescent growth spurt produced significantly more forward and vertically increased rami in the treated group than in the control group. Cevidanes et al.<sup>26</sup> concluded that the relatively small magnitude of the 3D growth vectors might explain why they are often missed with conventional cephalometrics.

TPS analysis showed that treatment with the bionator is able to produce favorable mandibular shape changes that contribute significantly to the correction of the Class II dentoskeletal imbalance reported in previous studies.<sup>16–18</sup> Long-term studies are needed to determine the extents to which these mandibular shape changes are maintained and their influence on facial esthetics.

## CONCLUSIONS

- Treatment with the bionator is able to produce significant shape changes that are characterized by a forward and downward displacement of the mandible associated with mandibular elongation. These shape changes contributed significantly to the dentoskeletal correction of the Class II dentoskeletal imbalance.
- These findings confirm the effectiveness of functional jaw orthopedics in the treatment of patients with Class II malocclusion associated with mandibular retrusion.

## REFERENCES

1. Broadbent BH. A new x-ray technique and its applications to orthodontia. *Angle Orthod.* 1931;1:45–66.
2. Hofrath H. Bedeutung der Röntgenfern und Abstandsaufnahme für die Diagnostik der Kieferanomalien. *Fortschr Orthod.* 1931;1:232–258.
3. Moyers RE, Bookstein FL. The inappropriateness of conventional cephalometrics. *Am J Orthod.* 1979;75:599–617.
4. Bookstein FL. On the cephalometrics of skeletal change. *Am J Orthod.* 1982;82:177–182.
5. McIntyre GT, Mossey PA. Size and shape measurement in contemporary cephalometrics. *Eur J Orthod.* 2003;25:231–242.
6. Bookstein FL. *Morphometrics Tools for Landmark Data.* New York, NY: Cambridge University Press; 1991.
7. Franchi L, Baccetti T, McNamara JA Jr. Thin-plate spline analysis of mandibular growth. *Angle Orthod.* 2001;71:83–89.
8. Franchi L, Baccetti T, Stahl F, McNamara JA Jr. Thin-plate spline analysis of craniofacial growth in Class I and Class II subjects. *Angle Orthod.* 2007;77:595–601.
9. Lux JC, Ru J, Starke J, Conrad C, Stellzig A, Komposch G. Effects of early activator treatment in patients with Class II malocclusion evaluated by thin-plate spline analysis. *Angle Orthod.* 2001;71:120–126.
10. Singh GD, Hodge MR. Bimaxillary morphometry of patients with class II division 1 malocclusion treated with twin block appliances. *Angle Orthod.* 2002;72:402–409.
11. Baccetti T, De Clerck HJ, Cevidanes LH, Franchi L. Morphometric analysis of treatment effects of bone-anchored maxillary protraction in growing Class III patients. *Eur J Orthod.* 2011;33:121–125.
12. Balters W. Extrait de technique du Bionator. *Rev Franc Odontostomat.* 1964;11:191–212.
13. Balters W. *Guía de la Técnica del Bionator.* Buenos Aires, Argentina: Editorial Mundi; 1969:68.
14. Carels C, Reyckler A, Van Der Linden FP. Cephalometric evaluation of dento-skeletal changes during treatment with the Bionator type 1. *J Oral Rehabil.* 1997;24:841–848.
15. Celestin LA. *Thérapeutique Fonctionnelle d'Orthopédie Dento-Faciale: La Méthode Bionator du Professeur Wilhelm Balters.* Paris, France: Maloine; 1967:116.
16. Faltin K Jr, Faltin RM, Baccetti T, Franchi L, Ghiozzi B, McNamara JA Jr. Long-term effectiveness and treatment timing for Bionator therapy. *Angle Orthod.* 2003;73:221–230.
17. Malta LA, Baccetti T, Franchi L, Faltin K Jr, McNamara JA Jr. Long-term dentoskeletal effects and facial profile changes induced by bionator therapy. *Angle Orthod.* 2010;80:10–17.
18. Cozza P, Baccetti T, Franchi L, De Toffol L, McNamara JA Jr. Mandibular changes produced by functional appliances in Class II malocclusion: a systematic review. *Am J Orthod Dentofacial Orthop.* 2006;129:599.e1–599.e12.
19. Ricketts RM, Roth RH, Chaconas SJ. *Orthodontic Diagnosis and Planning: Their Roles in Preventive and Rehabilitative Dentistry.* Vol 1. Denver, CO: Rocky Mountain Data Systems; 1982.
20. Faltin K Jr, Machado CR, Rebecchi MCVC. Valores médios da análise cefalométrica de Schwarz-Faltin para jovens brasileiros, leucodermas com oclusão normal. *Rev Soc Paran Ortodon.* 1997;1:31–42.
21. Baccetti T, Franchi L, McNamara JA Jr. The cervical vertebral maturation (CVM) method for the assessment of optimal treatment timing in dentofacial orthopedics. *Semin Orthod.* 2005;11:119–129.
22. Rohlf FJ, Slice DE. Extensions of the Procrustes method for the optimal superimposition of landmarks. *Systematic Zool.* 1990;39:40–59.
23. Dahlberg AG. *Statistical Methods for Medical and Biological Students.* London, UK: Bradford and Dickens; 1940.
24. Stavridi R, Ahlgren J. Muscle response to the oral-screen activator. An EMG study of the masseter, buccinator, and mentalis muscles. *Eur J Orthod.* 1992;14:339–349.
25. McNamara JA Jr, Bookstein FL, Shaughnessy TG. Skeletal and dental changes following functional regulator therapy on Class II patients. *Am J Orthod.* 1985;88:91–110.
26. Cevidanes LH, Franco AA, Gerig G, et al. Comparison of relative mandibular growth vectors with high-resolution 3-dimensional imaging. *Am J Orthod Dentofacial Orthop.* 2005;128:27–34.