

Muscle shortening manoeuvre reduces pain and functional impairment in shoulder impingement syndrome: clinical and ultrasonographic evidence

D. Melchiorre¹, M. Maresca¹, R. Bracci², A. Ravaschio², B. Valiensi², R. Casale³, F. Bandinelli¹, A. Candelieri⁴, S. Maddali Bongi¹, F. Porta¹, M. Innocenti⁵, C. Carulli⁵, M. Matucci-Cerinic¹

¹Department of Clinical and Experimental Medicine, Division of Rheumatology, University of Florence, Italy; ²ASL 2, Neurological Rehabilitation Service, Lucca, Italy;

³Department of Clinical Neurophysiology, Salvatore Maugeri Foundation, Montescano, Pavia, Italy;

⁴Laboratory of Decision Engineering for Health Care Delivery, Department of Electronics, Informatics and Systems, University of Calabria, Cosenza, Italy;

⁵Department of Traumatology and Orthopaedics, University of Florence, Italy.

Abstract

Objective

To evaluate the short-term efficacy of muscle shortening manoeuvre (MSM), by inducing an increase in strength of the shoulder muscles, for the treatment of shoulder impingement syndrome (SIS).

Methods

Sixty subjects (mean age: 58.6 years) with SIS were assigned to one of 3 different treatment interventions:

- 1) MSM: a series of fast accelerations in the upward direction was applied to the upper limb that was also submitted to forces acting in the opposite direction (added mass);
- 2) traditional physiotherapeutic technique: scapulothoracic gliding;
- 3) simple traction: the added mass was applied to the limb without the series of fast accelerations.

Pain intensity, Neer's impingement sign, range of motion and muscle strength were assessed. Ultrasound (US) examination was performed before, immediately after and 30 days after each treatment to study the width of the subacromial-subdeltoid bursa, long biceps tendon sheath and acromioclavicular joint. Impingement was evaluated by dynamic examination.

Results

After treatment with MSM, pain was significantly reduced ($p < 0.001$), Neer's impingement sign was negative, range of motion and muscle strength were increased. US examination showed that the widths of the subacromial-subdeltoid bursa ($p < 0.001$), long biceps tendon sheath ($p < 0.001$) and acromioclavicular joint ($p < 0.001$) were significantly reduced; impingement was no more detected. After 30 days, improvement in clinical and US findings was maintained.

In the two control groups, no significant changes were observed after treatment.

Conclusion

Clinical and US findings demonstrate that MSM, by inducing an increase in muscle strength, is effective in the short-term treatment of SIS.

Key words

shoulder impingement syndrome, ultrasonography, physical therapy.

Daniela Melchiorre, MD
Marco Maresca, MD
Riccardo Bracci, PhD
Andrea Ravaschio, MD
Bruno Valiensi, MD
Roberto Casale, MD
Francesca Bandinelli, MD
Antonio Candelieri, PhD
Susanna Maddali Bonghi, MD
Francesco Porta, MD
Massimo Innocenti, MD
Christian Carulli, MD
Marco Matucci-Cerinic, MD

Please address correspondence to:
Daniela Melchiorre, MD,
Dipartimento di Medicina Interna,
Sezione di Reumatologia,
Università degli Studi di Firenze,
Viale Pieraccini 18,
50139 Firenze, Italy.
E-mail: daniela.melchiorre@unifi.it

Received on January 16, 2013; accepted
in revised form on June 26, 2013.

© Copyright CLINICAL AND
EXPERIMENTAL RHEUMATOLOGY 2013.

Introduction

Shoulder impingement syndrome (SIS) is a term commonly used to define a syndrome characterised by pain and functional impairment of the shoulder, caused by the impingement of the rotator cuff tendons and subacromial-subdeltoid bursa (SSB) against the coracoacromial arc (1-3). It must be noted that different types of shoulder impingement have been described (4, 5) and, according to Braman *et al.* (5) the term 'shoulder impingement syndrome' should be discontinued; however, the term is still currently used to describe shoulder pain related to subacromial impingement.

As Harrison and Flatow (6) recently observed, SIS represents a spectrum of pathology ranging from subacromial bursitis to rotator cuff tendinopathy and full-thickness rotator cuff tears. The diagnosis of SIS is based on clinical and instrumental findings. The several aspects covered by the concept of impingement syndrome cannot be reliably defined by clinical signs alone. The current availability of sonography, magnetic resonance imaging, and arthroscopy now enables these conditions to be accurately differentiated, as observed by Papadonikolakis *et al.* (7). The treatment of SIS is still the object of discussion. Surgical subacromial decompression is performed to remove the cause of the impingement. Physiotherapy is also widely used. In a recent study, Haar *et al.* (8) observed that the arthroscopic subacromial decompression did not obtain better results than physiotherapy.

It has been suggested that SIS may be a consequence of an unbalanced action of shoulder muscles with loss of central position of the humeral head (2, 3, 6). Muscle unbalance may be removed by muscle shortening manoeuvre (MSM) (9, 10) which is therefore a potential therapeutic application in SIS. The manoeuvre is a physiotherapeutic technique which induces an increase of muscle strength. When applied to the shoulder, this manoeuvre mainly increases serratus anterior muscle strength, stabilising and balancing the joint with pain relief. This hypothesis is supported by the findings of Slemenda *et al.* (11) who demonstrated the impor-

tance of muscle weakness with unbalanced muscle action as a cause of pain in osteoarthritis of knee.

The aim of the present study was to evaluate the short-term effect of MSM in the treatment of SIS. Pain and other clinical aspects of the syndrome were considered. Ultrasound (US) examination was also performed before and after the manoeuvre (12-19).

Subjects and methods

Sixty SIS patients [36 men and 24 women, with mean age 58.6 (range 34–86) years] were consecutively enrolled. The study protocol was approved by the local ethics committee and all the patients signed an informed consent. Patients were included in the study if they fulfilled the following diagnostic criteria: chronic (>6 months) shoulder pain, pain provoked by abduction of shoulder with painful arc, and positive Neer's impingement sign (1, 5, 6). Exclusion criteria were: a history of acute trauma, previous surgery or previous rupture of tendons of supraspinatus, subscapularis or long biceps tendon, neck pain, shoulder instability, osteoarthritis of glenohumeral joint, and tendon calcification (8, 14, 15).

The enrolled patients were consecutively assigned to 3 treatment groups: 1) MSM was performed in 20 subjects; 2) other 20 subjects were included in a first control group (traditional physiotherapeutic technique, *i.e.* scapulothoracic gliding), 3) 20 subjects were included in a second control group (simple traction). Pain, Neer's impingement sign, range of motion (ROM) and muscle strength were evaluated in every subject by an observer (MM) before the therapeutic cycle, immediately after treatment and 30 days after treatment. Pain intensity was assessed by a visual analogue scale and was measured in range 0–10 cm. ROM was evaluated during intra and extra rotation of the shoulder with patient sitting. The value of ROM was considered reduced when <45°. Muscle strength was measured manually and graded according to the Medical Research Council (MRC) score (range 0–5 per muscle when 4-5 is considered normal) (20). US examination was performed by a different observer (DM)

Competing interests: none declared.

blinded to the results of clinical evaluation. Both observers were also blinded for the type of treatment used in every patient.

Ultrasound exam

US examination was performed in all patients with equipment Logiq 520 (General Electric with a linear probe 8.5–12 MHz). The intraobserver ($\kappa=0.97$) agreement was assessed. The following structures were examined: supraspinatus tendon (ST), SSB, acromioclavicular joint (ACJ) and long biceps tendon (LBT) (12). ST and SSB were examined with the subject's shoulder in internal rotation to expose ST from underneath the acromion and to detect the width of SSB that when normal does not contain fluid (16, 17). LBT and ACJ were examined with the patient seated, the arm held in neutral position, the elbow flexed to 90°, and the forearm in a supinated position on the thigh. Transverse and longitudinal planes from LBT were scanned. A transverse scan of ST, SSB and ACJ was performed. The width of SSB, in transverse scan (normal value ≤ 2 mm) (17), ACJ, in coronal scan, and LBT in longitudinal scan was measured in mm. In all patients, the contralateral shoulder was examined to compare US findings (17, 18). ACJ was examined because this joint is part of the coracoacromial arc and LBT was examined to evaluate whether its involvement could play a role in functional impairment.

SIS was evaluated by dynamic examination. A dynamic view of ST was obtained by moving the subject's arm from a neutral position to 90° abduction to detect encroachment of the acromion into the rotator cuff. Then, the probe was moved laterally to scan the rotator cuff. The supraspinatus and infraspinatus tendons were examined with the subject's shoulder in hyperextension and internal rotation to expose the supraspinatus from underneath the acromion. This position allowed the maximal visualisation of the length of tendons (19).

Muscle Shortening Manoeuvre (MSM)

This manoeuvre introduced by Grimaldi *et al.* (9, 10) is derived from Feld-

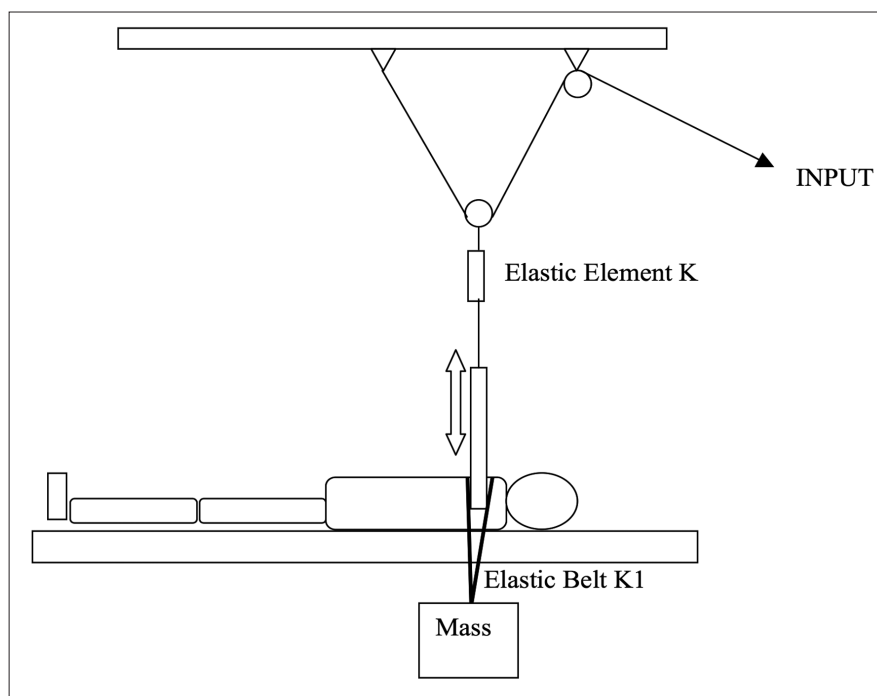


Fig. 1. Schematic diagram of muscle shortening manoeuvre (MSM): the subject is lying supine. The upper limb is extended connected to an elastic system. A weight of twelve kilograms is applied on the shoulder by an elastic belt.

man's model of motor control (21, 22). In MSM a series of fast accelerations is applied to the upper limb in the upward direction while the limb is also subjected to forces acting in the opposite direction (added mass) (9, 10, 21, 22). The manoeuvre provokes a dynamic lengthening associated with sudden shortening of the muscles responsible for protraction and retraction of the shoulder girdle.

Each subject was lying supine and the upper limb was lifted with the elbow extended. Thus, the shoulder extended slightly off the edge of the bed (Fig. 1). The subject's hand (fist closed) was connected to a spring (elastic element *K*, Fig. 1) through a metal plate equipped with a ring and connected to a pulley system (Fig. 1). For all subjects a weight of 12 kg was applied using an elastic belt positioned around the subject's shoulder (elastic belt *K1*, Fig. 1). A physiotherapist acting on the rope (Input, Fig. 1) induced oscillations of the system provoking excursions of 6 cm along the main axis of the arm with a frequency of 2 Hz. The manoeuvre lasted ten minutes. In every subject the manoeuvre was performed only once. MSM is not painful.

Control groups

The findings observed before and after MSM were compared with the findings observed in the control groups. The twenty subjects of the first control group were treated with a traditional physiotherapeutic technique, (*i.e.* scapulothoracic gliding with passive mobilization of the scapula). Each subject was lying on one side; a physiotherapist standing on the subject's ventral side placed one hand on the superior aspect of the acromion, while the other hand was placed upon the inferior angle of the scapula. Movements of the scapula were induced (protraction, retraction, upward and downward rotation). Each exercise session lasted 20 minutes and ten sessions were performed in a period of 4 weeks. In the twenty subjects of the second control group a simple traction was applied. In each subject, lying supine with the upper limb lifted and the elbow extended, the added mass of 12 kg was applied to the limb for ten minutes, without the series of fast accelerations. This procedure was chosen because it is similar to MSM. Every subject was treated only once. Systemic or topic pharmacological therapy with analgesic or anti-inflam-

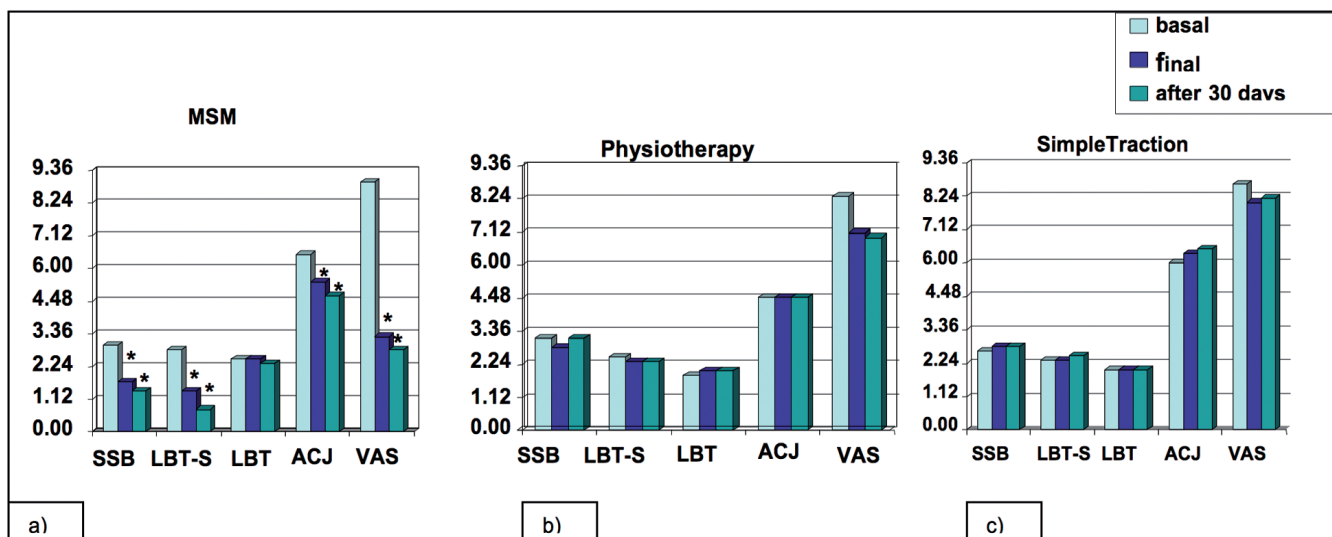


Fig. 2. Comparison of mean values of US findings (values in mm) and of pain intensity (values in cm) at baseline, at the end of treatment and 30 days after the end of treatment in the three groups, as shown by colour columns.

a) MSM: muscle shortening manoeuvre; SSB: subacromial-subdeltoid bursa; LBT- S: long biceps tendon sheath; LBT: long biceps tendon; ACJ: acromioclavicular joint; VAS: pain intensity (visual analogue scale); b) Physiotherapy; c) Simple traction. The asterisk (*) indicates statistical significance: $p < 0.001$.

matory steroidal or non steroidal drugs had been withdrawn in all the patients of the three groups at least 5 days before treatment. No patient took the above mentioned drugs until the evaluation performed 30 days after treatment.

Statistical analysis

One way ANOVA for independent samples was used. The probability (p) values of less than 0.05 were considered significant. Sonographic findings, pain intensity and MRC score values observed before and after the manoeuvre were compared.

Results

In all patients, at baseline Neer's impingement sign was positive and ROM was $<45^\circ$; the mean value (m.v.) of MRC score was 2.48 (SD ± 0.57) and m.v. of pain intensity was 8.41 (SD ± 0.97). The following US findings were observed: increased width of SSB, enlargement of LBT sheath, increased width of ACJ and occurrence of encroachment of the acromion into the rotator cuff.

In the three groups, no drop-out was observed and no side effects were reported.

In patients treated by MSM, immediately after the manoeuvre Neer's impingement sign was negative, ROM was $>45^\circ$, m.v. of MRC score was 4.3 (SD ± 0.47) and, m.v. of pain in-

tensity was 3.3 (SD ± 1.17). The m.v. of width of SSB, ACJ and LBT sheath evaluated by US was significantly reduced in comparison with the m.v. at baseline (Fig. 2) The encroachment of the acromion into the rotator cuff was not detectable by US. Thirty days later, Neer's impingement sign was still negative, ROM, MRC score and pain intensity were not modified; the m.v. of width of SSB, ACJ and LBT sheath was still reduced (Fig. 2), encroachment of acromion into the rotator cuff was still not detectable by US.

At the end of treatment and 30 days later, in patients treated with traditional physiotherapy Neer's impingement sign was still positive, ROM was still $<45^\circ$, MRC score and pain intensity values were not changed in comparison with the baseline value; the m.v. of width of SSB, ACJ and LBT sheath evaluated by US was not significantly different from baseline (Fig. 2), The encroachment of the acromion into the rotator cuff was still evident in all patients immediately after the end of treatment, while after 30 days it was not detectable in 7/ 20 patients only.

In patients treated with a simple traction, at the end of treatment and after 30 days, Neer's impingement sign was still positive, ROM was still $<45^\circ$, MRC score and pain intensity values were not changed in comparison with

the baseline values, the m.v. of width of SSB, ACJ and LBT sheath evaluated by US was not significantly different from baseline (Fig. 2), encroachment of the acromion into the rotator cuff was still detected.

In Fig. 2, mean values of US findings and of pain intensity in the three groups are reported. The statistical analysis showed: a significant difference of SSB, LBT sheath, ACJ and pain intensity values only in MSM group ($p < 0.001$).

In Fig. 3, the US images of SSB and ACJ in patients treated by MSM are shown.

Discussion

The treatment of SIS usually includes surgery and physiotherapy with or without local drug injections (23, 24). Surgery has been claimed to be able to solve the problem of SIS but no works validating this approach can be found in the literature. Haahr *et al.* (8) observed better results in patients treated with physiotherapy than in patients treated with surgery. The invasiveness of surgery and the frequent relapse of SIS, along with better results obtained with conservative treatment, do not allow to consider surgery as a first line treatment.

MSM has been used in different neurological and orthopaedic diseases obtaining a rapid recovery of muscle function

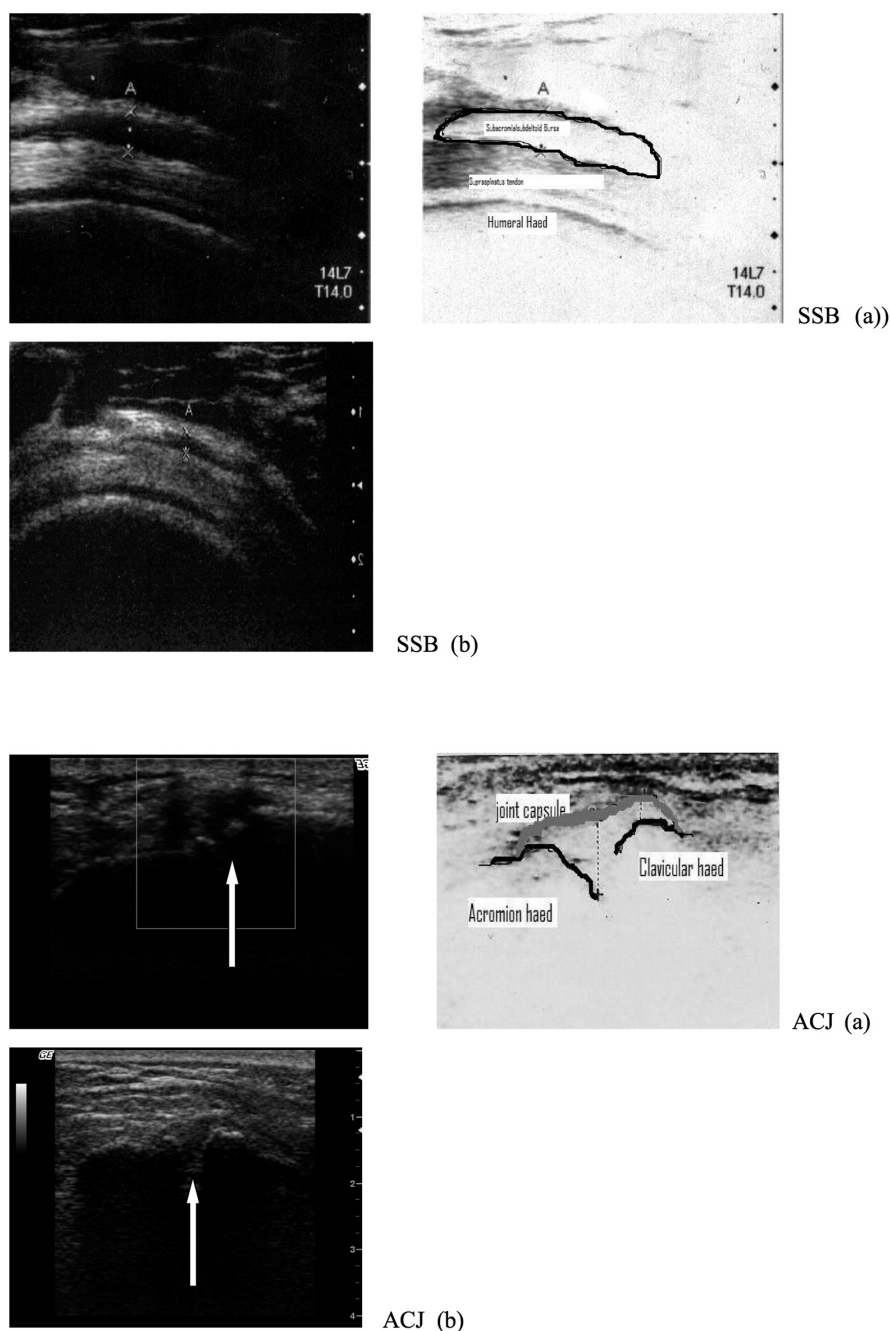


Fig. 3. SSB (Subacromial Subdeltoid Bursa): transverse sonogram before (a) and after (b) Muscle Shortening Manoeuvre (MSM). In (a) SSB width is increased (2,7 mm) as shown by calipers (normal value ≤ 2 mm) as indicated in the drawing; in (b) a marked decrease of SSB width is evident (width: 1,3 mm) as shown by calipers.

ACJ (Acromioclavicular Joint): coronal sonogram before (a) and after (b) MSM (the white arrows indicate the joint). In (a) the joint capsule is distended by fluid as indicated in the drawing. In (b) the distension of the joint capsule is no more detectable.

(9, 10). The effect of MSM may be explained by considering that it increases muscle strength without morphological changes (*i.e.* muscle hypertrophy) but with neural adaptations (25-27). It has been also suggested that muscle weakness with unbalanced muscle action may be a cause of pain (11).

In fact, pain relief obtained in our patients confirms that MSM, inducing a recovery of muscle strength, relieves pain together with a prompt recovery of ROM and increase of MRC score values. The changes of US findings immediately after MSM, with reduction of SSB, LBT sheath and ACJ and with

the lack of encroachment of acromion into rotator cuff, confirm the clinical efficacy of MSM. This effect was still evident 30 days after the manoeuvre. Improvement was not seen in both control groups. As regards simple traction, we did not expect different results. The results of the traditional physiotherapy were not indicative of improvement at short time both for pain relief and for recovery of muscle strength. The results obtained by MSM showed pain relief and recovery of muscle strength immediately after the manoeuvre and after thirty days. It may be deduced that MSM has a different action, if compared with traditional physiotherapy. MSM acts mainly on the serratus anterior muscle which provokes internal rotation of the shoulder by an action on scapulo-thoracic joint and abduction of the scapula. In the present study all patients treated with MSM showed ROM $>45^\circ$ indicating a great functional improvement and demonstrating the efficacy of the treatment. Moreover, the manoeuvre, inducing a fast recovery of muscle strength, achieves pain relief in a very short time. The neuromuscular reassessment due to the manoeuvre induces a stabilisation of the shoulder function.

In conclusion, our results show that MSM is a simple, not invasive and efficient approach for mild SIS without tendon degeneration or rupture. This manoeuvre allows a rapid relief of pain with a persistent functional reset and improvement of US findings, avoiding injections of steroids or more invasive surgical procedures. Further studies are however warranted to investigate the long term efficacy of MSM.

References

1. NEER CS: Impingement lesions. *Clin Orthop Relat Res* 1983; 173: 71-7.
2. VAN DER WINDT DA, KOES BW, DE JONG BA, BOUTER LM: Shoulder disorders in general practice: incidence, patient characteristics, and management. *Ann Rheum Dis* 1995; 54: 959-64.
3. BROX JI: Shoulder pain. *Best Pract Res Clin Rheumatol* 2003; 17: 33-56.
4. BELTRAN LS, NIKAC V, BELTRAN J: Internal impingement syndromes. *Magn Res Imaging Clin N Am* 2012; 20: 201-11.
5. BRAMAN JP, ZHAO KD, LAWRENCE RL, HARRISON AK, LUDEWIG PM: Shoulder impingement revisited: evolution of diag-

- nostic understanding in orthopaedic surgery and physical therapy. *Med Biol Eng Comput* 2013; Apr 10.
6. HARRISON AK, FLATOW EL: Subacromial impingement syndrome. *J Am Med Orthop Surg* 2011; 19: 701-8.
 7. PAPADONIKOLAKIS A, MCKENNA M, WARME W, MARTIN BI, MATSEN FA: Published evidence relevant to the diagnosis of impingement syndrome of the shoulder. *J Bone Joint Surg Am* 2011; 93: 1827-32.
 8. HAAHR JP, OSTERGAARD S, DALSGAARD J *et al.*: Exercises versus arthroscopic decompression in patients with subacromial impingement: a randomized, controlled study in 90 cases with a one year follow up. *Ann Rheum Dis* 2005; 64: 760-4.
 9. GRIMALDI L, LIPPI P, MARRI P, FANTOZZI M, BRACCI R: Evoking of absent motor components in CNS lesions. Pisa, Editori Giardini, 1986-88.
 10. CRIPPA A, CARDINI R, PELLEGATTA D, MANZONI S, CATTANEO D, MAGAZZINI F: Effect of sudden, passive muscle shortening according to Grimaldi's method on patients suffering from multiple sclerosis: a randomized controlled trial. *Neurorehabil Neural Repair* 2004; 18: 47-52.
 11. SLEMENDA C, BRANDT KD, HEILMAN DK *et al.*: Quadriceps weakness and osteoarthritis of the knee. *Ann Int Med* 1997; 127: 97-104.
 12. IAGNOCCO A, FILIPPUCCI E, SAKELLARIOU G *et al.*: Ultrasound imaging for the rheumatologist XLIV. Ultrasound of the shoulder in healthy individuals. *Clin Exp Rheumatol* 2013; 31: 165-71.
 13. AWERBUCH MS: The clinical utility of ultrasonography for rotator cuff disease, shoulder impingement syndrome and subacromial bursitis. *Med J Aust* 2008; 188: 50-3.
 14. NAREDO E, AGUADO P, DE MIGUEL E, USON J, MAYORDOMO L, GIJON-BANOS J: Painful shoulder: comparison of physical examination and ultrasonographic findings. *Ann Rheum Dis* 2002; 61: 132-6.
 15. BILLI A, CATALUCCI A, BARILE A, MASSOCCHI C: Joint impingement syndrome: clinical features. *Eur J Radiol* 1998; 27: S39-S41.
 16. MIDDLETON WD, REINUS WR, TOTTY WG, MELSON CL, MURPHY WA: Ultrasonographic evaluation of the rotator cuff and biceps tendon. *J Bone Surg (Am)* 1986; 68: 440-50.
 17. VAN HOLSBECK M, INTROCASO JH: Sonography of the shoulder. In VAN HOLSBECK M, INTROCASO JH (Eds.): *Musculoskeletal Ultrasound*. Chicago, Mosby Year Book, 1991: 265-274.
 18. CRASS JR, CRAIG EV, FEINBERG SB: The hyperextended internal rotation view in rotator cuff ultrasonography. *J Clin Ultrasound* 1987; 15: 416-20.
 19. FARIN PU, JAROMA H, HARJU A, SAIMAKALLIO S: Shoulder impingement syndrome: sonographic evaluation. *Radiology* 1990; 176: 845-9.
 20. KENDALL FP, MCCREARY KE, PROVANCE PG, RODGERS MM, ROMANI WA: Muscles testing and function with posture and pain. Baltimore, Lippincott Williams & Wilkins, 2005.
 21. FELDMAN AG, LEVIN FM, MITNITSKI AM, ARCHAMBAULT P: 1998 ISEK Congress Keynote Lecture, Multi-muscle control in human movements. *J Electromyogr Kin* 1998; 6: 383-90.
 22. FELDMAN AG, LEVIN FM: The origin and use of positional frames of reference in motor control. *Behav Brain Sci* 1995; 18: 723-806.
 23. ALVAREZ CM, LITCHFIELD R, JACKOWSKI D, GRIFFIN S, KIRKLEY A: A prospective, double-blind, randomised clinical trial comparing subacromial injection of betamethazone and xylocaine to xylocaine alone in chronic rotator cuff tendinosis. *Am J Sports Med* 2005; 33: 255-62.
 24. WINTERS JC, SOBEL JS, GROENIER KH, ARENDZEN HJ, MEYBOOM-DE JONG B: Comparison of physiotherapy, manipulation, and corticosteroid injections for treating shoulder complaints in general practice: randomised, single blind study. *Br Med J* 1997; 314: 1320-5.
 25. ENOKARM: Muscle strength and its development: new perspectives. *Sports Med* 1988; 6: 146-68.
 26. SANES JN, DONOGHUE JP: Oscillations in local field potentials of the primate motor cortex during voluntary movement. *Proc Natl Acad Sci USA* 1993; 90: 4470-4.
 27. SANES JN, DONOGHUE JP: Plasticity and primary motor cortex. *Ann Rev Neurosci* 2000; 23: 393-415.