

Research Article – Human Anatomy Case Report

Multimodal imaging in the diagnosis and evaluation of intestinal malrotations in adults: a case report

Anna Mancuso¹, Anna Franca Milia², Mirko Manetti², Martina Ruffo², Desiree Pantalone³, Leonardo Capaccioli¹, Massimo Falchini¹, Lidia Ibba-Manneschi^{2*}

¹ Department of Biomedical, Experimental and Clinical Sciences, University of Florence, Florence, Italy

² Department of Experimental and Clinical Medicine, Section of Anatomy and Histology, University of Florence, Florence, Italy

³ Department of Surgery and Translational Medicine, University of Florence, Florence, Italy

Submitted February 10, 2014; accepted May 30, 2014

Abstract

Midgut malrotation is a congenital anomaly referring to either lack of or incomplete rotation of the fetal intestines around the axis of the superior mesenteric artery during fetal development. It is rare in adulthood and the true incidence is difficult to estimate because most patients are asymptomatic. The diagnosis is usually performed with several radiological and surgical methods. We report a case of a woman who presented with cramp-like abdominal pain localized to the right iliac fossa. The patient underwent abdominal ultrasound, radiological examination without and with contrast, and computed tomography with three-dimensional volume rendering reconstruction. Although small bowel follow-through is often enough to recognize the type of malrotation, using multimodal imaging may offer a better definition of this abnormality with a better definition of the kind of malrotation, by adding additional anatomical information. In our case, the imaging clearly showed malrotation of the small bowel with reverse rotation of the colon. Hence a multimodal imaging strategy proved useful for the diagnosis of intestinal malrotation in an adult afflicted by chronic cramp-like abdominal pain.

Key words

Adult intestinal malrotation, multimodal diagnosis, RX-contrast studies, computed tomography, three-dimensional volume rendering.

Introduction

Intestinal malrotation, traditionally considered a disease of infancy, is a congenital disorder resulting from failure in the normal embryologic sequence of bowel rotation and fixation by mesenteric bands, or by absence of fixation of portions of the bowel (Applegate *et al.*, 2006; Nehra *et al.*, 2011). This condition has been recognized as a cause of obstruction in neonates and children and can predispose affected adults to potentially life-threatening conditions such as intestinal necrosis or midgut volvulus (von Flüe *et al.*, 1994; Appaji *et al.*, 2013).

The incidence of malrotation is not well known. The Center for Disease Control survey registry of birth defects estimates that the prevalence of malrotation in infants under 1 year age is 3.9:10,000 live births (Applegate, 2009). Pediatric surgeons report

* Corresponding author. E-mail: lidia.ibba@unifi.it.

that it occurs more frequently, in approximately 1:500 live births. Symptomatic malrotation is a diagnosis usually made in the newborn and young infant; up to 75% of cases occur within the newborn period and up to 90% of cases occur within the first year of life (Applegate, 2009; Emanuwa *et al.*, 2011). Post mortem studies suggest that gut malrotation may affect up to 1:6,000 individuals (Emanuwa *et al.*, 2011). The true incidence in adults is difficult to estimate because most patients are asymptomatic.

In older children and adults the disease can manifest with a broad range of symptoms, ranging from acute abdominal pain, vomiting, mild intermittent pain to malabsorption and other less frequent manifestations (Applegate *et al.*, 2006). Due to such not specific clinical symptoms, a very high index of suspicion and a solid understanding of embryology and anatomy are required to promptly diagnose and appropriately treat this condition (Nehra *et al.*, 2011).

The normal embryological development of the digestive tract takes place between the 4th and 12th week, with initial rapid longitudinal growth and a 90° anticlockwise rotation around the axis of the superior mesenteric artery (SMA) during a phase of herniation into the umbilical cord, followed by a further 180° rotation on return to the abdominal cavity. The midgut is supplied by the SMA, and by the 5th week it begins rapid elongation and outgrows the capacity of the abdominal cavity, which causes temporary physiological herniation into the umbilical cord followed by later return into the abdominal cavity. The midgut therefore undergoes a 270° counterclockwise rotation around the SMA axis that leads to the formation of the duodenal C-loop, which remains placed behind the SMA in a retroperitoneal position and emerges at the Treitz ligament. The duodeno-jejunal flexure (DJF) and jejunum then lie to the left. The base of the small bowel mesentery subsequently fuses with the posterior peritoneum in a diagonal fashion, from the Treitz ligament at the DJF to the caecum, completing the whole process at about the 11th week. The distal small bowel comes to lie progressively to the right in the abdominal cavity. The ascending colon then assumes a retroperitoneal position, also on the right side. The descent of the caecum from its higher position to the right lower abdominal quadrant is the latter part of this complex rotational development.

Midgut malrotation is a congenital anomaly referring to either lack of or incomplete rotation of the fetal intestine around the axis of the SMA during development. The diagnosis is usually performed with several methods such as barium studies, computed tomography (CT) scans, angiography, and sometimes during emergency laparotomy.

Case report

A 38-year-old woman presented with cramp-like abdominal pain localized to the right iliac fossa. She reported a normal physiological anamnesis and had no history of previous relevant organic pathology. Clinical examination did not show significant signs of peritoneal irritation, but just a mild diffuse tenderness to deep palpation. Routine laboratory analysis revealed a mild elevation of inflammatory markers and a modest syderopenic anemia. An inflammatory bowel disease or appendicitis were suspected. Patient underwent abdominal ultrasound and abdominal X-rays examination, without significant pathologic reports.

Results

A radiological study with small bowel follow-through technique was performed because of clinical suspicion of chronic inflammatory bowel disease. Diagnostic imaging showed malrotation of the small bowel without evidence of duodenum crossing the lumbar spine, lack of DJF, and the right colon localized in the left abdominal side, while the left colon showed a normal localization. The small bowel was entererly sequestered on the right abdominal side. The last loop of the small intestine converged to the ileocecal valve on the right side of the ascending colonic wall, without evidence of small bowel inflammatory disease signs (Fig. 1). Due to the persistence of abdominal symptoms, an abdominal CT with contrast and three-dimensional (3D) volume rendering reconstruction was performed. CT confirmed the diagnosis of intestinal malrotation (Fig. 2) and clearly showed the location of transverse colon posterior to the SMA, which is typical of reverse rotation.

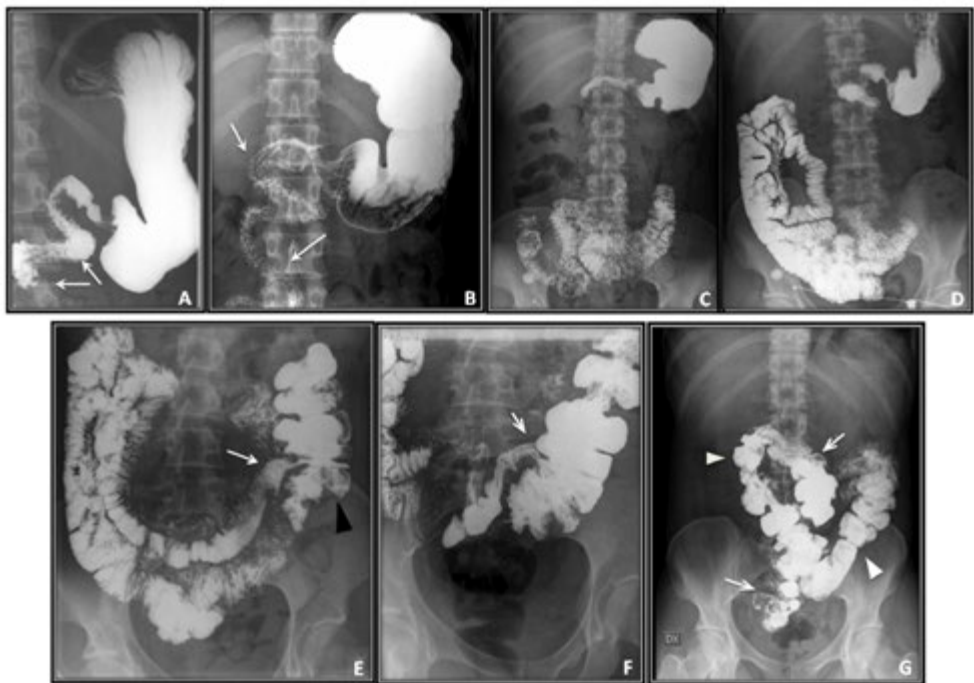


Figure 1 – **A, B**: Contrast gastrointestinal series: duodenal malrotation and absence of duodeno-jejunal flexure (Treitz) (arrows). **C, D**: Jejunal loops are completely located in the right abdomen side. **E, F**: Contrast gastrointestinal series: ileo-colic junction converges with large intestine on the right side of colonic wall (white arrow), with caecum and ascending colon located in the left abdomen side (black arrowhead). **G**: Late views of small bowel follow-through with normally opacified colon. The right parietocolic space is empty. Caecum and ascending colon are located on the left abdomen side (arrows). Normally located hepatic flexure, transverse colon (arrowheads) and left colon segment are evident.

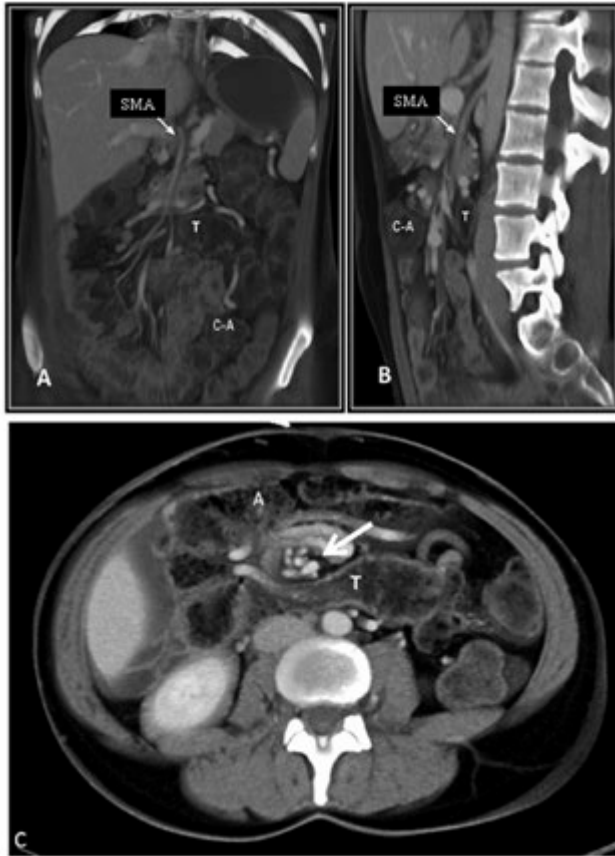

Figure 2 – Abdominal contrast enhanced computer tomography (CT) with three-dimensional (3D) volume rendering (VR) reconstruction confirmed intestinal malrotation. **A, B:** 3D coronal (**A**) and sagittal (**B**) VR images show left side localization of right colon, and reverse rotation expressed by transverse colon (T) running posterior to the superior mesentery artery (SMA, arrow) and to the caecum and ascending colon (C-A). **C:** Axial 3D VR of contrast enhanced abdominal CT. Transverse colon (T) is recognizable posteriorly to SMA and to ascending colon (A). Superior mesenteric vein shows a whirling pattern (“barber pole sign”) (arrow).

Discussion

The incidence rate of malrotation is highly variable depending on whether the data are clinical or from autopsies, but it may be estimated that it represents the cause of about 3–5% of cases of mechanical obstructions and 5% of cases of appendicitis and appears in 0.5% of radiological digestive series (Penco *et al.*, 2007). Studies on the incidence of malrotation in mixed populations show the influence of ethnic factors, radioactive or toxic insults and low birth weight, but not of sex or number of siblings (Penco *et al.*, 2007). In this study, we show a case of intestinal malrotation and reverse rotation of the colon in an adult. Radiological imaging well depicts

the figure of malrotation in our patient. Small bowel follow-through is often enough to recognize the type of malrotation, but multimodal imaging offers a better definition of this abnormality. For some conditions, like in this case, in which the transverse colon has a posterior location behind the SMA, CT can help to better define the kind of malrotation by adding additional anatomical information. In our case, 3D coronal and sagittal volume rendering images clearly showed the left side localization of the right colon and the position of the transverse colon posterior to SMA and to the caecum. In axial 3D volume rendering reconstruction, the transverse colon was recognizable posteriorly to SMA and to the ascending colon. Thus, CT with 3D volume rendering reconstruction allows to recognize the specific and more complex forms of reverse rotation, that are not clearly depicted by the small bowel follow-through imaging (Lee *et al.*, 2010).

In conclusion, a multimodal imaging strategy proved to be useful for a unique diagnosis of intestinal malrotation in an adult patient afflicted by chronic cramp-like abdominal pain.

References

- Appaji A.C., Kulkarni R., Kadaba J.S. (2013) Nonrotation of intestine: a case report. *J. Clin. Diagn. Res.* 7: 2575-2576.
- Applegate K.E., Anderson J.M., Klatte E.C. (2006) Intestinal malrotation in children: a problem-solving approach to the upper gastrointestinal series. *Radiographics* 26: 1485-1500.
- Applegate K.E. (2009) Evidence-based diagnosis of malrotation and volvulus. *Pediatr. Radiol.* 39 (Suppl 2): s161-s163.
- Emanuwa O.F., Ayantunde A.A., Davies T.W. (2011) Midgut malrotation first presenting as acute bowel obstruction in adulthood: a case report and literature review. *World J. Emerg. Surg.* 6: 22 [6 pages].
- Lee N.K., Kim S., Jeon T.Y., Kim H.S., Kim D.H., Seo H.I., Park do Y., Jang H.J. (2010) Complications of congenital and developmental abnormalities of the gastrointestinal tract in adolescents and adults: evaluation with multimodality imaging. *Radiographics* 30: 1489-1507.
- Nehra D., Glodstein A.M. (2011) Intestinal malrotation: varied clinical presentation from infancy through adulthood. *Surgery* 149: 386-393.
- Penco J.M., Murillo J.C., Hernandez A., De La Calle Pato U., Masjoan D.F., Aceituno F.R. (2007) Anomalies of intestinal rotation and fixation: consequences of late diagnosis beyond two years of age. *Pediatr. Surg. Int.* 23: 723-730.
- von Flüe M., Herzog U., Ackermann C., Tondelli P., Harder F. (1994) Acute and chronic presentation of intestinal nonrotation in adults. *Dis. Colon Rectum* 37: 192-198.