EWMA 2026 CONFERENCE ABSTRACTS

The European Wound Management Association
EWMA

EWMA 2026 Conference Abstracts

© EWMA 2026 Copyright of published material and illustrations is the property of the European Wound Management Association. However, prior written consent for their reproduction, including parallel publishing (e.g., via repository), can be obtained from EWMA via the Editorial Board of the Journal, If proper acknowledgement is given, such permission will normally be readily granted. Requests to produce material should state where material is to be published, and, if it is abstracted, summarised, or abbreviated, then the proposed new text should be sent to Journal of Wound Management Editor for final approval. Although EWMA has taken great care to ensure accuracy, EWMA will not be liable for any errors of omission on inaccuracies in this publication.

Published by the European Wound Management Association, Nordre Fasanvej 113, 2, 2000 Frederiks-berg, Denmark Web: www.ewma.org. Email: ewma@ewma.org

DOI: 10.35279/jowm2026.27.02.sup01

Contents

ENGLISH E-POSTERS 6
ACUTE WOUNDS 6
ATYPICAL WOUNDS 26
BASIC SCIENCE 36
BURNS 55
CASE STUDIES 71
DEVICES & INTERVENTION 150
DIABETIC FOOT 169
DRESSINGS 198
EDUCATION 230
E-HEALTH 248
HEALTH ECONOMICS & OUTCOME 253
HOME CARE 263
INFECTION 269
PHD RESEARCH-IN-PROGRESS 282
LEG ULCER 307
NEGATIVE PRESSURE WOUND THERAPY 323
NUTRITION 337
PAIN 338
POST-MARKET SURVEILLANCE 340
PRESSURE ULCER 341
PREVENTION 362
PROFESSIONAL COMMUNICATION 375
QUALITY OF LIFE 376
SURGICAL APPROACHES 387
STOMA 403
TRANSLATIONAL SCIENCE 403
WOUND ASSESSMENT 409
ENGLISH ORAL PRESENTATIONS
ACUTE WOUNDS 420
ATYPICAL WOUNDS 427
BASIC SCIENCE 431

BURNS 432
DEVICES & INTERVENTION 435
DIABETIC FOOT 440
DRESSINGS 469
EDUCATION 472
E-HEALTH 474
HEALTH ECONOMICS AND OUTCOMES 475
HOME CARE 477
INFECTION 480
LEG ULCER 483
NEGATIVE WOUND PRESSURE THERAPY 488
NUTRITION 489
PAIN 490
PRESSURE ULCER 490
PREVENTION 494
QUALITY OF LIFE 496
SURGICAL APPROACHES 499
TRANSLATIONAL SCIENCE 504
WOUND ASSESSMENT 509

GERMAN E-POSTER PRESENTATIONS

E-HEALTH 513
AKUTE WUNDEN 514
ATYPISCHE WUNDEN 516
GRUNDLAGENWISSENSCHAFT 518
VERBRENNUNGEN 518
INSTRUMENTE UND EINGRIFFE 520
DIABETISCHES FUSS SYNDROM 521
AUSBILDUNG 522
HÄUSLICHE PFLEGE 523
INFEKTION 524
ULCUS CRUSIS 526
UNTERDRUCK WUNDTHERAPIE 527
SCHMERZEN 528
DEKUBITUS 529

PRÄVENTION 530
CHIRURGISCHE ANSÄTZE 531
WUNDBEURTEILUNG 532
POST-MARKET SURVEILLANCE 534
VERBRENNUNGEN 536
DIABETISCHES FUSSSYNDROM 537
AUSBILDUNG 538
INFEKTION 538
ULCUS CRURIS 539
UNTERDRUCK WUNDTHERAPIE 540
DEKUBITUS 541
ENGLISH ABSTRACTS PRESENTED AT THE EWMA COOPERATING ORGANISATIONS SESSION 2026 542

English E-posters

ACUTE WOUNDS

EP001 Clinical observation of the efficacy of a topical ointment containing beta-sitosterol in the treatment of radiation-induced dermatitis in cancer patients

Meerim Ibraeva[1]

[1]*National Center for Oncology and Hematology under the Ministry of Health of the Kyrgyz Republic, Chüy Region, Kyrgyzstan*

Aim: To evaluate the clinical effectiveness of a beta-sitosterol–based ointment for prevention and treatment of radiation-induced skin reactions in patients undergoing radiotherapy for various malignant tumors.

Method: In 2024, 120 patients who received external beam radiotherapy using linear accelerators were observed. All developed radiation-induced skin reactions after the 6th–7th session, presenting with erythema, epithelial desquamation, or secondary infection. The patients had malignancies of the lip, parotid gland, tongue, palatine tonsil, breast, prostate, urinary bladder, kidney, lung, and brain. Beta-sitosterol ointment was applied twice daily during radiotherapy and for 10 days after completion. Clinical responses were assessed visually and by measuring the time to epithelialization compared with a control group that received standard care.

Results / Discussion: After using beta-sitosterol, epithelialization began within 2–3 weeks, occurring 3–4 days earlier than in the control group. Ninety percent of patients showed visible improvement, reduced dermatitis severity, and faster epithelial regeneration. The ointment also prevented moist desquamation and secondary infection. No adverse reactions were observed.

Conclusion: Topical beta-sitosterol ointment containing beta-sitosterol significantly accelerates epithelialization, reduces the severity of radiation-induced skin reactions, and improves patients' comfort and quality of life.



Before and after




Before and after




Before and after

EP002 Acute wounds constitute a notable global health challenge, especially in low- and middle-income nations

Faruk Faraj[1], Zhwan Rafaat[2]

[1]Kurdistan Technical Institute, Sulaymaniyah, Iraq, *[2]Sulaimani Teaching Hospital, Sulaymaniyah, Iraq*

Aim: This study explored the characteristics and patterns of acute wounds in trauma patients in Sulaymaniyah, Iraq. Aim was to explore the characteristics and patterns of acute wounds in trauma patients in Sulaymaniyah, Iraq. Analyzing acute wounds' demographic, clinical, and injury-related patterns is crucial for formulating targeted preventive and treatment strategies.

Method: A cross-sectional study was carried out in the Emergency Hospital over three months from January to March 2025. One hundred ninety-two patients with different types of acute wounds were included in the study, excluding those with burn injuries. Data were collected via Microsoft Excel and analyzed using SPSS version 27.

Results / Discussion: Most patients were male (82.3%), with the largest age group being 20–40 (39.1%). Head injuries constituted the most prevalent category at 45.8%, with extremity trauma following closely at 42.7%. Falls accounted for 24.0% of injuries, while sharp object injuries represented 20.8%. Tidy wounds represented 51.6% of cases according to the Rank-Wakefield classification. Surgical intervention was necessary in 35.9% of patients. No statistically significant differences in injury patterns or surgical requirements were observed between genders. Falls were commonly linked to additional injuries; however, this association did not reach statistical significance ($p = 0.068$).

Conclusion: Over three months in Sulaymaniyah, acute wounds predominantly affected young adult males, mainly from urban areas; falls and sharp-object injuries were most common, with head and extremity wounds prevailing. Rank-Wakefield classification showed equal tidy/untidy distribution, and 35.9% required surgery. Structured classification and targeted prevention are essential to enhance patient outcomes.

EP003 The role of antiseptic wound gel in the management of umbilical granuloma in newborns

Prof. Djordje Kravljanac[1]

[1]*Institut for Mother and Child Healthcare of Serbia, Faculty of Medicine, University of Belgrade, Belgrade, Serbia*

Aim: Evaluation of safety and efficacy of antiseptic gel in umbilical granuloma healing in newborns.

Method: The prospective study included newborns with umbilical granuloma treated by various therapeutic procedures in combination with an octenidine-based antiseptic wound gel. The therapeutic approach depends on clinical finding. The research was conducted in outpatient settings in a tertiary-level university pediatric center. Children were reviewed for age, sex, size of umbilical granuloma, type of therapeutic procedure, complication and length of healing.

Results / Discussion: Study included 60 newborns (36 male, 24 female), treated between January and June 2025. The mean age was 17,6 days (range 9 -30 days). The average size of the umbilical granuloma was 3,5 mm in diameter (range 1 - 8 mm). Monotherapy with octenidine-based wound gel and antiseptic solution was used in 18.3%, combined with prior silver nitrate application in 53.3% and combined with both surgical ligature and silver nitrate application in 28.4% patients. All treatment procedures achieved complete resolution of the umbilical granuloma with no signs or symptoms of infection or delayed wound healing. The average time of healing was 9.7 ± 3 (range 3-20) days.

Conclusion: Octenidine-based wound gel demonstrated favorable safety and efficacy in newborns for infection prevention and umbilical granuloma healing. These findings support its role as an additional treatment option suitable for newborns.

EP004 Injectable, antimicrobial 3D wound care foam for burns, and fresh and chronic wounds

Christiana Pliakou[1], Rasmus Kristensen[2], Romisa Fakhari[1], Liyun Yu[1], Stina Nielsen[1], Klaus Kirketerp-Møller[3], Tim Jakobsen[2], Anne Ladegaard Skov[1]

[1]*DTU - Department of Chemical and Biochemical Engineering, Kgs Lyngby, Denmark*, [2]*Costerton Biofilm Center, Copenhagen University, Copenhagen, Denmark*, [3]*Department of Immunology and Microbiology, Bacteriology, Copenhagen University, Copenhagen, Denmark*

Aim: To develop and evaluate an injectable, antimicrobial 3D foam designed for advanced wound care, targeting burns as well as fresh and chronic wounds. This technology addresses the high incidence of polymicrobial, drug-resistant infections, particularly in crises such as battlefield injuries, by providing a wound dressing that rapidly seals, protects, and promotes healing.

Method: The silicone-based foam was formulated to mix and cure in situ in under 20 minutes, allowing direct injection and perfect conformity to wound geometry. Antimicrobial activity against clinical isolates of seven species, including *Escherichia coli*, *Staphylococcus aureus*, *Pseudomonas aeruginosa*, *Klebsiella pneumoniae*, and *Acinetobacter baumannii,* was evaluated by quantification of colony-forming unit (CFU), with 10^3 CFU/mL initial inoculum. Cytocompatibility was tested on L929 fibroblasts using a tetrazolium-based calorimetric assay. Exudate absorption was measured for 1-5 days using artificial wound fluid (AWF), and compared with standard wound care products, including silver-impregnated dressings.

Results / Discussion: The foam demonstrated complete in-vitro antimicrobial eradication after 24 hours, with no detectable CFU across 10^0-10^{-2} serial dilutions (n=3 biological, technical triplicate). Cell viability assays confirmed 100% viability after 24 hours, indicating no cytotoxicity. The foam absorbed more than 50% of its own weight in AWF after 5 days, with 0.47 ± 0.01 g/cm^2 of fluid uptake, higher than silver dressings. The foam's sealing and fragment-surrounding properties may reduce environmental contamination, offering significant advantages over traditional dressings. **Conclusion:** This injectable 3D foam represents a promising advance in wound care, combining easy

application, superior antimicrobial efficacy, and exudate handling. Its ability to address both fresh and chronic wounds, especially in resource-limited or crisis settings, positions it as a valuable alternative to current wound dressings and candidate for rapid clinical translation.

EP005 Innovative application of regenerative wound ointment in the treatment of multidrug-resistant infectious wounds

Liuhong Liu[1]
[1]*Beijing, China*

Aim: To explore the innovative application of regenerative wound ointment in the treatment of multidrug-resistant (MDR) infectious wounds.

Method: A total of 50 patients with MDR infectious wounds admitted to our hospital from October 2020 to October 2024 were randomly divided into an observation group and a control group. The control group received conventional anti-infective and wound care measures, while the observation group was treated with regenerative wound ointment on the basis of the control group. Indicators such as wound treatment methods, wound healing time, infection control, pain level, antibiotic use duration, and adverse reactions were compared between the two groups to comprehensively evaluate the bacterial culture negative rate and overall clinical efficacy.

Results / Discussion: The negative rate of MDR bacterial culture in the observation group (96.000%) was significantly higher than that in the control group (52.174%) (P<0.05), and the overall clinical efficacy of the observation group (96.000%) was significantly better than that of the control group (60.870%) (P<0.05).

Conclusion: The innovative application of regenerative wound ointment in the treatment of MDR infectious wounds provides a new and effective method for clinical treatment. It can effectively promote wound healing, control infection, relieve patient pain with good safety and significant curative effect, thus having high clinical application value.

Table 1 Baseline data of patients in the two groups

Name	Control group (n=25)	Observation group (n=25)	χ^2	P
Gender				
Male	13	15	0.234	0.453
Female	12	10		
ESBKS	9	9	0.412	0.412
CR-AB	2	2	0.562	0.354
MDR-PA	12	14	0.321	0.265

Table 2 Baseline data of patients in the two groups

Name	Control group (n=25)	Observation group (n=25)	t	p
Age (years)	65.831±3.125	66.412±2.524	0.756	0.401
Wound area (cm^2)	112.616±6.324	114.313±4.601	1.037	0.312

Table 3 Baseline data of patients in the two groups (χ^2=0.432, P=0.653)

Group	Burn/scald (cases)	Diabetic foot ulcer (cases)	Chronic ulcer wound (cases)	Others (cases)	Total cases	χ^2	P
Observation group	3	9	11	2	25	0.432	0.653
Control group	4	8	10	1	23		

Table 4 Comparison of negative culture results of multidrug resistance between the two groups [n(%)]

Course of treatment	Observation group	Control group	t	p
1st course	10（40.000）	4（17.391）	-3.231	0.001
2nd course	14（56.000）	8（34.783）	-2.643	0.002
Total	24（96.000）	12（52.174）		

Note: Compared with the control group, P<0.05

EP006 Postoperative wound care practices of nurses in acute care settings: An integrative review

Gayani P Gamage[1], Josepine Lovegrove[2 3 4], Sanjeewa Seneviratne[5], Georgia Tobiano[2 6], Brigid. M Gillespie[2 6]

[1]Griffith University, Queensland, Australia, *[2]NHMRC Centre of Research Excellence in Wiser Wound Care, School of Nursing and Midwifery, Griffith University, Gold Coast Campus, Southport, QLD, Australia*, *[3]Herston Infectious Diseases Institute, Metro North Health, Herston, Australia*, *[4]School of Nursing, Midwifery & Social Work, UQ Centre for Clinical Research, The University of Queensland, Queensland, Australia*, *[5]Department of Surgery, Faculty of Medicine, University of Colombo, Colombo, Sri Lanka*, *[6]Nursing and Midwifery Education and Research Unit, Gold Coast University Hospital, Gold Coast Hospital and Health Service, Gold Coast, Australia*

Aim: To explore the available evidence on surgical wound care practices of nurses working in acute care settings.

Method: This integrative review was guided by Whittemore and Knafl's methodology. Searches were conducted on five databases, including Medline, Scopus, CINAHL Complete, Embase and Web of Science, between 1 January 2000 and 1 August 2024 and supplemented by backward and forward citation searching. Full-text, primary articles focused on postoperative wound care by nurses in hospital settings were included. Quality appraisal was undertaken using the Mixed Methods Appraisal Tool (2018) for the qualitative and quantitative studies, and the Standards for Quality Improvement Reporting Excellence 2.0 guidelines for the quality improvement (QI) studies. Inductive content analysis was used for data synthesis. Reporting of the review followed the Preferred Reporting Items for Systematic Reviews and Meta-Analyses (PRISMA) Statement 2020.

Results / Discussion: Of the 5352 records screened, 36 studies using quantitative, qualitative, mixed-method and QI designs were included. Three categories were identified: 'Variation in using a holistic approach impacts optimal wound care practice', 'Nurses' surgical wound care practices are shaped by individual factors, organisational support, and resource availability', and 'Nurses' participation in surgical wound care is influenced by role clarity and multidisciplinary collaboration'.

Conclusion: Acute care nurses are predominantly focused on technical dressing procedures with limited emphasis on comprehensive assessment, documentation, nutrition and patient education. Nurses' adherence to evidence-based practice recommendations is influenced by a mix of individual and organisational factors. Nurses' full participation in wound care depends on understanding their scope of practice and multidisciplinary collaboration between other healthcare professionals. Overall, adopting a more holistic approach in surgical wound care could minimise practice variations among acute care nurses.

EP020 Evaluating the use of a topical desiccating agent on the diabetic foot wound care pathway

Neala Rezai[1], Hannah Cook[1 2], Sylvia Rofael[3], Iryna Muravska[3], Hans-Pieter Snels Snels[4], Richard Leigh[1], Sophie Collier[1 3], Janice Tsui[1 2], T.d. McHugh[3], Ash Mosahebi[1 2]

[1]Royal Free Hospital, London, United Kingdom, *[2]UCL Division of Surgery and Interventional Science, London, United Kingdom*, *[3]UCL Department of Microbiology, London, United Kingdom*, *[4]DebX Medical, Amsterdam, Netherlands*

Background: A major barrier to healing diabetes-foot-ulcers (DFUs) is biofilm formation. Topical-desiccating-agents (TDA) aim to disrupt this environment, potentially reducing biofilm persistence, enhancing wound-healing, and decreasing antibiotics use. This case-based service evaluation investigates the impact of TDA on DFU biofilm, wound-healing outcomes, and antibiotic requirements in a specialist diabetes foot clinic.

Aim: To evaluate the effect of a TDA on DFU biofilm, wound-healing outcomes and antibiotic requirements in patients attending a UK tertiary diabetes foot clinic.

Method: This service evaluation recruited 10 wounds from November 2025 - February 2026. Routine baseline investigations were recorded. Wound measurements, photography and microbiological samples were collected before and after TDA intervention, and at weeks 1 and 4 post-intervention for standard cultures and microbiome profiling.

Results / Discussion: Wound size at 4 weeks was reduced in all cases. Mean area was 2070mm^2 pre-treatment, 1982mm^2 1-week (4.2% reduction) post-treatment and 928mm^2 (55% reduction) at 4 weeks. No cases required antibiotics following TDA application. No treatment related complications were observed. Estimated mean cost saving was £2400 per patient (compared to predicted clinical course without a TDA). Clinically, wounds showed reduced exudate and increased granulation. Early post-treatment culture plates exhibited no growth. Full microbiome sequencing is pending and will be reported in March 2026.

Conclusion: Early findings suggest TDAs reduce biofilm, support wound healing and decrease antibiotics use. These results support further investigation in a larger cohort.

EP384 Umbilical cord mesenchymal stem cell-derived secretome hydrogel promotes early wound closure and neovascularization in rats with full-thickness cutaneous wound

David Perdanakusuma[1], Fiera Ferdianty[1], Iswinarno Doso Saputro[1]

[1]Department of Plastic Reconstructive and Aesthetic Surgery, Faculty of Medicine, Universitas Airlangga, Surabaya, Indonesia

Aim: This study aims to ascertain the efficacy of a Umbilical Cord Mesenchymal Stem Cell (UCMSC) secretome hydrogel preparation on the healing process of cutaneous wounds on Wistar rats (*Rattus norvegicus*).

Method: A full-thickness cutaneous wound was made on the dorsal side of 40 rats. Then, the rats were randomly assigned to four wound dressing groups: framycetin sulphate 1% gauze dressing (control), hydrogel dressing, UCMSC secretome dressing, and UCMSC secretome hydrogel dressing (all n = 5). Dressings were reapplied three days after initial dressings (day 3). Wound closure, epithelial thickness, neovascularization, expression of epidermal growth factor (EGF), and collagen deposition were measured on days 3 and 7 and compared among the groups.

Results / Discussion: The fastest wound closure was found in groups receiving UCMSC secretome hydrogel dressing when compared to control and hydrogel dressing groups. There was no significant difference in the wound closure and epithelial thickness between the UCMSC secretome dressing and UCMSC secretome hydrogel dressing groups (p>0,05). Rats receiving UCMSC secretome hydrogel dressing expressed the highest neovascularization on day 3 compared to other groups (p=0,000). The highest EGF expression on day 7 was found in the hydrogel group (p=0,000). No significant differences in collagen deposition were observed among the groups (p>0,05).

Conclusion: Our findings reiterate the potential of UCMSC secretome hydrogel to promote epithelialization, neovascularization, and thus, cutaneous wound healing.

EP385 Medical adhesive-related skin injury in central venous catheter in pediatrics: An overview of systematic reviews

Paula Freitas[1], Lucas Rezende[2 3], Aline Ramalho[4], Isabella Dias Dias[2], Gideao de Carvalho[2], Amanda Colombi[2], Natalia Barros[5]

[1]Universidade Federal do Espírito Santo, Departament of Nursing, Vitória, Brazil, *[2]Centro Universitário Salesiano, Vitória, Brazil*, *[3]Universidade Federal do Rio de Janeiro, Rio de Janeiro, Brazil*, *[4]Hospital Sirio Libanês, São Paulo, Brazil*, *[5]Essity, São Paulo, Brazil*

Aim: To map and synthesize the body of evidence available in systematic reviews regarding MARSI in CVC among pediatric and neonatal populations, aiming to support qualified clinical decision-making based on evidence.

Method: The overview followed the JBI *Manual for Evidence Synthesis* and PRISMA-ScR guidelines, with a protocol registered on OSF. The search was conducted in July 2025 in the EMBASE, PubMed, and EBSCOhost databases, using controlled combinations of descriptors related to CVC, medical adhesives, and pediatric/neonatal care. The initial search retrieved 876 publications, of which 15 were included after screening.

Results / Discussion: Consolidated evidence indicates that MARSI is a highly prevalent and underestimated event in the context of pediatric CVC, especially in preterm neonates whose skin presents significant structural immaturity. Injuries arise from mechanisms often exacerbated by high-adhesion adhesives, inadequate removal techniques, prolonged exposure, and compromised skin integrity. The lack of standardized monitoring systems and absence of mandatory reporting accentuate its epidemiological invisibility. The reviews converge in highlighting strategies with stronger evidence: careful selection of adhesive technologies compatible with immature skin, use of protective skin barriers, adoption of standardized application and removal techniques, systematic monitoring of skin integrity, and continuous training of specialized nursing teams.

Conclusion: This overview suggests relevant gaps in care standardization and reinforces the urgent need for specific clinical protocols, incorporation of safe fixation technologies, and strengthening of professional competencies. It concludes that consolidating evidence-based practices is essential to mitigate MARSI occurrence and promote qualified and safe care for pediatric and neonatal populations.

EP386 Self-assembly of human embryonic stem cells derived keratinocytes and fibroblasts into 3D spheroid structures for epidermal regeneration in murine wound

Chenghao Cai[1], Chunmao Han[1], Xingang Wang[1]

[1]Department of Burns and Wound Care Center, the Second Affiliated Hospital of Zhejiang University School of Medicine, Hangzhou, Zhejiang province, China

Aim: Extensive burn injuries are characterized by a severe insufficiency of autologous skin grafts, which poses a significant clinical challenge. This study aimed to develop a novel cell therapy strategy featuring rapid differentiation, off-the-shelf availability, and high post-transplantation survival. Our findings could provide a new therapeutic strategy for treating patients with extensive burns.

Method: We used a differentiation medium supplemented with retinoic acid and bone morphogenetic protein 4 to acquire human embryonic stem cells derived keratinocytes (EKCs). Gene expression was analyzed by RT-qPCR. EKCs were co-cultured with human dermal fibroblasts under low-attachment conditions to form mixed 3D cell spheroids. These spheroids were then transplanted onto full-thickness skin defects on the backs of immunodeficient mice. Epidermal regeneration and wound healing were assessed by hematoxylin-eosin (HE) staining and immunofluorescence staining.

Results / Discussion: We induced the differentiation of embryonic stem cells into keratinocytes in vitro. RT-qPCR analysis confirmed that the differentiated cells could express relevant epidermal-specific markers at different stages. Dermal fibroblasts could provide extracellular matrix and microenvironment support for EKCs. The two cell types self-assembled into spheres for in vivo transplantation. In this way, EKCs were successfully transplanted onto dorsal wounds of immunodeficient mice and significantly promoted wound healing. Our approach offers the advantages of scalable production, immediate usability, and high post-transplantation survival rate, which provides a valuable reference for future pluripotent stem cell-based wound therapies.

Conclusion: This study successfully enabled human embryonic stem cell-derived keratinocytes and fibroblasts to self-assemble into 3D spheroids, which were then transplanted into full-thickness skin wounds in immunodeficient mice. The transplantation significantly accelerated wound healing and promoted epidermal regeneration.

EP387 A retrospective study comparing the efficacy of ON101 versus standard care in radiation dermatitis management

Hsiao-Lin Liu[1], James Liao[2], Yuk-Wah Tsang[1], Sheng-You Su[3], Hsiao-Ju Fu[1], Chih-Chia Chang[1]

[1]Dept. of Radiation Oncology Ditmanson Medical Foundation Chia-yi Christian Hospital, Chia-Yi City, Taiwan, *[2]Oneness Biotech Co., Ltd., Taipei, Taiwan*, *[3]Clinical Medicine Research Center, Ditmanson Medical Foundation Chia-yi Christian Hospital, Chia-Yi City, Taiwan*

Aim: Radiation dermatitis (RD) is a common side effect of radiation therapy among patients with cancers in the head and neck, breast, extremities, and anal regions. Severe cases (RTOG grades 3–4) are typically managed with topical antimicrobials or protective dressings to prevent infection and promote healing. This study assesses the therapeutic potential of ON101, a botanical topical cream that supports the wound microenvironment, compared with conventional care.

Method: A retrospective study was conducted among 58 patients with RTOG grade 3 or higher RD after their radiation therapy suspended. Participants were stratified into two groups: those treated with ON101 cream (n=32) and those receiving conventional wound dressings (n=26). The assessment included dressing duration, RTOG score, and VAS improvement from Day 1 to Day 9.

Results / Discussion: Significant between-group differences were observed across all clinical outcomes. Patients using ON101 topical cream exhibited significant reduction in median dressing duration (12 days versus 15.5 days; p=0.003) alongside RTOG improvement of 1 grade, whereas the conventional group showed no change (p=0.001).

ON101 treatment resulted in greater pain reduction, with median VAS scores decreasing by 6.82 points (from 9.38 on Day 1 to 2.56 on Day 9), whereas conventional therapy showed a smaller decrease at 2.04 points from 9.04 to 7.00.

Conclusion: ON101 topical cream showcased superior outcomes in treating radiation dermatitis, including improved RTOG grading that supports further radiotherapy continuation, accelerated wound recovery with reduced dressing duration, and substantial pain reduction. These promising outcomes underscore its potential as a highly effective treatment option for RD to improve patient comfort, maintaining oncologic treatment schedules, and reducing overall treatment burden.

EP007 Clinical efficacy and optimized parameters of long-pulsed 1064-nm Nd:YAG laser for keloid treatment in Korean patients

Young-Jun Choi[1]

[1]*Department of Dermatology, Kangbuk Samsung Hospital, Sungkyunkwan University School of Medicine, Seoul, Korea, Rep. of South*

Aim: To verify the clinical efficacy of a long-pulsed 1064-nm Nd:YAG laser and identify optimized laser parameters for the treatment of keloids in Asian patients.

Method: A single-institution, retrospective chart review and photographic analysis were performed on patients treated for keloid improvement using a long-pulsed 1064-nm Nd:YAG laser. Clinical outcomes were evaluated using two distinct modalities based on photodocumentation collected at each visit: the Vancouver Scar Scale (VSS) and a 5-point Global Assessment Score (GAS), both assessed by two blinded physicians. All cutaneous adverse events were recorded to evaluate the safety profile of the treatment.

Results / Discussion: A total of 25 Korean patients were selected and retrospectively evaluated. The commonly utilized laser parameters included a 1064-nm wavelength, a 5-mm spot size, a 25-millisecond pulse duration, an energy fluence of 75-90 J/cm^2, and a 1.5-Hz repetition rate. The average VSS and GAS scores decreased significantly following laser treatment. No persistent or serious adverse events occurred during the analysis period. By employing a pulse duration designed for optimal absorption by blood vessels within the reticular dermis, our optimized parameters effectively targeted deeper keloid tissue, resulting in a reduction in scar erythema.

Conclusion: The long-pulsed 1064-nm Nd:YAG laser can be considered an effective therapeutic modality for the treatment of keloids in Korean patients.

EP008 Early postoperative outcomes in high-risk surgical incisions: Pooled descriptive analysis from an ongoing randomized clinical trial

Dimas Milcheski[1], Rafael Santos Jr[1], Bruna Amaral[1], Rolf Gemperli[1]

[1]*Faculty of Medicine, University of São Paulo, Sao Paulo, Brazil*

Aim: To characterize the clinical profile and early postoperative outcomes of patients with high-risk surgical incisions enrolled in an ongoing randomized clinical trial evaluating closed-incision negative pressure therapy (ciNPT). The objective is to describe the complexity of this population and reinforce the need for robust evidence to guide management.

Method: A prospective randomized study is underway at a tertiary academic center. This interim report presents a pooled descriptive analysis of the first 19 consecutive surgical incisions, independent of treatment allocation. High-risk criteria included traumatic wounds, joint-related incisions, pressure-injury closures, and patients with comorbidities known to impair healing. Data were collected at postoperative days 7, 14, and 28, including minor and major dehiscence, infection, seroma, hematoma, edge necrosis, and reoperation. No inferential or between-group comparisons were performed.

Results / Discussion: The mean patient age was 48.7 years. Obesity and hypoalbuminemia were the most frequent risk factors (both 52.6%), followed by diabetes (21.1%). These characteristics reflect a population highly vulnerable to postoperative complications. In the pooled 28-day analysis, any dehiscence occurred in 31.6% of incisions (21.1% minor; 10.5% major). Infection and edge necrosis each occurred in 5.3% of cases, and reoperation related to the incision in 5.3%. No catastrophic wound failures were recorded. Recruitment challenges and imbalance in certain comorbidities highlighted the importance of strict randomization procedures and appropriate stratification for subsequent phases.

Conclusion: Preliminary pooled findings show that this study population carries a considerable burden of surgical risk, with complication rates consistent with the severity of underlying comorbidities. Completion of the planned 140-incision cohort remains essential to determine the true effectiveness of ciNPT in high-risk surgical wounds.

EP009 Intact fish skin grafts for treatment of complex wounds in premature neonates and hospitalized infants

Rene Amaya[1 2], Emily Heisler[1 2]

[1]HCA Houston Healthcare, Houston, United States, *[2]Pediatrix Medical Group, HCA Houston Healthcare, Houston, United States*

Aim: Intact fish skin grafts (IFSGs), derived from Icelandic cod, have demonstrated favorable outcomes in adult acute and chronic wound care. Their dermal-like structure and bioactive properties promote healing while limiting complications. In contrast, neonatal wound management presents distinct challenges, including fragile skin, elevated infection risk, and long-term cosmetic and functional considerations. Although IFSG use is well established in adults and reported in pediatric cases, evidence in neonates is limited. This study evaluated the safety and clinical outcomes of IFSG application in infants with complex wounds.

Method: All neonatal intensive care unit (NICU) patients treated with intact fish skin grafts from January 2022 through December 2025 were reviewed. Infants ranged from 21 weeks' gestation to term and 7–371 days of life. Wound types included IV extravasation, soft tissue infection, congenital defects, and device-related injury. Grafts were applied at the bedside without operative intervention and remained in place for 7–14 days. Sites were evaluated every 3–4 days for infection or graft-associated complications. The primary endpoint was time to complete wound closure.

Results / Discussion: Nineteen infants met criteria. Complete wound closure occurred in all patients, with an average healing time of 18 days. No graft-related adverse effects were identified.

Conclusion: This represents the largest case series describing IFSG use in preterm infants and neonates with complex wounds. In 19 patients, grafts were well tolerated without complications. These findings provide preliminary evidence that IFSGs can be safely incorporated into neonatal wound care and broaden biologic treatment options for this highly vulnerable population.

EP010 Prevention and treatment of skin injury related to medical adhesives in pediatrics: A scoping review

Paula Freitas[1], Lucas Rezende[2 3], Aline Ramalho[4], Natalia Barros[5], Adrieli Oliveira[6], Amanda Colombi[3]

[1]Universidade Federal do Espírito Santo, Departament of Nursing, Vitória, Brazil, *[2]Universidade Federal do Rio de Janeiro, Rio de Janeiro, Brazil*, *[3]Centro Universitário Salesiano, Vitória, Brazil*, *[4]Hospital Sirio Libanês, São Paulo, Brazil*, *[5]Essity, São Paulo, Brazil*, *[6]Hospital Municipal do Idoso Zilda Arns, Curitiba, Brazil*

Aim: To map the available evidence on strategies for the prevention and treatment of MARSI in pediatric and neonatal patients, identifying the most common types of injuries, high-risk scenarios, and preventive interventions adopted.

Method: The scoping review followed the JBI *Manual for Evidence Synthesis* and PRISMA-ScR guidelines, with a protocol registered on OSF (DOI: 10.17605/OSF.IO/6HZ74). The search was conducted in July 2025 in the MEDLINE/PubMed, Cochrane, LILACS, and Embase databases, using the PCC strategy to identify studies on prevention and treatment of MARSI in pediatric and neonatal patients. DeCS/MeSH descriptors and Emtree terms were combined with Boolean operators to create reproducible search strategies.

Results / Discussion: Ten studies were selected, mostly observational and with a moderate level of evidence. The included studies predominantly consisted of prospective cohorts, followed by clinical trials, scoping reviews, and mini-reviews, mostly classified as moderate-level evidence. Most research was conducted in NICUs, reflecting the vulnerability of neonates to MARSI. The studies mainly addressed adhesive removal techniques and materials, prevalence and risk factors, the relationship between tape types and injury occurrence, as well as peristomal injuries. Evidence points to the need for standardized protocols, systematic skin assessment, appropriate adhesive selection, and nursing team training as essential strategies to reduce MARSI incidence in pediatrics and neonatology.

Conclusion: MARSI in pediatrics requires specific, evidence-based care. Standardization of care protocols, staff qualification, and development of validated diagnostic tools are essential to reduce the incidence of these injuries and improve clinical outcomes for hospitalized children.

EP390 Skin tear prevalence, incidence, and risk factors in palliative care: An ISTAP-based assessment

Azize Özdaş Gündoğan[1], Dilek Sari[2]

[1]Afyonkarahisar Health Sciences University, Faculty of Health Sciences, Department of Nursing, Afyonkarahisar, Türkiye, *[2]Ege University, Faculty of Nursing, Department of Fundamentals of Nursing, İzmir, Türkiye*

Aim: Skin tears (ST) are acute wounds that commonly affect older adults and individuals with fragile skin, yet global prevalence data remain heterogeneous and insufficient. This study aimed to determine the prevalence of ST in a palliative care unit and identify associated clinical and functional factors.

Method: This descriptive cross-sectional study included all adult patients hospitalized in a palliative care unit between October and November 2025. Data were obtained from patient records, structured interviews, and skin inspection. All identified ST were photographed using a standardised imaging procedure and classified according to the ISTAP system. Functional status, pressure injury risk, consciousness, mobility, nutritional status, and skin characteristics were assessed with validated tools. Epidemiological indicators were calculated as follows: point prevalence = [(ST at initial assessment / total assessed patients) × 100]; incidence rate = [(new ST during follow-up / total patient-days) × 1000]. Fisher's Exact test and Mann-Whitney U test were used ($p<0.05$).

Results: Thirty-four patients were included (mean age 63.47±15.95 years; mean length of stay 74.88±78.83 days). Baseline point prevalence was 11.11% (2/18). Five new cases occurred over two months, yielding an incidence rate of 4.16 per 1000 patient-days. Twelve ST were documented, 58.3% classified as Type 3, most often on the hands and upper extremities. ST occurrence was significantly associated with pale skin, diagnostic category, ecchymosis/hematoma, and prior tear history ($p<0.05$). Affected patients had lower hemoglobin, hematocrit, and albumin levels, higher dryness scores, and lower Braden scores ($p<0.05$).

Conclusion: This study provides early data on ST prevalence among palliative care patients in Türkiye and is expected to support strengthened prevention, broader use of ISTAP classification, and the development of protocols for ST management.

EP011 Epidemiology of skin tears in the community setting: A scoping review

Alexandre Rodrigues[1], Pedro Sardo[1], João Simões[1], Sofia Santos[1], Beatriz Oliveira[1], Marilyn Maia[1], Mariana Domingues[1], Marisa Sousa[1]

[1]University of Aveiro, Aveiro, Portugal

Aim: To identify epidemiological data on skin tears in a community context;

To analyze characteristics of individuals with skin tears in the community.

Method: An integrative review of the literature, organized according to the steps recommended by the Joanna Briggs Institute, and developed in accordance with the PRISMA (Preferred Reporting Items for Systematic Reviews and Meta-Analyses) flowchart. The established inclusion criteria included the acronym PCC, with data collection being carried out in March of 2025.

Results / Discussion: The skin tears established in the community context represent a relevant and emerging public health problem, mainly affecting the elderly population, bedridden or with cognitive and mobility limitations, whether at home or in institutions. These injuries compromise quality of life, generate high costs and remain underdiagnosed. The prevalence varies between 2,27% and 59%, while the incidence between 2,2% and 62,62%. The main risk factors are related to anatomical and physiological changes of aging, comorbidities, polymedication and environmental conditions.

Conclusion: We have a large difference between minimum and maximum values of prevalence and incidence of skin tears in the community. But this is a topic of great importance in the healthcare field, as they compromise the quality of life of affected individuals and their caregivers and entail higher socioeconomic costs for both the individuals/families and the healthcare system. Nursing plays a central role in prevention, monitoring and health education, promoting personalized and quality care.

EP012 Prevalence study of MARSI and its relationship with associated factors in adult patients hospitalised in intensive care unit

Bastian Spruth[1], Solange Paola Cortes Luengo[2], Maria Fernanda Morales-Labarca[3], Ana Villalobos Sandoval[2], Francisca Villagran-Silva[4], Cristian Sandoval Vásquez[5]

[1]BSN medical GmbH (Essity Group), Hamburg, Germany, *[2]Hospital Clinico de la Universidad de Chile, Santiago, Chile*, *[3]Essity Health&Medical, Santiago, Chile*, *[4]Universidad de La Frontera, Temuco, Chile*, *[5]Medical Technology School, Faculty of Health, Universidad Santo Tomás, Osorno, Chile, Department of Internal Medicine, Faculty of Medicine, Universidad de La Frontera, Temuco, Chile, Osorno, Chile*

Aim: To determine the prevalence of medical adhesive-related skin injury MARSI and its association with relevant clinical factors and medical devices in critical ill patients.

Method: An observational, cross-sectional, analytical study was conducted on 84 critical ill adult patients from a Chilean Hospital. Data collection included sociodemographic characteristics, MARSI occurrence and types, use of medical devices including adhesive fixation products, medical history, nutritional status, risk factors for skin lesions, biochemical and hematological parameters, and skin characteristics. Standardization training was conducted for data collection. Analysis was performed using STATAv18 ($\alpha = 0.05$).

Results / Discussion: A total of 9 MARSI was observed with 9.5% prevalence (n = 8). Number of adhesive products per patient ranged from 4 to 21. Transparent polyurethane film (TPF) was most frequently implicated (44.4%). Upper limbs were the most affected region, and skin tears and irritant contact dermatitis were the most common MARSI types. Multiple logistic regression identified Diabetes Mellitus (DM) as significantly associated with MARSI development chance (OR 8.28; p=0.024; 95% CI: 1.31 – 52.14) while the use of elastic polyester non-woven wide area fixation (ENWAF) suggested a reduced chance for developing MARSI (OR 0.116; p=0.035; 95% CI: 0.01 – 0.86). Consistent with previous studies, mechanical and dermatitis MARSI and acrylate-based adhesives such as TPF were linked to these injuries.

Conclusion: Critically ill adults, particularly those with DM, are at higher MARSI risk, while ENWAF may represent an alternative to reduce this risk among acrylate adhesive products. Strengthening education on risk factors and product properties is essential to improve care quality in critical settings and to guide preventive strategies, including appropriate adhesive selection, evaluation of backing material characteristics, skin preparation, and removal techniques.

Table 1. Distribution of injuries (n=9) associated with medical adhesives according to anatomical location identified in patients (n= 8) hospitalized in a Critical Patient Unit.

Location	Type of MARSI						Total	
	Epidermal stripping		Skin tear		ICD			
	%	n	%	n	%	n	%	n
Cervical region	1.2	1	1.2	1			**2.4**	**2**
Thorax			1.2	1			**1.2**	**1**
Upper limb			3.6	3	3.6	3	**7.2**	**6**
Total	1.2	1	6.0	5	3.6	3	**10.8**	**9**

ICD: Irritating Contact Dermatitis.

Table 2. Anatomical location and the causal agent that caused MARSI (n=9), identified in patients (n=8) hospitalized in an Intensive Care Unit.

Location	Causal Agent										Total	
	MT		TF		ED		EWAF		Unknown			
	%	n	%	n	%	n	%	n	%	n	%	n
Cervical region			2.4	2							2.4	2
Thorax							1.2	1			1.2	1
Upper Limb	1.2	1	2.4	2	1.2	1			2.4	2	7.2	6
Total	1.2	1	4.8	4	1.2	1	1.2	1	2.4	2	10.8	9

Nota. MT: Microporous tape; TF: Transparent polyurethane film; ED: Electrode; EWAF: Elastic polyester non-woven wide area fixation.

Table 3. A multiple logistic regression model adjusted of the independent variable associated with the development of MARSI.

Independent Variable	OR	*p*	95% CI	
Gender	0.25902	0.168	0.03801	1.76517
Type 2 diabetes mellitus	8.27644	**0.024**	1.31351	52.1498
Incontinence	1.65203	0.568	0.29547	9.23686
Antibiotics	1.20224	0.835	0.21274	6.79398
Serum Protein	0.76094	0.738	0.15306	3.78298
Serum Albumin	3.09927	0.366	0.26644	36.0507
Hemoglobin	0.83705	0.405	0.55071	1.27229
Ecchymosis or hematoma	0.02455	0.366	0.31281	23.3571

OR: odds ratio; CI: confidence interval

Adjusted variable: high blood pressure, dyslipidemia, kidney failure, alcoholism, smoking, anti-inflammatories, anticoagulant, corticosteroids, vasopressors, immunosuppressants, downtown syndrome, SBP, DBP, height, BMI categories, Glasgow score, age, arterial line use, serum urea levels, Braden risk, edema, senile purpura or actinic purpura, decreased turgor, white atrophy, eczema or atopic dermatitis.

Table 4. A multiple logistic regression model of the total medical adhesive product with the development of MARSI.

Medical adhesive product	OR	*p*	95% CI	
Microporous paper tape	2.10572	0.449	0.30622	14.4798
Transparent polyethylene tape	1.36121	0.739	0.22191	8.34982
Mixed paper and polyethylene tape	0.52691	0.475	0.09095	3.05262
Elastic polyester non-woven wide area fixation	0.11638	**0.035**	0.01568	0.86409
Transparent polyurethane film	0.91039	0.942	0.07133	11.6197
Hydrocolloid dressing	4.44118	0.266	0.32126	61.3964
Hydrocolloid ostomy plate	2.26738	0.631	0.08035	4.82913

OR: odds ratio; CI: confidence interval. Adjusted variable: Electrode; Polyurethane foams.



Figure 1. 77-year-old woman with Skin Tears Type 3 caused by transparent film in neck, for Central Venous Catheter fixation. BMI Normal, Risk factor: Incontinence, Downtown 3 or more, and Braden Moderate-High, edema and Senile Purpura. Drugs: anticoagulant, Corticosteroids. Hematologic parameters: Anemia and thrombocytosis.



Figure 2. 70-year-old woman with Epidermal Stripping caused by transparent film in neck, for Central Venous Catheter fixation previously withdraw. BMI Low weight, Clinical variables: HBP. Risk factor: Incontinence, Downtown 3 or more, and Glasgow 14 or less, Braden Moderate-High, ecchymosis and white atrophy. Drugs: anticoagulant, Antibiotics, Vasopressors. Hematologic parameters: Anemia.



Figure 3. 70-year-old woman with Skins Tears type 3 caused by an electrode in upper limb. BMI Low weight, Clinical variables: HBP. Risk factor: Incontinence, Downtown 3 or more, and Glasgow 14 or less, Braden Moderate-High, ecchymosis and white atrophy. Drugs: anticoagulant, Antibiotics, Vasopressors. Hematologic parameters: Anemia.

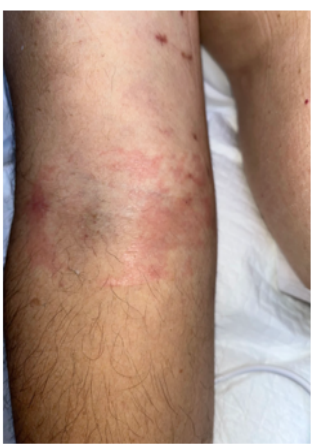

Figure 4. 69-year-old man with Irritating Contact Dermatitis in upper limb caused by transparent film to fixate a peripheral venous device. BMI Overweight, Clinical variables: DM2, HBP. Risk factor: Incontinence, Downtown 3 or more and edema. Drugs: Antibiotics, anticoagulants. Biochemical parameters: hypoalbuminemia. Hematologic parameters: Anemia.



Figure 5. 28-year-old man with Irritating Contact Dermatitis in upper limb caused by microporous film to fixate a peripheral venous device. BMI Overweight, Clinical variables: DM2, Alcoholism. Risk factor: Downtown 3 or more, Braden Moderate-High and ecchymosis. Drugs: none. Biochemical parameters: low serum urea.



Figure 6. 58-year-old man with Skin Tears type 3 in thorax caused by elastic polyester non-woven wide area fixation. BMI Overweight, Clinical variables: none. Risk factor: Incontinence, Downtown 3 or more, Braden Moderate-High, Glasgow 14 or less, edema and ecchymosis. Drugs: Anti-inflammatories, anticoagulants, antibiotics. Biochemical parameters: hypoalbuminemia and hypoproteinemia. Hematological parameters: anemia and thrombocytosis.

EP013 Development of a telemonitoring protocol for surgical wounds in a maternity ward

Jabiael Carneiro da Silva Filho[1], Alice Fonseca Pontes[1], Samara Letícia Bezerra da Hora Silva[2], Ana Carolyna Batista dos Santos[2], Giullia de Souza Ribeiro[2], Renan Alves Silva[3], Isabel Cristina Santos[1], Marilia Valenca[1]

[1]University of Pernambuco - Postgraduate Program in Nursing, Recife, Brazil, *[2]University of Pernambuco, Recife, Brazil*, *[3]Federal University of Campina Grande, Campina Grande, Brazil*

Aim: To develop a telemonitoring protocol for surgical wounds in a maternity ward.

Method: Methodological study was conducted in two stages: 1) a Scoping Review and 2) the establishment of an Expert Committee to consolidate the identified variables. The PCC strategy guided the Scoping Review, considering Population: people with surgical wounds; Concept: telemonitoring; and Context: maternity wards. A total of 456 studies were selected for full-text screening, of which 448 were excluded for not meeting the study objectives, resulting in a final sample of eight publications. The Expert Committee composed of a wound care nurse, a generalist nurse, and a professional with expertise in telemonitoring analyzed and consolidated the variables required for structuring the protocol. The study was conducted in a reference maternity hospital in Northeast Brazil between May and November 2025.

Results / Discussion: The analysis of the studies enabled the identification of key variables for the protocol, including the assessment and management of surgical wounds, identification of signs of surgical site infection (SSI), type of surgery, and available technologies for synchronous or asynchronous remote monitoring. Discussions with the expert committee revealed three structuring axes to guide protocol development: facilitators and barriers in building a therapeutic alliance in a remote environment; the nurse's role in the telemonitoring of surgical wounds; and the ethical and regulatory implications of telemonitoring in Brazil. The final protocol integrated these elements and incorporated a systematized flow for patient follow-up.

Conclusion: The protocol was developed based on the needs of the maternity ward and supported by robust scientific evidence, contributing to improved monitoring of surgical wounds and promoting the early identification of surgical site infections.

EP014 Healing trajectories and risk factors post-surgical abscess drainage

Ren Hong Por[1], Joseph Wei Ern Teo[1], Shaun Chan[2], Sadhana Chandrasekar[2], Chee Wei Lee[2], Zhiwen Joseph Lo[2]

[1]Singapore, [2]Woodlands Health Wound and Vascular Centre (Singapore), Singapore

Aim: This study aims to analyse and determine the demographic and clinical factors affecting the rate of abscess wound healing post-surgical drainage in a tertiary healthcare institution.

Method: From May 2024 to July 2025, 1033 patients underwent skin and subcutaneous tissue surgery at our institution. From these, 229 patients with 240 abscesses were selected. Inclusion criteria comprised patients with abscesses located at the neck, shoulder, axilla, breast, chest wall, abdomen, umbilicus, back, gluteal, and lower limb regions that underwent surgical drainage, and followed up with documented healing of abscess cavity. Exclusion criteria comprised patients with genital, head, or foot abscesses. Clinical data of each patient was studied against the duration of wound healing using univariate and multivariate analysis.

Results / Discussion: 105 female and 124 male patients were included. Median age was 51 years. Median abscess area, cavity area, and days to healing were 11.78cm^2, 7.46cm^2, and 45 days respectively. Age, diabetes mellitus, hyperlipidemia, total white cell counts, C-reactive protein, latest HbA1c ≥ 8.0, abscess location, packing, culture, abscess area, cavity area, were all statistically significant ($p<0.05$) in affecting days to healing after univariate analysis. Back (n=83), gluteal (n=33), and axilla (n=33) abscesses were the most common. Abscesses packed with chlorhexidine-soaked ribbon gauze or Kaltostat, and MSSA-positive abscesses had the longest median days to healing. After multivariate analysis, only fever and cavity area post-surgery were statistically significant ($p<0.05$) in increasing the median days to healing after correcting for other variables.

Conclusion: For patients who underwent surgical abscess drainage, the mean duration to wound healing was 8.90 days per cm^2 of cavity area. Cavity area and fever are independently associated with increased post-surgery wound healing time.

Table 1: Welch's t-test of Categorical Variables

		Median Days to Healing (n ± IQR)	t-value	p-value	95% CI
Gender (n=240)	Male	44 ± 30	-1.53	0.128	-13.76, 1.74
	Female	45 ± 22.2			
DM (n=240)	No	42 ± 26	-2.56	**0.0112**	-18.34, -2.38
	Yes	51 ± 26			
Latest HbA1c >= 8.0 (n=155)	<8.0	45 ± 22.5	-2.15	**0.0354**	-21.80, -0.80
	>=8.0	54 ± 29			
Hypertension (n=240)	No	42 ± 25	-0.98	0.329	-11.45, 3.85
	Yes	49 ± 23.5			
Hyperlipidemia (n=240)	No	42 ± 25.5	-2.09	**0.0374**	-16.23, -0.49
	Yes	50 ± 24			
ESRF (n=240)	No	44 ± 24	-1.25	0.234	-23.35, 6.27
	Yes	63 ± 26			
IHD (n=240)	No	43 ± 23	-2.07	0.0546	-27.42, 0.30
	Yes	65 ± 14			
Fever (n=240)	No	43 ± 24	-1.99	0.0551	-41.92, 0.48
	Yes	55 ± 23			
Raised TW (>10.0x10^9/L) (n=222)	No	43 ± 24	-2.49	**0.0141**	-21.26, -2.43
	Yes	49 ± 29.5			
Raised CRP (>9.1mg/L) (n=136)	No	47 ± 22.5	-2.21	**0.0287**	-23.35, -1.30
	Yes	48 ± 29			

Table 2: Spearman's Correlation of Continuous Variables

	Median (n ± IQR)	Median Days to Healing (n ± IQR)	Spearman's rho	p-value	95% CI
Age (n=240)	51 ± 27	45 ± 25	0.182	**0.00467**	0.05, 0.31
BMI (n=202)	26.75 ± 7.53	45 ± 28.5	0.0320	0.650	-0.12, 0.18
Duration (days) (n=228)	7 ± 13.5	45 ± 25	0.0140	0.839	-0.13, 0.15
Abscess Area (n=236)	11.78 ± 13.98	45 ± 25	0.297	$\mathbf{3.49 \times 10^{-6}}$	0.17, 0.42
Cavity Area (n=222)	7.46 ± 11	45 ± 25.75	0.337	$\mathbf{2.59 \times 10^{-7}}$	0.21, 0.47

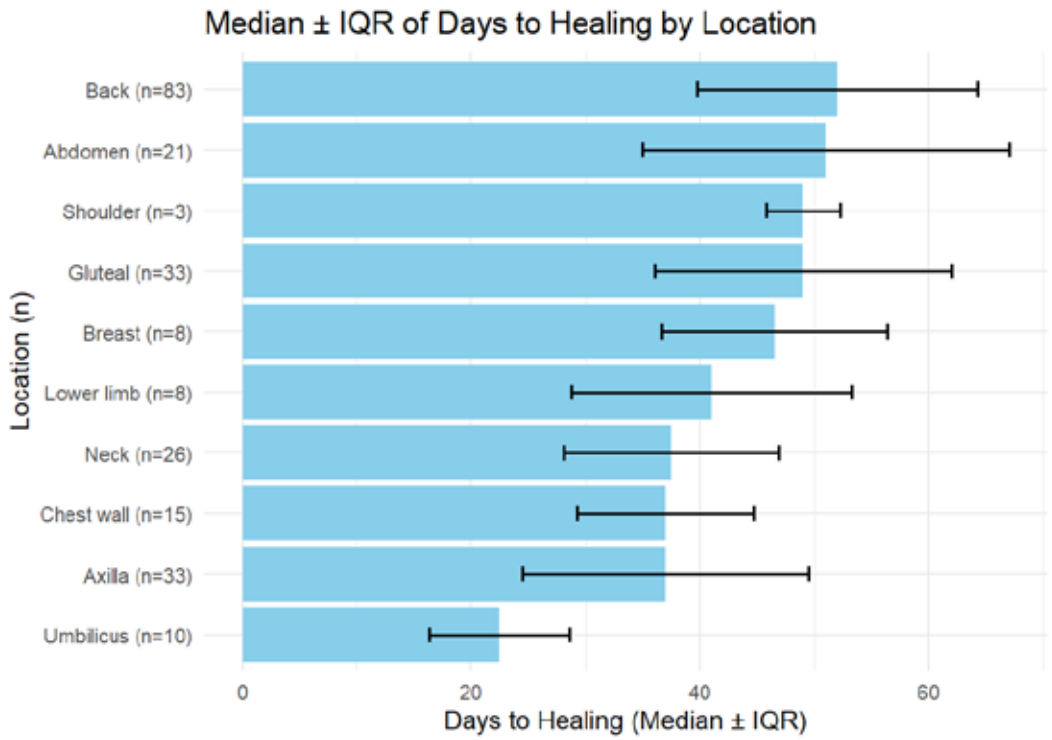

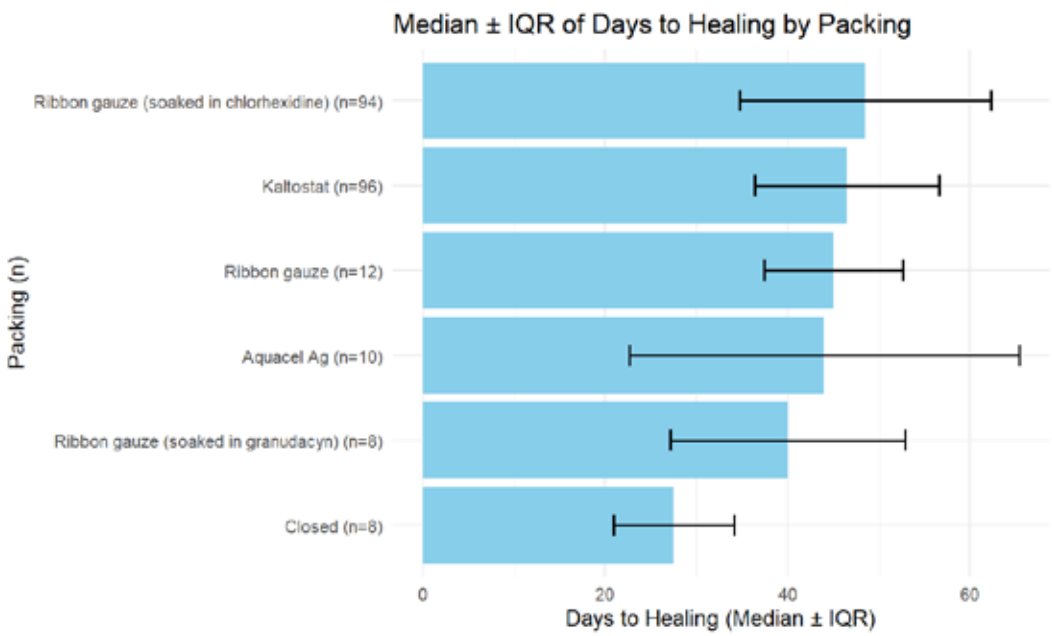

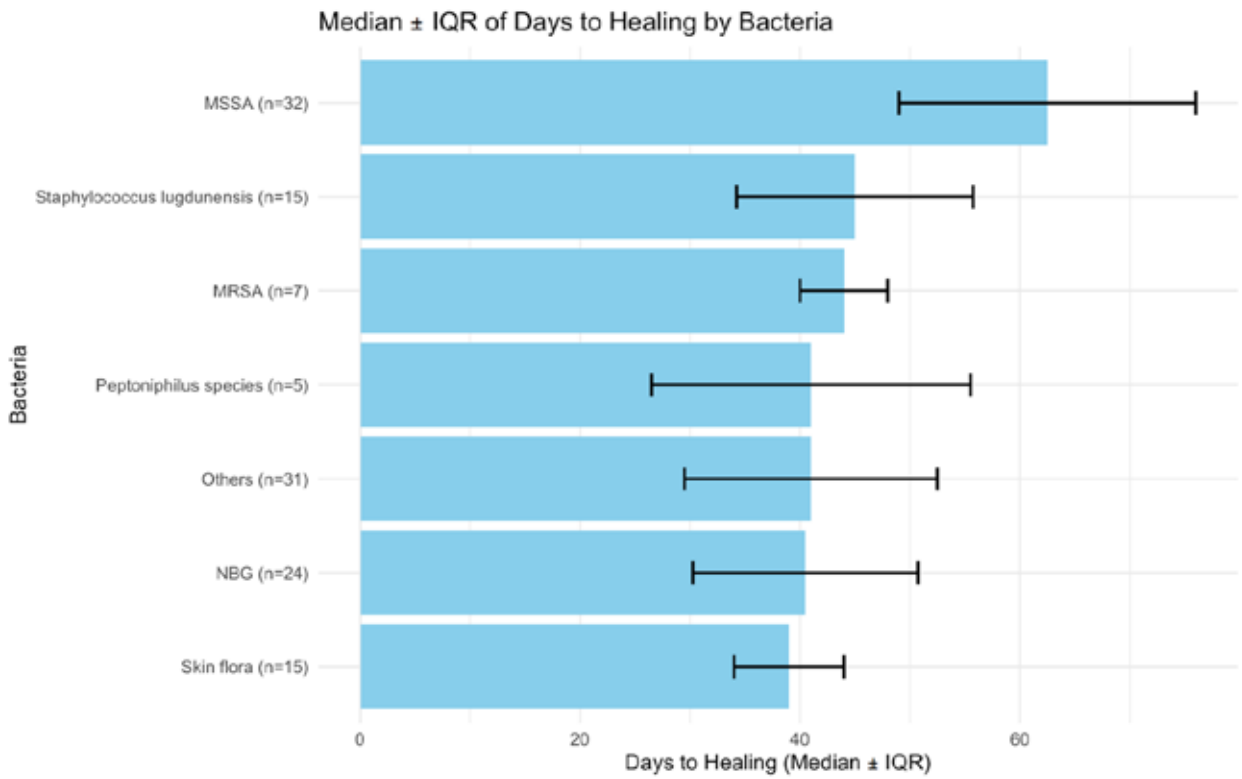

EP015 Development and evaluation of an Aloe vera and Calendula healing gel

Juliana Lucinda dos Santos[1], Fabiola Didier[2]

[1]Entre nós, São Paulo, Brazil, *[2]Universidade do Vale do Sapucai, Careaçu, Brazil*

Aim: To develop and evaluate the healing effects of a topical blend containing *Aloe vera* and *Calendula officinalis* in an excisional wound model.

Method: Forty male Wistar rats were randomized into two groups: (i) control (gel base without extracts) and (ii) treatment (gel containing the herbal blend). Full-thickness excisional wounds (16 cm^2) were surgically induced and treated topically once daily for 28 days. Wound contraction was assessed on days 9, 16, 23 and 30. Histological analysis of the wound bed included fibroblast proliferation, collagen deposition, neovascularization, re-epithelialization and inflammatory infiltrate. Comparative statistical analysis was performed, with significance set at $p < 0.1$.

Results / Discussion: Both groups demonstrated progressive wound contraction over time. On day 30, the treatment group showed significantly greater reduction in wound area compared with the control ($p < 0.1$). Histological evaluations revealed tissue remodeling in both groups, characterized by re-epithelialization, fibroblast activity and collagen organization. Although no statistically significant differences were observed in individual histological parameters, qualitative improvements in tissue organization were more evident in the treatment group.

Conclusion: The topical blend containing *Aloe vera* and *Calendula officinalis* enhanced wound contraction in an experimental excisional model, supporting its potential as an accessible option for cutaneous wound care. Further studies using larger samples and molecular analyses are warranted to clarify underlying mechanisms and optimize formulation efficacy.

EP016 Inflammatory nail environment undergoing treatment with nail brace therapy

Christine Kuberka-Wiese[1]

[1]Verband Deutscher Podologen VDP e.V./ German Podiatric Association VDP e.V., 06571 Rossleben-Wiehe, Germany

Aim: The aim is to show the effect of a by a podiatrist custom- made nail brace device in an inflammatory nail surrounding.

Method: In 10 cases it is shown how the, from a 0,5mm chrome-nickel-wire of the podiatrist in Germany individually manufactured, nail brace affects the nail surrounding and the shape of the nail over a period of about 6-12 months.

Results / Discussion: Ingrown toenails with pus in the nail surrounding are conservatively treated in podiatric practices in Germany. With the support of podiatric padding, tamponade, wound disinfection and a nail brace model Ross Fraser (0,5mm feather-hard chrome nickel wire) after impression and positive model success is mostly satisfactory especially for anxious patients with bad surgery experiences.

Conclusion: Results show that this conservative nail brace therapy is an alternative treatment to surgical nail intervention and allows inflammation in the nail fold to heal more quickly.

EP391 Holistic approach to the treatment of skin and soft tissue infections

Zülal Özkurt[1], Esra Cınar Tanrıverdi[2]

[1]Atatürk University, Medical School, Department of Infectious Diseases and Clinical Microbiology, Erzurum Türkiye, Department of Medical Education (MD), Department of Public Health (PH), Erzurum, Türkiye, *[2]Atatürk University Medical School Department of Medical Education, Erzurum, Türkiye*

Aim: Skin and soft tissue infections are a significant health concern. The study aimed to demonstrate the importance of a functional and holistic approach to skin and soft tissue infections.

Methods: Patients hospitalised in the Wound Service of the Infectious Diseases and Clinical Microbiology Clinic were included in the study. Patients were evaluated holistically. Treatments that increase tissue oxygenation and nutrition were added. Tissue oedema rapidly resolved, thus restoring perfusion. Antiedema treatments given. LMWH was initiated in patients with vascular occlusion. Vasodilators and medications to increase tissue oxygenation (pentoxifylline) were administered. Haemoglobin levels were corrected in patients. Iron was started in those with low iron and ferritin levels, and folic acid and vitamin C were added. Hyperbaric oxygen therapy was administered to suitable patients. Patients with neuropathy received alpha-lipoic acid. Supplements containing multivitamins and trace elements, especially zinc were administered. A protein-rich diet was prescribed. Patients with very low albumin were given albumin. Antioxidants and anti-inflammatory supplements (e.g., Omega-3) were added, and vitamin D replacement was administered.

Results/Discussion: From 2021, 54 patients were observed. One patient with gas gangrene died, because of she did not accept arm amputation. Others were successfully treated.

Conclusion: A functional and holistic approach is essential in the treatment of skin and soft tissue infections. Individualized and sensitive medical practices should be employed in wound care.





EP017 Evaluation of the efficacy, tolerability, and acceptability of a new pain-free healing matrix in the local treatment of second-degree burns

Anne Le Touze[1], Valerie Skiba[2], Marc Chaouat[3], Silvia Gandolfi[4], Doan Julie[5]

[1]Hôpital Clocheville, Tours, France, *[2]CHU Amiens, Plastic Surgery, Amiens, France*, *[3]Hôpital Saint Louis,, Plastic and Reconstructive Surgery, Paris, France*, *[4]Hôpital Rangueil, Toulouse, France*, *[5]Urgo Medical, Paris, France*

Aim: The primary objective is to evaluate the efficacy and safety of a new, pain-free healing matrix for treating patients with burns. Secondary objectives include evaluating pain during dressing removal, treatment tolerance, the condition of the perilesional skin and acceptability of the dressing among healthcare professionals and patients.

Methods: This case series study includes 10 adult and 5 paediatric patients with second-degree burns. The new soft matrix was applied for a period ranging from a few days to four weeks. Several scheduled evaluation visits were included in the study to document wound healing progress, pain and tolerance. The parameters studied included wound condition and the ease with which the dressing could be applied or removed.

Results/Discussion: The wounds of all patients showed favourable evolution within a few days or several weeks. Treatment adherence was high. Pain experienced during dressing removal was significantly reduced. Furthermore, the matrix's ease of cutting, application, handling and ability to conform to the wound were clearly demonstrated.

Conclusion: The new pain-free healing matrix evaluated is a safe and effective treatment for second-degree burns. It promotes healing and improves patients' quality of life by reducing pain and trauma related to wound care.

EP018 Management of sternal wound infection and mediastinitis after heart surgery: association of NPWT and recostructive tools, our experience

Antonio Capo[1 2], Bianca Dalbesio[2]

[1]AIUC Italian Association of Skin Ulcers, Turin, Italy, *[2]SICCH Italian Society of Cardiac Surgery, Rome, Italy*

Aim: We evaluate the results of our treatment strategy for complex sternal dehiscence and mediastinitis.

Method: Since 2010, we have adopted a multi-phase protocol for the treatment of complex sternal dehiscence associated with infection and, in some cases, mediastinitis. The first step consists of extensive debridement with removal of the sternal wires and cultures; immediately thereafter, we begin broad-spectrum antibiotic therapy (ABT), targeted as soon as possible. Meanwhile, the wound is left open and negative pressure wound healing (NPWT) is applied.

Once negative cultures are obtained and blood inflammatory markers return to normal, reconstructive surgery is performed using titanium sternal plates and screws. The ABT is extended as needed.

Results / Discussion: Since 2010, 70 patients have been treated according to our protocol, 6 of whom died, which, considering the complexity of the cases, was a very satisfactory outcome.

The use of NPWT with an open sternum reduced the need for mechanical ventilation and the number of dressing changes.

Eliminating the use of the omentum avoided the creation of a new surgical incision with the associated risk of dehiscence.

Hospital stay was prolonged due to the need to obtain definitively negative cultures, but we had essentially no recurrences.

We achieved good sternal stability in all patients.

Only a few cases required late partial removal of the plates.

Conclusion: The use of NPWT and late sternal reconstruction with titanium plates, in association with rigorous antibiotic therapy, leads to a dramatic decrease in mortality and late complications, such as pain and sternal instability.

EP019 Tangential serial excision of wound and split thickness skin grafting

Prem Shanker[1]

[1]*Department of General Surgery, Gsvm Medical College Kanpur, Kanpur, India*

Aim: To assess the difference in efficacy of procedure in relation to take of skin graft, minimizing the number of post operative dressings and hospital stay, comparison of cosmetic result and pain control and to evaluate the need for blood transfusion during the grafting procedure, between regular debridement by knife and curette followed by skin grafting and tangential excision of wound bed and skin grafting.

Method: Tangential excision of granulation tissue of wound bed was done in a layer-by-layer fashion with the help of Humby's knife. All granulation tissue tangentially excised till whitish healthy wound bed was obtained. Split thickness skin graft harvested from thigh and applied over wound. First dressing was done on 7th post operative day.

Results / Discussion: Total 172 patients were included in the study,105 patients underwent debridement by tangential excision and 67 patients with conventional technique using a knife and curette. Immediate split thickness skin grafting was done. Over all skin graft take in tangential excision group was 98%, morbidity, pain control and treatment cost was minimal. Mean hospital stay was 10 days and with minor wounds <10 % TBSA it was 4.5 days while in conventional technique it was 85%.

Conclusion: Tangential excision followed by split skin grafting was much better tolerated by patients with better results and lesser hospital stay than traditional wound excision and split skin grafting.

ATYPICAL WOUNDS

EP023 Bioactive core–shell aerogel particles for adenosine delivery in chronic wound healing

Beatriz G. Bernardes[1 2], Clara Sousa[1], Maria Rosaria Sellitto[3], Ana Iglesias-Mejuto[2 4], Pasquale Del Gaudio[3], Raquel Costa[1], Carlos A. García-Gonzaléz[2], Ana Oliveira[1]

[1]*Universidade Católica Portuguesa, CBQF - Centro de Biotecnologia e Química Fina – Laboratório Associado, Escola Superior de Biotecnologia, Porto, Portugal*, [2]*AerogelsLab, Department of Pharmacology, Pharmacy and Pharmaceutical Technology, I+D Farma group (GI-1645), iMATUS and Health Research Institute of Santiago de Compostela (IDIS), Universidade de Santiago de Compostela, Santiago de Compostela, Spain*, [3]*Department of Pharmacy, University of Salerno, Salerno, Italy*, [4]*Porto, Portugal*

Aim: Chronic wounds require biomaterials that combine structural integrity with controlled delivery of bioactive agents. This study aimed to develop and characterize core–shell aerogel particles composed of silk fibroin (SF), silk sericin (SS), and alginate (ALG) for sustained release of adenosine (ADO), a nucleoside with anti-inflammatory and pro-regenerative properties.

Method: Core–shell particles were fabricated using coaxial prilling followed by supercritical carbon dioxide (CO_2) drying under mild conditions to preserve ADO bioactivity. Two architectures were produced: SF/ALG cores with ALG shells and SF/ALG cores with ALG/SS shells. Physicochemical characterization included scanning electron microscopy (SEM), Fourier-transform infrared spectroscopy (FTIR), principal component analysis (PCA), and textural analysis. Drug loading and release were quantified by high-performance liquid chromatography (HPLC), while swelling behavior was assessed under different pH conditions. Biological performance was evaluated through cytocompatibility assays with human dermal fibroblasts (HDF), keratinocytes (HaCaT), and microvascular endothelial cells (HDMEC), anti-inflammatory tests in lipopolysaccharide (LPS)-stimulated HaCaT cells, and angiogenic assessment via the chorioallantoic membrane (CAM) assay.

Results / Discussion: Particles exhibited high porosity (94-97%), pH-responsive swelling, and specific surface areas up to 451 m^2/g. FTIR and PCA confirmed structural integrity and compositional differentiation. ADO encapsulation achieved moderate loading (0.98–1.36%) with controlled release influenced by shell composition. Biological assays demonstrated excellent biocompatibility, significant reduction of pro-inflammatory cytokines, and angiogenic potential in CAM assays.

Conclusion: Silk-based core–shell aerogels effectively protect ADO and enable sustained release while promoting anti-inflammatory and angiogenic responses, positioning them as innovative platforms for chronic wound treatment and regenerative medicine.

EP392 Tuberculosis of Finger mimicking a Neoplasm

Andika Winata[1]

[1]*Eka Hospital, Tangerang, Indonesia*

Aim: Cutaneous tuberculosis remains an uncommon clinical entity, often presenting with non-specific features that can delay diagnosis and lead to inappropriate management. This challenge is amplified when lesions resemble malignant skin conditions. This case highlights the diagnostic pitfalls of cutaneous tuberculosis, the value of tissue biopsy, and the need for heightened awareness among clinicians to avoid misdiagnosis and ensure timely treatment.

Method: This is a case report of 45 years old male, worker, non smoking with no underlying co-morbid illness, presented with a two-month history of an ulcer on the right index finger. It began with a small rounded redness lession on proximal digit. Initially, it was painless and did not restrict finger movement but after month the lession getting bigger and a bit painful and restrict the movement. He had no other skin lesions or rashes on his body and had never had a similar complaint before. There are no systemic symptoms such as fever, chills, night sweats, or insomnia.

After having a biopsy and pus drainage, mycobacterium was found, and treated with anti tuberculosis drug.

Results / Discussion: To diagnose cutaneous tuberculosis, a combination of clinical suspicion, microbiological tests, including PCR (the most sensitive), and histology must be considered. A regiment of rifampicin, isoniazid, pyrazinamide, and ethambutol is followed by a next course e of only rifampicin and isoniazid helps the infection treated.

Conclusions: This case highlights the diagnostic pitfalls of skin lession mimicking a cutaneous squamous cell carcinoma (cutaneous tuberculosis). The value of tissue biopsy, and the need for heightened awareness among clinicians to avoid misdiagnosis and ensure timely treatment.

EP025 Efficacy report of MEBT/MEBO combined with multi-surgery-technique in the treatment of bone (joint) exposure wounds

Yongchong Chen[1]

[1]*Shantou MEBO Pharmaceutical, Beijing, China*

Aim: To summarize and analyze the clinical efficacy of Moist Exposed Burn Therapy/Moist Exposed Burn Ointment (MEBT/MEBO) combine with multi-surgery-technique in the treatment of bone (joint) exposure wounds, thereby providing reference for the management of such complex wounds.

Method: A total of 319 patients with bone (joint) exposure wounds admitted between January 2018 and December 2024 were included. They were treated with combined techniques such as MEBT/MEBO + amputation, MEBT/MEBO + bone marrow drilling + flap transfer, sequestrectomy + MEBT/MEBO+ microskin grafting, and open arthrodesis + MEBT/MEBO. Relevant data were collected to analyze and evaluate the clinical outcomes.

Results / Discussion: Among the 319 patients, 16 were lost to follow-up. Of the remaining 303 patients, 225 were cured and discharged, yielding a cure rate of 74.26%. Forty-one patients showed significant improvement and were effectively discharged, resulting in an effective rate of 13.53%. Thirty-seven patients died (primarily elderly patients with multiple underlying diseases). The wound healing time ranged from 10 to 187 days, with an average healing time of 49.5 ± 31.25 days.

Conclusion: MEBT/MEBO combine with multi-surgery-technique can effectively treat various types of bone (joint) exposure wounds, offering more therapeutic options for managing these complex conditions.

EP026 Bioactive technology in managing peristomal and PEG-related wound complications: A case series

Chausha Weitman Cernica[1], Claudia Poggi[1], Shoshi David[1]

[1]*Hadassah Medical Center, Jerusalem, Israel*

Aim: To evaluate the effectiveness of chitosan dressing in managing peristomal wound complications and wounds associated with percutaneous endoscopic gastrostomy (PEG). Peristomal complication can significantly impair quality of life, leading to skin breakdown, leakage, odor, pain, and discomfort. Timely and effective wound management is essential to reduce morbidity and improve patient outcomes.

Method: 16 patients, 7% in one year (N226) presenting with stoma-related wounds of various etiologies were assessed and treated by a specialist nurse over a two month period. Cases included mucocutaneous separation and other complex pristomal wound presentation. Most patients had undergone emergency surgery, resulting in tension at the stoma-skin suture line. Additional risk factors included malnutrition and poor tissue perfusion.

Standard wound care protocols were followed, including cleansing prior to the application of chitosan dressing as the primary contact layer. Chitosan is a bioactive material that accelerates the natural healing process through a unique combination of hemostatic, antibacterial, and tissue-regenerative properties. Wound assessments were conducted at each dressing change, evaluating wound appearance, exudate level, periwound skin condition, and patient comfort.

Results / Discussion: All patients demonstrated marked improvement in wound healing parameters, including cleaner wound beds, reduced leakage, decreased pain and discomfort, and formation of granulation tissue leading to closure.

Conclusion: This case series supports the use of chitosan dressings as an effective primary contact layer for managing a range of peristomal and PEG-related wound complications.

Positive outcomes were observed across diverse wound types and patient profiles, including those with significant comorbidities.

EP393 Activation of stagnant chronic wounds using a polylactic acid matrix in an outpatient setting

Bert Drijkoningen[1], Kristof Balliu[1]

[1]*Yarrow BV, Bree, Belgium*

Aim: Chronic venous leg ulcers (VLU) may enter a biologically stagnant phase despite appropriate standard of care, characterized by minimal wound area reduction and absence of granulation tissue formation. This impaired metabolic microenvironment limits progression toward healing.

The aim of this prospective case series was to evaluate whether a bioactive polylactic acid (PLA) matrix can function as a metabolic reactivation tool in clinically stagnant chronic leg ulcers in an outpatient setting.

Methods: A prospective observational case series was conducted in an outpatient wound care clinic.

Seven patients with chronic leg ulcers showing insufficient progression under appropriate standard of care were included. Stagnation was clinically defined as:

- Minimal visible granulation tissue
- Pale, poorly vascularized wound bed
- Lack of meaningful wound area reduction over time despite appropriate therapy

The study population consisted of six venous leg ulcers and one traumatic leg ulcer.

Following standard wound bed preparation, a single application of a bioactive PLA matrix was performed. Standard of care was continued, including compression therapy in all venous leg ulcers.

Clinical assessments were performed at baseline and within 7 days after application, followed by continued follow-up. Parameters evaluated included:

- Onset of visible granulation tissue
- Changes in wound bed color and vascularization
- Clinical signs of metabolic activation
- Wound size progression
- Safety outcomes

Results: All seven wounds (7/7) demonstrated clear clinical signs of wound bed activation within 7 days following PLA application.

Wound beds transitioned from pale, non-granulating surfaces to visibly red, vascularized tissue with new granulation formation. Increased tissue vitality was observed in all cases.

No treatment-related adverse events occurred.

During continued follow-up, sustained wound progression was observed in the majority of patients, with ongoing granulation tissue development and reduction in wound size compared to baseline.

Discussion: The observed rapid transition from a clinically stagnant phenotype to an active granulating wound bed supports the hypothesis that the PLA matrix may act as a metabolic reactivation tool.

Controlled lactate release from PLA degradation may modulate the wound microenvironment toward a pro-healing state. Lactate is recognized as a metabolic signaling molecule capable of stimulating angiogenesis, promoting fibroblast proliferation, and supporting extracellular matrix formation. By shifting the wound from a low-metabolic to a pro-angiogenic phenotype, stalled healing processes may be reinitiated.

Conclusion: In this prospective case series of seven patients, a single application of a bioactive polylactic acid matrix was associated with rapid metabolic reactivation of clinically stagnant chronic leg ulcers, evidenced by granulation tissue formation within one week.

PLA may represent a safe and practical outpatient strategy to restore healing dynamics in venous ulcers unresponsive to conventional therapy. Controlled studies with quantitative outcome measures are required to confirm these preliminary findings.

EP027 Combined use of topical policresulen and hydrofiber dressing for biofilm-associated chronic wounds: A prospective feasibility study

Seung-eun Hong[1]

[1]Ewha Women's University, Ewha Women's University Seoul Hospital, seoul, Korea, Rep. of South

Aim: Biofilm contributes to persistent inflammation, excessive exudate, and delayed granulation in chronic wounds. Practical bedside strategies that destabilize biofilm while restoring moist balance are needed. This study aimed to evaluate the combined use of topical policresulen and a hydrofiber dressing as a biofilm-modulating approach in chronic wounds.

Method: A prospective study was conducted in 26 patients with chronic wounds exhibiting clinical indicators of biofilm (viscous slough, repeated surface debris, malodor, delayed granulation). After conservative debridement, 36% policresulen was applied weekly. A hydrofiber dressing (Aquacel Extra) was then applied and changed every 2–4 days based on exudate volume. Outcomes assessed over 4 weeks included slough thickness (0–3), exudate viscosity (0–3), debris re-accumulation frequency, granulation quality, wound-area change, patient discomfort, and semi-quantitative swab cultures.

Results / Discussion: By week 2, slough score improved from 2.5 to 1.0 (60% reduction) and exudate viscosity from 2.3 to 0.8 (65% reduction). Debris re-accumulation frequency decreased from 4.0 to 1.6 episodes/week. At week 4, granulation quality improved in 77% of wounds and mean wound-area reduction reached 30%. Swab cultures showed ≥1-log bacterial reduction in 65% of cases. These findings suggest synergistic effects: policresulen weakens biofilm matrix and removes devitalized tissue, while the hydrofiber dressing absorbs excess exudate, immobilizes loosened debris, and maintains optimal moist balance.

Conclusion: The combined use of topical policresulen and hydrofiber dressing appears to be a practical and effective bedside strategy for biofilm-associated chronic wounds. Further controlled studies are warranted.

EP028 Experimental study of the effectiveness of rat skin wound healing in complex immunosuppression

Irina Shestel[1], Ivan Pikirenia[2]

[1]State Institution «Minsk Scientific and Practical Center for Surgery, Transplantology and Hematology», Belarusian State Medical University, Minsk, Belarus, *[2]State Institution «Minsk Scientific and Practical Center for Surgery, Transplantology and Hematology», Minsk, Belarus*

Aim: The use of a complex of immunosuppressive drugs in transplantation is important to prevent rejection, but it can potentially have a negative effect on skin wound healing.

Method: The study was conducted on a model of white laboratory rats. A 1x1 cm skin wound was formed in the scapular. In group 1 (study group, n=12), animals were injected with immunosuppressive drugs– a combination of dexamethasone (0.8 mg/kg), tacrolimus (0.3 mg/kg), MMF (100 mg/kg). In group 2 (n=12), rats did not receive any medications or wound treatment. The dynamics of the wound area was evaluated, morphological and immunohistochemical examination of skin tissue samples in the wound area was performed.

Results: When analyzing the dynamics of the wound surface area during 21 days, its reduction was insignificant, while in animals of group 2, complete healing of the defect occurred by 7-10 days. The maturation of granulation tissue in the rats of the study group was sharply slowed down, the stratification of the wound layers was disrupted, large areas of necrosis, by day 21 there was no epithelialization, and no pronounced positive dynamics was observed. According to an immunohistochemical study in group 1 rats, the average values of osteopontin expression decreased (by 28.7%), Ki-67 (by 19.5%), CD31 (by 32%) and CD34 (by 37.3%), $p<0.05$, the ratio of metalloproteinases was disrupted (the content of MMP-1 significantly increased, the concentration decreased of MMP-2 and MMP-9).

Conclusion: An experimental study demonstrates the negative effect of a complex of immunosuppressive drugs on the wound healing process by disrupting wound cleansing, formation and restructuring of granulation and connective tissue.

EP029 Necrotizing fasciitis of the lower extremity: risk factors, surgical strategies and adjunctive treatments associated with improved survival – A case series of 22 consecutive patients in 2025

Marcus Duda[1]

[1]*OrthoCare Cone Health Medical Group, Greensboro, NC, United States*

Aim: To improve outcomes for patients with necrotizing fasciitis of the lower extremity.

Necrotizing fasciitis (NF) is a life threatening, rapidly progressive, bacterial infection that causes fascia, muscle and subcutaneous tissue necrosis. The infection travels along avascular fascial planes and diagnosis is generally delayed due to delayed skin involvement. Current consensus (2023-2025 literature), Laboratory Risk Indicator for Necrotizing Fasciitis (LRINEC) ≥ 8 demonstrates a mortality of 45-50%.

Method: Serial surgical debridement were performed to excise non-viable tissue including all fascia, necrotic muscle, and skin. After each debridement the tissue defect was covered with Fish Skin Graft fragments (FSGf) to promote granulation coverage of tissue defects. The FSGf was directly covered with Negative Pressure Wound Therapy hydrophilic sponge (NPWT hydrophilic) and covered with a thin hydrophobic sponge with a silicone border.

Results / Discussion: The surgical technique resulted in a limb salvage rate of 59%, major amputation rate of 31% and a mortality of 1 %. A survival rate of 99%. Surgical delay demonstrated rapid biochemical deterioration with average LRINEC increase of 8 points with 7 day delay. Initial LRINEC score > 8 had 50% incidence of major amputation and initial LRINEC score >11 had a 30% mortality.

Conclusion: This case series demonstrates the importance of surgical debridement within 24 hours of presentation, including the benefits of adjunctive modalities of FSGf and NPWT hydrophilic.

EP030 Anorexia nervosa and a mixtum chronic wounds

Javorka Marković Delić[1]

[1]*Clinic Vizim, Belgrade, Serbia*

Aim: Anorexia nervosa (AN) is a psychiatric obsessive-compulsive eating disease of teenagers and adolescents (12-24 years), with a metabolic, psychological and somatic consequences. One of the complications AN is a chronic wound (CW), usually associated with co-factors. Mortality in AN is 10-20%, due to a suicide or somatic disorders.

The presentation of cinical image AN and a mixtum, multiple CW, at patient with a long term of AN and a late stage of a malabsoption syndrome.

Method: Clinical image. Low body mass index, loss of fat and muscle tissues, digestive problems, osteoporosis, amenorrhea, anemia, xerosis (dry skin), acrocyanosis, movement disorder, aggressive posture, swelling of the left lower leg with a five submaleloar CWs during 10 months. CWs,are painful, covered with layers of crusts and bloody secretion, with linear cellulitis around the wounds.

Laboratory analyses: lower values of proteins, cholesterol, minerals, estrogen, anemia, leukopenia. Color Duplex Scan: Insufficiency of VV perforantes of the left lower leg. Ultrasound of abdomen: ptosis of the stomach. Bacteriological exam: Proteus mirabilis in the wounds.

Results / Discussion: After 2,5 months with a compressive bandage, debridement, antiseptics, biostimulative laser, three wounds were healed.

Wounds in AN are often a consequences of self-injuries. The key factors for CWs are a venous stasis, injury, malabsorption syndrome and immunodeficiency. CWs are mixtum, atypical. The prevalence of AN is 0.5-1% on the young people, more common in females. BMI is <17.5 kg/m2, bulimia have 3% and depression 6% patients. On basis of AN is a family conflict, the key person is mother.

Conclusion: Patients often had a depression, anxiety, autism. The team for the treatment of AN, includes, specialists team of gastroenterology, angiology, nutrition, psychiatrist.

EP394 Pain control and comprehensive management of Martorell Hypertensive Ischemic Ulcers: A case series

Victor Gadea Lopez[1], Miguel Ángel Parada Sanchis[1]

[1]*Dermatology and Tissue Regeneration Research Unit, Health Research Institute La Fe, Valencia, Spain*

Aim: To describe the clinical approach and therapeutic outcomes of patients with Martorell Hypertensive Ischemic Leg Ulcer (HYTILU) treated in our dermatology unit using a diagnostic and therapeutic algorithm developed and implemented by our team in routine practice.

Method: A retrospective, descriptive, observational case series was conducted including all patients diagnosed with MHIU between 2022 and 2025. Inclusion criteria were: atypical painful lower-limb ulcer, preserved distal pulses, history of hypertension, absence of significant macrovascular disease, and clinical features compatible with HYTILU. Anonymous clinical data and standardized wound photographs were collected. All patients were managed following our internally developed algorithm, which includes: pain control and optimized analgesia; enhancement of blood pressure, glycemic control, and review of anticoagulation; assessment and treatment of infection; wound bed preparation with selective surgical debridement and topical corticosteroids on inflamed borders; immediate autologous seal-grafting; and portable NPWT to promote graft integration and control exudate.

Results / Discussion: All patients presented rapidly progressive necrotic ulcers with disproportionate pain and preserved pulses. Application of the algorithm resulted in consistent pain reduction, improved local inflammation, and progressive wound healing. Seal-grafting combined with NPWT facilitated graft adherence and controlled exudate. No major complications were observed. Patients showed gradual re-epithelialization and favourable tissue recovery during follow-up.

Conclusion: This case series illustrates the usefulness of a structured, team-designed clinical algorithm for managing HYTILU in a real-world setting. The small sample size does not allow validation or generalization, sharing this framework may assist clinicians facing this rare and frequently misdiagnosed condition. Further prospective studies with larger cohorts are needed to evaluate its reproducibility and clinical impact.

EP395 The clinical performance of decellularized porcine placental extracellular matrix (PPECM) in hard-to-heal wounds at a single-center: A retrospective study

Constanza Cabrera[1], Eddie Soong[2], Cristin Taylor[3], Helen Hahn[3], Chris Michaelis[2]

[1]*convatec Medical Care, Bogota, Colombia*, [2]*Charleston Wound Care Center, Mount Pleasant, United States*, [3]*Convatec Limited, Convatec Technology Center, Lexington, United States*

Aim: Cellular, acellular, matrix-like products (CAMPs) were developed to augment the conventional care of hard-to-heal wounds. This retrospective, single-center study aimed to collect and evaluate real-world performance data on PPECM*, a novel CAMP produced from decellularized porcine placenta, in the management of hard-to-heal wounds.

Method: Electronic medical records at a single wound clinic were screened for patients with hard-to-heal wounds, receiving PPECM* between May 2022 – March 2024. Hard-to-heal wounds were defined as those with <50% reduction in wound area over 4-weeks of standard wound care treatment.

Results/Discussion: A total of 89 patients with a median age of 79 were included. Trauma wounds (30.3%), venous ulcers (25.8%), surgical wounds (21.3%), and diabetic ulcers (10.1%) were the most common wound types. Median wound age at first PPECM* application was 11.4 weeks [IQR: 7.3 – 20.1], and median number of PPECM* applications was 5.0 [min: 2.0, max: 13.0]. The median PAR at 4- and 12-weeks was 43.33% [95% CI: 32.92 – 64.29, n=75] and 100% [95% CI: 100 – 100, n=65]. Wound closure was observed in 63% of subjects (n=56). Kaplan-Meier (KM) estimate for median time to complete wound closure was 66 days [95% CI: 55 – 96, n=56]. KM estimates for probability of wound closure at 4-, 12-, and 20-weeks were 0.21 [95% CI: 0.05 – 0.35], 0.62 [95% CI: 0.40 – 0.76], and 0.83 [95% CI: 0.31 – 0.96].

Conclusion: Hard-to-heal wounds managed with PPECM* showed a clinically relevant reduction in wound area at 4 weeks, with a high probability of wound closure at weeks 12 and 20. PPECM* may provide an optimal environment for healing, supporting the closure of hard-to-heal wounds.

*PPECM: InnovaMatrix® AC, Convatec Triad Life Sciences, LLC, Memphis, TN, USA

EP396 Real-world use of porcine placental extracellular matrix (PPECM) in hard-to-heal wounds: Retrospective, multicenter analysis

Constanza Cabrera[1], Caroline E. Fife[2 3], Ben LeBoutillier[3], Helen Hahn[4], Cristin Taylor[4]

[1]Convatec, Bogota, Colombia, *[2]Baylor College of Medicine, Houston, United States*, *[3]Intellicure, LLC, The Woodlands, United States*, *[4]Convatec Limited, Convatec Technology Center, Lexington, United States*

Aim: This multicenter analysis of real-world data describes the clinical performance of PPECM*, a novel cellular, acellular, matrix-like product, in a medically complex patient population with severe, limb-/life-threatening (L/LT) wounds.

Method: The US Wound Registry aggregates electronic health records from 502 wound centers. From this, a deidentified dataset from 10-Oct.-2022 to 25-Mar.-2024 containing 76,278 patients with 248,278 wounds was screened for patients receiving PPECM*.

Results/Discussion: 60 wounds in 41 patients were managed with PPECM*. Median patient age was 74 years [IQR, 66.0 – 80.0], 32 patients (78%) were ≥65 years old, 49% had impaired ambulation, 12% autoimmune disease, and 12% peripheral arterial disease. Wound types included: chronic ulcers (30%), diabetic ulcers (20%), pressure injuries (12%), dehisced surgical wounds (12%), venous leg ulcers (10%), traumatic wounds (8%), and arterial ulcers (3%). 17% were present >1 year; 87% showed signs of bioburden; and 52% were L/LT. Only 3% had no necrotic tissue at first application. Wound age at first PPECM* application was 91.0 days [IQR: 61.0-249.0]. Median PPECM* applications per wound was 2.0 [IQR: 1.0 – 5.0]. Median percent area reduction at 4-, 8-, and 12-weeks was 55.8% [IQR: 19.6-97.9, n=40], 96.7% [IQR: 54.5-100, n=37], and 100% [IQR: 78.0-100, n=34]. Closure was achieved in 32 wounds (of which 44% were L/LT); 5 showed major improvement (60% L/LT); 13 experienced Modest Improvement, Stalled, or Deteriorated (MISD); 10 did not have outcomes reported. No adverse events or complications were reported.

Conclusion: In this real-world dataset, hard-to-heal wounds managed with PPECM* showed clinically meaningful, rapid progress toward closure, in the setting of high wound complexity and judicious product utilization.

*PPECM: InnovaMatrix® AC, Convatec Triad Life Sciences, LLC, Memphis, TN, USA

EP397 Hypochlorous acid-based irrigation solution as an alternative to normal saline for intraoperative wound irrigation in patients undergoing vascular surgery – results of a large-scale randomised controlled trial

Simon Classen[1], Peter Engels[2], Anna Borm[1], Yanina Kozovska[1]

[1]Kerckhoff-Harvey Gefäßzentrum, Bad Nauheim, Germany, *[2]Engelsconsult, Bergisch Gladbach, Germany*

Aim: Comparison of the efficacy and safety of a hypochlorous acid-base rinsing solution (HOCl)* with that of normal saline (NS) for intraoperative wound irrigation during vascular surgery.

Method: A prospective, single-centre, randomised, double-blinded, two-arm controlled clinical trial recruiting patients who underwent vascular surgery in the groin area for a bypass or a thromboendarterectomy procedure in the leg area was performed. Either a normal saline solution (0.9% sodium chloride) or HOCl-based solution was applied prior to the wound closure. Both solutions were delivered in neutral white bottles. Primary outcome measure was the development of a surgical side infection (SSI) within the first 7 days post-operatively in the hospital and up to 30 days

after discharge. Adverse events related to the solutions were recorded to evaluate the safety of both treatment arms.

Results / Discussion: 479 patients (median age of 70 years) were included in the study, while 470 patients (228 patients in the HOCl group and 242 patients in the NS group) could be included in the full data analysis. HOCl-based solution revealed to have a lower incidence of surgical side infections at 5.70%, compared to *8.26%* in the NS group (difference not statistically significant). No solution-related adverse events were reported for both groups.

Conclusion: The results of the RCT revealed that the tested HOCl -based solution can be considered equivalent to the commonly used NS in terms of efficacy and safety and can be considered suitable for the intraoperative irrigation of wounds following vascular surgery.

*Granudacyn Wound Irrigation Solution (Mölnlycke)

EP398 Skin biopsy in the diagnosis of calciphylaxis: A scoping review

Sumangali Chandra Prasad[1], Alexandra Scholze[2], Subagini Nagarajah[3], Marghan Ansari[4]

[1]Department of Dermatology, Odense University Hospital, Odense Denmark, Odense, Denmark, [2]Department of Cardiac, Thoracic, and Vascular Surgery, Department of Clinical Research, University of Southern Denmark, Odense, Denmark, [3]Department of Nephrology, Department of Clinical Research, University of Southern Denmark, Odense, Denmark, [4]Department of Clinical Research, University of Southern Denmark, Odense, Denmark

Aim: Calciphylaxis is a rare, life-threatening condition characterized by skin necrosis and vascular calcification. It is commonly seen in patients with chronic kidney disease (CKD), where it is referred to as calcific uremic arteriolopathy (CUA). Diagnosis is challenging, and while skin biopsy can aid in confirming the diagnosis, there is no consensus on the optimal technique; specifically regarding biopsy depth, tissue volume, and the method itself.

Our scoping review aimed to map current practices in skin biopsy for the diagnosis of calciphylaxis, focusing on the types of biopsies performed, related histological findings, and reported complications.

Method: A systematic search of PubMed and Embase was conducted in April, 2025. We included studies that involved patients diagnosed with calciphylaxis and used skin biopsy as part of the diagnostic process. Data were extracted on biopsy techniques, depth, related histopathological results, and complications.

Results / Discussion: A total of 47 studies were included in the review.

- *Biopsy Technique*: Punch biopsy was the most commonly used method, typically with a 4-5 mm punch.
- *Biopsy Depth*: Few studies provided details on biopsy depth.
- *Related Histological Findings*: Common findings included vascular calcification, fibrin thrombi, and fat necrosis.
- *Complications*: Rarely reported, but included delayed wound healing and necrosis.

Table 1. Distribution of biopsy methods across included studies

Biopsy method	n	%
Punch biopsy	29	61.7%
Telescopic punch biopsy	6	12.8%
Incisional biopsy	8	17.0%
Wedge biopsy	4	8.5%
Excisional biopsy	5	10.6%
Full-thickness biopsy	2	4.3%
Core-needle biopsy	2	4.3%
Shave biopsy	1	2.1%

Conclusion: Skin biopsy remains an important diagnostic tool in calciphylaxis, provided that sufficient tissue is obtained and findings are interpreted in a clinical context. Our review highlights the need for further standardization regarding biopsy depth, awareness of potential complications, and better reporting practices in future clinical studies.

Table 2. Examples of reported biopsy depth in selected studies

Study (Author, Year)	Biopsy method	Reported depth or detail
Helmeczi 2021	Punch biopsy	Specific mention of 2 mm punch, repeated twice
Zulauf 2022	Full-thickness biopsy	Recommends minimum depth of 4-5 mm to reach subcutis
Rondbjerg 2023	Punch biopsy	4 mm from both lesional and non-lesional skin
Kahn 2022	Punch biopsy+ surgical excision	4 mm punch biopsy performed first
Kochhar 2025	Punch biopsy (x2)	Two 4 mm biopsies; 4-5 mm depth recommended
Nugent 2022	Telescopic punch biopsy	6 mm outer + 4 mm inner punch; included subcutis
Mask-Bull 2019	Core-needle biopsy	10-20 mm length, image-guided
Toker 2023	Telescopic punch biopsy	Mean punch size: 4,2 mm; positive if subcutis was sampled
Rotondi 2020	Telescopic punch biopsy	4-5 mm punch reaching dermis and subcutis; edge-to-center sampling

Key Takeaways: Punch biopsy is most common. Few studies report biopsy depth. Complications reporting is mostly lacking

EP031 Competence and care: The decisive role of specialized nursing in a suspected case of loxoscelism in the Amazon

Rogério Nunes Aguiar[1], Juliana Lucinda dos Santos[2]

[1]*Instituto Rogerio Nunes, Manaus, Brazil*, [2]*Prime Care, Santo Andre, Brazil*

Aim: The Amazon is a region with a high prevalence of accidents caused by venomous animals, especially spiders, whose identification is often difficult, hindering timely diagnosis and treatment. Cases of loxoscelism pose severe tissue risks, requiring specialized care to prevent necrosis and functional sequelae.

Method: This is a descriptive case report based on direct observation during three consecutive sessions conducted by a nurse specialized in wound care, laser therapy, and ozone therapy. The patient, a rural worker, suffered a bite from an unidentified spider and was initially treated with tetanus and antivenom sera. Specific interventions were applied: cleansing with 0.9% saline solution, polyhexamethylene biguanide (PHMB) for 5 minutes, conservative debridement, red and infrared laser therapy (1 J/cm^2 each), ozone therapy in a bag (20 minutes, 40 µg/mL), and lipid colloidal dressing impregnated with silver.

Results / Discussion: After the first session, a significant reduction in pain and edema was observed, along with the beginning of granulation tissue formation. The second session showed marked improvement in hyperemia, mobility, and wound healing progression. The third session demonstrated initial epithelialization, consolidating the restorative process. The combination of antivenom serum and advanced nursing interventions proved effective in preventing necrosis and infection, accelerating the patient's functional recovery.

Conclusion: This case highlights the crucial role of specialized nursing in managing arthropod-related accidents in remote Amazon regions, emphasizing the importance of training in modern therapeutic technologies to ensure efficient healing and prevent severe complications.

BASIC SCIENCE

EP032 Nerve regeneration using hydrogel of mussel adhesive protein

Sang Wha Kim[1], Young Joon Jun[2]

[1]Seoul National University, College of Medicine, Seoul National University Hospital, Seoul, Korea, Rep. of South, *[2]Seoul St Mary Hospital The Catholic University of Korea, Seoul, Korea, Rep. of South*

Aim: Autologous nerve grafting has been applied as the best method of treating peripheral nerve defects but it has problems such as donor site morbidity. If the defect is more than 2 cm, direct suture is difficult and the nerve conduit is used for nerve regeneration. In addition, nerve repair by suture can damage nerve tissue. Therefore, we would like to repair nerve using hydrogel of mussel adhesive protein. We use mussel adhesive protein to induce nerve regeneration without suture of nerve injury site and compare with conventional nerve repair by suture.

Method: We made a 10mm long defect in the sciatic nerve of 46 rats and divided to subgroups. 1) Normal (positive control), 2) Sham (negative control), 3) Direct anastomosis –suture, 4) Direct anastomosis by fibrin glue, 5) Direct anastomosis by Mussel adhesive protein (MAP). After 6 weeks, nerve conduction velocity (NCV) and histological observations were made.

Results / Discussion: In vivo results revealed that the NCV was improved more in the experimental groups after 6 weeks from nerve repairing by MAP than in the control group by suture. Histologic(H&E, Toluidine blue staining) and immunohistochemistry(Nestin, MAP–2, GFAP) staining showed more regenerated nerve findings.

Conclusion: In this study, we propose nerve repair by MAP because of shortening operation time and additional nerve damage by suture, Additionally Mussel adhesive protein with substance P propose to be a good method of promoting nerve regeneration.

EP399 The effects of adipose derived stem cells on peripheral nerve regeneration

Young Joon Jun[1]

[1]Seoul St Mary Hospital The Catholic University of Korea, Seoul, Korea, Rep. of South

Aim: Autologous nerve grafting has been applied as the best method of treating peripheral nerve defects but it has problems such as donor site morbidity. Thus, this research was planned in order to see if it is possible to culture adipose derived stromal cells(ASCs) and differentiate and multiply them to neuronal cells and to graft the neuronal progenitor cells and ASCs into nerve defects bridged with polycaprolactone(PCL) nano–tube in vivo and examine the effects of the grafting on nerve regeneration.

Method: Using ASCs, neurogenic differentiation was induced in a mono-layered culture medium containing neuronal induction agents. In addition, we made a 15mm long defect in the sciatic nerve of 30 rats and connected a PCL nano–tube to the defect. Then, we grafted neuronal progenitor cells differentiated from ASCs. After 10 weeks from the grafting, nerve conduction velocity (NCV) and histological observations were made.

Results / Discussion: ASCs differentiated to the neuronal cells were observed in a monolayered culture. The NCV was improved more in the experimental groups after 10 weeks from grafting (exp 1: 18.0000 ±7.4864 m/s, exp 2: 17.4750 ±6.9259 m/s) than in the control group (4.3250 ±2.6174 m/s) ($p<0.05$). But, there was no statistical difference between experimental groups($p<0.05$). Histologic (H&E, Toluidine blue staining) and immunohistochemistric (Nestin, MAP–2, GFAP) staining showed more regenerated nerve findings.

Conclusion: This research proved that ASCs could multiply and differentiate into neuronal cells. When they were grafted into nerve defects, the grafted cells were differentiated into Schwann like-supportive cells and contributed to peripheral nerve regeneration. Further evaluation is needed to analyze the facts of grafted cells and clarify the mechanism of nerve regeneration.

EP033 In vitro evaluation of cytotoxic and proliferative effects of wound irrigation solutions on human skin cells

Ismena Mardani[1], Malin Bjursten Brailsford[1], Tina Hamberg[1], Anette Svensson Henriksson[1]

[1]*Mölnlycke Health Care, Mölndal, Sweden*

Aim: To evaluate the effect of six wound irrigation solutions on tissue viability by assessing the cytotoxic and proliferative effects on normal human epidermal keratinocytes (NHEK) and normal human dermal fibroblasts (NHDF).

Method: NHEK and NHDF cell cultures in low or serum-free growth medium were exposed to wound irrigation solutions for 15 minutes, simulating a clinically relevant worst-case scenario. The exposure was dose-dependent, ranging from undiluted (100%) down to 50% dilution. Cell viability was assessed with Cell Counting Kit-8 (CCK-8) assay immediately after 15-minutes exposure, while cell proliferation was measured with CyQUANT cell proliferation assay, 24 hours post-treatment to allow for cell division to occur.

Results / Discussion: In this study, the cytotoxic and proliferative effects of six wound irrigation solutions containing hypochlorous acid (HOCl) in concentrations ranging from 0.003% to 0.08%, and polyhexamethylene biguanide (PHMB) at 0.1% were evaluated. The results demonstrated superior cell viability (across both NHEK and NHDF cells) for the two wound irrigation solutions with the lower concentrations of HOCl (0.003% and 0.004%). Higher concentrations of HOCl (0.033% and 0.08%) significantly reduced cell viability with as much as 60% ($p<0.0001$), particularly at lower dilutions. The PHMB-based irrigation solution significantly reduced cell viability for both NHEK and NHDF across all dilutions ($p<0.0001$). A similar trend was observed in cell proliferation assays, where both PHMB and higher-concentrations of HOCl irrigation solutions impaired cell proliferation with as much as 70% ($p<0.0001$) regardless of cell-type.

Conclusion: Wound irrigation solutions containing higher concentrations of HOCl (≥0.033%) or PHMB (0.1%) adversely affected cell viability and proliferation in NHEK and NHDF. In comparison, solutions with lower HOCl concentrations (0.003-0.004%) exhibited improved biocompatibility with human skin cells.

EP034 Architecture-informed engineering of a biomimetic dermal scaffold for enhanced wound healing

Aobuliaximu Yakupu[1], Chunmao Han[1], Xingang Wang[1]

[1]*Department of Burns & Wound Care Center, the Second Affiliated Hospital of Zhejiang University, School of Medicine, Hangzhou 310009, China, Zhejiang Key Laboratory of Trauma, Burn, and Medical Rescue, Zhejiang University, Hangzhou 310009, China, Hangzhou, China*

Aim: The intricate spatial structural changes during wound healing, particularly in complex skin defects, remain poorly characterized, limiting the development of biomimetic regenerative therapies. This study aims to delineate the detailed histological and spatial architecture of the healing wound and to utilize these insights to engineer a novel dermal scaffold that promotes rapid and functional tissue repair.

Method: We systematically analyzed the dynamics of wound healing using Hematoxylin and Eosin (H&E) and Masson's trichrome staining, which revealed a distinct four-layer structure within the wound bed. The three-dimensional spatial organization of the wound was further elucidated using whole-tissue clearing combined with immunofluorescence staining. Based on these structural findings, a new dermal scaffold was designed to mimic the native wound microenvironment.

Results / Discussion: Our histological analysis identified a unique, stratified architecture in the active wound, comprising four consecutive layers from the wound edge to the center. This structure underwent dynamic reorganization throughout the healing process. Spatial imaging confirmed this complex cellular and extracellular matrix arrangement. Inspired by this natural organization, we developed a novel dermal scaffold. In vitro and in vivo experiments demonstrated that this scaffold significantly enhanced key regenerative processes, most notably by accelerating robust vascularization within the wound bed, which in turn led to markedly improved wound closure rates and tissue quality.

Conclusion: This study provides a novel structural perspective on the wound healing process. The successful development of a biomimetic dermal scaffold based on these intrinsic structural findings underscores the importance of understanding native tissue architecture for regenerative medicine. Our scaffold presents a promising and effective strategy for promoting rapid wound healing through enhanced vascularization.

EP035 Comparative effects of immediate versus delayed cryotherapy on wound healing

EunSoo Park[1], Galina Khan[1], DongGyu Kim[1], Hangyu Cha[1], Seungmin Nam[1]

[1]Soonchunhyang university Bucheon Hospital, Bucheon, Korea, Rep. of South

Aim: In this study, we compared immediate and delayed application of superficial cryotherapy and selective cryolysis using a rat wound model.

Method: Model: 16 rats were divided into two groups based on the timing of cryotherapy initiation. The immediate group (I) began treatment immediately after wound formation, and the delayed group (D) began treatment 3 days after wound formation.

Cryotherapy: Both groups received TargetCool at 3°C and -3°C for 10 seconds. Cryotherapy was administered once daily for a total of three sessions. Tissue samples were collected from eight mice (four from each group) on days 7 & 14 to assess the healing process on those days.

Wound Healing Rate (WHR): Before each cryotherapy session, dorsal photographs were taken. A wound healing index was calculated to assess wound re-epithelialization.

Histopathological Analysis: Tissue samples collected on days 7 and 14 were embedded in paraffin, and histopathological analysis was performed using 1) H&E & 2) Sirius Red staining.

Results / Discussion: The immediate/-3˚ group showed the highest WHR on day 7, but there was no statistically significant difference. PCR analysis showed that TNF-α expression was significantly lower in the immediate/-3˚ group on day 7 compared to the immediate/3˚ and delayed/3˚ groups. CD34 expression was significantly lower in the delayed/3˚ group than in the other groups.

A significant difference was observed between days 4 and 7, and by day 14, both groups showed almost complete healing. Photographically, epithelialization was observed earlier in the immediate group than in the delayed group.

Conclusion: Immediate cryotherapy at -3°C showed a positive effect on wound healing.

EP036 Lactate-mediated healing in burns: Mechanistic insights into the bioactivity of pla-based membranes

Jose Ramirez-Garcialuna[1], Ana Lorena Novoa-Moreno[2], Mario Aurelio Martínez-Jimenez[2]

[1]Division of Experimental Surgery, Faculty of Medicine, McGill University, Montreal, QC, Canada, *[2]Medicine Faculty of the Autonomous University of San Luis Potosí, San Luis Potosí, Mexico*

Aim: To explore the mechanistic basis for the observed clinical efficacy of polylactic acid (PLA)-based membranes in burn wound healing, with emphasis on the role of lactate as a bioactive molecule.

Method: This mechanistic review synthesizes experimental, translational, and clinical evidence regarding the effects of lactate released from PLA-based epidermal membranes in burn injury patients. Peer-reviewed data was compiled from cellular, animal, and human studies addressing vascular, immune, and neurosensory responses to lactate signalling in the wound environment.

Results / Discussion: Lactate released from PLA-based membranes initiates a multifaceted cascade of bioactive effects essential for burn repair. First, lactate mimics hypoxic signalling and activates hypoxia-inducible factor-1α (HIF-1α), promoting neoangiogenesis via VEGF expression. Second, fibroblast survival, keratinocyte proliferation, and extracellular matrix deposition are enhanced. Third, lactate modulates inflammation by shifting macrophage polarization from pro-inflammatory (M1) to reparative (M2) phenotypes. Fourth, it lowers wound pH, creating an acidic microenvironment that impairs bacterial growth and favours enzymatic activity involved in healing. Lastly, lactate reduces nociceptor sensitization through TRPV1 channel desensitization, contributing to adequate pain control. Clinically, these mechanisms correlate with faster healing, lower infection rates, reduced need for grafting, and improved patient comfort.

Conclusion: PLA-based membranes act not only as physical wound coverings but also as bio-inductive platforms that release lactate, driving a cascade of regenerative effects. Their multifactorial action makes them uniquely suited for managing partial-thickness burns, with implications for broader use in complex wound care. Further clinical trials should continue to elucidate the optimal indications and comparative advantages of lactate-releasing dressings.

EP037 Advanced bioactive hydrogel delivery of mirna-engineered MSC-EVS for malignant wound healing in advanced cancer: Preclinical results supporting advancement to clinical trials

Danae Georghiou[1], Marina Hadjicharalambous-Ryder[2], Nikoletta Christodoulou[2], Anna Katsioloudi[2], Kyriakos Spanoudes[3], Demetra Wiedl[1], Despoina Kokkinidou[4], Giannis Andronikou[4], Eleftheria Sidira[4], Anna Christofini[4], Marianna Prokopi-Demetriades[1 2 4]

[1]Promed Bioscience Ltd, Limassol, Cyprus, *[2]Theramir Ltd, Limassol, Cyprus*, *[3]Vet Ex Machina, Nicosia, Cyprus*, *[4]RSL Revolutionary Labs Ltd, Limassol, Cyprus*

The program is funded by the European Union Recovery and Resilience Facility of the NextGenerationEU instrument, through the Cyprus Research and Innovation Foundation (ENTERPRISES/0223/Sub-Call1/0212)

Aim: Malignant wounds occur in 5–10% of advanced cancer patients and up to 14% in late-stage disease. In breast cancer, malignant fungating wounds affect up to 60–62% of locally advanced or metastatic cases and severely impair quality of life. Current treatments are mainly palliative. This study developed and evaluated a sustained-release atelocollagen hydrogel containing MSC-derived EVs engineered to overexpress wound-healing and anti-tumour microRNAs.

Methods: EVs were isolated and characterised according to ISEV guidelines using TRPS, western blotting and RT-PCR to verify miRNA enrichment. A biocompatible atelocollagen hydrogel was developed for controlled EV delivery. Cytocompatibility was evaluated by MTT assays, and irritation potential by HET-CAM. Functional efficacy was assessed via *in vitro* scratch assays, collagen and elastin expression (western blotting, RT-PCR), *ex vivo* wound closure in human skin biopsies and *in vivo* wound healing, histology and immunohistochemical analysis of extracellular matrix and angiogenesis markers in small-animal models.

Results / Discussion: The EV–atelocollagen hydrogel demonstrated excellent cytocompatibility, with no cytotoxicity and a 5% increase in cell proliferation compared with controls. HET-CAM testing showed minimal irritation (score ≤0.9). In vitro, treated cells exhibited a 20% increase in wound closure and significantly increased expression of collagen I, collagen III and elastin. *Ex vivo*, hydrogel–EV treatment achieved approximately 48% wound closure while control wounds exhibited enlargement. *In vivo*, accelerated closure was evident from day 3, with near-complete closure by day 10. Histology revealed a thicker, organised epidermis and immunohistochemistry confirmed increased collagen III and VEGFA, indicating enhanced extracellular matrix formation and angiogenesis.

Conclusion: This bioactive, sustained-release EV hydrogel demonstrates compelling preclinical efficacy and safety, supporting its advancement into further development, clinical translation and future clinical trials for malignant-wound management.

EP038 Acellular adipose matrix accelerates wound healing and enhances angiogenesis compared with synthetic collagen

Jaewoo Kim[1], Dongjian LI[2], Heewoong Yang[2], Ying Zhu[2], Ki Yong Hong[3]

[1]Department of Plastic and Reconstructive Surgery, SMG-SNU Boramae Medical Center, Seoul, Korea, Rep. of South, *[2]Department of Plastic and Reconstructive Surgery, Seoul National University College of Medicine, Seoul, Korea, Rep. of South*, *[3]Department of Plastic and Reconstructive Surgery, Seoul National University Hospital, Seoul, Korea, Rep. of South*

Aim: Acellular adipose matrix (AAM) is a decellularized adipose-derived extracellular matrix (ECM) that exhibits favorable biological properties, particularly by preserving key ECM components and the native three-dimensional architecture. Direct comparative evidence between AAM and synthetic collagen (SC) in wound healing remains limited. This study aims to address this gap and provide experimental support for the clinical translation of AAM as a superior wound repair material.

Method: Full-thickness skin wounds were established on the dorsal surface of nude mice and treated with either AAM or SC. Wound healing was monitored for 14 days by measuring the wound area. Histological assessments, including H&E staining, Masson's trichrome staining, and CD31 immunohistochemistry were performed to evaluate re-epithelialization, collagen deposition, and angiogenesis.

Results / Discussion: During the early postoperative phase (days 1–10), wound healing rates were comparable between the two groups. However, in the later phase (days 11–14), wounds treated with AAM exhibited significantly accelerated healing compared to the SC group ($p < 0.01$). Hematoxylin and eosin (H&E) evaluation demonstrated that AAM treatment resulted in a significantly greater epidermal thickness ($p < 0.001$). Immunohistochemistry results further showed that the AAM group exhibited a markedly larger $CD31^+$ vascular area ($p < 0.001$) compared with the SC group.

Conclusion: AAM outperformed SC in promoting wound healing, demonstrating superior advantages in angiogenesis. These findings suggest that AAM represents a promising bioactive material for clinical wound regeneration, offering distinct benefits over conventional synthetic dressings.

EP400 Direct viral inactivation of herpes simplex through cation-releasing micelle hydrogels: Evaluation of a fentonite clay-based formulation against HSV-1

Darlene McCord[1], Robert Frykberg[2]

[1]McCord Research, Chatanooga, TN, United States, *[2]University of Texas San Antonio, San Antonio, Texas, United States*

Aim: Chronic and biofilm-rich wounds require topical technologies that can disrupt pathogens without relying on cytotoxic agents. Cation-releasing hydrogels formulated with fentonite clay —a rare-earth–rich clay with high cation-exchange capacity—may offer a non-cytotoxic strategy for microbial and viral inactivation. This study evaluated the in vitro cytotoxicity, antiviral cytoprotection, and direct viral inactivation potential of a hydrogel formulation, fentonite clay, against Herpes Simplex Virus Type 1 (HSV-1).

Method: Fentonite clay hydrogel (1:9) was assessed using validated ISO 10993-5 cytotoxicity methods and standardized HSV-1 antiviral assays. Cytotoxicity was quantified using the XTT metabolic activity assay after six days. Antiviral cytoprotection was measured in infected Vero cell cultures. Direct viral inactivation was evaluated using a 2-hour pre-exposure assay followed by $TCID_{50}$ quantification.

Results / Discussion: The fentonite clay formulation exhibited low cytotoxicity, with a TC_{50} of 4.42%, compared to the highly cytotoxic positive control, staurosporine (TC_{50} = 0.03 µM). No antiviral cytoprotection was observed in culture. However, direct interaction with the Hydrogel: Fentonite formulation resulted in a 2,800-fold reduction in HSV-1 infectivity, decreasing $TCID_{50}$ values from 1.81×10^6 to 6.40×10^2.

Conclusion: Although the fentonite clay hydrogel formulation does not provide intracellular antiviral cytoprotection, it demonstrates substantial direct viral inactivation with low cytotoxicity, supporting its potential role as a topical, non-cytotoxic mineral-based strategy for managing contaminated or biofilm-rich wound environments. These findings reinforce cation-delivery micelle systems as a promising modality for pathogen reduction in advanced wound care.

EP039 Using micelle technology to deliver cations for the elimination of wound biofilms

Robert Frykberg[1], Darlene McCord[2]

[1]University of Texas San Antonio, San Antonio, Texas, United States, *[2]McCord Research, Chatanooga, TN, United States*

Aim: Biofilm persistence remains a primary barrier to healing in chronic and surgical wounds. Negatively charged extracellular polymeric substances (EPS) shield pathogens and turn off innate immune cation-dependent pathways. This study evaluated three cation-delivering, micelle-based formulations—an anti-biofilm poloxamer hydrogel, a Fentonite suspension, and an anti-biofilm wound wash—for their ability to prevent *Pseudomonas aeruginosa* biofilm formation using the Colony Drip Flow Biofilm Reactor (CDFBR) method.

Method: Testing was conducted according to the standardized CDFBR methodology under Good Laboratory Practice guidelines. Prepared polycarbonate membranes were exposed to *P. aeruginosa* ATCC 15442 and treated with Test Article #1 (Anti-Biofilm Poloxamer Hydrogel), Test Article #2 (Fentonite Suspension A/G), or Test Article #3 (Anti-Biofilm Wound Wash). Microbial recovery (CFU/membrane) was compared with untreated controls. Log reductions were calculated using established ASTM E2647-20 procedures. No deviations impacted data integrity.

Results / Discussion: Across all three test articles, biofilm formation was reduced by 99.99% or more. Treated membranes consistently yielded bacterial counts below the detection threshold ($<4.0 \times 10^1$ CFU/membrane), compared with untreated controls, which demonstrated recoveries of 5.99×10^5 to 9.31×10^5 CFU/membrane. This corresponds to a greater than 7-log inhibition of biofilm development. All products performed equivalently, with no detectable biofilm accumulation under continuous-flow challenge conditions.

Conclusion: Cation-releasing micelle technology—delivered through poloxamer hydrogels, Fentonite suspensions, and anti-biofilm washes—demonstrated profound suppression of *P. aeruginosa* biofilm formation. The ≥7-log reductions observed confirm the effectiveness of these formulations in preventing early biofilm assembly. These findings support the clinical utility of cation-based micelle systems as a non-cytotoxic, biofilm-preventive strategy for chronic, surgical, and high-risk wounds.

EP040 Adipose-derived stem cells encapsulated Platelet Lysate-rich PlasmaMacroporous Hydrogel prolongs allogeneic skin graft survival via M2 macrophage recruitment and treg regulation

Danyang Ren[1], Weixue Jin[1], Celia Ho[1], Songxue Guo[1 2]

[1]The Second Affiliated Hospital of Zhejiang University School of Medicine, Hangzhou, China, *[2]Zhejiang Key Laboratory of Trauma, Burn, and Medical Rescue, Hangzhou, China*

Aim: Allogeneic skin transplantation is a crucial clinical strategy for repairing severe tissue injuries and burn wounds when autologous skin grafts are unavailable. However, skin tissue's inherent high immunogenicity leads to a higher risk of immune rejection compared to solid organ transplantation. Systemic immunosuppressive agents used to mitigate rejection often cause severe adverse effects such as nephrotoxicity, opportunistic infections, and tumorigenesis. Therefore, leveraging the immunological mechanisms of allogeneic skin transplantation, we aimed to develop a species-matched bioactive hydrogel with immunomodulatory properties to prolong graft survival, minimize systemic immunosuppression-related complications, and induce localized immune tolerance.

Methods: Platelet lysate-rich plasma hydrogel (PLP-Gel) was fabricated using adipose-derived mesenchymal stem cells (ADSCs) combined with platelet lysate (PLP), alginate (ALG), 1-ethyl-3-(3-dimethylaminopropyl) carbodiimide (EDC), and N-hydroxysuccinimide (NHS) via freeze-thaw crosslinking. ADSCs were isolated from C57BL/6 mice, identified by surface markers ($CD44^+$, $CD73^+$, $CD90^+$, $CD105^+$, $CD31^-$, $CD45^-$) and trilineage differentiation potential (adipogenic, osteogenic, chondrogenic). The physicochemical properties of PLP-Gel (pore size≈50μm, Young's modulus 53.60±8.50 kPa, in vitro degradation time >21 days) and biocompatibility with ADSCs were verified using scanning electron microscopy (SEM), laser scanning confocal microscopy (LSCM), CCK-8 assay, and Calcein AM/PI staining. In vitro, ADSC@PLP-Gel was co-cultured with RAW 264.7 macrophages and mouse splenic $CD4^+$ T cells. Macrophage polarization (Arg1, CD206 for M2; iNOS, CD86 for M1) and Treg differentiation ($CD4^+$ $Foxp3^+$) were analyzed by Western Blot, RT-qPCR, immunofluorescence, and flow cytometry. In vivo, a mouse allogeneic skin transplantation model was established (donor: BALB/c mice; recipient: C57BL/6 mice), with groups including Isograft (C57BL/6→C57BL/6), Control (no treatment), ALG-Gel (blank alginate hydrogel), PLP-Gel, and ADSC@PLP-Gel. Graft survival was monitored for 12 days. Histopathological changes (H&E staining), local immune cell infiltration, cytokine expression (IL-10, TGF-β, IL-6, TNF-α), and splenic Treg proportion were evaluated by immunohistochemistry, immunofluorescence, Western Blot, RT-qPCR, and flow cytometry.

Results: ADSC@PLP-Gel exhibited a highly porous interconnected structure with excellent biocompatibility, supporting ADSC adhesion and proliferation. In vitro, ADSC@PLP-Gel significantly enhanced macrophage chemotactic recruitment (higher than Control, $P<0.01$), promoted M2 polarization (Arg1 and CD206 expression increased, iNOS and CD86 expression decreased, $P<0.05$), and induced $CD4^+$ T cell differentiation into Treg cells ($Foxp3^+$ proportion increased, $P<0.01$). In vivo, ADSC@PLP-Gel prolonged graft survival time to 12 days (vs. 6 days in Control and ALG-Gel groups, $P<0.001$), reduced inflammatory cell infiltration, and promoted neovascularization. It upregulated local M2 macrophage markers (CD206, Arg1) and Treg cell accumulation (Foxp3), increased anti-inflammatory cytokines (IL-10, TGF-β). The proportion of splenic $CD4^+Foxp3^+$ Treg cells in the ADSC@PLP-Gel group was higher than that in the Control group ($P<0.001$).

Conclusion: ADSC@PLP-Gel effectively regulates macrophage M2 polarization (M1→M2), M2 recruitment and enhances $CD4^+Foxp3^+$Treg differentiation and activation, thereby inducing local immune tolerance and significantly prolonging allogeneic skin graft survival. This study provides a safe and effective local immunomodulatory strategy for allogeneic skin transplantation, with promising clinical translation potential.

EP041 Evaluation of the effect of bacterial nanocellulose membrane incorporated with insulin on cell viability, migration, and gene expression of inflammatory mediators in vitro

Camila Quinetti[1], Carolyna Carvalho[2], Jessica Santos[3 4], Caliandra Bernardi[5], Joseane Ricciardi de Aguiar[6], Samara Silva de[7], Eliana P Araújo[2], Maria Helena Lima[2]

[1]Faculty of Nursing, Laboratory of Biotechnology and Experimental Research, Federal University of Juiz de Fora, Juiz de Fora, Brazil, *[2]School of Nursing, University of Campinas, Brazil, Laboratory of Cell Signaling, Obesity and Comorbidities Research Center, University of Campinas, Brazil, Campinas, Brazil*, *[3]School of Nursing, State University of Campinas, Brazil, Laboratory of Cell Signaling, Obesity and Comorbidities Research Center, University of Campinas, Campinas, Brazil, Campinas, Brazil*, *[4]School of Nursing, State University of Campinas, Brazil Campinas, Brazil, Laboratory of Cell Signaling, Obesity and Comorbidities Research Center, University of Campinas, Brazil, Campinas, Brazil*, *[5]Federal University of Technology - Parana, Brazil, Dois Viizinhos, Brazil*, *[6]Laboratory of Cell Signaling, Obesity and Comorbidities Research Center, University of Campinas, Campinas, Brazil, Campinas, Brazil*, *[7]Federal University of Technology - Parana, Brazil, Dois Vizinhos, Brazil*

Aim: To investigate the incorporation of insulin into the bacterial nanocellulose membrane (NCB+INS).

Method: The NCB membranes were synthesized under static culture conditions using *Komagataeibacter xylinus* grown in Hestrin–Schramm medium. After production, membranes were purified and sterilized. For incorporation, NCB and NCB+INS membranes were incubated for 24 h at 4°C with 50 μL of saline and 50 μL of human insulin,

respectively. They were then immersed for 72h in 5 mL of DMEM High Glucose medium (4.5 g/L glucose) supplemented with 1% fetal bovine serum (FBS) to obtain the conditioned medium. From this volume, 400 µL were applied per well containing HaCaT keratinocytes. Cell migration was assessed using a scratch assay at three time points (0 h, 24 h, and 48 h), and wound areas were measured using ImageJ®. After 48 h, cell viability was determined using the MTT assay, and the gene expression of vascular endothelial growth factor (VEGF), transforming growth factor-beta (TGF-β), and fibroblast growth factor 10 (FGF-10) was evaluated by quantitative PCR (qPCR).

Results / Discussion: After 24 and 48 hours, both NCB and NCB+INS groups showed wound closure, but the NCB+INS group exhibited significantly greater reduction ($p<0.0001$), indicating enhanced cell migration. Cell viability was also higher in the NCB+INS group ($p<0.0001$), demonstrating absence of cytotoxicity and increased mitochondrial activity. No significant differences were observed in VEGF, TGF-β, or FGF-10 expression, possibly due to insulin acting through rapid signaling pathways and post-transcriptional mechanisms that stimulate migration and viability without altering mRNA levels.

Conclusion: The NCB+INS membrane significantly increased keratinocyte migration and viability, modulating early stages of wound healing and reinforcing its potential as a promising biomaterial for tissue repair.

EP042 Effects of novel bioactive compounds on inflammatory pathways in an in-vitro diabetic wound model

Thomas Green[1], Mandeep Marwah[2]

[1]Aston Medical School, Birmingham, United Kingdom, *[2]Aston Medical School, College of Health and Life Sciences, Aston University, Aston Research Centre for Health in Ageing, Aston University, Birmingham, United Kingdom*

Aim: To test the effects of novel therapeutic compounds on inflammation and extracellular matrix-related pathways using an in-vitro diabetic cell model that mimics the diabetic wound environment.

Method: Human dermal fibroblasts were exposed to a diabetic-mimicking insult using high-glucose media and tumour necrosis factor-alpha (TNF-α). Cells were treated with selected bioactive compounds including naringenin, Withaferin A, epigallocatechin gallate (EGCG) and the hydrogen sulphide donor ADT-OH at concentrations determined to be non-cytotoxic by preliminary viability assays. Cell viability was assessed using a tetrazolium-based XTT assay. Inflammatory responses were quantified by measuring interleukin-8 (IL-8) secretion using enzyme-linked immunosorbent assays. Additional data from published in-vitro studies examining matrix metalloproteinase-9 (MMP-9), transforming growth factor-beta 1 (TGF-β1) and related pathways were included to contextualise experimental findings.

Results / Discussion: High-glucose conditions consistently upregulated IL-8 through epidermal growth factor receptor kinase signalling. TNF-α intensified oxidative stress and MMP-9 activity which in turn hindered fibroblast migration and disrupted collagen organisation. These effects were compounded by dysregulated TGF-β1 signalling, resulting in impaired ECM deposition. Viability assays confirmed non-cytotoxic concentrations for the compounds tested, enabling downstream analysis. Across studies, treatments with EGCG, naringenin and related molecules produced measurable reductions in IL-6, IL-8 and MMP-9, alongside partial restoration of pro-healing signalling pathways. These findings were consistent with observations from our in-vitro experiments which demonstrated similar reductions in IL-8 cytokines and MMP-9 activity following compound treatment.

Conclusion: Chronic diabetic wounds are strongly driven by inflammatory signalling and imbalances in MMP-9 and TGF-β1 activity. Bioactive compounds demonstrated reproducible anti-inflammatory and ECM-modulating effects in experimental models. These findings highlight several molecular targets that may inform future translational approaches to diabetic wound healing.

EP043 Peptide and peptidomimetic-ionic liquid conjugates as next-generation topical treatments for infected wounds

Ana Gomes[1], Inês Costa[1], Mariana Ferreira[1], Paula Gameiro[1], Paula Gomes[1]

[1]LAQV-REQUIMTE, Department of Chemistry and Biochemistry of the Faculty of Sciences of the University of Porto, Porto, Portugal

Aim: We have previously developed an unprecedented type of topical product for wound healing applications. This innovative product merges an antimicrobial ionic liquid with a cosmeceutical peptide commonly used in anti-aging formulations and displays both antimicrobial activity and enhanced wound-healing potential demonstrated *in vivo* on diabetic mice. Following these encouraging results, we are now exploring peptidomimetic derivatives to improve peptide stability and reduce conjugate size by incorporating shorter cosmeceutical peptide sequences.

Method: Several peptides and peptidomimetics were coupled to ionic liquids, and the resulting conjugates evaluated *in vitro* for their antimicrobial activity against both Gram-positive and Gram-negative bacteria. The structural diversity of the products prepared allowed for a comprehensive analysis of structure-activity relationships that will guide future work.

Results / Discussion: *In vitro* data show that: (i) shorter peptide- and respective peptidomimetic-derived conjugates retain potent broad-spectrum antibacterial activity; (ii) conjugates incorporating longer wound-healing peptide sequences were inactive against both Gram-positive and Gram-negative bacteria; and (iii) the presence of the ionic liquid core is essential for antimicrobial activity.

Conclusion: The use of shorter peptide ionic liquid conjugates and their peptidomimetic counterparts does not diminish the antimicrobial activity of the parent conjugates, which is a frankly positive outcome as shorter peptide-based constructs have lower production costs and are unlikely to trigger immunoallergic reactions. Thus, we will continue to explore these short conjugates as promising candidates for innovative interventions towards topical wound management.

EP044 Development of a biodegradable PLCL patch for transdermal drug delivery using a customized 3D printing process

Kyung Ah Lee[1], Inbaek Park[2]

[1]Haeundae Paik Hospital, Inje University, Busan, Korea, Rep. of South, *[2]AM Solution, Production Engineering Research Institute, LG Electronics, Seoul, Korea, Rep. of South*

Aim: This study aimed to develop a biodegradable patch for transdermal drug delivery systems (TDDS) utilizing poly lactide-co-ε-caprolactone (PLCL) and optimize a customized 3D printing process to ensure structural integrity and biomedical performance.

Method: PLCL, a copolymer of lactide (LA) and ε-caprolactone (CL) (Fig. 1), was selected for its superior elasticity and tunable biodegradation compared to p polycaprolactone (PCL). Specimens with varying LA:CL ratios were tested for tensile strength and elongation to determine optimal composition. A specialized high-pressure, high-temperature dispensing system was engineered for accurate extrusion. Silica-coated polyethylene terephthalate (PET) films were used as substrates to prevent deformation during detachment

Results / Discussion: PLCL (LA:CL=3:7) exhibited elongation exceeding 300% with stable morphology (Fig. 2, 3). Long-term stability tests showed time-dependent reductions in viscosity and tensile strength, validating biodegradability (Fig. 4). The process yielded patches with consistent pores and thickness, achieving 50 μm deposition accuracy per layer and successful scale-up to A4-sized constructs.

Conclusion: The PLCL-based patch produced via the customized 3D printing process demonstrated exceptional structural stability, biodegradability, and reproducibility. This study confirms that the optimized fabrication method provides a viable platform for TDDS. By effectively controlling pore architecture, the process facilitates potential drug incorporation and extended release, establishing the construct's suitability for tissue regeneration.

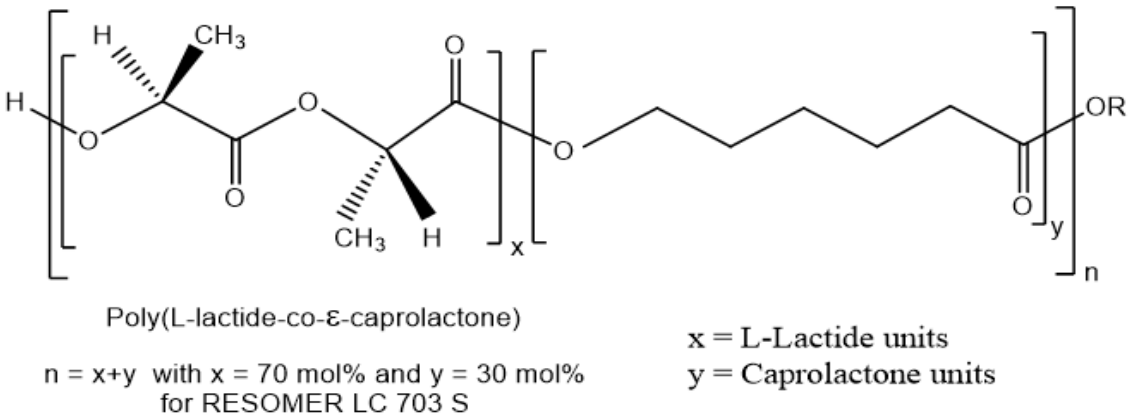

Fig. 1. Molecular structure of PLCL copolymer composed of LA and CL units.



Fig. 2. Initial white granule morphology of PLCL providing stable characteristics.



Fig. 3. PLCL (LA:CL=3:7) demonstrating high elasticity with >300% elongation.

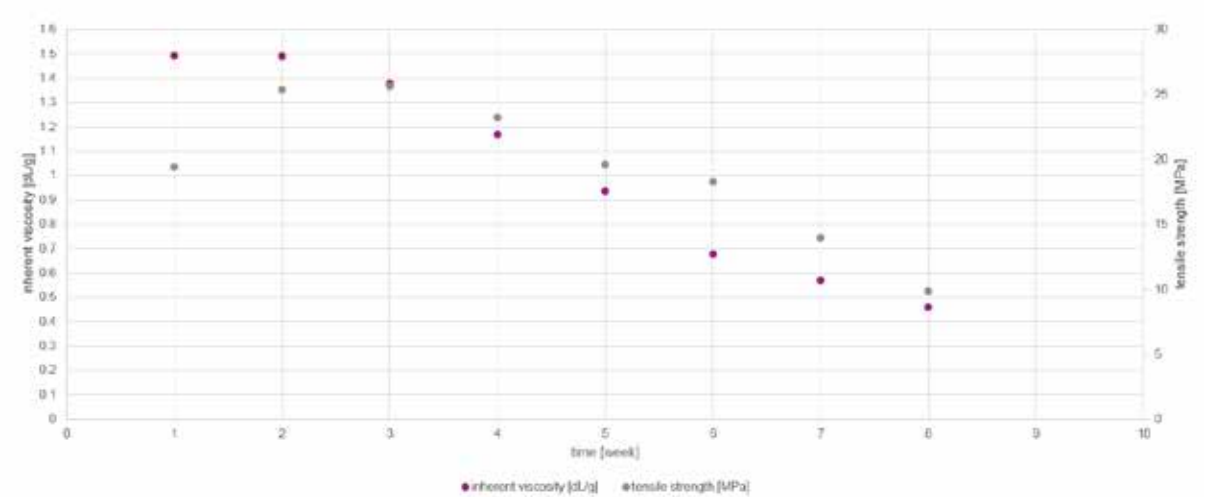

Fig. 4. Biodegradation profile showing declines in inherent viscosity and tensile strength over time.

EP045 In vitro and in vivo evaluation of Lorentz fields in wound healing

Reyhan Zengin[1], Merve Açıkgöz[1], Ali Kuruçay[1]

[1]*Inönü University, Malatya, Türkiye*

Aim: This study investigated the effects of Lorentz fields generated by ultrasonic and static magnetic fields on wound healing, using in vitro cell culture and in vivo animal models to develop a non-invasive, clinically adaptable complementary treatment.

Method: The study had two parts. In vitro, L-929 mouse fibroblast cells underwent a scratch assay with five groups: Control, Static Magnetic Field (SMF), Ultrasound (US-10 cycles), and two Lorentz Field groups (LF-1 and LF-10). Stimulation was applied via a 16-element linear phased array transducer at 1 MHz and 100 Vpp. LF-1 received a single-cycle square wave; US-10 and LF-10 received a 10-cycle square wave. Cell migration and wound closure were recorded every 2 hours for 48 hours. In vivo, 32 rats were divided into four groups (LF-1, LF-3, LF-10, Control), each receiving a 2×2 cm^2 dorsal wound. Treatments lasted 5 minutes daily for 14 days, and wound areas were measured to assess closure.

Results / Discussion: In vitro, the fastest wound width reduction at 48 hours was in LF-10 (35.6%), followed by LF-1 (45.9%) and US-10 (45.6%). SMF showed limited effect (50.6%), while control healed slowest (61.2%). In vivo, LF-3 had the fastest closure, followed by LF-10 and LF-1. By day 14, wound areas decreased ~95% in LF-3, 92% in LF-10, 88% in LF-1, and 80% in controls. These findings indicate that Lorentz fields, especially with multiple ultrasound cycles, accelerate wound healing.

Conclusion: Lorentz fields may serve as a non-invasive, clinically adaptable method to enhance wound repair. Further studies are needed to evaluate different wound types and long-term safety.

EP046 Influence of wound dressing composition on pH at the dressing–wound bed interface

Rita Hlal[1], Jean-Marc Pernot[2], Vincent Peyrou[2]

[1]Urgo, Chenove, France, *[2]URGO Recherche Innovation et Développement, Chenove, France*

Aim: Desloughing dressings for chronic wounds use nonwoven fabrics composed of fibers such as carboxymethylcellulose (CMC), alginate, ammonium polyacrylate, polyvinyl alcohol, or cellulose ethylsulfonate. Electrostatic interactions can occur with exudates, mainly between anionic fiber charges of wound dressings (most often carboxylates) and cationic protein charges of exudates (e.g., fibrin). Depending on the isoelectric point of the proteins, cationic charges will be in greater quantity at low pH. However, since the pH of chronic wounds is between 7 and 9, it will be beneficial to locally reduce the pH of the exudate in contact with the non-woven fabric to ensure that more cationic charges can interact with the anionic charges of the non-woven fabric.

Method: Dressings were immersed for 30–60 s in buffer solutions (pH 7 and 9), drained, and surface pH measured using a Cutometer with a pH probe over 20 s (average value recorded).

Results/Discussion: Commercial dressings based on CMC, alginate, and ammonium polyacrylate were tested. All induced a pH decrease at the interface, with the most significant shift observed for ammonium polyacrylate fibers compared to alginate or CMC. It was shown that the nature of wound dressing fibers affects the pH values measured.

Conclusion: This reliable and repeatable method enables to examine the relationship between the nature of wound dressing fibers and the pH at the interface of the dressing and the wound bed. This improves our understanding of desloughing mechanisms in chronic wound management, ultimately leading to more effective clinical wound care.

EP401 A validated ex vivo skin biofilm model for antibiofilm evaluation

Rui Chen[1], Rebecca Catton[1], Jeanne Saint Bezard[1], Mia Hanrahan[1], Marcus Swann[1], Fergus Watson[1], Steven Percival[1]

[1]5D Health Protection Group, Liverpool, United Kingdom

Aim: Porcine skin closely mimics human skin in terms of structure, composition, and microbiome, making it more clinically relevant than in vitro models. It provides a native microenvironment for biofilm formation, which is critical for studying acute and chronic wound infections. However, variability in porcine skin source, preparation, and wound induction methods can lead to inconsistent results in/across labs. This study aimed to develop and validate an ex vivo porcine skin biofilm model for evaluating the efficacy of antibiofilm agents under clinically relevant conditions.

Method: Porcine skin samples were prepared and inoculated with Staphylococcus aureus ATCC 6538 at concentrations of 1×10^6, 1×10^7, and 1×10^8 CFU/mL. Biofilms were allowed to develop under controlled conditions simulating wound environments for 24 hours. The model was validated by evaluating reproducibility, biofilm density, and structural integrity using quantitative culture techniques and microscopy. Antibiofilm treatments were then applied, and their efficacy was assessed through viable cell counts and analysis of biofilm disruption.

Results / Discussion: The porcine skin model effectively supported robust biofilm development, maintaining consistent bacterial loads and structural features comparable to clinical biofilms. No significant differences (p>=0.4059, one-way ANOVA) in CFU counts were observed after 24 hours, despite initial inoculation levels ranging from 10^6 to 10^8 CFU/mL. However, variations in EPS mass and architecture were evident through microscopy and biomass assays. Antibiofilm agents displayed variable efficacy, underscoring the need for evaluation under physiologically relevant conditions.

Conclusion: The validated ex vivo porcine skin biofilm model offers a reliable and clinically relevant platform for antibiofilm evaluation. It enables more accurate prediction of treatment performance in real-world wound scenarios, supporting the development of effective antibiofilm strategies.

EP402 A human in vivo platform for evaluating skin regeneration after MLA-focused picosecond laser–induced optical breakdown

Yun-Nan Lin[1]

[1]*Wesing Breast Hospital, Kaohsiung, Taiwan*

Aim: To develop and characterize a standardized human in vivo platform using micro-lens array (MLA)–focused picosecond laser–induced optical breakdown (LIOB) as a reproducible dermal micro-injury model for studying wound-healing responses and evaluating topical interventions.

Method: Low-fluence picosecond irradiation (1064 nm, 2.1 J/cm^2, 4-mm spot) was applied to generate controlled subsurface cavitation vacuoles, creating uniform micro-injury sites. Occlusive dressings and serial skin-analysis imaging were used to observe epidermal and dermal responses. Three-spectrum evaluation (white, polarized, UV light) and multi-parameter assessments (brightness, moisture, oil level, elasticity) were used to document inflammation and early repair dynamics.

Results / Discussion: MLA-focused LIOB produced consistent, localized dermal micro-injuries with predictable erythema and inflammatory signatures on polarized-light imaging. UV fluorescence highlighted focal inflammatory activity, while white-light imaging documented surface texture disruption. Over two weeks, progressive reduction of redness and restoration of dermal uniformity were observed. The platform demonstrated high reproducibility and sensitivity for differentiating post-treatment changes in hydration, barrier status, and elasticity.

Conclusion: This human in vivo LIOB platform provides a controlled, quantifiable micro-injury model suitable for evaluating wound-healing mechanisms and topical therapeutic strategies. Its ability to standardize injury depth, visualize inflammatory progression, and capture multi-dimensional skin-recovery parameters supports its application in clinical research on skin regeneration and wound-care innovations.

EP047 Full-thickness biomimetic skin substitute with svf cells and autologous keratinocytes in a single scaffold

Kyung-Chul Moon[1]

[1]*Korea University Guro Hospital, Seoul, Korea, Rep. of South*

Aim: To develop a biomimetic full-thickness artificial skin by integrating stromal vascular fraction (SVF) cells and autologous keratinocytes to reconstitute the dermal and epidermal layers, respectively.

Method: Full-thickness scaffolds were fabricated using 4% porcine collagen with or without elastin (collagen-to-elastin ratios of 100:0 and 100:4) through low-temperature three-dimensional printing. Structural characteristics, collagenase degradation, and tensile properties were analyzed, and the biologic performance of keratinocytes and SVF cells was assessed.

Results / Discussion: Collagen-only scaffolds demonstrated gradual enzymatic degradation within 24 hours, whereas collagen–elastin scaffolds maintained structural integrity and resisted degradation. Tensile testing revealed a significant mechanical advantage in the collagen–elastin group (4.2 N) compared with collagen-only scaffolds (2.2 N). Keratinocyte viability was 89.32 ± 3.01% on day 1 and increased to 97.22 ± 4.99% by day 7. SVF cells similarly showed high viability, rising from 93.68 ± 1.82% on day 1 to 97.12 ± 1.64% on day 7. Scanning electron microscopy confirmed a uniform, gradient pore-density architecture favorable for cellular attachment and proliferation. These findings demonstrate an optimized strategy for engineering full-thickness artificial skin using a single collagen-based scaffold reinforced with elastin and populated with autologous keratinocytes and SVF cells.

Conclusion: This approach provides enhanced mechanical stability and biocompatibility, supporting its potential use in advanced wound repair and regenerative skin therapy.

EP048 An injectable, self-healing polysaccharide-based hydrogel loaded with plasmid and microsphere for wound healing

Jialiang Wang[1], Jiaming Shao[2]

[1]Department of Burns & Wound Repair, The Second Affiliated Hospital, Zhejiang University School of Medicine, Hangzhou, China, *[2]Department of Burns and Wound Repair, the Second Affiliated Hospital of Zhejiang University School of Medicine, Hangzhou, Zhejiang Province, China*

Aim: To design an injectable, self-healing hydrogel loaded with plasmid and microsphere to efficiently transfect local cells and continuously release the drug on the wound.

Method: Prepare a series of hydrogel synthesized by oxidized sodium alginate (OSA) and adipic acid dihydrazide-modified carboxymethylcellulose (CMC-$NHNH_2$), and observe the morphology, and assess the swelling behavior, mechanical property, self-healing characteristics, injectability, degradation behavior of the hydrogel. Live-dead cell staining assay and CCK-8 assay were performed to detect the effect of hydrogel on the survival status of RAW264.7, fibroblasts, and human umbilical vein endothelial cells. Above all, the optimum ratio of OSA and CMC-$NHNH_2$ in the hydrogel was selected. Prepare the OSA/CMC-$NHNH_2$ hydrogel based on PEI coupled plasmid DNA and a microcapsule platform (OC@PLGA@pcDNA-PEI), and detect the slow-release property in vitro. Evaluate the hemocompatibility of the composite hydrogel. Evaluate the effect of the composite hydrogel on fibroblast motility using scratch wound healing assay. Evaluate the chemotactic effect of the composite hydrogel on HUVEC using chemotaxis assay.

Results / Discussion: We successfully synthesized OSA/CMC-$NHNH_2$ hydrogel and observed that the hydrogels have good biocompatibility, swelling behavior, mechanical properties, self-healing characteristics, injectability, and degradation behavior when the ratio of OSA and CMC-$NHNH_2$ is 1/2. Then, we constructed OC@PLGA@pcDNA-PEI hydrogel and observed the slow release of pcDNA-PEI and model drug. The hemolysis ratios at different concentrations of the composite hydrogels were $<5\%$, indicating the composite hydrogels have good hemocompatibility. The composite hydrogels also have good biocompatibility.

Conclusion: We successfully developed the OC hydrogel based on PEI-coupled plasmid DNA and a microcapsule platform with continuous release, which had good biocompatibility, hemocompatibility, swelling behavior, mechanical properties, self-healing characteristics, injectability, and degradation behavior.

EP049 The biocompatibility of a novel biomaterial based on intact decellularized brown seaweed in vitro and in vivo

Svava Kristinsdottir[1], Ottar Rolfsson[1], Olafur Sigurjonsson[2], Hildur Sigurgrimsdottir[1], Jona Freysdottir[1], Sigrun Karlsdottir[1], Sigurður Brynjólfsson[1]

[1]University of Iceland, Reykjavik, Iceland, *[2]Reykjavik University, Reykjavik, Iceland*

Aim: To evaluate the biocompatibility of a novel biomaterial based on intact decellularized brown seaweed in vitro and in vivo.

Method: Cytotoxicity was assessed according to ISO 10993-5 and ISO 10993-12 using media extracts from brown seaweed scaffolds (BSS) prepared per ISO 10993-12 for porous materials. Sterilized BSS were incubated in DMEM growth medium at 37°C, 5% CO_2 for 24 h with intermittent shaking. Three human keratinocyte clones were cultured in triplicate (7.5×10^3 cells/well, 96-well plates), and metabolic activity was quantified by AlamarBlue® reduction at 24, 28 and 72 h. Direct cell ingrowth was evaluated by seeding 1×10^4 fibroblasts onto the scaffold and culturing for 7 days, followed by light microscopy to assess attachment. For in vivo assessment, full-thickness 3 × 3 cm excisional wounds were created within 4 × 4 cm tattooed boxes on the dorsal skin of 2 female pigs (25-30 kg) under general anaesthesia. Wounds were randomised to brown seaweed scaffold, standard of care (SOC) or sodium carboxymethylcellulose wound dressing (SCC). Macroscopic images and histological biopsies were collected on days 7, 14, 21 and 60.

Results / Discussion: BSS extracts demonstrated non-cytotoxic properties, maintaining keratinocyte viability at or above 70% across all assessed time points. The scaffolds facilitated direct cell attachment and ingrowth in vitro. Preliminary data indicate that BSS is biocompatible and elicited immunological responses comparable to both SOC and SCC Furthermore, granulation tissue, macrophage activity, and re-epithelialisation were more pronounced in wounds treated with BSS relative to controls.

Conclusion: BSS demonstrate favourable biocompatibility and promote tissue regeneration in a full-thickness porcine wound model, supporting further development as a plant-derived dermal substitute for wound management.

EP050 Artificial intelligence (AI) for enhanced wound care: A review of applications and future direction

Abdulaziz Binkanan[1]

[1]*King Abdullah bin Abdulaziz University Hospital (KAAUH), Princess Noura University (PNU), Riyadh, Saudi Arabia*

Aim: To provide an overview of the applications of AI in wound care, focusing on the potential benefits, limitations and the future directions.

Method: In this narrative review, a total of 205 papers retrieved. Firstly, we reviewed the limitations of the current practice for wound assessment. Then, we presented the findings of the published studies evaluating AI-based wound assessment, classification, diagnosis, treatment selection, and monitoring.

Results / Discussion: AI-powered solutions have demonstrated superior performance in various aspects of wound management, including risk assessment, wound evaluation, and patient monitoring. By leveraging advanced techniques such as deep learning and computer vision, AI models can accurately analyze wound images, classify tissue types, and predict healing trajectories. However, several challenges remain in the practical implementation of AI in wound care. Issues such as data quality, model interpretability, and ethical considerations need to be carefully addressed to ensure the safe and effective deployment of these technologies. Future research should focus on developing robust and user-friendly AI tools, integrating them into existing healthcare workflows, and conducting rigorous clinical trials to evaluate their impact on patient outcomes. By addressing these challenges and capitalizing on the opportunities presented by AI, we can significantly improve the management of chronic wounds and enhance the quality of life for affected individuals.

Conclusion: This review underscores the significant potential of AI in revolutionizing wound care. AI-powered solutions have demonstrated superior performance in various aspects of wound management, including risk assessment, wound evaluation, and patient monitoring.

EP051 Patients' and caregiver satisfaction with virtual wound care service

Abdulaziz Binkanan[1]

[1]*King Abdullah bin Abdulaziz University Hospital (KAAUH), Princess Noura University (PNU), Riyadh, Saudi Arabia*

Aim: This study aimed to assess patient and caregiver satisfaction with virtual wound care services.

Method: A cross-sectional survey was conducted among 4190 respondents, comprising 2300 patients and 1890 caregivers who had used virtual wound care services from April to December 2024. The survey captured socio-demographic details, satisfaction levels and experiences with various wound care system domains.

Results / Discussion: Results revealed that patients reported significantly higher satisfaction levels compared to caregivers. Younger participants, males, and individuals with higher education or full-time employment were more likely to report high satisfaction. Domains such as voice and visual quality, personal comfort, and team courtesy were rated higher by patients, while caregivers expressed concerns regarding accessibility and communication. Approximately

half of patients (42.2%) indicated a strong willingness to reuse telehealth services and recommend them, reflecting positive acceptance of virtual wound care.

Conclusion: Virtual wound care services are generally well-received, with patients showing greater acceptance than caregivers. Findings highlight the importance of targeted support and training to address caregiver needs, improve accessibility, and promote equitable telehealth satisfaction. The findings suggest that telehealth can be an effective option for wound care, but addressing caregiver concerns is crucial for improving satisfaction.

EP052 Adipose-derived stem cell therapy for post-ischemic wounds: Mechanims and regenerative outcome

Eliza Nindita[1], Muhammad Anas[2]

[1]Division of Plastic Surgery, Department of Surgery, Faculty of Medicine, Universitas Sumatera Utara, Medan, Indonesia, *[2]Department of Surgery, Faculty of Medicine, Universitas Sumatera Utara Medan, Indonesia, Medan, Indonesia*

Aim: This study aims to investigate the therapeutic potential of Adipose-Derived Stem Cells (ADSCs) in enhancing wound healing and mitigating necrosis in post-ischemic skin flap models.

Method: This randomized controlled experimental study used 24 male Wistar rats undergoing a standardized 3×2 cm groin skin flap with 8-hour pedicle ischemia. On day 7, flaps were assigned to four groups: ADSC injection (5×10^6 cells), low-dose heparin, ADSC-heparin combination, and control. Flap viability and necrosis were quantified using *Analyse Digital Image®*. VEGF and IL-6 levels were measured using ELISA. Histopathology (H&E staining) assessed inflammation, vascular proliferation, oedema, thrombosis, and tissue injury severity.

Results: Treatment with ADSCs resulted in a marked increase in flap viability and a significant reduction in necrotic areas compared to the control and heparin only groups. Elevated levels of VEGF in ADSC-treated flaps indicated enhanced angiogenesis, while IL-6 levels were measured at reduced levels, reflecting a moderated inflammatory response. Histopathological assessments revealed improved neovascularization, decreased oedema and thrombosis, and superior tissue organization in both ADSC and ADSC-heparin treated groups, with the combination therapy exhibiting the most pronounced regenerative effects.

Conclusion: ADSC therapy significantly promotes angiogenesis, modulates inflammatory responses, and enhances tissue survival in the context of post-ischemic wounds, underscoring its efficacy in preventing ischemia. The synergistic effects observed when combining ADSCs with low dose heparin highlight its potential as a promising adjunctive treatment strategy in reconstructive surgery for ischemic tissue.

EP053 Development and evaluation of polymer–hydrogel prototypes for advanced wound dressings

Franciska Erdő[1], Anna Nowak[2], Olena Pavlenko[3], Silvia Letasiova[4], Paula Ossowicz-Rupniewska[5]

[1]Pazmany Peter Catholic University, Budapest, Hungary, *[2]Pomeranian Medical University in Szczecin, Szczecin, Poland*, *[3]National academy of Science of Ukraine, Kyiv, Ukraine*, *[4]MatTek In Vitro Life Science Laboratories, s.r.o., Limited liability company, Mlynske Nivy 73, Brastislava, Slovakia*, *[5]West Pomeranian University of Technology in Szczecin, Szczecin, Poland*

Aim: The study aimed to develop multifunctional polymer-based wound dressings for chronic and traumatic wounds by integrating polymer matrices with bioactive components and controlled-release mechanisms to enhance healing-relevant properties, antimicrobial potential, and biocompatibility.

Method: Prototype dressings were produced by combining polymeric and hydrogel matrices synthesized under controlled conditions and modified with antioxidant, anti-inflammatory, and metal-derived antimicrobial agents. Physicochemical characterization included swelling behaviour, rheological properties, thermal transitions, and

mechanical resistance. Drug-release characteristics were assessed using standardized diffusion assays with kinetic modelling. Biological performance was evaluated using reconstructed three-dimensional human skin models to assess cytotoxicity, tissue viability, inflammatory mediators, and early wound-healing markers. All procedures followed unified protocols supported by inter-laboratory calibration.

Results / Discussion: Polymer–hydrogel matrices were successfully synthesized and underwent the planned physicochemical assessments. The materials showed stable structural organization, reproducible hydration profiles, and rheological behaviour consistent with soft-matter systems for topical application. Diffusion-based assays enabled characterization of release patterns of incorporated bioactive compounds and demonstrated suitability of the setup for comparative screening. In vitro assays using reconstructed human skin models confirmed compatibility of the prototypes with the biological workflow and supported evaluation of cytotoxicity and basic tissue-response parameters. Cross-laboratory analyses indicated consistency between measurement procedures following protocol harmonization.

Conclusion: The study established a methodological framework for developing and evaluating polymer–hydrogel wound-dressing prototypes. The completed stages confirm the feasibility of combining physicochemical testing with in vitro biological assessment for this material class. The findings provide a basis for refining matrix composition and extending evaluation to more advanced biological models while supporting systematic comparison of formulations within a reproducible research environment.

This study was conducted within the framework of the Visegrad+ grant (ID 22520083)

EP054 The safety of one-per-mil tumescent infiltration into tissue that survived ischemia

Eliza Nindita[1], Casvin Jus[2], Alfredo Fransiscus[2], Defry Utama[1]

[1]Division of Plastic Surgery, Department of Surgery, Faculty of Medicine, Universitas Sumatera Utara, Medan, Indonesia, *[2]Department of Surgery, Faculty of Medicine, Universitas Sumatera Utara Medan, Indonesia, Medan, Indonesia*

Aim: The aim of this study was to assess the safety of one-per-mil tumescent injections into viable skin flaps that had survived an ischemic insult, in order to assess the potential suitability of one-per-mil tumescent injections in future secondary reconstructive procedures such as flap revision and refinements after replantation.

Methods: Forty groin flaps harvested from 20 healthy Wistar rats weighing 220 to 270 g were subjected to acute ischemia by clamping the pedicle for 15 minutes. All flaps showing total survival on the 7th postoperative day were randomly divided into group A (one-per-mil tumescent infiltration; n=14), group B (normal saline infiltration; n=13), and group C (control, with no infiltration; n=13) before being re-elevated. Transcutaneous oxygen tension (TcPO2) was measured before and after infiltration, and changes in TcPO2 were statistically analyzed using analysis of variance, the paired t-test, and the independent t-test. The viability of flaps was also assessed using the Analyzing Digital Images software at 7 days after the second elevation.

Results: Thirty-nine flaps survived to the final assessment, with the sole exception of a flap from group A that did not survive the first elevation. TcPO2 readings showed significant decreases ($P<0.05$) following both one-per-mil tumescent (99.9±5.7 mmHg vs. 37.2±6.3 mmHg) and normal saline (103±8.5 mmHg vs. 48.7±5.9 mmHg) infiltration. Moreover, all groin flaps survived with no signs of tissue necrosis.

Conclusions: One-per-mil tumescent infiltration into groin flap tissue that had survived ischemia did not result in tissue necrosis, although the flaps experienced a significant decrease of cutaneous oxygenation.

EP055 Evaluation of skin cleansing performance and it's impact on hydration and barrier function in controlled clinical studies

Natalie Maguire[1]

[1]*GAMA Healthcare, Halifax, United Kingdom*

Aim: To determine the skin cleansing effectiveness and the effects on hydration and skin barrier efficiency of an advanced 3-in-1 barrier cloth.

Method: Two single-centre, controlled laboratory studies were conducted. In the hydration and barrier study, 23 participants completed paired assessments on the forearms at baseline, 15 minutes and 24 hours, after a single application; the contralateral site remained untreated as the control. Skin hydration was measured by electrical capacitance, and barrier efficiency by Transepidermal Water Loss (TEWL). In the cleansing study, 12 participants received synthetic dirt containing black carbon on paired sites; removal used either the advanced 3-in-1 barrier cloth or water and soap, and micro-image analysis quantified percentage removal.

Results / Discussion: Hydration increased by 32.6% at 15 minutes and 14% at 24 hours compared with baseline and control. All participants showed improved hydration at 15 minutes and 24 hours. TEWL decreased by 30.6% at 15 minutes, 11.1% at 24 hours. Baseline values around 9 grams per hour per square metre fell to approximately 6.2 grams per hour per square metre at 15 minutes. In the cleansing study, mean dirt removal was 99.3%, reaching up to 99.8% with the advanced 3-in-1 barrier cloth, versus 90.0% (up to 95.6%) for water and soap.

Conclusion: The advanced 3-in-1 barrier cloth achieved greater removal of dirt than water and soap and delivered rapid, clinically relevant improvements in skin hydration and barrier efficiency for at least twenty-four hours.

EP056 A new bioactive dermal substitute for wound healing and skin regeneration

Beatriz G. Bernardes[1], Marta Rosadas[1], Teresa Sousa[1], Mariana Reis[1], Clara Sousa[1], Alda Sousa[2], Christian Sánchez Espinel[3 4], Mercedes Peleteiro[3 4], África González Fernandez[3 4], Viviana Pinto Ribeiro[1], Ana Oliveira[1]

[1]*Universidade Católica Portuguesa, Porto, Portugal*, [2]*Cortadoria Nacional de Pêlo, São João da Madeira, Portugal*, [3]*CINBIO, University of Vigo, Vigo, Spain*, [4]*Instituto de Investigación Sanitaria Galicia Sur, Vigo, Spain*

Aim: Rabbit skin is an abundant agri-food by-product with interesting properties to be up-cycled into a xenogeneic dermal substrate for skin regeneration. When decellularized, rabbit dermis preserves collagen–elastin components that can guide cell behavior [1]. However, decellularization conditions can also influence the preservation of tissue architecture and may introduce immunogenic triggers such as damage-associated molecular patterns (DAMPs) [2]. This work aimed to develop low-immunogenicity decellularized dermal matrices (dDMs) using a rabbit skin by-product.

Method: dDMs were generated using optimized chemical decellularization protocols and evaluated for structural and biochemical integrity using SEM, tensile testing, FTIR, proteomics, and DNA, GAGs, collagen, and elastin quantification. Immunogenicity was assessed through endotoxin analysis and by exposing human peripheral blood mononuclear cells (PBMCs) to the matrices to measure complement activation, ROS, apoptosis, activation markers, and cytokine release. The ability of dDMs to support human dermal fibroblasts (hDFs) and keratinocytes (HaCaTs) was examined over 14 days using Alamar Blue, BrdU, SEM, and DAPI/phalloidin staining.

Results/Discussion: dRDMs preserved native collagen–elastin architecture, and GAG levels were comparable to human dermis. Residual DNA confirmed effective decellularization. No significant immune activation occurred: ROS and apoptosis were absent, and PBMC activation matched controls with only mild monocyte and B-cell responses. Cytokine release indicated modest inflammatory signaling induction. Interestingly, lower DNA content matrices triggered stronger immune responses, suggesting biocompatibility is also influenced by processing-related factors (detergent residues or DAMPs). hDF and HaCaT adhesion, viability, and proliferation were maintained for 14 days.

Conclusion: dRDMs showed favorable structural, biochemical, and immunological profiles and supported dermo-epidermal cell growth, demonstrating potential as bioactive dermal substitutes for skin regeneration.

[1] Rosadas et al., Front. Biomaterials, 2024.

[2] Kasravi et al., Biomaterials Research, 2023.

EP057 Frutalin biomatrix enhances healing and modulates behavior in infected wounds

Natalia Holanda[1], Sacha Santos[1], Adriana Campos[1], Ana Moreira[1], Felipe Sousa[1], Laís Martins[1], Thiago Marques[1], José Assis[1], Maurício Girão[1]

[1]*University of Fortaleza, Fortaleza, Brazil*

Aim: Wound healing is a dynamic process, favored by topical therapies. Extracted from *Artocarpus altilis*, frutalina (FTL) is a carbohydrate-binding protein, whose healing model has already shown cicatricial modulatory capacity by stimulating the production of defense cells. Therapies with healing properties in infected environments are still needed, and therefore, this research investigated the therapeutic potential of FTL in a galactomannan matrix for the treatment of contaminated wounds in *Swiss* mice, using macroscopic and behavioral analysis.

Method: Forty-eight animals were anesthetized and subjected to the creation of a circular excisional wound (10 mm), contaminated with *Pseudomonas aeruginosa* and *Staphylococcus aureus* (10^8 CFU/mL). The animals were allocated into two groups: Control, with daily topical application of 0.15 M NaCl, and FTL, with a single application (0.5 mg) incorporated into galactomannan. On days D3, D7, and D14 post-excision (n= 8/group/day), macroscopic characteristics (pachymetry and inflammatory signs) and behavior were assessed using Open Field (OF) and Elevated Plus Maze (EPM) tests.

Results / Discussion: On D3, both groups presented similar dimensions and closure rate, although macroscopic indicators of FTL suggested an early transition to the proliferative phase. On D7, FTL exhibited smaller dimensions (51 mm versus 59 mm) and a closure rate approximately 20% higher. On D14, the Control group completed the epithelialization process more quickly. In behavioral tests, there were no statistical differences in the OF test. In the EPM test, FTL remained longer in the closed arm ($p < 0.05$), indicating altered anxious behavior and suggesting a reduction in nociceptive discomfort.

Conclusion: Treatment with galactomannan-based FTL improved wound healing parameters in the proliferative phase and modulated behavioral signs of discomfort, supporting its therapeutic potential in infected wounds.

EP058 Advantages of using platelet-rich plasma at the donor site after skin grafting: A systematic review and meta-analysis

Feras A. A. Zaqout[1], Laura Awad[1]

[1]*Department of Surgery and interventional Sciences, University College London, Royal Free Hospital, London, United Kingdom*

Aim: Split-thickness skin grafting is a fundamental technique in Plastic Surgery, though it carries a drawback of creating a secondary wound at the donor site, which leads to complications such as pain, scarring, itching, pruritus or dyschromia. Therefore, we explore the adjunct biological application of Platelet-rich plasma (PRP) to standard dressing at the donor site, in comparison to the standard dressing alone. Investigating the outcomes of pain, healing time, re-epithelialization, incidence of scar, and pruritus/itching.

Method: A Systematic Review and Meta-Analysis was conducted in accordance with PRISMA guidelines. Embase, PubMed and Scopus were searched from inception until April 2025 (n=471). Included studies must compare at least one outcome. Statistical analysis was performed. This review is registered in PROSPERO (CRD420251112137).

Results / Discussion: Eight studies were included, resulting in a total of 170 patients having 172 wounds in the PRP group, and 172 patients having 174 wounds in the control group. Mean follow up was 3 months, and mean age was 49.35. Our meta-analysis indicated a statistically significant lower pain in the PRP group (SMD= -0.59, 95%-CI = -0.93, 0.25; P value= 0.0006) at postoperative day 7, besides lower pain scales across postoperative days 3,14, and 21. The PRP re-epithelization was significantly faster (OR= 4.91; 95%-CI= 2.13, 11.30; P value= 0.0002). The PRP healing days range were shorter, and incidence of scar was lower.

Conclusion: PRP demonstrates potential benefit in graft donor-site outcomes: reducing pain, accelerating re-epithelialization rates, and shorter healing days. PRP represent a promising strategy for decreasing incidence of scar and hospital stay. Further large-scale, standardized techniques and trials are warranted.

BURNS

EP059 The role of free flap reconstruction in the management of acute and chronic burn injuries

Youn Hwan Kim[1]

[1]*Department of Plastic surgery, Hanyang University Medical Center, Seoul, Korea, Rep. of South*

Aim: Free flap reconstruction has become an essential method for addressing severe burn-related defects, yet direct comparisons between primary and secondary procedures remain limited. This study aimed to analyze and compare the patient demographics, operative characteristics, complication rates, and outcomes of primary versus secondary free flap reconstructions in burn patients.

Method: A retrospective review was conducted of 65 patients who underwent free flap reconstruction for burn-related defects at Hanyang University Hospital from 2012 to 2024. Primary reconstructions were defined as those performed during the acute phase of burn treatment, while secondary reconstructions were defined as procedures performed after wound healing. Data collected included demographics, burn etiology, defect site, flap type, operative time, complications, need for revision, and follow-up duration. Statistical analyses employed t-tests and Chi-square tests, with significance set at $p<0.05$.

Results / Discussion: Of the 65 patients, 37 underwent primary and 28 secondary reconstructions. The primary group was significantly older (mean 55.4 vs. 39.4 years, $p<0.001$) and predominantly male, while the secondary group had more female patients ($p=0.01$). Operation time was longer in the secondary group (237 vs. 173 minutes, $p=0.001$). Flap survival was excellent overall, with minimal complications. Thoracodorsal artery perforator (TDAP) flaps were most commonly used (42/65), followed by latissimus dorsi musculocutaneous flaps (7/65).

Conclusion: Both primary and secondary free flap reconstructions for burn injuries demonstrated high success and low complication rates. Secondary reconstructions, however, were associated with longer operative times and occasional flap failures. Thoracodorsal vessel–based flaps proved versatile and reliable across both settings, supporting their use as primary options for burn-related reconstruction.

EP060 Surgical treatments in chemical burns

Sung Won Jung[1]

[1]*Hanil General Hospital, Seoul, Korea, Rep. of South*

Aim: Although chemical burns account for a small proportion of all burn injuries, they remain clinically significant because of the risk of progressive tissue necrosis caused by residual agents. These injuries require prompt removal of the offending substance and timely wound coverage when indicated. This study aims to evaluate surgical treatment strategies, focusing on escharectomy and wound coverage, in patients with chemical burns.

Method: A retrospective review was conducted of 66 patients with chemical burns admitted to the Department of Plastic and Reconstructive Surgery at Hanil General Hospital between 2019 and 2024. Data collected included causative agents, wound location, total body surface area (TBSA), burn depth, surgical interventions, and postoperative complications. Surgical procedures, such as early or delayed escharectomy, split-thickness skin grafting (STSG), STSG with an acellular dermal matrix (ADM), full-thickness skin grafting (FTSG), and local flap coverage, were selected according to the wound characteristics.

Results / Discussion: Of the 66 patients, 48 underwent surgical treatment, and 18 were managed conservatively. Among the surgical cases, early excision (escharectomy) was performed in 10 patients (20.8%), whereas delayed excision was performed in 38 patients (79.2%). Wound coverage procedures were performed in 30 patients (62.5%).

Conclusion: Early excision of necrotic tissue and appropriate wound coverage is associated with favorable outcomes in patients with chemical burns.

EP404 Modified Moist Occlusive Burn Therapy (MMOBT) for cervicofacial burns: A promising approach for enhanced healing and aesthetic outcomes

Xuelei Li[1], Chao Lian[1]

[1]*Changzhi People's Hospital, Changzhi Medical College, Shanxi, China*

Aim: This study introduces an innovative integrated protocol, Modified Moist Occlusive Burn Therapy (MMOBT), and evaluates its clinical efficacy and aesthetic restoration potential in treating cervicofacial burns, addressing the limitations of traditional Moist Occlusive Burn Therapy (MOBT) and Moist Exposed Burn Therapy (MEBT).

Method: The MMOBT protocol synergistically combines ultrasonic debridement (UD), Ointment containing β-sitosterol, and sterile polyethylene film (SPF). Treatment initiated with UD for precise debridement and bacterial suppression while preserving viable tissue. Ointment containing β-sitosterol was then applied to promote re-epithelialization and mitigate scar formation. Finally, the wound was covered with SPF to maintain a moist occlusive environment, accelerating healing and enabling direct visual monitoring. Twenty-five patients with cervicofacial burns from various mechanisms (scalding, flame, molten metal splash, electrical flash, and dust explosion) were treated and followed up for 6 to 12 months.

Results / Discussion: All patients achieved successful wound healing with significantly alleviated pain. No complications such as infection, pigmentary changes, hypertrophic scarring, or contracture were observed during follow-up. Excellent aesthetic restoration was accomplished in all cases without the need for reconstructive surgery, demonstrating high patient satisfaction.

Conclusion: Effectively integrates the advantages of MOBT and MEBT while overcoming their drawbacks, significantly improving the quality and efficiency of wound healing in cervicofacial burns. This approach offers substantial clinical applicability and is particularly suitable for managing burns in aesthetically sensitive areas like the face and neck, providing a new strategic option and evidence-based perspective for burn care.



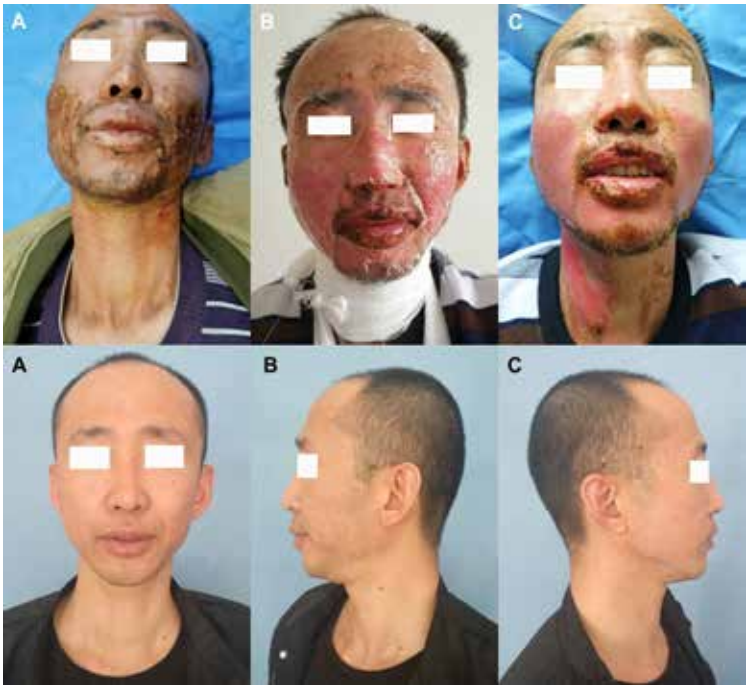
A
B
C
A
B
C


A
B
C
A
B
C


A
B
C
D
E
F


A
B
C
A
B
C

EP061 AI-driven segmentation of skin grafts for future outcome prediction: A methodology protocol

Nanthakumahrie Gunasegaran[1], Necip Gurler[2], Darshini Devi Rajasegeran[1], Patrick Cheng[2], Shin Yuh Ang[1], Ozgur Guler[2], Fazila Aloweni[1 1]

[1]Singapore General Hospital, Singapore, Singapore, *[2]ekare Pte Ltd, Fairfax, Virginia, United States*

Aim: To evaluate and compare the performance of Mask R-CNN and U-Net++ segmentation models for delineating wound boundaries and graft-related tissue structures in skin graft images.

Method: This prospective imaging study was conducted in the burns unit of an acute tertiary care hospital. Adult patients undergoing split-skin graft (SSG) procedures were recruited, and graft sites were imaged using a standardized 3D wound management system. Imaging started on postoperative day 5 during routine dressing change, then every two days until the graft was assessed as stable, fully taken, healed, failed, or until discharge. All images were de-identified and manually annotated by experienced burns clinicians to define wound and tissue boundaries. U-Net++ and Mask R-CNN with a ResNet 50 FPN backbone were trained using a patient level train, validation, and test split. Model performance was assessed using Dice similarity coefficient and Intersection over Union (IoU) at image and per patient levels.

Results / Discussion: On held out test patients, U-Net++ achieved an image level Dice of 0.95 and IoU of 0.91, with mean per patient Dice 0.94 ± 0.03 and IoU 0.89 ± 0.05 for wound segmentation. The best Mask R-CNN configuration achieved validation mean per patient Dice 0.92 ± 0.02 and IoU 0.86 ± 0.03, and test mean per patient Dice 0.83 ± 0.17. U-Net++ showed higher quantitative performance, while Mask R-CNN additionally provided instance level delineation of graft-related structures.

Conclusion: This methodology protocol shows that standardized 3D wound imaging combined with deep learning segmentation is feasible for assessment of SSGs. The segmented regions can serve as quantitative inputs for future models to predict graft outcomes and support clinical decisions in burns and reconstructive surgery.

EP062 Interactive impact of blue light, cold argon plasma and amino acids in the treatment of deep dermal and full thickness burns

Gaurav Narad[1], Panche Taskov[2], Zorin Crainiceanu[2], Wael El Amine[1], Ahmad El Amine[1], Mihai Glaja[1], Viviana Narad[1], Daniela Corodati[1], Dragos Cuc[1], Andreea Babii[1], Robert Blendea[1], Daniela Taskov[1], Ancuta Pop Coman[1], Daniel Pit[1 1]

[1]Plastic and Reconstructive Surgery Department Casa Austria, County Emergency Clinical Hospital "Pius Branzeu", Timisoara Romania, Timisoara, Romania, *[2]University of Medicine and Pharmacy "Victor Babes", Timisoara Romania; Plastic and Reconstructive Surgery Department Casa Austria, County Emergency Clinical Hospital "Pius Branzeu", Timisoara Romania, Timisoara, Romania*

Aim: Tangential excision and split-thickness grafting (SOC) remain the reference for deep burns but are blood-intensive, donor-site–limited and frequently yield hypertrophic scars.

We evaluated a multimodal regenerative protocol ("PAN-EDNX") coupling bromelain-based selective enzymatic debridement with autologous skin micro-grafts, platelet-rich plasma, microbial nanocellulose, cold argon plasma, blue light, HA and AA topics.

Method: A single-centre retrospective study (2025) compared consecutive adults with grade IIB/III burns treated by PAN-EDNX (n = 10) with size and depth-matched SOC controls (n = 10).

Primary end points were time to complete eschar removal, need for secondary surgery and safety of the treatment.

Results / Discussion: Baseline age (35.3 ± 11.2 y vs 43.1 ± 7.8 y;) and %TBSA (36.3 ± 4.3 vs 33.2 ± 4.3;) were comparable; ABSI scores did not differ.

PAN-EDNX halved eschar-clearance time (5.0 ± 1.1 vs 9.1 ± 1.5 d;) and eliminated secondary grafting (0 % vs 93 %;).

Spontaneous/stimulated epithelialisation occurred in every PAN-EDNX case vs 7 % of SOC.

No procedure-related bleeding, electrolyte disorders or mortality differences were observed.

Conclusion: The PAN-EDNX concept accelerates eschar clearance, obviates grafting, improves scar quality and shortens rehabilitation without compromising safety.

Dermis preservation and micro-graft bio-stimulation appear synergistic, supporting wider integration of regenerative adjuncts into enzymatic debridement pathways for extensive burn.

The clinical results obtained with therapeutic flowchart based on “PAN EDNX” demonstrate excellent aesthetic outcomes as well as functionality restoration.

This novel regenerative technique has shown promising results in burn healing process, reduced costs and hospitalization, decreased lost working days and increased quality of life.

“PAN EDNX” is a safe procedure and real CHALLENGE of personalized care in burn treatment.

EP063 The epidemiological characteristic and trends of burns globally

Aobuliaximu Yakupu[1], Chunmao Han[1], Xingang Wang[1]

[1]Department of Burns & Wound Care Center, the Second Affiliated Hospital of Zhejiang University, School of Medicine, Hangzhou 310009, China, Zhejiang Key Laboratory of Trauma, Burn, and Medical Rescue, Zhejiang University, Hangzhou 310009, China, Hangzhou, China

Aim: It is difficult for policymakers and clinicians to formulate targeted management strategies for burns because data on current epidemiological patterns worldwide are lacking.

Method: The incidence, disability-adjusted life years (DALYs), and deaths of burns in 204 countries and regions from 1990 to 2019 were calculated and stratified by sex, age, geographical location, and sociodemographic index (SDI). The estimated annual percentage change (EAPC) of incidence, DALYs, and deaths was calculated to evaluate the temporal trends.

Results / Discussion: A total of 8,378,122 new cases (95% UI, 6,531,887-10,363,109cases) of burns were identified globally in 2019, which is almost evenly split between men and women, and most of the new cases were concentrated in the 10-19-year age group. Besides, burns account for 111,292 deaths (95% UI, 132,392-88,188) globally in 2019, most of which were concentrated in those aged 1-4 years. The burden of burns measured in DALYs was 7,460,448.65 (95% UI, 5,794,505.89-9,478,717.81) in 2019, of which 67% and 33% could be attributed to YLLs and YLDs, respectively. The EAPC of incidence, DALYs, and deaths was negative; the age-standardized rate (ASR) of incidence, DALYs, and deaths was considered to be decreasing in most of the regions, and the EAPCs were negatively correlated with SDI levels, universal health coverage (UHC), and gross domestic product (GDP).

Conclusion: Globally, the age-standardized rates of burn incidence, DALYs, and mortality, as well as the number of burn DALYs and death cases, will continuously decrease, but the number of new burn cases has an increasing tendency globally. In addition, the EAPCs of burns in incidence, DALYs, and deaths indicated that the burden of burns was considered to be decreasing in most of the regions.

EP405 Optimizing burn wound recovery with ON101 through faster healing, pain relief, and improved scar outcomes: A case series evaluation

Irene Wang[1], Yi-Chia Chen[2], Ming-Hsien Chung[2], Chieh-Kai Chang[2], ChengYeu Wu[2], Yi-ling Lin[2], Yueh-Chi Tsai[2], Chen-Te Lu[2], I-Chen Chen[2], Chih-Sheng Lai[2]

[1]Oneness Biotech Co., Ltd., Taipei, Taiwan, *[2]Division of Plastic and Reconstructive Surgery, Department of Surgery, Taichung Veterans General Hospital, Taichung, Taiwan*

Aim: Burn injuries, whether acute or chronic, often involve prolonged inflammation, persistent pain, delayed epithelialization, and risk of hypertrophic scarring. This case series evaluated ON101 topical cream as a reparative

therapy in inpatient burn care, focusing on its effects on healing speed, symptom relief, and safety across diverse clinical cases.

Method: Five hospitalized burn cases were reviewed, including three thermal burns (two adult, TBSA 20%, one superficial partial-thickness under immunosuppressive therapy and one superficial to deep partial-thickness; one pediatric facial burn, TBSA 11.5%, superficial partial-thickness), one electrical burn (TBSA 3.5%, superficial partial-thickness), and one chronic burn (TBSA 15%, superficial partial-thickness to full-thickness with polymyositis, diabetic , and vascular comorbidities) unhealed for 16 months. ON101 was applied once wounds were stable, adequately debrided, and free of infection. Application frequency ranges from daily to every other day depending on exudate level. Adjunctive care included surgical debridement and absorbent dressings.

Results / Discussion: In all five cases, ON101 demonstrated consistent epithelialization and wound improvement in both acute and chronic burns. Large-surface thermal burns achieved full closure within 10 days, electrical burns in 7 days, the pediatric facial burn in 8 days, and chronic burn in 12 weeks. All wounds showed reductions in inflammation, exudate, and pain. ON101 was well tolerated in children, immunosuppressed patient, and patient with diabetic and vascular comorbidities. Scar assessment after ON101 treatment suggested uniform and soft remodeling.

Conclusion: ON101 supported efficient healing, reduced inflammation, relieved pain, and promoted favorable scar outcomes in both acute and chronic burn wounds. It may serve as a novel and effective first-line option for managing acute, complex or chronic burns, supporting both wound repair and patient comfort.

EP064 HIF-1α protects the burn-wound progression by mitochondria and mitochondria-associated endoplasmic reticulum (ER) membranes (MAMs)-involved mitophagy

Weixue Jin[1], Danyang Ren[1], Songxue Guo[1 2]

[1]The Second Affiliated Hospital of Zhejiang University School of Medicine, Hangzhou, China, *[2]Zhejiang Key Laboratory of Trauma, Burn, and Medical Rescue, Hangzhou, China*

Aim: Burn-wound progression contributes to the deterioration of primary burn-wound and is related to the severity of burn patients. Recently, we demonstrated mitophagy attends to the quality of mitochondria and regulate downstream biological behavior, which seems a novel player in burn-wound protection. The current study is to clarify the molecular regulation on mitophagy mediated by the interaction between organelles (like mitochondrium and endoplasmic reticulum) and detailed effect on downstream injurious mechanism in burn-wound progression.

Method: Hypoxic stimulation model of human fibroblasts and rat model were both established for in vitro and in vivo study. Structural and functional homeostasis of mitochondria and MAMs were analyzed by TEM, JC-1 probe, immunofluorescence staining, and western blot. The qPCR and western blot were utilized to assess the mitophagy, inflammation, and apoptosis of fibroblasts. Adenovirus-based gene silencing of hypoxia-inducible factor (HIF)-1α and selective inhibitors helped identify structural components of MAMs as regulatory mediator.

Results: Hypoxia induced a time-dependent change in inflammation cytokines release (IL-1β/6/18), apoptosis (cleaved Caspase 3/9 and Cytochrome C), pyroptosis (Gasdermin D), and mitochondrial homeostasis in the zone of stasis. We observed a time-dependent fluctuation in HIF-1α expression and mitophagy markers (P62, TOMM20, LC3II) in hypoxic fibroblasts, and mitophagy peaked 24 hours after hypoxia. Silencing HIF-1α abandoned increased expression of these mitophagy markers (P62, TOMM20, LC3II) and exacerbated apoptosis (as downregulation of Caspase 3/9 and Cytochrome C). Crucially, TEM revealed a progressive loosening of MAMs structure following hypoxia. Transcriptional analysis and immunoblot revealed that voltage-dependent anion channel (VDAC)1 expression increased with injury severity, while VDAC2 expression mirrored the protective “rise-and-fall” pattern of HIF-1α. Adenovirus-based gene silencing and selective inhibitors of HIF-1α and/or VDAC1/2 helped identify VDAC2 as regulatory mediator of HIF-1α on MAMs and secondary mitophagy, due to a synchronous and obvious change in VDAC2 expression as HIF-1α. In rats model, we further demonstrated a similar role of MAMs in the regulation of HIF-1α on mitophagy in the zone of stasis, considering VDAC2 mediated the effects of HIF-1α on mitophagy activation (P62, TOMM20 and LC3II expression changed with HIF-1α/VDAC2) and downstream inflammation/cell

death (increased mitophagy combined with downregulated IL-1β /6/18, cleaved Caspase 3/9, Cytochrome C and Gasdermin D). These findings were similar to the results form in vitro experiments.

Conclusion: HIF-1α modulates mitophagy and following mitochondrial homeostasis via VDAC1/2 during the early stage of burn-wound conversion. Further studies into comprehending the basic mechanisms as well as the crosstalk behind mitophagy may facilitate the development of more comprehensive selective reagents and therapeutic targets.

EP065 Artificial dermis in reconstruction of joint-involved burn wounds: A single-center experience in Southern Taiwan

Chia Min Chen[1]

[1]*Kaohsiung Chang Gung Memorial Hospital, Kaohsiung, Taiwan*

Aim: Full-thickness burn wounds involving major joints pose reconstructive challenges due to limited donor sites, donor-site morbidity, and the need to preserve mobility. This study aimed to evaluate clinical outcomes of artificial dermis followed by split-thickness skin grafting (AD+STSG) in joint-involved burn reconstruction, and to compare them with full-thickness skin grafting (FTSG).

Method: A retrospective review was performed on patients with joint-related burn injuries treated between August 2021 and August 2023 at Kaohsiung Chang Gung Memorial Hospital in Southern Taiwan. Patients underwent AD+STSG or FTSG based on wound depth. Primary outcomes included graft take, infection rate, and donor-site morbidity. Secondary outcomes included 12-month scar quality using the Vancouver Scar Scale and joint range of motion. Patients lacking adequate follow-up were excluded.

Results / Discussion: AD use promoted robust granulation, enabled reconstruction of larger or deeper defects, reduced donor-site burden, and achieved reliable graft take. At 12 months, scar appearance and joint mobility were comparable to or improved over those in the FTSG group.

Conclusion: AD+STSG appears to be an effective and versatile option for joint-involved burn wounds, providing favorable wound healing, reduced donor morbidity, and preserved functional outcomes.

EP406 Milk burns resulting from home accidents; approach to burn treatment in children: A case report

Canan Bulut Ayaz[1], Harun Tekin[1]

[1]*Kutahya Cıty Hospital, Kutahya, Türkiye*

Aim: The choice of appropriate dressing materials significantly influences the healing process in pediatric burn patients. The aim of this case report is to evaluate the rapid healing achieved with daily application of enzyme + alginate gel and tulle dressing in a four-year-old child with second-degree burns on the face, neck, and shoulder caused by hot milk spillage.

Method: Daily dressing changes were initiated on the first day for the second-degree burn areas. The treatment protocol included gentle cleansing of the burn wound, application of enzyme-based alginate gel, and coverage with sterile tulle dressing. Dressings were replaced daily following the same protocol.

Throughout the treatment, signs of infection, pain level, tissue viability, and epithelialization were assessed on a daily basis.

Results / Discussion: By the third day of treatment, a marked reduction in erythema and edema was observed. On the fifth day, epithelialization had accelerated, necrotic tissues had cleared completely, and pain had significantly decreased. By the seventh day, full epithelialization was achieved, and healing was complete. No signs of infection, delayed healing, or significant scar formation were noted during the course of treatment.

Alginate gel supported rapid epithelialization by providing a moist wound environment, while its enzymatic component facilitated atraumatic debridement. The tulle dressing preserved the effect of the gel and allowed painless dressing changes. The accelerated healing observed in this case suggests that this dressing combination may serve as an effective and comfortable treatment option for pediatric burns.

Conclusion: The use of enzyme + alginate gel in combination with tulle dressing represents a safe, practical, and effective treatment approach for achieving rapid healing in second-degree burns in pediatric patients.



EP066 Novel management of burns in pediatric patients with bacterial biocellulose

Juan Eduardo Gonzalez Aboytes[1], Vanessa Navarro Muñoz[1], Juan Ascencio Reyes[1], Jose Ruiz Aguirre[1], David Medina Preciado[1], Aldo Arana Gomez[1], Leticia Chavez Dagostino[1], Ariel Miranda Altamirano[1], Adolfo Ruiz[1], Jesus Briseno[1], Andre Galvez Ramirez[1], Raquel Gaitan Vargas[1]

[1]*Hospital civil de Guadalajara "Fray Antonio Alcalde", Guadalajara, Mexico*

Aim: To demonstrate the use of the bacterial biocellulose membrane that has a safe use in the treatment of superficial and deep second-degree burns in pediatric patients.

Method: A cross-sectional observational study was conducted between June 2024 and June 2025. Following initial management, fluid resuscitation, surgical cleaning (hydrosurgery, mechanical with sterile gauze) with tissue debridement in 50 patients, a bacterial biocellulose dressing (Membracel) was applied. After application, a decrease in pain was observed, secondary dressings remained dry without increasing odor perception, and epithelialization >95% of the affected surface was achieved 5-7 days after removal of the secondary dressings.

Results / Discussion: Significant evidence of epithelialization 5-7 days after placement, in outpatient follow-up with a decrease in hypertrophic/keloid scars.

Conclusion: It is a safe and reliable dressing treatment option for superficial and deep second-degree burns in pediatric patients, and can be used on any skin surface.

EP067 Bromelain enzymatic debridement combined with other modern devices in deep burns treatment - a clinical study

Camelia Tamas[1], Angela Tecuceanu[1], Radu Tataru[1], Audrey Clebant[1], Ioana Tamas[1], Irina Jemnoschi-Hreniuc[1], Cristina Stanescu[2], Catalina Pintilie[1]

[1]Grigore T. Popa University of Medicine and Pharmacy Iasi, Emergency Saint Spiridon County Hospital Iasi, Iasi, Romania, *[2]University Dunarea de Jos Galati, Emergency Saint Spiridon County Hospital Braila, Braila, Romania*

Aim: To evaluate the clinical performance of enzymatic debridement with bromelain, in deep burns, in combination with other devices as bacterial nannocellulose dressing (BCN, hydroactive compresses, dialkylcarbamoyl –chloride dressing (DACC) or negative pressure wound therapy (NPWT).

Method: Our study included 36 patients with 2nd B-3rd degree thermal burns on 15–45% of total body surface area (TBSA) who underwent enzymatic debridement. 12 patients received classical protection dressing after bromelain (control group). The rest were treated with NPWT (12 cases) or with other devices able to stimulate the healing process as bacterial nannocellulose dressing, hydroactive compresses, dialkylcarbamoyl –chloride dressing (12 cases). We evaluated the thickness of burn wound, before and after enzymatic debridement, and the progression of the healing process using a Periscan Laser Doppler system.

Results / Discussion: Enzymatic debridement was efficient in all the cases. 16 patients with burns located on 20-45% TBSA needed skin grafts (micrografts in 14 cases, meshgrafts in 2 cases). The use of NPWT over the skin grafts stimulated the wound healing, reduced hospitalization days and the infection risk, as confirmed by bacteriological examination. This approach was more effective (healing daily rate of 4.14 – 3.98% from the initial burn area) compared to enzymatic debridement followed by other devices (3.07 – 2.98%) or to the control group (2.34-2.02%).

Conclusion: The combination of bromelain with NPWT is an efficient alternative to surgical treatment, improving healing, reducing the need for skin grafts and pain level associated with dressing changes. Bromelain proved to be useful in extensive burns treatment, where skin-grafts donor zones reserves are limited.

EP407 Clinical outcomes of a bacterial nanocellulose dressing in partial-thickness burns: A retrospective study of 35 patients

Alexandru-Hristo Amarandei[1], Andra Bulgaru-Iliescu[1], Stefana Luca[1], Dan Crstian Moraru[1], Mihaela Pertea[1]

[1]U.M.F. Grigore T. Popa Iasi, Iasi, Romania

Aim: To assess healing outcomes, pain evolution, and treatment tolerability associated with a nanocellulose biosynthetic wound dressing in patients with partial-thickness thermal burns.

Method: A retrospective analysis was conducted on 35 consecutive patients treated between 2022–2024. Eligibility criteria included partial-thickness burns (IIA–IIB), total burn surface area (TBSA) 5–20%, early application of the nanocellulose dressing, and complete follow-up until full re-epithelialisation. Variables collected included patient age, burn depth and extent, timing of application, pain scores (VAS), need for dressing changes, healing time, and complications. All patients were monitored clinically until complete epithelial coverage was achieved.

Results / Discussion: The cohort included 35 patients with a mean age of 47 years and TBSA ranging from 5% to 20%. The dressing was applied within the first 24 hours post-injury in most cases. Pain scores decreased markedly within the first 24 hours of application (median VAS 7 → 3). No patient required re-dressing, as the nanocellulose matrix remained adherent and stable throughout the healing period. Complete re-epithelialisation occurred within a median of 11–14 days. No patient required split-thickness skin grafting. No cases of invasive infection, allergic reactions, or dressing-related complications were recorded. Early scar quality at short-term follow-up (4–6 weeks) showed satisfactory pliability and pigmentation.

Conclusion: The nanocellulose biosynthetic dressing provided reliable healing, substantial pain reduction, and high patient tolerability in partial-thickness burns. Its stability and moisture regulation supported predictable re-epithelialisation without grafting, making it a valuable option in modern burn care.

EP069 Oxygen-enriched olive-oil dressing in moderate-degree pediatric burns: Impact on care and budget in a tertiary children's hospital

Silvia Borghetti[1], Ugo Maria Pierucci[2], Chiara Palladino[1], Stefania Vimercati[1], Francesca Selmin[3], Andrea Marcellusi[3], Giulia Tosi[1], Alessia Musitelli[2], Irene Paraboschi[2 4], Gloria Pelizzo[2 4]

[1]Pharmacy Unit, ASST Fatebenefratelli-Sacco, Milan, Italy, *[2]Department of Pediatric Surgery, "V. Buzzi" Children's Hospital, 20154 Milan, Italy, Milan, Italy*, *[3]Department of Pharmaceutical Science (DISFARM), University of Milan, Milan, Italy*, *[4]Department of Biomedical and Clinical Science, University of Milano, Milan, Italy*

Aim: Pediatric burns pose a substantial clinical and economic burden, largely driven by prolonged hospitalization. This study aimed to evaluate whether integrating an oxygen-enriched olive-oil dressing (NovoX®) into the management of moderate-degree pediatric burns could reduce length of stay and generate measurable budget benefits for a tertiary children's hospital.

Method: A hospital-perspective budget impact analysis was conducted according to ISPOR guidance over a 4-year horizon (2022–2025). The analysis included 32 inpatients (<18 years) with grade I–IIG burns involving <20% TBSA, treated between 2022 and 2023. Two scenarios were modeled: standard of care (SoC) and SoC plus the oxygen-enriched olive-oil dressing (OEoD). Costs included dressings, medications, devices, and hospitalization expenses, using data from the hospital Control & Management Unit. The mean daily hospitalization cost was €1,438.99. Annual caseload projections were applied for 2024–2025.

Results / Discussion: OEoD increased per-patient dressing expenditure compared with SoC (€271.4 vs €121.9) but markedly reduced length of stay (13 vs 20 days). This reduction in LOS generated consistent savings in total hospital costs across all modeled years, with annual decreases of 7%, 13%, 16%, and 18% between 2022 and 2025. For instance, projected 2025 costs were €612,516 with OEoD versus €751,445 with SoC (Δ –€138,929). The cumulative 4-year savings reached €337,399. Sensitivity analyses supported the robustness of these findings, with economic benefits persisting under varied assumptions.

Conclusion: Incorporating oxygen-enriched olive-oil dressings into pediatric burn care was associated with shorter hospitalization and substantial budget savings, despite higher dressing acquisition costs. These findings support their adoption within multidisciplinary burn management pathways and warrant further prospective, multicenter evaluation.

EP408 Control of wound infection of combat burns with probiotic antiseptic

Olga Kovalenko[1], Oleksandra Lynnyk[2], Anton Kovalenko[3]

[1]KNP Medical Center City Kyiv Burn Clinic, Shupyk National Healthcare University of Ukraine, Kyiv, Ukraine, *[2]Shupyk National Healthcare University of Ukraine, Kyiv 04112, Ukraine*, *[3]KNP Medical Center City Kyiv Burn Clinic, Kyiv 02059, Ukraine*

The wounded who arrive from the battlefield at the evacuation stages already have infected wounds and burns. Each stage adds its own hospital microflora.

Aim: To improve the treatment outcomes of patients with infected combat burn wounds with multiresistant microflora through the use of probiotic antiseptics based on Bacillus bacteria

Method: The study involved 29 patients with infected combat burn wounds who arrived during the military evacuation. In the main group of wounded (n=15), probiotic antiseptics based on Bacillus bacteria were used for local treatment, and in the control group (n=14) traditional antiseptics were used. The levels of pro-inflammatory markers (IL-6, α2-macroglobulin, CRP, procalcitonin) were studied; the type of microflora and sensitivity to antibiotics were determined; and the type of cytogram upon admission to the hospital (day 1 in the burn center) and on the 7th and 14th days were assessed.

Results / Discussion: Wound infection delays healing. Analysis of changes in pro-inflammatory markers between the first and seventh days of the study showed that only in the main group was there a statistical difference (IL-6 (P=0.005), macroglobulin-α (P=0.001), CRP (P=0.015)), procalcitonin P=0.002)), regenerative-inflammatory and

regenerative type of cytogram on the 14th day in the main group was statistically different from the control group (p=0.002 and p=0.002). Probiotic antiseptics changed the quantity and quality of wound microflora.

Conclusion: Topical application of probiotic antiseptics leads to positive dynamics of systemic inflammation indices, changes in microflora to one sensitive to antibiotics in patients with infected combat burn wounds. Probiotics can accelerate wound healing due to their pronounced antipathogenic and immunomodulatory effects (p<0.001).

EP070 Hyaluronic acid and silver sulfadiazine – essential compounds in the treatment of burns after enzytmatic debridement

Mihaela Pertea[1], Alexandru-Hristo Amarandei[2], Andra Bulgaru Iliescu[1], Dan Cristian Moraru[3]

[1]Grigore T Popa University of Medicine and Pharmacy Iasi Romania, Iasi, Romania, *[2]Grigore T Popa University of medicine and Pharmacy Iasi Romania, Iasi, Romania*, *[3]Grigore T popa University of Medicine and Pharmacy Iasi Romania, Iasi, Romania*

Aim: Hyaluronic acid (HA) is an extracellular matrix component. It decreases the infiltration of inflammatory cells, improves re-epithelization and granulation, and promotes angiogenesis. HA and silver sulfadiazine (SSD) have been used in therapy of burns like a topical treatment. This study aims to investigate the effectiveness of hyaluronic acid and silver sulfadiazine association for treating superficial and deep second-degree burns.

Method: The study was conducted on 82 patients aged 20 to 82 years old, with II-nd degree burn (superficial and deep), not exceeding 25% of total body surface area. Data pertaining to epidemiologic status of the patients, etiology, and degree and percentage of burn were collected. The etiology of burns was hot liquid, contact burns, electricity and flame burn. All patients received enzymatic debridement as initial treatment of burn lesions. In all cases HA was applied from the second day after debridement

Results / Discussion: Healing time varied between 10 and 30 days. Furthermore, this topical association had favourable antibacterial, anti-edematous and local analgesic effects, with an evident stimulatory activity on the re-epithelialization process. All cases needed pain management.

Conclusion: Because of its hygroscopic proprieties, HA provides a proper environment for tissue regeneration, with important use in scar management. Our study confirms all of this, proving that using HA and SSD has a significantly favourable response concerning the average healing time of superficial or deep partial-thickness burns.

EP072 Octenidine antiseptic solution in deep extensive burn wound management-single center experience

Jelena Isakovic Subotic[1], Branko Sudjecki[1], Miodrag Karamarkovic[1], Nevena Mutavdzic[1], Milana Jurisic[1], Filip Milosevic[1], Jelena Jeremic[1 2], Marko Jovic[1 2], Milan Jovanovic[1 2], Maja Nikolic Zivanovic[1], Milan Stojicic[1 2]

[1]Clinic for Burns, Plastic and Reconstructive Surgery, University Clinical Center of Serbia, Belgrade, Serbia, *[2]University of Belgrade Faculty of Medicine, Belgrade, Serbia*

Aim: To assess the clinical effectiveness of an octenidine-based antiseptic solution in the local management of deep extensive burns, with accent on infection control and wound monitoring.

Method: A retrospective case series of seven patients with extensive burns treated in 2025 was analysed. The cohort included four males and three females aged 18–84 years. Burn mechanisms included flame injuries (n=4) and electrical injuries (n=3). Total body surface area (TBSA) ranged from 20% to 70%, with most injuries classified as deep partial-thickness or full-thickness burns. Inhalation injury was present in four patients. The antiseptic solution was introduced between day 8 and day 50 post-injury, following positive microbiological swabs, and used for wound irrigation and dressing changes (5–20 applications per patient).

Results / Discussion: All patients had positive microbiological cultures for Acinetobacter spp. and Enterococcus spp., with frequent co-isolation of Pseudomonas spp. (71.4%) and Klebsiella spp. (57.1%) and exhibited clinical signs of both local and systemic infection prior to initiation of octenidine-based antiseptic. Following implementation, no survivors developed progressive systemic inflammatory deterioration attributable to wound infection. Due to its colorless formulation, the solution allowed continuous visual assessment of the wound bed without masking tissue viability. A clinically evident reduction in bacterial burden was observed, facilitating preparation for definitive wound coverage. One patient achieved spontaneous epithelialization (27% TBSA), while the remaining patients underwent split-thickness skin grafting using temporary human skin allografts and definitive autografts. Only one patient with 70% TBSA died.

Conclusion: In deep extensive burns with confirmed infection, octenidine-based antiseptic therapy supported infection control, better wound surveillance, and contributed to preservation of graft viability, supporting its role as a valuable tool in modern burn care.

EP073 Living skin donation for burn patients: A single-center retrospective analysis

Branko Sudjecki[1], Miodrag Karamarkovic[1], Jelena Isakovic Subotic[1], Milana Jurisic[1], Filip Milosevic[1], Nevena Mutavdzic[1], Marko Jovic[1 2], Jelena Jeremic[1 2], Milan Jovanovic[1 2], Maja Nikolic Zivanovic[1], Milan Stojicic[1 2]

[1]Clinic for Burns, Plastic and Reconstructive Surgery, University Clinical Center of Serbia, Belgrade, Serbia, *[2]University of Belgrade Faculty of Medicine, Belgrade, Serbia*

Aim: Reporting demographic characteristics, safety profile, and complication rate of living skin donation used for temporary burn coverage.

Method: A retrospective analysis was performed on 124 consecutive living skin donors who underwent skin harvesting between 2019 and 2025. Eligible donors were healthy volunteers aged 18–65 years, commonly relatives or acquaintances of burn patients. Donor and recipient surgeries were performed simultaneously in separate operating rooms. Split-thickness skin grafts were harvested from the thighs using an electric dermatome set at 0.2 mm and immediately transferred for temporary burn wound coverage. Donor sites were dressed with paraffin gauze, antiseptic dressings, dry sterile gauze, and compression bandages. Early mobilization and physiotherapy were encouraged in all patients. The first dressing change was performed on postoperative day 7 and repeated on day 14. Study variables included sex, age, length of hospital stay, and complication profile.

Results / Discussion: The cohort consisted of 97 male (78.2%) and 27 female donors (21.8%) with a mean age of 37.9 ± 10.4 years. Mean hospital stay was 8.7 ± 3.4 days and did not differ significantly between sexes. In most donors, complete epithelialization was achieved within 14-15 days following skin harvest. The overall complication rate was 4.8%, and delayed donor-site healing was the only recorded adverse event. Four donors required further inpatient management, while two were treated successfully on an outpatient basis. Female donors exhibited a higher complication rate compared to males (14.8% vs. 2.1%).

Conclusion: Living skin donation remains a lifesaving procedure in low- to moderate-resource settings, demonstrating a favorable safety profile, lower complication rate, and rapid donor-site healing. Strict donor selection and standardized perioperative care ensure donor safety and favorable outcome.

EP409 Bacterial nanocellulose for burn wound management: A systematic review of therapeutic efficacy and mechanisms of action

Raman Lotfi[1], Mehrnaz Boroumand[1], Javad Ghorbani[2], Kimia Soltaniha[1]

[1]Member of Alborz University of Medical Sciences Research Committee, Karaj, Iran, Member of Zakhm Karaj Wound Clinic, Alborz University of Medical Sciences, Karaj, Iran, Karaj, Iran, [2]Non-Communicable Diseases Research Center, Alborz University of Medical Sciences, Karaj, Iran, Head of Zakhm Karaj Wound Clinic, Alborz University of Medical Sciences, Karaj, Iran, Karaj, Iran

Aim: This systematic review and meta-analysis aims to definitively evaluate the efficacy of bacterial nanocellulose (BNC) dressings in burn wound management. It synthesizes clinical and preclinical evidence on patient-centered outcomes—including healing time, infection rate, and analgesia—against standard care. A core objective is to analyze BNC's bioactive mechanisms and assess its potential as a functionalized, multi-functional therapeutic platform.

Methods: This PRISMA 2020-compliant review conducted a systematic search (2000-2024) of major databases using defined MeSH/keyword terms for BNC and burns. Eligible PICOS criteria included: (P) human/animal burn models; (I) BNC dressing; (C) standard care; (O) healing time, infection, pain, histopathology; (S) controlled trials. Two reviewers independently executed study selection, data extraction, and bias assessment. Meta-analysis was performed on homogeneous data.

Results / Discussion: Synthesis of 28 studies (7 RCTs, n=542; 21 preclinical) demonstrates BNC dressings significantly accelerate healing, reducing epithelialization time by a mean of -3.8 days (95% CI: -5.1 to -2.5), lower procedural burden (45% fewer dressing changes), and improve analgesia. Preclinical evidence confirms bioactive mechanisms, including modulation of pro-inflammatory cytokines and promotion of angiogenesis. Functionalized BNC enhances antimicrobial efficacy (>99% bioburden reduction). Clinical infection rates were lower with BNC (5.6% vs. 14.3%; RR: 0.39) with excellent biocompatibility.

Conclusion: This review establishes bacterial nanocellulose (BNC) as an active therapeutic agent for burns, not merely a passive dressing. Clinical evidence confirms BNC expedites healing, reduces procedural burden, and improves infection control. Preclinical data elucidate its mechanistic role in modulating inflammation and promoting angiogenesis. Critically, BNC's potential as a customizable drug-delivery platform is validated. Future translation necessitates large-scale RCTs with standardized formulations and health-economic analyses to integrate BNC into next-generation burn protocols.

EP410 Comparative outcomes of surgical escharotomy and bromelain-based enzymatic debridement in burn-related compartment syndrome: A retrospective study of 35 patients

Alexandru-Hristo Amarandei[1], Pertea Mihaela[1], Moraru Dan Cristian[1], Andra Bulgaru Iliescu[1], Stefana Luca[1]

[1]U.M.F. Grigore T. Popa Iasi, Iasi, Romania

Aim: To compare surgical escharotomy and bromelain-based enzymatic debridement as decompressive strategies in circumferential deep burns with evolving compartmental compromise, evaluating perfusion recovery, metabolic stabilization, and the need for secondary interventions.

Methods: A retrospective analysis of 35 patients treated between 2019–2024 was performed. Two cohorts were evaluated: escharotomy group (n = 18) and enzymatic debridement group (n = 17). Collected parameters included capillary refill, Doppler signal, CK kinetics, requirement for secondary decompression, quality of tissue demarcation, time to definitive wound closure, complications, and limb salvage.

Results/Discussion: Escharotomy provided immediate release of external constriction, rapidly restoring macroperfusion. Enzymatic debridement produced a gradual but stable improvement in perfusion indicators, with significantly faster metabolic normalization. CK levels declined below 4,000 U/L within ≈48 hours in the enzymatic group versus ≈96 hours after escharotomy, indicating earlier resolution of muscle ischemia. Secondary decompression was required in 5/18 (28%) patients in the escharotomy cohort and in 0/17 in the enzymatic cohort.

Enzymatic eschar removal provided markedly clearer tissue demarcation, allowing earlier reconstructive planning and fewer re-interventions. Time to definitive closure was shorter following enzymatic debridement (5–6 days) compared with escharotomy (8–9 days). Infection rates, transfusion needs, and limb salvage were similar, with no limb loss in either group.

Conclusions: While surgical escharotomy remains indispensable for immediate decompression in established compartment syndrome, bromelain-based enzymatic debridement offers faster metabolic stabilization, improved tissue differentiation, and reduces secondary surgical interventions. These findings support its role as an effective alternative decompressive strategy in selected burn patients with evolving but not yet fixed compartmental compromise.

EP074 Combined enzymatic debridement protocol vs standard care in burns: A tissue-sparing retrospective study

Dan Cristian Moraru[1], Alexandru-Hristo Amarandei[1], Andra Bulgaru Iliescu[1], Stefana Luca[1], Mihaela Pertea[1]

[1]*"Grigore T. Popa" University of Medicine and Pharmacy, Iasi, Romania*

Aim: To assess whether a novel sequential enzymatic debridement approach improves burn healing outcomes and tissue preservation compared to the standard enzymatic debridement protocol.

Method: A retrospective study was conducted on 42 burn patients (2022–2025). Patients included had deep partial-thickness thermal burns covering ≤15% total body surface area (TBSA), no inhalation injury, no chemical/electrical burns, and no major comorbidities. They were grouped by treatment protocol. 21 patients received the combined enzymatic approach, consisting of initial rapid eschar removal with a bromelain-based enzyme, followed by alternating applications every 3 days of a collagenase ointment derived from *Vibrio alginolyticus* and a silver sulfadiazine (SSD) cream enriched with hyaluronic acid (HA). The other 21 patients underwent the standard protocol of a bromelain-based enzymatic debridement followed by daily SSD (without HA). Key outcomes (time to complete wound epithelialization, need for skin grafting, and infection rates) were compared between groups.

Results / Discussion: The sequential enzymatic protocol significantly accelerated wound healing, with a median time to full epithelialization of 21 days versus 28 days in the standard care group ($p<0.01$). A higher proportion of patients in the combined treatment group achieved complete healing without surgical excision or skin grafting (81% vs 52%, $p<0.05$). Infection rates were low and not significantly different between groups. These findings suggest that the combined approach preserved more viable tissue, indicated by a greater spontaneous healing rate.

Conclusion: The innovative enzymatic debridement protocol (bromelain-based rapid debridement followed by collagenase + HA) yielded superior outcomes compared to the conventional enzymatic approach. This tissue-sparing strategy facilitated faster re-epithelialization and reduced the need for grafting, underscoring its potential as a valuable advance in burn wound management.

EP411 Experiences with nanomedic: Use of a synthetic nanofibre epidermal substitute dressing in the treatment of burn injury at the Prague Burn Centre

Hubert Suca[1], Peter Gál[2 3]

[1]*Prague Burn Center, Third Faculty of Medicine, Charles University and University Hospital Kralovske Vinohrady, Prague, Czech Republic, Department of Pharmacology, Faculty of Medicine, Pavol Jozef Safarik University, Kosice, Slovak Republic, Department of Biomedical Research, East-Slovak Institute of Cardiovascular Diseases, Kosice, Slovak Republic, Prague, Czech Republic*, [2]*Prague Burn Center, Third Faculty of Medicine, Charles University and University Hospital Kralovske Vinohrady, Prague, Czech Republic*, [3]*Department of Pharmacology, Faculty of Medicine, Pavol Jozef Safarik University, Kosice, Slovak Republic, Department of Biomedical Research, East-Slovak Institute of Cardiovascular Diseases, Kosice, Slovakia*

Aim: The use of nanofibre materials in medicine has gained substantial attention over the past decade, particularly in the field of wound healing, and in recent years these technologies have reached clinical application. In this poster, we present and summarise our experiences in series of cases with the bedside application of a synthetic epidermal substitute created via electrospinning—SPINCARE™—and its use in the operating theatres of the Prague Burn Centre.

Methods: The SPINCARE™ device produced nano-fibre was applied in 28 patients with a median age of 1.50 years (IQR: 1.25–3.00; range: 0.58–52.00 years), with superficial (IIa) and intermediate dermal (IIab) degree burns, hospitalised and treated at the Prague Burn Centre between years 2021 and 2025. The majority of patients (n=23; 82.1%) sustained scald injuries, predominantly within the pediatric age group (median age: 1.50 years), flame burns were recorded in 5 patients (17.9%), representing an older demographic (median age: 46.00 years). The overall mean extent of the thermal injury was 9.05% ± 4.19% TBSA (range: 2.0–18.0%). The scald group exhibited a mean TBSA of 9.37% ± 4.31%, while the burn group showed a mean TBSA of 7.60% ± 4.62%. Burn depth and extent were assessed by an experienced burn surgeon on the day of injury. Excluded werw the burns with presence of deeper burns (IIb and III degree). Under general anaesthesia, the burn wound was cleansed with an antiseptic solution (Prontosan®), followed by careful mechanical debridement using sterile gauze. Subsequently, the nano-fibrous synthetic temporary epidermal cover (SPINCARE™) was applied over the entire burn surface, then covered with a non-adherent silicone dressing (Mepitel®), dry sterile gauze and elastic lightweight bandage. The healing process was monitored by a surgeon and photographed until complete epithelialisation. Recorded clinical parameters included ease of application, dressing adherence, the need for re-intervention, requirement for general anaesthesia and length of hospital stay.

Results: The overall mean time to re-epithelialization was 8.93 ± 1.62 days, with a mean hospital stay of 7.5 days. When stratified by wound depth, the healing time was 8.33 ± 1.28 days for Grade 2a and 9.20 ± 1.48 days for intermediate Grade 2ab injuries. Although in 2 cases with focal progression to Grade 2b components with local purulent secretion without specific bacterial findings or general signs of infecion. This deep dermal component represented 18.75% and 0.71% of their respective total burn areas. Only 1 patient required subsequently STSG with up to 21 days for full maturation, primary superfitial surface closure in these mixed-depth lesions was achieved within the initial 9-day period. No significant difference in healing kinetics was observed between scalds (8.74 ± 1.51 days) and burns (9.40 ± 1.67 days), Surgical management was highly efficient, with 92.9% of the cohort (n=26/28) requiring only a single intervention under general anaesthesia. Only two patients (7.1%) necessitated more than one general anaesthetic procedure. The average length of hospital stay (LOS) was 7.39 ± 2.64 days, with a mean of 7.61 days for the scald group and 6.40 days for the burn group, reflecting a streamlined clinical workflow and rapid stabilisation of the patients.

Conclusions: Our findings demonstrate that nano-fibre dressings provide uniform and reliable wound coverage, including in anatomically challenging areas, while forming an elastic protective layer that does not restrict daily activities. SPINCARE™ adhered to the wound surface until full healing without the need for re-application, fewer operating theatre visits, reduced need for general anaesthesia (especially relevant in paediatric patients), shorter hospital stays and an overall reduction in treatment costs. These outcomes reflect the expected performance of a modern epidermal wound covering and confirm its benefits across different clinical indications, particularly in patients with superficial thermal injuries. Looking ahead, we see significant potential in modifying this nano-fibre material with pharmacologically active substances to further influence the healing process, control microbial growth, reduce pain, and minimise scarring.

Acknowledgement: Study was supported by the Czech Health Research Council grant no. NW24-08-00073.

CASE STUDIES

EP500 Comprehensive wound care strategies for enteroatmospheric fistula following pediatric liver transplantation: A five-year journey

Tuğçe Aksan[1], Ecem Eren[2]

[1]Koç University School of Medicine, Istanbul, Türkiye, [2]Koç University Hospital, Istanbul, Türkiye

Aim: Although enteroatmospheric fistula (EAF) occurs in 5–25% of adult open abdomen cases, it is rare in children with limited data post-liver transplants. This case illustrates how specialized nurses manage EAF—from development to closure—in the context of a pediatric transplant patient.

Method: This is a case report describing EAF and peristomal skin complications management in a pediatric patient who required open abdomen care following liver transplantation and EAF closure.

Results / Discussion: A male infant born at 33 weeks (1060 g) developed neonatal cholestatic hepatitis and had a living donor liver transplant at 9 months. Postoperative abdominal compartment syndrome necessitated ten laparotomies and Bogota bag use. NPWT started on day 28 and concluded on day 40 following the detection of biliary and enteric fistulas. After 1.5 months of conservative management, the wound was managed by specialized nurses. Assessments identified one bile fistula, one EAF, and severe dermatitis. Nursing interventions focused on treating dermatitis and managing the EAF utilizing stomadevices. Despite substantial effluent, wound care involving powder, barrier spray, alginate dressing, hydrocolloid, paste, and pouches achieved epithelialization by April 2021. The bile fistula closed spontaneously; the EAF was maintained until surgical closure in June 2025. Postoperative incision complications, including inflammation, dehiscence, and slough, were addressed with hypochlorousacid, barrier spray, and enzyme-alginogel. The frequency was gradually reduced, and full epithelialization was achieved by August 29, 2025. Remodelling with *Centellaasiatica* and *Triticum-vulgare* creams was continued for two months.

Conclusion: When spontaneous or early surgical closure isn't feasible, stoma and wound care nurses turn complex fistulas into manageable, stoma-like conditions and handle peristomal and delayed healing issues. Their specialized care prevents complications, especially in immunosuppressed children.

EP502 Eye-tracking games and advanced dressings in pediatric burn treatment: A case report

Anna Hepa-Banasik[1], Magdalena Szatan[1]

[1]Burn Treatment Center, Dr. Stanisław Sakiel, Siemianowice Śląskie, Poland, Siemianowice Śląskie, Poland

Aim: Pediatric burns remain a significant clinical problem due to the unique vulnerability of children's skin and the potential for long-term physical and psychological consequences. The aim of this case report was to present the outpatient management of a 10-year-old girl with a 6% TBSA thermal burn, focusing on the integration of advanced dressings and non-pharmacological pain management using eye-tracking technology.

Method: A 10-year-old female sustained a mosaic scald burn involving the arm and chest (mainly IIB depth). The patient was admitted to an outpatient plastic surgery clinic two days after the injury. Treatment consisted of advanced synthetic skin substitutes, hydrofiber dressings with silver, and silicone foam dressings. Pain management included the use of eye-tracked computer games designed to distract the patient during dressing changes. Clinical progress was monitored during regular follow-up visits, assessing wound healing and pain intensity.

Results / Discussion: Outpatient management resulted in complete wound healing without the need for hospitalization, surgical demarcation, or autologous skin grafts. Use of advanced dressings supported moist wound healing and reduced scarring risk. Eye-tracking games significantly improved the child's tolerance of dressing changes, with notable reduction in perceived pain after the first session. This case highlights the dual importance of advanced wound coverage materials and innovative non-pharmacological pain control methods in pediatric burn management. Preventing hospitalization also reduced the risk of trauma and long-term psychological consequences.

Conclusion: Ambulatory treatment of pediatric burns can be safe and effective when combining advanced dressings with innovative analgesic strategies such as eye-tracking games. This multidisciplinary approach promotes wound healing, minimizes pain, and prevents invasive surgical interventions. Further implementation of such models may improve outcomes in pediatric burn care.

EP503 Advanced wound care and systemic immunosuppression in pyoderma gangrenosum: A case report

Anna Hepa-Banasik[1], Magdalena Szatan[1]

[1]Burn Treatment Center, Dr. Stanisław Sakiel, Siemianowice Śląskie, Poland, Siemianowice Śląskie, Poland

Aim: Pyoderma gangrenosum (PG) is a rare neutrophilic dermatosis, often associated with systemic diseases and characterized by rapid progression and severe pain. Diagnosis is challenging and treatment requires individualized, multidisciplinary approaches. This case report presents the management of a patient with PG resistant to conventional therapies, highlighting the role of advanced wound care and systemic immunosuppression.

Methods: A 67-year-old female presented with a rapidly progressing ulceration of the lower leg, preceded by pustules and intense pain. She had a history of rheumatoid arthritis. Initial outpatient care with topical antiseptics and standard dressings failed to prevent deterioration. After admission to a specialized wound care center, PG was diagnosed following exclusion of infection and vascular disease. Treatment included systemic corticosteroids, cyclosporine, and local therapy with atraumatic dressings, silver products, and negative pressure wound therapy (NPWT). Wound progress was monitored by photographic documentation and pain intensity scoring.

Results / Discussion: Within six weeks, significant reduction in wound size, pain, and inflammation was achieved. Granulation tissue progressively filled the ulcer bed, and exudate decreased. The combination of systemic immunosuppression and advanced local therapy stabilized the wound and improved quality of life. No major complications occurred. This case underscores the importance of early PG recognition, avoidance of surgical trauma (pathergy), and integration of systemic and local therapies.

Conclusion: Pyoderma gangrenosum remains a therapeutic challenge due to its rarity and diagnostic complexity. This case confirms that successful outcomes can be achieved through timely diagnosis, systemic immunosuppression, and advanced wound care strategies, emphasizing the essential role of multidisciplinary collaboration in managing rare chronic wounds.

EP504 Holistic treatment of necrotic wound caused by spider envenomation: Combining surgery, NPWT, HBOT and advanced dressings

Anna Hepa-Banasik[1], Magdalena Szatan[1]

[1]Burn Treatment Center, Dr. Stanisław Sakiel, Siemianowice Śląskie, Poland, Siemianowice Śląskie, Poland

Aim: Necrotic skin lesions caused by envenomation are extremely rare in Europe but present a major therapeutic challenge. The aim of this case report was to describe the holistic management of a patient with necrotic skin damage of the thigh following a bite by a Brazilian wandering spider (*Phoneutria* spp.), emphasizing the need for a multidisciplinary and individualized treatment approach.

Methods: A 61-year-old male presented with a non-healing thigh wound two months after a spider bite sustained during work. Initial outpatient therapy included antibiotics, iodine ointment, and silver dressings, but the wound deteriorated with progressive necrosis. The patient was admitted to a specialized wound care center where two surgical procedures (necrosectomy, sandwich graft with acellular dermal matrix and split-thickness skin graft) were performed. Adjunctive therapies included negative pressure wound therapy (NPWT), hyperbaric oxygen therapy (HBOT), and structured outpatient nursing care with advanced dressings containing collagen, extracellular matrix, hyaluronic acid, and silver. Microperfusion was monitored using laser speckle imaging.

Results / Discussion: Despite initial graft lysis, intensive multidisciplinary treatment combining surgery, NPWT, HBOT, and modern wound dressings led to gradual wound closure. Regular outpatient follow-up and mechanical debridement further supported tissue regeneration. The wound fully healed after several months, with no systemic infection observed throughout treatment. This case highlights the therapeutic challenges associated with rare wound etiologies and the importance of combining surgical, technological, and nursing interventions.

Conclusion: Chronic wound treatment requires comprehensive, multidirectional strategies. In rare cases such as spider envenomation, effective management is possible through timely surgical intervention, advanced adjunctive therapies, and specialized outpatient nursing care. Holistic therapy, supported by microperfusion monitoring, contributed to successful wound healing in this patient.

EP505 Successful healing with conservative treatment in a chronic hand wound with mycobacterium tuberculosis growing at the wound site following amputation recommendation: A 18-month follow-up case report

Aysegul Erciyas[1], Gulderen Ercoban[1], Secim Kaya[1], Serap Ulusoy[1]

[1]*Ankara Bilkent City Hospital, Ankara, Türkiye*

Aim: The aim of this study is to highlight the risk of complications associated with non-healing extremity wounds in patients with multiple chronic diseases such as rheumatoid arthritis, Crohn's disease and ankylosing spondylitis, and to present the successful healing of a dorsal hand wound with exposed tendons using conservative methods.

Method: A 53-year-old female patient, previously advised to undergo toe amputation due to a chronic wound, presented to our chronic wound clinic after refusing surgery. Conservative treatment was planned, and wound culture was obtained. Dressings with an enzyme-alginate gel providing autolytic debridement were applied once daily for two weeks, followed by antimicrobial enzyme-alginate gel from the third week onwards. The patient was monitored weekly initially, then monthly, with regular wound assessments, blood tests, and education on wound care and hand hygiene.

Results / Discussion: The patient had a 5×4 cm chronic wound with tendon exposure on the dorsal right hand after solid mass excision. MRI revealed osteomyelitis and loss of third finger function. Tissue culture grew Mycobacterium tuberculosis, and the patient received follow-up by the infectious diseases clinic. Progressive wound size reduction and tendon coverage were achieved during treatment, without infection or further complications. After 18 months of follow-up, complete epithelialisation was obtained, and limb loss was avoided.

Conclusion: This case demonstrates that conservative treatment and a multidisciplinary approach can achieve full wound healing and prevent amputation in chronic hand wounds unsuitable for surgery. The findings underline the importance of long-term follow-up and patient education, suggesting that such strategies may be effective alternatives for limb preservation in high-risk patients.

EP506 Limb salvage in a diabetic foot initially indicated for amputation successful outcome after revascularization and negative pressure wound therapy

Arya Prananda[1]

[1]*Faculty of Medicine Universitas Sumatera Utara, Adam Malik General Hospital Medan, The Clinic Beautylosophy, Medan, Indonesia*

Aim: To report a case of successful limb salvage in a diabetic foot initially indicated for below-knee amputation, emphasizing the role of revascularization and negative pressure wound therapy (NPWT) in avoiding major limb loss and restoring ambulation.

Methods: A 56-year-old male with diabetes mellitus presented with severe diabetic foot infection and ischemic changes for which major amputation had been planned. An alternative management strategy was initiated consisting of intensive wound care, repeated surgical debridement, vascular assessment followed by revascularization, strict limb

elevation, and sequential NPWT application. Clinical progress was monitored over a 6-month period through serial physical examinations and imaging, including computed tomography angiography.

Results: The patient demonstrated progressive wound healing with robust granulation and epithelialization. Although partial amputation of three necrotic toes was required, the forefoot and overall limb were preserved. After six months of multidisciplinary care, the patient achieved independent ambulation with preservation of the hallux and second toe, which provided sufficient weight-bearing stability. Imaging confirmed improved vascular perfusion. Scar maturation was favorable, and no further infectious complications were noted. The patient reported high satisfaction with both functional recovery and limb preservation.

Conclusions: This case highlights that with a multidisciplinary approach - combining revascularization, NPWT, and meticulous wound management - limb salvage is achievable in severe diabetic foot initially scheduled for major amputation. Even with partial digital loss, the preservation of critical toes allowed stable ambulation and improved quality of life. NPWT combined with vascular optimization should be considered a valuable adjunct in the comprehensive management of advanced diabetic foot wounds.

EP507 Successful management of a grade IV heel pressure ulcer in a 96-year-old patient with heart failure a case report

Muhammad Maleki[1], Hossein Hasani[1], Yasaman Zeinalou[1]

[1]*Nursing and Midwifery Care Research Center, Health Management Research Institute, Iran University of Medical Sciences, Tehran, Iran*

Aim: Pressure ulcers are common in elderly, immobile patients with chronic illnesses. Heel ulcers, particularly in advanced stages, pose a significant risk of infection, delayed healing, and reduced quality of life. Management of Grade IV pressure ulcers in very elderly patients with comorbidities such as heart failure remains a major clinical challenge.

Case Presentation:

A 96-year-old male with chronic heart failure presented with a right heel pressure ulcer that had developed two weeks earlier. On examination, the ulcer measured approximately 5 × 5 cm with extensive necrosis, consistent with a Grade IV lesion (NPUAP). Surrounding erythema and mild edema were observed, but no systemic infection was present. The patient was alert, hemodynamically stable, and had no history of diabetes or renal disease, though she was severely mobility-limited.

Method: Treatment included stepwise conservative sharp and autolytic debridement, application of advanced moist dressings every 48–72 hours, In the middle of treatment, after debridement of necrotic tissues, the tendon wound was exposed and grade 4 and the wound larger and approximately 10 x 5 cm. Prophylactic systemic antibiotics were prescribed, and strict aseptic wound care was maintained. Supportive measures included frequent repositioning, nutritional optimization, hydration, and family education for home care.

Results / Discussion: This case demonstrates that even in extremely advanced age with significant comorbidity, a multidisciplinary and individualized approach can achieve favorable outcomes. Prior studies confirm that staged debridement combined with advanced dressings accelerates healing and reduces infection risk. Addressing systemic factors alongside local wound care is critical to success.

Conclusion: Comprehensive, team-based management can result in successful healing of Grade IV pressure ulcers in high-risk elderly patients.

EP508 Sclerodermic foot ulcers: efficacy of a biocative dressing and proposal a novel risk stratification model

Lavinia Cacciatore[1]

[1]*Podokynamic, Licata, Italy*

Aim: This study pursues a dual objective: to evaluate the clinical effectiveness of a bioactive dressing containing Triticum vulgare (TVE) and polyhexanide in treating non-infected digital ulcers in a patient with systemic sclerosis (SSc), and to propose - for the first time - a dedicated risk stratification model for the sclerodermic foot, currently absent in the literature.

Method: A case report was conducted on a 61-year-old woman with SSc and non-infected, low-exudate digital ulcers. Treatment included cleansing every 48 hours with a TVE and polyhexanide-based spray, selective debridement, application of impregnated bioactive gauze, and weekly clinical monitoring (photographic documentation, wound area measurement, pain VAS scale).

In parallel, a new multidimensional tool - the ScleroFoot Risk Assessment Tool - was applied, integrating:

- Patient history and disease subtype
- Comorbidities and peripheral vasculopathy
- Foot examination (biomechanical and cutaneous changes)
- Diagnostic imaging (capillaroscopy, ABI, Doppler)
- Footwear and offloading assessment
- A weighted scoring system (low, moderate, high, critical)

Results / Discussion: The ulcer treated from July 12 to August 1 showed near-complete healing in 3 weeks (1.4 mm/week), with pain reduced from VAS 6 to 2 and no recurrence at 2-month follow-up. The ScleroFoot Tool categorized the patient as moderate risk, enabling a personalized treatment and prevention strategy. A retrospective comparison with a prior ulcer (Feb 23–Apr 5), treated using standard dressing, showed slower healing (0.5 mm/week), further supporting the effectiveness of the bioactive protocol.

Conclusion: This case demonstrates the clinical value of a TVE and polyhexanide-based dressing and introduces the first structured risk stratification model for the sclerodermic foot. This tool may enhance targeted prevention, support multidisciplinary care, and help reduce complications such as amputation. Further validation is recommended.

EP509 Treating a chronic leg ulcer - A multidisciplinary approach

Panteleimon Staktopoulos[1], Georgios Chatzikorios[2], Theodosios Bisdas[3]

[1]*Physiotherapist, Clinic for Vascular Surgery, Athens Medical Center, Athens, Greece*, [2]*Wound Manager, Clinic for Vascular Surgery, Athens Medical Center, Athens, Greece*, [3]*Vascular surgeon, Clinic for Vascular Surgery, Athens Medical Center, Athens, Greece*

Aim: Chronic leg ulcers are complex and recurrent conditions that often require a multidisciplinary strategy for effective management. This case highlights the role of coordinated care in the successful treatment of a longstanding venous ulcer.

Method: A 54-year-old male with morbid obesity (BMI 46.3 kg/m^2), chronic venous insufficiency and phlebolymphedema presented with a leg ulcer persisting for 25 years after a traumatic injury. The ulcer exhibited repeated healing-recurrence cycles, chronic edema and impaired quality of life. The patient was referred by a vascular surgeon to physiotherapy for preoperative edema management before treating superficial venous insufficiency. Complete Decongestive Therapy (CDT) was performed, achieving marked reduction in swelling, limb circumference and exudate. Concurrently, a wound care specialist nurse provided topical management including debridement, microbial culture, biofilm removal and appropriate dressings. An antibiogram guided targeted antibiotic therapy coordinated by the treating physician. After CDT, a silver flat knitted custom-made compression stocking was prescribed for long-term edema control.

Results / Discussion: Before vascular surgery, the ulcer had decreased but plateaued. A minimally invasive, incisionless procedure - laser-assisted saphenectomy of the great saphenous and connecting veins at the level of the ulcer plus sclerotherapy of any superficial varicose vein - was performed. The postoperative course was uneventful and complete wound healing occurred within 8 weeks. At 12-month follow-up, the patient maintained intact, softer skin and required no further ulcer care with consistent compression stocking use.

Conclusion: This case underscores the importance of multidisciplinary collaboration in managing chronic venous ulcers, particularly the role of limb preconditioning prior to any surgical procedure. The integration of physiotherapy, nursing, medical and surgical care facilitated complete healing and optimized long-term outcomes.

EP510 Tailored glove-shaped polyurethane foam design for NPWT in burn extremity salvage following multisite escharectomy

Arya Prananda[1]

[1]*Faculty of Medicine Universitas Sumatera Utara, Medan, Indonesia*

Aim: To describe the use of a customized glove-shaped polyurethane foam in NPWT for burn extremity salvage following multisite escharectomy, emphasizing wound bed preparation, functional preservation, and infection control.

Methods: Two patients with severe burn injuries of both upper extremities underwent early multisite escharectomy followed by NPWT. A glove-shaped polyurethane foam was tailored to fit the hand and fingers, ensuring uniform pressure distribution around complex anatomical contours. NPWT was applied at continuous –100 mmHg with dressing changes every 48–72 hours. Clinical outcomes assessed included granulation tissue quality, wound coverage readiness, infection control, and functional mobility.

Results: The glove-shaped foam conformed precisely to hand anatomy, preventing collapse of the wound cavity and maintaining pressure across interdigital spaces. Both patients achieved rapid granulation within 5 days, allowing secondary closure with grafts. No secondary amputations were required. Functional outcomes were favorable, with preservation of joint mobility and minimal scarring. Patients tolerated the device well, and no adverse events were reported.

Conclusions: Glove-shaped polyurethane foam in NPWT offers a practical and effective approach for managing complex burn wounds of the extremities. By providing tailored anatomical fit, it optimizes wound healing dynamics, supports limb salvage, and improves functional recovery. This technique may represent a valuable adjunct in reconstructive burn care protocols and warrants further evaluation in larger cohorts.

EP511 Non-uraemic calciphylaxis: A rare case report

James Tung[1], Peishi Lew[1], Ki Wei Tan[1]

[1]*Changi General Hospital, Singapore, Singapore*

Aim: Calciphylaxis is a rare, life-threatening condition marked by vascular calcification and thrombosis of small dermal arterioles, leading to painful, necrotic skin lesions. While typically seen in patients with end-stage renal failure (ESRF), non-uraemic calciphylaxis (NUC) occurs in individuals with preserved renal function and is often under-recognised. The aim of this case report is to describe the diagnosis and management of a case of non-uraemic calciphylaxis.

Method: We describe a 44-year-old woman with no renal impairment who presented with a non-healing lateral shin ulcer. Her history included morbid obesity, poorly controlled diabetes, and cardiovascular disease. Initial management with antibiotics and debridement failed. Skin biopsy confirmed calciphylaxis, revealing intramural vascular calcification. Laboratory tests showed mild secondary hyperparathyroidism and severe vitamin D deficiency. Imaging ruled out primary hyperparathyroidism. She was treated with 25mg of intravenous sodium thiosulfate (STS) three times per week, vitamin D supplementation, analgesia, and wound care with iodine-based dressings.

Results / Discussion: The patient was found to have significant improvement of her shin wound, with complete healing after 3 months.

Conclusion: This case highlights the diagnostic difficulty of NUC and emphasises the need for early biopsy in atypical ulcers. A multidisciplinary approach remains critical, and STS therapy may offer benefit despite being off-label. Greater awareness and further research are needed to optimise outcomes in NUC.

EP512 The silent amputation – How chronic wounds reshape the patient's world

Gabriela-Simona Vlantoiu[1]

[1]*Diabetologie Kaiserpassage, Reutlingen, Germany*

Aim: This case study explores what can be called a *"silent amputation"*—the invisible loss that occurs when chronic wounds reshape a patient's world. Beyond clinical outcomes, the purpose is to show how diabetic foot syndrome (DFS) alters identity, family life, and social participation, underscoring the need for holistic, patient-centered care.

Method: We observed a 65-year-old male with type 2 diabetes over four years. His course included recurrent ulcers, infections, amputations of toes on both feet, multiple endovascular interventions, and a femoral bypass. Care was primarily delivered in a specialized outpatient diabetic practice, complemented by several hospital admissions for acute interventions. A broad interdisciplinary network supported him: general practitioner, diabetology and wound care practice, orthopedic footwear technology, physiotherapy, radiology and hospital specialists. Patient narratives were documented alongside medical data to capture psychosocial impact.

Results / Discussion: Medically, all wounds are now closed. Yet the *"silent amputation"* was profound: the patient lost his profession, transitioned into disability pension, and struggled with fear, hopelessness, and the sense of premature ageing. Still, turning points emerged: empathy from clinicians, continuity of care, and teamwork across disciplines. These restored not only wound healing but also emotional resilience, dignity, and renewed trust. Despite persistent mobility restrictions, the patient reports a regained sense of belonging and quality of life.

Conclusion: The concept of the *"silent amputation"* captures the true burden of DFS: not only the physical loss of tissue, but the hidden amputations of independence, identity, and purpose. Healing must therefore extend beyond closure. Only by addressing physical, emotional, and social recovery together can we claim real success in diabetic foot care.

EP513 Post-gastrectomy esophagostomy care in a patient with mitochondrial disorder: A case report

Yunru Lu[1], Chia Fan Lin[1]

[1]*Cathay General Hospital, Taipei, Taiwan*

Aim: Mitochondria play a crucial role in energy production and cellular metabolism. Dysfunction may significantly affect postoperative wound healing, immunity, and infection risk. This case report discusses nursing interventions and outcomes in a patient with mitochondrial disorder who required an esophagostomy management after gastric cancer surgery.

Method: A 26-year-old male with congenital mitochondrial disorder underwent an esophagostomy in the left neck for saliva drainage due to poor anastomotic healing after proximal subtotal gastrectomy, with double tract reconstruction. A one-piece colostomy pouch was initially used to reduce skin damage, but frequent detachment caused irritation. Therefore, the care plan was modified to use a skin barrier film spray, pediatric urine bag, hydrocolloid paste, and continuous suction to prevent maceration. Furthermore, intravenous nutrition was provided, and serum albumin levels were monitored.

Results / Discussion: The pouch change frequency decreased from daily to once every 5–6 days. No peristomal dermatitis occurred, and saliva drainage was effective. As the patient's condition improved, intravenous nutrition was transitioned to enteral feeding. The caloric intake reached to 1200kcal per day, the protein intake achieved the target level of 1g/kg, and serum albumin improving from 3.1 to 3.4 g/dL.

Conclusion: Patients with mitochondrial disorders face challenges in wound healing and nutrition maintenance. Nurses should integrate nutritional support and esophagostomy care, collaborating with multidisciplinary teams to provide individualized, comprehensive care.

EP514 Hirudotherapy in peripheral arterial disease: Revisiting an ancient therapy for modern vascular challenges

Hashem Boalbanat[1], Hamad Alshuaib[1], Daniah Hassan[1], Khadeja Alrefai[1], Mohammed Hasan[1], Fatmah Alsughayer[1], Ahmad Alsarraf[1]

[1]*Ministry of Health, Kuwait, Kuwait*

Aim: To present a unique case of self-administered leech therapy in a patient with critical limb ischemia (CLI) who refused amputation, and to propose a broader literature review exploring the potential role of hirudotherapy in limb salvage for peripheral artery disease (PAD).

Method: We present a 50-year-old male with PAD and CLI unresponsive to medical and surgical interventions. The patient declined below-the-knee amputation and initiated self-treatment with medicinal leech therapy (hirudotherapy) over six months. Clinical outcomes were documented, and a review of relevant literature was initiated to assess the therapeutic potential and risks of leech therapy in similar vascular conditions.

Results / Discussion: Following six months of self-administered leech therapy (using four leeches, twice daily, five days a week), the patient demonstrated marked clinical improvement: resolution of ischemic pain, restoration of foot warmth, and reappearance of palpable distal pulses. No further pharmacological therapy was used during this period. Literature suggests hirudotherapy may offer benefits due to anticoagulant, thrombolytic, vasodilatory, and analgesic properties in leech saliva. However, complications such as infection and bleeding remain significant concerns. Existing data are largely limited to case reports, lacking randomized clinical trials or systematic evidence to support standard use in CLI.

Conclusion: This case underscores a potential adjunctive role for hirudotherapy in CLI, particularly where conventional interventions fail or are refused. Our ongoing review will evaluate broader clinical data to determine whether hirudotherapy merits further investigation in PAD/CLI treatment guidelines. Controlled trials are necessary to assess efficacy, safety, and reproducibility.

EP515 Holistic management of unstageable pressure ulcers in home healthcare services: A case study

Nadir Karahan[1], Cansu Özer Kaya[1], Meryem Kapanci[1], Sultan Aziz Yildiz[1]

[1]*Medipol Mega Üniversite Hastanesi, İstanbul, Türkiye*

Aim: This case study evaluates the effectiveness of a holistic and multidisciplinary approach in managing high-risk, unstageable pressure ulcers in home healthcare settings and describes the wound healing process supporting recovery.

Method: An 88-year-old male presented with an unstageable pressure ulcer measuring 12×9 cm and 7 cm deep in the right gluteal region. Initial assessment revealed a BMI of 19 kg/m^2, Hgb 10.10 g/dL, albumin 24.8 g/dL, and CRP 54.62 mg/L. Wound culture showed microbial growth, leading to systemic antibiotic therapy. Necrotic tissue was debrided in six sessions using complex enzyme algionegel (GLC). Sodium hyaluronate cream was applied to maintain

moisture and support cell proliferation. Negative pressure wound therapy (NPWT) was performed in nine sessions at 72-hour intervals to control exudate and promote granulation. Nutritional support, including protein, vitamin, and mineral supplementation, was provided, and caregivers were educated on positioning and prevention. Total treatment duration was 111 days.

Results / Discussion: After 65 days, follow-up tests revealed no microbial growth. Laboratory results showed improvement (Hgb 12.10 g/dL, Albumin 37.7 g/dL, CRP 16.77 mg/L), and the wound demonstrated marked size reduction, controlled exudate, and healthy granulation tissue formation.

Conclusion: The integration of wound debridement, NPWT, antibiotic therapy, nutritional support, and caregiver education accelerated healing and improved care quality. A holistic and multidisciplinary approach in Home Healthcare Services proved effective and feasible for managing high-risk unstageable pressure ulcers. Written informed consent and publication permission were obtained from the patient or legal representative for all data and images used in this case report.

	Initial Assessment				After 65 Days			
	Wound Culture	**Hgb**	**Albumin**	**Other**	Wound Culture	**Hgb**	**Albumin**	**Other**
Laboratory Results	*Escherichia coli, Klebsiella pneumoniae, Pseudomonas aeruginosa ve Staphylococcus aureus*	10.10 g/dL	24.8 g/dl	CRP 54.62 mg/L	No growth	**12.10 g/dL**	37.7g/dL	CRP 16.77 mg/L
Physical Assessment	**Pulse**	**Temperature**	**Color**	**Movement**	**Pulse**	**Temperature**	**Color**	**Movement**
	100 dk.	37.7 °C	Pale	Limited	75 dk.	36.7 °C	Normal	Limited



EP516 Application of an adapted T.I.M.E. concept in the management of a chronic wound in a patient with multiple comorbidities: a clinical case

Yunus Abdurakhmanov[1]

[1]*Kyrgyz State medical Academy named after I. K. Akhumbaev, Bishkek, Kyrgyzstan*

Aim: The management of extensive chronic wounds with comorbidities (Type 2 Diabetes, obliterating atherosclerosis) is challenging in resource-limited settings without advanced dressings. To demonstrate the efficacy of a strategy adapted from the T.I.M.E. concept, using readily available means and zoned therapy.

Method: A clinical case of a 65-year-old male with an extensive infected wound of the lower leg and heel following flap necrosis is presented. Treatment included:

1. Systemic management (diabetes compensation, vascular therapy);
2. Local staged therapy per T.I.M.E. principles: surgical/enzymatic debridement (T), antisepsis (I), moisture balance (M), and edge stimulation (E);
3. A key innovation—zoned application of medications (antiseptics, methyluracil, beta-sitosterol, dexpanthenol) to different areas of the heterogeneous wound bed.

Results / Discussion: Infection control was achieved within two weeks. The zoned therapy allowed for an in vivo comparison of regeneration stimulants: the highest epithelialization rate (0.7–0.8 mm/day) was noted with beta-sitosterol, surpassing methyluracil (0.4–0.5 mm/day). Complete epithelialization of the lower leg wound was achieved in 75 days, and the heel area in 88 days.

Conclusion: The consistent application of the T.I.M.E. concept, combined with zoned therapy, enables complete healing of complex wounds without expensive dressings. Efficacy is determined by a rational strategy, not product cost. The observed difference in epithelialization rates underscores the need for further research into the in vivo compatibility and efficacy of wound care agents and the development of specialized dressings for zoned treatment.



EP517 Successful management of a diabetic foot ulcer using enzymatic alginate gel

Sercan Kamalak[1], Ilgın Yıldırım Simsir[1], Zeren Suluoğlu[1], Serap Güven[1], Eylem Ceylan[1]

[1]Ege University Faculty of Medicine, Department of Internal Medicine, Division of Endocrinology and Metabolism Disorders, Izmir, Türkiye

Aim: To present a case of a Wagner grade 3 diabetic foot ulcer successfully managed with conservative therapy including enzymatic alginogel, highlighting its role in local wound healing.

Method: A 72-year-old female with a 30-year history of type 2 diabetes mellitus and multiple comorbidities presented with a chronic infected ulcer (1.5×4 cm) on the left heel, classified as Wagner grade 3. Laboratory findings revealed elevated inflammatory markers (CRP: 103 mg/L, WBC: 14,180/µL). Radiography suggested osteomyelitis.As recent coronary stenting posed a high cardiac risk, surgical debridement was deemed unsuitable . The patient was hospitalized and received intravenous piperacillin–tazobactam based on antibiogram results. During hospitalization, daily sharp debridement with a scalpel was performed by a wound care nurse. Local treatment with enzymatic alginogel was applied once or twice daily depending on exudate level, together with pressure offloading.

Results / Discussion: After 14 days, inflammatory markers decreased markedly (CRP: 17 mg/L), and the wound showed granulation and size reduction. The patient was discharged with oral antibiotic therapy and continued outpatient wound care with enzymatic alginogel. The ulcer achieved complete closure without surgical intervention and remained healed during one year of follow-up.

Conclusion: This case highlights that conservative multidisciplinary management—including infection control, offloading, and advanced local therapy—can achieve successful outcomes even in high-risk patients. The enzymatic alginogel supported wound healing through enzymatic debridement and antimicrobial activity, maintaining moist conditions and aiding biofilm control.

Generic name: enzymatic alginogel (Flaminal®, Flen Health, Belgium)

EP518 Complex post-gastrectomy fistula care: Skin integrity and multidisciplinary strategies

Tuğçe Aksan[1], Ecem Eren[1], Ezgi Şanlı[1], Onur Karaca[2], Zeynep İrem Gür[1], Serhat Özer[1], Ahmet Rencüzoğulları[3]

[1]Koç University Hospital, Istanbul, Türkiye, *[2]Yunus Emre Devlet Hastanesi, Eskişehir, Türkiye*, *[3]Koç University School of Medicine, Istanbul, Türkiye*

Aim: This report highlights the role of a multidisciplinary team in maintaining skin integrity and managing complex fistulas in a patient who underwent total gastrectomy for gastric cancer and developed multiple postoperative fistulas.

Method: The patient underwent total gastrectomy at an outside institution. Postoperative complications included esophageal and colonic fistulas, managed with endoscopic stent placement—one in the esophagus and two in the colon. Due to an enteroatmospheric fistula, the patient was referred to general surgery. Planned laparotomy was not feasible because of extensive intra-abdominal adhesions. Negative pressure wound therapy was attempted for incision dehiscence but discontinued due to obstruction by fistula effluent. On multidisciplinary assessment, multiple abdominal skin tears were identified, with the three largest classified as ISTAP Category 3 in the suprapubic and bilateral medial abdominal regions. Treatment for dermatitis and skin tears began on August 4 and concluded on August 21. Barrier products and ostomy pouches were applied to protect the skin and manage fistula effluent, while tissue-equivalent materials were used for skin tears. Oral intake was withheld for 72 hours to prevent artificial graft contamination. Nutritional management was coordinated by a clinical dietitian working with the surgical team, while appropriate consultations were provided for coexisting medical and psychiatric conditions.

Results / Discussion: By August 21, Category 3 skin tears had fully epithelialized, and perifistula dermatitis had regressed. Closure of other fistulas improved laboratory parameters, increased oral intake, and restored rectal defecation. Selected interventions significantly contributed to wound healing and patient comfort.

Conclusion: Managing enteroatmospheric fistulas is a complex process that necessitates a multidisciplinary approach, appropriate product selection, and consistent monitoring to preserve skin integrity and facilitate safe discharge.

EP519 Assess, don't guess: Managing malignant breast wound in oncological-surgical stalemates

Mohamad Helmi Mohd Rashidi[1]

[1]*Smith & Nephew, Essity, Beier Drawtex Healthcare, Kuala Lumpur, Malaysia*

Aim: Malignant breast wounds from lymphoma with cutaneous metastasis are rare but often complicated by infection, odour, and high exudate. In cases where systemic therapy is delayed and surgery is not viable, effective wound management becomes critical. This case illustrates how a thorough wound assessment paired with a structured multilayer dressing protocol achieved symptom control and enabled further oncological treatment.

Method: A 34-year-old woman with lymphoma presented with an infected, sloughy, painful, and malodorous breast wound. Histopathology confirmed malignancy. Surgical excision was deemed unsuitable because of risk of tumour dissemination, while chemotherapy was delayed due to active local infection.

A comprehensive wound assessment was conducted addressing tissue type, infection status, moisture balance, wound edges, and odour control. Based on the assessment, a multilayer wound management protocol was introduced twice weekly. Tissue management by using Hydrogel for autolytic debridement, infection control by using Dialkylcarbamoyl chloride (DACC) to bind bacteria and Silver nanocrystalline for broad-spectrum antimicrobial action, moisture control by using Hydroconductive and superabsorbent dressings with polyruethane foam for cushioning and protection, added with Activated charcoal for odour reduction

Results / Discussion: After three weeks of treatment, there was visible reduction in slough and exudate, with significant odour control. Pain intensity decreased, and the patient reported improved psychological well-being. The infection was brought under control, enabling initiation of systemic chemotherapy without surgical intervention. Over the following three months, progressive wound healing was achieved, culminating in complete closure.

Conclusion: Thorough wound assessment and tailored multilayer dressing protocols can significantly improve complex wound management in oncology patients, offering advantages over single-dressing approaches.

EP520 Allopathic skin substitute associated with cellulose membrane in arterial lesion

Margrit Wilke[1], Leticia Giaconia[1], Janaina Santos Lima[2]

[1]*Qualy Life Home Care, Sao Paulo, Brazil*, [2]*Qualy Life Residencial, Sao Paulo, Brazil*

Aim: Lower limb lesions are frequent complications in patients with peripheral arterial insufficiency and represent a major risk of amputation due to infection, intense pain, and necrosis progression. Allopathic skin substitutes and cellulose membranes have gained prominence in tissue regeneration and wound healing due to their bioactive and protective properties. To report the clinical evolution of a patient with a right lower limb lesion treated with an allopathic skin substitute associated with a cellulose membrane, emphasizing its effectiveness in tissue repair and pain control

Method: Descriptive case report conducted in a home care setting. Female patient, 68 years old, with heart disease, smoking history, peripheral arterial insufficiency, and a chronic right lower limb lesion showing slow improvement over three months of conventional therapy. On August 30, 2025, a new treatment was initiated with wound bed preparation followed by the application of an allopathic skin substitute based on lactide copolymer and a secondary cellulose membrane dressing. The membrane promoted better adherence, prolonged contact, and moisture maintenance, with dressing changes every 12 days.

Results / Discussion: After 14 days, 80% epithelialization and complete pain remission were observed. On October 28, 2025, full epithelialization and lesion closure were achieved. The photographic record documented each healing stage, demonstrating progressive granulation, reduced inflammation, and excellent integration of the biomaterials, even under unfavorable arterial conditions.

Conclusion: The combination of an allopathic skin substitute with a cellulose membrane proved to be an effective, safe, and innovative therapeutic strategy for patients with peripheral arterial insufficiency, promoting rapid epithelialization, pain reduction, and functional skin restoration in a hard-to-heal wound.

EP521 Tissue recovery in digital necrosis using nanovectorized cream and cellulose membrane: Case report

Leticia Giaconia[1], Margrit Wilke[1], Janaina Santos Lima[1]

[1]*Qualy Life Residencial, Sao Paulo, Brazil*

Aim: Trophic lesions in extremities are frequent complications in patients with peripheral arterial insufficiency, often associated with necrosis and risk of amputation. Advances in topical therapies have enabled effective conservative approaches. The use of bioactive membranes and nanovectorized creams stands out for their regenerative, healing, and anti-inflammatory effects. To report the clinical evolution of a patient with digital necrosis and surgical indication for amputation, treated with a nanovectorized cream and crystalline cellulose membrane, highlighting the effectiveness of topical therapy in tissue preservation.

Method: Male patient, 49 years old, presenting distal necrosis on the right fifth toe and peripheral arterial insufficiency diagnosed by Doppler (monophasic flow). Conservative therapy began on March 20, 2025, with topical application of nanovectorized cream three times a day during the first seven days, reduced to twice daily from the eighth day, associated with a cellulose membrane changed every four days. After complete closure (April 15, 2025), daily hydration was maintained.

Results / Discussion: Over 26 days, progressive tissue regeneration, complete pain remission, and amputation prevention were observed. In the first week, there was a reduction of the inflammatory process and intense pain. From the second week, granulation tissue formation occurred with peripheral epithelialization and total pain regression. By the end, the lesion was fully epithelialized, and the patient was free from surgical risk.

Conclusion: The combined use of nanovectorized cream and crystalline cellulose membrane proved to be effective and safe in the conservative treatment of digital necrosis, promoting healing in ischemic tissue, pain control, and functional preservation, demonstrating the potential of these technologies to prevent amputations.

EP522 Combination of moist burn ointment and macromolecule microporous dressing for repair of third-degree thermal crush injury with infection on the back of fingers: A case report

Xiuqiu Yao[1], Yongfang Wu[1], Shuling Yang[1]

[1]*Affiliated Southwest Hospital of Youjiang Medical University for Nationalities, Guangxi, China*

Aim: To explore the effectiveness of combining moist burn ointment and macromolecule microporous dressing in the treatment of third-degree thermal crush injury with infection on the back of fingers.

Method: A 31-year-old male presented with a non-healing, infected third-degree thermal crush injury on multiple left fingers, featuring full-thickness skin loss and exposed structures. Treatment combined systemic therapy with local wound care. After initial iodophor cleansing and application of Moist Burn Ointment (MBO) gauze, uneven granulation was observed. A macromolecular microporous dressing was then added as an intermediate layer to regulate tissue growth and promote healing, with this combined protocol continued until closure.

Results / Discussion: The wound showed progressive healing: by day 4, robust but uneven granulation was observed, which evened out after applying the macromolecular microporous dressing, accelerating epithelial migration. After 17 days of combined therapy, complete epithelialization was achieved in the index and ring fingers with near-complete healing in the middle finger, prompting discharge. One-year follow-up revealed minimal pliable scarring, normal finger function, and high patient satisfaction.

Conclusion: The combination of moist burn ointment and macromolecular microporous dressing proved to be a highly effective strategy for managing a complex third-degree thermal crush injury with infection. This regimen successfully promoted wound bed preparation, controlled granulation tissue growth, and accelerated epithelialization, leading to complete wound closure without the need for surgical intervention such as skin grafting. The long-term outcome was excellent, with minimal scarring and full functional recovery. This case demonstrates that the combination is a feasible, effective, and promising non-surgical alternative for achieving both functional and aesthetic repair in challenging finger injuries.



Figure 1: Wound on left hand at admission; Figure 2: Wound after four days of autolytic debridement;
Figure 3: Inner layer dressed with polymer microporous dressing; Figure 4: Outer layer dressed with moist burn cream gauze;
Figure 5: Bandaged with cotton pad and bandage; Figure 6: On the 10th day of treatment;
Figure 7: On the 17th day of treatment; Figure 8: Follow-up one year after discharge.|

EP523 Salvage of a heel pressure ulcer aggravated by unprincipled debridement through revascularization and a bioactive cellulose graft

Javad Ghorbani[1], Raman Lotfi[2], Kimia Soltaniha[2]

[1]Non-Communicable Diseases Research Center, Alborz University of Medical Sciences, Karaj, Iran, Head of Zakhm Karaj Wound Clinic, Alborz University of Medical Sciences, Karaj, Iran, Karaj, Iran, *[2]Member of Alborz University of Medical Sciences Research Committee, Member of Zakhm Karaj Wound Clinic, Alborz University of Medical Sciences, Karaj, Iran, Karaj, Iran*

Aim: To demonstrate the critical need for vascular assessment before wound debridement and present a successful multidisciplinary protocol for salvaging a complex heel pressure ulcer worsened by unprincipled debridement. This case highlights how integrating revascularization, NPWT, and a bacterial nanocellulose graft achieved complete closure despite severe comorbidities and iatrogenic complications.

Method: A female patient in her 60s with multiple comorbidities presented with a deteriorating Grade4 heel pressure ulcer following unprincipled debridement. Management followed a structured protocol: 1) Immediate multidisciplinary referral with debridement moratorium until revascularization; 2) Endovascular revascularization for critical limb ischemia; 3) Surgical debridement after perfusion restoration; 4) NPWT followed by bacterial nanocellulose grafting for epithelialization; 5) Continuous offloading and glycemic control throughout treatment.

Results / Discussion: The implemented multidisciplinary protocol resulted in successful limb salvage and complete wound healing. Following revascularization, negative pressure wound therapy (NPWT) stimulated robust granulation tissue formation, achieving approximately 30% wound coverage. Subsequent transition to a bioactive bacterial nanocellulose (BNC) graft prompted rapid, uninterrupted epithelialization, effectively overcoming the previous healing plateau. Complete wound closure was confirmed 30 days post-BNC application and remained stable throughout a 5-week post-closure monitoring period. The patient reported significant pain resolution and expressed high treatment satisfaction, reflecting markedly improved quality of life.

Conclusion: This case underscores three vital principles for complex heel ulcer management: First, the heel's poor vascularity mandates vascular assessment as an absolute prerequisite to debridement to prevent iatrogenic harm. Second, a strict revascularization → debridement → NPWT → bioactive grafting sequence is crucial for navigating complications. Finally, bacterial nanocellulose grafts are a potent, non-surgical solution for overcoming healing plateaus and achieving closure.This physiology-driven protocol can salvage even the most challenging cases.

EP524 Preserving the blister roof: A novel protocol of protective drainage and bacterial nanocellulose dressing for large serous burn bullae

Kimia Soltaniha[1], Raman Lotfi[1], Javad Ghorbani[2], Shabnam Faraji[3]

[1]Member of Alborz University of Medical Sciences Research Committee, Member of Zakhm Karaj Wound Clinic, Alborz University of Medical Sciences, Karaj, Iran, Karaj, Iran, *[2]Non-Communicable Diseases Research Center, Alborz University of Medical Sciences, Karaj, Iran, Head of Zakhm Karaj Wound Clinic, Alborz University of Medical Sciences, Karaj, Iran, Karaj, Iran*, *[3]Member of Zakhm Karaj Wound Clinic, Alborz University of Medical Sciences, Karaj, Iran, Karaj, Iran*

Aim: Conventional management of large serous burn blisters often involves deroofing, which removes the natural biological barrier and can delay healing. This study aims to evaluate the efficacy of a novel, integrated protocol that combines controlled micro-drainage with the application of a bacterial nanocellulose (BNC) dressing to preserve the blister roof and promote optimal healing in complex cases, including patients with comorbidities and wounds in high-risk anatomical locations.

Method: Three patients with large serous burn blisters (≥10 cm^2) underwent a standardized protocol: 1) Antisepsis with 0.1% hypochlorous acid; 2) Controlled micro-drainage with blister roof preservation; 3) Application of bacterial nanocellulose (BNC) dressing with 7-day wear time. Outcomes measured included healing time, pain scores (VAS), and infection rates.

Results / Discussion: The protocol achieved consistent success across complex cases (diabetic patient, multiple confluent blisters, high-mobility joint). All blister roofs remained viable with complete re-epithelialization in mean 18.3 days. Pain scores (VAS) decreased dramatically from 7.7 to 1.3 by day 7. No infections occurred during treatment.

Conclusion: This study demonstrates that the integrated protocol of protective blister drainage and bacterial nanocellulose dressing is a highly effective and reproducible strategy for managing large serous burn bullae. By preserving the blister roof as a natural biological dressing and reinforcing it with advanced technology, this approach facilitates rapid, uninterrupted re-epithelialization, eliminates infection, and significantly enhances patient comfort. The protocol's consistent success across complex cases, including comorbidities and high-risk anatomical sites, challenges the conventional practice of routine deroofing and offers a potential new standard of care for optimal burn blister management.

EP525 The human factor in limb salvage: How psychosocial barriers override gold-standard care in charcoot foot ulcers

Raman Lotfi[1], Javad Ghorbani[2], Kimia Soltaniha[1], Alireza Soleimani[3], Shabnam Faraji[4]

[1]Member of Alborz University of Medical Sciences Research Committee, Member of Zakhm Karaj Wound Clinic, Alborz University of Medical Sciences, Karaj, Iran, Karaj, Iran, *[2]Non-Communicable Diseases Research Center, Alborz University of Medical Sciences, Karaj, Iran, Head of Zakhm Karaj Wound Clinic, Alborz University of Medical Sciences, Karaj, Iran, Karaj, Iran*, *[3]Infectious disease specialist.Assisstant professor of medical sciences.Alborz University of Medical Sciences. Karaj.Iran, Karaj, Iran*, *[4]Member of Zakhm Karaj Wound Clinic, Alborz University of Medical Sciences, Karaj, Iran, Karaj, Iran*

Aim: While total contact casting (TCC) is the gold-standard for offloading neuropathic foot ulcers, its real-world effectiveness is ultimately determined by patient acceptance. This study aimed to investigate how patient-specific psychosocial barriers to TCC influence healing outcomes in comparable cases of non-surgical Charcot foot ulcers, where biological and wound care parameters were near-identical.

Method: A comparative case series analyzed four female patients with homologous midfoot Charcot neuropathic ulcers, matched for size, vascular status (ABI >0.8), and glycemic control. All received identical standardized wound care. The critical divergence occurred through patient self-selection: two accepted total contact casting (TCC) while two refused due to psychosocial barriers (economic fears and disability denial), using removable walkers instead. Primary outcome was percentage wound area reduction at 4 weeks; secondary outcomes included complete healing time and limb salvage at 12-week follow-up.

Results / Discussion: Dramatically divergent outcomes were observed. Total contact casting (TCC) acceptance led to rapid healing (81.5% mean area reduction at 4 weeks; complete healing by 12 weeks). In stark contrast, removable device users showed minimal improvement (7.5% mean reduction), with one case culminating in below-knee amputation. Unaddressed psychosocial barriers, not biological factors, directly prevented effective offloading and caused therapeutic failure despite optimal standard care.

Conclusion: This study reveals that patient-perceived psychosocial barriers can be the ultimate determinant of therapeutic success, potentially overriding even gold-standard biological interventions. Our findings necessitate a paradigm shift in Charcot management toward integrated biopsychosocial models where systematic assessment and addressing of treatment barriers becomes as crucial as the technical aspects of wound care itself.

EP526 Marjolin's ulcer in a traumatic wound scar: Treatment with negative pressure therapy and partial-thickness skin graft

Simas Gindriunas[1], Emilija Dedelyte[1], Rusnė Vaitkevičiūtė[1], Tomas Sparnauskas[1], Ernest Zacharevskij[1], Loreta Pilipaityte[1]

[1]Hospital of Lithuanian University of Health Sciences Kaunas clinics, Kaunas, Lithuania

Aim/Introduction: Marjolin's ulcer is a malignant degeneration of chronically injured skin, usually arising in long-standing scars or non-healing wounds. Diagnosis relies on history, clinical and laboratory evaluation. Most lesions are squamous cell carcinomas. Typically affecting lower limbs and often emerge decades after injury.

Method/Case presentation: A 64-year-old man developed a chronic wound on his left ankle following a soft-tissue injury treated with a free flap 30 years earlier. Recurrent ulceration and poor healing progressed in an 8 × 10 cm ulcer. Clinical suspicion for squamous cell carcinoma (SCC) led to a planned wide excision with sentinel lymph node excision. Postoperative negative-pressure wound therapy (VAC) was applied while awaiting histological confirmation. The patient developed a purulent infection caused by P. aeruginosa requiring antibiotic treatment and daily dressings. VAC therapy was continued once the infection subsided. Histology confirmed a radically excised, well-differentiated invasive SCC. VAC therapy promoted granulation tissue formation over two weeks, after which a meshed split-thickness skin graft was applied to cover the defect.

Results / Discussion: Marjolin's ulcer is an aggressive malignant transformation of chronically scarred or non-healing skin that is easily overlooked, leading to delayed and sometimes inadequate treatment. In our patient, decades of impaired perfusion, chronic irritation, and recurrent ulceration in a post-traumatic scar eventually led to malignant transformation, highlighting the slow progression of Marjolin's ulcer and the importance of biopsying any ulcer that fails to heal within 3 months. **Conclusion:** Marjolin's ulcer is a rare but aggressive malignancy. Early recognition and biopsy of ulcers persisting beyond 3 months are crucial. In our case, wide excision with VAC followed by split-thickness skin grafting led to successful healing and avoided amputation.

EP528 Bridging the gap: Integrated inpatient and outpatient management of diabetic foot ulcers

Migdrey Falcon Martinez[1], Boris Garcia Freire[1], Arianny Hechavarria Gonzalez[1]

[1]Hamad, Dukhan, Qatar

Aim: To describe the clinical, microbiological, and demographic characteristics of patients with diabetic foot ulcers managed through an integrated inpatient and outpatient care approach in this case series.

To assess the impact of continuity of care and multidisciplinary collaboration—including the role of nursing—on healing outcomes and complication rates in patients with diabetic foot ulcers within the context of this case series.

Method: The study employed a descriptive case series approach involving five patients with diagnosis of Diabetic Foot Ulcer treated between January - August 2025. Patients were selected based on hospitalization due to complications and subsequent outpatient follow-up. Data were collected through structured patient interviews, focused direct observation and extraction of clinical information from the institutional electronic medical record.

Results / Discussion: Throughout the case series, patients exhibited marked progress in wound healing, enhanced glycaemic control, and a notable reduction in the incidence of major amputations. The adoption of inter-hospital referrals, standardised protocols, and coordinated follow-up significantly minimised care fragmentation and fostered greater adherence to treatment. Nursing leadership and intervention were instrumental in facilitating smooth transitions across different levels of care, thereby strengthening continuity and patient safety in the integrated management of diabetic foot ulcers.

Conclusion: Integrated inpatient and outpatient management improves outcomes, reduces hospital readmission, and enhances patient safety. Bridging the gap between care levels through structured coordination and nursing leadership is essential for successful management.

EP529 Sucessful diagnosis in nail squamous cell carcinoma

Andika Winata[1]

[1]*Eka Hospital, Tangerang, Indonesia*

Aim: Squamous cell carcinoma of the nail unit (SCCNU) is a rare yet often underrecognized malignancy that can lead to delayed diagnosis and significant functional morbidity. Delayed diagnosis is common due to variable clinical presentation.

Method: A 45-year-old male presented with a non-healing subungual growth in the nail bed of the right second toe for a year. The lesion was first medicated with iodine and antibiotic by the patient herself without any relief. Twelve months later, a biopsy confirmed the lesion was Squamous cell carcinoma.

Results / Discussion: Squamous cell carcinoma of the nail bed is a rare disease, or at least it has been poorly reported. Potential risk factors of SCC include trauma, chronic paronychia, chronic actinic damage, X-ray irradiation, burns, and chemical or virus exposure among others. It has unspecific symptoms ranging from chronic intermittent pain, nail deformity, subungual growth, ulcers, and complicated infections, frequently lead to misdiagnoses, like chronic paronychia, onychomycosis, pyogenic granuloma, subungual wart, subungual glomus tumor, and enchondroma.

Conclusions: Successful diagnosis for this case highlight the need for additional attention to long-standing non-healing lesions of the nail bed and the necessity for discreet evaluation but a failure in management because of reluctant to have a surgical interventions from the patient.

EP530 Diverting colostomy and staged wound therapy for Fournier's gangrene in a frail patient with a pressure ulcer

Eren Acikgoz[1]

[1]*Zonguldak Karadeniz Ereğli State Hospital, Zonguldak, Türkiye*

Aim: To describe the surgical and wound management strategy and healing course of a frail nursing home resident with Fournier's gangrene related to a pressure injury.

Method: A 68-year-old male with hypertension, type 2 diabetes, epilepsy and prior stroke with residual motor and sensory deficits presented with sepsis, perineal pain and a sacral pressure ulcer. Examination and imaging revealed Fournier's gangrene involving the perianal region. Broad-spectrum antibiotics were initiated and laparoscopic diverting colostomy with extensive debridement was performed. Wound and blood cultures were obtained. Serial debridements and negative pressure wound therapy (NPWT) were applied, followed by daily dressings with a Enzimalginogel once the defect had filled with healthy granulation tissue.

Results / Discussion: Admission laboratory tests showed haemoglobin 11 g/dL, white blood cell count 10.9×10^9/L, platelets 323×10^9/L and C-reactive protein (CRP) 223 mg/L. Wound cultures remained negative, while blood cultures grew Klebsiella pneumoniae, treated with imipenem and vancomycin in consultation with infectious diseases. Over 70 days of repeated debridement and NPWT the extensive perineal defect progressively granulated, with no residual pockets or cavities. Laboratory parameters normalised (haemoglobin 14.5 g/dL, white blood cell count 7.0×10^9/L, platelets 280×10^9/L, CRP 7 mg/L). After a further 17 days of outpatient hydroactive gel dressings, complete cutaneous closure was achieved and the patient was discharged for follow-up.

Conclusion: In severe Fournier's gangrene with perianal involvement in frail, immobile patients, early faecal diversion combined with aggressive debridement, prolonged NPWT and structured transition to topical therapy can achieve complete wound closure without complex reconstruction. This multidisciplinary approach may facilitate sphincter preservation and later stoma reversal, improving functional recovery and quality of life.

EP531 Arteriosclerotic (ischemic) leg ulcer: Non-conventional management

Andres Salazar[1], Jose Dario Patino[1]

[1]*Megaheridas Megacentro, Pereira, Colombia*

Aim: To describe the clinical outcome of a non-conventional management strategy using an arterial circulator device followed by neuromuscular electrical stimulation (NMES) in an arteriosclerotic (ischemic) ulcer refractory to conservative care.

Method: A 76-year-old woman with type II diabetes mellitus, mild diabetic neuropathy, cervical dyskinesia, and normal renal function developed a highly painful, dark, blood-tinged anterior mid-leg lesion after minor trauma. The ankle–brachial index (ABI) on the affected side was 1.33. Three weeks of conservative management—including autolytic debridement with silver gel and gentle mechanical debridement secured with a non-woven breathable polyester fabric—failed, with progression to dermal dryness and loss of vascular response. A two-step physiological stimulation protocol was then implemented: first, application of an arterial circulator device (a non-pharmacologic method reported to support arterial inflow and reduce ischemic pain), followed by NMES of the calf muscle pump (1 hour ON, 2 hours OFF; four daily sessions) once the wound stabilized. Treatment duration was July 21 to October 15, 2025, culminating in complete epithelialization.

Results / Discussion: Arterial circulator therapy produced rapid pain reduction within the first treatment week. By week 4, pain decreased to 2/10 on the Visual Analogue Scale (VAS). After NMES initiation, granulation tissue steadily increased, and perfusion-related symptoms improved. Full wound closure was achieved by week 12, and no adverse effects occurred.

Conclusion: Sequential physiological stimulation using an arterial circulator device followed by NMES improved pain, tissue viability, and overall healing trajectory in an arteriosclerotic ulcer unresponsive to conservative care. Controlled studies are warranted to further evaluate these modalities in arteriosclerotic ulcer management.

EP532 Advanced and adjunct approaches in calciphylaxis wounds: A case report

Suseela Devi[1], Sue En Lee[1], Sivagame Maniya[1]

[1]*Sengkang General Hospital, Singapore, Singapore*

Aim: Calciphylaxis is a life-threatening atypical ulceration primarily affecting patients with advanced renal disease. It is characterised by microvascular calcification, tissue ischemia and rapidly progressive skin necrosis, leading to severe pain, recurrent infection and high mortality. These painful chronic wounds pose challenges and require early diagnosis and multidisciplinary interventions. This case report shares the integration of advanced and adjunct wound care strategies to manage a complex calciphylaxis wound. with peripheral arterial disease.

Method: The patient with multiple comorbidities on haemodialysis was admitted with intraparenchymal hematoma. She presented with a chronic eschar wound over the right posterior calf with increasing pain.

Despite revascularisation, the wound did not show improvement. Although the initial punch biopsy was negative, a subsequent deep tissue biopsy during surgical debridement confirmed calciphylaxis. sodium thiosulfate was initiated. The debrided wound was managed with an antiseptic cleanser, antimicrobial hydrogel, and hydro-alginate dressings to promote autolytic debridement through conservative, gentle wound debridement. After 4 weeks of autolytic dressings, extracellular matrix (ECM) was applied to enhance granulation and tissue regeneration, coupled by a lipido-colloid dressing. Wound progression was closely monitored via digital imaging. Systemic optimisation focused on mineral metabolism control and multimodal analgesia. Outcomes were evaluated based on wound measurements, granulation development, and patient-reported pain score.

Results: The patient achieved wound healing after 9 months, with improved pain control and enhanced functional ability.

Conclusion: An interdisciplinary team comprising vascular surgery, wound care nursing, nephrology, dermatologist, dietetics, and pain services, combined with advanced wound technologies and adjunct therapies, can enhance healing and patient experience in calciphylaxis wounds. Management of calciphylaxis wounds demands an interdisciplinary team approach and may benefit from advanced wound technologies.

EP533 Multimodal conservative management of enterocutaneous fistula using enzyme alginogel

Meltem Ada[1], Mehmet Yildirim[2], Ahmet Mucteba Ozturk[1]

[1]Republic of Türkiye, Ministry of Health, Bozyaka Training and Research Hospital, Wound and Stoma Clinic, Izmir, Türkiye, *[2]Republic of Türkiye, Ministry of Health, İzmir City Hospital Department of General Surgery, University of Health Sciences, Faculty of Medicine, Izmir, Türkiye*

Aim: Enterocutaneous fistulas (EF) remain a major challenge in wound management. Treatment varies according to anatomical site and drainage type. This report presents the clinical outcomes of a multimodal conservative approach using an enzyme alginogel (a hydrated alginate containing antibacterial enzymes) combined with a hydrocolloid and adapter system in the management of a complex EF-related wound.

Method: A 33-year-old male underwent surgery for colon perforation following a traffic accident. On postoperative day 10, he presented with sepsis; CT revealed a 20x13×7 cm retroperitoneal abscess. Emergency drainage (1000 cc) and jejunojejunostomy were performed. On postoperative day 5, a low-output EF (70 cc/day) developed at the former ostomy site, resulting in a 6×4×3 cm infected wound.



A catheter was inserted into the fistula opening and connected to a custom adapter system. Periwound skin was protected with stoma paste; enzyme alginogel was applied to the wound and covered with a hydrocolloid dressing. The procedure was repeated every three days.

Results: This multimodal therapy provided rapid infection control and created an optimal wound-healing environment. By week two, wound size had reduced by 40% while maintaining skin integrity. The patient was discharged on postoperative day 25, and **complete closure** occurred by day 40.



Conclusion: The multimodal use of enzyme alginogel with hydrocolloid and adapter systems demonstrated a promising, innovative, and safe conservative approach for complex EF management. This multimodal strategy supported rapid infection control, skin preservation, and early fistula closure, emphasizing its clinical potential.

Product reference: Flaminal® Forte (Flen Health, Belgium).

EP534 Addition of a novel emollient to the wound care formulary – a process case study

Kelly Phillips[1], Michaela Delahunty[2]

[1]Doncaster and Bassetlaw Teaching Hospitals NHS Foundation Trust, Doncaster, United Kingdom, *[2]Tissue Viability and Lymphoedema Service, Doncaster, Rotherham and South Humber Trust (TVALS RDaSH), Doncaster, United Kingdom*

Aim: To support the application of evidence-based practice in skin care provision by evidencing the need for a new formulary addition.

Method: As an evidence-based service the two specialist wound care services within the Doncaster Wound Care Alliance (SIT and TVALS) regularly review pathways and support guidance for product removal, continuity and addition to the wound care formulary. It was identified that outside of Dermatology guidance there was a gap for standard emollient application, with lower limbs and lymphoedema. It was acknowledged that HOFA based emollients have been introduced into the UK market. We wanted to evaluate whether a new approach to emollient therapy could be effective for our patients. We conducted an evaluation including 36 patients with a lower limb wound or lymphoedema. Following this we submitted a formulary change.

Results / Discussion: 94% of patients met their treatment objective of hydrating the skin, improving appearance, removing plaques, or easier application of compression. It was noted that patient compliance and easier fit with lifestyle were reported and overall, less product was used meaning that this was easier for application and coverage – providing a cost-neutral option to the current emollients. Using this evidence and the process outlined in the Best Practice Statement for Developing a Wound Care Formulary (Wounds UK 2023) we submitted a formulary update to the medicine management group of the ICB which provided a rational/summary of our evidence and explained the reasoning for adding HOFA based emollient to the wound care formulary.

Conclusion: This evidence-based approach to product evaluation and formulary listing ensured all stakeholders were part of a collaborative formulary listing approach. Monitoring trials continue with 72 evaluations completed.

EP535 Iatrogenic spark burn injury to the chest from a trancsutaneous pacing patch

Daiwon Jun[1], Jong Yun Choi[2]

[1]Bucheon St. Mary's Hospital, College of Medicine, The Catholic University of Korea, Bucheon, Korea, Rep. of South, *[2]The Catholic University of Korea, Seoul St. Mary's Hospital, Seoul, Korea, Rep. of South*

Aim: Electrical burns from paddle-type defibrillators or pacing devices are typically deeper than scald or contact burns. A transcutaneous cardiac pacing patch delivers shocks during abnormal rhythms. This report describes a chest burn caused when electrical energy from such a patch produced a spark due to foreign material on the contact surface.

Method: A 57-year-old unconscious man with recurrent ventricular tachycardia and fibrillation was admitted to the cardiac intensive care unit. A transcutaneous cardiac patch was applied for monitoring and intervention (Figure 1). During recurrent arrhythmic episodes, he received 150 J shocks, totaling 41 discharges over 2 days. After recovery of consciousness, multiple bullae and an eschar developed at the patch site.

Results / Discussion: The burn measured about 8×12 cm with a ring-like erythema matching the patch area (Figure 2). Bullae formed along the margins, and dermal injury was evident. Daily wound care with topical growth factor ointment and a non-adherent foam dressing was administered. Cardiac rhythm stabilized without further shock therapy. He was discharged after 2 weeks, and complete epithelialization was confirmed by 3 weeks (Figure 3).

Conclusion: When using transcutaneous pacing patches, ensure a clean, flat contact surface free of foreign matter. Proper placement and adequate conductive lubricant are essential. Continuous skin inspection around the patch is recommended to detect early burn signs and prevent severe injury.

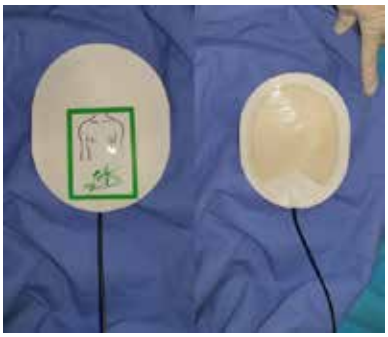

Figure 1. Transcutaneous gel pad and pacing device.



Figure 2. Initial burn appearance after 41 electric shocks.



Figure 3. Healed wound after 3 weeks.

EP536 The psychodermatological paradigm: Integrating transparent nanocellulose facial mask and photobiomodulation for holistic facial burn recovery

Kimia Soltaniha[1], Javad Ghorbani[2], Raman Lotfi[1], Mehrnaz Boroumand[1]

[1]Member of Alborz University of Medical Sciences Research Committee, Karaj, Iran, Member of Zakhm Karaj Wound Clinic, Alborz University of Medical Sciences, Karaj, Iran, Karaj, Iran, *[2]Non-Communicable Diseases Research Center, Alborz University of Medical Sciences, Karaj, Iran, Head of Zakhm Karaj Wound Clinic, Alborz University of Medical Sciences, Karaj, Iran, Karaj, Iran*

Aim: Facial burns cause severe psychological distress, exacerbated by conventional opaque dressings that promote social stigma and require painful changes. While biological healing is essential, the profound psychological impact demands equal attention. This study evaluates an integrated protocol combining advanced transparent dressings with light therapy to simultaneously address both physical and psychological recovery.

Method: A prospective analysis of five patients (3 female, 2 male; age range 32-58 years) with partial-thickness facial burns (4-8% TBSA) was conducted. The intervention protocol included: 1) Application of a transparent bacterial nanocellulose (BNC) facial conformer dressing changed every 5 days; 2) Daily photobiomodulation (PBM) therapy (630nm red light, 5J/cm^2); 3) Standardized psychological evaluation using the Derriford Appearance Scale (DAS-24) and Pain Visual Analog Scale (VAS) at baseline, day 7, and day 21. Primary outcomes measured were time to complete re-epithelialization and psychological metric improvements.

Results / Discussion: The protocol demonstrated significant dual efficacy, with all patients achieving complete re-epithelialization within 10-16 days (mean 13.2 days). The transparent BNC membrane enabled uninterrupted wound monitoring while maintaining dressing integrity. Psychometric evaluation revealed substantial improvement: DAS-24 scores decreased from 48.6 to 22.4, alongside pain VAS reduction from 7.8 to 1.4. Patients consistently reported the psychological benefit of preserved facial identity and maintained social interaction throughout recovery.

Conclusion: This integrated psychodermatological approach represents a transformative advancement in facial burn management. By synergistically combining transparent wound coverage with photobiomodulation and psychological assessment, we demonstrate that simultaneous optimization of biological healing and psychological well-being is achievable. The protocol successfully addresses the critical gap in conventional burn care where psychological trauma remains undertreated, establishing a new standard for comprehensive facial rehabilitation that merits broader clinical adoption.

EP537 Successful reconstruction of post-sternotomy fungal osteochondritis with free tissue transfer: A rare case report

Seong Oh Park[1]

[1]*Seoul National University Hospital, Seoul, Korea, Rep. of South*

Aim: To present the diagnostic challenges of persistent, culture-negative post-sternotomy wounds and demonstrate the successful management of invasive Aspergillus fumigatus osteochondritis requiring complex microvascular reconstruction.

Method: A 66-year-old male with multiple comorbidities (diabetes mellitus) developed a persistent sternal wound 3 months after OPCAB (LITA conduit). Despite nine serial debridements by the cardiac surgery team and empirical treatment, the wound was recalcitrant. Serial bacterial and fungal cultures were repeatedly negative for several months. Furthermore, advanced imaging (contrast CT and MRI) provided no definitive evidence of deep sternal infection. Deep tissue biopsy showed only chronic chondritis, further delaying definitive diagnosis.

Results / Discussion: The patient underwent six subsequent radical debridements (total 15 procedures). Targeted fungal culture from the late-stage debridement tissue successfully isolated Aspergillus fumigatus; subsequent histopathologic review confirmed invasive fungal osteochondritis involving the costal cartilage. The right internal thoracic artery was transected during prior surgery, precluding a pedicled rectus abdominis flap. Definitive coverage was achieved using a free latissimus dorsi musculocutaneous (LDmc) flap, anastomosed to the right internal thoracic artery and vein, providing robust coverage and dead space obliteration. The patient received a 6-month course of systemic antifungal therapy (voriconazole).

Conclusion: Fungal osteochondritis requires strong suspicion in atypical, culture/imaging-negative, non-healing sternal wounds, necessitating repeated tissue sampling for definitive diagnosis. Free tissue transfer is a vital reconstructive option when local options are compromised by prior vessel injury or complex anatomy. At 12-month follow-up, no recurrence was observed, confirming the efficacy of combined aggressive surgical and medical management.

EP538 Bilateral foot burns in a child: Successful conservative management in a low-resource rural hospital

Orson Juan Hernandez[1], Frida Rosas Lezama[1]

[1]*Instituto Mexicano del Seguro Social, Tuxtla Gutierrez Chiapas, Mexico*

Aim: This case aims to describe the conservative management of deep partial thickness burns affecting both feet in a 5-year-old girl treated in a rural hospital with limited resources. The objective is to demonstrate how structured wound care, serial debridement, and appropriate topical therapy led to complete epithelization without grafting.

Method: The patient sustained bilateral thermal burns after stepping on burning logs, resulting in deep partial thickness injuries involving dorsum, ankles, and toes of both feet. She was admitted to a rural facility lacking specialized burn dressings and advanced equipment. Management consisted of scheduled mechanical debridement and programmed wound washouts every three days. Nitrofural ointment was applied initially to maintain moisture and provide antimicrobial coverage. As deeper areas demarcated, silver nitrated parches were placed to control bioburden and support granulation. Analgesia, elevation, and daily clinical assessment were maintained. No systemic antibiotics were required. Due to the extent of the wounds and the need for close monitoring, hospitalization continued for two months.

Results / Discussion: Progressive improvement was documented in both feet. Early and repeated debridement effectively removed devitalized tissue and prevented infection. Washouts optimized the wound bed, while silver therapy helped control local bacteria. Despite limited resources, the wound care protocol promoted healthy granulation and progressive epithelization. The child regained full weight bearing without gait abnormalities, contracture, or functional limitations.

Conclusion: This case demonstrates that pediatric bilateral deep partial thickness foot burns can be successfully managed conservatively in low resource rural setting. Consistent debridement, appropriate topical therapy, and close clinical follow up allowed complete epithelization within two months.

EP539 8-year evolution of a devastating hemifacial electrical burn wound: Reconstruction of a lower eyelid ectropion and peri-oral contracture

Chuan Han Ang[1], Khong Yik Chew[1]

[1]Singapore General Hospital, Singapore, Singapore

Aim: Modern multi-disciplinary care has led to increased survival after devastating burn injuries which leads to more complex reconstructive challenges. In the pediatric population, resultant abnormal balance in the facial musculature leads to contraction-induced skeletal and dental growth deformities. We describe the reconstruction of a severe hemiface electrical burn with a focus on lower eyelid ectropion and oral commissure contracture.

Method: A 40-year-old Chinese gentleman suffered a left cheek electrical burn 30 years ago. He previously underwent a failed thoracodorsal-artery-perforator-flap in another hospital. He presents with severe left hemiface scarring from the orbits down to the neck. This was complicated by left eyelid ectropion, retraction of left oral commissure, teeth displacement and extensive involvement of alveolar bone, reduced jaw opening and loss of left pinna.

Results: To avoid extensive resection and reconstructive for the patient, non-conventional orthodontics was attempted pre-operatively for the patient, before he underwent an anterolateral thigh free flap reconstruction of the left cheek scar with tensor fascia lata to shape the new oral commissure. Subsequently, he underwent left facial flap debulking, left ectropion repair with lateral tarsal strip and lateral canthoplasty. Lastly, he underwent further facial flap debulking, commissuroplasty, and multiple z-plasties. After 8 years follow-up, he has no more ectropion, excellent occlusion without trismus, and satisfactory aesthetic outcomes.

Conclusion: Surgeons need to design operations that balance both dynamic and aesthetic concerns, in order to achieve long-lasting ideal outcomes in facial burn reconstruction. Other than reconstructing the soft tissue deficit in the cheek, a tarsal strip and canthoplasty will provide additional support for the eyelid. For the commissure, a fascial sling and commissuroplasty will facilitate adequate mouth closure with complementary orthodontic treatment.

EP540 Role of multi-dimensional care of necrotizing fasciitis in a diabetic leg ulcer patient with high risk of amputation: A case report

Dr. Hadi Zomorrodian[1], Mahdi Akbarzadeh Amirdehi[2], M. Raouf[1 3 4 5]

[1]Aktischicht Wound Care Solutions, Frankfurt am Main, Germany, *[2]Sadra wound, ostomy and osteomyelitis specialized center, Tehran, Iran*, *[3]Aktischicht-Nano Fanavaran Narin Teb Co., Tehran, Iran*, *[4]Nanotechnology Research Center, Faculty of Pharmacy, Tehran University of Medical Sciences, Tehran, Iran*, *[5]Physical Chemistry I, Department of Chemistry and Biology & Research Center of Micro and Nanochemistry and (Bio)Technology (Cμ), University of Siegen, Siegen, Germany*

Aim: Necrotizing fasciitis is a progressive soft-tissue infection characterized by skin and underlying tissue necrosis. It is most commonly caused by *Group A Streptococcus* and occurs frequently in diabetic patients due to impaired circulation and weakened immune response. This study aims to evaluate the role of multi-dimensional care of necrotizing fasciitis in a diabetic leg ulcer patient.

Method: A 60-year-old female patient with a medical history of type 2 diabetes mellitus presented with a left diabetic leg ulcer classified Wagner class 5. Wound culture revealed infection with pseudomonas aeruginosa. She was admitted to the hospital with a diagnosis of necrotizing fasciitis. Initial surgical debridement and irrigation were performed, and an above-knee amputation was considered due to the severity of the condition. The patient was

subsequently referred to our wound care centre, where wound management continued in accordance with the TIME framework (Tissue management, Infection/Inflammation control, Moisture balance, and Edge advancement). Adjunctive biophysical therapies and negative pressure wound therapy, with monitoring of exudate quantity and quality, were used to promote healing. The wound was then managed with antimicrobial dressings, including bio-synthetic and biologic options.

Results / Discussion: During the treatment sessions, Infection, exudate, and odour were effectively controlled, and slough tissue progressively decreased as granulation tissue increased. Wound closure was achieved after 20 treatment sessions without the need for amputation.

Conclusion: This case demonstrates the value of multi-dimensional care for necrotizing fasciitis in diabetic leg ulcers by combining surgical intervention with advanced wound care techniques, thereby preventing major amputation and improving patient outcomes.

EP541 Holistic approach to a complex traumatic wound in the lower limb from primary care

Pilar Palomares Diaz[1], Maria Teresa Pingarron Montes[2], Sara Costa Miralles[3], Francisco Soriano Mor[1]

[1]Departamento de Salud de Gandia, Gandia, Spain, *[2]Autonomo, Gardamar de la Safor, Spain*, *[3]Departamento de Salud de Dénia, Pedreguer, Spain*

Aim: To present a clinical case of a traumatic lower limb injury and describe its management using the DOMINATE acronym, a structured tool that evaluates 12 key parameters to support clinical decision-making in complex wound care.

Method: A patient with a traumatic lower limb wound was assessed comprehensively using the 12 components of the DOMINATE framework: debridement, offloading, exudate management, malignancy screening, medication review, mental health considerations, infection control, inflammation, nutrition, arterial insufficiency, advanced wound care techniques, and edema management. Based on the findings for each parameter, individualized nursing interventions were implemented, including appropriate debridement methods, selection of advanced dressings, compression therapy when indicated, and ongoing evaluation of systemic factors such as nutrition and psychological well-being.

Results / Discussion: The structured approach enabled the identification of multiple contributing factors delaying wound healing. Targeted interventions—such as effective debridement, optimized exudate control, improved nutritional support, infection and inflammation management, arterial assessment, and the application of specialized dressings—resulted in progressive wound improvement. Edema reduction through compression therapy and consistent reassessment further contributed to tissue recovery. Ultimately, the wound achieved complete healing, leading to an overall improvement in the patient's functional capacity and quality of life.

Conclusion: Applying the DOMINATE acronym provided a clear and comprehensive framework for evaluating and managing a complex traumatic wound. Its holistic structure facilitated accurate prioritization of care needs and guided the integration of essential elements such as pain control, nutritional optimization, mental health considerations, and advanced wound care techniques. This case demonstrates that the DOMINATE approach enhances clinical decision-making, supports individualized nursing care, and contributes to improved healing outcomes in patients with complex wounds.

EP542 Use of a gel composed of andiroba oil, neem, tea tree, fermented glycolic extract of papaya and hyaluronic acid in the treatment of pressure ulcers

Andréa Dultra[1], Rosenildes Almeida[1]

[1]Multicentro Liberdade, Salvador, Brazil

Aim: To report the effectiveness of treatment with a gel composed of Andiroba oil, Neem, Melaleuca, fermented glycolic extract of papaya and Hyaluronic Acid as an antiseptic and debriding agent in the treatment of pressure ulcers.

Method: This is an experience report. The case was documented through photography. The study was conducted during home visits from July 24, 2024 to September 10, 2024. Ethical aspects of research involving human subjects were respected - Resolutions No. 466/2012 and 510/2016 of the National Health Council.

Results / Discussion: Patient O.F.R., male, 61 years old, hypertensive, diabetic, with a pressure ulcer on the left buttock. The patient had used other technologies for three months without success. Irrigation with 0.9% saline solution was performed, and a gel composed of Andiroba oil, Neem, Melaleuca, fermented glycolic extract of papaya, and Hyaluronic Acid was applied, with changes every 48 hours. Figure A: lesion with coagulation necrosis (07/24/24), Figure B: presence of liquefaction necrosis and granulation points (07/28/24), Figure C: wound with granulation tissue (08/05/24), Figure D: edge contraction and granulated tissue (08/20/24), Figure E: remodeled tissue (09/10/24).

Conclusion: The effectiveness of pressure injury treatment using a gel composed of Andiroba oil, Neem, Melaleuca, fermented glycolic extract of papaya and Hyaluronic Acid in autolytic debridement, antisepsis and tissue remodeling can be observed.

EP543 Accelerated healing of infected chronic diabetic foot wounds with amniotic membrane dressing: A case study

Ali Alibrahim[1]

[1]Department of Wound Care, Ministry of Health, Jizan Health Cluster, Jizan, Saudi Arabia

Aim: To evaluate the impact of structured family involvement on the healing progress of a stage 4 sacral pressure ulcer after hospital discharge, and to examine how targeted caregiver education contributed to continuity of home-based care.

Method: A case study approach was used to observe an adult patient discharged with a slough-covered stage 4 sacral pressure ulcer. Before discharge, the family received structured education on pressure-relief techniques, daily wound observation, and the purpose of modern dressing principles. Caregivers performed routine home care while maintaining regular communication with the clinical team. Weekly assessments documented wound size, tissue characteristics, comfort levels, and caregiver adherence to the care plan.

Results / Discussion: Over a three-month follow-up period, the wound demonstrated steady improvement, transitioning from sloughy tissue to full granulation and complete closure. No complications were recorded, and the patient reported increased comfort and stability. The family demonstrated consistent adherence to positioning routines and monitoring practices, contributing to sustained wound progress. The findings support existing evidence that well-prepared family caregivers can enhance continuity of care and reduce the risk of delays in healing when managing complex wounds at home.

Conclusion: Structured caregiver education and active family engagement played a key role in the successful healing of a stage 4 sacral pressure ulcer following discharge. The case underscores the importance of family-centered approaches in promoting continuity of care and improving outcomes in home-based pressure ulcer management.

EP544 Combination of oral lumbrokinase and a channa striata extract for non-healing diabetic foot ulcer (DFU) in diabetic patients with peripheral arterial disease (PAD): Three case reports

Alvin Yalung[1], Claudette Albarico[1], Enrique Constantino[1], Raymond Tjandrawinata[2]

[1]Touch of Life Medical Clinic and Wound Care Center, Antipolo, Philippines, [2]Dexa Laboratories of Biomolecular Sciences, Department of Biotechnology Atma Jaya Catholic University of Indonesia, Bekasi, Indonesia

Aim: Non-healing diabetic foot ulcers (DFUs) with coexisting peripheral arterial disease (PAD) frequently lead to infection and amputation. Smoking further increases the risk of PAD progression and impairs wound healing in diabetic individuals. Adjunctive therapies intended to improve blood circulation and promote cell proliferation may accelerate wound healing in such high-risk populations. This report aims to describe clinical outcomes from three cases of non-healing DFUs with PAD treated with standard care and a combination of oral lumbrokinase and a *Channa striata* extract.

Method: Three patients with type 2 diabetes mellitus (T2DM), non-healing DFUs, and PAD confirmed by Ankle-Brachial Index (ABI), all had a smoking history, including one active smoker, were treated with debridement and standard wound care. In addition, they received oral lumbrokinase at 490 mg three times daily and a *Channa striata* extract at 250 mg twice daily for 30-60 days. Clinical wound progressions were documented.

Results / Discussion: A 34-year-old male presented with an infected wound on the left foot, persisting for two weeks. **Case 2**: An 82-year-old female presented with a progressively enlarging infected wound on the right lateral malleolus and dorsum, persisting for more than eight months. **Case 3:** A 49-year-old female presented with an infected hypertrophic scar on the left foot, persisting for two months. Each case demonstrated significant clinical outcomes, with a significant reduction of wound size and depth, development of healthy granulation tissues, and progressing toward epithelialization or complete closure. Thus, no revascularization or amputation was indicated in any case.

Conclusion: These cases suggest that combining the oral lumbrokinase with a *Channa striata* extract may offer a promising adjunctive therapy for non-healing DFUs with PAD.

EP545 Efficacy of antibiotic-loaded soluble synthetic pure calcium sulfate beads in the treatment of charcot foot osteomyelitis

Serdar Terzioglu[1]

[1]Türkiye Cumhuriyeti Sağlık Bakanlığı, Ankara Bilkent Şehir Hastanesi, Ankara, Türkiye

Aim: To investigate the role of antibiotic-loaded soluble synthetic pure calcium sulfate beads for local high-concentration antibiotic delivery following radical debridement in the treatment of osteomyelitis associated with Charcot foot disease, which presents a challenging clinical scenario often requiring prolonged systemic therapy.

Method: This is a case report detailing the management of a patient presenting with Charcot foot, chronic osteomyelitis, and a Wagner Grade 4 diabetic foot ulcer characterized by significant tissue loss and destruction of the plantar fascia. After the patient declined a proposed below-knee amputation, a comprehensive soft tissue debridement was performed to remove all infected and necrotic material. In the same surgical session, frozen granules prepared by loading 5 cc of calcium sulfate with a combination of vancomycin and gentamicin (1 flacon and 3 ml respectively) were meticulously placed into the deep plantar debridement cavity. An antibacterial wound dressing was then applied. The patient's clinical course was closely monitored with follow-up examinations on days 15, 30, and 40 post-intervention.

Results / Discussion: At the final follow-up, the treatment resulted in a dramatic reduction in the size of the plantar ulcer, indicating successful control of the persistent infection. Near-complete epithelialization and healing of the open wound were achieved, with only a minimal, residual open area remaining on the medial sole of the foot.

Conclusion: The synergistic combination of radical debridement of infected bone and soft tissue with the local delivery of high-concentration antibiotics via calcium sulfate beads appears to be an effective, limb-salvaging adjunctive treatment in the management of complex Charcot foot healing. This approach should be considered as a valuable addition to standard systemic antibiotic therapy and wound care protocols.

EP546 Enzymatic alginates as an antimicrobial stewardship in the menagementof non-healing wounds: 12-patients experience

Maurizio Carnali[1]

[1]Ast Ancona Civic Hospital Fabriano, General Surgery Deparment, Viale Stelluti scala 26 60044 Fabriano, Italy

Introduction: Non-healing wounds frequently remain in the inflammatory phase, leading to delayed tissue repair. Effective healing requires a viable wound bed, appropriate moisture balance, and absence of infection. EA dressing combines an absorbent alginate matrix with an enzymatic antimicrobial system, promoting continuous autolytic debridement, exudate management, and non-cytotoxic antimicrobial protection. This approach reduces reliance on Ag+ dressings, limiting selective pressure on microorganisms and aligning with key AMS principles.

Materials and Methods: 12 patients aged 52–78 years with non-healing wounds were included: 6 vascular ulcers, 4 post-traumatic ulcers, and 2 vasculitic or connective tissue–related lesions. Inclusion criteria: chronicity >4 weeks and presence of devitalized tissue or biofilm. Exclusion criteria: neoplastic wounds, severe immunosuppression, or hypersensitivity. EA was applied every 72 hours with a PU secondary dressing for 30 days. Outcomes were compared observationally with SC, consisting of collagenase plus PU or PU Ag+ in cases of infection or high exudate. Evaluated endpoints included wound progression, pain reduction, safety, dressing change frequency, and AMS relevance.

Results: Autolytic debridement was evident within 1 week, with granulation tissue appearing by week 2. The proliferative phase began by week 3 and week 4 in vasculitic lesions. Early re-epithelialization was observed in vascular and post-traumatic wounds. No septic complications occurred. Pain reduction was reported within 3 to 5 days. Dressing changes were reduced by 50% compared with SC, decreasing resource use and outpatient visits while avoiding Ag+ exposure and supporting AMS goals.

Conclusions: EA promotes effective healing, reduces patient discomfort and resource consumption, and provides antimicrobial control without contributing to resistance. This approach represents an AMS-aligned strategy for managing non-healing wounds, improving clinical efficiency and patient outcomes.

EP547 Case report of medical adhesive-related skin injury (MARSI) after sternotomy: Use of transparent postoperative dressing with polyacrylate and dialkylcarbamoyl chloride

Lucas Rezende[1 2], Paula Freitas[3], Aline Ramalho[4], Natalia Barros[5]

[1]Centro Universitário Salesiano, Vitória, Brazil, *[2]Universidade Federal do Rio de Janeiro, Rio de Janeiro, Brazil*, *[3]Universidade Federal do Espírito Santo, Departament of Nursing, Vitória, Brazil*, *[4]Hospital Sirio Libanês, São Paulo, Brazil*, *[5]Essity, São Paulo, Brazil*

Aim: To report a case of medical adhesive–related skin injury (MARSI) after removal of a sternotomy dressing following valve replacement surgery.

Method: Case report developed according to CARE Guidelines. Data were obtained through retrospective review of the institutional electronic medical record, authorized photographs, and team notes. The patient provided informed consent.

Results / Discussion: A 48-year-old woman presented with a six-month history of fever, night sweats, tachycardia, and hypotension. Echocardiography identified valvular vegetation compatible with infective endocarditis. She underwent sternotomy for valve replacement, with intraoperative normoglycemia and <4 hours of postoperative mechanical ventilation. On postoperative day one, a simple gauze dressing secured with microporous tape was

applied. After 24 hours, the first dressing change resulted in MARSI due to improper tape removal and lack of adhesive remover, causing erythema >30 minutes and skin stripping. Management included barrier film spray, cleansing with hypochlorous acid, and a transparent polyurethane postoperative dressing with polyacrylate adhesive, combined with a dialkylcarbamoyl-chloride–coated absorbent layer. Complete resolution occurred within three days, with intact skin and no infection. The surgical site healed appropriately, without recurrent MARSI, and the patient was discharged after seven days on intravenous antibiotics.

Conclusion: This case underscores postoperative skin vulnerability in cardiac surgery and highlights the underrecognition of MARSI, especially with microporous adhesives on fragile skin. Early identification and transparent postoperative dressings containing polyacrylate and dialkylcarbamoyl chloride may help prevent MARSI and surgical site infection.

EP548 Gracilis myocutaneous flap for perineal and scrotal reconstruction in a patient with urethral perforation following fournier's gangrene: A functional, salvage-oriented approach

Manel Dik[1]

[1]*Public Hospital Eloued - Eloued Algeria, ElOued, Algeria*

Aim: To present a functional, salvage-oriented reconstructive strategy using a pedicled gracilis myocutaneous flap for perineal and scrotal defects associated with urethral perforation following Fournier's gangrene in a resource-limited setting.

Method: A 76-year-old man with extensive perineoscrotal loss and a 1 cm urethral perforation at the penoscrotal junction underwent reconstruction using a pedicled gracilis myocutaneous flap.

The muscle reinforced the urethral repair after primary closure, while the skin paddle resurfaced the scrotum. A full-thickness skin graft was applied to the penile root. Postoperative complications were managed with chemical leeching and, later, a local The procedure resulted in restored urinary continence, stable scrotal coverage, complete graft take, and significant improvement in mobility and quality of life.

Despite partial cutaneous paddle loss, staged management achieved full functional recovery.

This case highlights the reliability of the gracilis flap for complex perineoscrotal wounds, offering vascularized, protective tissue even where advanced urethral reconstruction techniques are unavailable flap.

Results / Discussion: The procedure resulted in restored urinary continence, stable scrotal coverage, complete graft take, and significant improvement in mobility and quality of life.

Despite partial cutaneous paddle loss, staged management achieved full functional recovery.

This case highlights the reliability of the gracilis flap for complex perineoscrotal wounds, offering vascularized, protective tissue even where advanced urethral reconstruction techniques are unavailable.

Conclusion: The gracilis myocutaneous flap is a safe, versatile, and effective salvage option for combined perineoscrotal defects and urethral injury after Fournier's gangrene, particularly in low-resource environments. It ensures durable coverage, infection control, and functional preservation.

EP549 Octenidine as an accompanying treatment for cutaneous leishmaniasis can improve wound healing and scarring

Dragan Iedina[1], Ivana Zebic[1], Sandra Sardelic[1], Julia Walochnik[2], Edita Drazic[1]

[1]*University Hospital Split, Split, Croatia*, [2]*Medical University of Vienna, Vienna, Austria*

Aim: Cutaneous leishmaniasis (CL) is a parasitic skin disease caused by protozoa of the Leishmania genus and is endemic in nearly 100 countries, including Croatia. Although typically linked to endemic areas, population mobility and environmental changes have contributed to its wider distribution. CL often results in chronic, slow-healing ulcers

due to persistent parasite-induced inflammation that disrupts normal tissue repair. We report the first use of topically applied octenidine-based products as adjunctive wound therapy in combination with standard treatment using meglumine antimoniate. Octenidine has previously been shown to improve surgical scar quality and was therefore evaluated in this context.

Method: A case of a 44-year-old male with a genetic predisposition to hypertrophic scarring and PCR-confirmed Leishmania infantum infection is presented. Standard therapy consisted of intradermal injections of meglumine antimoniate (2 mL every three days; five sessions). Adjunctive local treatment of three lesions included: (1) octenidine-based antiseptic solution for daily cleansing; (2) hydrogel to support healing until closure; and (3) a cream applied post-epithelialization to enhance regeneration. Clinical examinations with photographic documentation were performed throughout the treatment period.

Results / Discussion: Complete healing was achieved within 60 days for the facial lesion, 25 days for the upper-arm lesion, and 20 days for the back lesion. The facial lesion healed with an excellent cosmetic outcome and no scarring, while mild hyperpigmentation persisted on the upper arm and back. No adverse reactions occurred. The combined approach was well tolerated and simple to apply in routine care.

Conclusion: This case suggests that octenidine-based products may represent a useful adjunct to standard CL therapy, supporting epithelialization and potentially improving cosmetic outcomes.

EP550 Near infrared imaging pre and post lower limb revascularistation: a case report

Kari Clifford[1], Emil Schmidt[2], Jolanta Krysa[3]

[1]Surgical Outcomes Research Centre, Department of Surgical Sciences, Dunedin, New Zealand, *[2]Surgical Outcomes Research Centre, Department of Surgical Sciences, Dunedin, New Zealand*, *[3]Surgical Outcomes Research Centre, Dunedin School of Medicine, Vascular Surgery Clinical Leader, Dunedin, New Zealand*

Aim: Peripheral arterial disease (PAD) frequently leads to chronic lower-limb ulcers. Near infrared imaging modalities such as fluorescence-based (NIRF) and reflectance spectroscopy (NIRS) offer methods to visualise tissue perfusion, particularly in the microvasculature. This case report compares and contrasts these modalities in visualising a chronic lower-limb ulcer post-angioplasty.

Method: A 90-year-old male type 2 diabetic with multiple comorbidities presented with a non-healing left lateral lower limb ulcer. Vascular assessment showed a right ankle-brachial pressure index (ABPI) of 1.1 and left of 0.66, with severe impairment noted on lateral (183 ms, class 3) and medial plantar (250 ms, class 4) acceleration times (PAT). Imaging revealed a 10 cm high-grade stenosis of the left posterior tibial artery.

Results / Discussion: Angioplasty without stenting was performed. NIRF imaging demonstrated severely compromised perfusion pre-angioplasty, with predominantly dark-blue coloration indicating ischemia around the wound. NIRS imaging revealed heterogeneous pre-angioplasty tissue oxygenation. Post-angioplasty, PAT improved laterally and medially (137ms and 160ms respectively). NIRF imaging showed dramatic improvement indicating enhanced microvascular blood flow, with an area under the curve 2.8 x higher than pre-angioplasty. Post-angioplasty NIRS showed substantial improvement in tissue oxygen saturation. Both modalities concordantly demonstrated successful revascularization.

Conclusion: Near infrared vascular imaging modalities enabled dynamic and static perfusion assessment of a chronic limb ulcer in a high-risk patient post-angioplasty. NIRF offered superior temporal resolution and detail, while NIRS provided cost-effective data without invasive contrast. Application of these techniques allowed monitoring of response to revascularisation and informed ongoing wound care in a complex clinical scenario.

EP551 Managing gas gangrene in a resource-constrained bahamian setting: A podiatric care perspective

Lauren Stevens[1], Allison Abrishami[2], Gabrielle Donaldson[3], Lady Paula DeJesus[41]*Yale New Haven Health - Bridgeport Hospital, Bridgeport, United States*, [2]*Barry University School of Podiatric Medicine, Miami Shores, United States*, [3]*Dr. G Podiatry, Nassau, Bahamas*, [4]*Yale New Haven Health - Greenwich Hospital, Greenwich, United States*

Aim: This case report evaluates the clinical effectiveness of an integrated wound care regimen for gas gangrene in a resource-limited outpatient setting in the Bahamas where surgical management is unavailable. The approach combines iodine, topical antibiotic powder, gentian violet, and serial sharp excisional debridement to suppress a Clostridium perfringens infection, safeguard limb function, and stimulate healing in a setting without advanced technologies or inpatient surgical access. This multimodal protocol aims to optimize local infection control, particularly where systemic antibiotics are less effective due to necrosis and impaired tissue perfusion.

Method: The report follows a 54-year-old female who developed gas gangrene of the left foot and underwent outpatient management over 30 weeks. Treatment involved repeated sharp excisional debridement using #10 blade scalpel, currette, metzenbaum scissors, surgical forceps, application of iodine (amount: 50ml), topical antibiotic powder (type: 20ml), and gentian violet (amount 5ml). The protocol emphasized serial debridements for removal of devitalized tissue and wound decompression, combined with locally-acting antimicrobials, antifungals, and pharmacologics.

Results / Discussion: Emergent sharp debridement, combined with topical iodine and antibiotic therapy synergistically reduced wound bioburden. Exposure of the infection to aerobic conditions inhibited proliferation of anaerobic bacteria. In this case report, the use of foundational wound care methods compensated for limited systemic and technological resources.

Conclusion: Foundational, multimodal wound care notably decreased bacterial load, created an aerobic wound environment, and fostered host tissue repair through mechanical, biochemical, and pharmacological interventions. This approach created a hostile environment for C. perfringens, highlighting effective outpatient alternatives in emergent settings. This case described a novel approach of managing gas gangrene in an underserved population with limited resources including unavailable surgical management and hospitalization.

EP552 Early burn scar management using mesenchymal stem cell

Christeen Youssef[1]

[1]*Everlast Wellness Medical Center, Everlast Wellness Academy, Abu Dhabi, United Arab Emirates*

Aim: To evaluate the effectiveness of early mesenchymal stem cell (MSC) therapy, derived from adipose tissue, in preventing permanent scar formation following an acute scald burn.

Method: A patient presented 10 days after sustaining a superficial-to-deep partial-thickness scald burn involving approximately 9% of the total body surface area. Examination showed erythema, increased vascularity and irregular borders without contracture. MSCs, defined as multipotent regenerative cells obtained from adipose tissue, were harvested through lipoaspiration of the lower limbs and periumbilical region. Thirty milliliters of lipoaspirate were processed and centrifuged to isolate an MSC preparation for intradermal use. One milliliter was injected across the affected area using a 27G needle. Three sessions were performed at monthly intervals alongside standard burn care. Scar progression was evaluated over 12 months, focusing on vascularity, pigmentation, texture, pliability and function.

Results / Discussion: Clinical improvement appeared after each session. At one month, vascularity decreased and wound borders began to regularise, indicating modulation of inflammation and early remodelling. At 12 months, the treated area showed soft pliable tissue with minimal pigment change, reduced visibility and no contracture. Findings suggest that early MSC therapy may enhance dermal regeneration by guiding fibroblast activity and supporting organised collagen deposition. No adverse events or donor-site complications occurred.

Conclusion: Early MSC therapy combined with standard burn management was associated with reduced long-term scarring and improved tissue quality following a scald injury. This case highlights the potential value of MSC-based regenerative treatment in early scar modulation and supports further controlled research on its role in acute burn care. Future studies should explore optimal dosing strategies, timing of administration, and comparative effectiveness against existing regenerative interventions to establish standardized clinical protocols for burns.

EP553 Interdisciplinary management of chronic venous ulcers: Case studies and therapeutic challenges in the Greek healthcare context

Evripidis Triantafyllou[1], Panteleimon Staktopoulos[2], Aikaterini Chrysikou[3], Georgios Chatzikorios[4]

[1]panhellenic Physiotherapy Association, Athens, Greece, *[2]Independent Researcher, Athens, Greece*, *[3]panhellenic Physiotherapy Association, Thessaloniki, Greece*, *[4]Technological Institute of Athens, Athens, Greece*

Aim: Chronic venous ulcers associated with obesity, phlebolymphostatic edema and comorbidities are complex clinical conditions that require coordinated, interdisciplinary management. In the Greek healthcare setting, their treatment is often hindered by the absence of structured therapeutic coordination, insufficient training among healthcare professionals, lack of national guidelines and limited provision of organized home-care services.

This presentation aims to analyze a series of case studies of patients with chronic ulcers treated through collaboration among physicians, nurses and physiotherapists. The objective is to highlight both the healthcare shortcomings in Greece and the therapeutic potential of well-coordinated, multidisciplinary interventions.

Method: Three patient case studies are presented, each with ulcers arising from different underlying causes (obesity, phlebolymphostatic edema, comorbidities). Management included comprehensive wound care, complete decongestive therapy and targeted physiotherapy focusing on restoring functional mobility and reducing mechanical overload contributing to ulcer formation.

Results / Discussion: Despite the significant structural and organizational challenges within the Greek healthcare system, all cases achieved successful wound healing, effective edema control and notable restoration of patient functionality. Improvement in mobility—facilitated by physiotherapeutic intervention beyond edema management—appeared to reduce the risk of ulcer development or recurrence, underscoring the crucial role of functional capacity in the pathophysiology of chronic ulcers.

Conclusion: A structured interdisciplinary approach can overcome systemic barriers and lead to meaningful clinical outcomes for patients with chronic ulcers. Strengthening healthcare professional training, developing national clinical guidelines, and expanding home-care services are essential steps toward improving ulcer management and preventing recurrence through functional rehabilitation.

EP554 Management of a Fournier's Gangrene with a TLC-Ag polyabsorbent fibre pad dressing as part of the patients' holistic management

Emilio Galea[1], Phuong Dong Dinh[2], Xuan Thien Nguyen[2]

[1]Urgo Medical, Paris, France, *[2]Trung Vuong Hospital, Burn & Plastic Aesthetic Dept, Ho Chi Minh City, Viet Nam*

Aim: Evaluate the efficacy of TLC-Ag polyabsorbent fibre pad dressings in the management of a post-surgical debridement Fournier's Gangrene.

Method: This article presents a surgical wound post-surgical debridement of a Fournier's gangrene managed by the TLC-Ag polyabsorbent fibre pad dressing as part of the holistic management of the patient. The patient was admitted on 03/04/2025 with Fournier's Gangrene, with nearly total necrosis of the scrotal region and the posterior penile shaft. Surgical debridement, suprapubic cystostomy, and colostomy were performed. Intravenous antibiotics were started and continued throughout the treatment. Post debridement, the wound was cleansed with an antimicrobial and a betaine surfactant, and the TLC-Ag polyabsorbent fibre pad dressing was applied as the primary dressing

Results / Discussion: Progress, with a healthy granulating wound bed, was noted on 19/04 (15 days post-op). The same local protocol was continued until 26/04, where partial surgical closure was performed, with complete surgical closure performed on 15/05.

Conclusion: Fournier's gangrene is a rare but very serious and complex condition with multiple long-term complications and high mortality rates (Kostovski et al, 2021). In this case, although surgical debridement was essential as a first intervention, the TLC-Ag polyabsorbent fibre pad dressing allowed continuous debridement of the wound and management of the local infection, which was instrumental in achieving a wound that was healthy enough for surgical closure.

EP555 Traumatic lower limb injury with necrotizing fasciitis managed with revision bypass surgery and negative pressure wound therapy

Ilgiz Tuzken[1], Dilara Karakaya[1], Can Boztug[1], Ömer Arda Çetinkaya[1]

[1]*Department of Peripheral Vascular Surgery, Ankara University School of Medicine, Ankara, Türkiye*

Aim: To present the multidisciplinary management of a young patient with a traumatic lower limb injury complicated by necrotizing fasciitis, failed revascularization, and prolonged wound healing requiring negative pressure wound therapy (NPWT).

Method: A male patient presented with extensive soft-tissue necrosis, multiple drainage sites, and clinical findings consistent with necrotizing fasciitis surrounding a previously performed but thrombosed femoro-distal bypass. A foreign body had been removed at an outside facility before referral.Upon admission, treatment included extensive debridement and revision revascularization using an autologous saphenous vein bypass. Due to persistent tissue loss and polymicrobial colonization in wound cultures, repeated NPWT applications and systemic antibiotic therapy were administered. Follow-up consisted of serial wound assessments, vascular imaging for graft patency, and microbiological monitoring.

Results/Discussion: After revision bypass surgery, the patient underwent more than 45 NPWT applications. Early polymicrobial cultures improved with targeted systemic therapy. Imaging consistently demonstrated patency of the new bypass with adequate distal perfusion. Granulation progressed sufficiently for split-thickness skin grafting over the tibial defect; however, the plantar, weight-bearing wound remained partially open due to depth and anatomical complexity, requiring continued advanced wound care. Despite preserved limb perfusion, both motor and sensory functions of the distal limb were lost, reflecting the severity of initial trauma and soft-tissue involvement. The overall treatment course required hospitalization exceeding seven months, underscoring the complexity of infection control and limb preservation.

Conclusion: In traumatic lower limb injuries complicated by necrotizing fasciitis and failed revascularization, early debridement, revision bypass surgery, and NPWT may be essential for limb salvage. Even with significant functional loss, maintaining graft patency and achieving graftable granulation tissue highlight the value of a coordinated multidisciplinary approach in reducing the risk of major amputation.

EP556 Clinical beneffits of octenidine for damaged peristomal skin

Željka Mihovilić[1], Vesna Konjevoda[1]

[1]*Clinical Hospital Sveti Duh, Zagreb, Croatia*

Aim: Maintaining peristomal skin integrity is a major challenge in stoma care. Up to 75% of patients experience some degree of peristomal skin damage, which can impair quality of life and increase the risk of secondary infections. Antimicrobial cleansing with octenidine-based formulations may offer additional benefit when incorporated into standard stoma-care routines. This study aimed to evaluate clinical outcomes associated with the use of octenidine in the management of peristomal skin damage.

Method: Six adult patients with colostomies or ileostomies who presented with peristomal skin complications (PSCs) were treated following the local stoma-care protocol. Reported symptoms included hypergranulation, erythema, erosion, infection, ulceration, pain, bleeding, and moisture- or adhesive-related injury. During each stoma-device change, the affected area was cleansed using an octenidine-based antiseptic solution with a 1-minute contact time, then gently dried and managed with standard stoma-care accessories. Clinical outcomes were documented for up to four weeks through serial photographic records and patient-reported symptom assessments.

Results / Discussion: Regular use of octenidine during stoma-device changes was associated with noticeable improvement in peristomal skin condition. Patients showed reductions in redness, exudation, discomfort, hypergranulation, and signs of infection when the antiseptic solution was used alongside standard management. Symptom relief was often reported early during follow-up, and no adverse reactions occurred. These findings suggest that octenidine supports stabilization of the peristomal microenvironment, enhances appliance adherence, and contributes to improved patient comfort.

Conclusion: This case series indicates that octenidine is a well-tolerated adjunct to standard care, with the potential to alleviate symptoms, support peristomal skin integrity, and reduce infection risk in patients with PSCs.

Keywords: octenidine; peristomal skin; stoma care; skin complications; antiseptic management

EP557 Complex palliative management of cervical myiasis and infected malignant wounds in hypopharyngeal cancer

Bianca Oliveira[1], Juliana Batista[1], Caio Lopes[1]

[1]*Hipermed, Vitória da Conquista, Brazil*

Aim: To report skin-integrity management and palliative care for an adult with hypopharyngeal cancer and an extensive infected cervical lesion complicated by myiasis, active bleeding and laboratory indicators of systemic inflammatory response/possible sepsis, describing local measures (cleansing, PHMB, antiseptic-impregnated gauze, occlusion) and systemic antibiotics.

Methods: Case report of a 44-year-old man with hypopharyngeal tumor admitted with an infected left cervical wound. He was conscious, ventilated/tracheostomized and receiving ciprofloxacin plus metronidazole (initially oral, later IV). Nursing staff performed manual larval removal. Labs showed progressive anemia (Hb 8.8→7.5 g/dL), marked leukocytosis (31,760→15,900/mm^3), very high CRP (192→170 mg/L) and elevated lactate (13.2 mmol/L), indicating severe infection and metabolic compromise. The lesion presented extensive necrosis, myiasis, fibrinous slough, serosanguinous exudate, fetid odor and irregular borders. Local care included 0.9% saline cleansing, PHMB-impregnated gauze to reduce bioburden and absorb exudate, sterile occlusion and manual larval extraction. Systemic management used empirical ciprofloxacin plus metronidazole, escalated to IV per clinical evolution.

Results: Manual larval removal offered immediate control. Topical PHMB reduced microbial load and supported a cleaner wound bed. Systemic antibiotics were maintained and adjusted according to clinical status. Laboratory abnormalities indicated high risk for instability and potential sepsis; wound cultures and surgical evaluation for possible debridement were advised. Literature supports combining physical larval removal with antiparasitic agents (e.g., ivermectin) in myiasis and endorses PHMB for topical bioburden control, though evidence that systemic antibiotics reduce malodor remains limited.

Conclusions: A combined strategy—manual myiasis removal, topical PHMB and antiseptic-impregnated occlusive dressings plus targeted systemic antibiotics—aligns with recommended care for malignant fungating wounds. Severe laboratory derangements justify ICU-level monitoring, multidisciplinary coordination, culture-guided therapy and shared decision-making prioritizing symptom control and patient safety.

EP558 The protagonism of Brazilian specialized nursing the management ofpostoperative complications: Application of advanced technologies in pediatric polydactyly correction

Juliana Lucinda dos Santos[1], Lys Santos[2]

[1]Entre Nos, Santo André, Brazil, *[2]Alianca Medica Vascular Ltda, Rio de Janeiro, Brazil*

Introduction: Congenital foot malformations, such as syndactyly and polydactyly, may impair foot function and development. Surgical correction is often necessary, but postoperative complications, including critical ischemia and tissue necrosis, can compromise healing, requiring specialized and phased wound management.

Objective: To describe specialized nursing Brazilian management in a complex postoperative wound case involving critical ischemia after congenital foot surgery in a pediatric patient, using advanced therapeutic strategies in a phased protocol.

Methods: This descriptive, observational case report involved an 8-year-old child with no comorbidities who underwent surgical correction of syndactyly and polydactyly. After Seven days postoperatively, critical ischemia and tissue necrosis were observed. The patient was referred to a specialized wound care clinic in Santo André, SP, Brazil, where a strategic three-phase wound management plan was implemented.

- Phase 1 – Initial wound bed preparation (dressings every 3 days): cleansing with PHMB, low-level laser therapy (2 J, 660 nm, 10 mW), enzymatic debridement with Angionogel, application of a non-adherent DACC contact layer, and bandaging. Daily hyperbaric oxygen therapy.
- Phase 2 – Viable wound bed: Following reduction of necrotic tissue and establishment of viable tissue, an acellular extracellular matrix was applied to support physiological regeneration.
- Phase 3 – epithelialization

Results: Progressive necrotic tissue reduction, improved perfusion, optimized wound bed, and steady epithelialization were observed. The phased, multimodal approach facilitated effective healing.

Conclusion: Phased advanced wound care, guided by specialized nursing assessment, was crucial for managing complex postoperative ischemia and promoting wound resolution in this pediatric case.

EP559 Clinician versus artificial intelligence assessment of wound size and tissue composition in a simulated wound model

Ljubisa Paden[1 2]

[1]The University of Manchester, Division of Nursing Midwifery and Social Work, Manchester, United Kingdom, *[2]University of Ljubljana, Faculty of Health Sciences, Ljubljana, Slovenia*

Aim: The aim of this study was to evaluate the relationship between clinician wound assessments, including wound size and wound bed tissue types, and the assessments generated by an AI handheld medical device.

Method: A cross-sectional survey used purposive, non-random sampling to recruit 20 registered nurses. Participants assessed a wound model using their clinical judgement, guided by the wound care assessment form, and then repeated the assessment using the AI device. They recorded wound length, width, depth, and estimated the proportions of granulation tissue, slough and eschar.

Results / Discussion: Clinician measurements showed greater variability across all aspects of wound assessment than the AI device, which produced more tightly clustered values. This pattern was consistent for both wound size and tissue-type estimates. Consistency between the two methods was further examined using the Wilcoxon matched-pairs test, which indicated no significant differences for wound length, width, depth, or granulation ($p > 0.05$). However, slough and eschar measurements differed significantly between clinicians and the AI ($p < 0.05$). Overall, clinician and AI assessments were similar for most parameters, with notable discrepancies for slough and eschar.

Conclusion: While this consistency suggests potential for AI to support more standardised wound evaluation, the findings should be interpreted with caution. Further research with multiple wound types and validated reference standards is needed to determine the tool's accuracy and clinical usefulness.

EP560 Reconstruction of a large hemifacial defect following fourth-degree contact burn using an anterolateral thigh flap

Cho-Han Wu[1]

[1]*Department of Surgery, China Medical University Hospital, College of Medicine, China Medical University, Taichung, Taiwan*

Aim: To report the reconstructive outcome of a large hemifacial defect caused by a fourth-degree contact burn using a free anterolateral thigh (ALT) flap and to evaluate its functional and aesthetic effectiveness.

Method: A 17-year-old male sustained a fourth-degree contact burn involving the right hemiface, resulting in extensive soft tissue loss and severe injury to the right eye and auricle. After thorough debridement and stabilization, reconstruction was performed using a large free ALT flap measuring 28 × 18 cm to restore facial contour and soft tissue volume. Secondary reconstruction included the use of local flaps and split-thickness skin grafts for external auditory canal recreation. Clinical outcomes were assessed based on wound healing, flap viability, functional recovery, and aesthetic appearance during follow-up.

Results / Discussion: The ALT flap survived completely without vascular compromise, and stable wound healing was achieved. Secondary procedures successfully reconstructed the external auditory meatus. However, stenosis of the external auditory meatus was noted. Regular self-dilation was required, and intralesional steroid injections around the external auditory meatus were administered every three months to reduce scar contracture.

Conclusion: The free ALT flap provides a reliable and versatile option for the reconstruction of extensive composite hemifacial defects following deep contact burns. It enables effective restoration of facial contour, protects vital structures, and allows for staged functional reconstruction.

EP561 Non-viable tissue removal using collagenase ointment with hyaluronic acid: Using Bates-Jensen scoring system analysis

M. Vadivelu Muniandi[1], Yusoff Shariff[1], Jawati Belik[1], Mohd Syafiqbillahi Al Fakhrazi Bin Mohd Ripin[1], Norhani Othman[1], Rosyati Johari[1], Mohd Amir Nasir[1], Norasimah Shahari[1], Maziah Fouzi[1], Chin Wen Jie[1], Sunantha G Gobu[1]

[1]*Hospital Tuanku Ja'afar, Seremban, Lincoln University College, Malaysia, Seremban, Malaysia*

Aim: To assess the speed and efficiency of the combination of collagenase enzyme and hyaluronic acid in eliminating non-viable tissue.

Method: Three patients with wounds exhibiting necrotic tissue and slough were identified. An initial quantitative evaluation of the wound bed was conducted using the Bates-Jensen Wound Assessment Tool (BWAT). Wound dressing done with collagenase enzyme combination with 0.2% hyaluronic acid. The wound was reassessed with BWAT scoring approximately on the 2nd and 4th week.

Results / Discussion: Enzymatic debridement uses a specific enzyme to remove non-viable tissue. It facilitates wound debridement by breaking down proteins with the collagenase enzyme. The BWAT serves as an objective means to evaluate and monitor the healing process of wounds. It analyzes various wound features such as dimensions, depth, and edges, along with types of tissue, exudate, and surrounding skin. Fast and effective removal of non-viable tissue is vital for the formation of healthy granulation tissue and epithelization.

The first patient initially presented with a BWAT score of 43, which improved to 37 after approximately 4 weeks. The wound severity decreased from extreme to mild.

The second patient started with a score of 53 and, following around 4 weeks of treatment, achieved a score of 13, indicating a transition from extreme severity to complete wound closure.

The third patient had a starting score of 44, which improved to 22 by the end of approximately 4 weeks. The wound severity improved from extreme to mild.

Conclusion: Enzymatic debridement of wounds using a 0.2% hyaluronic acid-collagenase enzyme formulation aids rapid removal of non-viable tissue. This process is crucial in preparing the wound bed, leading to quicker healing of the wound.

EP562 Brazilian clinical podiatry focus: Excellence in managing complex wounds and humanized care

Natalia Santos[1], Juliana Lucinda dos Santos[2], Elizabet Afonso[1]

[1]Podoonic Podologia Avançada, Nova Serrana, Minas Gerais, Brazil, [2]Prime Care Cuidados Integrados a Feridas, Santo Andre, Sao Paulo, Brazil

Aim: The treatment of chronic and acute wounds in patients with vascular comorbidities, such as deep vein thrombosis (DVT), represents a significant challenge due to the increased risk of delayed healing and infections. This study aimed to describe podiatric care and evaluate the clinical response to specialized management of an acute plantar wound, demonstrating the impact of integrating therapeutic technologies in care.

Method: A descriptive and exploratory case study was conducted in November 2025 at a podiatry clinic in Minas Gerais, Brazil. Clinical records, lesion assessments, therapeutic interventions, and healing evolution were analyzed. A 44-year-old male patient with a history of deep vein thrombosis (DVT) on continuous anticoagulant use presented with intense pain and a plantar lesion on the head of the fifth metatarsal after previous inadequate treatment with nitric acid. Clinical examination showed a central hematoma, peripheral hyperkeratosis, serous exudate, and infection controlled with antibiotics. Treatment followed a well-defined schedule. On 11/05/2025. Interventions included cleaning with PHMB soap on adjacent margins, debridement of hyperkeratotic edges, application of photodynamic therapy (PDT) with 9J centrally, and silver hydrofiber dressing for moisture control and protection. A follow-up appointment was scheduled for 48h later; pressure relief with felt was recommended.

Results / Discussion: This protocol, including PDT, advanced dressings, safe debridement, and biomechanical management, led to a significant reduction in inflammation, pain relief, and progress in healing. Plantar pressure control was fundamental to the results.

Conclusion: The podiatric care demonstrated a direct impact on healing and the prevention of complications, emphasizing its fundamental role in the management of plantar lesions in vascular comorbidities. The results reinforce the need for protocols and of podiatric interventions in vascular risk scenarios.

EP563 AI or clinical evaluation? A burn case where hybrid intelligence informed optimal management

Serdar Terzioglu[1], Kubra Bilge Polat[1], Fatma Betul Ozguven[1], Mehmet Ozer[1]

[1]Ankara Bilkent City Hospital, Ankara, Türkiye

Aim: To delineate therapeutic divergence between an image-based artificial intelligence (AI) burn assessment and clinical bedside evaluation, and to illustrate how their integration can inform a Hybrid Intelligence model in burn management.

Method: A thigh burn presenting with a dry, dark, and firm eschar was independently assessed by an AI system and by clinical examination. The AI, operating solely on the wound image, classified the burn as deep partial- to full-thickness and recommended early surgical debridement in accordance with established burn protocols. Clinical assessment revealed stable local conditions, including absence of infection, absence of increased local temperature, and absence of progressive erythema. Tissue characteristics suggested that physiological eschar separation was feasible without operative intervention. Consequently, conservative management with enzyme alginogel therapy was initiated without surgical or mechanical debridement. Wound progression was monitored over 21 days with scheduled dressing changes.

Results / Discussion: Contrary to the AI recommendation, conservative enzyme alginogel therapy achieved progressive eschar softening, complete autolytic separation, and development of a healthy granulation bed, obviating the need for surgery. This discrepancy underscores key limitations of image-only AI systems, which cannot evaluate tissue elasticity, thermal gradients, pain responses, or peri-wound clinical signs. Clinical reasoning corrected the AI-derived recommendation and prevented unnecessary operative trauma.

Conclusion: Despite an AI-generated suggestion for early debridement, the wound healed fully under conservative management. This case illustrates that Hybrid Intelligence - combining rapid AI image interpretation with comprehensive clinical assessment - can enhance decision-making and support safer, individualized burn care.

EP564 Customized 3D-printed orthosis for postoperative management of recurrent finger contracture: A case report

Kyung Ah Lee[1], Inbaek Park[2]

[1]Haeundae Paik Hospital, Inje University, Busan, Korea, Rep. of South, *[2]AM Solution, Production Engineering Research Institute, LG Electronics, Seoul, Korea, Rep. of South*

Aim: Postburn scar contracture often requires surgical release, yet preventing recurrence remains challenging. This study aimed to evaluate the efficacy of a customized 3D-printed orthosis in the postoperative management of finger contracture.

Method: A 7-year-old patient presented with progressive contracture of the 2nd and 3rd fingers following a prior split-thickness skin graft (STSG) (Fig. 1). Scar release involved multiple Z-plasties and a full-thickness skin graft (FTSG) from the plantar region (Fig. 2). Ten months post-surgery, a customized, mesh-like 3D-printed orthosis was fabricated to maintain extension and facilitate movement (Fig. 3).

Results / Discussion: Over a 7-week monitoring period, the patient reported reduced tightening sensations. The device effectively maintained finger extension, preserved range of motion, and prevented recurrence (Fig. 4). Furthermore, its lightweight and adjustable design facilitated high compliance and consistent daily use.

Conclusion: This case demonstrates that a customized 3D-printed orthosis provided early functional improvement and effective contracture control. The lightweight and comfortable design enhanced tolerance, which is particularly critical in pediatric patients, and supported consistent rehabilitation. These findings suggest that 3D-printed orthoses represent a promising supportive tool for improving outcomes in postoperative contracture management.



Fig. 1. Preoperative view of recurrent contracture in the 2nd and 3rd fingers after prior STSG.

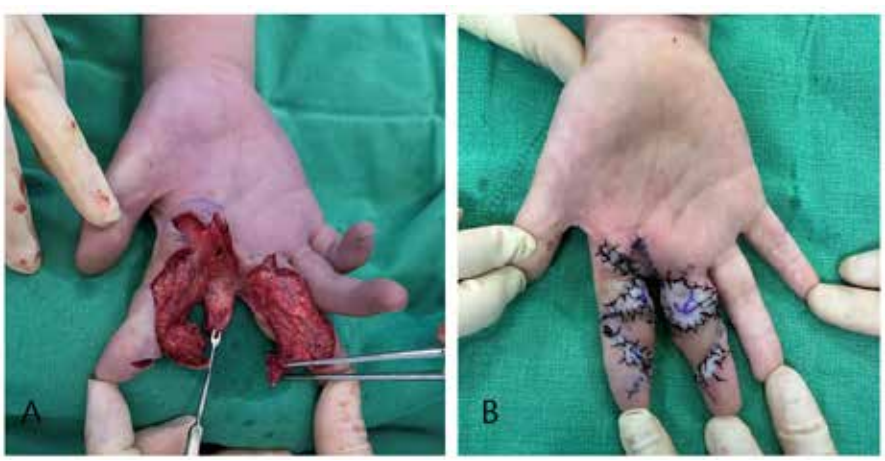

Fig. 2. (A) Intraoperative release via Z-plasty; (B) Postoperative plantar FTSG coverage showing improved extension.



Fig. 3. Patient wearing the customized 3D-printed orthosis designed to maintain extension.



Fig. 4. Follow-up at 1-year post-surgery (7 weeks post-orthosis) showing maintained extension without recurrence.

EP565 An alternative treatment modality in Nicolau syndrome

Serdar Terzioglu[1], Fatma Betul Ozguven[1], Kubra Bilge Polat[1], Mehmet Ozer[1]

[1]*Ankara Bilkent City Hospital, Ankara, Türkiye*

Aim: Nicolau syndrome is an uncommon iatrogenic ischemic necrosis of the skin and deeper tissues that may occur following intramuscular injection. It is classified as an atypical wound - a category defined by wounds that do not fit into the primary non-healing wound groups and may arise from inflammatory, infectious, chronic, or genetic causes. The aim of this study was to minimize invasive interventions and identify a more cost-effective alternative treatment modality for the management of Nicolau syndrome.

Method: A 47-year-old woman with a gluteal wound that developed after an intramuscular injection of diclofenac sodium was referred to our clinic following several surgical debridement procedures for consideration of negative pressure wound therapy and additional surgical intervention. After wound assessment, in order to avoid further unnecessary surgeries and hospitalization, enzyme alginogel dressings and a structured follow-up plan were initiated. Dressings were changed every 1–2 days over a 12-week period.

Results / Discussion: Following treatment with enzyme alginogel dressings, detachment of necrotic tissue from the wound bed was observed by the 4th week, a marked increase in granulation tissue by the 8th week, and progressive epithelialization by the 12th week.

Conclusion: This case demonstrates that enzyme alginogel dressings may serve as an effective alternative in the management of atypical wounds such as Nicolau syndrome, reducing the need for repeated invasive procedures and hospitalization while supporting both debridement of necrotic tissue and promotion of granulation.

EP566 Infrared thermography for differential diagnosis of complex diabetic foot lesions in primary care settings

Lourdes Muñoz-Hidalgo[1], Katia Furtado[2]

[1]USF Cruz de Celas - ULS Coimbra, ELCOS - Sociedade Portuguesa de Feridas, Coimbra, Portugal, *[2]ULS Alto Alentejo, Comprehensive Health Research Center, Portalegre, Portugal*

Aim: This case study aims to demonstrate the utility of Infrared Thermography (IRT) as a rapid, complementary, non-invasive diagnostic tool in primary healthcare for differential diagnosis of complex diabetic foot pathology, especially in distinguishing ischemia from inflammatory conditions. Early detection is crucial for prevention and management, helping to avoid severe complications and improving quality of life.

Method: A descriptive case study was conducted on an 87-year-old male patient with Type 2 Diabetes Mellitus, renal insufficiency and hypertension during a routine assessment. Ethical considerations were strictly followed. Clinical examination indicated weak pedal pulses and an abnormal Toe-Brachial Index (IPTB) of 0.5, suggesting Peripheral Arterial Disease (PAD). IRT imaging was performed with a 320x240 pixels resolution camera, after the patient acclimatization, registering thermal radiation from the foot surface. Thermal distribution patterns were analyzed, where localized temperature increases indicated inflammation, while decreases suggested hypoperfusion or ischemia.

Results/Discussion: Conventional clinical investigation confirmed circulatory disorders (weak pulses, IPTB ≤0.9). IRT complemented these findings, visualizing cold areas indicating ischemia or hypoperfusion versus hot areas suggesting inflammation or infection. The assessment confirmed ischemia and hypoxia, indicative of poor perfusion. IRT provided objective analysis of thermal asymmetry and localized temperatures, offering critical information beyond standard clinical assessment.

Conclusion: Infrared Thermography is a practical, non-invasive and reproducible method for differential diagnosis and risk stratification of complex diabetic foot lesions in primary car. It effectively visualizes thermal asymmetries, distinguishing heat from inflammatory processes and cold from ischemia. This objective data is vital for early detection and timely referrals, enabling tailored patient-centered care and prevention strategies.

EP567 Topical octenidine-based hydrogel as an effective alternative in a newborn with junctional epidermolysis bullosa and hypersensitivity to other antimicrobials: A case report

Cecilia Valles Quintilla[1], Pilar Ibars Moncasi[1], Silvia Bravo Pons[1], Núria Elena Alba Miro[1], Laura Puig Garcia[1], Xavier Bringue Espuny[1], Maria Rosa Gonzalez Farre[1]

[1]Hospital Universitari Arnau De Vilanova, LLEIDA, Spain

Aim: Newborns with Junctional Epidermolysis Bullosa (JEB) require frequent wound hygiene to reduce microbial burden while avoiding irritation of fragile skin. This case aimed to evaluate the safety, tolerance, and clinical response of a topical octenidine-based hydrogel as an alternative antimicrobial in an infant who developed hypersensitivity to other topical agents.

Method: A retrospective clinical assessment was conducted in a 2-month-old infant with JEB presenting with a 2 × 1.5 cm wound on the right hand. The lesion displayed exposed dermis, moderate-to-abundant serous or serosanguineous exudate, and periwound alterations including dry residues and milium cysts. Pain intensity was recorded as 5/10 using the LLANTO scale. A thin layer of octenidine-based hydrogel (<1 ml) was applied to the wound bed once daily and covered with a permeable foam dressing and cohesive bandage. Dressing changes and clinical evolution including exudate level, wound-bed quality, periwound condition, epithelialization, and tolerance were documented.

Results / Discussion: After 24 hours, the wound demonstrated reduced exudate, disappearance of the suspected biofilm, absence of bleeding, and improved periwound skin without erythema or maceration. Partial resolution of milium cysts was also noted. Complete epithelialization occurred after seven consecutive daily applications. No local adverse reactions were observed. Caregiver and clinical observations indicated improved tolerance compared with

previously used topical antimicrobials, as the infant showed no signs of distress during application, facilitating daily wound care.

Conclusion: Topical octenidine-based hydrogel demonstrated excellent tolerance and rapid epithelialization in a newborn with JEB and hypersensitivity to other antimicrobial agents. It represents a safe and effective alternative for use in fragile-skin pediatric wounds, supporting its role as part of a gentle and evidence-based wound care strategy.

EP568 Wound healing with electrospinnig in a rare case of lymphangioma

Müge Sert[1], Alperen Pala[1], Gaye Filinte[2]

[1]Kartal Dr.Lütfi Kırdar City Hospital, Istanbul, Türkiye, *[2]University of Health Sciences, Kartal Dr. Lütfi Kırdar City Hospital, Istanbul, Türkiye*

Aim: To highlight the potential role of advanced wound-healing technologies in patients with complex lymphatic anomalies.

Method: A 14-year-old male patient with a history of congenital lymphangioma involving the right forearm and hand presented with chronic lymphedema and recurrent pain. The patient underwent his first surgical intervention at the age of 2, followed by multiple debulking procedures over the years. After his most recent surgery, he developed a 2×1 cm wound dehiscence at the surgical site on the forearm. Initial management with conventional wound dressings was unsuccessful, and the wound enlarged rapidly.

A split-thickness skin graft was applied to the defect; however, the graft failed due to elevated compartmental pressure from chronic lymphedema. A second grafting attempt three months later resulted in a similar outcome. Given the repeated failures and persistent wound defect, an electrospun nanofibrous matrix was applied. The matrix was used twice during the course of treatment. Within one month, the wound completely epithelialized with no signs of infection, inflammation, or further dehiscence.

Results / Discussion: Patients with congenital lymphangioma often experience chronic lymphatic stasis, leading to impaired wound healing. In this case, graft applications were unsuccessful due to increased pressure within the wound bed. Because electrospun nanofibers mimic the extracellular matrix and support cell adhesion, migration, and neovascularization, this technology facilitated complete closure of the defect.

Conclusion: Electrospun nanofibrous matrix application enabled complete epithelialization and wound healing in a pediatric patient with congenital lymphangioma and recurrent graft failure. This approach may serve as an alternative method for managing difficult-to-treat wounds associated with chronic lymphedema.





EP569 Brazilian podiatry science, technique and sensitivity in the integral care of diabetic foot

Natalia Santos[1], Elizabet Afonso[1], Juliana Lucinda dos Santos[2]

[1]Podoonic Podologia Avançada, Nova Serrana, Minas Gerais, Brazil, [2]Prime Care Cuidados Integrados a Feridas, Santo Andre, Sao Paulo, Brazil

Aim: The practice of podiatry in Brazil is governed by specific legislation recognizing podologists as professionals trained to assess, prevent, and treat low- and medium-complexity podiatric conditions. To describe the evolution of a deep grade 2 plantar lesion in a diabetic patient, triggered by hypersensitivity to Lonomia obliqua and aggravated by corticosteroid use.

Method: This descriptive experience-report was conducted in a private clinic in Minas Gerais, Brazil. The patient, a 61-year-old man with type 2 diabetes, presented with bullous ischemia on the medial plantar region after contact with Lonomia obliqua, progressing to a deep ulcer with purulent exudate, hyperkeratosis, slough, edema, erythema, and peripheral neuropathy to the 10 g monofilament. The protocol, antibiotics,ded serial clinical evaluations, photodynamic therapy (PDT), advanced dressings, pressure offloading with felt and complementary ILIB application. Follow-up spanned nine weeks, with clinical and photographic documentation.

Results / Discussion: At the initial visit 09/24/2025, the patient exhibited significant claudication, intense pain, cane aid for walking, and functional limitation. The lesion showed hyperkeratosis, slough, and purulent exudate. Treatment included cleansing with PHMB, PDT (9 J centrally, 1 J peripherally), silver hydrofiber dressings, pressure offloading, and ILIB for 20 minutes per session. Visits were initially every 72h, then spaced to three and seven days.

Conclusion: Progressive improvement was observed, reduced pain, exudate, edema, and erythema, as well as tissue regeneration, inflammatory modulation, and functional recovery. Advanced dressings maintained an ideal moist environment, and PDT accelerated healing. ILIB provided complementary benefit. This case underscores the effectiveness of Brazilian podiatry, demonstrating that a combination of dynamic phototherapy, advanced dressings, and specialized pressure management can successfully treat complex plantar lesions in diabetic patients.

EP570 Application of the "Four-Dimensional Holistic Care" concept in nursing care for patients with advanced breast cancer complicated by extensive wound

Yi Wang[1], Jie Zeng[1]

[1]Da Hua Hospital, Shang Hai, China

Aim: To explore the effect of "Four-Dimensional Holistic Care" (physical, psychological, social, spiritual) in managing an 80-year-old female with advanced breast cancer and an extensive wound, aiming to improve comfort, support dignified end-of-life care, and provide insights for cancerous wound palliative care.

Method: A case management approach was adopted, with care delivered across four dimensions tailored to the patient's condition:

Physical Care: For massive exudation, alginate silver dressings combined with foam dressings were used to control exudate and prevent infection. For wound malodor, metronidazole solution was administered for wound irrigation; post-routine dressing change, IV3000 film was applied to seal odor and alleviate disease-related stigma. Additionally, the waterproof property of IV3000 allowed the patient to bathe daily prior to dressing changes, improving comfort. To address the high bleeding risk of cancerous wounds, autolytic debridement combined with normal saline irrigation was utilized to minimize mechanical trauma. Others: WHO three-step analgesia + adjuvant therapies; enteral nutrition plan; lymphedema specialist-led drainage/compression.

Psychological intervention: Empathetic communication to build trust and alleviate depression. Social support: Family education for care participation and encouraging relatives' visits.

Spiritual care: Life review, wish fulfillment, and religious belief support.

Results / Discussion: Wound exudation/dressing changes reduced (2→1 time/day), odor (Grocott Scale 0→4) and pain (VAS 6→3) improved; no uncontrollable bleeding. Patient gained 1kg, edema stabilized; GDS-15 score dropped (14→8). Family shifted from avoidance to care participation. The patient passed away peacefully in comfort and dignity, with both patient and family satisfied.

Conclusion: Four-Dimensional Holistic Care effectively improves clinical symptoms and quality of life for patients with advanced cancerous wounds, supports dignified death, and is widely recognized.

EP571 Minimally invasive management of calcaneal and cuboid osteomyelitis using suction Curettage Bone Harvester and absorbable antibiotic beabs: A case study

Leslie Owusu[1], Lady Paula Dejesus[2]

[1]Yale New Haven Health Bridgeport Hospital, Bridgeport, United States, *[2]Yale New Haven Health Greenwich Hospital, Greenwich, United States*

Aim: Chronic foot ulcers complicated by osteomyelitis are difficult to manage and often risk progression to limb loss. Traditional open debridement may result in prolonged healing and increased morbidity. Minimally invasive suction curettage with Bone Harvester allows for targeted removal of infected bone while preserving healthy tissue. Adjunctive use of local antibiotic delivery can further optimize infection control.

Method: A 55-year-old male presented with a chronic ulcer on the left foot with suspected osteomyelitis of the calcaneus and cuboid. The ulcer measured 0.5 × 1.5 × 2.0 cm (surface area 0.75 cm^2) at presentation. The patient underwent minimally invasive suction curettage of the calcaneus and cuboid using Bone Harvester. Intraoperatively, absorbable antibiotic beads were constructed and loaded with 500 mg of vancomycin powder and 40 mg of tobramycin, which were placed directly into the debrided calcaneus and cuboid cavities to achieve high local antibiotic concentrations.

Results / Discussion: The postoperative course was uneventful, with progressive wound healing and resolution of infection. One month postoperatively, the wound size had decreased to 0.1 × 0.1 × 0.1 cm (surface area 0.01 cm^2), demonstrating near-complete closure.

Conclusion: This case demonstrates the efficacy of a minimally invasive approach to pedal osteomyelitis using Suction Curettage Bone Harvester combined with locally delivered antibiotics. The technique provided excellent infection control, promoted rapid wound healing, and minimized soft tissue disruption. This approach represents a promising limb-salvage option for patients with localized osteomyelitis of the foot.

EP573 Pediatric facial burn scar: case report

Tânia Manuel[1], Sara Filipa Brandão Pereira[1], Beatriz Manuela Azevedo Costa[1], Nuno Miguel Mendes Pinto[1]

[1]*Clínica Nuno Mendes, Penafiel, Portugal*

Aim: To describe the therapeutic approach and clinical evolution of a pediatric facial and truncal burn treated with LED phototherapy and topical silicone, highlighting the importance of treatment adherence for favorable scar outcomes.

Method: Case report of a 3-year-old female patient, with no relevant medical history, first evaluated on 25 November 2023 for a thermal burn caused by hot oil on 29 October 2023, affecting the right side of the face, right ear and trunk. At the initial assessment, the burn was in an inflammatory phase, with marked erythema and warmth, and the patient was using protective repair cream twice daily and sunscreen in the morning. Skin asepsis was performed, followed by application of a 633 nm LED mask and topical silicone.

Results / Discussion: To date, 11 treatment sessions have been performed, with very positive evolution, absence of inflammatory signs and a marked reduction in scar elevation. Despite limited initial collaboration, with frequent removal of the silicone and refusal of additional techniques beyond the LED mask and rotary brush, the minimum continuity of the treatment plan allowed favorable modulation of the scarring process, suggesting a benefit of combining phototherapy and silicone even in a context of partial adherence.

Conclusion: Phototherapy and silicone show potential in inflammatory modulation and reduction of scar elevation in pediatric burns, contributing to a better aesthetic and functional prognosis. Treatment adherence remains crucial for therapeutic success, especially in pediatric patients, underscoring the need for specific education strategies and active family involvement.

EP574 Contralateral recurrence of myroides odoratimimus necrotising infection in a diabetic foot: From amputation to limb salvage with instillation NPWT

Bianca Vicari[1], Marco Marcianò[1], Renato Di Vuolo[1], Isabella Campo[1], Paolina Venturelli[1], Valentina Lombardo[1], Riccardo Salzillo[1], Giovanni Guercio[1]

[1]*AOUP Paolo Giaccone, UNIPA, Università Degli Studi di Palermo, Palermo, Italy*

Aim: Throughout this case, we aim to alert the wound care community to the clinical relevance of multidrug-resistant *Myroides odoratimimus* as a cause of rapidly progressive necrotising fasciitis in diabetic foot with severe consequences. We present a case where this pathogen first led to amputation of the affected foot and later caused a contralateral necrotising infection that, once recognised early and treated appropriately, was successfully salvaged.

Method: A 58-year-old man with long-standing type 2 diabetes, neuropathy and peripheral arterial disease initially presented with a fulminant necrotising infection of the right plantar foot. Despite multidisciplinary management, the extent of destruction ultimately required amputation of the first affected limb. Months later, he re-presented with a rapidly evolving necrotising infection of the contralateral plantar foot. Deep tissue cultures again isolated *M. odoratimimus* with an identical resistance profile. Within hours, the multidisciplinary team performed wide “skin-sacrificing” debridement followed by negative pressure wound therapy with instillation (NPWTi) of hypochlorous acid solution (Granudacyn), strict offloading and targeted systemic antibiotics.

Results / Discussion: In contrast to the first episode ending in amputation, the second limb was preserved. Early aggressive surgery combined with NPWTi rapidly controlled bioburden, produced a clean, granulating wound bed and avoided major amputation. The patient recovered a plantigrade, shoeable foot and independent ambulation, with no further recurrences at follow-up.

Conclusion: *Myroides odoratimimus* is an emerging, water-associated pathogen capable of causing devastating, even bilateral, necrotising infections in diabetic feet. Timely recognition, radical debridement, NPWTi with hypochlorous acid, strict offloading and tailored antibiotics are essential to move the outcome curve from amputation toward limb salvage and should be more widely recognised within the wound care community.

EP575 Wound cleansing with an absorption mechanism-based wound dressing and autolytic debridement: A case series

Derya Karakaya[1], Şenay Gül[2], Emine Sezgünsay[3]

[1]Pursaklar State Hospital, Ankara, Türkiye, *[2]Hacettepe University, Ankara, Türkiye*, *[3]Izmir Economy University, Ankara, Türkiye*

Aim: The aim of this study is to present three cases in which we observed the positive effect of a wound dressing with a wound-cleaning absorption mechanism on patients with cavitary, infected, exudative pressure injuries.

Methods: Consecutive patients treated with a Hydro-Responsive Wound Dressing were prospectively followed up, and wound healing parameters and the autolytic debridement process were recorded. Informed consent was obtained from all patients included in the study, and clinical data were collected using a standardized assessment form.

Results / Discussion: Case 1 was an 81-year-old female patient. Initial assessment showed incontinence-associated dermatitis and an unstageable pressure injury measuring 25 × 20 cm. Following surgical debridement, the wound was clearly assessed as Stage 4, with dimensions of 25 × 20 × 6 cm. Hydro-Responsive Wound Dressing was placed on the wound surface. Healing was achieved after the 14th dressing change.

Case 2 was an 89-year-old male patient. Initial assessment revealed a 20x18 cm unsatgeable pressure injury, with the wound edges identified as macerated. Hydro-Responsive Wound Dressing was placed on the wound surface. Healing was achieved after the 8th dressing change, with dressing changes performed every 3 days.

Case 3 was a 42-year-old male patient. He had a stage 4 pressure injury measuring 7x22x4 cm, with a 22 cm tunneled sacral exit from the right ischium at the initial evaluation. Hydro-Responsive Wound Dressing was applied to the tunnel and necrotic area. Subsequent dressings were changed every 3 days. Healing was completed after the 11th dressing.

Conclusion: The Hydro-Responsive Wound Dressing was observed to have a healing effect on cavitated, infected, exudative wounds.

EP576 Transferring a simplified wound care strategy across contexts: From Madrid to Burundi

Joachim Ciza[1], Bernard Ntahindiriye1982@gmail.com[1], Begoña de Santiago[2], Verónica Couso[3], Elena Conde Montero[3], Ricardo Ruiz[3]

[1]Hospital Ngozi, Ngozi, Burundi, *[2]Facultad de Medicina Universidad Complutense de Madrid, Madrid, Spain*, *[3]Clínica Dermatológica Internacional, Madrid, Spain*

Aim: To evaluate the effectiveness of a simple, low-cost approach combining zinc oxide lotion, alginate dressings and individually adapted compression therapy for managing lower-limb wounds of two main etiologies - post-traumatic wounds and venous leg ulcers **-** in a low-resource setting in Burundi.

Method: Six patients were treated with zinc oxide lotion applied directly to the wound bed for its anti-inflammatory, astringent and protective effects, followed by alginate dressings for moisture and exudate control. Compression therapy was added adjusting pressure to vascular status and tolerance.

All materials were donated, conditioning availability and follow-up. Importantly, wounds were not cleansed at each dressing change. Clinical and photographic follow-up was performed over three weeks.

Results / Discussion: Across both etiologies, the combination of zinc oxide lotion, alginate and adapted compression rapidly improved the wound microenvironment. Zinc oxide reduced inflammation and stabilized fragile tissue, while alginate provided consistent exudate management. Compression accelerated edema reduction.

Weekly dressing changes were sufficient - crucial in contexts where materials and clinical time are limited. Despite minimal manipulation and absence of routine cleansing, no cases of superinfection were observed. All wounds

progressed with increased granulation and earlier epithelial advancement.

The main limitation was the restricted amount of donated supplies, which limited long-term follow-up.

Conclusion: In Burundi, a treatment strategy based on zinc oxide lotion, alginate dressings, minimal wound manipulation and patient-adapted compression proved safe, practical and clinically effective for post-traumatic wounds and venous leg ulcers. Its reproducibility in Madrid and increasing dissemination in Europe support its value as a scalable, efficient model for global wound care.

EP578 From major amputation to limb salvage: Tropical lucilia cuprina free-range maggot debridement therapy in diabetic foot ulcers

Dr. Mohd Zurairie Mohd Zubir[1]

[1]*Monash University Malaysia, Bandar Sunway, Malaysia*

Aim: To report limb-salvage outcomes in five patients with diabetic foot ulcers (DFU) who were listed for below-knee amputation (BKA) but underwent free-range maggot debridement therapy (MDT) using Tropical Lucilia cuprina larvae, and to contextualise effectiveness relative to the widely used L. sericata literature.

Method: Five adults with advanced infected DFU and multidisciplinary BKA indication declined amputation and consented to MDT with sterile free-range L. cuprina. Larvae were applied to devitalised tissue and covered with a porous secondary dressing for 48–72 hours per cycle, alongside standard care including appropriate systemic antibiotics, offloading and metabolic optimisation. Outcomes included number of MDT cycles, reduction in non-viable tissue, infection control, time to granulation readiness and avoidance of major amputation. Application parameters and endpoints were aligned with published MDT protocols.

Results / Discussion: All cases showed rapid slough and necrosis reduction within three to four cycles, with clear demarcation enabling conservative sharp debridement where required. All five limbs were salvaged without major amputation, progressing to healthy granulation with infection control and closure by secondary intention, pain was manageable and no systemic adverse events were observed. These outcomes accord with evidence that L. cuprina MDT achieves effective debridement and healing endpoints in DFU, including high rates of near-complete debridement and clinical tolerability.

Conclusion: Free-range L. cuprina MDT functioned as an effective initial debridement and infection-control strategy, enabling limb preservation in patients otherwise listed for BKA. When interpreted alongside comparative and prospective data, these findings support L. cuprina MDT as a clinically effective alternative to the more commonly used L. sericata, delivering comparable benefits in debridement and limb salvage in DFU care.

EP579 Use of polylactic acid membranes as treatment for facial burns in adult patients

Ana Lorena Novoa-Moreno[1], Mario Aurelio Martínez-Jimenez[2], Victor Loza-González[3], Eleazar Samuel Kolosovas-Machuca[5], Jose Ramirez-Garcialuna[4]

[1]*Medicine Faculty of the Autonomous University of San Luis Potosí, San Luis Potosí, Mexico*, [2]*Burn Unit of the High Specialty Regional Hospital "Ignacio Morones Prieto", San Luis Potosí, Mexico*, [3]*Institutional Doctorate of Engineering and Materials Science of the Autonomous University of San Luis Potosí, San Luis Potosi, Mexico*, [4]*Division of Experimental Surgery, Faculty of Medicine, McGill University, Montreal, QC, Canada*, [5]*Coordination for the Innovation and Application of Science and Technology (CIACYT), Autonomous University of San Luis Potosí, San Luis Potosí, Mexico*

Aim: To present clinical outcomes of polylactic acid (PLA) membranes as an alternative treatment for superficial partial-thickness facial burns.

Methods: A case series was conducted including four patients admitted to our burn unit with superficial second-degree facial burns of diverse etiologies, including direct flame, scald, and chemical injury. All patients underwent surgical debridement followed by application of a PLA membrane without adjunct dressings. Patients were monitored during hospitalization and through outpatient follow-up until complete re-epithelialization.

Results: PLA membranes demonstrated consistent adherence to the wound bed and maintained stable coverage throughout the healing process. The absence of secondary dressings eliminated the need for repeated dressing changes, reducing discomfort and facilitating earlier discharge when appropriate. Progressive transparency of the membrane allowed continuous visual assessment of epithelialization, supporting timely clinical decision-making. Membrane separation occurred spontaneously upon completion of healing. No complications were observed, including infection, delayed closure, or hypertrophic scarring. All patients achieved rapid recovery with favorable cosmetic outcomes, characterized by smooth, nearly normal-appearing skin at the end of follow-up.

Conclusion: PLA membranes provide a viable and effective option for managing superficial partial-thickness facial burns. Their stable adherence, absence of dressing-change requirements, and favorable clinical and aesthetic outcomes support their incorporation into treatment algorithms for facial burn care.

EP580 Use of collagen-based extracellular matrix (ECM) derived from ovine forestomach submucosa in facial burn: Case report

Leonardo Cardoso[1], Francisco Silva Junior[2], Priscilla Sckarlat[3], Pedro Henrique Malagoli[3]

[1]Hospital e Maternidade São Cristóvão, São Paulo, Brazil, *[2]Universidade Federal do Ceará, Fortaleza, Brazil*, *[3]UNIREGEN Teaching And Research Institute Ltd., Brasília, Brazil*

Aim: To describe the clinical evolution of a deep facial burn treated with an extracellular matrix (ECM) bio-scaffold derived from ovine forestomach submucosa, emphasizing its role in inflammatory modulation, structural support, and progressive healing.

Methods: This descriptive case report followed an adult patient who sustained a full-thickness thermal burn to the face, including the left periocular region. The patient was initially treated in an emergency department and transferred to a tertiary hospital in São Paulo. During hospitalization, the injury progressed with extensive necrosis, requiring multiple surgical debridements, enucleation of the left eye, and local skin grafting. The grafted area evolved with necrosis, necessitating additional surgical interventions and sessions of hyperbaric oxygen therapy.

After hospital discharge, the patient continued outpatient follow-up. On May 14, the wound showed a residual area of 8.85 cm^2 with viable bright-red tissue, moderate serous exudate, irregular borders, and intact perilesional skin. Regenerative therapy using an ECM bio-scaffold was initiated, applied directly to the wound bed and covered with a non-adherent secondary dressing. Wound progression was monitored through serial measurements, photographic documentation, and standardized assessments. Reapplication was performed only when irregular bio-scaffold degradation was observed.

Results: The wound demonstrated consistent improvement over 11 weeks: 8.2 cm^2 (week 1), 7.4 cm^2 (week 3), 5.9 cm^2 (week 5), and 3.6 cm^2 (week 10), culminating in complete epithelialization by week 11. The bio-scaffold supported granulation, maintained a favorable wound environment, reduced pain during dressing changes, and showed no infection or adverse reactions.

Conclusion: The ECM bio-scaffold proved effective in managing this complex deep facial burn, promoting sustained healing despite previous surgical failure and significant clinical complications.



EP581 Management of wound dehiscence using tension-reduction suture and closed incision negative pressure wound therapy

Ardea Perdanakusuma[1], David Perdanakusuma[1]

[1]Department of Plastic, Reconstructive and Aesthetic Surgery, Faculty of Medicine, Universitas Airlangga, Indonesia, Surabaya, Indonesia

Aim: To present the effectiveness of a combination excision, tension-reduction suture, and the application of closed-incision Negative Pressure Wound Therapy (ciNPWT) in the management of chest wound dehiscence.

Method: A 19-year-old female patient with post-mediastinal tumor excision developed postoperative wound dehiscence, resulting in a non-healing wound for over one month. Debridement, excision and wound closure were performed using a tension-reduction suture technique. After wound closure, ciNPWT was applied over the incision line with continuous pressure of 125 mmHg and maintained for 7 days postoperative.

Results / Discussion: The operative procedure and postoperative care has been shown to be clinically effective. After 7 days, the surgical incision appeared clean and well-approximated, with minimal oedema. At the 21-day and 3-month follow-up evaluations, the scar demonstrated a good structural integrity with a stable, and cosmetically favorable appearance. No clinical evidence of recurrent dehiscence demonstrating appropriate progression of wound healing. The clinical success achieved from the tension-reduction suture technique, which allowed even distribution of mechanical forces across multiple tissue layers, including the deep, superficial fascia and dermal subdermal suture. The application of ciNPWT provided external anti-tension support that effectively reduced strain on the wound edges.

Conclusion: The combination of tension-reduction suture and application of ciNPWT represents a highly effective and promising management strategy for wound dehiscence. This multimodal approach successfully addresses tensile forces identified as key contributors to dehiscence, thereby preventing recurrence of wound dehiscence after repair. This strategy may represent a valuable management option for cases of dehiscence or high-risk potential of dehiscence in relatively tense suture wound areas.

EP582 Treatment of diabetic foot osteomyelitis using antibacterial bioactive glass (S53P4) and platelet-rich plasma: Clinical outcome of an advanced regenerative approach

Priscilla Sckarlat[1], Pedro Henrique Malagoli[1], Erika Fernandes[2], Ana Paula dos Santos Albuquerque[3], Cristiano Ricardo Teixeira[2], Mario Soares Ferreira Júnior[2]

[1]UNIREGEN Teaching and Research Institute Ltd., Brasília, Brazil, [2]AKHOS Specialized Medicine, Brasília, Brazil, [3]Hospital Regional do Agreste, Caruaru, Brazil

Aim: To present the clinical outcome of a multidisciplinary regenerative strategy integrating antibacterial bioactive glass (S53P4) and Platelet-Rich Plasma (PRP) as adjuncts to surgical management of complex diabetic foot osteomyelitis at high risk of major amputation.

Methods: A male patient with decompensated diabetes and peripheral neuropathy, developed a right-foot injury after glass penetration, initially unnoticed due to sensory loss. Progressive tissue damage and inadequate topical care resulted in osteomyelitis involving the metatarsal head and proximal phalanx (Image 1), with an initial indication for transmetatarsal amputation. After evaluation in a specialized orthopedic infection service (Image 2), the therapeutic plan included extensive debridement, osteotomy of infected bone, defect filling with bioactive glass and PRP application to soft tissues (Image 3). Postoperative care consisted of advanced wound management performed by specialized clinicians and low-level laser therapy to support tissue repair.

Results: The combined surgical and regenerative strategy enabled early infection control without postoperative complications. Within seven days (Image 4), the wound showed marked reduction of inflammatory signs, substantial granulation tissue formation, and progressive closure. At eight months (Image 5), complete resolution of bone and soft-tissue infection was confirmed. Limb function was preserved, with independent ambulation and absence of pain, deformity, or functional limitation. The patient resumed daily activities without restrictions.

Conclusion: The integration of antibacterial bioactive glass (S53P4) with autologous regenerative therapy contributed to inflammation modulation, enhanced healing dynamics, and effective control of complex diabetic foot infection. The favorable outcome highlights the potential of this combined strategy to prevent major amputation and maintain long-term function. This case reinforces evidence that multidisciplinary, biologically oriented interventions may offer effective limb-preserving options for severe diabetic foot conditions requiring advanced therapeutic approaches.

Image 1



Image 2



Image 3



Image 4



Image 5



EP583 Avoiding surgery in a high-risk patient: Conservative healing of a stage IV pressure ulcer with enzyme alginogel therapy

Serdar Terzioglu[1], Kubra Bilge Polat[1], Fatma Betul Ozguven[1], Mehmet Ozer[1]

[1]Ankara Bilkent City Hospital, Ankara, Türkiye

Aim: Pressure ulcers in immobilized and medically fragile patients are often managed surgically, although perioperative risk may outweigh the expected benefit. The aim of this case is to demonstrate that conservative wound care using an enzymatic alginogel can promote healing and prevent unnecessary surgery in a Stage IV pressure ulcer in a high-risk patient.

Method: A 77-year-old bed-bound patient with diabetes, cardiac disease and hypoalbuminemia developed a Stage IV sacral pressure ulcer. The treatment was initiated with surgical debridement and diverting colostomy was performed at the same session. Due to multiple comorbidities and high surgical risk, conservative treatment was chosen over surgical closure. Wound management was initiated with enzyme alginogel dressings to enable biofilm control, complex debridement, exudate balance, and granulation. Daily dressings were performed initially, then continued alternate days after fibrin burden reduction.

Results / Discussion: Over the first weeks, necrotic tissue markedly decreased, and healthy granulation tissue developed without surgical intervention. Wound size progressively reduced, epithelization was established, and no infection, hospitalization, or systemic complication occurred. Throughout the course, conservative treatment was well tolerated, and no further surgical intervention was required.

Conclusion: This case demonstrates that conservative enzymatic dressing therapy can be an effective alternative to surgery in selected high-risk patients with Stage IV pressure ulcers. Enzyme alginogel based wound care supported debridement, maintained moisture balance, and promoted healing while avoiding surgical complications. Advanced dressing-centered management may prevent unnecessary surgery in medically fragile patients.

EP585 Use of indirect, 3D, cold atmospheric plasma-aerosol in severe acne – A case report

Preben Joffe[1], Mette Kilsgaard[1], Robert Fuchs[2]

[1]PlasmoClean Test Center, Copenhagen, Denmark, *[2]WK-MedTec GmbH, Bückeburg, Germany*

Aim: We describe the use of indirect, 3-dimentional Cold Atmospheric Plasma-Aerosol (CAP-A) in a patient with multiple papules, pustules, noduli and cysts associated with pain, hyperpigmentation, scares and facial appearance affecting quality of life due to acne vulgaris. The patient had the last 10 years been treated with topical and systematic modalities including courses of antibiotics and isotretinoin with limited effect. CAP-A was chosen as a non-invasive, non-pharmacological therapeutic approach due to its reactive oxygen species with antimicrobial, anti-inflammatory, and tissue-regenerative effects.

Method: CAP-A was applied 3-7 cm from affected skin 3 times weekly for two weeks (each session 3 minutes at both cheeks and forehead). Due to partly effect the patient was switched to self-treatment 3 times daily (3 minutes sessions) for additional 3 consecutive days successfully. A relapse was seen 4.5 months and CAP-A twice daily (3 minutes of the 3 anatomic areas for two weeks) was restarted as self-treatment. Moreover, CAP-A was used for additional two weeks, 3 times daily until all elements of acne vulgaris were erased.

Results / Discussion: CAP-A resulted in complete cessation of acne vulgaris except preexisting scars following 17 days of therapy. This effect lasting for 4.5 months when a new episode of severe acne was seen. Renewed application of CAP-A for 4 weeks resulted in complete normalisation of facial skin for the last 1.5 year.

Conclusion: This seems to be the first documented case of acne vulgaris successfully treated with CAP-A. The result indicates that this approach offers a safe, effective, non-pharmacological, and cost-effective therapy as an alternative for conventional yearlong treatment.

EP412 Bioactive membrane enables complete healing of complex chronic ulcer

Camila Moraes[1], Dioney Neves[2], Camila Safranski[2]

[1]*Dra Camila Mendonca - Enfermagem Avancada, guaxupé, Brazil*, [2]*Missner, Blumenau, Brazil*

Aim: To report the clinical and functional evolution after incorporation of a bioactive membrane into the management of a complex leg ulcer within a global therapeutic strategy.

Method: A 65-year-old woman presented with a 10-year history of a 14 × 11 cm distal right leg ulcer associated with arterial occlusion and concomitant venous insufficiency. Baseline assessment showed irregular margins, hyperemia, rigid biofilm, severe persistent pain (Numeric Rating Scale [NRS]: 10/10), and marked functional limitation (Barthel Index: 45/100). The patient also had multiple drug allergies related to prolonged analgesic and anti-inflammatory use.

Results / Discussion: During three months, a stable multimodal regimen was maintained, including medication optimization, targeted nutritional support, atraumatic cleansing with polyhexamide foam, and topical ozonetherapy (60 mcg/20 min). Gradual wound progression was observed; however, persistent severe pain compromises adequate debridement, also patient mobility, and adherence to the treatment. A biocompatible, moisture-retentive, flexible, non-adherent bioactive membrane was incorporated to improve microenvironment stability and mechanical protection. Dressings were changed every three days. After incorporation, pain decreased to NRS 2/10, biofilm removal became easier, and complete granulation coverage was achieved within four weeks. Pain reduction enabled ambulation, improved comfort, and greater therapeutic adherence. Functional status improved to 95/100, and full epithelialization occurred at four months.

Conclusion: In this case, incorporation of a bioactive membrane within a multimodal strategy was associated with substantial pain reduction, functional recovery, and accelerated tissue repair. Although healing was multifactorial, pain modulation after membrane introduction appeared to represent a clinical turning point. Controlled clinical studies are necessary.

EP586 Comprehensive approach to complex skin infection in a patient with systemic sclerosis: case report

Maria Graciana Algorta[1]

[1]*Hospital Paysandu, Paysandu, Uruguay*

Aim: To describe the evolution and management of advanced wound care in a patient with untreated systemic sclerosis (SSc) and a severe skin and soft tissue infection in the right lower limb (RLL).

Method: A descriptive analysis was performed of a clinical case of soft tissue and skin infection in the RLL in the context of systemic sclerosis. A 49-year-old woman with long-standing untreated SSc, without follow-up, consulted for ulcerated lesions in the RLL that had developed over four days. The ulcerated lesion was erythematous, with blisters, oedema and heat. It was located on the dorsum and sides of the foot and on the anterior aspect of the leg, extending up to the upper third of the leg. Pedal and posterior tibial pulses were present. No fever or local pain. She was admitted to the intensive care unit and then completed her treatment at home.

Results / Discussion: She presented with a marked inflammatory reaction and skin involvement in the MID. Vascular studies showed arterial and venous permeability. A local treatment plan for the MID was implemented. Autolytic debridement of devitalized tissue. Mechanical drainage of blisters. Wet healing using hydrogels and gauze with water-soluble glycolic excipients and perilesional skin with zinc oxide. The regression of the oedema and signs of flux progressed to necrosis on the dorsum of the foot, requiring surgical debridement requiring surgical, autolytic, and enzymatic debridement. This achieves granulation of the wound bed.

Conclusion: Systemic sclerosis increases susceptibility to serious infections and hinders healing. This case provides evidence of how moist wound therapy, selective debridement, and multidisciplinary management achieved beneficial progression tailored to this patient without adherence to treatments.

EP587 Dermal needle aspiration culture (DNAC) and quantitative culture biopsy (QCB) of skin in the diagnosis of infection in complex wounds guided by fluorescence

Adriana Dell Aquila[1 2], Sergio Tiossi[3], Juliana Maeda[2], Douglas Paggi[4], Alexandre Inacio Cruz de Paula[4], Neusa Valente[4 5], Paula Nogueira[2], Vera Lucia Conceição Gouveia Santos[2]

[1]Department of Infectious Diseases of Instituto de Assistência Médica ao Servidor Público Estadual (IAMSPE) - Hospital do Servidor Público Estadual (HSPE), Sao Paulo, Brazil, *[2]Escola de Enfermagem da Universidade de São Paulo, São Paulo, Brazil*, *[3]Department of Vascular Surgery of Instituto de Assistência Médica ao Servidor Público Estadual (IAMSPE) - Hospital do Servidor Público Estadual (HSPE), Sao Paulo, Brazil*, *[4]Instituto de Assistência Médica ao Servidor Público Estadual (IAMSPE) - Hospital do Servidor Público Estadual (HSPE), Sao Paulo, Brazil*, *[5]Hospital das Clínicas da Faculdade de Medicina da Universidade de São Paulo (HCFM USP), Sao Paulo, Brazil*

Aim: Demonstrate dermal needle aspiration culture (DNAC) and quantitative culture biopsy (QCB) as methods for wound infection.

Method: Report a case series as a pilot study of the accuracy of DNAC.

Results / Discussion: Eight patients with chronic wounds were submitted to DNAC and QCB. Patients enrolled in the study were assessed for wound microbial load using a camera, which emits violet light, allowing microorganisms to be identified by their fluorescence. Additionally, the fluorescence of a 100-LED, 395nm Violet Light UV Flashlight was assessed to assess the fluorescence agreement between the two instruments. Half male (4 - 50%) and half female (4 - 50%); Minimum age of 46, maximum of 78 years, with an average of 65 years (SD:12); 87.5% with venous insufficiency, 75% with arterial hypertension, 62.5% diabetic, 25% with bone infection, 12.5% with positive Probe-to-Bone and 12.5% paraplegia. 100% Sensitivity; 83,3% Specificity; 87,5% Accuracy; 66,67% Precision; 66,7% Positive Predictive Value and 100% Negative Predictive Value. Among the eight patients, three with negative cultures, five with positive cultures, with only one *Staphylococcus aureus* and four with gram-negative bacilli – *Enterobacter cloacae*, *Serratia marcescens*, *Pseudomonas aeruginosa* and *Proteus* spp.

Conclusion: DNAC seems to have high sensitivity and specificity in Pilot Study. It is possible to find the agreement between two fluorescence light devices in the assessment of infected complex wounds. In the positive fluorescence, QCB is necessary when no sign of infection is present.

EP626 Wound bed preparation with a topical dehydrating agent followed by wool-derived keratin matrix xenograft in a hard-to-heal lower-extremity diabetic ulcer: A case from the Kingdom of Tonga

William Tettelbach[1 2 3], Nya Akoteu[4], Katrina-Anne Palu[4], Michelle Moore[5]

[1]Duke University School of Medicine, University of Health Science - Department of Podiatric Medicine, RestorixHealth, Durham, United States, *[2]Woodside Analytics, St. Petersburg, United States*, *[3]RestorixHealth, Metairie, United States*, *[4]Vaiola Hospital, Nukalofa, Tonga*, *[5]Kaleidoscope Clinical Consulting, Las Vegas, United States*

Aim: Lower extremity diabetic ulcers (LEDUs) are a common and morbid complication of diabetes, and infection-related complications can be especially burdensome in low-resource settings. This single clinical observation describes the treatment sequence and healing trajectory of a hard-to-heal LEDU managed with wound bed preparation using a topical dehydrating agent (TDA*) followed by serial application of a wool-derived keratin-based matrix (KBM†), alongside standard wound care.

Method: Care was provided in a hospital-based outpatient wound clinic in the Kingdom of Tonga. Prior to advanced intervention, the ulcer was treated for >30 days with standard dressings (alginate and normal saline) and selective sharp debridement without meaningful improvement. On 14/07/2025, a TDA containing methane sulfonic acid was applied for chemical debridement. On 17/07/2025, after surgical debridement to healthy bleeding tissue, a KBM xenograft moistened with stabilized hypochlorous acid solution was applied and tucked into undermined areas. A properly fitted offloading boot was initiated. Weekly visits included sharp debridement as needed, nutritional counselling emphasizing protein intake, and KBM re-application every 7–10 days.



Following basic cleaning of the wound and peri-wound area, the single-use vial of the TDA should be applied over the wound bed and one cm of the peri-wound skin. After being left in place for 60 seconds, the gel is diluted and removed by rinsing with saline or sterile water. After application, there is no specific requirement for dressings or other interventions, and these can be used at the clinician's discretion.



The wound base may have a caramelized appearance after removal of the dehydrating gel. The dehydrating agent is indicated for non-surgical debridement and treatment of hard-to-heal wounds that are infected and contain biofilm and/or necrotic tissue. Several contraindications apply, including ischemic wounds before effective revascularization; neoplastic wounds; underlying abscesses or fasciitis that requires incision/excision and drainage; underlying osteomyelitis; exposed cartilage and/or intolerance or allergies to any of the product ingredients.

Results / Discussion: After initiation of this sequence (with concurrent standard care), weekly assessments documented progressive granulation, reduced undermining, and epithelial advancement. Complete epithelialization was documented on 23/08/2025. Duration of advanced therapy was 48 days.



By 23/08/2025, the LEDU 100% epithelialized, successfully preserving the limb in a patient who had been at significant risk of amputation.

Conclusion: In this single case, wound bed preparation with TDA followed by serial KBM applications, delivered alongside standard wound care, was feasible in a resource-limited outpatient setting and was associated with healing to closure. Given the uncontrolled single-patient design, these observations are descriptive and hypothesis-generating. Causality and comparative effectiveness cannot be inferred. Prospective studies or comparative real-world cohorts are warranted to evaluate patient selection and incremental contribution beyond standard care components.

*TDA=DEBRICHEM, DEBx Medical, Amsterdam, Netherlands

†KBM=Keramatrix®, Biowound Solutions Inc., Las Vegas, NV, USA

EP588 Management of a multidrug-resistant acinetobacter baumannii infection in a post-amputation wound: A low-cost protocol using demerara sugar and povidone-iodine in primary care - case report from the “Love-for-the-Skin Project”

Adrize Rutz Porto[1], Lilian Rubira[2], Alejandro Martins Rodriguez[1]

[1]Federal University of Pelotas, Pelotas, Brazil, *[2]Municipal Government of Pelotas, Pelotas, Brazil*

Aim: To describe the clinical effectiveness of a low-cost topical protocol using demerara sugar and 10% povidone–iodine for the management of a post-amputation wound infected by carbapenemase-producing Acinetobacter baumannii in a Primary Health Care (PHC) setting with limited therapeutic resources.

Method: A case report was conducted within the “Amor-à-Pele” - “Love-for-the-Skin Project” - university outreach project in partnership with a PHC unit. A patient with type 2 diabetes and a recurrent lower-limb amputation presented with stalled healing, purulent exudate, and culture-confirmed multidrug-resistant A. baumannii. The intervention consisted of a sterile mixture of demerara sugar and 10% povidone-iodine applied twice daily for seven days. Clinical follow-up occurred three times per week, including photographic documentation and structured assessments of exudate, granulation, and infection markers.

Results / Discussion: The protocol led to a rapid and clinically relevant improvement. After one week, the wound exhibited substantial reduction of exudate, effective autolytic debridement, and development of robust granulation tissue. All local signs of infection regressed, and a control culture confirmed eradication of A. baumannii. The wound bed transitioned to a condition compatible with standard therapeutic options available in the Brazilian public health system. These findings reinforce the potential relevance of revisiting traditional, resource-appropriate wound care strategies in the context of antimicrobial resistance and PHC constraints.

Conclusion: This case highlights that a simple, inexpensive combination of demerara sugar and povidone-iodine may serve as a viable therapeutic alternative for managing multidrug-resistant wound infections in low-resource PHC environments. The intervention demonstrates the added value of university–PHC partnerships in integrating care, education, and practical innovation to address a growing public health challenge.

EP589 Use of autologous platelet-rich fibrin matrix associated with negative pressure wound therapy in a scalping injury

Priscilla Sckarlat[1], Kelvis Gabriel Soares[1], Pedro Henrique Malagoli[1]

[1]*UNIREGEN Teaching and Research Institute Ltd., Brasília, Brazil*

Aim: To describe the sequential application of Autologous Platelet-Rich Fibrin (PRF) combined with Negative Pressure Wound Therapy (NPWT) in the management of a large scalping injury, highlighting clinical outcomes and the potential synergistic effect between therapies.

Methods: This is a case report of a 17-year-old female patient with no comorbidities who sustained a traumatic scalping injury. Treatment was performed in the surgical setting of a public hospital in Brasília, Brazil, between December 2023 and January 2024. The therapeutic plan was developed jointly by the reconstructive surgery team and nurses specialized in regenerative therapies. A protocol of serial application of PRF megamembranes combined with NPWT was initiated on 12/21/23, with dressing changes performed on 12/28/23, 01/04/24, and 01/09/24. On 01/18/24, a split-thickness skin graft harvested from the right thigh was performed, along with an additional application of PRF to both the recipient site and part of the donor area.

Results: Rapid granulation tissue formation and progressive reduction of exudate were observed, with adequate pain control. Wound-bed preparation enabled grafting 28 days after the initiation of the combined therapy. Complete graft integration occurred within 7 days, without dehiscence, necrosis, or infection. PRF acted as a biological matrix with proangiogenic potential, supporting cell proliferation and modulating the inflammatory response. NPWT contributed to edema reduction, removal of interstitial fluid, and mechanical stimulation of angiogenesis and cell migration mechanisms described in the literature as potentially synergistic.

Conclusion: The combination of autologous PRF and NPWT proved to be feasible and safe, promoting rapid wound-bed preparation, early grafting, and accelerated healing. The findings support the use of complementary strategies in tissue regeneration.


12/21/2023
12/21/2024
04/01/2024

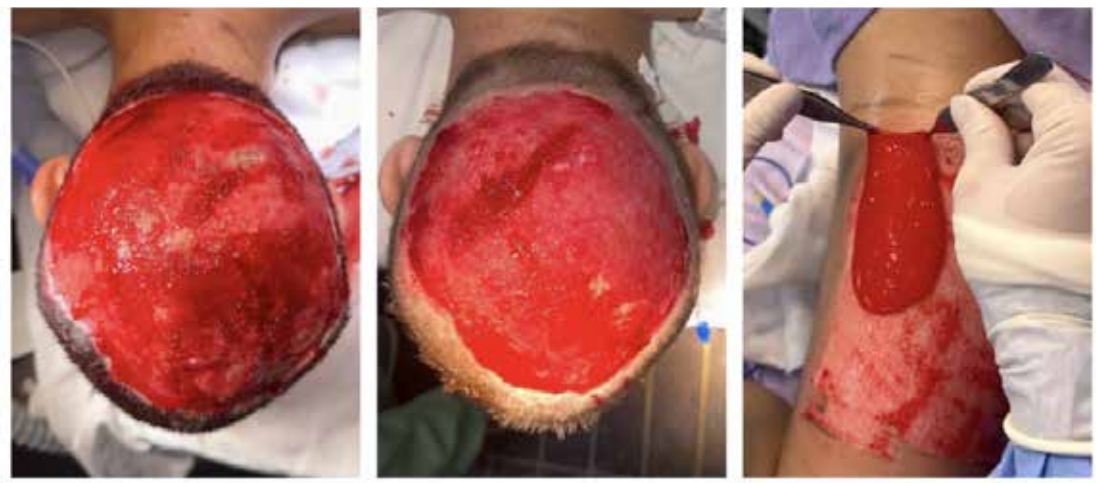
01/04/2024
01/18/2024
01/18/2024


01/18/2024
01/25/2024
01/25/2024

EP590 Recurrent keloid excision with tension reduction suture and adjuvant closed incision negative pressure wound therapy (ciNPWT)

Ananda Perdanakusuma[1], Ardea Perdanakusuma[1], David Perdanakusuma[1]

[1]Department of Plastic, Reconstructive and Aesthetic Surgery, Faculty of Medicine, Universitas Airlangga, Surabaya, Indonesia

Aim: To present the effectiveness of a combination of excision, tension reduction sutures, and ciNPWT in high-risk recurrent keloids.

Method: A 16-year-old male patient with a recurrent keloid on the right upper arm underwent an excision procedure and tension reduction suture technique. After wound closure, a ciNPWT dressing was applied over the incision line and connected to a portable device. Continuous negative pressure therapy of –125 mmHg was maintained for 7 days post-operation.

Results / Discussion: The surgical procedure and post-operative care proceeded smoothly without complications such as infection or wound dehiscence. After 7 days, the surgical wound appeared clean and tightly closed with minimal edema. At the 3-month follow-up, the scar appeared calm, flat, and aesthetic, with no clinical signs of keloid recurrence. The success of managing this case strongly validates the fundamental theory that mechanical tension is the primary trigger for keloid recurrence. The applied approach—through surgical excision followed by a tension reduction suture techniqudirectly targets this crucial factor. Furthermore, the application of ciNPWT as an adjuvant therapy functions as an effective external "mechanical splint." Its role is to neutralize residual tension on the wound and actively disrupt the profibrotic mechanotransduction cascade that triggers fibrosis.

Conclusion: The combination of surgical excision, tension reduction suture technique, and adjuvant ciNPWT application proved to be a highly effective and rational management strategy for recurrent keloids. This multimodal approach successfully addresses the tension factor identified as the primary etiology thus precisely breaking the recurrence cycle.

EP591 Limb-salvage reconstruction in acute-on-chronic charcot neuroarthropathy using bioactive glass and synthetic dermal matrix: A patient-centered approach

Marco Marcianò[1], Isabella Campo[1], Bianca Vicari[1], Valentina Lombardo[1], Francesco Maltese[1], Alessia Valenti[1], Giuseppe Carollo[1], Paolina Venturelli[1], Giovanni Guercio[1]

[1]A.O.U.P. Paolo Giaccone, Università degli studi di Palermo, Palermo, Italy

Aim: Severe neuropathic diabetic foot complications with Charcot neuroarthropathy are frequently managed with major amputation due to deformity, exposed bone, and high infection risk. When a patient categorically refuses this option, the clinical team must pursue complex and unconventional reconstructive strategies to respect patient autonomy preserving limb function while preventing sepsis. This case report illustrates an innovative multidisciplinary limb-salvage approach combining aggressive infection control, skeletal realignment, and advanced biomaterials.

Method: A patient with chronic neuropathic ulceration and acute-on-chronic Charcot neuroarthropathy of the left foot presented with a pronounced rocker-bottom deformity and a plantar wound with exposed bone confirmed on CT. Due to patient's refusal of amputation, surgical limb-savage management consisted in extensive debridement of infected tissue and osteotomy of the malacic talus removing diseased bone and correcting alignment. Resulting bone cavities were filled with bioactive glass for its osteoconductive and antibacterial properties. To rebuild the weight-bearing plantar surface, a synthetic dermal matrix (BTM) was applied to promote tissue formation, followed by rotation flaps for wound closure. Multidisciplinary postoperative care focused on infection control, off-loading, and stabilization.

Results / Discussion: At 20-day follow-up, rotational flaps demonstrated complete healing, plantar ulcer had fully resolved, and the foot regained a stable plantigrade configuration. No signs of local or systemic infection were detected, and the patient maintained functional ambulation.

Conclusion: Even in advanced Charcot neuroarthropathy with complex plantar defects and exposed bone, limb salvage is achievable when guided by patient-centered decision-making. Integration of aggressive surgical decontamination, structural correction, bioactive glass implantation, and synthetic dermal regeneration provided an effective alternative to major amputation. Early outcomes highlight the potential of innovative biomaterials to enhance reconstruction in severe diabetic foot pathology.

EP592 Pediatric post-burn keloid: multimodal therapy

Tânia Manuel[1], Adriana Gonçalves[1], Mariana Monteiro[1], Nuno Miguel Mendes Pinto[1]

[1]Clínica Nuno Mendes, Penafiel, Portugal

Aim: To describe the therapeutic approach and clinical evolution of a pediatric post-burn keloid scar treated with phototherapy, mechanical therapy and silicone, highlighting the impact of combined intervention on scar quality parameters.

Method: Case report of a 2-year-old female patient, with no relevant medical history, presenting with a burn from hot soup involving the neck, right arm and chest, with Fitzpatrick skin phototype II. At the initial assessment, she presented a keloid scar with elevation grade 3 (>5 mm), vascularity grade 2 (red), normal pigmentation and flexibility grade 4 (adherence). A 633 nm LED mask was applied, and the mother was instructed to perform compression over the scar with silicone tape and myofascial massage to reduce adhesions.

Results / Discussion: Over the follow-up period, now totaling 18 sessions, the patient underwent 633 nm LED mask with anti-inflammatory effect, myofascial massage, rotary brush and microneedling, progressively introduced according to tolerance. There was good clinical evolution, with the scar currently showing normal elevation, vascularity, pigmentation and flexibility, suggesting effectiveness of the combination of phototherapy, silicone compression and mechanical techniques in scar remodelling in pediatric patients

Conclusion: The integrated multimodal intervention combining LED, compressive silicone and manual techniques demonstrated potential to normalize the parameters of a post-burn keloid scar in a child, with aesthetic and functional improvement. This case reinforces the importance of combined protocols and parental education to ensure treatment continuity and optimize scar outcomes in pediatrics.

EP593 The effects of autologous fat grafts on chronic neuropathic foot ulcers

Helen Talvistu[1], Terje Arak[2]

[1]University of Tartu, Tartu, Estonia, *[2]Dept. of General and Plastic Surgery, Tartu University Hospital, Tartu, Estonia*

Aim: To evaluate the effect of autologous fat grafts in the healing process on chronic neuropathic non-diabetic foot ulcers.

Method: We conducted a retrospective review based on four case studies involving patients with plantar ulcers. The ulcers were unilateral for three patients and bilateral for one. All patients received autologous fat grafts. The procedure involved administering a tumescent solution under general anaesthesia, followed by liposuction using a vacuum locking syringe. Different fat layers were separated through decanting. The patients received a combination of milli-, micro-, and/or nanofat injections at least twice, with a three-month interval between procedures. Healing was evaluated based on ulcer characteristics such as size and depth, and treatment adjustments were made according to the wounds' progress.

Results / Discussion: Three out of the four patients achieved complete wound healing, including the patient with bilateral ulcers. The remaining patient whose wound did not heal, refused to comply with the treatment plan and regime. Notably, two patients reported a restoration of sensation in the affected area. The three patients with fully

healed wounds have not experienced reulceration and did not require amputation 6 to 36 months after the procedure. No complications were observed during the follow-up period.

Conclusion: Based on our case studies, autologous fat grafting can lead to complete healing of chronic neuropathic non-diabetic foot ulcers and may restore sensation in the affected leg for some patients.

EP594 Reconstruction of a giant postoperative groin lymphedema: A rare presentation of MLL

Uzay Cambaz[1], Okan Gürsoy[2], Tahsin Acartürk[1]

[1]University of Pittsburgh, Pittsburgh, United States, *[2]Istanbul University, Istanbul Faculty of Medicine, Istanbul, Türkiye*

Aim: To present a rare case of postoperative Massive Localized Lymphedema (MLL) developing in the groin of a non-obese patient and to describe the surgical management and reconstructive approach used to restore function and prevent complications.

Method: A 42-year-old non-obese male developed a progressively enlarging soft-tissue mass in the right groin following a previous inguinal procedure. The mass reached 60×50×40 cm over 10 years and caused severe mobility restriction, difficulty with daily activities, and recurrent episodes of cellulitis. Conservative therapy, including compression and physiotherapy, failed. The patient underwent en-bloc excision of the approximately 20-kg mass using an elliptical medial incision. Two ectatic lymphatic vessels with active leakage were identified during dissection and repaired with an imbrication technique. The right testis and spermatic cord were preserved. The defect was closed primarily under minimal tension as planned.

Results / Discussion: No postoperative complications occurred. Throughout a four-year follow-up period, there was no evidence of recurrence or lymphatic leakage. The patient reported marked improvement in gait, mobility, and overall quality of life. This case highlights that MLL can develop independently of obesity and may be triggered by congenital lymphatic dysplasia or iatrogenic factors such as prior surgery. If untreated, MLL carries risks of ulceration, recurrent infection, and malignant transformation, including angiosarcoma.

Conclusion: Early recognition and timely surgical intervention are essential in atypical presentations of MLL. En-bloc excision with meticulous lymphatic control provides effective groin reconstruction, restores function, and prevents long-term complications, including the risk of angiosarcoma.

EP595 Micrografts in the treatment of autoimmune ulcers: a new frontier? Clinical experience at a Level II Vulnology Center

Stefania Chiarenza[1], Loris Pelosi[1], Cecilia Muscarà[1], Roberto Cassino[1], Simone Toscano[1], Francesca Misto'[1], Carlo Iannuzzi[1], Francesca Turrini[1], Maria Teresa De Rose[1], Maria Castoldi[1], Beatrice Mosca[1], Michela Di Biasio[1], Stefano Ghislanzoni[1], Luisa Asumaduh[1]

[1]Gruppo San Donato, Milano, Italy

Aim: Micro-units of tissue clusters from mechanical skin processing are rich in progenitor, mesenchymal cells, EPCs, fibroblasts, pericytes, and GF. These can provide the starting signal for endogenous repair.

Micrografts are used in burns and acute wounds treatment. However, we would like to report our clinical experience on patients with long-standing chronic ulcers of autoimmune etiology.

Method: Two female aged 77 and 88 were selected: one suffering from rheumatoid arthritis with 18 cmq leg ulcer with tendon exposure from several month and the other from Behçet's disease with leg ulcer of approximately 400 cm^2 , atrophic, from 20 yo

Both undergoing immunosuppressive therapy and had previously undergone other treatment without results.

The patients were hospitalized and underwent micrografting of 2 cm^2 of micro-fragmented skin/subcutaneous tissue, obtained with disposable device.

The product was injected into the edges and bottom of the lesions (including tendon), after surgical debridement.

The lesions were covered with collagen/hyaluronic acid pads, and high-stiffness bandage.

Results / Discussion: The patients underwent medical examinations and dressing changes twice a week for 16 weeks.

At the endpoint a significant improvement in wound bed score was observed in both cases, with the resumption of healthy granulation tissue growth also within the tendon and the progressive appearance of new epithelium from the margins in the second case, with a reduction of the wound.

Conclusion: The micrograft technique has proven effective in restarting tissue repair of autoimmune ulcers with difficult management in selected cases. However, although the small number observed is not significant, it can guide us in future clinical choices and in the design of larger and more detailed future studies.

EP596 Successful wound healing using negative pressure wound therapy after wide excision in a patient with metastatic breast cancer

Kyung Ah Lee[1], Dong Gyu Kim[1]

[1]*Haeeundae Paik Hospital, Inje University, Busan, Korea, Rep. of South*

Aim: Metastatic breast cancer with extensive skin invasion may require palliative debulking, leaving large soft tissue defects in patients unsuitable for complex reconstruction. This case aimed to describe the use of negative pressure wound therapy (NPWT) as a wound-healing adjunct after wide excision in this setting.

Method: A 54-year-old woman with neglected metastatic breast cancer and marked skin invasion underwent palliative wide excision to reduce tumor volume and alleviate mass effect. Excision created a 40×30 cm defect extending from the breast to the flank (Fig 1). A partial fasciocutaneous flap was advanced to reduce the defect, leaving a residual area of 15×10 cm without gross residual tumor. NPWT was then applied over the remaining defect as the main strategy for wound management (Fig 2). Wound size, granulation, and the need for additional surgery were monitored during follow-up.

Results / Discussion: Progressive wound contraction and granulation were observed over a 4-month period, with reduction of the defect from 15×10 cm to 3×4 cm without further operative intervention. During the available follow-up, no local tumor progression at the wound bed was noted (Fig 3).

Conclusion: In this metastatic breast cancer case, NPWT facilitated gradual wound healing after palliative debulking where definitive oncologic resection and complex reconstruction were not appropriate. While caution remains necessary in malignant wounds, this experience suggests that NPWT may be considered as a practical option for large post-excisional defects in carefully selected palliative patients.

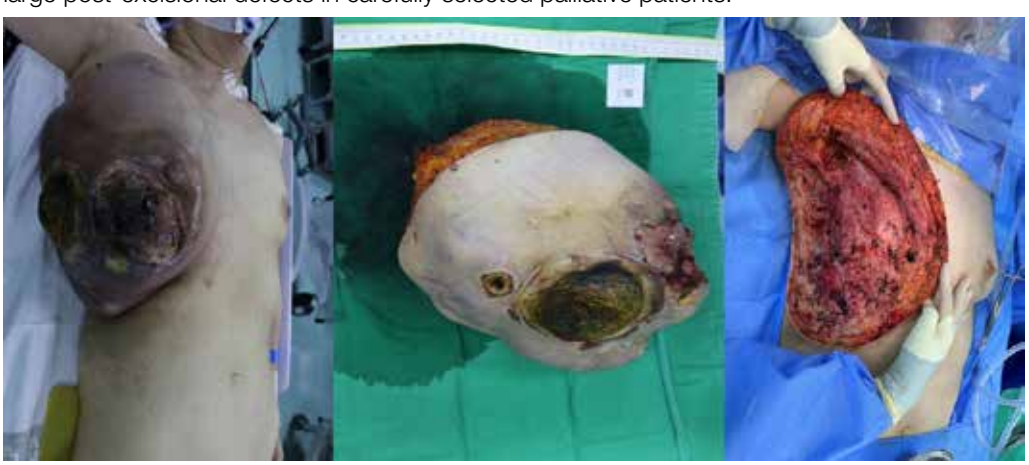

Fig 1. Preoperative breast cancer with skin invasion and volume effect, and the resulting 40×30 cm^2 defect after wide excision.

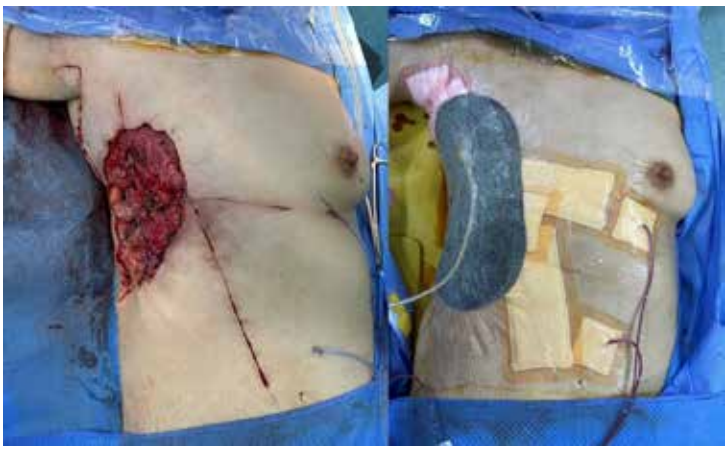

Fig 2. Fasciocutaneous flap reconstruction and NPWT application.



Fig 3. Wound healing progress at 1 month and 6 months postoperatively.

EP597 Ultrasonic debridement and NPWTi-d: A staged approach for limb salvage in necrotizing diabetic foot infection

Isabella Campo[1], Marco Marcianò[1], Bianca Vicari[1], Paolina Venturelli[1], Aurora Bullaro[1], Valentina Lombardo[2], Francesco Maltese[2], Giuseppe Carollo[2], Roberto Gullo[2], Giovanni Guercio[1]

[1]Università degli Studi di Palermo, palermo, Italy, *[2]Policlinico Paolo Giaccone, palermo, Italy*

Aim: This report details a multi-stage, advanced-therapy protocol for a severe dorsal diabetic foot lesion (SINBAD 4 / Texas 3C) complicated by necrotizing fasciitis, focused on rapid wound-bed optimization, microbiological eradication, and limb preservation.

Method: A 50-year-old male with type II diabetes underwent aggressive surgical debridement for necrotizing fasciitis. On postoperative day (POD) 3, bedside ultrasonic debridement with Granudacyn irrigation achieved microbiological sterilization (negative culture). Following this, a seven-day course of negative-pressure wound therapy with instillation (NPWTi-d) using Granudacyn prepared the wound for synthetic dermal matrix application. Progression and complications were monitored until complete closure.

Results / Discussion: Immediate sterilization followed ultrasonic debridement. NPWTi-d created a robust, graft-receptive wound bed. On POD 15 post-grafting, a myiasis complication necessitated graft removal. The underlying wound remained intact, well-granulating, and infection-free. Complete healing was achieved by secondary intention by POD 90.

Conclusion: Early bedside ultrasonic debridement, targeted antimicrobial irrigation, and NPWTi-d proved a rapid, effective strategy for optimizing a high-grade diabetic foot wound with necrotizing fasciitis. Despite the complication, the stability of the prepared wound bed allowed complete healing via secondary intention, validating this staged approach as a successful limb-salvage strategy.

EP598 A natural antioxidant dressing: The importance of green wound care

Marina Pierangeli[1], Giovanni Di Benedetto[1], Alessandro Scalise[1]

[1]*Marche Politechnical University, Ancona, Italy*

Aim: The increase in life expectancy is resulting in a large number of patients with chronic skin wounds suffering from a variety of co-morbidities. The reckless use of antibiotics leads to multi-resistant infections. The exploitation of non-renewable resources to produce advanced dressings leads to the progressive depletion of the Earth, which, combined with pollution, exposes us to serious global climate anomalies. Green wound care is a movement of thought that encourages the production of natural wound dressings from renewable sources, using eco-sustainable systems, usable in wound care. We tested a natural antioxidant dressing of plant origin on hard to heal wounds of the lower extremities, not infected but no responsive to standard of cure.

Method: 10 patients: 75 years; hard to heal wounds of lower limbs between 4 and 10 cm2; We used a natural antioxidant dressing based on carob, turmeric + N-acetyl cysteine. The patients were medicated 2 times a week, with or not an elastic compression bandage. Duration: 12 weeks.

Results / Discussion: Eight patients recovered and two improved. The periwound skin reduced hyperemia, edema, and pruritus. The edges showed signs of re-epithelialization. The bases of the lesions reactivated. Average healing time: 5 weeks.

Conclusion: Oxidative stress, cellular senescence, and comorbidities contribute to delayed healing. A natural antioxidant dressing is useful for interrupting the chronic inflammation phase, reactivating the normal healing process, and protecting the environment.

Green wound care, therefore, brings together the wound specialist, the patient, and the environment in which we all live.

EP599 Adhesive pouch dressing as a practical solution for encephalocele wound protection: Experience and outcomes

Ummu Atirah Muhammad[1], Chin Yen Lee[1], Jacob Abraham[1], Silvania Susan Binba[1]

[1]*Hospital Tengku Ampuan Afzan, Kuantan, Malaysia*

Aim: To evaluate the safety, utility, and clinical outcomes of using an adhesive pouch dressing for protecting encephalocele wounds, infection prevention, dressing integrity and ease of monitoring.

Method: We present a case of baby day 12 of life with encephalocele using an adhesive pouch dressing customized to fit the defect following sterile technique and gentle cleansing. Outcomes evaluated included infection control, containment of CSF or wound fluid, dressing integrity, maintenance frequency, ease of monitoring, and skin tolerance.

Results / Discussion: The adhesive pouch dressing provided effective isolation of the encephalocele sac, maintained a clean and protected wound environment, and remarkably minimized the leakage-related complications. The pouch allowed for continuous visual assessment, preserved perilesional skin integrity and lessen the need for frequent dressing changes. No evidence of skin breakdown dressing-related infections were observed.

Conclusion: Adhesive pouch dressing is a safe, practical and efficient solution for wound protection in infants with encephalocele. It offers secure containment, reduces contamination risk, and enhances clinical monitoring. This technique may be considered a valuable adjunct in preoperative encephalocele management, particularly in resource-limited or emergency settings.



EP600 Clinical experience with exosome injection in advanced pressure injuries

Kyung Ah Lee[1], Dong Gyu Kim[1]

[1]*Haeeundae Paik Hospital, Inje University, Busan, Korea, Rep. of South*

Aim: Stem cell–derived exosomes modulate inflammation and promote angiogenesis, but clinical data in full-thickness pressure injuries and poor granulation are limited. This series evaluated wound-bed changes after adjunctive exosome injection during serial debridement and coccygeal pressure injuries.

Method: A retrospective case series included four adults with stage III–IV or unstageable sacral or coccygeal pressure injuries. Wounds were full-thickness defects with slough and frequent bone exposure. All patients received repeated sharp debridement and, in most cases, negative pressure wound therapy until a thin layer of granulation tissue formed, but residual devitalized tissue, exposed bone, or stalled margins persisted. At that stage, an amniotic stem cell–derived exosome preparation was injected into the wound bed at selected sessions in addition to standard care, with 1 mL delivered per session and 5–7 sessions per patient. Serial operative notes and photographs were reviewed to assess granulation, necrosis, purulence, and depth.

Results / Discussion: Granulation tissue became progressively more robust after exosome injections, forming a well-vascularized, beefy-red wound bed. In all wounds, depth decreased from exposed bone to a granulating base within 1 week. Necrotic and sloughy tissue diminished, purulence resolved, and exposed deep structures became covered by granulation (Figure 1). Exosome use was associated with wound-bed optimisation rather than immediate closure. No adverse reactions, infection worsening, or procedure-related complications occurred during follow-up.

Conclusion: Adjunctive exosome injection during serial debridement was associated with rapid wound-bed improvement and early coverage of exposed bone in these pressure injuries. Exosome may be considered as an additional option for wound-bed optimisation in carefully selected patients.

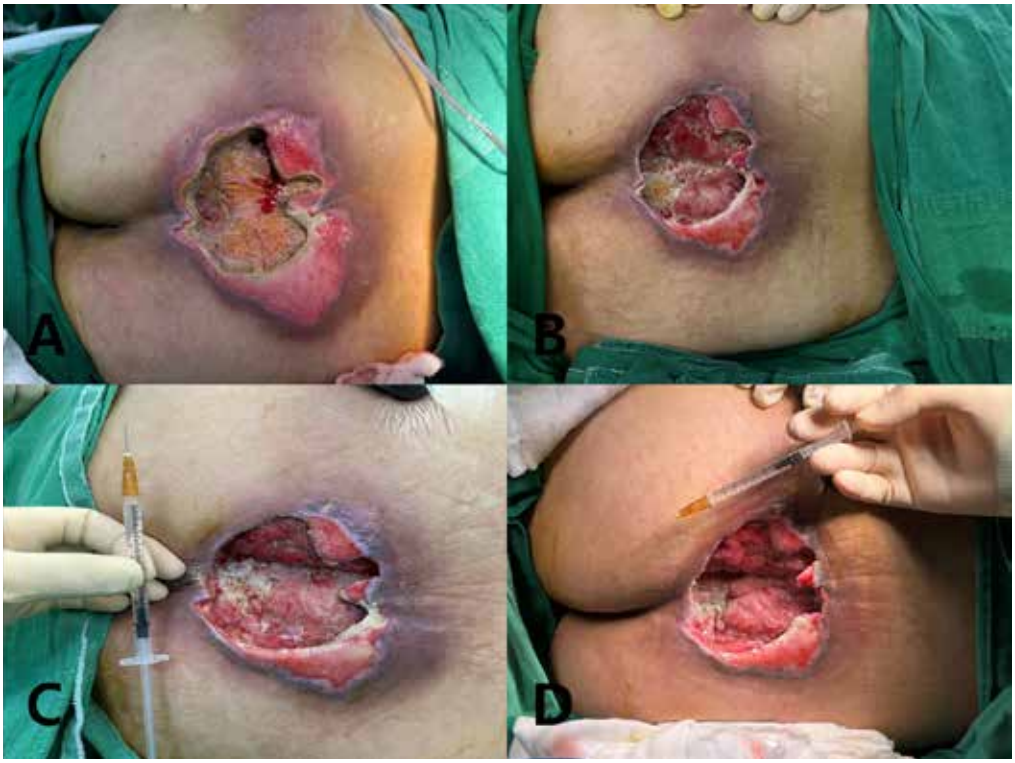

Figure 1. Serial wound-bed changes after adjunctive exosome injection in an advanced sacral pressure injury.

EP601 Innovative dual flap reconstructive for large multiplane oncologic defects: Combining superthin deltopectoral perforator and trapezius flaps

Eliza Nindita[1], Wendy Warto Septianto[2], Arya Prananda[1], Muhammad Anas[2]

[1]Division of Plastic Surgery, Department of Surgery, Faculty of Medicine, Universitas Sumatera Utara, Medan, Indonesia, *[2]Department of Surgery, Faculty of Medicine, Universitas Sumatera Utara Medan, Indonesia, Medan, Indonesia*

Aim: To describe a staged reconstructive strategy for coverage of a complex cervicothoracic defect with exposure of vital structures following extensive oncologic thyroid surgery.

Method: A 44-year-old male with a thyroid neoplasm suspicious for malignancy (clinical stage cT3N0M0) underwent total thyroidectomy, radical neck dissection, and tracheostomy. Postoperatively, a large anterior neck defect extending to the upper thoracic region developed, with exposed vital structures and impaired wound stability. Reconstruction was performed in stages: (1) thoracic wall repair to create a stable foundation, (2) selective split-thickness skin grafting (STSG) to well-vascularised superficial areas, and (3) definitive coverage with a pectoralis major myocutaneous flap to provide bulk, vascularised tissue to protect the tracheostoma and major vessels and restore contour.

Results: Staged reconstruction achieved complete soft-tissue coverage of the cervicothoracic defect and protection of exposed vital structures. No future-tense outcomes are reported; please insert objective postoperative results required for submission (e.g., STSG take rate [%], flap viability [complete/partial], complications [none/seroma/infection/dehiscence], time to wound stability [days], and follow-up duration [weeks/months]).

Conclusion: A staged approach combining thoracic wall repair, selective STSG, and a pectoralis major myocutaneous flap can provide reliable coverage and stabilisation for extensive cervicothoracic defects after radical thyroid surgery, particularly when vital structures and a tracheostoma require durable vascularised protection.

EP602 Beyond the horizon of mountains, care knows no distance - Mission Impossible: Distance is not a nursing problem

Yuting Yeh[1]

[1]*Hsiao Chung-Cheng Healthcare Group - Chingfu Hospital, Sanxia Dist., New Taipei City, Taiwan*

Aim: Through a patient-centered approach and a multidisciplinary care model, the use of modern wound dressings combined with nutritional support can lessen the need for surgical debridement and enhance healthcare accessibility for bedridden individuals and patients in remote areas.

Method: An 89-year-old woman with diabetes, stroke, and late-stage dementia presented with multiple grade III–IV pressure injuries on the sacrum and lower extremities, resulting from total paralysis and limb contractures. The sacral wound was the most severe, containing a mixture of yellowish-brown necrotic tissue and black eschar, with copious exudate and a foul odor. The wound measured 11.5 × 9.0 × 2.0 cm.

Initial bedside debridement was performed to remove the yellowish-brown necrotic tissue, revealing a deep wound with exposed bone. The patient subsequently received a 10-day course of medical-grade honey to inhibit bacterial growth and promote autolytic debridement. This was followed by a two-month regimen of the anti-biofilm agent Prontosan, along with alginate dressings to maintain moisture, while a nutritionist optimized her dietary intake.

After two and a half months, the wound had reduced to 5.0 × 3.4 × 1.3 cm, with substantial red granulation tissue formation. Hyaluronic acid gel combined with alginate dressings was then used to maintain a moist healing environment.

Results / Discussion: After 6.5 months, the wound decreased to 1.3 × 1.6 cm, with a healthy, rosy wound bed and no necrotic tissue.

Conclusion: Bedside debridement combined with modern wound dressings sustains an optimal moist environment and facilitates autolytic debridement, thereby enhancing wound healing. This approach also improves the accessibility and effectiveness of home-based medical care.

EP603 Workflow for the application of a polylactic acid matrix in conjunction with a 3D-printed splint for pediatric hand burns

Eleazar Samuel Kolosovas-Machuca[1], Mario Aurelio Martínez-Jimenez[2], Víctor Manuel Loza González[3], Ana Lorena Novoa-Moreno[4], José Luis Ramírez GarcíaLuna[5]

[1]*Coordinación para la Innovación y Aplicación de la Ciencia y Tecnología, Universidad Autónoma de San Luis Potosí, San Luis Potosi, Mexico*, [2]*Burn Unit, Hospital Regional de Alta Especialidad Dr. Ignacio Morones Prieto, San Luis Potosi, Mexico*, [3]*Doctorado Institucional en Ingeniería y Ciencia de Materiales Universidad Autónoma de San Luis Potosí (DICIM, UASLP), San Luis Potosi, Mexico*, [4]*Burn Unit, Hospital Regional de Alta Especialidad Dr. Ignacio Morones Prieto, San Luis Potosi, Mexico*, [5]*Faculty of Sciences, Universidad Autónoma de San Luis Potosí, San Luis Potosi, Mexico*

Aim: This study presents a scan-free digital workflow for the design and 3D-printing of pediatric hand splints. The objective is to offer an accessible, economical, and clinically viable alternative to conventional 3D-printed splint workflows, while enabling direct application of a synthetic polylactic acid matrix to the wound without the need for external dressings.

Method: The proposed method replaces direct 3D scanning with a hybrid approach that combines simple anthropometric measurements, standardized photographic references, and a scalable anatomical model generated in DAZ Studio. After dimensional calibration, the customized splints were sculpted in ZBrush and manufactured using FDM 3D printing with PLA. The workflow was applied to five pediatric hand burn cases to evaluate dimensional accuracy, reproducibility, and clinical compatibility over three weeks of wound healing.

Results / Discussion: The method enabled the creation of patient-specific hand splints that fit correctly without requiring post-printing adjustments. The dimensional calibration strategy, based on four key linear measurements,

proved sufficient accuracy for reliable, patient-specific modeling. All devices were used successfully for three weeks without adverse effects. The workflow demonstrated consistent manufacturing results and feasible clinical implementation in a hospital setting. The 3D-printed splits were fully compatible with the polylactic acid membrane, without interfering with its adherence to the wound bed, and provided mechanical protection to the injured area.

Conclusion: This scan-free digital workflow offers a practical, reproducible, and accessible alternative for the production of pediatric hand splints, reducing the technical and economic barriers associated with 3D scanning and parametric CAD systems. Its generalizable structure (Base Model → Scaled with Measurements → Digital Sculpting) makes it suitable for the treatment of burns on the extremities in children.

EP604 Management of enteroatmospheric fistulas using NPWT: A multidisciplinary approach in four cases

Giulia Vidotto[1], Umberto Cazzaro[1], Lina Carmela Ognibene[1], Gaetano De Angelis[1], Sara Maria Lupi[1], Vittoria Azzimonti[1], Francesco Carlo Denti[1], Davide Brambilla[1]

[1]Ospedale San Raffaele, Milano, Italy

Aim: This case series describes the management of four patients who developed enteroatmospheric fistulas following postoperative complications. The primary goal was to achieve closure of abdominal wound dehiscence and restore intestinal continuity through the creation of a new stoma, using Negative Pressure Wound Therapy (NPWT) in a multidisciplinary approach.

Method: Four patients with complex abdominal wounds and enteroatmospheric fistulas were treated during past year, using NPWT as part of an integrated care pathway. The process involved close collaboration between stoma care nurses and wound care nurses. NPWT was applied to control effluent, promote granulation tissue formation, and protect periwound skin. Regular assessments were performed in both inpatient and outpatient settings to monitor progress and adapt treatment strategies.

Results / Discussion: All patients achieved progressive wound healing, allowing for the construction of a new stoma. The use of NPWT facilitated early discharge, enabling patients to continue treatment at home and return for scheduled outpatient follow-up. This approach minimized hospitalization time while maintaining safety and continuity of care.

Conclusion: NPWT, combined with strong interdisciplinary collaboration between stoma care nurses and wound care nurses, proved effective in managing enteroatmospheric fistulas and complex abdominal dehiscence. This strategy supports early discharge and outpatient follow-up, improving patient outcomes and optimizing resource utilization.

EP605 Adjunctive use of negative pressure wound therapy with instillation and dwell in the management of a severe soft tissue infection

Alexandra Cristancho Ferrer[1], Carolina Hoyos[2]

[1]Clínica San José de Cúcuta, Norte de Santander, Colombia, *[2]Solventum, Bogota, Colombia*

Aim: Fournier's gangrene is a necrotizing infection that affects perineal, anal, scrotal, and genital soft tissues, with an annual incidence of 1.6 cases per 100,000 men. We evaluated the adjunctive use of negative pressure wound therapy with instillation and dwell (NPWTi-d*) in the management of a severe soft tissue infection.

Method: We present the case of a 38-year-old male with severe trauma following a traffic accident. He sustained a partial traumatic amputation of the right lower limb and major vascular injury, requiring transfemoral amputation. The patient developed necrosis of the stump and disarticulation, progressing to Fournier's gangrene with testicular involvement, necessitating bilateral orchiectomy. Extensive surgical debridement and colostomy were performed. The resulting defect measured 40 cm × 34 cm × 3 cm. NPWTi-d was applied with instillation of 200 mL of normal saline, dwell time of 10 minutes, and cycles of -125 mmHg applied every 4 hours.

Results / Discussion: Broad-spectrum systemic antibiotic therapy was administered, along with NPWTi-d dressing changes every 3 days. After 5 dressing changes, infection control (negative cultures) was achieved. The defect size was reduced to 11 cm × 10 cm × 2 cm, allowing definitive coverage with split-thickness skin grafts, which healed without complications and enabled adaptation of an external prosthesis.

Conclusion: Cases of Fournier's gangrene require management by a multidisciplinary team, with surgical debridement as the gold standard. In this case study, NPWTi-d was an effective adjunctive tool for preparing the wound bed for skin grafts. It promoted granulation tissue formation, reduced the need for additional surgical interventions, and provided hydromechanical removal of infectious materials, non-viable tissue, and wound debris.

EP606 Successful management of deep auricular burns with exposed cartilage: A case-based approach

Miodrag Karamarkovic[1], Branko Sudjecki[1], Jelena Isakovic Subotic[1], Nevena Mutavdzic[1], Filip Milosevic[1], Jelena Jeremic[1 2], Milana Jurisic[1], Marko Jovic[1 2], Milan Jovanovic[1 2], Maja Nikolic Zivanovic[1], Milan Stojicic[1 2]

[1]Clinic for Burns, Plastic and Reconstructive Surgery, University Clinical Center of Serbia, Belgrade, Serbia, *[2]University of Belgrade Faculty of Medicine, Belgrade, Serbia*

Aim: Deep burns of the auricle remain a challenge due to limited soft tissue coverage, susceptibility of cartilage to infection and necrosis and variable aesthetic results. The aim of this case report was to illustrate a practical treatment pathway by combining advanced wound care with delayed surgical reconstruction.

Method: A 22-year-old woman presented with deep flame burns affecting the face, neck, scalp, and both auricles, involving approximately 4% of the total body surface area. The injury occurred six days prior to referral, with inadequate initial local wound management, which led to burn deepening. Clinical evaluation revealed mixed deep partial-thickness and full-thickness burns with bilateral cartilage exposure, predominantly within the helix and antihelix. Management included serial surgical debridement of devitalized tissue and partial cartilage excision. Advanced wound dressings consisting of calcium alginate, hydrogel, and non-adhesive polyurethane foam were applied in a layered approach to facilitate autolytic debridement, control exudate, and promote granulation tissue formation. Dressings were changed every 2-4 days based on wound exudation. Definitive reconstruction was performed on post-injury day 22 using split-thickness skin grafts once an adequate wound bed had formed.

Results / Discussion: Progressive development of healthy granulation tissue was achieved without infectious complications. No clinical signs of chondritis were observed. Complete skin graft take (100%) was achieved. The final outcome demonstrated preservation of auricular architecture and satisfactory facial symmetry. Inflammatory markers normalized before discharge.

Conclusion: Advanced wound care strategies can successfully prepare deep auricular burn wounds with exposed cartilage for delayed skin grafting. A structured conservative-surgical pathway may reduce complications, support tissue preservation, and enable reliable auricular salvage in complex thermal injuries.

EP607 Advanced practice nursing management of chemotherapy-induced foot ulcer: Clinical experience

Mariana Altamirano Cardoso[1], Yolanda Torralba Garcia[1], Ana Belen Rodríguez Garcia[1], Noemi Bartolome Cerda[1]

[1]Hospital Clinic de Barcelona, Barcelona, Spain

Aim: To optimize the treatment of a patient with a chemotherapy-induced foot ulcer caused by paclitaxel.

Method: A 57-year-old female diagnosed with stage IV serous ovarian carcinoma, undergoing fifth-line of therapy with weekly paclitaxel plus bevacizumab (every three weeks). Taxanes, as paclitaxel, induce cutaneous toxicity (as dryness and skin fissures) and peripheral neuropathy, reducing plantar sensitivity and hindering early detection of lesions. Bevacizumab, an anti-angiogenic antibody, inhibits vascular endothelial growth factor (VEGF), delaying wound healing.

The patient developed a grade 2 ulcer on the left foot following blister rupture (2.5 × 2 cm), with macerated edges and granulation tissue. No systemic infection was detected. Due to the extension of the ulcer treatment was suspended. As urgent podiatry referral was not possible, oncology advanced practice nurses (APNs) assumed management, applying wound-care expertise. The treatment included cleansing with hypochlorous acid, mechanical debridement, silver dressing, and offloading. Follow-up was documented in the electronic health record in coordination with Primary Care.

Results: Within 12 days, the ulcer showed significant improvement, with size reduction and tissue recovery. Treatment continued with cleansing, offloading, and advanced dressings, incorporating a reparative cream. Complete healing allowed resumption of oncologic therapy after skipping only one bevacizumab and one paclitaxel session.

Conclusion: Taxane-associated foot ulcers represent a clinical challenge, exacerbating cutaneous toxicity, neuropathy, and impaired healing due to bevacizumab. These lesions compromise tissue integrity and continuity of cancer treatment.

Early intervention and the autonomous role of APN, trained in wound management, are essential for rapid and safe healing. A coordinated clinical response reduces complications, optimises the duration of treatment interruption, and prevents delays in chemotherapy administration, thereby preserving therapeutic efficacy and enhancing patient quality of life.

EP608 Treatment of necrotic heel ulcers in diabetic patients with alginogel: Clinical case experiences

Levent Demir[1], Sena Aslan[1]

[1]*Kayseri City Hospital, Kayseri, Türkiye*

Aim: This study presents three cases that demonstrate the efficacy of the enzyme alginogel in managing necrotic heel ulcers.

Method: This evaluation is a single-center, single-arm case series involving 3 patients with wounds of different etiologies treated with alginogel enzyme. The product was administered in accordance with the manufacturer's instructions.

Results/Discussion: The first patient is a 70-year-old female who has been on insulin for 30 years. For a period of one year, the patient has suffered from a non-healing necrotic wound on the left heel. Over a period of two months, enzyme alginogel was applied to the wound. This resulted in granulation of the wound on the heel.

The second patient is a 54-year-old male who has been diagnosed with type 2 diabetes mellitus for the past 20 years. He has been treated for a necrotic wound on the left heel for a period of six months. The application of the enzyme alginogel to the wound was conducted over a period of one month. This resulted in a substantial reduction in the size of the wound on the heel.

The third patient is a 70-year-old female who has suffered from type 2 DM for the past 25 years and has been afflicted with a deep necrotic wound on her right heel for the past 2 years. The application of the alginogel enzyme to the wound was carried out over a period of one year. As a result, the heel wound closed.

Conclusion: The healing processes observed in these three cases suggest that alginogel enzyme may be an effective and promising option in the management of necrotic heel wounds.

EP609 Supporting a patient to manage health anxieties in leg ulcer management

David Taylor[1]

[1]*HCRG Care Gorup, Swindon, United Kingdom*

Aim: The aim of this case study is to demonstrate the importance of holistic assessment in leg ulcer management when supporting a patient living with a leg ulcer in relation to their health anxiety and the need for an MDT approach.

Method: Patient is a 31 year old female, with bilateral lower limb ulceration which are lymphovenous in aetiology. Patient had attended A+E, urgent care and subsequent admission for cellulitis. Patient required multiple visits from the Tissue Viability Nurse Specialist to support an agreed partnership in care and support the community nursing team and wider MDT with the patients care.

Results / Discussion: The tissue viability nurse supported the patient and community nursing team in the patients leg ulcer management. Through motivational interviewing, working with the wider MDT, pain management, reviewing goals and addressing face to face weekly and a weekly phone call. The patient was supported to achieve goals within their care through accepting an ankle brachial pressure index by week three when this was declined, accepting compression bandaging by week 4 and compression wraps by week 7. Through completing weekly visits and setting agreed goals the patient now feels more fulfilled in life and embraces her leg ulcer management regime and is positive about her healing journey and that her leg ulcers will heal.

Conclusion: The need for a collaborative approach in care between multiple health professionals in crucial in successful leg ulcer management and increasing a patient's confidence in their ability to heal and quality of life. Through motivational interviewing and achieve small goals each visit the patient has full engaged in their care with a positive outlook on healing

---

EP610 Effective LED phototherapy for iron burn healing - a case study

Tânia Manuel[1], Sara Filipa Brandão Pereira[1], Celina Peixoto[1], Nuno Miguel Mendes Pinto[1]

[1]*Clínica Nuno Mendes, Penafiel, Portugal*

Aim: To describe the early therapeutic approach and clinical evolution of a facial iron burn in an adolescent, using air cryotherapy, 633 nm Laser LED phototherapy, and antimicrobial metallic complex repair gel, emphasizing their role in preventing scar sequelae and infections.

Method: Case report of a 13-year-old male patient who immediately sought skin health consultation after a facial burn caused by a household iron, accidentally inflicted by his younger brother. Initial management included immediate regional cooling with air cryotherapy, followed by bioestimulatory 633 nm LED PDT phototherapy and application of fatty gauze for protection and moist environment maintenance. Subsequent sessions continued exclusively with 633 nm LED PDT phototherapy. The patient was advised to apply a soothing repair gel twice daily containing Copper + Zinc + Manganese complex, with antimicrobial properties and reduced bacterial adhesion.

Results / Discussion: Immediate intervention enabled rapid discomfort reduction and local inflammatory response control, favoring skin barrier integrity and minimizing infection risk. The association of sequential phototherapy and metallic complex repair gel contributed in two sessions to organized healing, with preservation of skin texture and coloration, and no clinically significant hypertrophic scarring observed during follow-up. This case illustrates the importance of early action in pediatric facial burns, integrating thermal control, inflammatory modulation, and bacterial colonization prevention.

Conclusion: The combination of immediate air cryotherapy, 633 nm Laser LED phototherapy, and Copper + Zinc + Manganese complex repair gel proved a safe and potentially effective strategy for managing acute facial burns in adolescents, promoting higher-quality healing and reducing complication risks. Structured early intervention protocols for domestic burns in pediatric and adolescent age groups can contribute to improved aesthetic, functional, and psychosocial outcomes.

EP611 Treatment of a stagnant post-surgical sacrococcygeal wound using a ROS-releasing oil-impregnated bandage

Alessio Natale[1 2], Yuri Merli[1 2], Federico Bardazzi[1], Corrado Zengarini[1 2], Cosimo Misciali[1 2], Michelangelo La Placa[1 2]

[1]Unit of Dermatology, IRCCS University Hospital of Bologna, Policlinico S. Orsola-Malpighi, Bologna, Italy, Bologna, Italy, *[2]Department of Medical and Surgical Sciences, Alma Mater Studiorum, University of Bologna, Bologna, Italy, Bologna, Italy*

Aim: To describe how a non-healing but infection-free post-surgical sacrococcygeal wound, initially healed by secondary intention after pilonidal cyst excision, resumed healing and achieved rapid closure after switching from standard foam dressings to a targeted Reactive Oxygen Species (ROS)-releasing, oil-impregnated bandage approach.

Method: A young adult male developed wound re-opening after a long car journey without protective or pressure-relief aids. For the next 3 months, the wound remained clinically stable under polyurethane foam dressings, but showed no signs of epithelial movement or tissue remodelling, despite the absence of infection. Treatment was changed to a sterile bandage impregnated with an oil-based matrix releasing Reactive Oxygen Species (ROS), applied once daily to both the wound bed and the surrounding scar tissue. The goal was to restore hydration, soften the rigid fibrotic tissue around the wound, and support natural ROS-mediated repair signalling without traditional antiseptic products.

Results / Discussion: Foam dressings maintained wound stability, but did not reactivate healing. After the switch to the oil-impregnated, ROS-releasing bandage, the fibrotic tissue around the wound gradually softened, hydration improved, and epithelial repair progressed quickly. The wound closed completely within 2 weeks, with no clinical signs of infection or inflammation during treatment.

Conclusion: Some wounds may look stable and non-infected, but remain biologically inactive for long periods due to stiff and dehydrated scar tissue around the lesion. In this case, targeted hydration and controlled ROS signalling helped restore tissue flexibility and restarted epithelial migration, leading to rapid closure when foam dressings alone were not enough to move the repair process forward.

EP612 Use of closed incision negative pressure therapy for reducing wound complications in soft tissue tumor resection

Alexandra Cristancho Ferrer[1], Carolina Hoyos[2]

[1]Clínica San José de Cúcuta, Norte de Santander, Colombia, *[2]Solventum, Bogota, Colombia*

Aim: Patients undergoing musculoskeletal tumor excision are at high risk of infection, dehiscence, and delayed healing due to extensive dissection, vascular and lymphatic alterations, residual cavity, and adjuvant therapies. These complications are associated with poorer oncological outcomes in soft tissue tumors. Closed incision negative pressure therapy (ciNPT*) may help reduce these risks without compromising oncologic safety. This case study evaluated the effectiveness of ciNPT in reducing postoperative wound complications following soft tissue tumor resection.

Method: A 41-year-old male patient developed a large mass in the right thigh. Diagnostic studies revealed massive lymphoedema, venous dilation, and an undifferentiated lipoma. He had a history of hypertension and dyslipidemia, and had previously sustained a diaphyseal fracture of the right femur which had been treated with osteosynthesis. The patient underwent oncological resection with 5 cm margins following prior vascular embolization.

Results / Discussion: The excised mass measured 28 cm × 15 cm × 5 cm and weighed 1.5 kg. Plastic surgery performed a flap with primary closure. Given the high risk of surgical wound complications, continuous ciNPT at −125 mmHg was applied for 12 days. The patient achieved complete wound closure with optimal healing and no complications. Histopathological analysis confirmed a well-differentiated liposarcoma of the lipoma-like subtype.

Conclusion: In this patient, ciNPT was an effective and safe alternative for preventing complications in a high-risk surgical wound following large soft tissue tumor resection. Use of ciNPT was well tolerated, reduced edema, and improved postoperative outcomes.

EP613 Chronic lower limb ulcer with complex vascular pathology: A case report

Petra Andonovski Fužir[1]

[1]*General Hospital Slovenj Gradec Slovenia, Slovenj Gradec, Slovenia*

Aim: To present the diagnostic and therapeutic approach in a patient with a chronic lower limb ulcer and a complex medical background involving lymphoma treatment, chemotherapy, and extensive deep vein thrombosis (DVT).

Methods: A 45-year-old male patient was first evaluated in January 2021 with a chronic ulcer measuring approximately 5 × 2 cm on the anterior right lower leg. Due to suspected vascular etiology, diagnostic imaging included CT angiography (CTA) and venous ultrasound. Percutaneous transluminal angioplasty (PTA) was performed. Regular local wound care with modern wound dressings and systemic antibiotic therapy were initiated when signs of infection appeared. Because of persistent stagnation in healing, the patient was reassessed by a multidisciplinary team in early 2023, and advanced wound management was continued. In September 2024, therapy with a zinc compression bandage was introduced, with weekly dressing changes.

Results: CTA performed in December 2022 confirmed persistent vascular pathology. Gradual improvement was observed during advanced local wound therapy. After initiation of zinc compression bandaging in September 2024, progressive granulation and epithelialization followed. Complete wound closure was achieved on July 17, 2025.

Conclusions: This case demonstrates that in patients with complex oncological, vascular, and immunological backgrounds, comprehensive vascular assessment, consistent advanced wound care, and compression therapy can lead to complete healing of chronic lower limb ulcers. Continued follow-up and patient education on skin care and long-term compression use are recommended due to the risk of recurrence.

Reference (brand name / supplier): Zinc compression bandage: CoFlex® — supplied by MM Surgical d.o.o., Slovenia (https://www.mmsurgical.si/oskrba-rane)

EP614 Multidisciplinary management and care continuity in malignant cutaneous lesions of HER2-low breast cancer: A clinical case

Nacira Arab[1], Eva Alejandra Díaz Quiroz[1], Mireia Hita[1 1], Margarita Viladot[1], Lucía Llavata[1]

[1]*Institute of Cancer and Blood Diseases, Hospital Clínic de Barcelona, Barcelona, Spain*

Aim: Cutaneous metastases in breast cancer often lead to highly complex malignant wounds with substantial impact on pain, exudate, local control, and quality of life. Their management requires advanced expertise and efficient coordination across healthcare teams.

This case report describes a multidisciplinary management model and continuity of care between an acute-care hospital and an intermediate-care hospital (ICH) for malignant cutaneous lesions in metastatic HER2-low breast cancer.

Method: A 40-year-old woman from Ukraine with luminal A breast cancer diagnosed in 2019 and metastatic progression in 2022 was admitted in October 2024 with massive pleural effusion and extensive ulcerated and necrotic lesions involving both breasts and the thoracic wall. Systemic treatment with trastuzumab-deruxtecan was initiated, along with an advanced wound care protocol every 48 hours (cleansing, antiseptic solution, high-absorption dressing, protective bandage), coordinated among oncology, specialized nursing, and the complex-wound unit of Hospital Clínic.

Following clinical stabilization, a structured transition to ICH Sant Antoni was carried out, with continued supervision and material support from the acute-care hospital to ensure full continuity of wound management.

Results / Discussion: Over six weeks, functional improvement was observed (ECOG PS 2 → 1), with reduced pain, exudate, malodor, and progressive re-epithelialization and stabilization of lesions. The patient reported increased comfort, better tolerance to care, and a strong perception of continuity thanks to the shared pathway between both centers.

Conclusion: This case shows that a coordinated, multidisciplinary model between acute and intermediate-care settings can be successfully implemented for highly complex malignant wounds, improving clinical status, continuity, symptom control, and patient experience. Continuity of care is confirmed as a key factor in optimizing outcomes in cutaneous metastatic disease.

EP615 Application of autologous blood product and extracellular matrix in hard-to-heal mixed leg ulcer - case report

Jadranka Kovačević[1], Tamara Sinožić[1], Domagoj Butkovic[2]

[1]Private practice of Family Medicine Tamara Sinožić, FD, Mošćenička Draga, Croatia, *[2]BETAMED, Zagreb, Croatia*

Aim: To demonstrate the use of autologous blood product and extracellular matrix in the treatment of hard-to-heal mixed leg ulcers.

Method: A 76-year-old patient presents with right lower leg ulcers that are present for 3 years. His medical documentation shows right GSV insufficiency with stage IV reflux and occlusion of PTA, ATA and DPA without detectable flow. Concomitant diseases include type 2 diabetes, PAD, chronic kidney disease, arterial hypertension and obesity. Therapy is metformin 1000, dulaglutide, monoxidine, perindopril with indapamide, diazepam, cholcalciferol, atorvastatin, acetylsalicylic acid. On the right lower leg there are two wounds on the medial side irregular in shape, size 5,5x2,5 cm and 7x3 cm, yellow wound bed, moderate exudate and two wounds on lateral side, size 8,5x3,5 cm and 5,5x2,5 cm with same characteristics. Hemosiderosis, with pitting edema and varicose veins. General measures were applied, local therapy with wound dressings and low-dose compression therapy with a short-stretch bandages. Four months after the start of wound therapy and wound bed conditioning, autologous blood product and extracellular matrix were applied. Autologous blood product was applied to the lateral wounds on three occasions with an interval of one week and two weeks, respectively, while extracellular matrix was applied once to the medial wounds. In the continuation wound dressing containing medical copper was applied once a week.

Results / Discussion: 15 weeks after application of the extracellular matrix wounds on the medial side healed completely. 24 weeks after application of autologous blood product the wound on the lateral side healed.

Conclusion: Application of autologous blood product and extracellular matrix is simple, significantly accelerates the healing of hard-to-heal leg ulcers and was well tolerated without side effects.

EP616 Management of a complex ulcerated infantile haemangioma in an infant

Rachel Allaway[1], Maria L Bageta[1]

[1]Great Ormond St Hospital for Children, London, United Kingdom

Aim: Ulceration is a common complication of infantile haemangiomas (IH), which leads to substantial morbidity including pain, bleeding, infection, functional impairment, and scarring.

Method: We present a case of an infant referred with a segmental IH with superficial exophytic growth covering 2/3 of her left upper limb showing early signs of ulceration. The area was swabbed, and she was commenced on low dose systemic beta blockers and standard topical management. The ulceration worsened rapidly, and swabs showed growth of Pseudomonas aeruginosa; hence they were treated with oral ciprofloxacin, and topical treatment was replaced with an ointment containing dexamethasone, polymyxin B sulphate, and neomycin sulphate. Despite a week of treatment, dry necrosis was seen to 90% of the wound bed and 10% slough. Analgesia was optimised; the wound was cleansed with an antimicrobial solution and an algino woundgel was added. Dressings included a gentle one-sided wound contact layer and sterile silicone bordered dressing. Once all necrotic tissue was debrided, a small area of muscle was exposed which healed by secondary intention.

Results / Discussion: This was a complex case requiring combination therapy with adequate analgesia, oral beta blockers and topical treatment. Optimal treatment for ulcerated IH remains a knowledge gap and current clinical practice is heavily reliant upon anecdotal reports, expert consensus, and generalized principles of wound care. Multidisciplinary team (MDT) approach is often needed to manage these complex patients.

Conclusion: Use of a new MDT treatment strategy has been found to be beneficial in both healing these complex lesions whilst improving quality of life. This clinical case study will help form the basis for a specialist clinical guideline to address management of these wounds.

EP617 Crohn's perianal wound: Multimodal success

Tânia Manuel[1], Sara Filipa Brandão Pereira[1], Beatriz Manuela Azevedo Costa[1], Celina Peixoto[1], Sandra Carrilho[2], Nuno Miguel Mendes Pinto[1]

[1]Clínica Nuno Mendes, Penafiel, Portugal, *[2]Unidade Local Saúde de Santa Maria, Lisboa, Portugal*

Aim: To describe the multidisciplinary management and clinical evolution of a perianal wound dehiscence post-proctocolectomy in a young adult with Crohn's disease, integrating advanced dressings, hyperbaric oxygen therapy and platelet-rich fibrin (PRF), emphasizing their synergistic role in promoting wound closure.

Method: Case report of an 18-year-old autonomous male patient, living with mother and sister, diagnosed with Crohn's disease at age 7, with multiple childhood hospitalizations for disease flares culminating in proctocolectomy with definitive ileostomy on 31 May 2022. On 15 July 2022, outpatient follow-up initiated for perianal suture dehiscence measuring 8 cm (length) × 2 cm (width) × 10 cm (depth). Wound bed management involved sequential advanced dressings: calcium alginate with honey, povidone impregnated gauze, diaquicarbamoyl chloride with hydrogel, portable NPWT with hyaluronic acid, and MEC. Adjuvant therapies included approximately 80 hyperbaric oxygen therapy (HBOT) sessions and, from February 2024, three PRF sessions spaced one month apart.

Results / Discussion: The multimodal approach combining specialized dressings for biofilm control and moist healing, HBOT for tissue oxygenation and angiogenesis stimulation, and PRF for growth factor delivery and extracellular matrix remodeling led to progressive wound bed improvement. Notably, post-PRF sessions, significant wound area reduction was observed, transitioning from a deep cavitary defect to granulation tissue dominance, highlighting the efficacy of biological augmentation in chronic post-surgical wounds associated with inflammatory bowel disease.

Conclusion: Integrated wound care with advanced dressings, hyperbaric oxygen and PRF demonstrates substantial potential for managing complex perianal dehiscence in Crohn's disease patients post-colectomy. This case underscores the value of sequential, evidence-based interventions and biological therapies to achieve wound closure, reduce treatment duration and improve quality of life in young adults with challenging surgical wounds.

EP618 Comprehensive management of recalcitrant venous ulcers in a primary care complex wound nursing clinic using autologous "seal" graft: a case report

Eduardo González Álvarez[1], Laura Baltà Domínguez[1], Sofia Megino Escobar[1], Ruben Molina Carrilo[1], Amalur Mateo[1], Rosa Fernández Duart[2]

[1]Institut Català Salut, Barcelona, Spain, *[2]Institut Català de la Salut, Barcelona, Spain*

Aim: To describe the management of a patient with recalcitrant chronic venous ulcers, highlighting the role of a primary care complex wound nursing clinic, adherence, and combined advanced interventions.

Method: A 48-year-old woman with 20-year recurrent venous ulcers (IVC CEAP C6r), marked lipodermatosclerosis, and complex psychosocial factors presented two ulcers on the left lower limb gaiter area (42.5 cm^2 and 31.8 cm^2) with fibrotic beds, biofilm, and mild infection. Vascular assessment: ABI 1.1; triphasic arterial Doppler; venous Doppler showing paraostial incompetence of the great saphenous vein. Treatment in the primary care complex wound nursing clinic from February 12, 2025 included topical analgesia, sharp debridement, antimicrobial cleansing, antimicrobial/exudate-managing dressings, and low-elasticity compression (40 mmHg). Intravenous antibiotics were given per culture results. After wound bed stabilization, an autologous "seal" graft with 14-day negative pressure therapy was applied.

Results / Discussion: Ulcer areas decreased: Feb 12, 2025: 42.5/31.8 cm^2; Mar 4: 34.5/28.4 cm^2; Apr 29: 29.7/22.3 cm^2; May 27: 18.9/13.9 cm^2. On graft day (Jun 10), ulcers measured 14.4/13.1 cm^2. Complete healing occurred within 28 days post-graft. Wound-QoL improved from 49 to 22, and pain (VAS) from 9 to 0.

Conclusion: Management entirely in a primary care complex wound nursing clinic, combining debridement, antimicrobial therapy, effective compression, and autologous "seal" graft, enabled resolution of long-standing recalcitrant ulcers. Adherence and continuous nursing support were key. This case highlights the role of specialized wound nursing clinics in primary care for managing hard-to-heal ulcers and achieving significant improvements in patient outcomes.

EP619 Limb-threatening recurrent pyoderma gangrenosum in a diabetic patient: Multidisciplinary management with hyperbaric oxygen therapy, negative pressure wound therapy and extracellular matrix-based dressings

Veronica Valentim[1 2], Francisleny Vieira[1 3], Marcela Vieira[1 2], Luisa Ciucci Biagioni[1], Melissa Moraes Silva[1 2 3]

[1]TecCurar, HCITec, Itajubá, Brazil, *[2]IVES, Itajubá, Brazil*, *[3]HCITec, Itajubá, Brazil*

Aim: To present the clinical course and management of a 61-year-old male patient with diabetes mellitus who developed limb-threatening, recurrent pyoderma gangrenosum (PG) of the lower limb, highlighting diagnostic challenges, therapeutic sequencing and the role of adjunctive wound therapies and phase-adapted dressings.

Method: Management included systemic immunomodulation with a tapered oral corticosteroid regimen. Adjunctive wound therapies comprised hyperbaric oxygen therapy (HBOT) in 25 sessions followed by negative pressure wound therapy (NPWT). Local care used a phase-specific dressing strategy according to exudate, tissue characteristics and healing stage, including collagen-based and other extracellular matrix (ECM)-based dressings. Serial clinical assessments guided therapy adjustments.

Results / Discussion: A 61-year-old man with long-standing diabetes presented a rapidly progressive, painful ulcer on the anteromedial right leg, representing the second recurrence within three months. After four weeks, tibial exposure indicated severe PG activity and high risk of limb loss. Initial corticosteroid therapy achieved only partial inflammatory control. The subsequent introduction of HBOT and, sequentially, NPWT was associated with marked clinical improvement, with granulation tissue covering the exposed bone and progressive reduction in ulcer area. Phase-adapted local care contributed to control of exudate in the inflammatory phase and to tissue organisation as collagen- and ECM-based dressings were introduced in the granulation and epithelialisation phases. Complete wound closure occurred after approximately three months of continuous therapy.

Conclusion: This case illustrates the complexity of managing recurrent PG in the context of diabetes mellitus and underscores the importance of early recognition, tailored immunomodulation and multidisciplinary care. The outcome after integrating HBOT, NPWT and a phase-specific dressing strategy highlights the value of combining systemic therapy with advanced local wound management in atypical, severe and complex ulcers.

EP620 Multilayer foam dressing for the healing of a very difficult iatrogenic wound: clinical case

Carlo Rivellini[1]

[1]AIUC, SIC, SICVE, AFI, Italy

Aim: This clinical case aims to demonstrate how a multilayer foam dressing that also incorporates Hydrofiber technology can effectively contribute to the healing of very difficult wounds.

Method: We treated a 72-year-old diabetic patient with heart disease with a non-healing, infected ulcer (positive culture for two pathogens), very large and deep, with abundant, foul-smelling exudate. A further injury had been caused by bandaging on the ankle, corresponding to the flexor hallucis longus, with significant inflammation of the periwound skin. For this patient, it was essential to continue with compression therapy, for which an absorbent, multilayered polyurethane foam and hydrofiber dressing was used. Its excellent ability to dampen local pressure and absorb exudate, as well as its effect on the biofilm, allowed us to continue with multilayered bandages with pressure of 30-40 mmHg at the ankle. Targeted antibiotic therapy was also instituted for 4 weeks.

Results / Discussion: The wound healed after 3 months thanks to the dressing's ability to continue with highly compressive bandages and its ability to effectively absorb exudate.

Conclusion: Multilayer foam dressings are an extraordinary resource in the management of difficult, infected, and exuding wounds, especially pressure wounds.

EP621 High-pressure industrial paint injection injury of the hand: A rare limb-threatening case required debridement and advanced wound care

Mohamed Zaied[1]

[1]*Faculty of Medicine, Kafrelsheikh University, Kafrelsheikh, Egypt*

Aim: To present and analyze a severe high-pressure Doku gun paint injection injury to the hand. surgical management strategies, and factors influencing tissue preservation and functional recovery.

Method:

Patient Information

- Age/Sex: male patient 34 years old
- Occupation: Industrial worker
- Hand Dominance: right
- Relevant Medical History: No comorbidities influencing wound healing.
- Mechanism of Injury: Accidental discharge of a high-pressure Doku gun leading to forceful injection of industrial paint into the hand.

Clinical Presentation

- Symptoms: Severe pain out of proportion, swelling, limited range of motion.
- Physical Findings:
    - Small puncture wound at entry site.
    - Marked swelling and discoloration of the hand.
    - Motor affection
    - The patient misdiagnosed and came with Compartmental syndrome

Management urgent surgical debridement with two incisions for compartment decompression and removal of paint material from hand tissues.



Figure 1. Intraoperative two incisions and removal of paint material

Results / Discussion: Hand salvage achieved with preserved functions

High-pressure injection injuries caused by paint are associated with particularly severe outcomes due to chemical toxicity and high viscosity. Key learning points from this case:

- Early recognition is critical; delayed presentation markedly increases morbidity.
- Small skin wounds can mask extensive underlying tissue damage.
- Paint injection often requires aggressive serial debridement.
- Compartment syndrome risk is high.



Figure 2. Wound care until complete healing

Conclusion: This case illustrates the severity of Doku gun high-pressure paint injection injuries. Prompt surgical intervention, debridement and proper wound care are essential to remove the large volume of foreign material and preserve hand function.

EP622 Bioglass combined with gentalfoil in Charcot foot reconstruction reducing the risk of amputation and supporting early discharge

Bernardo Hime[1], Juliana Lucinda dos Santos[1], Walkiria Hueb[1], Giuliano Volpiani[1], Alexandre Fioranelli[1], Dimitri Hansen[1]

[1]*Irmandade Santa Casa de Misericórdia de São Paulo, Hospital Santa Isabel - Rede Dor, Prime Care Cuidados Integrados a Feridas, São Paulo, Brazil*

Aim: Charcot foot is a severe complication of diabetic neuropathy that leads to joint collapse, bone destruction, instability, and deformities. It carries major clinical relevance and is frequently associated with deep ulcers, osteomyelitis, and increased risk of amputation. Early diagnosis and advanced limb preservation strategies are essential. This report describes a 68-year-old woman with long standing type 2 diabetes mellitus, multiple segmental amputations, hypertension, obesity, prior myocardial infarction, and chronic heart failure. She presented with a deep calcaneal lesion showing progressive drainage and foul odor. Imaging and laboratory findings confirmed chronic osteomyelitis with significant soft tissue involvement.

Method: The case followed a structured protocol with initial surgical intervention and reassessment at 15 days. Treatment included wide debridement and aggressive calcaneal curettage until viable bone was reached, followed by filling of the defect with bioglass. The wound was temporarily covered with gentalfoil. Postoperative care involved only secondary dressing changes, with no additional local procedures. Clinical evolution was monitored throughout the recovery period. At 30 days, adequate epithelialization and clinical stability supported patient discharge.

Results: Patients with Charcot neuroarthropathy have high susceptibility to infection and ulceration. The combined surgical and regenerative strategy aimed to control infection and preserve limb integrity. After intervention, there was reduced drainage, improved wound appearance, emergence of viable tissue, and declining inflammatory markers. Bioglass contributed to local stability and bone regeneration.

Conclusion: Bioglass proved to be a beneficial adjuvant for infection control and tissue repair, reinforcing the importance of coordinated multidisciplinary management for advanced diabetic lesions.

EP623 Advanced vascular strategies for septic diabetic foot salvage in Brazil: The impact of negative pressure therapy and hyperbaric oxygen as adjunctive technologies – A case report

Bernardo Hime[1], Juliana Lucinda dos Santos[1], Fernando Bacalhau[2], Lucas Porto[1], Luciene Lima[2]

[1]Irmandade Santa Casa de Misericórdia de São Paulo, Hospital Santa Isabel - Rede Dor, Prime Care Cuidados Integrados a Feridas, São Paulo, Brazil, *[2]Cristovão da Gama Diadema, São Paulo, Brazil*

Aim: Septic diabetic foot is a severe complication of diabetes mellitus and a major cause of nontraumatic amputations worldwide. Up to 25 percent of diabetic patients develop foot ulcers, and roughly 20 percent progress to severe infection with risk of sepsis and limb loss. Delayed diagnosis, poor glycemic control, and deep tissue involvement accelerate clinical deterioration and demand multidisciplinary management supported by advanced therapeutic technologies.

Method: This report describes a patient admitted with diabetic ketoacidosis and sepsis from an extensive plantar infection, without prior diagnosis of diabetes. Management included urgent surgical debridement and subsequent serial procedures, preserving viable structures according to continuous vascular assessment. Advanced therapies were incorporated, including negative pressure wound therapy for infection control and promotion of granulation, hyperbaric oxygen therapy to enhance tissue perfusion, and a continuous venous infusion system for safe administration of antibiotics, insulin, and fluids. Intensive insulin therapy via infusion pump was used along with culture guided antibiotics, renal monitoring, and metabolic stabilization.

Results / Discussion: The patient demonstrated progressive infection control, hemodynamic stabilization, satisfactory granulation tissue formation, and limb preservation without major amputation. The coordinated involvement of vascular surgery and advanced technological support accelerated recovery and prevented secondary complications, emphasizing the value of modern adjunctive tools in complex diabetic foot infections.

Conclusion: The Brazilian experience reinforces that early vascular surgical intervention combined with advanced therapies and multidisciplinary care is essential for salvaging the septic diabetic foot, reducing the need for amputation, and improving outcomes in severe diabetic infections.

EP624 Care strategies for the management of complex wounds in a child with low compliance: A case report

Caterina Filippi[1], Marica Granziera[1]

[1]*Scientific Institute Irccs E. Medea, La Nostra Famiglia, Bosisio Parini, Italy*

Aim: Advanced dressings for the treatment of complex wounds offer significant benefits when applied with appropriate timing and modalities. However, these treatments require patient compliance, which is often difficult to achieve, particularly in pediatric care. The aim of this study is to identify care strategies for the management of complex wounds in children with reduced compliance.

Method: This case report describes the management of two complex upper-limb ulcers in a 4-year-old child with severe psychomotor delay and autistic traits. The child exhibited nearly continuous self-injurious biting behaviors. For one month at home, the wounds had been treated with hydrogen peroxide, causing discomfort and anxiety.

Results / Discussion: Within a proactive Wound Hygiene approach, the care plan focused on daily dressing changes, fostering an empathetic and trusting relationship with the child, and training the caregiver. Daily dressing changes enabled effective control of cleansing, wound bed preparation, and debridement, along with continuous monitoring of exudate, wound edges, and periwound skin.

The use of simple explanations, gentle movements and tone of voice, and distraction techniques—such as toys, videos, and music—enhanced compliance and reduced the child's anxiety. The mother was consistently involved during the procedures.

Conclusion: This approach led to complete healing of the wounds within 22 days, despite the persistence - although progressively reduced - of self-injurious behaviors. Relational and distraction techniques constitute an essential and fundamental component of first-line wound management in children with behavioral disorders, together with the therapeutic education provided to caregivers, which supports the effectiveness of home-based interventions.

EP625 Miracle or science? Rapid resolution of a plantar callus with abscess in a neuropathic diabetic foot: A case report

Ana Paula dos Santos Albuquerque[1]

[1]*Regional Hospital of Agreste / Pernambuco State Health Department, Nursing Clinic specializing in wound care, Caruaru, Brazil*

Aim: To describe the rapid healing of a plantar callus complicated by abscess in a patient with diabetic neuropathy, highlighting the combined effect of offloading, laser therapy, and antimicrobial management based on current evidence for high-risk diabetic foot wounds.

Method: This case report was conducted in an outpatient diabetic foot clinic in Pernambuco, Brazil. A patient with diabetes and established peripheral neuropathy presented with a plantar metatarsal callus displaying erythematous borders, fluctuation, and purulent drainage. After drainage of abundant purulent content, complete removal of the callus roof exposed the dermis, characterizing a high-risk wound due to its plantar location and loss of protective sensation.

Management included: Laser therapy (photobiomodulation) to modulate inflammation and stimulate tissue repair; Offloading, following IWGDF recommendations to reduce plantar pressure; Antimicrobial dressing for local bioburden control; Strict rest, minimizing mechanical stress.

The wound was reassessed over seven days.

Results / Discussion: After one week, the wound achieved complete closure, with no signs of infection or further tissue compromise. This outcome aligns with literature showing that: offloading is the most effective intervention for neuropathic plantar wounds; photobiomodulation may enhance granulation and epithelialization; early drainage with antimicrobial therapy reduces progression to deeper infection. The combination of unloading, infection control, and stimulation of cellular repair likely contributed to the fast-healing response.

Conclusion: The integrated use of offloading, laser therapy, and antimicrobial dressing resulted in rapid resolution of a plantar abscess in a neuropathic diabetic foot. This case reinforces the importance of early assessment, clinical decision-making, and evidence-based multimodal strategies. Outcomes sometimes perceived as “miraculous” are achievable when scientific principles are consistently applied in high-risk diabetic foot care.

03.12.25





10.12.25



DEVICES & INTERVENTION

EP075 Examination of the effect of mobile technology use on nursing care in the prevention of medical device-related pressure injury

Hilal Atmaca[1], Ozlem Dogu[1], Cemil Oz[1]

[1]*Sakarya University, Sakarya, Türkiye*

Aim: The study was planned to determine the effect of the use of Hi Nurse mobile application which was developed to provide care and follow-up for MDRP.

Method: The research was conducted in a methodological and one-group, pre-test-post-test quasi-experimental design. Data was collected by researchers through questionnaires that determined the sociodemographic data and MDRPI knowledge level of 13 nurses working in the intensive care unit. A total of 164 patients who were hospitalised between April and September were evaluated for 48 hours.

Results / Discussion: The pre-test average score for intensive care nurses on the 'MDRPIKQ Total' was 24.00±3.49, and the post-test average score on the 'MDRPIKQ Total' was 27.15±2.19. It was observed that 30.8% of the knowledge score reached a good level after using the Hi Nurse mobile application. In the pre-test group of the study, the MDRPI rate for the ICU was 42.7% in the three-month period before the use of the Hi Nurse mobile application, while the ICU incidence rate after the use of the Hi Nurse mobile application was 8.5%.

Conclusion: It has been noticed in clinical practices that the use of mobile applications by intensive care nurses in the clinic reduces the incidence rates of pressure injuries associated with medical devices in the intensive care unit and increases the knowledge and awareness of nurses. The investigation of the effects of the 'Hi Nurse' mobile application used in our study on MDRPI is beneficial in terms of clarifying issues related to MDRPI and contributing to science.

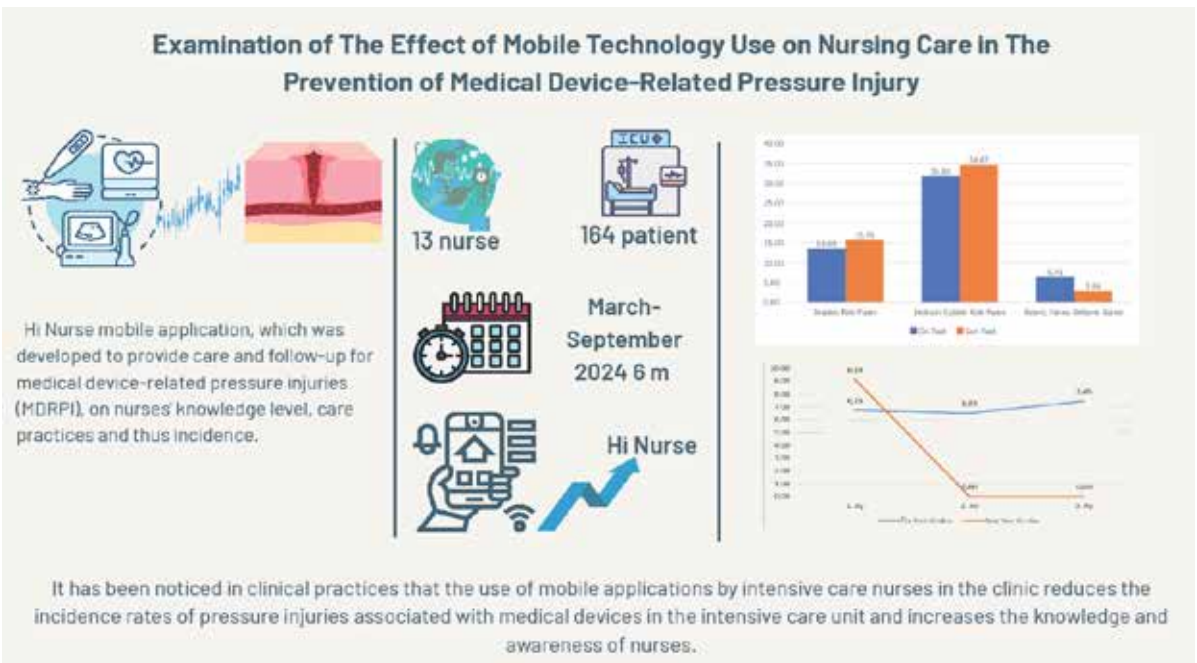

EP413 Thermal monitoring-assisted Er:Glass non-ablative fractional laser therapy for scar management using forward-looking infrared imaging in Asian skin

Eunji Jeong[1], Ha Jong Nam[2], Hwanjun Choi[1]

[1]Department of Plastic and Reconstructive Surgery, Soonchunhyang University Cheonan Hospital, Cheonan, Korea, Rep. of South, *[2]Department of Plastic and Reconstructive Surgery, Soonchunhyang University Gumi Hospital, Gumi, Korea, Rep. of South*

Aim: To evaluate the efficacy and safety of Er:Glass non-ablative fractional laser (NAFL) therapy for scar management in Asian patients, with adjunctive use of forward-looking infrared (FLIR) imaging to monitor thermal dynamics during treatment and to explore its potential role as an objective biomarker.

Method: This retrospective study included 55 patients with various scars who underwent Er:Glass NAFL therapy (1540 nm). FLIR thermal imaging was performed before treatment, immediately after irradiation, and 30 minutes post-procedure to quantify temperature changes (ΔT) (Fig. 1). Clinical outcomes were assessed at baseline and 1 month after treatment using the Vancouver Scar Scale (VSS), patient-reported pain scores, and satisfaction ratings. Safety was evaluated by documenting both immediate and delayed adverse events.

Results / Discussion: Patients (mean age 43.6 years, Fitzpatrick skin types III–IV) demonstrated significant improvements in scar erythema, pigmentation, and pliability. Mean VSS score decreased from 8.4±1.2 at baseline to 5.7±1.0 at 1 month ($p<0.001$) (Fig. 2). FLIR monitoring revealed a controlled temperature rise with mean ΔT of +1.3°C (range 0.6–2.0°C), which correlated with clinical improvement ($r=0.41$, $p=0.02$) (Fig. 3). Most patients tolerated treatment well; transient erythema and edema resolved within 48 hours without sequelae. Pain was generally mild (mean 3.2/10), and overall satisfaction was high, with 81.8% rating results as “good” or “excellent” (Table 1).

Conclusion: Thermal monitoring-assisted Er:Glass NAFL therapy is a safe and effective modality for scar management in Asian patients. Real-time FLIR imaging provides reproducible feedback on thermal response, offering a potential biomarker for both efficacy and safety. Incorporating thermal monitoring may optimize treatment parameters, enhance clinical outcomes, and expand precision-based strategies in laser scar therapy.

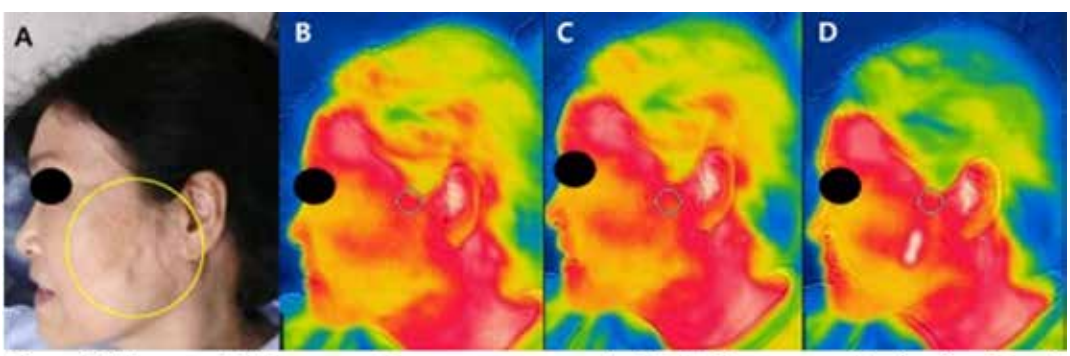

Figure 1. Representative case of scar management with Er:Glass non-ablative fractional laser therapy assisted by FLIR thermal monitoring.
(A) Baseline clinical photograph of an atrophic facial scar (yellow circle).
(B) Pretreatment FLIR image.
(C) Immediate post-treatment FLIR image showing controlled thermal elevation at the treated site.
(D) Thirty minutes post-treatment FLIR image demonstrating gradual return to baseline temperature.

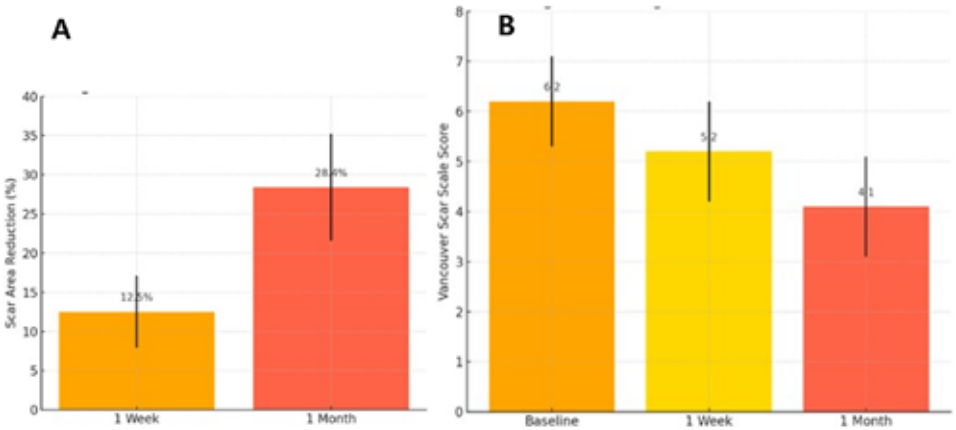

Figure 2. Quantitative outcomes of Er:Glass non-ablative fractional laser therapy with thermal monitoring.
(A) Scar area reduction (%) at 1 week and 1 month post-treatment, showing progressive decrease with a mean reduction of 28.4% at 1 month.
(B) Vancouver Scar Scale (VSS) scores at baseline, 1 week, and 1 month, demonstrating significant improvement from 6.2 to 4.1 ($p<0.001$). Error bars indicate standard deviation.

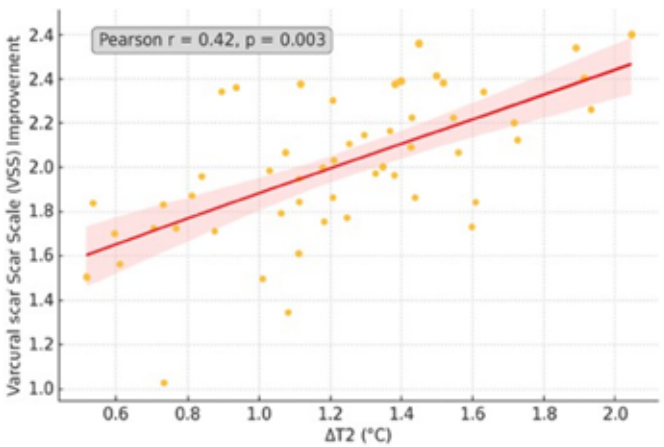

Figure 3. Correlation between thermal response and clinical improvement.
Scatter plot demonstrating the relationship between temperature elevation (ΔT_2) measured by FLIR thermal imaging and improvement in Vancouver Scar Scale (VSS) score at 1 month. A significant positive correlation was observed (Pearson r = 0.42, p = 0.003), suggesting that controlled thermal rise may predict better scar outcomes.

Table 1. Clinical outcomes after Er:Glass NAFL therapy with thermal monitoring (n=55)

Parameter	Baseline	1 month	p-value
VSS score (mean ± SD)	8.4 ± 1.2	5.7 ± 1.0	<0.001
Pain score (0–10)	–	3.2 ± 1.1	–
Patient satisfaction (good/excellent)	–	81.8%	–

EP076 Efficacy of combined non-ablative fractional laser and IPL treatment for improving skin graft donor site scars

Jongweon Shin[1]

[1]*Eunpyeong St. Mary's Hospital, College of Medicine, The Catholic University of Korea, Seoul, Korea, Rep. of South*

Aim: Skin graft donor site scars are a common concern, causing both aesthetic and functional issues that can significantly lower a patient's quality of life. Despite various treatments, achieving satisfactory results has often been challenging. This study evaluates the efficacy of combined non-ablative fractional laser (NAFL) and intense pulsed light (IPL) therapy for improving scars at skin graft donor sites.

Method: Eight patients who underwent skin graft surgery were enrolled. Their donor site scars were randomized into two halves: one received NAFL only, and the other received combined NAFL and IPL treatment. The treatments were administered at 4-week intervals for a total of 5 sessions, starting 4 to 12 weeks post-surgery. Patient satisfaction and scar characteristics (pigmentation, erythema, thickness, and texture) were quantitatively assessed using the Patient and Observer Scar Assessment Scale (POSAS).

Results / Discussion: Six months after the final session, the POSAS patient scale showed no statistical significance between the groups, though the combined treatment group showed a better trend (27.6 vs. 19.6, $p>.05$). However, the observer scale demonstrated statistically significant improvement for the combined treatment group (34.2 vs. 21.8, $p<.05$), and the total POSAS score also showed a significantly better outcome in this group (58.7 vs. 38.3, $p<.05$).

Conclusion: Combined NAFL and IPL treatment is effective for improving the pigmentation, erythema, thickness, and texture of skin graft donor site scars. This method can provide superior cosmetic outcomes compared to single-modality treatments and is expected to become a new standard in scar therapy.

EP414 Strategies for the prevention of pressure ulcers associated with non-invasive ventilation devices in intensive care: implementation of the TWI-JI methodology

Carlos Alves[1], Rui Pereira[2], Mariana Saraiva[3]

[1]*ARS Norte, USF Garcia de Orta, Matosinhos, Portugal*, [2]*Health Sciences Research Unit: Nursing, Nucleous U. Minho, Coimbra Nursing School, University of Coimbra, Coimbra, Portugal*, [3]*University of Minho, Nursing School, Braga, Portugal*

Aim: The problem of pressure ulcers (PUs) associated with medical devices represents a significant challenge in intensive care medicine. In an intensive care unit at a tertiary hospital, 44% of PUs identified were associated with devices, particularly non-invasive ventilation (NIV). The objective of this study is to propose and structure an intervention programme to reduce the incidence of PU in patients undergoing NIV through standardised training of the nursing staff.

Method: A critical analysis was conducted of the local occurrence of PU and scientific evidence on prevention. The proposed intervention focused on training nurses based on the Training Within Industry – Job Instruction (TWI-JI) methodology. This methodology was applied to teach and standardise preventive practices, such as the selection and correct adjustment of the NIV interface and continuous monitoring of the skin in areas at risk. The proposal includes the development of a practical training plan and the implementation of systematic audits.

Results / Discussion: The study culminated in the development of a structured Training Plan and a specific Audit Checklist to assess the compliance of PU preventive practices associated with NIV. This model, which includes practical demonstrations and direct supervision, ensures continuous reinforcement of training, consistency in the application of interventions, and feedback based on concrete data.

Conclusion: The integration of innovative supervision approaches, such as the TWI-JI methodology, together with periodic audits, is a robust and sustainable strategy. This standardised approach contributes significantly to professional development and is essential for reducing the incidence of PU in critically ill patients on NIV.

EP077 Application options for SpinCare© in children – An alternative to challenging dressing procedures?

Aileen Flach[1], Marcel Noatnick[1], Leila Harhaus-Wähner[2]

[1]Sana Klinikum Lichtenberg, Kinderchirurgie, Berlin, Germany, *[2]BG Klinikum Unfallkrankenhaus Berlin, Klinik für Hand-, Replantations- und Mikrochirurgie, Klinik für Schwerbrandverletzte und Plastische Chirurgie; Lehrstuhl für Hand-, Replantations-und Mikrochirurgie, Berlin, Germany*

Aim: The use of EHF-based technologies such as SpinCare© presents a promising alternative to conventional dressings, particularly for burn injuries located in difficult-to-treat areas such as the face, head, and genital region in children.

Method: This study is a retrospective in-house evaluation of SpinCare© application in 85 pediatric patients (average age: 14 months) treated within the past 22 months. We defined "difficult-to-treat areas" as the head, face, genitals, and buttocks—regions where standard dressing applications pose specific challenges in terms of hygiene, infection risk, and patient (or parental) compliance.

Results / Discussion: For second-degree burn wounds, SpinCare© proved to be a practical and significantly better-tolerated alternative to traditional dressings. This was especially evident in burns located on the head and face, where SpinCare© led to reduced pain and itching, while also supporting favorable cosmetic outcomes.

Conclusion: Very young children (particularly under 18 months of age) benefit greatly from SpinCare© treatment, as it supports a child-friendly daily routine—including activities such as breastfeeding and bottle feeding. Our evaluation demonstrates that SpinCare© is an effective and well-tolerated alternative for treating burns in anatomically sensitive or hard-to-dress areas.

EP078 Performance and user satisfaction with a superabsorbent dressing: Results from an international survey

Rebecca Rodger[1], Kara Buzza[1], Janet Mackenzie[2]

[1]Convatec Technology Centre, Deeside, United Kingdom, *[2]Convatec Technology Centre, Lexington, MA, United States*

Aim: To assess healthcare professionals' (HCPs) real-world experience with a multi-layered superabsorbent dressing* indicated for management of moderate-to-high exuding wounds.

Method: Between May–June 2024, a survey was distributed to HCPs across multiple European countries via an online electronic (n=46) and paper forms (n=6). The questionnaire focused on usage patterns, clinical performance, and improvement opportunities.

Results / Discussion: Fifty-two HCPs participated across France (73%), Poland (13%), UK (8%), and other countries (Czech Republic, Germany, Slovakia; each ~2%). Respondents primarily worked in clinics (41%) and hospitals (31%) and included nurses (83%), doctors (10%), and dermatologists (2%), with cumulative wound care experience >750 years. HCPs reported treating an average of 330 wounds each per year with the dressing, most commonly leg ulcers (n=8,247; 48%), followed by pressure injuries (n=3,317; 19%), diabetic foot ulcers (n=3,304; 19%), surgical wounds (n=896; 5%), and other wound types (n=1,482; 9%). Overall, 94% of respondents reported achieving the expected therapeutic benefit. High ratings of 'Very Good' or 'Good' were reported for exudate absorption and retention (both 100%), exudate absorption under pressure (98%), safety (94%), and usability (92%). Mean maximum wear time was 2.4 days (range: 1–7 days). Skin reactions were rare; 4 HCPs reported seeing allergic reactions in 0.5%–2% of their total patient population. Suggested improvements included anatomical shapes (heel, sacral; 19%), paediatric sizes (5%), odour control (5%), and enhanced border design to reduce shear (5%).

Conclusion: The superabsorbent dressing* demonstrated strong performance in exudate management and strong user satisfaction across multiple wound types and care settings. Future enhancements should focus on anatomical fit, paediatric needs, and additional functional features to further optimise clinical outcomes.

References:

*ConvaMax™ Superabsorber

EP415 Promoting cost-effective wound management with a novel point-of-care solution to streamline development of local wound care formularies

Elaine Song[1], Catherine T. Milne[2], Tiffany Hamm[1], Jeffrey Mize[1], Lawrence Meyers[1], Kimberly Harris[3], Amy Smith[4], Samantha Tucker[5], Lydia Ferreira[6], Alex Wong[7]

[1]WoundReference, Inc., San Francisco, United States, *[2]Connecticut Clinical Nursing Associates, Bristol, United States*, *[3]Newton Medical Center, Newton, KS, United States*, *[4]Bay Area Lean Institute, San Francisco, United States*, *[5]Onsite Wounds, Norman, OK, United States*, *[6]Federal University of São Paulo (UNIFESP), Sao Paolo, Brazil*, *[7]Keck School of Medicine of USC, Los Angeles, CA 90033, United States*

Aim: Local dressing formularies promote use of clinically appropriate and cost-effective products[1-3]. Despite its significant potential to impact on the bottom line, many institutions postpone their decision to create a local formulary, as the process is frequently regarded as time-consuming [1-4]. Once implemented, formularies are frequently saved as local files that need to be manually updated. We aimed to create a solution to simplify formulary development, implementation, and management.

Method: Using Design Thinking[5] the solution was developed as a module within a clinical/reimbursement decision support web-application* for wound care clinicians, as follows:

- Clinician needs/desired features were identified through interviews.
- The module was developed and implemented at a hospital-based outpatient wound clinic
    - Products, selected from ~1000 profiles in the module, were automatically categorized and listed in groups (e.g., alginates, foam).
    - Clinicians used the web-application's evidence, interactive matrices, and virtual advisory panel to select the best-fit products and eliminate redundancy within product groups.
    - Clinic added custom product instructions/educational notes to the digital formulary, creating a quick-reference manual for staff.
    - Clinic shared links to formulary with partnering institutions (e.g., Home-health agencies).

Results / Discussion: The module streamlined development of local wound care formulary through automatic product categorization, immediate access to critical formulary decision-making information, product-specific customized notes, and real-time interdepartmental collaboration. The process resulted in a 36% decrease in the number of products (from 67 to 43 across 22 categories), and inventory cost savings of 7%(US$35,888/year).

Conclusion: A solution to streamline creation of local wound care formularies was developed. Implementation resulted in inventory cost savings and increased staff efficiency. Its ease-of-use may significantly increase adoption of cost-effective formularies and maximize health outcomes.

EP079 Ablative fractional carbon dioxide laser improves wound healing and relieve pruritus in refractory recessive drystrophic epidermolysis bullosa: an exploratory study

Xiaoyi Liu[1], Junwen Ge[1], Pengjie Wan[1], Ruicheng Tian[1], Dan Deng[1]

[1]Department of Dermatology, Shanghai Children's Medical Center, School of Medicine, Shanghai Jiao Tong University, Shanghai, China

Aim: This study examined the therapeutic effects of ablative fractional carbon dioxide laser (CO_2AFL) on chronic wound healing and pruritus symptoms in patients with refractory recessive dystrophic epidermolysis bullosa (RDEB).

Method: Ten RDEB patients with 14 refractory wounds (lasting more than 6 months) received treatment with a 10,600 nm CO_2 fractional laser, followed by routine wound care.

Results / Discussion: The participants had a mean age of 11.0 ± 8.1 years (median age of 8.8 years) with an equal distribution of sexes. AFL treatment showed significant efficacy, as post-treatment evaluations indicated notable reductions in both wound area and color scores compared to baseline ($P = 0.017$ and $P = 0.006$, respectively).

Wound infections were controlled, and exudation improved significantly ($P = 0.002$). Current EB disease activity metrics showed substantial improvement, with more than a 50% decrease in the EBDASI activity score ($P < 0.005$) and a 34% reduction in the damage score ($P = 0.007$). Additionally, there were reductions in blistering frequency and pruritus VAS scores, along with a high mean patient/parent satisfaction rating of 3.5 ± 0.6.

Conclusion: The study demonstrated that ablative fractional carbon dioxide laser effectively promotes RDEB wound healing and achieves pruritus remission.

EP080 Assessing the impact of a muscle pump activator device on non-healing wounds in a NHS Health Board

Cheryl Lugton[1]

[1]*NHS Borders, Scotland, United Kingdom*

Aim: To evaluate the introduction of a Muscle Pump Activator (MPA) wound therapy device within an NHS Health Board as part of a service improvement initiative, assessing its potential to enhance outcomes for patients with hard-to-heal lower limb wounds.

Method: A review of the existing caseload identified patients suitable for MPA therapy. Eligibility included lower limb wounds of venous, mixed, or arterial aetiology that were not progressing after at least 28 days of optimal management. As the MPA device is patient-managed, only those able to apply and remove it safely, or supported by a carer, were included. Training was provided to staff and patients on device use. Baseline wound data was recorded, followed by weekly monitoring during treatment. Twelve patients with chronic, non-healing leg ulcers were enrolled. The evaluation involved multidisciplinary teams, including tissue viability, vascular services, and community nursing. Outcome measures included changes in healing trajectory, wound bed characteristics, pain levels, patient comfort and tolerance, and clinician-reported workflow impact.

Results / Discussion: The MPA device was easy to apply, required minimal training, and integrated effectively into existing care regimens. Patients generally tolerated the device well. Across the 12-patient cohort, early improvements in wound progression were noted. Clinicians also reported potential operational efficiencies, including reduced dressing change frequency. Based on these findings, the MPA device has been incorporated into the Health Board's lower limb wound management pathway.

Conclusion: This service improvement project suggests that the MPA wound therapy device is a feasible and valuable adjunct for managing non-healing lower limb wounds. Positive early clinical outcomes and workflow benefits support its continued use, alongside ongoing audit to assess long-term healing, recurrence rates, and broader service efficiency.

EP081 The first experience of using laser debridement and laser stimulation of reparative regeneration of chronic wounds in systemic pathology

Ivan Pikirenia[1], Irina Shestel[1], Validzhon Shoev[1]

[1]*State Institution «Minsk Scientific and Practical Center for Surgery, Transplantology and Hematology», Minsk, Belarus*

Aim: The purpose of this study is to demonstrate the first experience of using erbium laser debridement and MSRR (method for stimulating reparative regeneration) of chronic wounds in systemic pathology.

Method: From 2018 to 2025, 36 patients aged 21 to 73 years were treated with chronic wounds that developed against the background of systemic diseases (systemic sclerosis (9), rheumatoid arthritis (6), systemic vasculitis (6), systemic lupus erythematosus (3), and others (12).

Results: Laser treatment was performed against the background of systemic therapy of the underlying disease. Localization of chronic wounds is most often in the lower extremities, upper extremities, and trunk. 5 patients have

multiple localization. The size of the wounds is from 6 mm to 24 cm. In 31 patients, the previous standard treatment did not lead to wound healing. The first stage was debridation of the wound surface with erbium laser radiation (2.94 microns), followed by treatment using a special SMA nozzle that creates microablation zones with acoustic wave generation (Linline Medical Systems). Depending on the characteristics of the wounds, such treatment was performed from 1 to 23 times, starting, if necessary, with daily, and then once a week. The laser treatments were well tolerated and did not require anesthesia. There were no side effects or complications when using this technique. A positive trend was observed in 32 patients. In 19 cases, the wounds healed within 2 months.

Conclusion: The use of the developed laser MCRR for chronic wounds is safe, painless, easy to use, and does not cause side effects.

EP082 The autologous peripheral blood mononuclear cell therapy in no-option critical limb ischemia

Renzo Lombardi[1], Patrizia Dalla Caneva[2], Pierfrancesco Frosini[2], Stefano Michelagnoli[3], Claudia Lasagni[2]

[1]Nuovo San Giovanni di Dio, Firenze, Italy, *[2]Ospedale San Jacopo, Pistoia, Italy*, *[3]Ospedale Nuovo San Giovanni di Dio, Firenze, Italy*

Aim: Patients with critical ischemia who cannot be further revascularized and who have trophic lesions have a very poor quality of life due to pain. For several years, treatment with peripheral blood monocytes (Autologous Peripheral Blood-MonoNuclearCells), which have angiogenic and anti-inflammatory properties, has appeared to benefit these patients (both in terms of pain reduction and lesion improvement.

Method: We treated 130 patients with critical ischemia with rest pain and trophic ulcers. Two popliteal aneurysms were treated with two obstructed bypasses, even after ineffective fibrinolysis. The patients suffered from arterial hypertension, dyslipidemia, and diabetes mellitus. Of these, twenty were on dialysis and thirty eight had ischemic heart disease. All underwent at least one attempt at endovascular revascularization. All were treated with three cycles of monocyte infiltration. A 120 cc sample of peripheral blood was collected, filtered using a selective filtration system and implanted intramuscularly along the tibial vessels and peri-lesions 30 days apart.

Results / Discussion: Ten patients were eligible for major amputation. In 50 patients we had pain reduction, in 60 patients improvement of the lesions with complete healing in 30. 25 patients died during follow-up.

Conclusion: In our experience, monocyte treatment has shown good results in terms of improved lesion healing and, above all, a significant improvement in pain assessed by a visual analog scale (VAS). Patients who responded poorly to treatment were those undergoing dialysis. The procedure resulted in a reduction in major amputations, greater and faster healing of trophic lesions, reduction and resolution of pain, and improved peripheral oxygenation assessed by TcPO2.

EP083 The Role of Sensor Technology in Preventing Medical Device-related Pressure Injury Due to Continuous Positive Airway Pressure Respirator Use

Ayişe Karadağ[1], Beren Semiz[2], Ayşe Sılanur Demir Üçtepe[1], Fatma Yıldırım[3], Can Dimici[2], Hakan Ürey[2]

[1]Koç University, School of Nursing, Istanbul, Türkiye, *[2]Koç University, Electrical and Electronics Engineering, Istanbul, Türkiye*, *[3]Ankara Etlik City Hospital, Ankara, Türkiye*

Aim: This study aimed to develop a sensor-based monitoring system designed to detect early localized pressure elevations and the subsequent risk of pressure injury formation associated with Continuous Positive Airway Pressure (CPAP) mask use in patients undergoing non-invasive ventilation.

Method: Designed as a feasibility study, the project employed a system integrating a MAX30102 PPG sensor placed over the temporal artery and four thin-film force sensors located at forehead, chin, and bilateral zygomatic mask contact points. Ethical approval was granted, and all participants provided written informed consent. Following

preliminary testing in 20 healthy volunteers, clinical implementation included 43 adult patients newly started on CPAP therapy. Before system placement, demographic and clinical data were collected, and baseline skin moisture at the mask–skin interface was measured; moisture assessment was repeated immediately after monitoring to evaluate microclimate changes. Each patient was observed for at least 2 hours across three consecutive days. PPG signals were analyzed in 15-second windows relative to individualized baselines, and ≥20% deviation triggered a green-to-red LED transition indicating a high-pressure event.

Results / Discussion: The system captured synchronous mechanical pressure and IR/RED PPG alterations, enabling ON/OFF-based identification of pressure events. Chi-square analysis showed that total pressure duration, longest pressure duration, and mean RED/IR differences were the most discriminative features, yielding chi-square values of 6-10 ($p < 0.01$-0.001). Skin moisture rose significantly after CPAP monitoring, increasing from 52.9% to 59.7% ($p < 0.001$).

Conclusion: The prototype proved feasible, accurately detecting localized pressure elevations in real time and demonstrating strong potential as early-warning system for CPAP-related pressure injury prevention. Further studies with larger samples and refined algorithms are recommended to support clinical integration and automated decision-making.

EP084 Comparative results of electrospinning vs skin substitute in hand burns

Müge Sert[1], Alperen Pala[1], Gaye Filinte[1 2]

[1]Kartal Dr. Lütfi Kırdar City Hospital, Istanbul, Türkiye, *[2]University of Health Sciences, Kartal Dr. Lütfi Kırdar City Hospital, Istanbul, Türkiye*

Aim: To compare healing outcomes of an electrospun nanofibrous matrix vs a skin substitute in patients with partial-thickness hand burns.

Method: This retrospective study included 16 patients with second-degree hand burns treated at our center between 2024–2025. Patients were divided into two groups: skin substitute (n=8) and electrospun nanofibrous matrix (n=8) and were compared in epithelialization time, pain scores during the first 72 hours (Visual Analogue Scale, VAS), early mobilization of the hand, complications, and subsequent skin grafting.



Results / Discussion: Mean healing time in the nanofibrous matrix group was 6.1 days (±1.1) and 8.3 days (±1.3) in the skin substitute group, indicating faster epithelialization with the first group. Early mobilization was notably superior in the first group due to the ultrathin, flexible nanofiber layer that adhered closely to hand contours and tolerated movement without disruption. Patients treated with the skin substitute required more careful handling during the initial days, which limited early active range-of-motion exercises. Skin grafting was required in four patients overall, with three in the skin substitute group and one in the nanofibrous matrix group. No serious complications were observed in either group, and pain scores after the initial application were similar in both treatment modalities (VAS decreased from 7.2 to 3.3 in the nanofiber group and from 7.5 to 3.5 in the skin substitute group).

Conclusion: Both treatments provided safe and effective coverage for partial-thickness hand burns. The electrospun nanofibrous matrix demonstrated advantages in early mobilization and faster healing times, with a lower incidence of subsequent grafting. Despite its higher material cost, the nanofiber system showed better overall cost-effectiveness.

EP085 Multi-center, single-arm, prospective clinical study investigating the safety and effectiveness of ovine forestomach matrix in the Indian population

Barnaby May[1]

[1]*Aroa Biosurgery Limited, Auckland, New Zealand*

Aim: To evaluate the safety and effectiveness of various ovine forestomach matrix (OFM) products for managing acute and chronic wounds in the Indian population.

Method: Patients with acute or chronic wounds were prospectively enrolled into the study across four medical centers in India. Wounds were debrided as needed, then treated with antimicrobial single-layer OFM twice weekly, for a maximum of two weeks. Afterward, wounds received weekly single-layer OFM applications until considered suitable for multi-layer OFM device placement with suturing/stapling. Weekly assessments determined the need for a second multi-layer OFM application until 100% granulation tissue formation was achieved. Definitive closure occurred either by secondary intention with weekly single-layer OFM applications, or through split-thickness skin grafting (STSG). Demographics, wound characteristics, healing outcomes, and adverse events were analyzed.

Results / Discussion: One hundred patients were enrolled (74% male, 26% female), primarily middle-aged and of normal weight. Most wounds were traumatic (41%), followed by diabetic foot ulcers (17%) and soft tissue infections (15%). Wounds were predominantly located on the lower extremities (82%), were clean-contaminated (72%), and primarily chronic (median wound age of 4 weeks, IQR: 3, 9). Complete wound closure was achieved in a median of 9.02 (IQR: 5.56, 13.99) weeks. Full granulation tissue formation was attained in a median of 1.99 (IQR: 1.01, 2.13) weeks, and the median take of STSG at 1-week post-placement was 95 (IQR: 88.75, 100)%. No adverse events related to the OFM devices were observed.

Conclusion: OFM bioscaffolds are safe and effective for treating acute and chronic wounds in the Indian population.

EP086 Polylactic acid copolymer dermal substitute: preliminar retrospective study on lower limb ulcers

Stefania Chiarenza[1], Cecilia Muscarà[1], Loris Pelosi[1], Roberto Cassino[1], Francesca Turrini[1], Beatrice Mosca[1], Maria Teresa De Rose[1], Maria Castoldi[1], Simone Toscano[1], Francesca Misto'[1], Stefano Ghislanzoni[1], Michela Di Biasio[1], Luisa Asumaduh[1]

[1]*Gruppo San Donato, Milano, Italy*

Aim: This study investigates the efficacy of a polylactide polylactide/trimethylene carbonate/caprolactone- copolymer copolymer matrix in treatment of lower limb chronic ulcers (LLCU).

Method: The recruitment involved 222 patients 51-94 yo with LLCU with variable extension (4 to 500 cm^2) and different etiology: traumatic (10%), vascular (58%), pressure (3%), and autoimmune (15%).

All wound was necrotic/with biofilm or blocked in inflammatory phase.

All procedures and documentation were performed within standard treatment workflows.

Surgical debridement was performed and the DS was applied associated with inert secondary dressing and rigid bandage then discharge in 48-72 hours.

Follow-up was conducted on an outpatient basis, including wound assessment and dressing changes twice a week for 6-8 weeks.

Results / Discussion: In 63.1% of cases, we observed a stable permanence of the DS for 2-4 weeks.

In 36.9 % the DS was early removed (about 1 week) due to early degradation or appearance of perilesional maceration.

In all cases, improvement of the lesion base was observed.

Re-epithelialization at the edges, granulation tissue and dimensional reduction has been detected in approximately 80% of cases with complete healing in 7 patients.

A significant reduction in pain was also observed, with reduction in medication intake.

Conclusion: The polylactic acid copolymer DS has been demonstrated to be highly efficacious in promoting the healing of LLCU.

The retrospective design, the absence of a control group, and the lack of standardized quantitative assessment of wounds at fixed time intervals reduce the ability to draw causal or comparative conclusions. However, the results may guide the design of future prospective, controlled studies to further evaluate clinical outcomes and treatment pathways involving synthetic dermal matrices.

EP416 Use of a surgical glove as a sterile barrier for cold plasma handpiece without compromising functional performance

Yun-Nan Lin[1]

[1]Wesing Breast Hospital, Kaohsiung, Taiwan

Aim: To evaluate the feasibility of using a sterile surgical glove as a barrier method for cold plasma handpiece to facilitate aseptic wound procedures without affecting treatment efficacy or device output.

Method: A procedural assessment was performed in which a sterile surgical glove was placed over the handpiece during wound-care sessions requiring strict aseptic technique. The glove's elasticity allowed full coverage of the device body while maintaining tension-free contact over the active treatment panel. Treatment performance, airflow, plasma output, operator handling, and wound response were observed. No device modifications were made.

Results / Discussion: The glove barrier enabled seamless sterile-field integration and did not interfere with the device's functional surface. Plasma diffusion, visible emission characteristics, and treatment uniformity remained comparable to standard unshielded use. Handpiece handling and maneuverability were unaffected. No overheating, tactile impedance, or safety concerns were observed. Wounds treated under this sterile configuration demonstrated expected clinical responses with no increase in contamination risk.

Conclusion: Using a sterile surgical glove as a barrier for the handpiece is a practical and effective method to maintain aseptic conditions during wound procedures. This approach preserves full device functionality, enhances workflow in settings requiring sterile technique, and may serve as a simple, low-cost strategy for expanding cold plasma use in advanced wound care.

EP087 Enzymatic debridement in thermal injuries: A nationwide analysis of german inpatient care in 2024

Steffen Wahler[1], Christiane Koll[2]

[1]St. Bernward GmbH, Hamburg, Germany, *[2]Diabetespraxis Blankenese, Hamburg, Germany*

Aim: Enzymatic debridement is a selective, tissue-sparing alternative to surgical wound cleansing for thermal injuries. It can reduce the need for excision, preserve dermal structures, and improve functional and aesthetic outcomes. Despite increasing clinical adoption, population-based data on its real-world use in Germany remain limited. This study aimed to characterize patient demographics, clinical contexts, and hospital structures associated with enzymatic debridement for thermal injuries in 2024.

Method: Retrospective analysis of InEK hospital billing data for 2024 was performed. Included were inpatient cases with thermal injuries (ICD-10-GM T20–T31) and coded enzymatic wound management (OPS 8-191.70 ff). Variables extracted included case numbers, age and gender distribution, diagnosis patterns, DRG allocation, length of stay (LOS), comorbidities, and hospital characteristics. Analyses were descriptive.

Results / Discussion: In total, 325 inpatient cases with enzymatic debridement were identified. Children and adolescents representing 34.5% of cases, middle-aged adults (30–49 years) accounting for 26.8%, older adults (>65

years) comprised 18.8%. 69.5% male patients, consistent with international burn epidemiology. Common injury sites included the hand/forearm (11.7%), hip/leg (10.2%), and head/neck (7.4%). 51.1% of cases affected less than 10% of the body surface area.

Staphylococcus aureus was coded in 15.4% of cases, other staphylococci in 16.3%. Streptococci were coded in 22.9% of cases.

DRG allocation was dominated by Y03Z (28.6%), followed by Y01Z (24.6%) and Y02D (16.3%). Average LOS was 22.2 days (± 26.8). Treatment occurred primarily in public hospitals with >500 beds, specifically in defined burn centers.

Conclusion: Enzymatic debridement in Germany is mainly used in younger and male patient and predominantly in burn-centers. Its integration into established DRG structures underscores its growing role as a complementary approach to surgical burn care.

EP088 A mechanically-informed and infection-preventive care model for MCS driveline exit-sites: An integrated strategy for dressing, fixation and skin protection

Chin Wen Shiao[1]

[1]*National Taiwan University Hospital, Taipei City, Taiwan*

Aim: Mechanical circulatory support (MCS) driveline exit-site complications remain a major cause of hospital readmissions and morbidity. Traditional care pathways emphasize infection control; however, emerging evidence suggests that mechanical forces, skin stress, and medical adhesive–related skin injury (MARSI) equally contribute to chronic inflammation, granulation overgrowth, and misdiagnosed “driveline infections.” To address this gap, we developed an integrated, mechanism-based wound care model tailored for Taiwan’s humid climate and high-risk outpatient environment.

Methods: A conceptual framework was constructed based on literature review, clinical case analysis, and interdisciplinary practice (wound care, dermatology, and MCS teams). The model incorporates five components: (1) tube & skin cleaning, (2) wound antisepsis, (3) individualized dressing selection, (4) fixation strategy to reduce mechanical load, and (5) prevention of medical adhesive–related skin injury with concurrent skin care. Climate-specific and patient-specific factors (sweat, mobility, adhesive tolerance) were embedded into decision pathways.

Results: The model addresses recurrent clinical problems observed in MCS patients, including irritant contact dermatitis, exuberant granulation tissue, and chronic inflammatory changes refractory to antibiotics. It highlights mechanical stability and adhesive management as overlooked determinants of exit-site integrity. The framework supports daily patient self-monitoring, remote follow-up, and standardized documentation. It also provides guidance for selecting dressings with adequate breathability, moisture control, and secure adhesion in humid environments.

Conclusion: This integrated model reframes MCS driveline exit-site care as the intersection of infection prevention and mechanical load control. It offers a practical, adaptable structure for clinicians, improves consistency across institutions, and has potential to reduce long-term complications and healthcare costs. Further multicenter validation is recommended.

Keywords: Mechanical circulatory support, driveline exit-site, MARSI, fixation strategy, wound care model

EP089 Effectiveness of secretome gel in accelerating wound epithelialization

David Perdanakusuma[1], Ira Handriani[1], Hastika Saraswati[1], Yanuar Ari[1], Fiera Ferdianty[1]

[1]Department of Plastic Reconstructive and Aesthetic Surgery, Faculty of Medicine, Universitas Airlangga, Dr. Soetomo General Academic Hospital, Surabaya, Indonesia

Aim: This study aimed to rigorously evaluate the therapeutic efficacy and clinical benefits of a secretome gel in enhancing and accelerating the epithelialization process of acute wounds in human subjects.

Methods: A true experimental randomized controlled trial involving 15 patients was conducted at Dr. Soetomo General Academic Hospital from August 2023 to May 2024. Acute partial-thickness donor-site wounds (8 × 8 cm; depth 0.2 mm) created during split-thickness skin graft procedures were randomly allocated into two groups: (1) a control group receiving standard moist wound care with tulle gauze and (2) a treatment group receiving 9.1% secretome gel applied every 24 hours. Wound epithelialization was assessed using standardized photography, grid mapping, and digital planimetric analysis (Imito® Measure application) to quantify epithelialized and raw surface areas until day 5.

Results: A total of 15 eligible patients were included. The Secretome gel group demonstrated a pronounced and statistically significant acceleration of epithelialization. By day 5, treated wounds exhibited markedly smaller raw surface areas (mean 5.8 cm^2 vs 30.3 cm^2) and substantially higher epithelialization percentages (90.6% vs 49.5%; $p<0.001$) compared with controls. The consistently superior healing kinetics observed in the treatment group are indicative of enhanced regenerative and proliferative activity attributable to the bioactive paracrine factors present within the secretome gel.

Conclusion: The application of secretome gel demonstrated a statistically and clinically significant enhancement in epithelialization of acute wounds (donor-site wounds) compared with standard moist wound care. Patients treated with the secretome formulation exhibited a shorter time to complete re-epithelialization, more rapid wound surface coverage, and improved overall wound bed quality.

EP090 Gamechanger in wound care: calcium sulphate beads

Alperen Pala[1], Gaye Filinte[1 2], Müge Sert[1], Mertcan Rador[1], Cagla Cicek[1]

[1]Kartal Dr. Lütfi Kırdar City Hospital, Istanbul, Türkiye, *[2]University of Health Sciences, Kartal Dr. Lütfi Kırdar City Hospital, Istanbul, Türkiye*

Aim: Infection is a major factor that impairs wound healing by damaging tissue, promoting biofilm formation, and prolonging inflammation. Managing infection in chronic wounds remains challenging due to multidrug-resistant organisms and poor tolerance to prolonged systemic antibiotics. This study aims to evaluate the clinical effectiveness of antibiotic-loaded calcium sulfate beads in chronic wound management, with emphasis on infection control, wound bed preparation, and subsequent healing outcomes.

Method: A retrospective review was conducted on 17 patients with chronic wounds treated with antibiotic-impregnated calcium sulfate beads. Data collected included wound etiology, microbiological profiles, antibiotic combinations, and prior interventions. Clinical outcomes were assessed by measuring infection resolution, CRP trends, time to wound stabilization, grafting requirements, and complication rates.

Results / Discussion: After one week of treatment, CRP levels normalized in 15 patients, while 2 required additional intravenous antibiotic therapy. By week eight, 10 patients achieved complete wound closure. Five patients required a second application of calcium sulfate beads, and 2 underwent further reconstructive procedures. Use of calcium sulfate beads was associated with a measurable reduction in wound bioburden and improved wound bed quality, facilitating earlier progression to definitive closure in selected cases. Notably, significant wound contracture contributed to spontaneous closure without surgical intervention in some patients.

Conclusion: Calcium sulfate beads appear to be a promising adjunct in multidisciplinary chronic wound management. Their ability to deliver high local concentrations of antibiotics and disrupt biofilm makes them particularly

valuable in wounds complicated by infection or osteomyelitis, ultimately supporting more effective wound stabilization and closure.



EP091 Fluorescence-based in vitro detection of wound-associated bacteria with a handheld imaging system

Johannes Ruopp[1], Jonas Horn[1], Emil Paluch[2], Anna Dalinskaya[1], Finn-Ole Nord[1]

[1]CureVision GmbH, Munich, Germany, *[2]Wroclaw Medical University, Wroclaw, Poland*

Aim: Early detection of bacterial colonization is essential for accurate wound assessment and appropriate clinical management. Many wound-associated bacteria naturally produce molecules, which emit characteristic red or green fluorescence when excited with 405nm light. This study aimed to assess the capability of a handheld fluorescence imaging device to detect and quantify red, porphyrin-associated fluorescence from clinically relevant bacterial species under standardized in-vitro conditions.

Method: Twenty porphyrin-producing bacterial species relevant to wound care were cultured on agar supplemented with δ-aminolevulinic acid (ALA). After incubation, cultures were imaged using a hand-held fluorescence imaging system operating at 405 nm excitation. Both Red-Green-Blue (RGB) and fluorescence images were acquired. Fluorescence intensity was quantified by extracting grayscale pixel values from defined regions of interest and comparing them with non-inoculated control plates. Statistical analysis included the Wilcoxon signed-rank test and sign test. Species-specific fluorescence characteristics were assessed descriptively.

Results / Discussion: All twenty bacterial species produced detectable red fluorescence clearly distinguishable from the controls. Fluorescence intensities were significantly higher across all samples ($p < 0.001$), with a median intensity of 0.835 (IQR 0.630–0.975). Some species exhibited particularly strong fluorescence signals. The imaging system consistently detected porphyrin-associated fluorescence under ambient lighting conditions, and the acquired images allowed reliable quantification. These findings support the premise that porphyrin fluorescence can serve as a rapid optical indicator for numerous clinically relevant bacterial species.

Conclusion: This study shows that fluorescence imaging at 405 nm enables reliable and standardized detection of porphyrin-producing bacteria in vitro. The approach provides a rapid, non-invasive method for identifying bacterial colonization and offers a quantifiable fluorescence threshold that supports consistent assessment across different species, highlighting its potential value in wound diagnostics.

EP092 Topical oxygen therapy for pressure injury: a retrospective case series

Kyung Ah Lee[1], Dong Gyu Kim[1]

[1]Haeeundae Paik Hospital, Inje University, Busan, Korea, Rep. of South

Aim: Advanced pressure injuries (Stages 3 and 4) often exhibit delayed healing due to tissue hypoxia and a compromised wound environment. This study aimed to evaluate the clinical efficacy of topical oxygen therapy (TOT) in quantitatively reducing wound size and improving granulation tissue in these complex injuries.

Method: A retrospective review was conducted on 12 patients with Stage 3 and 4 pressure injuries treated with TOT. The mean patient age was 72 years. TOT was administered twice weekly for a total of 6 sessions. Negative pressure wound therapy (NPWT) was used concurrently in all cases. Clinical outcomes, including wound dimensions and tissue quality, were compared between baseline (pre-application) and 6 weeks after the initial application.

Results / Discussion: All 12 cases demonstrated significant clinical improvement at the 6-week assessment. The mean wound surface area decreased by 42.5% (from 35.2 cm^2 at baseline to 20.2 cm^2 at 6 weeks) (Fig 1). Furthermore, the quality of the wound bed improved markedly; the mean coverage of healthy, hyperemic granulation tissue increased significantly from 20% at baseline to 80% post-treatment ($p < 0.05$). Exudate levels progressively decreased, transitioning the wound environment from a stagnant state to one conducive to healing. No treatment-related complications were observed.

Conclusion: TOT effectively accelerates healing in Stage 3 and 4 pressure injuries within a 6-week period, evidenced by a quantitative reduction in wound size and a significant increase in healthy granulation tissue volume. These findings support TOT as a valuable adjunctive therapy for optimizing the wound environment in hypoxic, chronic pressure injuries.



Fig 1. Images before treatment and at 6 weeks after treatment.

EP093 Application of cold plasma in the preparation of total dehiscences for subsequent closure

Viviana Gonçalves[1], Paula Pena[1]

[1]*Centro Hospitalar e Universitário de São João, Porto, Portugal*

Aim: After solid, liquid, and gaseous, plasma is often considered the fourth state of matter. The most common method for producing plasma is through the use of electric fields or electromagnetic radiation to generate energy from a neutral gas, as well as chemicals processes, heating, or compression. The application of this technology in wound treatment is directly related to the ability of bacterial and viral activity suppression, without destruction of underlying structures. Complete dehiscence is very susceptible to the development of a higher bacterial load, which can lead to major infections and even death. The closure should be carried out as soon as possible in order to prevent this kind of situations.

Method: Case series, prevention of major complications of complete dehiscences, with application of cold plasma.

Results / Discussion: There were 7 cases, after cardiac surgery, with total dehiscence in the sternotomy, with bone visualization, 6 women and 1 man. After confirmation of the infection, the protocol of application of the technology was started 2 times a week, after which negative pressure therapy was applied. At the end of 4 weeks of multimodal therapy, the microbiology was negative and it was possible to make the closure, without major debridement and tissue loss, with application of incisional negative pressure therapy. All patients remained in the outpatient regime, with no worsening of the condition and no need for hospitalization.

Conclusion: The application of technologies that prevent long-term hospitalization, with a much higher direct and indirect cost associated, are essential to promote the quality of life of patients.

EP094 Two different approaches for wound granulation dermal matrix vs negative wound pressure therapy

Alperen Pala[1], Müge Sert[1], Gaye Filinte[1 2]

[1]Kartal Dr. Lütfi Kırdar City Hospital, Istanbul, Türkiye, *[2]University of Health Sciences, Kartal Dr. Lütfi Kırdar City Hospital, Istanbul, Türkiye*

Aim: Managing non-granulating complex wounds requires effective strategies that promote granulation and prepare the wound bed for closure. Two commonly used methods include negative pressure wound therapy (NPWT), which enhances granulation through controlled subatmospheric pressure, and synthetic dermal matrix substitutes, which facilitate neo-dermis formation through cellular infiltration. This study aimed to compare the clinical effectiveness, patient tolerance, and cost-related outcomes of these two approaches.

Method: Forty-three patients with complex wounds lacking adequate viable tissue for grafting were retrospectively reviewed and divided into two groups. Twenty-one patients received NPWT, while twenty-two were treated with a dermal matrix to achieve sufficient granulation tissue for autologous skin grafting. Outcomes analyzed included time to adequate granulation, time to grafting, graft viability, re-grafting requirements, treatment costs, and hospitalization duration.

Results / Discussion: The mean time to grafting was 22.6 days in the dermal matrix group and 25.6 days in the NPWT group, with similar granulation times across both treatments. Re-grafting was needed in 4 dermal matrix patients and 5 NPWT patients. Treatment cost showed a notable difference, averaging approximately 80,000₺ per patient for dermal matrix treatment compared with 20,000₺ for NPWT. Patient tolerance differed: 38% of NPWT patients reported discomfort, and frequent dressing changes every three days were inconvenient. Dermal matrices performed well in non-infected wounds due to their single, painless application, while in colonized wounds they often required multiple applications. NPWT demonstrated superior control of exudate and infection.

Conclusion: Both methods offer benefits in specific clinical contexts. NPWT is more effective for exudative or infected wounds, whereas dermal matrices are better suited for fragile wounds and wounds with exposed bone.



EP097 Progressive treatment path for chemical debridement and grafting: A case series

Miguel Angel Melado[1], Carmen Alba Moratilla[1], Mercedes Martinez[1], Bibiana Trevissor Redondo[2]

[1]Heridea Enfermeria Avanzada, Palencia, Spain, *[2]Department of Nursing and Physiotherapy, University of León, León, Spain*

Aim: The aim of this clinical investigation is to evaluate the safety and performance of a topical desiccating agent (TDA)(DEBRICHEM) for wound bed preparation, when used as part of a progressive treatment protocol for non-healing chronic wounds of the lower limb. The study further aims to determine whether TDA enhances graft success, accelerates wound improvement and supports market approval in additional regions.

Method: This is a clinical investigation using a CE-marked Class IIb medical device TDA in a structured treatment protocol. Ten adult patients with non-healing chronic wounds of the foot or lower leg were evaluated. Key exclusion criteria include ischemic ulcers without revascularisation, neoplastic wounds, underlying abscess or osteomyelitis, systemic antibiotic therapy, fever or sepsis, and pregnancy. The intervention consists of cleaning the wound, applying TDA for up to 60 seconds, rinsing for TDA neutralization, sharp debridement of desiccated material, and a fast-track autologous micrografting technique (performed in the same surgical act or delayed by a few days once an optimal wound bed is achieved). Follow-up assessments from weeks 1 to 12 include wound imaging (Moleculight), pH measurement, clinical signs of infection (NERDS and STONES), cultures, pain scoring (VAS), and Quality of Life questionnaires (DLQI and Wound QoL 17).

Results / Discussion: Results from the 10 evaluated patients over a 12-week period demonstrated a rapid and significant clinical improvement. Initial high pain levels (VAS 8-9) decreased drastically by week 1 (mostly dropping to VAS 3-5) and practically disappeared by week 12 (VAS 0-1). Clinical signs of infection strongly correlated with objective measures: baseline NERDS (3-4) and STONES (1-4) scores dropped to 0 for most patients between weeks 1 and 4. Similarly, bacterial presence was visually confirmed by Moleculight, which was positive in 90% of patients at day 0—supported by positive cultures for pathogens like *S. aureus*, MRSA, *E. coli*, *Serratia*, and *Pseudomonas aeruginosa* - but became completely negative for all patients by week 4. Wound bed pH, initially highly alkaline (ranging from 7.39 to 9.63 at day 0), progressively acidified towards physiological levels (5.48 to 7.14) by week 12. Consequently, quality of life showed dramatic improvements from day 0 to week 12, with DLQI scores decreasing from a baseline of 10-25 down to 2-11, and Wound QoL 17 reducing from 1.64-2.88 down to 0.41-1.58. By week 12, 50% of the patients achieved complete wound closure (0 cm^2 area), and the remainder showed a significant reduction in wound size, with 0% reporting allergic reactions.

Conclusion: The use of TDA combined with a fast-track autologous micrografting technique demonstrates an excellent safety profile and highly effective wound bed preparation. The strong correlation between the rapid reduction in pH, the clearance of bacterial load (confirmed by Moleculight and cultures), and the resolution of clinical infection signs (NERDS and STONES) directly translates into accelerated wound closure, immediate pain relief, and a vastly improved quality of life for the patients.

EP095 Photobiomodulation with blue light for scleroderma ulcers

Giuliana Elisabetta Bruno[1]

[1]Università Degli Studi di Torino, Orbassano, Italy

Aim: Evaluate efficacy of blue-light PBM in the management of scleroderma digital skin ulcers, a frequent and debilitating complication of systemic sclerosis

Photobiomodulation (PBM) with blue light has is a promising adjunctive modality capable of modulating cellular activity and promoting tissue repair and inflammatory process control.

Method: Observational study conducted on 16 patients presenting with scleroderma-related digital ulcers. Treatment protocol: 2 PBM sessions/week, each lasting 120 seconds, applied directly to the lesion following standard wound bed preparation and routine dressing. Each patient received between 16 and 24 sessions. Clinical parameters

assessed included pain intensity, measured using the Visual Analogue Scale (VAS), and ulcer size reduction. Data were collected weekly and analysed at baseline (T0), and after 4, 8, and 12 weeks (T12).

Results / Discussion: At baseline, all patients exhibited acral ulcers with a fibrinous base and severe pain (mean VAS 9). The mean ulcer area was 0.54 cm^2 (range 0.12-1.12 cm^2). After 4 weeks, 11 patients showed a reduction in lesion size (mean 0.48 cm^2), while 5 showed no change. At 8 weeks, all patients demonstrated significant improvement, with a mean ulcer area of 0.29 cm^2 (range 0.80-0.02 cm^2). After 12 weeks, four ulcers had completely healed (25%) and the remaining lesions further decreased in size (mean 0.12 cm^2; range 0.64-0.02 cm^2). Pain progressively decreased in all patients, with mean VAS scores of 4 at 4 weeks and 3 at both 8 and 12 weeks. No adverse effects or treatment-related complications were reported.

Conclusion: These findings suggest that blue-light PBM may beneficially influence ulcer evolution in scleroderma, promoting faster healing, reducing lesion size, and improving pain control.

References: Photobiomodulation EmoLED®

EP096 Fragmented dermo epidermal units for the treatment of no healing wounds

Renzo Lombardi[1]

[1]*Nuovo San Giovanni di Dio, Firenze, Italy*

Aim: Chronic wounds are defined as wounds that have failed to progress through the healing process in an orderly and timely manner. A chronic wound is one that generally does not heal within 8 weeks. More common in the elderly and those suffering from diabetes, peripheral arterial disease and obesity. Chronic ulcers represent a major economic and social problem. Regenerative medicine allows in many cases to bring about the healing of chronic ulcers. The fragmented dermo epidermal units It appears to lead to healing of chronic lesions.

Method: We treated 6 patients with chronic ulcer legs (4 patients with venous insufficiency, 2 diabetic). The mean size of the lesions was 10 cm2. All the interventions were carried out in the operating room, we took a small fragment of skin (2 cm2) from the inguinale region and fragmented it together with 10 cc of saline solution in the device for 60 seconds. The liquid obtained with inside dermo epidermal units It has been used (after ulcer debridement) to infiltrate the inside of the lesion and the perilesional area using collagen as a scaffold.

Results / Discussion: The 4 patients with venous ulcers healed 40 days after treatment, reduction in the size of the lesion in the 2 diabetic patients.

Conclusion: In our experience the use of fragmented dermo epidermal units It has proven to be a safe, minimally invasive, simple procedure capable of promoting the healing process of chronic ulcers.

DIABETIC FOOT

EP417 Clinical analysis of the communicating artery between the dorsal and plantar aspects of the foot

Eunji Jeong[1], Ha Jong Nam[2], Hwanjun Choi[1]

[1]Department of Plastic and Reconstructive Surgery, Soonchunhyang University Cheonan Hospital, Cheonan, Korea, Rep. of South, *[2]Department of Plastic and Reconstructive Surgery, Soonchunhyang University Gumi Hospital, Gumi, Korea, Rep. of South*

Aim: To investigate whether patency of the communicating artery between the dorsal and plantar arterial systems (Fig.1.) influences wound healing and symptom relief after percutaneous transluminal angioplasty (PTA) in patients with critical limb ischemia (CLI).

Method: We retrospectively reviewed 120 patients with CLI who underwent PTA for lower extremity ischemia between 2016 and 2018. Patients were stratified by communicating artery patency (Fig.2), and outcomes were assessed during 6 months of follow-up. Wound healing was defined as complete closure without recurrence and evaluated by Rutherford, University of Texas, and Wagner classifications, while symptom relief was measured by changes in Rutherford grade.

Results / Discussion: Among 120 patients, 87 presented with ischemic wounds and 33 with symptoms only. In the wound cohort, 34 patients had a patent communicating artery and 53 had non-patency (Table1). Complete wound healing within 6 months occurred in 29/34 patients (85.3%) with patency, compared with 16/53 patients (30.2%) without patency ($p<0.001$). In the subgroup of indirect revascularization (n=38), 18/21 patients (85.7%) with patency achieved full healing, versus 3/17 (17.6%) without patency ($p<0.001$). Most patients with patency healed within 12 weeks, requiring only minimal dressing. Symptom relief was observed in 100% of patients with patency and 75.0% without, though not statistically significant ($p=0.156$). Hypertension and renal dysfunction were associated with lower patency rates (Table2).

Conclusion: Patency of the communicating artery significantly enhances wound healing following PTA, especially when only indirect revascularization is feasible. Assessment of this vascular connection provides valuable prognostic information and should be considered when planning revascularization and reconstructive strategies in CLI patients. From a reconstructive perspective, ensuring pedal–plantar linkage can reduce relapse, broaden therapeutic options, and support multidisciplinary limb salvage strategies.

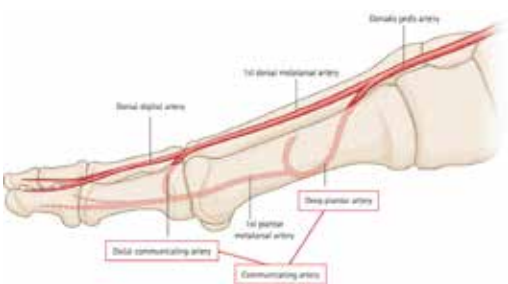

Figure 1. Anatomical diagram of the communicating artery between the dorsalis pedis and plantar arterial systems, consisting of the distal communicating artery and the deep plantar artery. These connections play a crucial role in collateral circulation of the forefoot.



Figure 2. Representative angiographic findings of the communicating artery.
(A) Preoperative angiography demonstrating the dorsalis pedis artery and the distal communicating branch (red asterisk).
(B) Absence of plantar arterial filling before percutaneous transluminal angioplasty (PTA)
(C) Retrograde filling of the plantar artery through the distal communicating artery after PTA.
(D) Enhanced plantar perfusion observed two seconds after contrast injection, confirming re-established dorsal–plantar communication.

Table 1. Baseline characteristics of patients according to communicating artery patency

Characteristic	Communicating artery patency		
	Yes	No	p-value
No. of patients	43	77	
Sex			
Male	29 (67.4)	67 (87.0)	0.01
Female	14 (32.6)	10 (13.0)	
Age (yr)	69.6 ± 10.4	71.8 ± 10.0	0.25
Height (cm)	161.8 ± 8.0	162.6 ± 8.2	0.597
Weight (kg)	60.0 (53.0–67.9)	62.0 (55.0–72.7)	0.151[a]
BMI (kg/m^2)	24.6 ± 4.0	23.0 ± 3.4	0.029
ABI			
1	2 (5.4)	4 (6.9)	>0.999[b]
2	16 (43.2)	25 (43.1)	
3	19 (51.4)	29 (50.0)	
Lower extremity			
Left	20 (46.5)	34 (44.2)	0.804
Right	23 (53.5)	43 (55.8)	

Values are presented as number only, number (%), mean±standard deviation, or median (interquartile range). BMI, body mass index; ABI, ankle-brachial index.
ABI: 1, >1.3 (vessel hardening); 2, 0.9-1.3 (normal); 3, <0.9 (arterial disease).
[a]Mann-Whitney test, [b]Fisher exact test.

Table 2. Wound healing and symptom relief according to communicating artery patency

Variable	Communicating artery patency		
	Yes	No	p-value
Wound healing			
Yes	29 (85.3)	16 (30.2)	<0.001
No	5 (14.7)	37 (69.8)	
Symptom relief			
Yes	9 (100)	18 (75.0)	0.156
No	0 (0)	6 (25.0)	

Values are presented as number (%).

Revascularization	Wound healing		
	Yes	No	p-value[a]
Patent	18 (85.7)	2 (11.8)	<0.001
Non-patent	3 (14.3)	15 (88.2)	

Values are presented as number (%).
[a]Fisher exact test.

EP098 A case report of a person with a high-risk foot complicated with developing an intracranial absess and verrucous squamous cell carcinoma transformaion in a previous transmetatarsal amputation

Donna Larsen [1], Rachel Carle[2]

[1]*Board member International Wound Infection Insitute, Editorial Board Wound Practise and Research, Perth, Australia*, [2]*Royal Perth Hospital, Perth, Australia*

Aim: Our case highlights the complexity of managing patients with a high-risk foot. Malignant transformation is often underdiagnosed due to the clinical appearance similar to verrucous hyperplasia. We illustrate in the same patient the complexity of life threatening disseminated multisite methicillin-susceptible *Staphylococcus Aures* (MSSA) infection leading to intracranial abscess.

Method: Verrucous squamous cell carcinoma is a variant of a cutaneous squamous cell carcinoma. Human papilloma virus and abnormal expression of the p53 tumor suppressor protein are a potential cause for pathogenesis. This gentleman had previous minor amputations, cumulating in a trans metatarsal amputation, life-threatening infections including a disseminated multisite methicillin-susceptible *Staphylococcus aureus* (MSSA) bacteremia requiring intensive care support, and five burrhole procedures for drainage of intercranial abscess. The verrucous carcinoma (VC) developed over a previous amputation site.

Results / Discussion: The VC tumor gradually increased in size taking on a warty like appearance, metastases is a rare occurrence, and the survival rate is high. The lesions can invade the plantar fascia and can cause destruction of the metatarsal bones. There can be a delay in diagnosis as the lesions present like verruca plantaris, actinomycosis, pseudoepitheliomatous hyperplasia and plantar fibromatosis. What is crucial is a biopsy taken correctly for histopathology to minimise false negative results, this will avoid delays in diagnosis and appropriate treatment. Wide surgical excision and Mohs micrographic surgery is the primary treatment choice.

Conclusion: Our case highlights the complexity of managing patients with a high-risk foot. He is fortunate he survived a life-threatening infection that involved seeding to three different anatomical locations including a left frontal lobe abscess that required five burrhole drainage as well as a malignant transformation of his wound.

EP099 Outcome of autologous split-thickness skin graft surgery in patients with infected wounds and type 2 diabetes mellitus

Bat-Orgil Enkhbayar[1]

[1]*National center for Traumatology and Orthopedics (NCTO), Ulaanbaatar, Mongolia*

Aim: To evaluate clinical outcomes of autologous split-thickness skin grafting (STSG) in patients with infected wounds and Type 2 Diabetes Mellitus (T2DM), focusing on infection characteristics, graft take rate, and related clinical factors. Ointment containing β-Sitosterol was applied as part of standard wound care before and after surgery.

Method: A retrospective descriptive study was conducted at the Burn Center of NCTO between February 2024 and September 2025. Forty-four inpatients meeting inclusion criteria were analyzed. Data collected included demographics, diabetes status, infection type, wound characteristics, and perioperative laboratory parameters. Statistical analysis was performed using SPSS version 26.0.

Results / Discussion: The mean age was 50.4 ± 13.0 years, and 65.9% were male. 16 (36.4%) patients were newly diagnosed with T2DM. The average hospital stay was 22.2 ± 10.5 days. Significant postoperative reductions were observed in blood glucose (9.3 → 6.56 mmol/L), WBC, and CRP levels ($p<0.001$). Pathogens were detected in 72.7% of wounds, predominantly MRSA, Pseudomonas aeruginosa, and Acinetobacter baumannii. The graft take rate was ≥75% in 84.1% of cases. Poor graft adherence was associated with large wound size (≥200 cm^2), persistent infection, and inadequate glycemic control.

Conclusion: Autologous STSG combined with ointment containing β-Sitosterol is effective in promoting wound healing, scarring, and controlling infection in diabetic patients. Early surgical intervention, strict glycemic management, and infection control are crucial for successful outcomes.















EP418 Effects of electrical muscle stimulation on hemodynamic performance and muscle strength in diabetic patients with lower extremity arterial disease

Shinobu Ayabe[1]

[1]*Yao Tokushukai General Hospital, Osaka, Japan*

Aim: Patients with lower extremity arterial disease (LEAD) frequently develop muscle weakness due to disuse. Although exercise therapy is recommended, ischemic pain and intermittent claudication often limit loading-based training. Electrical muscle stimulation (EMS) enables passive muscle activation without walking or weight-bearing. This study aimed to evaluate the effects of EMS on muscle strength and blood flow in patients with LEAD.

Methods: An EMS device (SIXPAD Foot Fit) was applied to the foot sole to induce contraction of lower-limb muscles. Six patients received bilateral EMS for 23 minutes, three times per week, over eight weeks. Hemodynamic parameters—including peak venous velocity (PV), time-averaged mean velocity (TAMEAN), and flow volume (FV)—were measured at baseline, 4 weeks, and 8 weeks. Additional assessments included skin perfusion pressure (SPP), dorsiflexion and plantarflexion strength, toe-grasping strength, and soleus muscle thickness.

Results / Discussion: EMS produced significant increases in TAMEAN and FV compared with rest and voluntary contraction at all time points. Dorsal SPP increased significantly from baseline at 4 weeks (56.0 ± 7.9 mmHg) and 8 weeks (55.6 ± 9.5 mmHg). Plantarflexion strength improved significantly at 8 weeks (15.4 ± 2.1 kg) compared with baseline (13.0 ± 3.0 kg). These findings indicate that EMS enhances venous return, microcirculation, and muscle performance even in individuals with limited mobility.

Conclusion: EMS improved lower-limb arterial and venous hemodynamics and increased plantarflexion strength in LEAD patients. This study is the first to demonstrate EMS-induced enhancement of skin perfusion pressure in hemodialysis patients with LEAD. EMS may represent a useful adjunctive therapy for conditions involving chronic arterial and venous insufficiency, although larger studies are needed to confirm long-term clinical benefits.

EP419 Association between diabetes-related lower-extremity amputations and renal function: An observational, single-center, retrospective cohort study

Hong-Wei Liu[1]

[1]*Department of Plastic and Reconstructive Surgery, The First Affiliated Hospital of Jinan University, Guangzhou, China*

Aim: The study aimed to analyze the effect of the lower extremity amputation (LEA) on renal function in diabetic patients with renal insufficiency, focusing on the changes of the estimated glomerular filtration rate (eGFR) and associated inflammatory indicators pre- and post-amputation.

Method: A retrospective cohort study analyzed 240 patients with diabetic foot ulcer (DFU) between 2020 and 2023 at a single university center for treating diabetic foot. Patients were categorized into five groups based on baseline eGFR and into three groups according to post-amputation changes in eGFR (improvement, stability, and deterioration). Univariate and multivariate logistic regression analyses were performed to identify predictors of renal function changes following amputation. Key inflammatory markers evaluated included white blood cells, neutrophil count, neutrophil percentage, neutrophil-to-lymphocyte ratio, and C-reactive protein (CRP).

Results / Discussion: Lower baseline eGFR was associated with a higher risk of major amputation and more severe DFUs. Post-amputation, 66.2% of patients exhibited improved eGFR, with reductions in serum creatinine, blood urea nitrogen, cystatin C, and inflammatory indicators such as CRP. Multivariate analysis was identified by changes in ΔCRP as a significant predictor of post-amputation renal function changes.

Conclusion: LEA in patients with DFU, particularly those with renal insufficiency, may improve renal function post-amputation, likely due to reduced systemic inflammation. Monitoring CRP and other inflammatory markers before and after amputation could help optimize management strategy in this high-risk population.

EP100 compression therapy in diabetic foot ulcers: Implementation and clinical outcomes in a multidisciplinary diabetic foot unit

Natalia Maella-Rius[1], Anabel Palma[2], Francesc Monés-Serrano[2], María Sol Batule Nallim[3]

[1]*Advanced Practice Nurse. Diabetic Foot Unit. Germans Trias i Pujol Hospital, Badalona, Spain*, [2]*Podiatrist. Diabetic Foot Unit. Germans Trias i Pujol Hospital, Badalona, Spain*, [3]*Endocrinologist. Diabetic Foot Unit. Germans Trias i Pujol Hospital, Badalona, Spain*

Background: The use of compression therapy in diabetic foot ulcers (DFUs) remains controversial, particularly in the presence of neuropathy, neuroischaemia, or complex postoperative conditions. Despite the frequent coexistence of oedema and venous insufficiency, compression is still underused due to safety concerns. Evidence from real-world clinical implementation in multidisciplinary diabetic foot units is limited.

Aim: To evaluate the feasibility, safety and clinical outcomes of implementing compression therapy as part of routine care for patients with diabetic foot ulcers in a multidisciplinary setting.

Methods: A descriptive clinical evaluation included patients with neuropathic or neuro-ischaemic diabetic foot ulcers, with or without oedema. Vascular assessment consisted of distal pulse examination, with ultrasound evaluation performed when pulses were not detected. Thirty consecutive patients with DFUs were included. Mean age was 68 years, and 80% were male. Ulcer aetiologies included neuropathic, neuroischaemic, post-surgical wounds, and Charcot neuroarthropathy–related lesions. Compression therapy was individually adapted to limb perfusion status and delivered using short-stretch bandages or multicomponent compression systems combining short-stretch and long-stretch components, either as a kit or a single-bandage system. Compression levels were adapted to vascular status, ranging from low to moderate compression (approximately 10–40 mmHg). Compression therapy was incorporated into broader treatment plans that included negative pressure wound therapy, skin punch grafting, advanced offloading and biomechanical optimization. Outcomes assessed included safety, tolerance, adherence and clinical evolution of wound healing.

Results: Compression therapy was successfully implemented in all 30 patients. Clinical effects consistent with compression therapy, including reduction of oedema, improved peri-wound stability and better exudate control, were consistently observed during follow-up. Therapeutic adherence to compression was high, and dressing-change intervals could be safely extended, contributing to greater continuity of care. No cases of ischaemic deterioration, increased pain or tissue loss occurred.

Conclusion: Personalized compression therapy is a safe and effective adjunct in diabetic foot ulcer management when guided by structured vascular assessment and integrated into a multidisciplinary care pathway. This clinical experience also led to the development of a standardized protocol to support implementation of compression therapy within the unit. Further research is warranted to define optimal compression strategies and quantify outcomes in neuropathic and neuro-ischaemic diabetic foot ulcers

EP101 Shared decision-making: Co-designing patient decision aids for offloading choices in diabetic foot care

Annabel Bourgault[1 2], Magali Brousseau-Foley[1 3 4], Anik Giguère[2 5], Diana Zidarov[6 7], Gabriel Moisan[1], Jean-Pierre Bureau[2], Laura Drudi[8 9], Amédé Gogovor[2 5], Jérôme Patry[2 5], Virginie Blanchette[1 2 10]

[1]Département des Sciences de l'Activité Physique, Université du Québec à Trois-Rivières, Trois-Rivières, Canada, *[2]VITAM; Centre de Recherche en Santé Durable, Québec, Canada*, *[3]Centre Intégré Universitaire de Santé et de Services Sociaux de la Mauricie et du Centre-du-Québec (CIUSSS MCQ), Trois-Rivières, Canada*, *[4]Département de Médecine de Famille et de Médecine d'Urgence, Faculté de Médecine de l'Université de Montréal, Montréal, Canada*, *[5]Département de Médecine de Famille et de Médecine d'Urgence, Faculté de Médecine, Université Laval, Québec, Canada*, *[6]Centre de Recherche Interdisciplinaire en Réadaptation du Montréal Métropolitain (CRIR), Montréal, Canada*, *[7]École de Réadaptation, Faculté de Médecine, Université de Montréal, Québec, Canada*, *[8]Département de Chirurgie, Centre Hospitalier de l'Université de Montréal, Montréal, Canada*, *[9]Carrefour de l'innovation, Centre de Recherche du Centre Hospitalier de l'Université de Montréal, Montréal, Canada*, *[10]Centre de Recherche du Centre intégré de Santé et Services Sociaux de Chaudière-Appalaches (CISSS-CA), Lévis, Canada*

Aim: The aim of this study was to co-design two patient decision aid (PtDAs) tools to support people with diabetes who have either active or in remission forefoot ulcers in choosing their offloading options.

Method: This mixed-method study was guided by the Ottawa Decision Support Framework, the International Patient Decision Aids Standards (IPDAS) guidelines, and a user-centered design approach. Content was informed by a rapid review and clinical guidelines. A French-speaking international steering committee of researchers, patient partners, and clinicians (n = 10) contributed to prototype development.

Alpha testing (usability and comprehensibility) was conducted in real-world clinical settings with patient-clinician dyads. Each dyad used the PtDAs during consultations and participated in individual think-aloud interviews followed by a usability questionnaire. Data saturation determined a sample size of seven patients and five podiatrists. The quantitative analysis was guided by a predefined quality threshold of 80%. Feedback informed iterative refinements of the PtDAs in collaboration with the steering committee.

Results / Discussion: The alpha testing provided valuable feedback on the PtDAs' usability, clarity, and comprehension. Observations and feedback helped define recommendations for future implementation, such as offering patients the opportunity to review the tool before their appointment to prepare questions and strategies to integrate the tool during consultations, thereby optimizing the clinical encounter. Final versions (one for active ulcers and one for remission) were refined through a consensus-based process and integrated into a digital platform, also available as downloadable PDFs.

Conclusion: We produced the first PtDAs designed to foster patient engagement and understanding when choosing among offloading options for diabetic foot management with their care partners. Through co-design, our PtDAs are better aligned with patients' needs and priorities.

EP102 Efficacy of the validated achiles (aetiology circulation history infection load education sensation) tool

Elizabeth Merlin-Kwan[1], Nichola Beard[1]

[1]NHS, Shropshire & Telford Hospitals NHS Trust, United Kingdom

Aim: Heel ulcers in people with diabetes are particularly prone to misclassification, often due to overlapping features of pressure-related and non-pressure-related pathology. These variations contribute to inconsistent reporting and management.

Current estimates suggest that diabetic foot complications, including heel ulcers, cost the National Health Service approximately £1 billion annually, due to extended treatment, increased resource use and preventable complications. Demonstrating the efficacy of the ACHILES tool aims to show enhanced diagnostic accuracy and support more cost-effective care.

Method: Hospital practice was compared pre and post 12 months of routine use of the ACHILES tool. Data collection was facilitated using an electronic form to support consistency and ease of use in accordance with relevant NICE guidelines to evaluate the extent to which current practices align with standards.

Outcome measures included the percentage of patients receiving a compulsory foot assessment within 24 hours; the rate of referral to specialist podiatry services and the proportion of at-risk individuals issued offloading devices.

Results / Discussion: The audit demonstrated improvements in early identification, intervention and appropriate referral for heel ulcers in people with diabetes. Compulsory diabetes foot assessment on admission increased by 50% while correct referrals to the multidisciplinary foot team improved by 21%.

Provision of heel pressure relief for high-risk patients, in line with NICE guidance, increased from 8% to 51%, reflecting enhanced adherence to best practice standards.

Conclusion: The efficacy of the validated ACHILES tool has clearly been demonstrated and can be used with confidence to improve timely appropriate diagnosis, referrals and treatment.

EP103 Efficacy of enzyme alginogel with hyluronic acid in management of diabetic foot ulcers

Mohamed Mosadak[1], Sameh Elimam[2], Mohamed Hamza[2], Tamer Ezzat[3]

[1]Kafr Elsheikh University Hospitals, Kafr Elsheikh, Egypt, *[2]Ass. Prof. Vasc. Surg, Alazhar University, Cairo, Head of Vasc. Surg. Department. Aldoah Islamic Hospital, Cairo, Egypt*, *[3]Ahmed Maher Teaching Hospital, Cairo, Egypt*

Aim: Evaluation of clinical efficacy and safety of a combined topical regimen of enzyme-based alginogel and hyaluronic acid in the management of Diabetic foot ulcers.

Method: A prospective, interventional clinical study was conducted on 50 patients with type 2 diabetes mellitus and Wagner grade I–III DFUs attending diabetic foot clinic at Diabetic foot clinics. All patients received daily local application of enzyme alginogel with hyaluronic acid. Patients were monitored over a 12-week period. Primary endpoints included percentage reduction in ulcer area and rate of complete healing. Secondary endpoints comprised time to granulation tissue formation, infection resolution, and treatment-related adverse events.

Results / Discussion: Of the 50 enrolled patients, 46 completed the study protocol. The mean ulcer surface area demonstrated a significant reduction, with an average decrease of 70.4 ± 12.6% at week 12 ($p < 0.001$). Complete epithelialization was achieved in 28 patients (56%), while partial healing (>50% reduction in area) occurred in 14 patients (28%). Early and sustained granulation tissue formation was observed in the majority of cases, typically within the first four weeks. Clinical signs of local infection markedly improved without the need for systemic antibiotic escalation in most patients. Treatment was well tolerated; only two cases (4%) reported mild transient local irritation, and no serious adverse events were recorded.

Conclusion: Topical therapy combining enzyme alginogel and hyaluronic acid appears to be a safe, well-tolerated, and clinically effective option for promoting healing and infection control in diabetic foot ulcers. The synergistic effects of Autolytic debridement and hyaluronic acid–induced tissue regeneration contribute to enhanced wound closure rates.

EP104 Time to heal reduction by oxygen therapy – a retrospective cohort analysis

Sandra Janssen[1], Peter Engels[2]

[1]Elkerliek Hospital, Helmond, Netherlands, *[2]Engelsconsult, Bergisch Gladbach, Germany*

Aim: To evaluate whether the addition of hemoglobin spray to the treatment protocol of patients with diabetic foot ulcers (DFU) had an impact on the time to complete wound closure. In addition, we want to evaluate if the impact of the oxygenation can be used as predictive marker for wound healing.

Method: Twenty consecutive patients treated at the clinic during the last 24 months were selected. Ten patients were treated according to the local protocol, another ten had the hemoglobin spray added to this protocol. Baseline characteristics (age, comorbidities, wound dimensions, duration wound before start of treatment) and time to complete wound closure were noted. Oxygenation saturation levels in the skin of 8 patients treated with the hemoglobin spray were measured using the hyperspectral technology of TIVITA, before and after application of the spray.

Results / Discussion: Real world data (RWD) analysis showed that there were no significant differences ($p>0.05$) between the two groups in terms of baseline characteristics. The treatment time for patients was significantly shorter in the hemoglobin group (43.6 vs. 133.6 days), as was the time to complete wound healing (86.4 vs. 168.3 days), $P<0.05$). Hyperspectral images showed an increase in oxygen levels at 1 and at 5 mm in depth of the skin, although the point measurements did not objectify this visual image.

Conclusion: Addition of oxygen therapy early in the treatment regimens accelerated the wound healing process of DFU. A larger RWD analysis will follow to substantiate current findings.

EP105 transcutaneous CO_2 therapy improves healing, enhances tissue oxygenation, and reduces pain in diabetic foot ulcers: a prospective controlled study

Miloš Potkonjak[1]

[1]General Hospital Novo Mesto, Novo Mesto, Slovenia

Aim: To evaluate the effect of transcutaneous carbon dioxide (CO_2) therapy on wound healing, exudate, pain and tissue oxygenation over 4 weeks in people with diabetic foot ulcers (DFU).

Method: In a prospective controlled study, 30 patients with neuroischaemic (n=10), ischaemic (n=8) or neuropathic (n=12) DFU were allocated 1:1 to standard care alone (control) or standard care plus daily transcutaneous CO_2 therapy for 20 sessions over 4 weeks. Groups were comparable for age, glycated haemoglobin, ulcer duration and wound area, but previous minor amputation (toe or partial foot) was more frequent in the CO_2 group (8 vs 4 patients). Primary outcomes were complete healing (wound area 0 cm^2) and ≥50% reduction in wound area at 4 weeks. Secondary outcomes were wound-area change, granulation, exudate, pain on an 11-point numerical rating scale and tissue oxygen saturation (StO_2). Standard statistical tests were used ($p<0.05$).

Results / Discussion: At week 4, 7/15 (46.7%) ulcers had healed in the CO_2 group versus 0/15 (0%) in controls ($p=0.005$). A ≥50% wound-area reduction occurred in 14/15 (93.3%) CO_2-treated versus 3/15 (20.0%) control ulcers ($p<0.001$). Median wound-area reduction was 54.9% in the CO_2 group versus 17.2% in controls ($p=0.001$). The CO_2 group had significantly more ulcers with complete granulation and no exudate (both $p<0.001$). Pain decreased to 0 (no pain) in 40.0% of CO_2-treated patients, whereas no control patient became pain-free ($p=0.002$). StO_2 increased significantly over 20 sessions in the CO_2 group ($p<0.001$).

Conclusion: Transcutaneous CO_2 therapy enhanced tissue oxygenation, improved DFU healing, and reduced pain and exudate compared with standard care alone. These findings are consistent with previously published clinical studies and support further evaluation of this microvascular-targeted therapy.

EP106 A within-patient randomized clinical trial exploring the development of direct microskin implantation onto granulation wounds in the treatment of diabetic foot

Xiaoqian Zhou[1], Hou-An Xiao[1], liyuan Jiang[1], Qian Kou[1], Zhaoyang Yue[1], Hanlin Liu[1]

[1]Xi 'an Ninth Hospital, Xi 'an, China

Aim: Severe diabetic foot ulcer tenseriously affect patients' quality of life. And Direct Microskin (razor-thin skin was cut into very small pieces of 0.3-0.5 mm size) implantation onto Granulation Wounds has been demonstrated powerful in accelerating wound healing by forming "skinislands". The study was designed to evaluate this therapy as a comfort-focused for patients who can not tolerate surgical treatment but have a strong intention to preserve their limbs.

Method: An open-label within-patient RCT was conducted in patients with diabetic foot ulcers. Eight patients were enrolled. Negative pressure suction and bone cement were initially applied to promote granulation tissue formation. Each granulation wound was divided into two halves: one half was randomly assigned to receive only negative pressure therapy (control group), while the other half received additional bedside microskin grafting (experimental group). Efficacy was evaluated within one month of treatment, with primary end points including wound healing rate and wound healing scale scores. Secondary outcomes included the survival rate of grafted microskin, pain intensity assessment, satisfaction surveys of patients or their families.

Results / Discussion: All 8 patients completed the study. At 14 days postoperatively, 6.63 ± 1.78 out of the 8 cases that received microskin grafting had resulted in wound closure. After 1 month of treatment, the wound reduction rates in the control group and the experimental group were (26.17 ± 9.03)% and (85.95 ± 16.02)%, respectively ($P < 0.5$).

Conclusion: The technique of direct microskin grafting onto granulation tissue can rapidly achieve wound closure and limb preservation in diabetic foot ulcers.



EP107 Enhancing diabetic foot prevention in primary care: updated brazilian manual now advancing toward a Latin American edition

Ana Paula dos Santos Albuquerque[1], Vanessa Azevedo[2], Wanessa Karla Regis da Silva[3], Prof. José Luis Lázaro-Martínez[4]

[1]Regional Hospital of Agreste / Pernambuco State Health Department, Nursing Clinic specializing in wound care., Caruaru, Brazil, [2]Urgo Medical Brasil, São José dos Campos, Brazil, [3]Curamed Recife, REcife, Brazil, [4]Universidad Complutense de Madrid, Madrid, Spain

Aim: To present the progress achieved after the implementation of a technical manual for Primary Health Care (PHC) teams on diabetic foot prevention and management, originally developed within the Master's in Diabetic Foot at the Complutense University of Madrid. The objective is to describe its national uptake, ongoing refinement, and planned expansion to Latin America.

Method: The manual was developed according to the most recent International Working Group on the Diabetic Foot (IWGDF) guidelines, integrating epidemiology, risk stratification, preventive measures, and decision-making algorithms for PHC teams. After publication, it was disseminated across Brazilian states and used in training initiatives to support protocol standardization. Feedback from users informed a revision cycle focused on updating recommendations, improving didactic structure, and adding emerging evidence. A Latin American edition is in preparation for publication in 2026.

Results / Discussion: National implementation showed that the manual is applicable across diverse PHC contexts. Its structured approach strengthened risk identification, systematic foot assessment, and patient education. Reports from PHC teams indicated increased adherence to preventive practices and earlier recognition of complications. The inclusion of QR codes with clinical demonstrations facilitated practical understanding and supported the adoption of evidence-based routines. The forthcoming Latin American edition aims to expand access to standardized guidance and promote regional alignment with international recommendations.

Conclusion: The manual has become an important educational and clinical resource for PHC professionals in Brazil and is evolving into a reference for Latin America. Its revision and upcoming regional publication highlight the need for unified preventive strategies and qualified training to reduce the burden of diabetic foot complications. By strengthening practice and training, the initiative may enhance outcomes and reduce morbidity.

EP108 Role of Flexor Tenotomy in preventing distal amputation in Non Healing Toe tip ulcer's: An observational study in multidisciplinary diabetic foot care centre in Bangladesh

Mohammad Mahbub Alam[1], Mafruha Nusrat Khan[1], Mahmud Ekram ullah[2], Jabayer Ahmad[3]

[1]Bangladesh diabetic wound and Foot care limited, BIRDEM General Hospital, Dhaka, Bangladesh, [2]BIRDEM General Hospital, Dhaka, Bangladesh, [3]Ibrahim Cardiac and Research Institute, Dhaka, Bangladesh

Aim: Non-healing toe tip ulcers, especially in diabetic and neuropathic patients, often progress to infection and digital amputation. Persistent plantar pressure from flexor tendon contracture delays healing. Flexor tenotomy, a simple and minimally invasive procedure, can relieve distal pressure and promote ulcer closure.

Method: A prospective observational study was conducted on 30 patients with chronic non-healing toe tip ulcers unresponsive to at least 4 weeks of conservative management. Under local anesthesia, percutaneous flexor tenotomy was performed at the level of the proximal phalanx. Patients were followed for 12 weeks to assess ulcer healing, time to closure, complications, and amputation rate.

Results: Complete ulcer healing was achieved in 88% (26/30) of patients, with a mean healing time of 6 weeks. No major complications or recurrence were observed. Minor wound infection occurred in 2 patients (6.6%), and no patient required digital amputation during follow-up.

Conclusion: Flexor tenotomy is a safe, simple, and effective outpatient procedure for managing chronic toe tip ulcers. It significantly reduces distal pressure, enhances healing, and prevents digital amputation, making it a valuable limb-salvage technique in diabetic foot care.

EP109 Prediction of diabetic foot ulcers using bayesian networks and evaluation of the D-Foot assessment tool in an Indian tertiary care setting

Malavika Krishnakumar[1], Vivek Lakshmanan[2], Georg Gutjahr[1], Gayatri Mohan[3], DIPU T S[3], Ulla Hellstrand[4 5], Anneli Ringblom[6]

[1]Department of Health Sciences Research, Amrita Institute of Medical Sciences and Research Center, Amrita Vishwa Vidyapeetham, Kochi, India, *[2]Department of Endocrinology and Diabetic Foot Surgery, Amrita Institute of Medical Science and Research Centre, Kochi, India*, *[3]Division of Infectious Diseases, Department of General Medicine, Amrita Institute of Medical Science and Research Centre, Kochi, India*, *[4]Department of Orthopaedics, Institution of Clinical Sciences, Sahlgrenska Academy, University of Gothenburg, Gothenburg, Sweden*, *[5]Department of Prosthetics and Orthotics, Sahlgrenska University Hospital, Gothenburg, Sweden*, *[6]Institute of Health and Care Sciences, The Sahlgrenska Academy, University of Gothenburg, Gothenburg, Sweden*

Aim: Diabetic foot ulcers (DFUs) are a major cause of morbidity, amputation, and mortality, especially in India, where diabetes prevalence is high and routine foot-risk screening is inconsistent. Early identification of feet at risk and timely intervention and proper intervention to prevent an ulcer are essential. The Swedish D-Foot tool offers a structured assessment of neuropathy, deformity, vascular status, and self-care, but its performance in Indian settings is unknown. This study evaluates the feasibility, inter-rater reliability, and usability of the D-Foot tool in a South Indian tertiary hospital and develops a Bayesian Network (BN) model to predict 6-month diabetic-foot complications using baseline risk factors derived from the D-Foot assessment.

Method: Fifty adults with diabetes underwent detailed foot assessments using the D-Foot tool, independently by two clinicians. Inter-rater reliability was measured using Cohen's kappa. Clinician perceptions of tool usability were assessed using the System Usability Scale (SUS) before and after structured training. Participants were followed for six months to document new diabetic foot complications. A BN model based on neuropathy, ulcer history, deformities, ankle–brachial index, vibration threshold, and self-care was developed to estimate conditional risk, with discrimination assessed by ROC analysis.

Results / Discussion: The D-Foot tool demonstrated strong inter-rater reliability ($\kappa = 0.79$). The BN model showed moderate predictive accuracy for 6-month complications, with neuropathy, previous ulceration, deformities, and impaired perfusion contributing prominently to risk estimation. ROC results indicated acceptable discrimination for short-term DFU prediction.

Conclusion: The D-Foot is a feasible, reliable, and well-accepted structured assessment tool for diabetic foot risk in Indian hospital settings. Integrating D-Foot findings with Bayesian modelling may strengthen early identification of high-risk individuals and support improved DFU prevention strategies.

EP110 Wound healing with local antibiotic beads in diabetic foot osteomyelitis: a matched case control non-inferiority study

Malavika Krishnakumar[1], Vivek Lakshmanan[2], Georg Gutjahr[1], DIPU T S[3], Gowri Nandhini[4], Merlin Moni[3], Agnetha Folestad[5], Mangalanandan T S[4], Harish Kumar[4]

[1]Department of Health Sciences Research, Amrita Institute of Medical Sciences and Research Center, Amrita Vishwa Vidyapeetham, Kochi, India, *[2]Department of Endocrinology and Diabetic Foot Surgery, Amrita Institute of Medical Science and Research Centre, Kochi, India*, *[3]Division of Infectious Diseases, Department of General Medicine, Amrita Institute of Medical Science and Research Centre, Kochi, India*, *[4]Department of Endocrinology, Amrita Institute of Medical Science and Research Centre, Kochi, India*, *[5]Department of Orthopaedics, Institution of Clinical Sciences, Sahlgrenska Academy, University of Gothenburg, Gothenburg, Sweden*

Aim: Diabetic foot osteomyelitis (DFO) is a limb-threatening infection that often requires prolonged systemic antibiotics, which may be limited by toxicity, inadequate bone penetration, and reduced effectiveness in patients with nephropathy or impaired perfusion. Local antibiotic bead therapy (ABT) using biodegradable calcium sulphate beads provides high local drug concentrations with minimal systemic exposure, but comparative real-world evidence remains

limited. This study aims to assess whether ABT is non-inferior to oral antibiotic therapy for wound-healing outcomes in DFO and to identify predictors of healing using a Bayesian Network (BN) model.

Method: A matched case-cohort study was conducted among 100 adults with culture-confirmed DFO at a tertiary diabetic foot centre. Fifty patients received ABT and fifty received oral antibiotics, matched for age, duration of diabetes, and microbiological profile. The primary outcome was wound-healing duration, evaluated using a non-inferiority margin of 15%. Secondary outcomes included recurrence at 3, 6, and 12 months, need for re-debridement, and amputation. A BN model incorporating clinical factors, inflammatory markers, and diabetes-related complications was constructed to identify direct and indirect predictors of healing.

Results / Discussion: Wound-healing duration was non-inferior between groups (median 56 days for ABT vs 55 days for oral therapy; p = 0.7). Recurrence at 6 months was lower with ABT (18% vs 48%), while amputation and re-debridement rates were similar. BN analysis identified CRP, duration of diabetes, and sex as the strongest predictors of healing time, with ABT showing no negative influence on healing pathways.

Conclusion: ABT is a safe and effective alternative to oral antibiotics for DFO, offering comparable healing and reduced recurrence. Its targeted delivery and favourable safety profile support its role as an adjunct in standard DFO management.

EP113 Intact fish skin graft as an alternative to split-thickness skin grafting in the management of diabetic foot ulcerations – a prospective observational study

Magdalena Maj[1]

[1]*Dr Maj Diabetic Foot Surgery, Poznan, Poland*

Aim: Diabetic foot treatment remains one of the most demanding and costly areas of healthcare. The number of amputations resulting from diabetic foot ulcerations (DFUs) in Poland remains among the highest in Europe. This study was designed to evaluate the efficacy and safety of the use of intact fish skin graft (IFSG) as a method for shortening treatment duration and reducing the risk of amputation in DFU patients.

Method: The study included 15 patients (14 males and 1 female) treated at a single DFU care centre in Poznan, Poland. The mean patient age was 60.8 years (range 32-76 yrs), mean duration of diabetes 14.6 years (range 1-30 yrs), and mean duration of DFU 38 weeks (range 2 - 120 weeks). Indications for IFSG use included peripheral arterial disease, oral anticoagulation, and the presence of exposed bone in the wound bed. The mean follow-up duration was 7 months. Grafts were applied on outpatient basis to optimally prepared wound beds without sutures and secured using dedicated dressings. Standard offloading was maintained until full closure.

Results / Discussion: Ulcerations healed in an average of 9 weeks. One patient was lost to follow-up. The remaining 14 achieved complete wound closure and avoided amputation. When compared with published data on split-thickness skin grafts (STSGs) – which typically require approximately 12 weeks to achieve closure in similar patient population – IFSG in this study demonstrated shorter treatment duration and better biomechanical result. IFSG was easy to apply, readily available, and exhibited high biocompatibility. Scar formation and bone adhesions were minimal compared with STSG.

Conclusion: In conclusion, IFSG may serve as a highly valuable approach to improving DFU treatment outcomes and supporting limb preservation.

EP114 Advancing diabetic wound management through inflammation modulation and multimodal strategies

Yun-Nan Lin[1]

[1]*Wesing Breast Hospital, Kaohsiung, Taiwan*

Aim: To summarize current challenges in diabetic wound healing and evaluate multimodal therapeutic strategies, focusing on inflammation control, tissue oxygenation, infection management, and advanced biologic interventions.

Method: A narrative synthesis was performed integrating pathophysiological mechanisms - hyperglycemia-induced immune dysregulation, persistent M1-dominant inflammation, microangiopathy, excessive protease activity, and impaired fibroblast/keratinocyte function - as illustrated in the clinical framework and case series of complex diabetic foot ulcers (DFUs). Treatment principles - including debridement, infection control, exudate management, pressure offloading, vascular intervention, and regenerative adjuncts - were reviewed.

Results / Discussion: Hyperglycemia prolongs inflammation, weakens host immunity, and impairs collagen synthesis and angiogenesis. DFUs commonly enter a vicious cycle of excessive exudate, bio-burden, and stalled granulation. Multimodal interventions—including negative-pressure therapy, advanced dressings, artificial dermis, biologics, and local oxygen therapies—facilitated wound progression when combined with optimized circulation and infection control.

Conclusion: Diabetic wounds require comprehensive strategies addressing both biological impairment and systemic barriers. Effective treatment integrates inflammation reduction, oxygenation improvement, infection/bioburden control, and regenerative stimulation. Clinical cases highlight that coordinated multimodal care can convert chronic inflammatory DFUs into healing wounds, supporting broader adoption of structured, evidence-based pathways in diabetic wound management.

EP115 Development of a booklet to guide self-care of the feet of people with diabetes mellitus

Bruna Barbosa da Silva[1], Samara Cecília Silva[1], Felicialle Pereira da Silva, Jabiael Carneiro da Silva Filho[1], Isabel Cristina Santos[1]

[1]*University of Pernambuco - Postgraduate Program in Nursing, Recife, Brazil*

Aim: To develop a booklet to guide foot self-care for people with Diabetes Mellitus.

Method: Methodological study based on psychometrics, operationalized in four stages: 1) Research with the target population: a qualitative descriptive study was conducted, in which 15 people with type 2 diabetes were interviewed to verify their learning needs regarding foot self-care; 2) Scoping review, to identify important variables to compose the booklet script; 3) Content validation through a committee of 17 judges: enterostomal therapist nurses, popular educators, and graphic designers, using the following data collection instruments: Health Educational Content Validation Instrument and the Suitability Assessment of Materials - SAM. The data were analyzed using the Content Validity Index and percentage of scores obtained in the SAM; and 4) Face validation evaluated by 30 people with type 2 diabetes, and the data were analyzed using the rate of agreement of positive responses.

Results / Discussion: Content validation with stoma therapist nurses obtained a CVI of 1.0. Content validation by community educators obtained a 97% agreement percentage, and validation by graphic design was performed in two rounds, reaching a 96% percentage. In the face evaluation, the booklet achieved an agreement index of 96.7% and 100%.

Conclusion: The booklet for teaching foot self-care to people with Diabetes mellitus was developed based on the learning needs of the target population and scientific evidence. Content evaluation and face validation suggest that the booklet for teaching foot self-care is a quality tool, valid for use in primary care.

EP116 Development and validity evidence of a questionnaire for assessing foot self-care in people with diabetes

Victor Hugo da Silva Martins[1], Samara Cecília Silva[1], Bruna Barbosa da Silva[1], Jabiael Carneiro da Silva Filho[1], Isabel Cristina Santos[1]

[1]*University of Pernambuco - Postgraduate Program in Nursing, Recife, Brazil*

Aim: To develop and evaluate the validity evidence of the questionnaire for assessing foot self-care in people with diabetes – QAPUD.

Method: Psychometric study. The QAPUD consists of 18 questions distributed across four domains (foot assessment, foot care, nail care, and shoe care) and was applied to a sample of 540 type 2 diabetics treated at a Reference Center. For test-retest stability assessment, the intraclass correlation coefficient was calculated for the domain scores. Internal consistency was assessed using Cronbach's alpha coefficient for the questionnaire as a whole and for each of the dimensions. For factor analysis, the iterated principal factors method was used in Stata 6.0 (Stata Corporation, College Station, United States) to obtain better estimates of the correlations, and varimax rotation was performed. Factor loadings lower than 0.40 were assumed to be small.

Results / Discussion: Test-retest reliability of the scores was estimated, with intraclass correlation coefficients ranging from 0.76 to 0.91 across the various domains. Levels of internal consistency, assessed by Cronbach's alpha coefficient, ranged from 0.69 to 0.79. In the factor analysis, using the iterated principal factors method and varimax rotation, the structure of the original instrument was exactly replicated.

Conclusion: The QAPUD has adequate validity evidence to assess the self-care construct for foot ulcer prevention in people with diabetes.

EP117 Large-area cold plasma therapy in multi-drug resistant complex severe burn wounds: a case series including combat related severe burns

Frederik Schlottmann[1], Moritz Milewski[1], Frederik Kloss[1], Lisa Lorbeer[1], Lukas Wellkamp[1], Thorben Dieck[1], Peter M. Vogt[1]

[1]*Hannover Medical School, Plastic, Aesthetic, Hand and Reconstructive Surgery, Hannover, Germany*

Aim: The increasing prevalence of multi-drug resistant (MDR) microorganisms presents a major challenge in the management of complex wounds, especially in severe burns. Conventional systemic and topical anti-infective strategies are often insufficient or restricted to reserve antibiotics. Combat burn casualties often reach definitive care after prolonged evacuation already colonized with MDRs, increasing the risk of graft failure and sepsis. This study aimed to evaluate the effectiveness of large-area atmospheric cold plasma therapy (ACPT) as an adjunctive modality for microbial reduction and wound bed optimization in MDR-colonized severe burn wounds.

Method: A case series of 10+ patients with extensive, complex severe burn wounds colonized by MDR pathogens including patients with combat related burns was analyzed. All patients demonstrated persistent microbial burden despite standard multimodal therapy, including repeated surgical debridement, topical antisepsis, and systemic anti-infective treatment. ACPT was performed daily using a large-area cold plasma device applied directly to the wound surface. Microbiological swabs, clinical wound assessments, and grafting outcomes were systematically documented.

Results / Discussion: All patients showed colonization with MDR organisms, including *Acinetobacter* spp. and *Pseudomonas* spp. Application of ACPT resulted in marked microbial reduction, in several cases achieving complete elimination of targeted pathogens. This microbial control enabled successful integration of split-thickness skin grafts and prevented local and systemic infectious complications. Improved wound healing trajectories were observed across cases with shortened hospital stay, accompanied by a reduction in the need for reserve antibiotics. Exemplarily, two cases illustrate the concept. A 40-year-old wounded soldier with 23% TBSA burns and traumatic lower-leg amputation had widespread 4-MRGN Acinetobacter baumannii colonization. Daily ACPT supported dermal matrix integration and subsequent Meek micrografting, achieving approximately 90% coverage by day 53

and near-complete consolidation by day 70, while systemic antibiotic therapy was limited to perioperative dosing and pneumonia-associated sepsis. In another case, a 27-year-old with 60% TBSA burns and polymicrobial MDR colonization received immediate daily treatment; dermal matrix integrated by day 30 and grafting yielded 99% wound coverage by day 40 with complete graft take, enabling discontinuation of systemic antibiotics once stabilized.

Conclusion: Large-area ACPT proved to be an effective and safe adjunct to established wound management strategies for MDR-colonized severe burn wounds. The therapy facilitated microbial control, optimized wound bed conditions, and supported reconstructive procedures. These findings highlight the potential of ACPT as a valuable component within multimodal treatment concepts. Larger retrospective and prospective studies are warranted to establish standardized protocols and confirm clinical efficacy.

EP118 Healing and limb preservation with ON101 topical cream in chronic diabetic foot ulcers: An observational comparative study

Yur-Ren Kuo[1], Yun-Nan Lin[1], Shu-Hung Huang[1], Su-Shin Lee[1]

[1]Division of Plastic Surgery, Department of Surgery, Kaohsiung Medical University Hospital, Kaohsiung Medical University, Kaohsiung, Taiwan

Aim: Chronic diabetic foot ulcers (DFUs) remain a leading cause of lower-limb amputation, and persistent inflammation contributes to impaired healing and high treatment costs. ON101 topical cream was developed to help maintain a favourable wound microenvironment. This study aimed to assess healing progression, limb preservation, and potential impact on healthcare resource use in patients with chronic DFUs treated with ON101 topical cream compared with current standard care modalities.

Method: An observational comparative study was conducted in 45 adults with chronic DFUs. Following adequate infection control and wound bed preparation, including debridement and/or revascularisation as indicated, patients received either ON101 (n = 20) or current combination therapy (n = 25), consisting of wound dressings, dermal substitutes, and/or surgical management. Treatments were applied once to twice daily according to local practice. Outcomes included complete epithelialisation during the observation period, treatment-related complications, limb preservation at six-month follow-up, and the need for additional wound-related procedures.

Results / Discussion: A higher proportion of patients in the ON101 group achieved complete healing compared with those receiving combination therapy. No therapy-related adverse events were reported in the ON101 group. All ON101-treated patients maintained limb preservation at six months' follow-up. Patients treated with ON101 required fewer additional wound-related interventions, suggesting the potential to reduce treatment burden and associated healthcare resource use.

Conclusion: In this observational study, ON101 topical cream, used as part of comprehensive DFU care, was associated with favourable healing outcomes and maintained limb preservation compared with current combination therapy. These real-world findings support its therapeutic potential as a limb-salvage option and generate hypotheses about possible cost-effectiveness that warrant confirmation in formal economic evaluations.

EP119 Clinical and morphological effects of collagen dressings on tissue repair in patients with diabetic foot ulcers

Ekaterina Zaitseva[1], Alla Tokmakova[1], Gagik Galstyan[1]

[1]Endocrinology Research Centre, Moscow, Russian Federation

Aim: to evaluate clinical and morphological effects of collagen dressings compared to standard care in diabetic ulcers.

Method: Clinical examination, ulcer biopsies (stained immunohistochemically for matrix metalloprotease -9 (MMP-9) and tissue inhibitor of MMP (TIMP-1) antibodies before and after treatment.

Results / Discussion: We observed 55 patients (37 men; 18 women) with diabetic ulcers after surgical debridement and divided them into 2 groups. In group1 (n=34) we used collagen-dressings, in group2 (n=21) we used standard atraumatic dressings for 9 ±5days.

Both groups were represented mainly by patients with type2DM and reliably matched by age(group1 54,5 [51; 63], group2 60 [57;72] years), glycaemic control (HbA1c in group1 8,8 [7,9; 10,1]%, in group2 8.8 [7.6;9.7]%), severity of microvascular complications, form of diabetic foot (neuropathic-28, neuroischemic–23 (after revascularization)),wound size(13,35 [7,8; 19,1] cm^2, group2-23.5 [12.3;55.3]cm^2), wound depth (group1–2,45 [1,6; 3,1] cm, group 2–3.2 [2.4;5.2]cm), p≥0.05. At the end of treatment both groups showed the significant decrease of wound size and depth. But in comparison collagen dressings were more efficient (p<0.05). TIMP-1 expression slightly increased and MMP-9 levels decreased more significant in group 1(p =0.03).

Conclusion: Collagen dressings are more effective in tissue repair compared to standard care, it reduces wound size and depth and decreases proteolytic activity according to immunohistochemical studies.

EP120 GLP1-receptor agonists and risk reduction of major adverse limb events in type 2 diabetes patients with or without lower-extremities peripheral artery disease: A systematic review and a meta-analysis of randomized controlled trials and real word evidence studies

Giuseppe Murdolo[1], Cristiana Vermigli[1], Francesco Gaggia[1], Irene Fagioli[1]

[1]*Perugia Hospital, Perugia, Italy*

Aim: This study aimed to determine whether GLP1-RAs is preferable to any anti-hyperglycemic agents (AHA) therapy in reducing the risk of MALEs or developing LE-PAD in T2D patients with and/or without a history of LE-PAD.

Method: A Medline and Embase search was conducted through November 30, 2025, to identify RCTs and real world evidence (RWE) studies comparing GLP1-RAs with AHAs in patients with T2D. Key efficacy outcomes included MALEs (composite of first event of newly diagnosed LE-PAD, newly diagnosed critical limb ischemia, percutaneous transluminal angioplasty or peripheral by-pass, and non traumatic LE-amputation). Mantel-Haenzel odds ratios and 95% confidence intervals (MH-OR, 95%CI) were calculated.

Results / Discussion: From a total 39 items retrieved, only 5 RCTs and 21 RWE studies met the inclusion criteria for efficacy outcomes component of the review. When disaggregated data were available, patients with or without history of LE-PAD at baseline were analyzed separately. In both RWE studies [MH-OR 0.80; 95% CI: 0.74-0.87] and RCTs [MH-OR 0.85; 95% CI: 0.69-1.03] analyzing T2D patients with and without LE-PAD, GLP1-RAs were consistently associated with a reduced risk of MALEs compared to different AHAs. In RCTs the subgroups analysis showed a similar trend among patients with prior LE-PAD at baseline [MH-OR 0.79; 95% CI: 0.65-0.96], whereas results were less consistent in patients without LE-PAD [MH-OR 0.75; 95% CI: 0.62-1.17]. Finally, RWE confirmed the significant effect of GLP-1 RAs on risk reduction of LE-PAD and MALES in subjects without [MH-OR 0.83; 95% CI: 0.76-0.92] and with history of LE-PAD.

Conclusion: In T2D patients, treatment with GLP1-RAs provides consistent risk reduction of MALEs independently of prior history of LE-PAD.

EP121 Real-world evaluation of amniotic grafts in chronic wounds: protocol design and interim analysis

Windy Cole[1]

[1]*Kent State University College of Podiatric Medicine, Independence, Ohio USA, United States*

Aim: To evaluate the effectiveness of amniotic tissue grafts as adjuncts to standard care for diabetic foot ulcers (DFUs) and venous leg ulcers (VLUs) using a pragmatic hybrid platform design. This real-world evidence (RWE) approach seeks to overcome the limited generalizability of randomized controlled trials by assessing complete wound closure at 12 weeks and percent area reduction in diverse clinical settings.

Method: Two cohorts (DFU and VLU) were randomized 1:1 to receive one of two amniotic grafts and compared with coarsened matched standard-of-care (SOC) control matched from the United States Wound Registry. Weekly follow-up visits occured up to 12 weeks. At the time of interim analysis, 31 subjects had been enrolled, generating 155 visit records. Feasibility and baseline characteristics were assessed through standardized data cleaning and patient-level aggregation.

Results / Discussion: 61% VLU and 32% DFU; mean age was 65 years (median 69), with 58% male. Wheelchair arrival occurred in 35% of visits; tobacco use was 19% (current or former). Patients averaged six comorbidities, most commonly hypertension and hyperlipidemia. Among patients with ≥2 visits, 61.3% showed decreased wound area and 22.6% showed increased granulation.

Conclusion: This real-world hybrid platform trial demonstrates the feasibility of evaluating amniotic tissue grafts in routine clinical practice. Interim results reveal a high comorbidity burden yet show early signals of wound area reduction. By integrating real-world evidence with rigorous methodology, this protocol exemplifies a modern, patient-centered approach to wound care research and aims to generate actionable insights to inform evidence-based treatment of chronic wounds.

EP420 Introducing wound bed preperation to podiatry wounds, the patient experience of wound condition

Debbie Willsea[1]

[1]*Highly Specialised Podiatrist- Diabetes and Vascular, Northern Care Alliance - The Royal Oldham Hospital, Oldham, United Kingdom*

Aim: Diabetic foot wounds often experience long healing times and this can have a negative impact on patients; we sought to evaluate if wound bed preparation would impact not only the wound condition but the patient experience.

Method: 7 patients were followed up over 6 weeks to determine the impact of wound bed preparation on wound condition, the patient's experience and QoL. Wound cleansing, debridement with a microfibre debridement pad followed by a surfactant containing gel were implemented. Wound measures included: size, tissue % (Slough, Granulation), infection status of the wound, exudate and malodour. Patient related measures included pain (VAS) and qualitative verbal reports.

Results / Discussion: In all 7 cases the wound size reduced at a greater rate than achieved with the previous dressing regime. Slough improved after debridement in 6/7 of patients. 3 patients had pain scores of 1,1 & 5 at first appointment, this reduced to 0 in all cases by end of treatment. 7/7 patients saw a reduction in exudate, impacting QoL positively with 2 patients noting that they had seen less strikethrough on their dressings and were feeling better about their wounds. Patients reported to clinician they felt distressed by their wounds, frustration, experienced depression and could be socially embarrassed their dressings and wound odour. Resolution of odour, improvement in exudate and reduction of wound size were mentioned by patients as having a positive impact on their outlook.

Conclusion: From this 7 patient sample there are positive correlations between wound condition improving (through wound bed preparation) and patients experiencing more positive impacts on their outlook and quality of life.

EP122 The Use of 3D bioprinted skin substitutes produced using mesenchymal stem cell–rich adipose-derived stromal vascular fraction in the treatment of diabetic foot

Guzin Aygun[1], Buse Irem Koc[1], Mehmet Mert Hidiroglu[1], Hamdullah Yanik[2], Eda Kural[1], Kerim Bora Yilmaz[3]

[1]Department of General Surgery, University of Health Sciences, Gulhane Training and Research Hospital,, Ankara, Türkiye, [2]Department of Basic Oncology, Cancer Institute, Hacettepe University, Ankara, Türkiye, [3]Department of General Surgery, University of Health Sciences, Gulhane Training and Research Hospital,, Department of Medical and Surgical Research, Institute of Health Sciences, Hacettepe University, Ankara, Türkiye

Aim: Regenerative approaches gain attention where conventional therapies fail restoring normal wound healing. Even with conventional therapies and recent advances in wound care, wound healing occurs in only 24–30% of these patients within 12–20 weeks. The aim of this study is to evaluate the effect of a 3D bioprinted skin substitute, produced using patient-derived adipose tissue–derived Stromal Vascular Fraction (SVF) enriched with mesenchymal stem cells, on wound healing.

Method: 7 patients with tissue defects from amputation or debridement due to diabetic foot ulcers were included. An autologous skin substitute, prepared via 3D bioprinting using the intracellular matrix derived from mesenchymal stem cell–enriched with adipose tissue collected by liposuction, was applied onto the tissue defect. Following treatment, granulation tissue samples were collected periodically for flow cytometry analysis, and wound size was monitored clinically.

Results / Discussion: Complete epithelialization was observed in all patients, with an average time to epithelialization of 64 days. While clinical epithelialization of the wound was observed, an increase in M1 macrophages (CD38) and M2 macrophages (CD209) was detected through flow cytometry analysis. The clinical efficacy of the treatment was found to correlate with the increase in myeloid and neutrophil cell populations in the wound bed. Changes in M1–M2 macrophage levels as shown by flow cytometry indicate that a chronic wound is transforming into an acutely healing form.

Conclusion: The use of 3D bioprinted skin substitutes, produced from adipose-derived SVF enriched with mesenchymal stem cells, may accelerate wound healing in chronic wounds with delayed granulation and epithelialization compared to conventional methods.

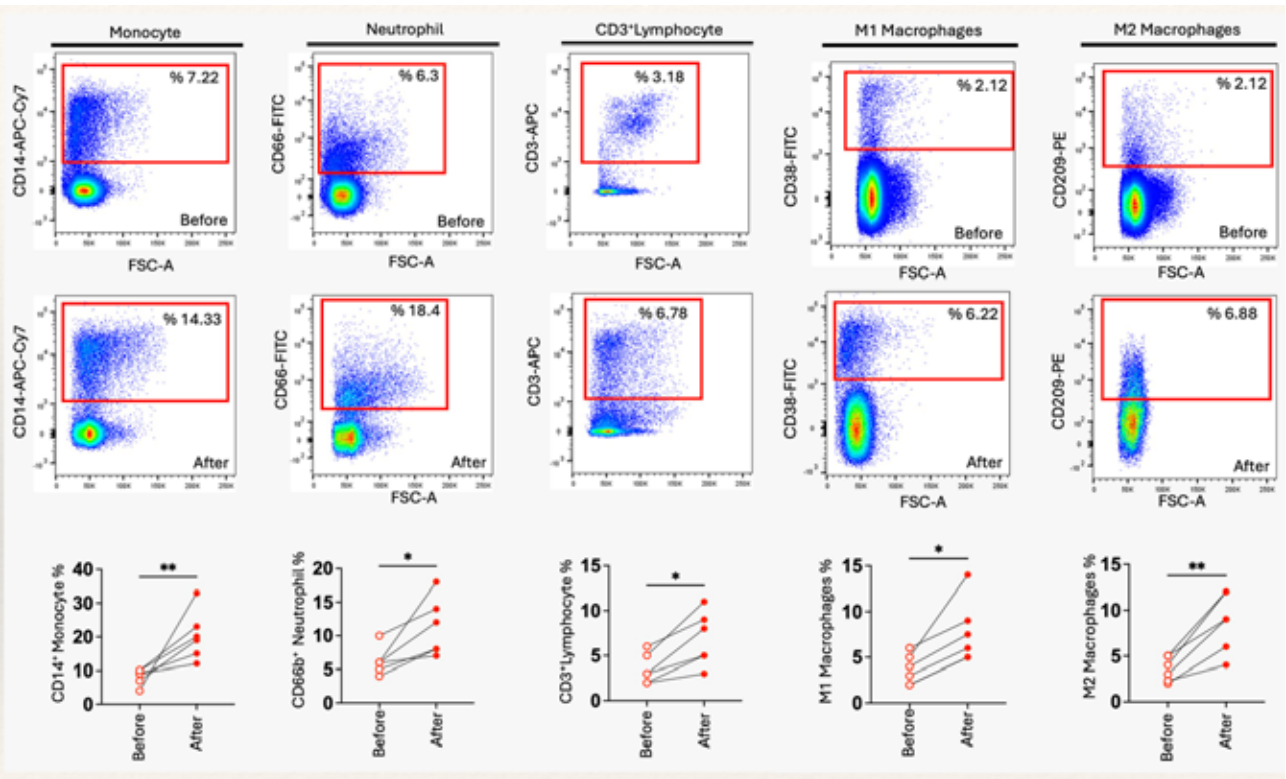

Figure1. Flow cytometry analysis of immune cell subset



Figure 2. 3D bioprinting



Figure 3. Wound healing after treatment

EP123 Effectiveness of a nitric oxide-generating dressing in patients with diabetic foot ulcers: preliminary data from a case series study

Marco Meloni[1], Ermanno Bellizzi[1], Federico Rolando Bonanni[1], Martina Salvi[1], Luigi Uccioli[1], Aikaterini Andreadi[1], Alfonso Bellia[1], Davide Lauro[1]

[1]Tor Vergata University, Rome, Italy

Aim: To assess the effectiveness of a multimodal dressing technology generating nitric oxide with an antimicrobial effect in patients with hard-to-heal diabetic foot ulcers (DFUs).

Method: The study is a preliminary case series study including patients with non-healing DFUs, defined by a wound area regression (<50%) after at least 4 weeks of treatment despite the application of the best standard of care. Excluded patients were those with severe limb ischaemia (TcPO2 < 25 mmHg), and with deep ulcer involving tendons, muscle or bones. Included patients were treated with a multimodal dressing technology generating nitric oxide in association to the standard of care (debridement, management of infection, offloading). Primary endpoint was to evaluate the wound area regression (>50%) after a maximum treatment period of 12 weeks. The secondary endpoints were the rate of new infections, the safety of the treatment (adverse events), and the increase in local perfusion (measured by TcPO2).

Results / Discussion: Overall, 5 patients were included. The mean age was 55±8 years, all of them were male and had type 2 diabetes; 1 DFU was in the forefoot, 2 in the midfoot and 2 in the rearfoot. At the assessment, the mean ulcer size was 8.2±4.1 cm^2. After 12 weeks, 4 patients showed a wound regression (>50%), no patient reported new

infections or adverse events. A significant increase in TcPO2 in the peri-wound area has been reported after 12 weeks of treatment vs baseline (46±5 vs 38±8 mmHg, p=0.03).

Conclusion: Preliminary data showed a potential effect on wound regression, protection against local infections, and a good tolerability of nitric oxide in hard-to-heal DFUs. A concomitant increase of peri-wound blood perfusion has been reported.

EP124 Cellular immunomodulation and clinical improvement with topical oxygen therapy using hemoglobin-based spray in diabetic foot ulcers

Buse Irem Koc[1], Guzin Aygun[1], Mehmet Mert Hidiroglu[1], Hamdullah Yanik[2], Kerim Bora Yilmaz[3]

[1]Department of General Surgery, University of Health Sciences, Gulhane Training and Research Hospital,, Ankara, Türkiye, *[2]Department of Basic Oncology, Cancer Institute, Hacettepe University, Ankara, Türkiye*, *[3]Department of General Surgery, University of Health Sciences, Gulhane Training and Research Hospital,, Department of Medical and Surgical Research, Institute of Health Sciences, Hacettepe University, Ankara, Türkiye*

Aim: In diabetic foot ulcers, the hypoxic tissue environment resulting from neuropathy and vascular impairment contributes to delayed wound healing. Topical oxygen therapy (TOT), administered as a Hemoglobin-Based Spray, is used as a practical method to increase local tissue oxygenation without systemic adverse effects. This study aimed to evaluate the effects of Hemoglobin-Based Spray TOT on wound healing at both cellular and clinical levels in patients with diabetic foot ulcers.

Method: A total of 156 diabetic foot patients were included, 76 of whom were treated with Hemoglobin-Based Spray TOT and 80 with conventional methods. Tissue samples obtained before treatment and after two weeks were analyzed by flow cytometry to assess immune cell composition. Wound sizes were monitored and documented until complete epithelialization was achieved.

Results / Discussion: The time required for wound epithelialization was shorter in the Hemoglobin-Based Spray TOT group compared with the conventional treatment group. In patients receiving Hemoglobin-Based Spray, flow cytometry demonstrated changes in immune cell activity consistent with wound repair, including increases in M1 (CD38) and M2 (CD209) macrophage populations. These cellular findings indicate that Hemoglobin-Based Spray TOT was associated with alterations in the chronic wound microenvironment, particularly in macrophage distribution and phenotype.

Conclusion: In this study, topical oxygen therapy administered as a Hemoglobin-Based Spray was associated with changes in immune cell composition and reduced time to wound epithelialization in diabetic foot ulcers. The data obtained demonstrate measurable effects of Hemoglobin-Based Spray TOT at both tissue and clinical levels.

Wound size measurements and epithelialization time			
	Group 1 Conventional (n=80)	Group 2 Topical Oxygen Therapy (n=76)	p-value
Baseline wound size measurement, cm^2	36.2 ± 24.7	26.4 ± 13.7	
Day 15 measurement, cm^2	31.2 ±21.2	20.7 ± 11.2	
Day 30 measurement, cm^2	26.4 ± 17.7	13.5 ± 8.6	
Day 45 measurement, cm^2	22.5 ± 16.2	6.1 ± 4.9	
Time to re-epithelialisation, day	192.4 ± 65.2	76.5 ± 18.5	<0.001*

Figure 1. Wound size measurements and epithelialization time

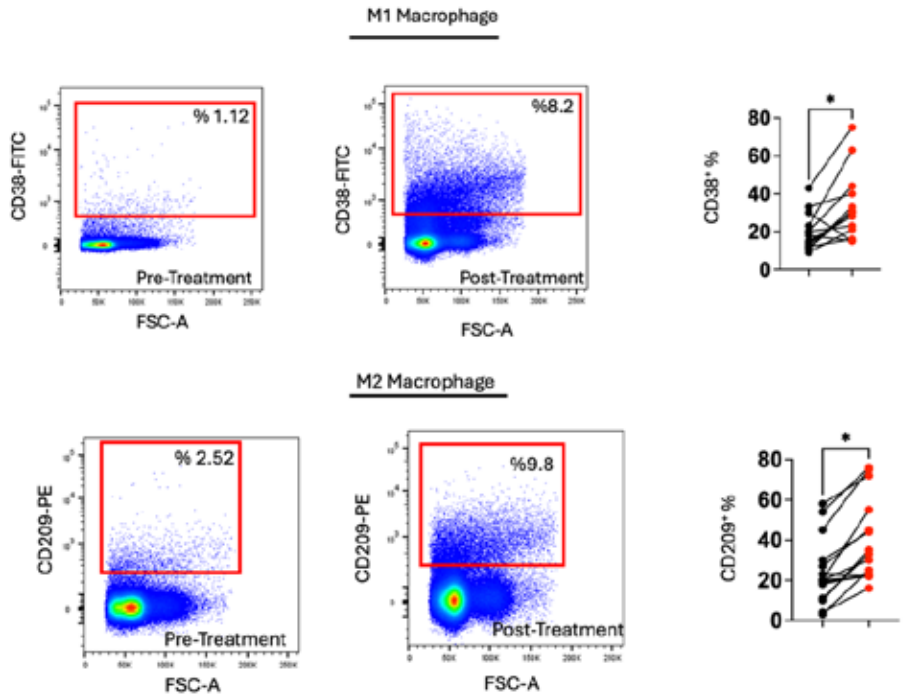

Figure 2. Flow cytometry analysis of immune cell profile changes following TOT



Figure 3. Wound size measurements following TOT

EP421 Association of amputation risk and dental care in patients with diabetic foot syndrome

Kamil Tkacz[1], Kaja Kłopecka[1], Paulina Kaczorek[1], Karolina Lisowska[1], Aleksandra Świstak[1], Anna Nowak-Szwed[1], Leszek Czupryniak[1]

[1]*Department of Diabetology and Internal Medicine, Medical University of Warsaw, Warsaw, Poland*

Aim: Oral health is increasingly recognized as an important element of systemic health, including type 2 diabetes mellitus (T2DM) and diabetic foot syndrome (DFS). Individuals with T2DM are prone to developing periodontal disease, and in turn, periodontitis may impair glucose regulation. It contributes to the development of complications like DFS. Chronic, non-healing wounds are associated with high risk of infections, resulting in amputations. The aim of this study was to investigate the association between amputations in diabetic foot patients, their oral health and dental care access.

Method: We conducted a prospective study involving 60 individuals with DFS, who were divided into two groups: those with a history of amputation and those without. The study included a questionnaire evaluating oral health, hygiene practices and clinical data such as diabetes duration, and diabetes complications.

Results / Discussion: Patients with amputation had a higher rate of edentulism compared to those without amputation (30.6% vs 8.3%, p=0.056). There were no significant differences in terms of oral-hygiene behaviours. However, in both groups oral practices were suboptimal. 37.5% patients with no amputation and 58% patients with amputation declared brushing their teeth less than twice a day. A regression model demonstrated that history of amputation was associated with limited access to dental care (OR=0.26, p=0.031). This may reflect reverse causality, as disability after amputation can reduce dental attendance.

Conclusion: Poor dental access and amputation risk are likely associated with multiple factors and may have bidirectional relationship. Although oral hygiene status was similarly poor in both groups, individuals with a history of amputation had a higher risk of edentulism. This may reflect greater disability, treatment burden, or limited healthcare engagement in this group.

EP125 To assess real-world characteristics and short-term outcomes of diabetic foot ulcers (DFUS) managed with a multi-modal nitric oxide-generating medical device using a structured clinical follow-up case report form

Natalia Maella-Rius[1], Anabel Palma[1], Francesc Monés-Serrano[1], María Sol Batule Nallim[1]

[1]*Hospital Universitari Germans Trias i Pujol, Badalona, Spain*

Aim: To assess real-world characteristics and short-term outcomes of diabetic foot ulcers (DFUs) managed with a multi-modal nitric oxide-generating medical device using a structured clinical follow-up case report form (CRF).

Method: A prospective observational study was conducted in patients with DFUs of varying severity. A standardized CRF captured demographics, wound characteristics (location, duration, size, tissue type, exudate, arterial status, WIfI classification, infection signs), and treatment variables (offloading, debridement, infection management, dressing performance). Descriptive statistics were applied.

Results / Discussion: Eleven patients (7 male, 4 female; mean age 67 years) were included. All had type 2 diabetes except one with type 1. Six ulcers were neuropathic and five neuroischemic. Most lesions were located on toes (45.4%) or anterior plantar region (36.4%), with low (54.5%) to moderate (45.4%) exudate levels. Mean ulcer duration was 32.5 weeks. WIfI stages indicated heterogeneous ischemia and infection risk; seven patients had palpable pulses. Common tissue types included slough, unhealthy granulation, and necrosis. One case (9%) showed clear infection; five patients (45.4%) received antibiotics. Debridement was frequent, while offloading adherence was inconsistent. During follow-up, six ulcers (54.5%) achieved complete healing, one improved but was lost to follow-up, and the remainder showed good progression and are still being monitored. Dressing usability scores were consistently high across the multidisciplinary team.

Conclusion: This real-world evaluation suggests that a nitric oxide therapy may support wound bed preparation, and promote healing in chronic DFUs when integrated with other interventions (e.g., off-loading, revascularization when needed). Outcomes align with the randomized controlled trial by Edmonds et al. (2018), reinforcing the potential role of nitric oxide-based technology in DFU management. Standardized CRFs enhance data quality and benchmarking for future studies.

EP126 Accelerating healing in diabetic foot ulcers: clinical outcomes of a multimodal nitric oxide–generating dressing with antimicrobial and antibiofilm activity

Francesco Giacinto[1 2 3], Mario Giacinto[4 5 6], Elisabetta Giacinto[7 8]

[1]Spec. In Chirurgia d'Urgenza e PS, Responsabile Ambulatorio di Chirurgia Vulnologica e Rigenerativa Asp CS, Responsabile SIMCRI Calabria, Cosenza, Italy, *[2]Docente Master in Medicina Rigenerativa, Roma, Italy*, *[3]Docente Master in Vulnologia UNINA, Napoli, Italy*, *[4]Podologo - Esperto in Vulnologia e Wound Care, Laurea Magistrale (LM/SNT2) in Scienze della Riabilitazione delle Professioni Sanitarie, Team Manager- Vulnologia Giacinto, Cosenza, Italy*, *[5]Docente del Master del Piede Diabetico - Fondazione Policlinico Universitario A. Gemelli IRCSS, Roma, Roma, Italy*, *[6]Docente al Master in Wound Care - Universotà degli Studi di Napoli "Federico II", Napoli, Italy*, *[7]Specializzanda in medicina Fisica e Riabilitativa Policlinico "A. Gemelli" Cattolica del Del sacro cuore. Roma, Roma, Italy*, *[8]Esperta wound care e medicina estetica e rigenerativa Vulnologia Giacinto Cosenza., Cosenza, Italy*

Aim: To evaluate the effectiveness of a multimodal dressing incorporating nitric oxide (NO)-generating technology with antimicrobial and antibiofilm activity in patients with hard-to-heal diabetic foot ulcers (DFUs).

Method: This case series included seven patients with DFUs of an average duration of 9.9 weeks (range: 2–24 weeks) prior to baseline, all previously treated with standard care. Patients underwent Wound Hygiene procedures and were subsequently treated with the multimodal NO-generating dressing. The primary endpoint was wound area reduction ≥50% within a maximum of 12 weeks of treatment.

Results / Discussion: The mean patient age was 70 years (range: 58–86 years). At baseline, the mean ulcer area was 390.6 mm^2 (range: 24–1456 mm^2; SD: 505.6), with five ulcers located on toes, one on the plantar calcaneus, and one on the plantar forefoot. The mean evaluation period was 32 days (range: 7–63 days). After a maximum of 12 weeks, five DFUs achieved complete healing and two showed significant improvement, with a final mean area of 9.4 mm^2 (range: 0-200 mm^2; SD: 22.4). No new infections occurred during treatment. Exudate levels improved markedly: baseline - 28.5% low, 28.5% moderate, 43% high; final - 71.4% none (healed), 14.3% low, 14.3% moderate. The dressing was rated easy to use, with excellent removal in 85.7% of cases and slightly challenging in 14.3%. Fluid handling was rated excellent in 100% of cases.

Conclusion: This preliminary clinical observation suggests that the multimodal NO-generating dressing is effective in promoting healing of DFUs, while providing protection against local infection and biofilm formation. Moreover, it appears to accelerate average healing times compared to standard of care, supporting its potential role in advanced wound management.

EP128 Regenerative response of fibrin matrix in "biologically infertile" diabetic foot wounds with bone exposure: case series report

Ana Paula dos Santos Albuquerque[1], Prof. José Luis Lázaro-Martínez[2], Priscilla Sckarlat[3]

[1]Regional Hospital of Agreste / Pernambuco State Health Department, Nursing Clinic specializing in wound care., Caruaru, Brazil, *[2]Universidad Complutense de Madrid, Madrid, Spain*, *[3]UNIREGEN Teaching and Research Institute Ltd., Brasília, Brazil*

Aim: To evaluate the regenerative response of autologous fibrin matrix (AFM) in chronic diabetic foot ulcers (DFU) with bone exposure and lack of healing progression despite standard care.

Method: This prospective case series included 4 patients with diabetes presenting chronic DFU with bone exposure and absence of satisfactory granulation after ≥4 weeks of standard treatment. All ulcers showed devitalized tissue and poor regenerative response prior to intervention. Standardized wound bed preparation was performed, including sharp debridement, infection control, and pressure offloading. Autologous fibrin matrix was prepared through blood centrifugation and applied in liquid or membrane form. Reapplications were performed at 7-day intervals according to clinical evolution. Patients were followed for a minimum of 12 weeks. Clinical outcomes included progression of granulation tissue, coverage of exposed bone, wound depth reduction, pain (VAS), exudate control, and adverse events. Wound evolution was documented through serial clinical measurements and photographic records.

Results: Granulation tissue formation over exposed bone was observed in all 4 cases within the first weeks after AFM application. Progressive coverage of exposed structures occurred during follow-up, with substantial reduction in wound depth by week 4. Exudate levels decreased in most cases, and pain scores improved markedly (from severe baseline levels to mild intensity on VAS). No major adverse events or local complications were observed.

Conclusion: In this case series, autologous fibrin matrix promoted rapid granulation and structural coverage in diabetic foot ulcers with bone exposure refractory to conventional therapy. AFM was associated with improved wound bed quality and favorable short-term healing progression. Further controlled studies are necessary to validate its impact on long-term healing and limb preservation.

Case 1:







Case 2:








Case 3:











Case 4:











EP129 efficacy of windowed total contact casting in resistant weight-bearing plantar ulcers associated with charcot neuroarthropathy: A prospective single-center study

Mohamed Zaied[1]

[1]*Faculty of Medicine, Kafrelsheikh University, Kafrelsheikh, Egypt*

Aim: To evaluate the efficacy of windowed Total Contact Casting in achieving ulcer healing, assess associated infection and recurrence rates in patients with resistant weight-bearing plantar ulcers secondary to Charcot neuroarthropathy.

Method: This prospective study was conducted in the Vascular Surgery Department, Kafrelsheikh University Hospital, from May 2024 to October 2025. Twenty-five patients with active Charcot neuroarthropathy and persistent weight-bearing plantar ulcers unresponsive to prior offloading modalities were enrolled. windowed casts were applied in positions that eliminated plantar pressure over the ulcer zone while maintaining full immobilization of the Charcot segment. Serial weekly assessments were performed.



Figure 1. Mid foot resistant ulcer for 4 years in windowed cast in planter flexion and complete healing in 12 weeks



Figure 2. Complete healing of heal ulcer in 17 weeks

Results / Discussion: In 25 patients, 16 were male and 17 presented with clinically infected ulcers. Complete ulcer healing was achieved in 18 patients (72%), while secondary infection developed in 6 patients (24%) during treatment. Two patients (8%) experienced new pressure ulcers attributable to cast edge or interface pressure; both resolved after cast revision. No major complications, deep infection, or progression to osteomyelitis necessitating surgical intervention occurred.

Conclusion: Windowed Total Contact Casting is a highly effective modality for resistant plantar ulcers in the context of Charcot neuroarthropathy. The technique provides reliable offloading, protects against further mechanical trauma, and allows ongoing joint stabilization—even in active deformity. High healing rates and an acceptable complication profile underscore its value as a limb-salvage strategy in complex diabetic foot reconstruction. Meticulous cast design, strict weekly surveillance, and early management of pressure-related issues are essential to optimize outcomes.

EP130 Skin micrograft for the management of hard and no- healing leg ulcers: a case series

Carlo Rivellini[1], Salvatore Piazza[2]

[1]AIUC, SIC, SICVE, AFI, Italy, *[2]AIUC, SICVE, TORINO, Italy*

Aim: This retrospective case series evaluated the clinical outcomes of skin micrograft therapy in managing hard-to-heal and no-heal leg ulcers.

Method: A total of 12 patients with no-heal and hard-heal leg ulcers (8 patients had a DFU, biabetic ulcer foot), who were treated in a territorial vulnological system, were included in this study. The primary outcome was the wound healing rate at 12 weeks. Secondary outcomes comprised the time to complete epithelialization, wound area reduction (WAR) at 4 and 12 weeks, and the incidence of adverse events. After treatment with hy-tissue micrograft (HT-MG), 8 (66%) of patients achieved complete wound closure within 12 weeks. No adverse effects related to the infiltration procedure at wound site were recorded with a promising wound healing rate during the follow-up period.

Results / Discussion: Several studies have demonstrated the potential benefits of using the conventional punch grafting technique on various wound etiologies. Furthermore, the literature has explored various types of skin micrografts across different wound settings, with the level of success varying due to process heterogeneity. The HT-MG offers several advantages that are particularly relevant for the common characteristics of DFU and other leg ulcers, compared to other similar techniques. Grinding and infiltration with HT-MG can be applied directly to the wound, streamlining the treatment process.

Conclusion: These results suggest that HT-MG could be a safe and effective treatment option for chronic leg ulcers and particularly DFU, promoting noteworthy wound healing and reducing healing times. Further studies are required to confirm these findings and assess long-term outcomes

EP131 Chemical debridement in complex diabetic foot wounds

Alpa Lakhani[1], Caoimhe Joyce-Hearne[1], Shi Pin Lim[1], Prashanth Vas[1], Hany Zayed[1]

[1]Guys and St Thomas' NHS trust, London, United Kingdom

Aim: Debridement is essential for managing diabetic foot ulceration (DFU); however, the gold standard, sharp debridement, may not always yield the desired outcomes. A novel topical desiccation agent (TDA) containing methane sulfonic acid may offer an alternative means of achieving adequate wound control to promote granulation and enhance the potential for wound healing. We evaluated the effectiveness of TDA in complex DFU with refractory necrotic tissue and biofilm expression resistant to sharp debridement.

Method: Prospective analysis of 10 patients with hard-to-heal ulcers, of which 80% had peripheral arterial disease (PAD). All DFU were TEXAS 2 B/D or 3B/D, IDSA2 were present for at least 2 weeks and received a minimum of four rounds of sharp debridement. A single application of TDA was undertaken. Over a six-week period, outcomes

evaluated were the development of new granulation, the proportion achieving a 50% percentage area reduction of (50%PAR), patient-reported pain reduction using the numeric rating scale (NRS), and the use of systemic antibiotics for new infection.

Results / Discussion: TDA application facilitated new granulation tissue formation in 80% of cases, with 70% of patients achieving measurable wound size and/or depth reduction. A 50%PAR was observed in 50% of patients within six weeks. Importantly, no new systemic antibiotics were started on 80% of patients post-TDA application. No adverse effects were reported.

Conclusion: Our experience indicates a significant potential for the novel TDA in enhancing the debridement process for wounds refractory to standard sharp debridement with improvements in key wound healing indicators. The lack of adverse events emphasises its safety profile. These findings imply that TDA may be a valuable adjunct in managing complex wounds resistant to conventional debridement methods.

EP132 Wound care-driven limb salvage: Amputation patterns and functional outcomes in a tertiary diabetic foot centre

Rajesh Kesavan[1], Savitha Rajesh[2], Darwin Britto[2], Sheela Sasikumar[2]

[1]Dr.RK Diabetic Foot and Podiatry Institute and Rakesh Jhunjhunwalla Amputation Prevention Center, Meenakshi Academy of Higher Education and Research, Chennai, India, *[2]Dr.RK Diabetic Foot and Podiatry Institute and Rakesh Jhunjhunwalla Amputation Prevention Center, Chennai, India*

Aim: This study aims to evaluate amputation rates and functional recovery in patients who were managed under a multidisciplinary limb salvage model.

Method: A retrospective review was conducted for all surgical admissions (January 2024–January 2025) at Dr RK Diabetic Foot and Podiatry Institute with IEC approval. Data collected included demographics, comorbidities, ulcer site, details of limb salvage and amputation procedures, mortality, and one-year quality-of-life outcomes.

Results / Discussion: Among 856 surgical admissions, 821 limbs were salvaged and 35 amputations were performed, resulting in an amputation rate of 4.06%. Amputees were predominantly male (74.3%) and between 50–70 years of age. Below-knee amputations accounted for 74.2% of procedures. Mortality was 11.1% for above-knee and 7.7% for below-knee amputations. At one year, all respondents used prosthetics or assistive devices; 83% maintained indoor mobility and 92% remained independent in personal care. Emotional distress was reported by 29% of patients. Follow-up completion was 100%.

Conclusion: The amputation rate of 4.06% reflected the effectiveness of the multidisciplinary limb salvage strategies implemented. Although functional recovery was generally positive, the persistence of emotional distress in nearly one-third of patients highlighted the need for integrated psychosocial and rehabilitative support to optimize long-term outcomes.

EP133 Foot Washing campaign: Strategy for preventing foot ulcers in people with diabetes mellitus in Brazil

Lidiany Felix[1], Kleane Araújo[1], Auridete Almeida[2], Camilla Andrade[3]

[1]Universidade Federal de Campina Grande, Paraíba, Brazil, *[2]Secretaria Municipal de Saúde de Campina Grande, Campina Grande, Brazil*, *[3]APS Santa Marcelina, São Paulo, Brazil*

Aim: report on the experience of implementing the “Foot Washing” campaign, a social action to prevent foot ulcers in people with DM. This initiative is inspired by a national strategy of the Ministry of Health to alert the population to the risks of DM and promote popular health education, associating preventive care with the Christian symbolism of Easter (the act of Jesus washing the feet of his disciples).

Method: Descriptive study in the form of an experience report, conducted in April 2025 at a Basic Family Health Unit in northeastern Brazil. The initiative was organized by faculty and students from the Nursing program at the Federal University of Campina Grande, in partnership with nurses from the service.

Results / Discussion: Fifty people with DM participated in the intervention. Upon arrival at the service, their feet were inspected and washed by nursing students and/or teachers. This procedure consists of inspecting and cleaning the feet. The purpose of this interaction was to welcome users and facilitate the early identification of possible changes. Next, blood pressure and capillary blood glucose were measured, and a complete physical examination of the feet was performed (tactile and vibratory sensitivity test and palpation of the pulses). Cases with changes in the examination or occasional findings were discussed and referred to the medical team at the service. Patients received group guidance on foot self-care practices, treatment, and diabetes monitoring.

Conclusion: The "Foot Washing" campaign demonstrated potential to facilitate bonding and deepen understanding about diabetes and its complications, promoting access to preventive care in a humane and effective manner, especially in the context of Primary Health Care.

DRESSINGS

EP135 DACC-coated dressings attenuate the negative effects of pseudomonas metabolites on keratinocyte wound healing in vitro

Kirsten Reddersen[1], Sara Sjögren[2], Johanna Husmark[2], Cornelia Wiegand[1]

[1]Department of Dermatology, Jena University Hospital, Jena, Germany, *[2]R&D Infection Management, Essity Hygiene and Health AB, Mölndal, Sweden*

Aim: Bacterial virulence factors, such as toxins and LPS, can impair keratinocyte function and delay wound healing. This study investigated the effect of Pseudomonas aeruginosa culture supernatants on wound closure using a keratinocyte scratch assay and evaluated the modulatory role of dialkylcarbamoyl chloride (DACC)-coated dressings compared to polyester (PES). IL-1α, IL-6, and IL-8 secretion was measured as indicators of inflammation and tissue regeneration.

Method: P. aeruginosa was cultured to logarithmic phase and adjusted to 3–5 × 10^6 cfu/mL. DACC-coated dressings and PES controls were incubated with bacterial suspensions for 24 h; supernatants were sterile-filtered for downstream assays. Human keratinocytes (HaCaT cells) were cultured to confluence, scratched, and treated with bacterial supernatants for 1–48 h. Wound closure was assessed via hematoxylin-eosin staining, digital microscopy and ImageJ-based quantification. Cytokine release (IL-1α, IL-6, IL-8) was determined by ELISA and expressed relative to medium controls.

Results / Discussion: P. aeruginosa supernatants delayed wound closure dose-dependently, with no healing observed at 1:1 dilution, and induced IL-1α, IL-6, and IL-8. PES reduced cytotoxicity and improved wound closure but did not reach levels of the physiological control. DACC-coated dressings further decreased bacterial metabolite and LPS-mediated toxicity, enhancing wound closure, and achieving complete regeneration at 1:2 and 1:10 dilutions comparable to the physiological control. IL-1α levels were lower in conditions with improved healing, while IL-6 and IL-8 showed a favorable balance supporting repair.

Conclusion: DACC-coated dressings mitigate bacterial metabolite toxicity and modulate cytokine responses, promoting keratinocyte recovery and in vitro wound healing. Material-dependent strategies may enhance tissue repair while maintaining controlled inflammatory signaling.

EP136 SmartSearch for Wound Sensors: A searchable, sensor-parameter-driven literature database of sensor technologies in wound dressings

Anika Fourie[1], Tim Torsy[1 2], Knaerke Soegaard[1], Amit Gefen[1 3 4], Daphne Weihs[1 4 5], Wim Deferme[6 7], Dimitri Beeckman[1 8]

[1]Skin Integrity Research Group (SKINT), University Centre for Nursing and Midwifery, Department of Public Health and Primary Care, Faculty of Medicine and Health Sciences, Ghent University, Ghent, Belgium, *[2]Department of Nursing and Midwifery, Odisee University of Applied Sciences, Sint-Niklaas, Belgium*, *[3]Department of Biomedical Engineering, Faculty of Engineering, Tel Aviv University, Tel Aviv, Israel*, *[4]Department of Mathematics and Statistics and the Data Science Institute, Faculty of Sciences, Hasselt University, Hasselt, Belgium*, *[5]Faculty of Biomedical Engineering, Technion-Israel Institute of Technology, Haifa, Israel*, *[6]Hasselt University, Institute for Material Research (IMO), Hasselt, Belgium*, *[7]IMEC, division IMOMEC, Diepenbeek, Belgium*, *[8]Swedish Centre for Skin and Wound Research (SCENTR), School of Health Sciences, Faculty of Medicine and Health, Örebro University, Örebro, Sweden*

Aim: Real-time wound-sensing technologies, including sensors measuring pH, temperature, moisture, and oxygen, offer tools for monitoring wound status, optimising treatment, and improving healing. However, evidence on wound parameter changes remains limited. As part of the SURMOUNT project, which combines sensors, sensor fusion in wound dressings, animal models, and AI to understand sensor performance, this mapping review synthesises existing evidence on wound care sensor technologies. It aims to support decision-making and advance smart wound dressing development using sensor fusion and data analytics to address wound management gaps.

Method: A literature search was conducted across nine academic databases covering health sciences and engineering. Records unrelated to sensor applications in wound care were excluded. Data extraction focused on sensor integration within dressings (stand-alone, single, multiple), source types, sensor measurement parameters, substrate materials, sensing mechanisms, and study phases. A searchable database with full-text links and data filters was created in Microsoft Excel using data up to April 2025. A stakeholder panel within the project consortium provided structured feedback on user experience, data quality, and usefulness.

Results / Discussion: The search identified 165 records from 17,228 entries, highlighting progress in wound-sensing technology over five years. Clinical validation remains limited, with few comparative studies or commercial technologies. Stakeholders confirmed the database's effectiveness as a research tool to identify gaps and guide wound dressing development. Academic database alerts were set to database relevance.

Conclusion: This literature database consolidates evidence on wound-sensing technologies into a user-friendly tool for clinicians, researchers, and industry. It enables identification of gaps, supports evidence-based decisions, and is regularly updated. By providing comprehensive data and filters, it streamlines research, accelerates clinical adoption, and improves outcomes through optimised smart dressings.

EP137 Aluminized low-adherent wound dressing in acute wound management: an international, prospective, multicentre, observational study

Luc Gryson[1], Norbert Kolbig[2], Ojan Assadian[3], Martin Weiner[3], Angela Odame[4], Angrit Namislo[4], Martin Abel[4]

[1]Centrum voor Nascholing en Posthogeschoolvorming (CNPV), Poperinge, Belgium, *[2]University Hospital Düsseldorf, Düsseldorf, Germany*, *[3]University Hospital Wiener Neustadt, Wiener Neustadt, Austria*, *[4]Lohmann & Rauscher GmbH & Co. KG, Neuwied, Germany*

Aim: To evaluate the safety and performance of an aluminized, low-adherent[1] wound dressing for the treatment of acute wounds in routine clinical practice.

Method: A prospective, multicentre, observational Post-Market Clinical Follow-up (PMCF) study was conducted involving 63 healthcare professionals (nurses with a specialisation in wound management) who treated 434 patients— primarily with acute wounds— over several weeks according to standard clinical practice in Germany, Austria, Belgium, and Colombia. After treatment with the aluminized, low-adherent[1] wound dressing, participants completed a questionnaire (online or paper-based) assessing key parameters such as performance, quality, usability, and safety.

Results/Discussion: Several wounds were treated, predominantly acute (82.5%) with low-to-moderate exudate levels, including burns, post-operative wounds, skin tears, cuts, and abrasions. Most participants applied the dressing for up to 7 days on a single patient, with dressing changes typically occurring every 2–3 days. The dressing provided consistent and reliable wound coverage, effectively managed exudate, and minimized the risk of adhesion, enabling atraumatic dressing changes. The majority of participants (85.7%) reported that the atraumatic dressing changes and the established wound rest provided by the dressing positively influenced the healing process, confirming its supportive role in wound healing. Clinicians described the dressing as soft, smooth, and gentle on the wound. Overall ratings on a six-point scale were favorable : performance (mean 2.25), safety (mean 2.21), and usability (mean 2.26). While nine side effects were reported, no severe adverse events occurred.

Conclusion: Study results confirmed that the aluminized, low-adherent[1] wound dressing is safe, well-tolerated, and effective for treating acute wounds in routine clinical practice. It reduces the risk of wound adhesion and pain during dressing changes, thereby supporting wound healing.

1 Metalline® Wound Dressing

EP138 Plant-derived bioadhesive formulation and physicochemical properties

Giorgi Bakuridze[1], Aliosha Bakuridze[1]

[1]Tbilisi State Medical University, Tbilisi, Georgia

Aim: The aim of the study is the determination and development of a bioadhesive containing new plant ingredients with antimicrobial, anti-inflammatory, hemostatic, and wound-healing effects. The objectives included the selection of excipients responsible for the formation of the bioadhesive, the determination of quality indicators, the determination of the antibacterial activity spectrum, and the determination of stability.

Method: Homogeneity was assessed using a microscope. Antibacterial activity was determined by the “Spot Test” method in a bacteriological and virology institute. Stability was evaluated by determining quality indicators during storage under normal conditions. The study objects were tannic acid, which contains 25 highly active phenolic hydroxyl groups capable of forming hydrogen bonds with amino groups on biological tissue surfaces, and tannin.

Results / Discussion: Organoleptic and physicochemical properties of formulations containing tannic acid were determined. Adhesive force, adhesion duration, moisture resistance, elasticity, and pH were assessed, and optimal formulations were identified. The bioadhesive showed activity on skin and biological tissues. The bioadhesive showed expressed and broad-spectrum antibacterial activity. Skin-irritation testing showed no irritation. The adhesive preserved optimal quality indicators for six months during storage.

Conclusion: The composition and formulations of tannic-acid- and tannin-containing bioadhesives were determined. Quality indicators and consumer properties were within optimal limits. “Spot Test” showed expressed antibacterial activity, and the adhesive did not cause skin irritation. Bioadhesive characteristics include natural formulation, ease of use, absence of skin irritation, expressed antibacterial activity, and the presence of biologically active substances of different chemical nature and action.

EP139 A dual gene-activated dermal scaffold loaded with nanocomposite particles co-expressing of VEGF and aFGF: Early vascularization to promote wound healing

Jialiang Wang[1], Xingang Wang[1]

[1]Department of Burns & Wound Care Center, Second Affiliated Hospital of Zhejiang University, College of Medicine, Zhejiang Key Laboratory of Trauma, Burn, and Medical Rescue, Zhejiang university, Hangzhou, China

Aim: To enhance the repair efficiency of dermal scaffolds for skin defect wounds, a dual gene-active scaffold (DGAS-M) with high co-expression of vascular endothelial growth factor (VEGF) and acidic fibroblast growth factor (aFGF) was constructed to improve early vascularization and vascular maturation of the dermal scaffolds.

Method: We encapsulated plasmid DNA (pDNA-VEGF and pDNA-aFGF) within liposomes to prepare nanocomposite particles (NPs) and the NPs were loaded onto PLGA (80-110 kDa) mesh-reinforced collagen/chitosan (Type I collagen and chitosan at 0.5% and 5%, respectively, in a mass ratio of 9:1) scaffolds to form DGAS-M. The performance of early vascularization and vascular maturation was evaluated in vitro, rat subcutaneous implantation models, and "one-step" full-thickness skin defect rat models.

Results / Discussion: NPs were measured to be 108.43 ± 3.38 nm and DGAS-M could release 70% of the NPs over 9 days. DGAS-M also exerted effects on the proliferation of umbilical vein endothelial cells while promoting angiogenesis, and the synthesis and secretion of VEGF and aFGF in vitro. Using rat subcutaneous implantation models, the results of gross observation and immunofluorescence showed the optimal gene loading dose was 15 μg/unit. Furthermore, in a rat full-thickness skin defect model, DGAS-M enhanced the survival rate of split-thickness skin grafts by 20.8% during the first 14 days post-surgery via "one-step" operation. The laser Doppler results showed DGAS-M increased wound blood flow, while IF and WB results suggested DGAS-M increased wound angiogenesis, reduced inflammation and promoted wound healing.

Conclusion: In this experiment, we developed DGAS-M loaded with NPs co-expressing VEGF and aFGF. Our findings demonstrated DGAS-M had an effect on vascularization and vascular maturation in vitro and vivo. DGAS-M exhibited the capacity to increase the vascularization in the wound and diminish the release of inflammatory factors, thereby promoting collagen deposition and enhancing healing quality.

EP422 Patient-reported and clinical outcomes of calcium alginate versus polyurethane dressings: A systematic review and meta-analysis

Sarmad Elahi Chattha[1], Moawiz Shahzad Chattha[2], Fahad Amin[1]

[1]*King Edward Medical University, Lahore, Pakistan*, [2]*Allama Iqbal Medical College, Lahore, Pakistan*

Aim: Acute traumatic and postoperative wounds require dressings that reduce pain, improve comfort, and support timely epithelialization. Calcium alginate and polyurethane are commonly used, but comparative evidence is inconsistent. This systematic review and meta-analysis evaluated whether calcium alginate offers any advantage over polyurethane in pain relief, patient satisfaction, or epithelialization, providing clearer clinical guidance and identifying gaps for future research.

Method: A systematic search identified randomized controlled trials comparing calcium alginate with polyurethane dressings. Extracted data included study design, sample size, demographics, wound type, and follow-up duration. Primary outcomes were pain scores, patient satisfaction, and time to re-epithelialization. Pooled effect sizes (SMD, MD, and RR when applicable) with 95% CIs were generated using random-effects models, and heterogeneity was assessed using I^2 statistics.

Results / Discussion: Five randomized controlled trials (n = 157) were included, with sample sizes ranging from 16 to 38 and mean ages from 32 to 79 years. Male proportion varied between 18% and 55%, and follow-up durations ranged from 10 days to 12 weeks. Calcium alginate did not demonstrate consistent superiority over polyurethane for pain reduction (SMD 3.29; 95% CI -3.94 to 10.51; I^2 = 96.6%). Patient satisfaction showed no significant difference (SMD 0.54; 95% CI -0.54 to 1.61; I^2 = 83.2%). Time to epithelialization also revealed no meaningful advantage (MD 0.86 days; 95% CI -5.29 to 7.01; I^2 = 98.8%). High heterogeneity likely reflects variations in wound type, assessment scales, and follow-up.

Conclusion: Current evidence does not favor calcium alginate over polyurethane dressings for pain relief, patient satisfaction, or epithelialization. Further standardized, well-powered RCTs are needed to clarify optimal dressing selection in wound care.

EP140 Quality of life of people with diabetes, diabetic foot ulcer and reduced or missing pain sensation or "The communication with a part of my body is missing"

Alexander Risse[1], Ralf Lobmann[2], Arthur Grünerbel[3], Claas Lüdemann[4 4], Stephan Morbach[5], Holger Lawall[6], Holger Diener[7], Christoph Volkering[8], Bernhard Kulzer[9]

[1]Diabeteszentrum, Berlin, Germany, *[2]Klinikum Stuttgart, Klinik für Innere Medizin, Abteilung für Endkrinologie, Diabetologie und Geriatrie, Stuttgart, Germany*, *[3]Diabeteszentrum München Süd, München, Germany*, *[4]Krankenhaus Brixen, Abteilung für Innere Medizin, Brixen, Italy*, *[5]Marienkrankenhaus Soest, Abteilung für Diabetologie und Angiologie, Soest, Germany*, *[6]Gemeinschaftspraxis für Herz-Kreislauferkrankungen, Akademie für Gefäßkrankheiten, Ettlingen, Germany*, *[7]Krankenhaus Buchholz, Abteilung für Gefäßchirurgie und endovaskuläre Chirurgie, Buchholz, Germany*, *[8]Praxis Orthoevo, München, Germany*, *[9]FIDAM GmbH Forschungsinstitut, Diabetes-Akademie, Bad Mergentheim, Germany*

Aim: The wound-specific quality of life of people with diabetes and diabetic foot syndrome (DFU) is usually measured using questionnaires such as WoundQoL. It is questionable whether this instrument is also valid for people with DFU and loss of protective pain (LOPP), as the items relating to pain do not apply to this group. The aim of this study is to use interviews with people with LOPP to generate content for additional items that could potentially form a separate scale for LOPP in the WoundQoL.

Method: In a first step, an interdisciplinary group of 10 experts (psychologists and diabetologists) interviewed 10 people with acute DFU and LOPP (Mean age: 73.9±11.4 years; DM duration: 23.9±12.6 years; DFS duration: 9.4±8.1 years;70% no pain sensation, 30% severely reduced). In a second step, the group formulated items based on the results of the interviews.

Results / Discussion: Patients are aware that the lack of pain perception means new risks for the prognosis of their foot ulcer, since they no longer feel their feet ("the communication with a part of my body is missing"). The main topics covered in the interviews related to no pain, better sleep, worries due to LOPP, fewer worries, improved everyday activities, unsteady gait/increased risk of falling, poor perception of the foot, worries about injuries.

Conclusion: The results of the interviews support the hypothesis that there are specific burdens and issues for people with LOPP. The items obtained from this study will be used in a further quantitative study (n = 125) to verify their psychometric quality. The aim is to clarify whether an additional subscale of the WoundQoL is necessary for LOPP.

EP141 Characterisation of novel wound dressings using wound infection model on diabetic rats

Kelli Randmäe[1], Kaisa Põhako-Palu[1], Mariliis Hinnu[2], Oksana Gerulis[1], Marta Putrinš[1], Ivo Laidmäe[1], Tanel Tenson[3], Karin Kogermann[1]

[1]Institute of Pharmacy, University of Tartu, Tartu, Estonia, *[2]Institute of Molecular and Cell Biology, University of Tartu, Tartu, Estonia*, *[3]Institute of Technology, University of Tartu, Tartu, Estonia*

Aim: The aim of this study was to assess the efficacy and safety of novel electrospun (ES) antimicrobial wound dressings in a diabetic rat wound infection model.

Method: Previously developed diabetic rat wound infection model was used. Dermatome wounds were used to study the efficacy and safety of ES polycaprolactone-polyethylene oxide-chloramphenicol (PCL-PEO-CAM) wound-dressings. Two wounds were created on the back of each animal and infected with 10E7 CFU/wound *S. aureus* DSM2569 artificial biofilm. Treatments were applied 24h after wounding and inoculation and kept for 24h or 72h. One wound was treated with PCL-PEO-CAM and commercial hydrogel as a secondary dressing. The other wound was used as a control and covered only with hydrogel. Wound healing, infection development, and immune reaction response to infection were assessed by measuring the wound dimensions, colony forming units (CFU) and cytokine levels, respectively. Histopathological analysis were performed to evaluate wound healing.

Results: Non-treated infected wounds showed consistently high bacterial loads after 72h. The PCL-PEO-CAM-treated wounds contained one log less bacteria than the hydrogel-covered control wounds. Hydrogel enabled to maintain moisture in the wound. The PCL-PEO-CAM-treated wounds had two times smaller IL-6 level compared to hydrogel-covered wounds at 72h. Histopathology analysis did not show any differences between treated and non-treated wounds in these early time-points.

EP142 Cutaneous safety and clinical performance of octenidine in pediatric wound care: A case series

Pablo García-Molina[1], Evelin Balaguer-López[1], Javier Estañ-Capell[1], Pedro García-Martínez[1], Maria Carmen Rodríguez Dolz[1]

[1]Nursing departament. University of Valencia, Hospital Clínico Universitario de Valencia, Upppediatria, Valencia, Spain

Aim: To assess the cutaneous safety and clinical performance of octenidine-based solutions in pediatric wound care by analyzing wound progression and local tolerability in seven patients aged 3–17 years.

Method: A retrospective case series of seven pediatric patients was conducted. Wound etiologies included thermal burns, friction injuries, traumatic lacerations, surgical dehiscence and pressure injuries. All patients were managed using a standardized wound hygiene protocol involving saline irrigation, timed exposure to octenidine solution or gel, and mechanical or sharp debridement. Dressing selection and change frequency followed clinical criteria. Variables collected included baseline infection status, systemic antimicrobial therapy, wound-bed characteristics, granulation and epithelialization dynamics, and any octenidine-related events. The primary endpoint was local tolerability; secondary endpoints were wound progression and infection control.

Results / Discussion: All seven patients completed treatment with octenidine without interruption. Three presented with confirmed or suspected infection and received systemic antibiotics, achieving resolution in all cases. No local adverse reactions attributable to octenidine were observed. No erythema, stinging, dermatitis, edema or tissue injury was reported. Wound evolution showed consistent progression from non-viable or contaminated tissue to granulation and epithelialization. Burns and dehiscence cases demonstrated notable improvement in wound-bed quality following repeated octenidine-based hygiene. The absence of adverse reactions across varied wound types supports the low cytotoxicity of octenidine in literature. The structured hygiene protocol may have contributed to infection resolution and wound-bed optimization.

Conclusion: Octenidine-based solution and gel demonstrated a favorable safety profile and supported wound-bed preparation in pediatric patients aged 3–17 years. The absence of local adverse events and the consistent improvement observed across diverse wound types indicate that octenidine is suitable for integration into pediatric wound hygiene protocols.

EP143 Managing chronic wounds with tlc-nosf dressings: Evidence from a prospective real-world cohort of 367 patients

Dr. Hester Colboc[1]

[1]Hopital Rothschild - APHP, Paris, France

Aim: To evaluate the performances of TLC-NOSF dressings in local management of chronic wounds in France.

Method: This multicentre, prospective, observational study with two polyabsorbent TLC-NOSF dressings (UrgoStart Plus® Pad and UrgoStart Plus® Border) and one non-adherent TLC-NOSF contact layer (UrgoStart® Contact) was conducted in France between June 2022 and July 2024. Main outcomes included wound healing rate within 12 weeks, clinical assessment of wound healing progression, local tolerability and acceptance of dressings.

Results / Discussion: 367 patients with venous leg ulcers (VLU) or diabetic foot ulcers (DFU) were treated with the evaluated dressings in 53 centers. By the last visit, wound healing was reported in 44.5% of VLU and 35.5% of DFU

and thus, a wound closure or an improvement in wound healing was reported in 82.6% of VLU and in 83.0% of DFU. Healing was optimal for wounds with the shortest duration at initiation of treatment (<3 months), with 68% VLU healed compared to 27%, and with 51% DFU healed compared to 27% for wounds with >6 months duration at initiation of treatment. At the final visit, dressings were judged by the investigators as 'extremely useful'/'useful' in 86.0% of patients and 'very well accepted'/'well accepted' by 95.9% of patients.

To conclude, consistent with findings from previous clinical evidence, this study confirms the wound-healing benefits of TLC-NOSF technology in the management of DFU and VLU and its positive impact on patient quality of life.

Conclusion: Combined with excellent tolerance and high acceptability among both patients and healthcare professionals, these findings reinforce the use of TLC-NOSF dressings as a first-line intervention and throughout the healing process in the local management of chronic wounds.

EP144 Non-toxic control of exudate and anionic burden as a foundational strategy for restoring chronic wounds to a healing trajectory

Robert Frykberg[1], Darlene McCord[2]

[1]University of Texas San Antonio, San Antonio, Texas, United States, *[2]McCord Research, Chatanooga, TN, United States*

Aim: Exudate plays a central role in wound physiology, supporting repair when balanced but driving tissue damage when excessive or biochemically deranged. Chronic wound exudate—persistently high-volume, chloride-rich fluid loaded with proteases, bacteria, and inflammatory mediators—creates a destructive microenvironment that promotes maceration, delays re-epithelialization, and sustains chronic inflammation. Traditional management strategies often rely on antiseptics that, despite reducing microbial load, demonstrate significant cytotoxicity to keratinocytes and fibroblasts, undermining tissue regeneration. This study reviews the biochemical composition of chronic exudate, with an emphasis on chloride as the predominant anion, and evaluates non-toxic, cell-compatible strategies for controlling exudate and anion levels.

Method: A comprehensive analysis of published clinical and laboratory literature was conducted to characterize the ionic, proteolytic, and microbial features of chronic wound exudate and to evaluate the impact of cytotoxic versus non-cytotoxic management technologies on wound healing.

Results / Discussion: Chronic exudate contains elevated MMP-2/MMP-9, reduced protease inhibitors, a high bacterial burden, altered pH, and large concentrations of chloride ions, analogous to those found in plasma. Antiseptics commonly used to control bioburden display marked cytotoxicity, reducing the viability of fibroblasts and keratinocytes at clinically relevant concentrations. In contrast, advanced absorbent dressings, ion-interactive materials, and non-cytotoxic cleansers effectively manage fluid and help normalize the ionic environment without harming host cells.

Conclusion: Non-toxic exudate and anion control represent a critical therapeutic target in chronic wound management. Strategies that remove or neutralize chloride-rich exudate more effectively interrupt the cycle of inflammation, protease-driven tissue destruction, and delayed healing. These findings support the integration of ion-modulating and exudate-responsive technologies,

EP145 Comparative evaluation of hyaluronic acid-based dressing versus hydrocolloid dressing in rat dermal wound healing

Hyemi Lee[1], Na Young-cheon[1], Jong Won Rhie[1], Hyeon Hee Lee[1], Seoul Lee[2]

[1]Department of Plastic and Reconstructive Surgery, Wonkwang University Hospital, Iksan, Korea, Rep. of South, [2]Pharmacology, Wonkwang University, Iksan, Korea, Rep. of South

Aim: Dressing materials play a critical role in creating barriers against contaminants, maintaining optimal moisture levels, and absorbing wound exudate. Hyaluronic acid (HA) is a natural biocompatible polymer that supports healing by regulating inflammation and promoting tissue repair. This study compared HA- and hydrocolloid-based hydrogels in a rat model to optimize wound care strategies.

Method: Full-thickness dermal wounds (diameter, 8 mm) were created on the dorsal skin of 12 Sprague-Dawley rats under sevoflurane anesthesia. The wounds were treated with HA/silver sulfadiazine gel (group A), hydrocolloid gel (group B), or left untreated(control), all covered with a transparent dressing. Biopsy specimens on days 3, 7, and 21 were used to assess histological parameters: inflammatory cell infiltration, fibroblast infiltration, collagen deposition, neovascularization, and epithelial thickness, using a semi-quantitative scoring system. Histological analyses were conducted blindly, and statistical analyses were performed using the Kruskal-Wallis test ($p < 0.05$).

Results / Discussion: On day 3, group A showed significantly higher inflammatory cell infiltration and collagen deposition than other groups, indicating extracellular matrix formation. By day 7, angiogenesis was highest in group A, followed by group B and controls. By day 21, epithelial layer thickness, reflecting inflammation and fibroblast maturity, was significantly higher in group A.

Conclusion: This study compared HA-based hydrogel and hydrocolloid-based dressings through histological analyses to elucidate wound healing mechanics. HA-based hydrogel dressings significantly enhanced wound recovery. These findings underscore the potential of HA-based dressings to enhance clinical outcomes in wound management, suggesting avenues for improving therapeutic strategies.

Table 1. Wound healing parameters on day 7 using a semi-quantitative scoring system

Parameter	Control	Group A	Group B	*p*-value
Inflammation	2.25 ± 0.50	2.50 ± 0.58	2.50 ± 1.00	0.671
Angiogenesis	1.25 ± 0.50	3.00 ± 0.00	1.75 ± 0.58	0.011
Fibroblast	2.25 ± 0.50	2.75 ± 0.50	2.50 ± 0.58	0.400
Collagen fiber	1.50 ± 0.58	1.75 ± 0.50	2.50 ± 0.58	0.180
Re-epithelization (μm)[a)]	0	0	0	0

Values are presented as mean±standard deviation. Using a semi-quantitative scoring system: 0, absent; 1, mild; 2, moderate; 3, severe.
Group A, using HA/silver sulfadiazine gel; Group B, using hydrocolloid gel.
[a)]Re-epithelization is the thinnest portion of the newly formed epithelium.

Table 2. Wound healing parameters on day 21 using a semi-quantitative scoring system

Parameter	Control	Group A	Group B	*p*-value
Inflammation	1.00 ± 0.82	1.25 ± 0.96	0.50 ± 0.58	0.411
Angiogenesis	1.00 ± 0.00	1.75 ± 0.00	1.00 ± 0.00	0.111
Fibroblast	1.00 ± 0.00	1.00 ± 0.00	1.00 ± 0.00	-
Collagen fiber	1.75 ± 0.50	2.25 ± 0.50	2.00 ± 0.00	0.503
Re-epithelization (μm)[a)]	267.75 ± 118.88	695.00 ± 221.14	370.25 ± 62.14	0.037

Values are presented as mean±standard deviation. Using a semi-quantitative scoring system: 0, absent; 1, mild; 2, moderate; 3, severe.
Group A, using HA/silver sulfadiazine gel; Group B, using hydrocolloid gel.
[a)]Re-epithelization is the thinnest portion of the newly formed epithelium.

EP146 Improved management of venous leg ulcers using copper oxide dressings

Amir Carmeli[1], Dr. Gadi Borkow[1]

[1]*MedCu Technologies Ltd., Herzliya, Israel*

Aim: Venous leg ulcers (VLUs) are chronic wounds caused by venous insufficiency and frequently fail to respond to standard care. The aim of the study was to evaluate the therapeutic potential of copper oxide–impregnated wound dressings (Copper Dressings) in hard-to-heal VLUs.

Method: Twenty-five patients with chronic VLUs—including cases unresponsive for years to standard care such as negative pressure wound therapy (NPWT) and conventional dressings—were treated with Copper Dressings. Each case was managed by different wound specialists from diverse geographic regions. Patients presented with complex profiles and multiple comorbidities, including chronic venous insufficiency, lymphedema, malnutrition, diabetes, rheumatoid arthritis, and wound infections. No adjunctive antimicrobial agents were used.

Results / Discussion: All wounds showed marked improvement after initiation of Copper Dressings, with accelerated autolytic debridement, granulation, epithelialization, and reduced periwound edema and exudate. The mean RESVECH 2.0 score improved from 19.61 ± 1.12 at baseline to 2.54 ± 1.01 at the end of treatment. Dressing use lasted 9.5 ± 6 weeks, and 80% of VLUs achieved closure within 12 weeks - substantially higher than the 30-40% reported in the literature for standard care. Patients received varying levels of compression therapy (light to strong; stockings to single- or multi-layer bandaging), demonstrating compatibility of Copper Dressings with all compression modalities. These outcomes align with known biological roles of copper in wound healing, including stimulation of angiogenesis and extracellular matrix remodeling, along with broad antimicrobial protection.

Conclusion: The consistent clinical improvements support the effectiveness of Copper Dressings as a primary therapy for VLUs. Their dual antimicrobial and pro-healing activity suggests a valuable treatment option for managing chronic venous ulcers.

EP148 Felting for diabetic foot ulcers (DFU): a rising trend

Susanne Kreuzer[1], Dirk Hochlenert[2]

[1]Luzerner Kantonsspital, Luzern, Switzerland, *[2]Praxis für Diabetologie, Endoskopie und Wundheilung, Köln, Germany*

Aim: Material and application of felted foam or felt ("felting") for offloading diabetic foot ulcers (DFU) are not standardized. Between 2012 and 2014, an interdisciplinary expert group developed a consensus-based standard according to ulcer location. This standard provides non-removable, effective offloading for immediate use and enables patients to remain mobile, in line with person-centred wound care. Felting is mentioned in the 2023 Guidelines of the International Working Group on the Diabetic Foot (IWGDF). We evaluated participation in certified felting courses to see whether its use has increased.

Method: We analysed the number of participants attending standardized felting courses before 2020 and from 2023 onwards. The periods 2014–2019 and 2023–2025 were compared using a two-sample t-test (RStudio 2025.09.2). The COVID-19 years 2020–2022 were excluded.

Results / Discussion: Since 2014, 1,763 individuals have been trained in Germany, Switzerland, Austria and the Netherlands. From 2014 to 2019, a mean of 74.5 participants per year (SD 37.5) attended, compared with 371 per year (SD 64.5) from 2023 to 2025, corresponding to a highly significant difference ($p = 0.0073$) and a 335% increase. In a subgroup of 772 participants, profession was documented: 177 were physicians and 313 wound care specialists.

Conclusion: Inclusion in international guidelines may encourage wound care professionals to learn this technique, resulting in a marked increase in participation. Felting appears to address an unmet need in DFU management. Standardization and certification of the technique, courses and instructors may ensure high quality and support the development of robust databases for systematic evaluation.

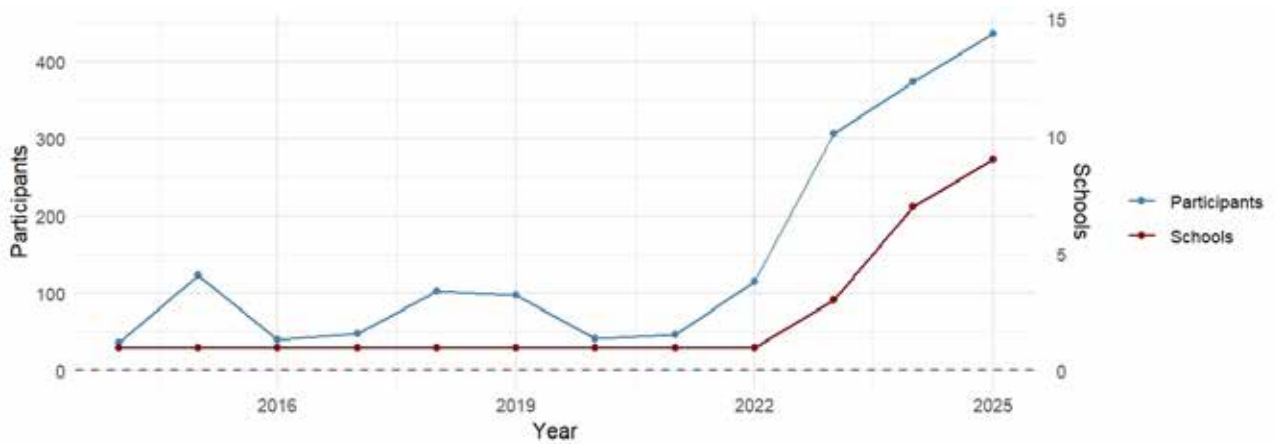

EP149 Advanced keratin-based wound dressings: Optimizing solution blow spinning for ecm-mimetic structures, enhanced healing, and hemocompatibility

Annalisa Aluigi[1], Barbara Canonico[1], Serena Benedetti[1], Mariele Montanari[1], Mattia Tiboni[1], Luca Casettari[1]

[1]Department of Biomolecular Science - University of Urbino, Urbino, Italy

Aim: The growing demand for advanced wound dressings has led to the exploration of new materials and techniques. Solution blow spinning (SBS) is a versatile, cost-effective method for producing micro- and nanofibrous dressings that mimic the extracellular matrix (ECM) and can be directly applied to wounds [doi.org/10.1002/jbm.b.35513]. Keratin, derived from wool, is an ideal material for wound healing due to its biodegradability, biocompatibility, good adhesion, and bioactivity [doi.org/10.1016/j.ijbiomac.2024.133722]. This study aimed to develop an SBS process for creating keratin-based patches with an ECM-like structure, optimizing parameters to enhance moisture retention and promote faster healing through improved cell adhesion and growth.

Method: A Design of Experiment (DoE) approach was used to optimize SBS process parameters, correlating them with filament diameters and adhesion properties on the wound site. Cytotoxicity and wound healing properties of the patches were evaluated using human HaCaT keratinocytes with a scratch test to assess monolayer repair. Hemocompatibility was also tested using fresh blood from healthy subjects within 4 hours of collection.

Results / Discussion: Keratin-based patches with interconnected, defect-free filaments (1–6 µm in diameter) and good adhesion were successfully produced. These patches significantly improved wound healing in HaCaT cells, showing increased monolayer repair after 24 hours. Erythrocyte aggregation and morphology changes over time were similar in both control and patch-treated samples, with no significant antigenic disturbances.

Conclusion: Keratin-based patches produced via the SBS process demonstrate excellent adhesion, cytocompatibility, and enhanced wound healing properties. This approach shows great promise for advanced, biocompatible wound care applications with no adverse effects on erythrocyte morphology or hemocompatibility.

EP150 Optimizing exudate management: Laboratory and clinical evaluation of new superabsorbent dressing

Klaus Zobel[1], Maurice Schmidt[2], Andrea Knobel[3], Joana Pinto[4], Marcus Philipp Moll[5], Niels Frank Jensen[4], Henrik Fallesen[4], Julie Hansen[4], Martin Vestergaard[4]

[1]Fachgesellschaft Stoma, Kontinenz und Wunde, Bielefeld, Germany, *[2]Vascular Center Dr. D. Predel, Nordhausen, Germany*, *[3]Vascular Center Dr. med G. Alvarez & Wydra, Hann. Münden, Germany*, *[4]Coloplast A/S, Humlebæk, Denmark*, *[5]Coloplast GmbH, Hamburg, Germany*

Aim: Effective management of exudate is critical for wound healing and prevention of complications such as maceration and infection. Superabsorbent wound dressings (SWDs) are designed to absorb and retain large volumes of exudate, but performance varies between products.

The aim is to evaluate the *in vitro* absorptive and retention capacities of a new non-adhesive SWD* (Superabsorber) compared to four market-leading SWDs, assess its ability to reduce matrix metalloproteinase (MMP) activity and retain bacteria, and explore its clinical application in three case reports.

Method: *In vitro* tests included free swell absorption, absorption and retention under compression (40 mmHg) were assessed according to EN-13726:2023, and MMP-2/MMP-9 activity reduction after 4-hour incubation. Bacterial retention was assessed for *Staphylococcus aureus* and *Pseudomonas aeruginosa*. Clinical performance was evaluated in three patients with moderately to highly exuding wounds.

Results / Discussion: The SWD* demonstrated significantly higher free swell absorption (2.08 g/cm^2), retention under compression (1.56 g/cm^2), and absorption under compression (1.37 g/cm^2) compared to comparators (p<0.001). MMP-2 and MMP-9 activity were reduced by 98% and 80%, respectively. Bacterial retention exceeded 97% for both species. Case reports indicated effective exudate management, reduced maceration, extended wear time, and improved patient comfort.

Conclusion: The SWD* showed superior *in vitro* performance and clinical benefits in managing moderate-to-high exudate, supporting its role in promoting wound healing, and reducing dressing change frequency. Further clinical studies are warranted.

Keywords: Exudate management, superabsorbent wound dressings, Biatain Superabsorber, MMP modulation, bacterial retention

*Biatain Superabsorber

EP151 Safety and efficacy of hydrogel EHO-85 in pediatric wound healing: an open-label pilot study

Pablo García-Molina[1 2], Evelin Balaguer-López[1 2], Laura Plá Marzo[1], Mireia Cazalilla-Pérez[2], Maria Carmen Rodriguez[1 2], Pedro García-Martínez[1], Beatriz Guzman Morais[2], Maribel Lázaro[2]

[1]Nursing departament. University of Valencia, Hospital Clínico Universitario de Valencia, Upppediatria, Valencia, Spain, [2]Hospital Clínico Universitario de Valencia, Valencia, Spain

Aim: To assess the safety and efficacy of hydrogel EHO-85, which contains olive leaf extract, in pediatric wound healing.

Method: This prospective, open-label, single-center pilot study enrolled pediatric patients aged 1 month–to 18 years) with wounds of various etiologies. The hydrogel was applied topically three times per week for up to 4 weeks or until complete closure. The primary endpoint was safety, evaluated through the recording of adverse events, serious adverse events, and suspected unexpected serious adverse reactions (SUSARs). Secondary endpoints included efficacy outcomes as the percentage reduction in wound area, the number of lesions achieving complete healing, the occurrence of local infection, and changes in pain intensity. Wound area was measured using HELCOS software. Changes between baseline and the last visit were assessed with non-parametric Wilcoxon signed-rank test.

Results / Discussion: 15 pediatric patients were included in the study. All enrolled patients completed the study, with no reported adverse events or withdrawals. No infections occurred during follow-up. Complete healing was achieved in 93.3% of patients, with a median healing time of 14 days. Wound area reduction reached 100% in 14 of the 15 patients ($p < 0.001$). Granulation tissue proportion and re-epithelialization increased significantly ($p = 0.0138$ and $p = 0.00379$, respectively). Pain scores decreased to 0 in 14 of the 15 patients, and RESVECH 2.0 scores dropped from a median of 11 to a median of 0 ($p = 0.00109$).

Conclusion: Hydrogel EHO-85 demonstrated an excellent safety profile and substantial efficacy in pediatric wound care, promoting rapid healing, effective tissue regeneration, and marked pain reduction. These findings support the need for further evaluation in larger, controlled studies to confirm these preliminary results.

EP152 Analysis of the use of extracellular matrix derived from sheep stomach in the healing time of complex wounds

Lys Santos[1], Patrícia Pereira[1], Juliana Lucinda dos Santos[1], Fernanda Machado[1], Giliane Carvalho[1], Hanna Dodde[1]

[1]Aliança Médica Vascular, Rio De Janeiro, Brazil

Aim: Our objective is to demonstrate the applicability and efficacy of using an extracellular matrix graft derived from ovine forestomach matrix (OFM), in the treatment of complex injuries in the lower limbs. We observed that this matrix not only acted as a scaffold for cellular and vascular recruitment, but also significantly reduced healing time.

Method: A retrospective analysis identified twenty patients of both sexes and different ages, with complex lesions that were managed with OFM. All lesions were vasculogenic and located on the lower limbs. They were initially surgically treated, according to their diagnosis (angioplasty, debridement, autologous stem cell micrograft…) And there was also another minimally invasive procedure as ultrasound guided foam.

After treatment of the underlying pathology was established and the wound bed was properly prepared (adequate granulation tissue, exudate control, and no infection), we began OFM to support closure and monitored the changes weekly.

Results / Discussion: This matrix derived from sheep stomach is a scaffold rich in collagen, elastin, fibronectin, laminin and glycosaminoglycans. When hydrated, it transforms into a soft, easily applied and adaptable sheet that naturally incorporates into the wound.

During follow-up, we observed that, regardless of previous procedures and comorbidities, the use of the matrix demonstrated a significant acceleration in the healing process. Furthermore, patients reported no pain during wound management and showed good acceptance and cooperation during dressing changes.

Conclusion: We conclude that when faced with complex wounds, the use of a scaffold becomes essential for optimizing healing outcomes. OFM was able to create an environment conducive to cell migration, which promoted dermal regeneration more effectively and faster than would occur without its use in the wound bed.

EP153 Moist exposed burn therapy with moisture burn ointment for chronic refractory wounds in Chinese patients: A meta-analysis of healing rate and effectiveness

Shuangna Xin[1]

[1]*Wound and Stoma Management Center,The Second Hospital of Dalian Medical University, Dalian, China*

Aim: To systematically evaluate the efficacy and safety of Moisture Burn Ointment for treating chronic refractory wounds in Chinese patients.

Method: CBM, Wanfang Database, CNKI, Cochrane Library, and PubMed database were searched by computer for randomized controlled trials of moist exposed burn therapy (MEBT) /moisture burn ointment (MBO) in treating chronic refractory wounds. The search years were from January 2012 to November 2025. The literature was screened, the data were extracted, the Cochrane Scoring Manual assessed the quality of included literature, and the RevMan 5.3 software was used for Meta-analysis.

Results/Discussion: A total of 14 randomized controlled trials (RCTs) involving 1,228 patients were included. The experimental group received MEBT/MBO combined with conventional treatment, while the control group received conventional treatment only. Meta-analysis results showed that the wound healing rate of the experimental group was higher than that of the control group, and the effective rate of the experimental group was higher than that of the control group. The mean wound healing time in the experimental group was shorter than that in the control group, and the time of granulation tissue appeared in the experimental group was earlier than that in the control group. None of the studies reported adverse reactions and complications.

Conclusion: The collective evidence from this study indicates that MEBT/MBO has established favorable efficacy and a high safety margin for Chinese individuals suffering from chronic refractory wounds. However, due to the limitations of the quality and quantity of the included literature, the conclusion still needs to be further verified by more high-quality RCTs.

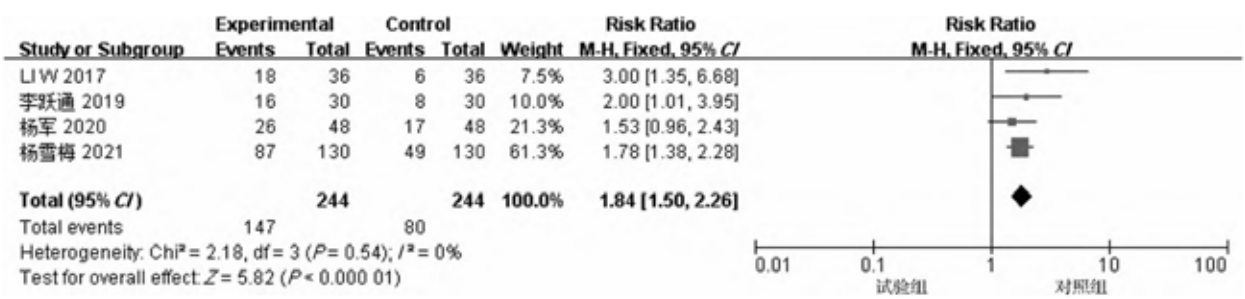

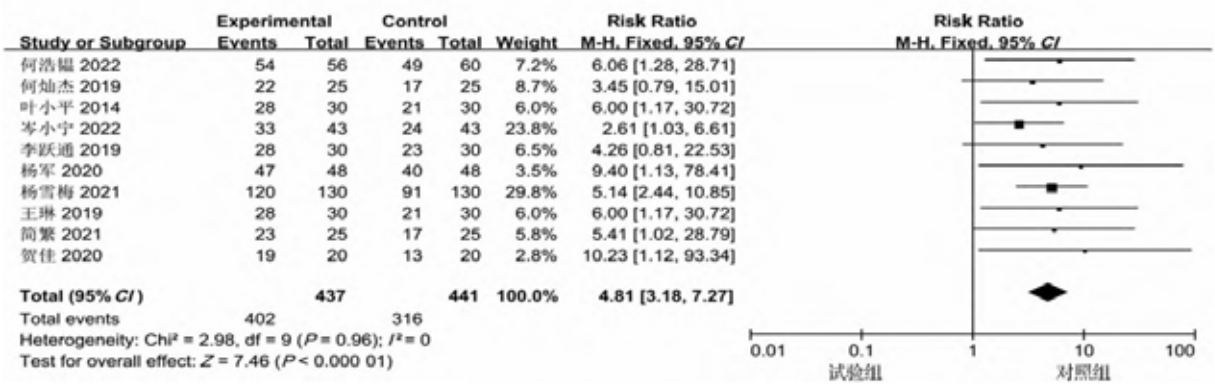

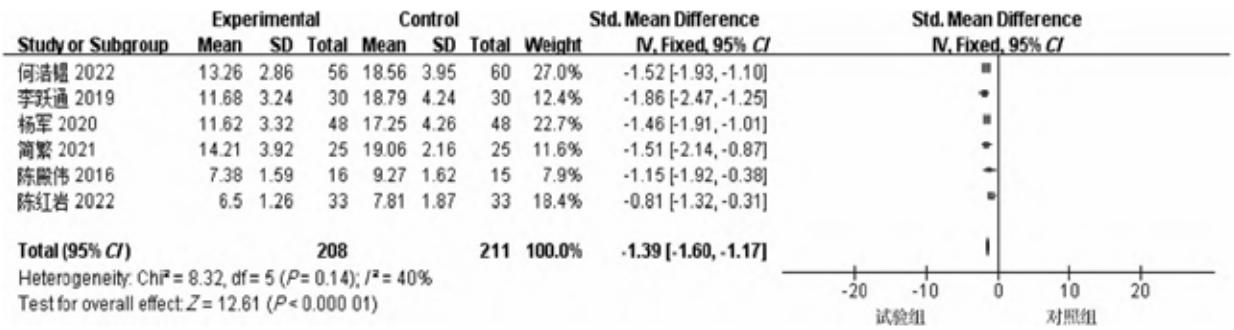

EP423 Dialkyl carbamoyl chloride-coated dressing in infection control of culture-positive venous and chronic wounds: Preliminary data from a 17-patient cohort

Gaye Filinte[1], Rıdvan Erden[2], Müge Sert[2]

[1]Kartal Dr. Lütfi Kırdar City Hospital, University of Health Sciences, Istanbul, Türkiye, [2]Kartal Dr. Lütfi Kırdar City Hospital, Istanbul, Türkiye

Aim: This study aimed to evaluate the effect of a dialkyl carbamoyl chloride-coated wound dressing on infection clearance, inflammatory response (CRP trend), and hospitalization duration in patients with culture-positive venous and chronic wounds, alongside antibiogram-matched systemic antibiotics.

Method: A retrospective single-center cohort study included 17 hospitalized patients with infected, moderately-to-high exudative, culture-positive wounds. The mean age was 61.4 years (12 males, 5 females). Primary wound etiology was venous ulcer in 14 patients (82.3%); the remaining 3 had chronic or traumatic/surgical wounds. Four patients had diabetes, 13 did not. Documented pathogens included Pseudomonas aeruginosa, Acinetobacter baumannii, and Klebsiella pneumoniae. The dressing was applied and changed every 24–72 hours based on exudate. Primary outcomes were infection clearance, culture conversion, antibiotic de-escalation timing, and hospitalization duration.

Results / Discussion: Of the 17 patients, 14 (82.3%) achieved culture-negative conversion. CRP levels showed an early and sustained decline. Documented local signs (purulence, erythema, odor) improved rapidly, with most patients experiencing odor reduction within the first week. The mean hospitalization duration was 41 days. Earlier antibiotic de-escalation was documented in culture-negative patients. Results were consistent in the venous ulcer subgroup, regardless of diabetes status.

Conclusion: The dialkyl carbamoyl chloride–coated dressing was associated with improved infection control, reduced inflammatory markers, earlier antibiotic de-escalation, and shorter hospitalization in this cohort. Further studies are needed to validate these findings.



EP154 Prolonged resting in place of Dermal Substitutes using a silicon porous dressing in comparison with traditional moist gauzes treatments

Roberto Cassino[1], Stefania Chiarenza[1], Francesca Mistò[1], Simone Toscano[1], Monica Pittarello[2], Elia Ricci[2]

[1]"Zucchi" Clinical Institutes, Vulnology Center, Monza, Italy, *[2]Policlinico di Monza, "Santa Rita" Clinic, Vercelli, Italy*

Aim: Dermal Substitutes applied to leg ulcers are generally not sutured to the wound edges, but are secured with dressings, usually moist gauzes, and bandages. The aim of this study is to demonstrate that a porous silicon dressing can significantly extend the dressing's stay-in-place time and prevent premature detachment.

Method: We enrolled 50 patients with lower limb ulcers surgically treated with dermal substitute, divided into two groups of 25 each: Group MG, medicated with moist gauze and "High Stiffness" bandage, and Group PS, medicated with porous silicon* dressing and the same bandage. Bandage renewal and dressing check/change twice a week.

End of the study: 4 weeks or healing or displacement/detachment of the dermal substitute or worsening/adverse event. Time the grafted tissue remained in place and state of the lesion were evaluated.

Results / Discussion: All PS Group patients kept the dressing in place until study end; 6 patients (24%) healed before 4 weeks; no displacement/detachment of the dermal substitute, no adverse events; mean weartime 18.9 days (min.10-max.35 days). All patients in the MG Group had to renew dressing before study end; displacement/detachment of dermal substitute before 4 weeks in 14 (56%); one healing (4%) within the fourth week; mean weartime 8.3 days (mini.4-max.14 days); perilesional skin maceration in 3 patients (12%).

Conclusion: Data demonstrate that porous silicone dressing stays in place longer than moist gauze and performs significantly better. Wound status results are also excellent. Despite its high cost, the silicone dressing offers advantageous cost-benefit ratio due to extended weartime.

*Touchmed® Silicone (DEALFA, Italy)

EP155 Collaborative regional foot care networks reduce major amputations but not treatment duration

Dirk Hochlenert[1]

[1]*Ambulantes Zentrum für Diabetologie, Endoskopie und Wundheilung, Köln, Germany*

Aim: Starting in 2005, 84 certified foot clinics and outpatient facilities, together with cooperating podiatrists, orthopaedic shoemakers and community nurses in three federal states, were organised into seven regional networks. These participants signed specific contracts with health insurance providers. Targeted additional funding, strict transparency procedures and comprehensive education for all involved health professionals were used to strengthen shared care. The four primary goals were to lower mortality, reduce above-ankle amputations, reduce treatment durations exceeding 6 months, and prevent new ulcers within the year after wound closure. A mandatory second opinion was required before any major amputation.

Method: Key clinical characteristics of all participating patients were recorded on site using a dedicated documentation program. Data quality was reviewed annually during intercollegiate visits. Clinical data were collected every 3 months and results were regularly fed back to all members of each regional network.

Results / Discussion: Between 2005 and 2021, 60,908 patients received treatment in these networks. Over time, patients presented with earlier stages of disease, reflected by a fall in bone involvement from 21% in 2006 to 10% in 2021. Major amputation rates declined from 2.8% to 0.5%, and minor amputations from 8.7% to 5.3%. After 6 months, about 70% of patients were alive and ulcer-free, while 6–9% died before wound closure, with a downward trend in mortality during the last decade. The incidence of new ulcers within one year after wound healing decreased from 35% to 30%.

Conclusion: Care within collaborative networks is linked to a sustained reduction in major amputations to 0.5%, likely supported by earlier presentation without bone involvement. However, overall treatment duration has not improved despite focussed measures.

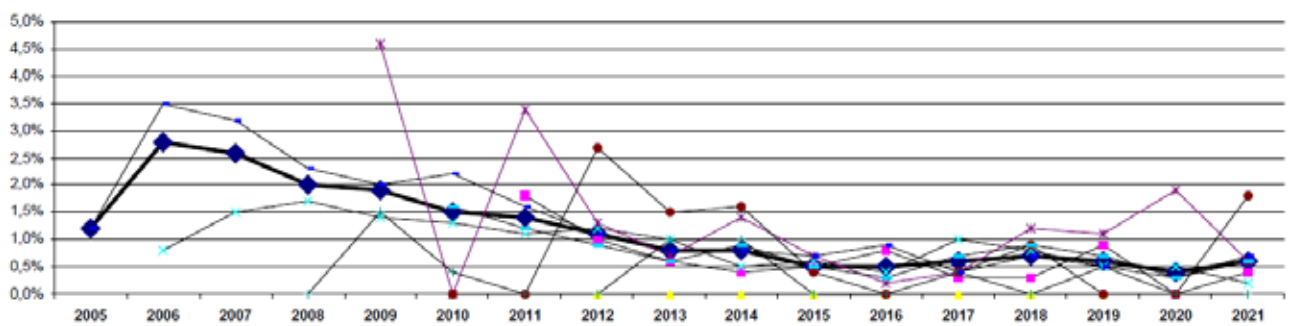

Fig.1

EP156 Is this a dressing? Form-stability variability via rheology in tube-dispensed wound care products

Amit Gefen[1 2 3], Daphne Weihs[2 3 4], Astrid Fremau[5], Youtha Van den Eynde[6], Sarah De Backer[6]

[1]School of Biomedical Engineering, Faculty of Engineering, Tel Aviv University, Tel Aviv, Israel, *[2]Skin Integrity Research Group (SKINT), Department of Public Health and Primary Care, Ghent University, Ghent, Belgium*, *[3]Department of Mathematics and Statistics and the Data Science Institute, Faculty of Sciences, Hasselt University, Hasselt, Belgium*, *[4]Faculty of Biomedical Engineering, Technion-Israel Institute of Technology, Haifa, Israel*, *[5]Medical Department, Flen Health, Kontich, Belgium*, *[6]Research and Development Department, Flen Health, Kontich, Belgium*

Aim: Classification of wound care products as form-stable dressings remains inconsistent, especially for tube-dispensed products. Regulatory decisions often rely on packaging or precedent rather than measurable material properties. This study applied an established rheological framework to compare the form stability of market-dominant, tube-dispensed wound care products across key formulation categories and to assess implications for product classification and clinical application.

Method: Dynamic, oscillatory shear rheology was used to quantify material moduli and phase shift angles across a broad range of tube-dispensed wound care products. Products (2-3 from various manufacturers) represented alginate-based gels, carboxymethyl cellulose hydrogels, other polymeric gels, silver-containing formulations, and honey- and petrolatum-based products. Form stability was determined via the phase shift angle, where values below 45° indicate solid-like responses and those below 30° represent form-stable materials.

Results / Discussion: Phase angles varied widely across categories and products, demonstrating that tube-dispensed products cannot be reliably classified by packaging format. Alginate-based (n=3) formulations consistently exhibited low phase angles, ranging 10-24°, indicating that they maintain form stability when subjected to mechanical loading. Three of 6 evaluated carboxymethyl cellulose and polymeric materials exhibited solid-like characteristics with phase angles <30°, while 3 others were clearly liquid-like, ranging 50-54°. Similarly, 2 silver-containing formulations demonstrated low phase angles (<30°) while the other was nearly liquid-like with 44°. Honey- and petrolatum-based products (n=5) typically exhibited high phase angles (ranging 50-72°), indicating liquid-like responses and lacking form stability; one sample with <50% honey exhibited lower (25°) phase angle. This variability across and within categories and products highlights the need for measurable materials science-based criteria as a classifier.

Conclusion: The pronounced variability in form stability among tube-dispensed wound care products shows that packaging does not reliably indicate form stability and clinical functionality. A material-science-based framework incorporating material properties, particularly the phase angle, can objectively and quantitatively differentiate between products even within same category, support more consistent regulatory classification, guide clinical product selection, and improve clarity in reimbursement processes.

EP157 Performance of dressings with charged polyabsorbent fibers in the local treatment of 377 patients with cutaneous exuding wounds – A multicenter, prospective, real-life study

Dr. Tino Breitfeld[1], Christoph Schicker[2], Sebastian Nilewski[3], Elisa Häuser[3], Winfried Keuthage[4], Arthur Grünerbel[5]

[1]Harzklinikum, Klinikum Wernigerode, Wound Competence Center, Wernigerode, Germany, *[2]Ärztezentrum, Bad König, Germany*, *[3]URGO GmbH, Department of Medical Affairs and Clinical Research, Sulzbach, Germany*, *[4]Schwerpunktpraxis Diabetes & Ernährungsmedizin, Münster, Germany*, *[5]Diabetes Center Munich South, Munich, Germany*

Aim: To evaluate the performance of dressings with charged polyabsorbent fibers in the local treatment of exuding cutaneous wounds, under real-life conditions.

Methods: A prospective observational clinical study was conducted in Germany (May - October 2025). The wounds were treated with the dressings for a maximum of three follow-up visits or eight weeks. Main endpoints included changes in wound healing progression and wound's characteristics, acceptability and tolerance of the dressings.

Results: In total, 377 patients (aged 3-98 years) were treated for a mean period of 33±21 days. Acute wounds (n=181) mostly included post-surgical wounds and skin abrasions, and chronic wounds (n=196) mostly leg ulcers, diabetic foot ulcers and pressure ulcers. By the final visit, 85.7% of wounds healed or improved, 1.3% remained unchanged and 3.7% worsened (9.3% were missing). At baseline, 232 wounds were at the debridement stage. Dressings were changed on average 3 times a week, mechanical debridement performed once a week and surgical debridement every other week. Effective wound debridement, resulting in ≥ 70% of granulation tissue, was observed in 78.0% of these wounds after a median period of 14 days (interquartile range: 9–28 days). The dressings were rated as very well tolerated and accepted by most patients (79.3% and 75.6%, respectively), and judged as useful or extremely useful by most physicians (89.7%).

Conclusions: These results are consistent with the previous clinical evidence on these dressings with charged polyabsorbent fibres and further support their good efficacy in continuous debridement of slough and promoting wound healing, tolerability, acceptance and usefulness in the treatment of patients with exuding wounds regardless of wound type.

EP158 Early healing outcomes with an SiO2-Aerosil-powder for diabetic foot ulcers: A pilot single-arm study

Noelle Moser- van der Geest[1], Joana Berger-Estilita[2], Yi Zhang[3]

[1]Cutempa Medical AG, Basel, Switzerland, *[2]Hirslanden, Bern, Switzerland*, *[3]Henan Provincial People's Hospital, Zhengzhou, China*

Aim: Diabetic foot ulcers (DFU) remain difficult to treat, with about one third healing within 12 weeks under standard care (SoC). We evaluated early healing, patient-reported outcomes and safety in patients treated with SiO2-Aerosil-powder1 plus SoC.

Method: We analysed a single-centre, single-arm pilot cohort of 20 DFU-patients treated with SiO2-Aerosil-powder1 plus SoC. Baseline data included age, sex, BMI, HbA1c, ankle–brachial index (ABI) and wound size. Primary outcomes were (i) complete healing (100% epithelisation without drainage, confirmed after 14 days) within 12 weeks and (ii) time to closure. Secondary outcomes included Diabetic Foot Ulcer Scale - Short Form (DFS-SF) scores and adverse events. Continuous variables were summarised as mean ± SD and median (IQR), and categorical variables as counts and percentages. Comparisons used t-tests and Fisher's exact tests. Time-to-event data were described with Kaplan-Meier curves.

Results / Discussion: Of 20 patients, 13 (65%) were male; mean (SD) age and BMI were 60.9 (9.7) yr and 24.1 (3.0) $kg \cdot m^{-2}$. Mean baseline wound area was 8.9 (7.3) cm^2. Eleven patients (55%) achieved documented healing, all within 12 weeks and median [IQR] healing time was 14 [7.5–18] days (6–29), compared with published SoC healing rates of 33–35% at 12–24 weeks and healing time around 50 days2,3. Clinic visits were modest, many healed before all scheduled assessments. DFS-SF scores tended to improve, but changes were not statistically significant given sample size. No adverse events occurred.

Conclusion: In this small pilot cohort, over half of DFU healed within 12 weeks and short closure time relative to benchmarks. Although limited by sample size and absence of a control group, these exploratory findings inform future study design.

EP159 Modulating and sampling diabetic foot ulcer infections with ceramic wound dressings

Sana Shah[1], Jason Ashworth[1]

[1]*Manchester Metropolitan University, Manchester, United Kingdom*

Aim: Ceramic wound dressings provide a novel alternative to traditional medicated dressings for wound infection management. Ceramic dressings are reported to immobilise and remove bacteria from the wound, whilst lacking disadvantages (poor drug delivery/uptake, antimicrobial resistance) associated with medicated dressings.

The aims of this study were to investigate ceramic dressings as potential wound microbiome sampling devices and evaluate their biofilm removal capability in the context of diabetic foot ulcer (DFU) infections.

Method: Ceramic dressings were applied to multi-species biofilms in *ex vivo* models of DFU infections for 24 or 48 hours using clinical isolates from DFU patients with mild, moderate or severe infections. Bacterial recovery counts (n=9) were determined from spent dressings and equivalent biofilm sampling with M40 swabs. Residual biofilm counts (n=9), alongside imaging of spent dressings by scanning electron microscopy (SEM) and confocal microscopy, were used to assess biofilm removal. Spent dressings and swabs from infected DFU patients were processed for 16S sequencing of wound microbiomes.

Results / Discussion: There was significant ($P<0.05$) biofilm removal in DFU infection models following application of dressings for 24 hours (mild/moderate>70%; severe>60%) or 48 hours (mild/moderate>80%; severe>75%). Bacterial recovery and SEM/confocal assessments confirmed predominant bacterial sequestration by ceramic spheres, with substantially higher (9.4 to 51.9%) biofilm sampling efficiencies achieved from dressings than swabs (4.2 to 13.4%).

Microbiome analysis indicated narrower species diversity in DFU patients with severe infections compared to those with mild/moderate infections. Compared with corresponding swab sampling at the same wound site, dressings consistently demonstrated greater ($P<0.05$) bacterial abundance (dressing:swab=14.2) and diversity (dressing:swab=2.8).

Conclusion: Ceramic wound dressings were highly effective at DFU-associated biofilm reduction and might be a preferential sampling device for DFU microbiome investigations.

EP160 Continuous debridement with charged polyabsorbent fibre dressings real-life - Results from a multicenter, prospective, clinical study IN 1558 patients with cutaneous exuding wounds

Finja Jockenhöfer[1], Michael Dietlein[2], Arthur Grünerbel[3], Prof. Dr. Markus Stücker[4], Elisa Häuser[5], Udo Möller[5], Laetitia Thomassin[6], Prof. Dr. Joachim Dissemond[1]

[1]*University Hospital Essen, Essen, Germany*, [2]*Diabetology Practice,, Stadtbergen, Germany*, [3]*Diabetes Center Munich South, Munich, Germany*, [4]*Hospital of Ruhr-University Bochum, St. Maria-Hilf Hospital, Venenzentrum, Bochum, Germany*, [5]*URGO GmbH, Department of Medical Affairs and Clinical Research, Sulzbach, Germany*, [6]*Urgo Medical, Paris, France*

Aim: To evaluate the performance of two charged polyabsorbent fibre dressings (a pad impregnated with technology lipido-colloid healing matrix and a rope) in an unselected cohort of patients with wounds, in daily practice.

Method: A prospective, multicentre, real-life study was conducted in 152 centres across Germany. Wounds were treated with the evaluated dressings for six weeks. Main outcomes included changes in: wound healing, wound bed tissues, infection status, malodour, maceration and pain, as well as acceptability and tolerance of the dressings.

Results: A total of 1558 patients (aged 3–100 years) were included: 944 patients with chronic wounds (mostly venous leg ulcers, diabetic foot ulcers and pressure ulcers); and 614 with acute wounds (mostly surgical wounds, skin abrasions and burns). At the initial visit, mechanical debridement was performed in 27.2% of patients, surgical debridement in 22.5%. By the final visit, 94.5% of wounds had improved or healed (58.2% of acute wounds and 27.8% of chronic wounds healed within 33±15 days). Sloughy tissue continuously reduced between initial and final

visits (from 60% to 10%, median values), regardless of wound type. This improvement was associated with reductions in wound infection by 87.3%; malodour by 86.7%; maceration by 65.6%; and spontaneous pain by 60.4%. Both dressings were very well tolerated and accepted by most patients (85.3 and 76.1%), and judged extremely useful by 72.0% of physicians, notably in cases of infected wounds without antibiotic therapy.

Conclusion: The two dressings were shown to be efficient in continuously removing sloughy tissue and promoting wound healing, regardless of wound type. These results are consistent with previous clinical evidence and support their intended use.

EP161 Key performance characteristics of a new 5-layer silicone foam dressing in a randomized, controlled, prospective, human volunteer trial

Sophie Berry[1], Michael Howarth[2], Adam Tompkin[2], Yueming Shi[3]

[1]Smith+Nephew, Watford, United Kingdom, *[2]Smith+Nephew, Hull, United Kingdom*, *[3]Smith+Nephew, Andover, United States*

Aim: Assessment of foam dressing clinical performance using standardized laboratory tests has limitations. Volunteer studies are a robust method to assess dressing presence during wear[1,2]. This large volunteer trial evaluated a new, 5-layer foam dressing against two marketed 5-layer foam dressings for non-inferiority using stringent assessment criteria.

Method: A single-centre, open-label, prospective, randomized volunteer study evaluated three, 5-layer silicone foam dressings over 7 days. All dressings were applied to participants' thighs and shins (2 of Dressing 1* [n=240]; 1 each of marketed Dressings 2† and 3‡ [n=120 each]). The primary endpoint was Acceptable Dressing Presence (ADP; definition: dressing presence with no border lift, pad exposure, or tears) at day 7. Secondary endpoints included dressing presence, and participant reported pain on dressing removal. Newcombe's score method (15% non-inferiority threshold) was utilized.

Results / Discussion: For the Full Analysis Set (FAS; n=120), ADP (day 7) was 72.9%, 83.3% and 65.0%, and dressing presence (day 7) was 95.0%, 94.5% and 90.9%, for Dressings 1, 2 and 3, respectively. Post-hoc analysis (mixed logistic regression model) indicated that Dressing 1 had a significantly higher rate of ADP than Dressing 3 (p=0.03). At day 7, all participants reported either 'None' or 'Mild' pain upon dressing removal.

Conclusion: This new 5-layer foam dressing performed well in key performance characteristics of dressing presence and low participant reported pain scores. Application of stringent clinical performance criteria can highlight differences versus conventional endpoints.

References:

1. Waring M, et al. *Wounds UK*. 2011;7(3):14-24.
2. Rippon MG, et al. *Wounds UK*. 2015;11(1):45-54.

*ALLEVYN◊ COMPLETE CARE Foam Dressing (10x10cm; Smith+Nephew)

†ALLEVYN◊ LIFE Foam Dressing (12.9x12.9cm; Smith+Nephew)

‡Mepilex™ Border Flex dressing (10x10cm; Mölnlycke Healthcare

EP162 Effectiveness of silicone superabsorbent polymer dressings for chronic wound management: A prospective single-arm clinical study

Anitha Pitchika[1], Teresa Szenk[2], Agnieszka Segiet-Święcicka[2], Vladica Velickovic[1 3], David G. Armstrong[4], Prof. Dr. Sebastian Probst[5]

[1]Hartmann Group, Heidenheim, Germany, *[2]Clean Data Labs, Warsaw, Poland*, *[3]Institute of Public Health, Medical Decision Making and HTA, UMIT, Hall, i.T., Austria*, *[4]Keck School of Medicine of University of Southern California, California, United States*, *[5]HES-SO, Geneva, Switzerland*

Aim: This study evaluated the effectiveness of silicone superabsorbent polymer (SAP) dressings in patients with venous leg ulcers (VLU) and diabetic foot ulcers (DFU), with emphasis on wound area reduction and improvement in wound bed characteristics over a six-week observation period.

Method: This prospective, single-arm study enrolled patients with VLU and DFU across multiple clinical sites. Patients received either silicone or silicone border SAP dressings combined with compression therapy (VLU) or offloading boots (DFU). The primary endpoint was wound area reduction, while secondary endpoints included wound healing, changes in granulation tissue, slough tissue, and exudate amount and dressing wear time.

Results / Discussion: Of the 80 patients included in the analysis (65.0% VLU; 35.0% DFU), 66 (83.5%; 90% CI 75.1–90.0) achieved >20% wound area reduction by week 6 ($p<0.001$ for superiority against 22.5% and non-inferiority against 50.0% non-inferiority margin 7.56%). The median percentage wound area reduction was 69.6% (IQR 28.9–100%) following cleansing/debridement. Complete wound healing occurred in 21 patients (26.3%). At the final visit, median granulation tissue coverage decreased by 75.2% (IQR: 24.3–100%) and slough coverage decreased by 98.6% (IQR: 46.7–100%) after cleansing/debridement, while median exudate volume reduced by 0.38 ml (IQR: -0.1–1.75 ml) from baseline (all $p<0.001$). The decrease in granulation and slough tissue likely reflects wound closure, as it is replaced by new epithelial tissue during healing. Median dressing wear time was 4 days (IQR: 3–6 overall).

Conclusion: Improvements in wound area, wound bed quality, and exudate control were observed with the use of SAP dressings over six weeks in patients with VLU and DFU. SAP dressings may therefore offer a beneficial option for managing chronic wounds.

EP163 PLA matrices for managing wounds secondary to orthopedic procedure complications

Ana Lorena Novoa-Moreno[1], Mario Aurelio Martínez-Jimenez[2], Victor Loza-González[3], Eleazar Samuel Kolosovas-Machuca[4], Jose Ramirez-Garcialuna[5]

[1]Medicine Faculty of the Autonomous University of San Luis Potosí, San Luis Potosí, Mexico, *[2]Burn Unit of the High Specialty Regional Hospital "Ignacio Morones Prieto", San Luis Potosí, Mexico*, *[3]Institutional Doctorate of Engineering and Materials Science of the Autonomous University of San Luis Potosí, San Luis Potosi, Mexico*, *[4]Coordination for the Innovation and Application of Science and Technology (CIACYT), Autonomous University of San Luis Potosí, San Luis Potosí, Mexico*, *[5]Division of Experimental Surgery, Faculty of Medicine, McGill University, Montreal, QC, Canada*

Aim: To present clinical outcomes of polylactic acid (PLA) matrices used to guide healing in complex wounds secondary to complications of orthopedic procedures, including cases with exposure of avascular structures.

Methods: A case series of seven patients was reviewed, all presenting postoperative wound complications between 7 days and 1 month after orthopedic surgery. Gentle debridement was performed when indicated prior to matrix placement. PLA matrices were applied directly to the wound bed and reapplied weekly, with the number of total applications determined by each wound's clinical evolution. Further management - either continuation of secondary healing or subsequent surgical closure - was decided by the treating physician based on wound progression and characteristics.

Results: Matrix applications were performed weekly until adequate progression was observed. Three patients achieved complete closure with PLA alone, while four required additional surgical management—full-thickness skin

grafts or local flaps—once optimal granulation tissue had developed. The mean number of PLA applications was three (range: 2–4). Mean time to complete healing was 2.7 weeks (range: 2–4) for wounds later managed with grafts or flaps, and 6.6 weeks (range: 6–8) for wounds healed by secondary intention. During a six-month follow-up period, no complications were identified, including infection, recurrent breakdown, hypertrophic scarring, or contracture.

Conclusion: PLA matrices represent a reliable and efficient option for the management of complex postoperative wounds. Their ability to promote granulation over compromised structures and to support both temporizing strategies and complete secondary healing makes them a valuable component of reconstructive decision-making, potentially reducing the need for more invasive procedures in selected cases.

EP164 Multifunctional hemostatic fibers with integrated antiseptics for advanced wound care applications

Marian Sedlář[1 2], Lucy Vojtova[1], Tomáš Hřebíček[3], Radim Dvořák[2]

[1]Central European Institute of Technology, Brno University of Technology, Brno, Czech Republic, *[2]Hemcon Medical Technologies CZ s.r.o., Tišnov, Czech Republic*, *[3]nanoSPACE Technology s.r.o., Most, Czech Republic*

Aim: To explore the development of next-generation hemostatic fibrous materials incorporating a hemostatically active substance together with an antiseptic agent (octenidine dihydrochloride). The objective is to assess their potential to provide simultaneous bleeding control and antimicrobial protection, supporting their further consideration as components of advanced wound dressing systems.

Method: Fibrous samples containing a hemostatic active substance and octenidine dihydrochloride were prepared using hybrid submicron/nanofiber spinning technology. Hemostatic performance was evaluated through *in vitro* assays assessing interactions with blood components and coagulation activity, supplemented by *in vivo* studies in an animal model to observe biological response under complex conditions. Antimicrobial activity was examined using growth-inhibition tests against representative Gram-positive, Gram-negative, and yeast organisms to provide an initial indication of the antiseptic functionality of the incorporated agent.

Results / Discussion: Pilot *in vivo* testing in rat models supported the *in vitro* findings and demonstrated promising hemostatic performance that could be evaluated alongside commercially available products without indicating substantial deviation under the test conditions. Fibrous samples containing octenidine dihydrochloride also demonstrated measurable antimicrobial activity, showing growth inhibition across representative panels of Gram-positive and Gram-negative bacteria, as well as yeasts.

Conclusion: Fibrous materials incorporating a hemostatic active substance together with an antiseptic agent demonstrate meaningful potential for further development as advanced, multifunctional wound dressing candidates. The initial findings indicate that these materials can support rapid hemostatic response while providing localized antimicrobial activity, suggesting relevance for use in acute wound management and trauma care. These encouraging outcomes form a basis for continued refinement of the material system and for extended preclinical evaluation to further elucidate their performance and prospective suitability for clinical application.

EP165 A new non-antimicrobial dressing that prevents early biofilm formation under clinically realistic wound conditions

Graeme Brookes[1], Per Wirsén[1], Ana Romero[1], Serhiy Surkov[1], Linda Bergström[1], Elena Dhamo[1], Narmin Asadli[1], Ahsan Ali[1], Henrik Larsson[2], Jenny Rönningen[2], Hans Karlsson[2], Jan Andersson[3]

[1]CytaCoat AB, Solna, Sweden, *[2]Absorbest, Kisa, Sweden*, *[3]Karolinska Institutet, Solna, Sweden*

Aim: Biofilms produced by bacteria and fungi drive persistent inflammation and delayed healing, while antimicrobial resistance limits conventional treatment options. A next-generation superabsorbent dressing[1] functionalised with a permanently bonded, non-leaching polymer surface coating[2], was developed to modulate microbial behaviour at the

wound interface. This study evaluated biofilm formation on the coated dressing compared with commercially available uncoated and hydrophobic dressings under wound-mimicking conditions.

Method: Dressings were tested on simulated wound fluid (SWF) agar, a physiologically relevant medium that conditions dressings and reduces artefacts of antimicrobial and hydrophobic technologies. *Staphylococcus aureus*, *Pseudomonas aeruginosa*, and *Candida albicans* were assessed over 1-7 days using confocal microscopy. Due to inherent autofluorescence of the coated and hydrophobic substrates, extracellular polymeric substance (EPS) structures were interpreted qualitatively via morphology and spatial distribution. Colony-forming unit counts quantified cellular adhesion. Non-antimicrobial behaviour was verified using Zone of Inhibition assays, EN17854:2024 antimicrobial efficacy, and chromogenic endotoxin assays, confirming absence of killing, stress responses, or increased endotoxin release relative to controls.

Results / Discussion: The coated surface permitted microbial contact yet consistently prevented transition into structured EPS-rich networks, in contrast to the dense, mature biofilms observed on uncoated and hydrophobic dressings. This phenotype-modulating effect persisted up to 7 days in SWF, demonstrating robust inhibition of early biofilm development under clinically realistic conditions despite similar levels of initial microbial adhesion.

Conclusion: The coated dressing represents a next-generation non-antimicrobial approach that interrupts early biofilm development while preserving absorbency. By preventing biofilm maturation without leaching or killing, it offers a novel strategy for infection prevention and supports antimicrobial stewardship in wound management.

Absorbest BioShield™ dressing (Absorbest AB, Kisa, Sweden)

[2] CytaCoat polymer surface coating (CytaCoat AB, Solna, Sweden)

EP166 Management of chronic skin lesions with non-vital wound bed through the use of oxygen-enriched oleic matrix technology in patients with comorbidity

Sara Sandroni[1], Stefania Fabrizi[1], Elisa Marinelli[1], Angela Peghetti[2], Vianella Agostinelli[1]

[1]Azienda USL Toscana sudest, Arezzo, Italy, *[2]IRCCS Azienda Ospedaliera Universitaria Bologna, Bologna, Italy*

Aim: In the treatment of skin lesions, the debridement method is a fundamental component of the management of the treatment phases and of all dressing activities. The use of new dressing technologies, can facilitate the wound bed management process.

Method: 42 patients with chronic skin lesions (varying etiology). The BWAT values for the tissue type ranged between 3 and 4 (i.e. slightly adherent yellow slough and black, soft adhering eschar), and the amount of necrotic tissue ranged between 4 and 5 (from 50% to 100%). An oxygen-enriched oleic matrix impregnated bandage has been applied in a multi-overlapping layout, with a dressing change time not higher than 48 hours. Also, the value of pain reported on a VAS scale and the patient feedback assessed through a 1-to-5 Likert scale. The device was used in 15-day cycles with 7-day interruption between each cycle.

Results / Discussion: After 60 days of observation, the device allowed to obtain an improvement on 100% of the treated lesions, with an observed significant reduction of the BWAT scale values. A reduction was observed in the VAS score for pain.

Conclusion: It is necessary to increase the knowledge of new technologically advanced dressing devices to improve some types of care intervention.

1. Murphy C, Atkin L, Swanson T, Tachi M, Tan YK, Vega de Ceniga M, Weir D, Wolcott R. International consensus document. Defying hard-to-heal wounds with an early antibiofilm intervention strategy: Wound hygiene. J Wound Care 2020; 29(Suppl 3b):S1–28.

2. Raccomandazioni di implementazione del Wound Hygiene nel contesto italiano: l'approccio ai pazienti con lesioni venose degli arti inferiori - Roma, dicembre 2023.

EP167 Can a multilayer polyester dressing provide negative pressure wound therapy comparable effectiveness in the management of highly exudative, hard to heal wounds?

Egesu İç[1], Hüseyin Garip[2], cemile sazak[3], Hakan Uncu[3]

[1]Ankara University, Ankara, Türkiye, *[2]Department of Peripheral Vascular Surgery, Ankara, Türkiye*, *[3]Ankara University Faculty of Medicine, Ankara, Türkiye*

Aim: Managing highly exudative and hard-to-heal wounds remains a major clinical challenge in modern wound care. Several advanced wound technologies have been developed to support tissue repair. One such product is a 3-layer polyester/polyester-cotton dressing that facilitates fluid drainage through capillary action, functioning as a low-level mechanical "pump" (Deeth & Pain, 2001). Although its mechanism does not fully replicate Negative Pressure Wound Therapy (NPWT), it generates an autologous negative pressure effect of approximately 68 mmHg. This study aims to report the clinical outcomes of this dressing in highly exudative and difficult-to-heal wounds, focusing on wound size reduction, exudate control, and patient comfort.

Method: A total of 12 patients who presented to our wound care center with wounds unresponsive to conventional treatments were included. The mean age was 67.4 years, and the mean BMI was 26.2. Etiologies included diabetic foot ulcers, venous ulcers, pressure injuries, and postoperative wound complications. All patients underwent surgical debridement prior to dressing application. The dressing was changed twice weekly, consistent with protocols described in the literature (Janssen et al., 2021).

Results / Discussion: Complete healing was achieved in five patients, while others demonstrated marked granulation and epithelialization. The mean reduction in wound size was 66.4% ± 29.9% (median 62.7%; IQR 46.3-100). Initial wound areas averaged 24.63 cm^2, with substantial decreases following treatment. These findings align with published healing times of 45–87 days. No complications occurred.

Conclusion: By removing excess exudate and improving the wound microenvironment, this capillary-action dressing may offer an effective, lower-cost, and more patient-friendly alternative to NPWT, particularly for moderate-sized, heavily exudative wounds. Larger comparative studies are still needed (Sanz et al., 2025).

EP168 Silk fibroin fibers as a bacterial binding component in wound dressing contact layer: a comparison to a DACC dressing

Anna-Liisa Kubo[1], Denys Bondar[2], Anita Dapon[1], Sten Miller[1], Natalja Savest[3], Jekaterina Krishtal[1], Grigory Vasiliev[1], Andres Valkna[1], Meelis Kadaja[1], Olesja Bondarenko[1]

[1]Nanordica Medical, Tallinn, Estonia, *[2]Tallinn University of Technology, Department of Chemistry and Biotechnology, Tallinn, Estonia*, *[3]Tallinn University of Technology, Laboratory of Biopolymer Technology, Tallinn, Estonia*

Aim: The aim is to study the binding properties of silk fibroin to bacteria.

Method: Wound dressings with silk fibroin nanofibrous scaffold were tested for viability with *Escherichia coli* bacteria on Resazurin reduction assay to measure the quantity of live bacteria bound to nanofibrous mesh after 1 hour of incubation. The bound bacteria were visualized via scanning electron microscopy.

Results / Discussion: We hypothesised that due to the hydrophobic nature of silk fibroin it might bind bacteria. The study was conducted on *in vitro* wound model.

DACC (Dialkylcarbamoyl chloride) dressing, silk dressings without and with Ag/Cu (Premotiv) and non-functionalized material (0-control) were tested in the study. The results showed that silk dressing entrapped about 55% of live bacteria, DACC dressing about 47%, Ag/Cu dressing 34% and 0-control 31% of live bacteria, respectively. Scanning electron microscopy showed that bacteria bound by Ag/Cu (Premotiv) silk dressing were inactivated, suggesting the bacterial binding was even higher for Ag/Cu silk dressing but live bacteria were efficiently inactivated inside the Ag/Cu silk layer.

Conclusion: Results showed that silk fibres were more efficient in binding bacteria than DACC. When silk fibres were combined with Ag/Cu collectively known as Premotiv nanotechnology, the counts of live bacteria bound to the dressing decreased, since most of the bacteria were inactivated inside the dressing. Our observation is supported by the bactericidal properties of Ag and Cu in silk fibres, because this innovative technology represents a promising means to inactivate bacteria and treating infected wounds.

EP424 A novel pioneering antibiofilm multifunctional molecular complex (MMC) and its synergistical effect with non-metal antimicrobials and surfactants

Rui Chen[1], Rebecca Catton[1], Jeanne Saint Bezard[1], Mia Hanrahan[1], Marcus Swann[1], Fergus Watson[1], Steven Percival[1]

[1]5D Health Protection Group Ltd., Liverpool, United Kingdom

Aim: Metal-based antimicrobials exhibit broad-spectrum, sustained activity through multi-target mechanisms, retaining efficacy against resistant strains. However, their slower onset, potential systemic toxicity, and sub-therapeutic bioavailability present limitations. In contrast, non-metallic agents demonstrate rapid, target-specific action but are characterized by reduced stability, heightened resistance development, and pronounced susceptibility to biological inactivation. This investigation reports the synthesis of a proprietary multifunctional molecular complex (MMC) and examines its synergistic antibacterial interactions with non-metallic additives across diverse experimental models.

Method: The minimum inhibitory concentration (MIC) of the MMC was determined against Staphylococcus aureus ATCC 29213 and Pseudomonas aeruginosa ATCC 15442, both with and without additives at subtherapeutic levels (0.25× MIC) of antimicrobials including hydrogen peroxide and PHMB. A checkerboard assay was conducted to evaluate potential synergy between MMC and polyhexanide (PHMB) against S. aureus ATCC 6538 and P. aeruginosa ATCC 15442. Additionally, kill-rate studies were performed for MMC combined with PHMB against P. aeruginosa ATCC 15442.

Results / Discussion: The MIC of MMC decreased 16-fold against S. aureus and 9-fold against P. aeruginosa when combined with 0.25× MIC H_2O_2. A 9-fold reduction was also observed against P. aeruginosa when combined with 0.25× MIC PHMB. Checkerboard assays confirmed synergistic interactions between MMC and PHMB, with fractional inhibitory concentration index (FICI) values ranging from 0.30 to 0.50 against P. aeruginosa. Kill-rate studies showed that adding a very low concentrations (0.01%) of PHMB to MMC achieved complete eradication (>6 Log10 reduction) of P. aeruginosa within 1, 5, and 10 minutes of exposure.

Conclusion: The newly synthesised proprietary MMC demonstrated strong synergistic effects with non-metallic additives such as H_2O_2 and PHMB against Staphylococcus aureus and Pseudomonas aeruginosa.

EP425 In vitro assessment of a hypochlorous acid-based wound solution at various dilutions

Rui Chen[1], Marcus Swann[1], Rebecca Catton[1], Mia Hanrahan[1], Jeanne Saint Bezard[1], Fergus Watson[1], Steven Percival[1]

[1]5D Health Protection Group Ltd., Liverpool, United Kingdom

Aim: The effectiveness of wound solutions - particularly topical antiseptics - can be reduced by dilution from wound exudate in clinical practice. This loss of efficacy is most pronounced in heavily exudative wounds, where antiseptic activity may be significantly compromised. This study aimed to evaluate the physicochemical properties (pH and ORP), in vitro biocompatibility, and antibacterial efficacy of four commercially available wound solutions at varying dilution levels.

Method: The wound solutions tested included hypochlorous acid (HOCl) cleanser solution* (~0.033%, pH 4.0), 0.125% sodium hypochlorite* (NaOCl, pH 9.80), a combined solution of 0.01% HOCl/NaOCl* (pH 7.0), and 0.1%

polyhexanide* (PHMB, pH 6.7). Each was assessed at three concentrations - 100%, 75%, and 50% - for pH and oxidation-reduction potential (ORP), cytotoxicity on HaCaT keratinocytes, HDFa fibroblasts, and mesenchymal stem cells (MSCs), as well as antibacterial activity against Pseudomonas aeruginosa.

Results / Discussion: The HOCl cleanser solution exhibited higher ORP values compared to NaOCl, HOCl/NaOCl, and PHMB, indicating strong oxidative potential and excellent stability even after dilution. Remarkably, the HOCl solution retained strong antimicrobial efficacy even at 50% dilution, as evidenced by the complete elimination of P. aeruginosa (>5.78 Log_{10} reduction). At equivalent dilutions, the HOCl-based wound solution exhibited little to no cytotoxicity toward HaCaT, HDFa, and MSCs during up to 15 minutes of exposure, showing lower cytotoxicity compared to NaOCl and PHMB solutions.

Conclusion: This study indicated that a hypochlorous acid cleanser solution (~0.033%, pH 4.0) offered the greatest preservative strength, strongest antimicrobial activity, and lowest cytotoxicity among the tested formulations.

*: Vashe® wound solution: HOCl cleanser solution; Dakin's® solution: 0.125% NaOCl; Granudycyn® wound irrigation solution: 0.01% HOCl/NaOCl; Prontosan® wound irrigation: 0.1% polyhexanide.

EP169 A multidisciplinary debridement pathway: Standardising care across anatomical sites

Katherine Griffin[1], Hollie Robinson[1]

[1]*South Warwickshire NHS Foundation Trust, Warwickshire, United Kingdom*

Aim: To develop a multidisciplinary debridement guide to standardise wound bed preparation across anatomical sites, reduce clinical variation, and support timely, risk-appropriate decision-making. The guide integrates Tissue Viability and Podiatry expertise and aligns with the TIME framework.

Method: A structured development process was undertaken between September 2024 and September 2025 involving ten clinicians across five specialities. Ten representative wound cases including necrotic foot wounds, leg ulcers, and pressure ulcers were reviewed to map practice variation and identify critical decision points. Guidance development progressed through five iterative drafts incorporating stakeholder feedback, evidence, anatomical risk considerations, and safety criteria. Debridement modalities were assessed against predefined factors such as conformability, moisture handling, safety in high-risk areas, and usability across community and acute settings. Enzyme alginogel was identified as a preferred option for specific wound presentations, while other modalities remained indicated where clinically appropriate. QR-linked sub-pathways were created for diabetic foot and leg ulcer management to support rapid access and local protocol integration.

Results / Discussion: Significant variability was identified in debridement selection, particularly regarding anatomical risk, cavity wounds, and escalation thresholds. Iterative refinement improved guidance clarity and alignment with clinical workflow, supporting more consistent risk stratification and dressing selection. Conformability and dead-space management informed the criteria-based recommendation of enzyme alginogel for cavity wounds, with hydrocolloid dressings, non-adherent dressings and sharp debridement, applied where indicated. QR-linked sub-pathways improved navigability and system integration.

Conclusion: A structured, multidisciplinary approach produced a clinically acceptable, risk-stratified debridement guide suitable for diverse wound types. Next steps include training, feedback loops, and prospective evaluation during implementation.

EP426 Assessment of synergistic treatments using wound solutions and antimicrobial gels to evaluate the degree of inactivation of biofilms

Rebecca Catton[1], Fergus Watson[1], Steven Percival[1]

[1]5D Health Protection Group Ltd., Liverpool, United Kingdom

Aim: Bacterial biofilms in wounds create substantial therapeutic challenges by forming protective extracellular matrices that dramatically reduces antimicrobial efficacy. Wound solutions can provide biofilm disruption without requiring prolonged antimicrobial activity, while antimicrobial gels often prolong antibacterial effects but limited penetration through intact biofilm structures. This study addresses how synergistic combination therapy with sequential applications of wound solutions and antimicrobial gels can overcome these limitations and enhance clinical outcomes.

Method: A 48 hour *P. aeruginosa* AATCC 15442 biofilm was established on a wounded porcine explant model, then submerged in *Hypochlorous acid solution or Saline for 10 minutes before being placed into a *Poloxamer gel, a *Hypochlorous acid gel or Saline for a further 4 hours. Also, samples were placed into a Hypochlorous acid gel for 10 minutes then placed into Saline for 4 hours. Samples were then neutralised for 5 minutes, sonicated for 30 minutes and enumerated to determine CFU/cm2. A log10 reduction value was calculated from an untreated 48 hour control.

Results / Discussion: Improved activity was observed for Hypochlorous acid solution and Saline, which produced a 3.59 log10 reduction. A combination of Saline followed by Hypochlorous acid gel achieved a >4 log10 reduction. The most successful synergistic treatment was the use of Hypochlorous acid solution followed by Hypochlorous acid gel which demonstrated a >6 log10 reduction. The poloxamer gel demonstrated lower biofilm inactivation, achieving <2 $\log_{10}$ reduction.

Conclusion: The results suggest there is a synergistic effect between the Hypochlorous acid antimicrobial solution and Hypochlorous acid antimicrobial gel in the inactivation of mature biofilms within a wounded pig skin model.

*: Vashe® wound solution: Hypochlorous acid solution, Vashe®gel: Hypochlorous acid gel, revyve™ gel: Poloxamer gel

---

EP170 Patient-reported outcomes and quality of life in chronic wounds: A prospective single-arm study of silicone superabsorbent dressings

Anitha Pitchika[1], Teresa Szenk[2], Agnieszka Segiet-Święcicka[2], Vladica Velickovic[1 3], David G. Armstrong[4], Prof. Dr. Sebastian Probst[5]

[1]Hartmann Group, Heidenheim, Germany, *[2]Clean Data Labs, Warsaw, Poland*, *[3]Institute of Public Health, Medical Decision Making and HTA, UMIT, Hall, i.T., Austria*, *[4]Keck School of Medicine of University of Southern California, California, United States*, *[5]HES-SO, Geneva, Switzerland*

Aim: This study evaluated the changes in patient-reported benefit and wound-specific quality of life following chronic wound management with silicone superabsorbent polymer (SAP) dressings in patients with venous leg ulcers (VLU) and diabetic foot ulcers (DFU) over a 6-week period.

Method: This prospective, single-arm study enrolled 80 patients with either VLU or DFU across multiple clinical sites. Patients received either silicone* or silicone border** SAP dressings combined with compression therapy for VLU and offloading boots for DFU. Patient-reported outcomes were measured using the Patient Benefit Index (PBI-W), Wound Quality of Life (Wound-QoL), and Social Support Questionnaire (SSQ). PBI-W and Wound-QoL scores were assessed at baseline and final visit, while SSQ was administered once during the study, primarily at baseline.

Results / Discussion: Global PBI-W scores improved significantly from baseline to final visit at week 6 (n=72). Overall mean (SD) increased from 2.26 (1.05) to 2.90 (0.94), mean change 0.57 (1.18); p<0.001. Wound-QoL scores demonstrated substantial improvement (n=75), with global scores decreasing from 2.2 (SD 0.8) to 1.3 (SD 0.9), mean reduction 0.9 (SD 1.0; p<0.001). Mean reduction in subscale scores were observed for body 0.6 (0.9), psyche 0.9 (1.4), and everyday life 0.9 (1.2); all p<0.001. These changes exceed the minimal important difference (MID) of 0.5,

indicating patient-relevant improvement in Wound-QoL. Overall SSQ total score (n=77) was high (mean 6.1), with similar values for significant other (6.4), family (6.2), and friends (5.7). These findings indicate strong perceived social support, which may contribute to positive patient-reported outcomes.

Conclusion: The findings support significant improvements in patient-reported benefit and wound-specific quality of life, alongside consistently high levels of social support following chronic wound management with SAP dressings.

EP171 Acceptability and usability of a tri-associate factor antimicrobial wound cleanser and gel across all care settings

Rose Raizman[1]

[1]Scarborough Health Network Centenary Hospital, Adjunct Lecturer Lawrence S. Bloomberg Faculty of Nursing, University of Toronto, Toronto, Canada

Aim: To evaluate the acceptability, usability, safety, and performance of a 0.057% sodium hypochlorite–based antimicrobial wound cleanser and gel in the management of acute and chronic wounds across multiple care settings.

Methods: A prospective observational study (February–November 2025) included 50 patients with venous leg ulcers (n=15), pressure injuries (n=8), diabetic foot ulcers (n=12), and surgical or fungating wounds (n=15). The antimicrobial cleanser was used for wound irrigation and/or soaking at each dressing change. The antimicrobial gel was applied as a primary dressing when indicated (n=10). In three cases, the cleanser was used for instillation dwell with negative pressure wound therapy (NPWT). Standardised assessments captured wound characteristics, bacterial load using clinical signs and fluorescence imaging, odour, pain, debridement progress, and clinician/patient satisfaction on 5-point Likert scales.

Results: Mean patient age was 64 years, and average healing occurred at 13 weeks. Most wounds presented with critical colonisation or infection, malodour, and necrotic tissue. Significant reductions in devitalised tissue and odour were observed within the first week. Patients treated with the gel and those receiving cleanser instillation/NPWT showed clear improvements in imaging. All pressure injuries managed with the gel healed fully. Clinician ratings were 100% excellent/good for ease of use; pain/stinging: 82% no pain, 8% minimal pain, 6% neutral, 4% fair pain; bioburden reduction 100%; odour reduction 86% excellent and 14% good; overall patient acceptance 96% excellent/good.

Conclusion: The formulation demonstrated strong clinician and patient acceptability, safety, and broad clinical effectiveness across wound types and care settings, showing rapid bioburden and odour reduction, minimal pain, effective support of debridement and healing, and successful use with NPWT.

EP172 Evaluation of a five-layer foam dressing for pressure injury prevention

Alicia Smith[1], Jennifer Gale[2]

[1]Grady Health System, Atlanta, Georgia, United States, *[2]Smith + Nephew, Hull, United Kingdom*

Aim: 1 in 10 adult patients in the United States (US) are impacted by hospital acquired pressure injuries (HAPIs) resulting in an average of 9.5 extra days in hospital, 95% are preventable. Foam dressings are applied as part of pressure injury prevention (PIP) to decrease strain on soft tissues and absorb shear forces, therefore lowering the risk of HAPIs. The aim of this evaluation was to assess clinician satisfaction with a dressing designed to prevent pressure injuries.

Method: Respondents in the US accessed the product evaluation form using a unique QR code to input data during a defined survey period. Clinicians were asked to follow their usual protocol for dressing examination and removal and trained on five-layer foam dressing* use in line with their clinical judgement. The evaluation captured ratings on comfortability as well as performance in other key areas, including how well the dressing stayed in place and wear time.

Results: Between September and December 2025, 385 responses were received from 31 hospitals (questions were non-mandatory). 96.3% (362/376 responses) of respondents were satisfied with the wear time of the dressing and 93.9% (339/361 responses) of respondents stated their expectations were met in terms of the dressings ability to be lifted and reapplied for skin inspection. Further to this, 97.8% (361/369 responses) of respondents stated their expectations were met with how the dressing conformed to body contours and 95.2% (362/380 responses) of respondents would continue to use the dressing for PIP.

Conclusion: This evaluation enabled hospitals to assess clinician satisfaction when applying a dressing for PIP and highlighted how expectations were met in several key areas.

* ALLEVYN™ COMPLETE CARE (Smith and Nephew, Hull, UK)

EP173 Comparative study of punch grafts and split skin grafts

Jurriën Kamphuis[1]

[1]*Deventer Ziekenhuis, Deventer, Netherlands*

Aim: The study aims to provide an evidence-based choice between punch grafts and STSG so that nurse specialists can decide together with patients without specialist consultation. The goal is to improve care quality by optimizing wound healing, pain, and quality of life, streamlining treatments, and reducing healthcare costs, thus providing patients with more effective wound care and improved healing.

Method: This quantitative, prospective cohort study involved chronic wound patients divided into two groups: punch grafts and STSG. Data on wound healing, pain, and quality of life were collected via validated instruments and questionnaires administered before treatment, after five days, and after three weeks. Analysis was performed using SPSS. The study was conducted in a medium-sized Dutch hospital by nurse specialists. Methodological quality was ensured through standardized procedures and instructions. Limitations such as external cultural influences were acknowledged.

Results / Discussion: In this cohort study, 20 patients were compared: ten patients in the punch grafts group and ten patients in the VHT group. The VHT group started with significantly larger wound areas but showed a faster reduction. Both groups reported pain reduction without a significant difference; donor site pain was higher in the VHT group, although not significantly. Quality of life improved more in the punch grafts group, though not statistically significant. VHT was associated with higher costs due to surgical intervention and hospital admission, whereas punch grafts were performed on an outpatient basis and were more cost-efficient a difference of 5000 euros.

Conclusion: Punch grafts in this study were associated with more favorable outcomes than VHT in terms of pain perception and quality of life, while achieving comparable wound healing over time.

EP427 The role of medical compression hosiery in the healing of C4–C6 venous leg lesions during pregnancy: A clinical case series

Nubar Ismayilova[1], Vugar Fattah-Pur[1]

[1]*Azerbaijan State Advanced Training Institute for Doctors named by A. Aliyev, Baku, Azerbaijan*

Aim: To evaluate the therapeutic role of Class II–III compression hosiery in promoting wound healing, reducing edema, and improving quality of life in pregnant women diagnosed with CEAP C4–C6 venous disease.

Method: A prospective case series of 11 pregnant women (gestational age 18–33 weeks) presenting with C4 (eczema), C5 (healed ulcer), or C6 (active ulcer). All patients were managed with:

- Class II or III compression hosiery (23–32 mmHg / 34–46 mmHg depending on severity)
- Standard wound care protocols suitable for pregnancy
- Lifestyle and mobility counseling.

Clinical assessments were performed every 2 weeks, including edema measurement, wound size, pain score, exudate level, and ultrasound evaluation of venous reflux.

Results / Discussion:

- Wound healing: 7/7 patients with C6 ulcers achieved ≥70% area reduction; 5/7 achieved full closure within 6–9 weeks.
- Edema: Mean limb circumference decreased by 18% ± 4.3 after 4 weeks.
- Pain: VAS score improved from median 6.5 to 2.
- No complications related to compression therapy were recorded.
- Patients reported improved mobility, sleep quality, and reduced heaviness.

Conclusion: Compression hosiery is a safe, effective, and pregnancy-compatible treatment for C4–C6 venous disease. It promotes accelerated wound healing, edema reduction, and symptomatic relief. These findings reinforce medical compression as a first-line therapy in pregnant women with advanced CVI.

Keywords: pregnancy, venous ulcer, compression hosiery, C4–C6, wound healing, edema

EP428 Retrospective descriptive analysis of transforming powder dressing in 70 patients with hard- to- heal wounds

Matthias Augustin[1 2], Natalia Kirsten[1 2], Sandra Wolf[2]

[1]Comprehensive Wound Center, University Medical Center of Hamburg, Hamburg, Germany, *[2]German Institute for Health Services Research in Dermatology and Nursing, Hamburg, Germany*

Aim: Wound healing outcomes are often confounded by systemic comorbidities and environmental factors that delay progression. Rising wound-management costs underscore the need for treatment strategies that are safer, more efficacious, and more cost-effective while reducing the overall burden of care.

To evaluate the effectiveness, healing trajectory, and safety of Transforming Powder Dressing (TPD) in hard-to-heal, Standard of Care (SOC)-refractory wounds and compare outcomes with a matched SOC cohort from the European Wound Registry (EWR).

Method: Seventy patients with hard-to-heal, SOC-refractory wounds were treated at a university-based German wound clinic and transitioned from SOC to TPD. Outcomes were compared with matched EWR data representing SOC aligned with European chronic wound-care guidelines.

Results / Discussion: Prior to conversion, mean wound duration was 19.1 months (range: 1–240). Mean patient age was 65.3 years (range: 23–96); 41 (59%) were female. Wound etiologies included: 23 venous ulcers (33%), 18 atypical wounds (26%), 10 traumatic/post-surgical wounds (14%), 7 diabetic foot ulcers (10%), 5 arterial ulcers (7%), and 7 other etiologies (10%).

Complete wound healing at 14 weeks was achieved in 37 TPD-treated patients (53%) versus 8% among SOC patients. Thirty-day extended wear time was maintained in 46 wounds (66%), of which 37 (80%) fully healed. Accelerated wound-surface–area reduction was observed, and clinical treatment goals (healing, granulation, pain reduction) were achieved in 50 patients (71%). No unanticipated adverse events occurred.

Conclusion: TPD demonstrated safety and effectiveness across a wide range of hard-to-heal wounds, with significantly faster healing compared to European SOC. Its extended wear time, low disruption, and favorable healing dynamics suggest TPD as a promising strategy to improve patient outcomes while reducing dressing-change burden and overall care demands.

EP174 Plant-derived bioadhesive with antimicrobial activity for potential wound-care applications

Giorgi Bakuridze[1], Aliosha Bakuridze[1]

[1]Tbilisi State Medical University, Tbilisi, Georgia

Aim: The aim of the study was to develop a plant-based bioadhesive (medical glue) containing secondary plant metabolites, to biosynthesize silver nanoparticles, and to investigate their pharmaco-technological properties. Over the past decade, numerous studies and experimental attempts have been conducted to replace surgical sutures and metallic clips with biodegradable or bioabsorbable adhesives that offer convenience and minimize invasiveness during surgical procedures. Despite their successful clinical application, commercially available tissue adhesives still present certain limitations.

Method: The study materials included: tannic acid, tannin, aqueous extracts of *Ficus carica* fruits, *Hedera helix* leaves, *Polypodium vulgare* roots, *Glycyrrhiza glabra* roots, *Plantago major* leaves, *Juniperus communis* berries, *Epilobium angustifolium* leaves, flaxseed mucilage, silk processing residues, acacia gum, pectin, quercetin, urotropin, polyethylene glycol, poloxamer, and polyvinyl alcohol, among others. Based on literature data, 15 experimental formulations containing tannic acid and 13 formulations containing tannin were developed using selected active and auxiliary ingredients. Physicochemical and technological analytical methods were employed throughout the research.

Results / Discussion: The physicochemical characteristics of the obtained bioadhesives were evaluated, including adhesive strength, adhesion duration, and moisture resistance. Optimal formulations containing tannic acid and tannin were identified. The “Spot Test” method confirmed that these bioadhesives exhibit pronounced antibacterial activity and do not cause skin irritation. The listed plant and synthetic ingredients, through establishing bonds with tannic acid, increase adhesive ability and also optimize biological activity.

Conclusion: Based on biopharmaceutical and technological research, formulations and preparation methods for tannic acid- and tannin-containing bioadhesives were developed. Evaluation of physicochemical parameters demonstrated favorable adhesion, resistance, biocompatibility, and biodegradation characteristics.

EP175 Advances in wound biomaterials: a systematic review on the therapeutic efficacy and drug-delivery capacity of bacterial nanocellulose dressings for chronic wound management (2015-2025)

Javad Ghorbani[1], Kimia Soltaniha[2], Mehrnaz Boroumand[2], Raman Lotfi[2]

[1]Non-Communicable Diseases Research Center, Alborz University of Medical Sciences, Karaj, Iran, Head of Zakhm Karaj Wound Clinic, Alborz University of Medical Sciences, Karaj, Iran, Karaj, Iran, *[2]Member of Alborz University of Medical Sciences Research Committee, Karaj, Iran, Member of Zakhm Karaj Wound Clinic, Alborz University of Medical Sciences, Karaj, Iran, Karaj, Iran*

Aim: This review aims to synthesize and evaluate the evidence (2015-2025) on the efficacy, mechanisms, and clinical utility of bacterial nanocellulose (BNC) dressings for refractory chronic wounds (DFUs, VLUs, PIs). It specifically assesses BNC’s performance versus standard care and the added value of its functionalization as a drug-delivery platform for antimicrobials and bioactive molecules.

Method: Conducted per PRISMA guidelines, a systematic search of PubMed/MEDLINE, Scopus, Embase, and CENTRAL (2015-2025) was performed using MeSH and keywords for bacterial nanocellulose (BNC) and chronic wounds. Eligible designs were RCTs, prospective cohorts, and controlled in-vivo models. The PICOS framework defined inclusion: Patients/models with DFU, VLU, or PI; Intervention with BNC dressings; Comparison to conventional/advanced dressings; Outcomes of closure rate, area reduction, infection control. Two independent reviewers conducted screening, data extraction, and risk-of-bias assessment (Cochrane RoB 2.0, SYRCLE’s tools), with discrepancies resolved by consensus.

Results / Discussion: Following PRISMA-guided screening of 256 records, 40 studies (12 RCTs, 10 cohorts, 18 in-vivo) were included. Meta-analysis indicates BNC dressings significantly accelerate wound closure (mean difference: -9.2 days, 95% CI: -12.1 to -6.3) and enhance granulation (35-50% increase in-vivo). Crucially, drug-functionalized BNC (e.g.,with silver nanoparticles, growth factors) demonstrated superior efficacy, achieving >2-log bacterial reduction and a 40% greater wound area reduction in complex wounds compared to pure BNC. No serious adverse events were reported.

Conclusion: This review establishes bacterial nanocellulose (BNC) as an active therapeutic platform, not a passive dressing. Its intrinsic properties enhance healing, but its transformative potential lies in functionalization as a targeted drug-delivery system to precisely control infection and inflammation. Translation requires future large-scale RCTs with standardized formulations and robust health-economic analyses to confirm its role in personalized wound care.

EP429 Engineered silk dressing for DFUs: Faster healing through inflammatory reset

Rajesh Kesavan[1], Sheela Sasikumar[2], Darwin Britto[2]

[1]Dr.RK Diabetic Foot and Podiatry Institute and Rakesh Jhunjhunwalla Amputation Prevention Center, Meenakshi Academy of Higher Education and Research, Chennai, India, *[2]Dr.RK Diabetic Foot and Podiatry Institute and Rakesh Jhunjhunwalla Amputation Prevention Center, Chennai, India*

Aim: To evaluate the therapeutic potential of an engineered silk dressing in enhancing wound healing in Grade 1A DFUs and to assess its role in modulating inflammatory pathways.

Method: Twenty patients with Grade 1A DFUs received treatment with the engineered silk dressing. Wound-closure dynamics were monitored through serial digital imaging at each dressing change. Non-invasive wound-bed tissue samples were analysed using semi-quantitative PCR to assess expression of pro-inflammatory cytokines, anti-inflammatory markers, matrix metalloproteinases (MMPs), and TIMP-1.

Results / Discussion: Treatment resulted in accelerated wound closure with early, robust granulation tissue formation. Gene expression analysis showed approximately 30% reduction in TNF-α, IL-1β, IL-6 and a decrease in MMP levels. Concurrently, TGF-β and TIMP-1 levels increased, indicating restoration of inflammatory balance and improved extracellular matrix regulation.

Conclusion: The engineered silk dressing demonstrates strong potential for DFU management by modulating inflammation, reducing MMP activity, and accelerating tissue repair, making it a promising bioactive option for chronic wound care.

EP430 Application of international recommendations for exudate management in complex wounds: an observational study based on a literature review and clinical cases

Sofia Megino Escobar[1], Laura Baltà Domínguez[1]

[1]Atención Primaria BCN, Barcelona, Spain

Aim: This work reviewed the literature including international guidelines on exudate management in complex wounds, with the objective of applying these principles in clinical practice and observing their impact in real-world conditions. The focus was on evaluating the performance of advanced dressings in relation to exudate control, pain and overall patient well-being.

Method: A literature review was conducted on international recommendations for exudate management and periwound skin protection. Based on these principles, a descriptive observational study was carried out using two representative clinical cases: calciphylaxis in a palliative care patient and a non-healing chronic venous ulcer. Both individuals presented significant comorbidities, functional limitations and dependence for self-care. Management followed a holistic, guideline-aligned approach incorporating biofilm control, exudate management, periwound

protection and pain relief. Within this framework, the performance of a polyurethane foam dressing with a silicone contact layer and vertical absorption was assessed for its suitability and practicality in routine care.

Results / Discussion: The foam dressing with vertical absorption provided effective exudate control of wounds with high-volume or viscous exudate. Its use reduced periwound maceration and the frequency of dressing changes. Pain levels decreased substantially, with Visual Analogue Scale (VAS) scores falling from high (VAS 8–10) to low or absent pain (VAS 0–4), and comfort during dressing changes improved. Effective edge sealing supported periwound skin protection and contributed to a stable wound environment, consistent with priorities identified in international consensus documents.

Conclusion: This observational study indicates that implementing international guidelines in real-world practice, supported by advanced dressings with vertical absorption and a silicone contact layer, can enhance exudate control, reduce pain and improve patient well-being within a holistic wound care approach.

EDUCATION

EP176 Prehabilitation as an emerging strategy in chronic wound care in Poland

Anna Hepa-Banasik[1], Magdalena Szatan[1]

[1]Burn Treatment Center, Dr. Stanisław Sakiel, Siemianowice Śląskie, Poland, Siemianowice Śląskie, Poland

Aim: Prehabilitation, understood as preparing and strengthening patients before or during therapy, has gained attention in surgery, oncology, and rehabilitation. In Poland, this concept is only beginning to emerge and has not yet been systematically integrated into chronic wound care. The aim of this paper is to present the idea of prehabilitation in the Polish healthcare context and discuss its potential role in wound management.

Method: A narrative review of international literature and national health policy documents was performed. In addition, early experiences from educational workshops for Polish patients with chronic wounds and their families were analyzed, providing insight into the feasibility of implementing prehabilitation strategies.

Results / Discussion: Polish patients with chronic wounds often present with multiple comorbidities, malnutrition, reduced mobility, and psychosocial stressors, all of which negatively affect healing outcomes. Introducing prehabilitation could address these determinants by combining nutritional support, physical activity, psychological care, and structured education. Although prehabilitation has not yet been formally included in national wound care pathways, initial pilot workshops indicate strong patient interest, improved adherence to therapy, and higher motivation for active participation in treatment. Integrating families into the process also strengthens long-term behavioral change. At a systemic level, prehabilitation has the potential to reduce complications, shorten healing times, and lower healthcare costs.

Conclusion: The idea of prehabilitation in Poland is at an early stage but represents a promising innovation for chronic wound care. By shifting from reactive treatment to proactive patient preparation, prehabilitation could transform wound management, enhance patient outcomes, and support healthcare sustainability. Broader implementation requires legislative recognition, interprofessional collaboration, and development of standardized programs adapted to the Polish healthcare system.

EP178 Exploring factors influencing the psychological well-being of patients with diabetic foot ulcers in Saudi Arabia

Rawan Afandi[1], Sultan Musa[2], Fatema Omar[3], Ahmed Najmi[3]

[1]MOH, Jazan Health Cluster. King Fahad Central Hospital, Jazan, Saudi Arabia, *[2]MOH, Jazan Health Cluster. Prince Mohammed Bin Naser Hospital, Jazan, Saudi Arabia*, *[3]MOH, Jazan Health Cluster, Jazan, Saudi Arabia*

Aim: This study aims to explore factors influencing psychological well-being of diabetic foot patients in Saudi Arabia.

Methods: A descriptive qualitative design was employed. Semi-structured, face-to-face interviews were conducted with nine purposively selected patients between September and October 2025. All interviews were audio-recorded, transcribed verbatim, translated into English, and analyzed thematically using an inductive–deductive approach aligned with Clarke and Braun's six-phase framework. Data saturation was reached after six interviews and confirmed with three additional interviews.

Results / Discussion: The sample included nine Saudi participants (six males, three females) aged 40–70 years. The analysis generated 85 initial codes refined into 70 main codes. Twelve themes emerged: six deductively mapped to the Health Belief Model constructs—perceived severity, susceptibility, benefits, barriers, cues to action, and self-efficacy—and six emerged inductively, capturing experiences beyond the theoretical framework. Findings revealed that psychological well-being was shaped by emotional distress, fear of disability, social stigma, treatment burden, and impact on daily life. Positive influences included strong family support, trust in healthcare providers, spiritual acceptance, and effective coping strategies. Beliefs about illness severity and perceived benefits strongly influenced adherence, while barriers such as pain, mobility limitations, and emotional strain hindered engagement with care.

Conclusion: Patients with diabetic foot ulcers experience substantial emotional, physical, and psychological burdens. Coping is enhanced by support systems, faith, and self-efficacy, while fear, stigma, and life obstacles create significant challenges. Addressing psychological needs is essential for delivering comprehensive and effective diabetic foot care.

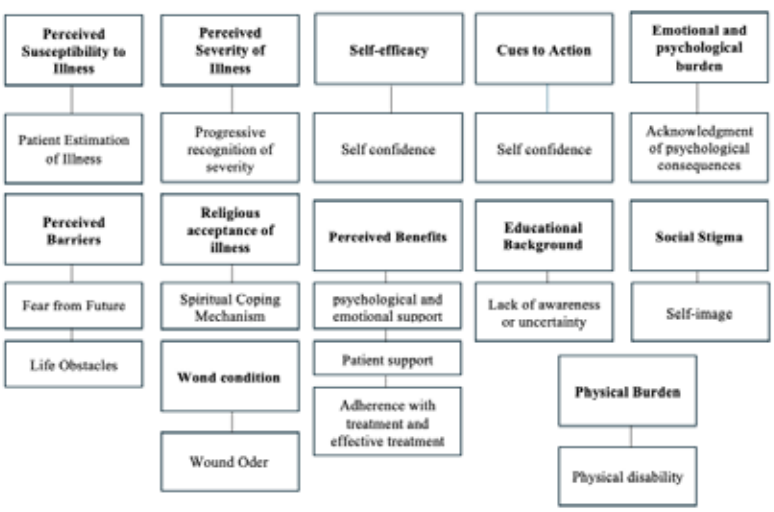

EP179 Artificial intelligence in wound care education: Scoping review

Rúben Encarnação[1], José Alves[2], Ana Marques[3], João Neves-Amado[4], Paulo Alves[4]

[1]Centre for Interdisciplinary Research in Health, Faculty of Health Sciences and Nursing, Universidade Católica Portuguesa, 4169-005, Porto, Portugal, Cardiology Intensive Care Unit, São João Local Healthcare Unit, 4200-319, Porto, Portugal, Porto, Portugal, *[2]Centre for Interdisciplinary Research in Health, Faculty of Health Sciences and Nursing, Universidade Católica Portuguesa, 4169-005, Porto, Portugal, Intensive Care Unit, Braga Local Healthcare Unit, 4710-243, Braga, Portugal, Porto, Portugal*, *[3]Centre for Interdisciplinary Research in Health, Faculty of Health Sciences and Nursing, Universidade Católica Portuguesa, 4169-005, Porto, Portugal, Intensive Care Unit, Gaia and Espinho Local Healthcare Unit, 4434-502, Vila Nova de Gaia, Portugal, Porto, Portugal*, *[4]Centre for Interdisciplinary Research in Health, Faculty of Health Sciences and Nursing, Universidade Católica Portuguesa, 4169-005, Porto, Portugal, Porto, Portugal*

Aim: This scoping review aimed to map and synthesise evidence on the use of artificial intelligence (AI) in wound care education, identifying current applications, benefits, challenges, and gaps in the literature.

Method: The review followed JBI methodology and PRISMA-ScR guidelines. A comprehensive search of major databases and grey literature was conducted in December 2023 and updated on 30 November 2024, with no restrictions on study design or publication date. Studies addressing AI within educational contexts related to wound care were eligible. Screening and data extraction were performed independently by two reviewers, and findings were synthesised using descriptive and content analysis.

Results / Discussion: Seventeen publications met the inclusion criteria, spanning 2006–2024, with a marked increase in recent years. Studies demonstrated diverse AI applications, including adaptive e-learning platforms that improved pressure ulcer assessment skills; machine learning and deep learning models for wound image analysis, tissue classification, and real-time pressure injury staging; AI-enhanced virtual and augmented reality simulations promoting immersive skill development; generative AI tools producing realistic synthetic wound images while preserving patient privacy; and case-based reasoning systems supporting diagnostic accuracy in diabetic foot ulcer care. Across studies, AI showed potential to enhance personalised learning, clinical reasoning, engagement, and real-time feedback. However, most publications were developmental, used small samples, lacked empirical validation, and provided limited evidence of impact on educational outcomes. Ethical concerns—including algorithmic bias, data governance, transparency, and educator readiness—were consistently highlighted.

Conclusion: AI offers promising opportunities to modernise wound care education by supporting interactive, personalised, and evidence-based learning environments. Stronger empirical evidence, ethical safeguards, and rigorous evaluation are required to ensure safe, effective, and equitable integration of AI-enhanced tools into educational practice.

EP432 Scientific view of the global literature on AI-Based educational interventions in wound care: A bibliometric analysis

Gulten Sucu Dağ[1]

[1]Eastern Mediterranean University, Famagusta, North Cyprus via Mersin 10, Turkey, Türkiye

Aim: The aim of this study is to evaluate global research on artificial intelligence-based training initiatives in wound care through bibliometric analysis and to obtain a structured overview of the features and developments in this field.

Method: A bibliometric analysis of 323 publications from 2000 to 2025 was performed to map the literature of artificial intelligence (AI)-supported educational interventions in wound care. Data were extracted from the Web of Science and analyzed using Bibliometrix/Biblioshiny (R 4.3.2).

Results / Discussion: Scientific output demonstrated a marked increase after 2015, accelerating sharply after 2020, reflecting global adoption of AI-driven tools in wound assessment, image segmentation, and decision-support training. In particular, since 2020, studies on AI-based wound assessment, image analysis, and decision support models

have rapidly gained visibility in the literature and received more citations. The Journal of Plastic Reconstructive and Aesthetic Surgery and the Journal of Surgical Research were the top spot, followed by Advances in Skin & Wound Care, the International Wound Journal, when it comes to publishing on the subject. The journal with the highest number of citations in the field of artificial intelligence in wound care is the International Wound Journal (220 citations). Trend topics of keyword plus that appear most frequently in artificial intelligence research on wound care are 'care' and 'management'. The United States (374), China (348) and Japan (100) are the 3 nations with the highest number of publications in the field of artificial intelligence-assisted wound care.

Conclusion: AI-supported education research in wound care has increased rapidly; most studies continue to prioritize clinical imaging and diagnostic applications, while education-focused interventions remain markedly insufficient in terms of content, methodological rigor, and multi-center.

EP180 Umbilical cord care practices among midwives in Austria: Results from a nationwide survey

Charlotte Reisinger[1], Katharina Pink[1 2]

[1]IMC Krems University of Applied Sciences, Austria, Krems an der Donau, Austria, *[2]Department of Evolutionary Anthropology, University of Vienna, Vienna, Austria*

Aim: Umbilical cord care is a key component of midwifery practice and crucial for preventing neonatal infection. In Austria a national guideline does not exist, likely resulting in heterogeneous practices. This study aimed to assess current cord care practices among Austrian midwives, identify trends and draw implications for national guideline development.

Method: A cross-sectional 21-item online survey was distributed between February and April 2025 and completed by 300 midwives (approx. 10% of the local professional workforce). Data were analysed descriptively. Chi-square tests were applied where appropriate, and open-ended responses were categorised inductively.

Results / Discussion: Dry cord care was the most common practice for inconspicuous stumps (77.7%, 233/300). For stumps with signs of inflammation, an octenidine-based antiseptic, was used most frequently (80.3%, 241/300), followed by a phytopharmaceutical powder based on Arnika, Calendula and Echinacea (24.7% healthy; 45.0% for inflamed stumps). Additional approaches included rose hydrolate, sugar, rice powder and breast milk. More than half of hospital-based midwives (54.5%, 108/198) indicated absence of written workplace instructions. Cord care was rated "relevant" or "highly relevant" by 73.7% (221/300), and 86.9% (259/298) considered it "important" or "very important" for parents. Nearly half (47.0%, 141/300) expressed interest for a national guideline on this topic.

Conclusion: Dry cord care predominated for healthy stumps, aligning with WHO recommendations, whereas octenidine was preferred for inflamed stumps. The use of diverse, partly non-evidence-based remedies and the frequent absence of institutional protocols highlight substantial variability. These findings support the need for an evidence-based national guideline to improve consistency, strengthen parental counselling and enhance midwifery education. This study provides the first nationwide overview of cord care practices in Austria and a foundation for guideline development.

EP181 Establishing a comprehensive wound care program in a maternity hospital: A three-year strategy to improve nursing competency and patient safety

Manal Abdul Rahman[1]

[1]Corniche Hospital, Abudhabi, United Arab Emirates

Background: At the end of 2023, Cornish Maternity Hospital had no wound care nurse, no standardized wound management materials, and no internal pathways for wound care. All wound cases were referred to external hospitals, and nursing staff demonstrated minimal knowledge and confidence in wound assessment and treatment.

Aim: To develop and implement a sustainable, evidence-based wound care program that builds nursing competency, standardizes clinical practice, and reduces safety risks.

Method: A wound care nurse specialist was appointed to lead the initiative. Over three years, the hospital enacted a structured improvement strategy that included:

1. development of hospital-wide wound care policies and competencies;

2. review and standardization of wound supplies, including access to advanced cleansing solutions and modern dressings

3. mandatory wound management training for all nurses, incorporating theory, simulation, and hands-on practice

4. pre- and post-training assessments and clinical competency evaluations

5. upskilling nursing educators to sustain competency rollout and provide continuous support.

Results / Discussion: More than 500 nurses completed mandatory wound care training and competency assessment. Knowledge evaluation demonstrated a marked improvement, with mean scores increasing from 45% pre-training to 90% post-training. Standardized supplies and clinical pathways are now embedded across all units. Safety performance improved, with a documented reduction in wound-related incidents. All complex wound cases are now referred internally to the wound care nurse rather than to external hospitals, supporting continuity of care and reduced system burden.

Conclusion: The introduction of a structured wound care service in a maternity hospital significantly enhanced nursing competency, safety culture, and clinical practice. The three-year phased strategy ensured sustainability and can serve as a replicable model for similar maternity settings that lack specialized wound services.

EP433 Evaluating nursing students' knowledge and experiences in team-based learning versus problem-based learning on pressure injury prevention

Ljubisa Paden[1], Renata Vettorazzi[2]

[1]*The University of Manchester, Division of Nursing Midwifery and Social Work, Manchester, United Kingdom*, [2]*University of Ljubljana, Faculty of Health Sciences, Ljubljana, Slovenia*

Aim: This study aimed to assess nursing students' knowledge levels on pressure injury risk assessment and prevention before and after Team-Based Learning (TBL) compared to Problem-Based Learning (PBL), and to explore their perspectives on learning approaches.

Method: A cross-sectional study was conducted with 50 second-year nursing students from one Slovenian higher education institution. Students were divided into two groups: a TBL intervention group (n = 25) and a PBL control group (n = 25). The intervention group engaged in TBL activities focused on pressure-injury risk assessment and prevention, while the control group attended a workshop on the same topic using a pre-developed PBL case study based on Levett-Jones' clinical reasoning model. Students' experiences were collected through written reflections in response to open-ended evaluation questions. Knowledge was assessed before the intervention and again one month later using the PUKAT 2·0 questionnaire.

Results / Discussion: Forty-three students completed both questionnaires (20 in the TBL group and 23 in the PBL group). Across the sample, no statistically significant differences in knowledge were observed prior to the intervention ($p > 0.05$). Similarly, no significant changes in knowledge were found within or between the groups one month after the intervention ($p > 0.05$). Nonetheless, students' reflections indicated that TBL provided a highly engaging and collaborative learning experience.

Conclusion: The TBL approach produced learning outcomes comparable to those of PBL. Students emphasized that case-based teamwork within the TBL structure increased their active participation and enhanced their understanding compared with conventional PBL instruction.

EP182 Wound care competencies in slovenian healthcare education: Results of a national educational audit

Ljubisa Paden[1 2], Zdenka Tičar[3 4], Vilma Urbancic-Rovan[5 6], Tanja Planinšek Ručigaj[7]

[1]The University of Manchester, Division of Nursing Midwifery and Social Work, Manchester, United Kingdom, [2]University of Ljubljana, Faculty of Health Sciences, Ljubljana, Slovenia, [3]Ministry of Health, Directorate for Health Care, Ljubljana, Slovenia, [4]Angela Boškin Faculty of Health Care, Jesenice, Slovenia, [5]University Medical Centre, Department of Endocrinology, Ljubljana, Slovenia, [6]University of Ljubljana, Faculty of Medicine, Ljubljana, Slovenia, [7]University Medical Centre Ljubljana, Dermatovenerology clinic, Ljubljana, Slovenia

Aim: The aim of this audit was to review competencies in wound care across all levels of healthcare education in Slovenia.

Method: A cross-sectional audit of formal and non-formal educational programmes was conducted, covering secondary-level nursing education, undergraduate healthcare programmes (nursing, medicine, midwifery, physiotherapy, occupational therapy, orthotics and prosthetics), and specialised continuing education. Data were collected from secondary schools, universities, colleges, and professional organisations providing non-formal training. Competencies were mapped against the EWMA Educational Frameworks for wound care, supplemented by relevant national documents and professional standards. Competency achievement was evaluated using a three-level assessment system (achieved, partially achieved, not achieved) and visualised through heat maps to enable comparison across professions and educational levels.

Results / Discussion: Findings reveal substantial variability in the depth and breadth of wound care competencies across programmes. Medicine and bachelor's-level nursing programmes exhibited the highest alignment with the EWMA Framework. Physiotherapy, occupational therapy, and orthotics/prosthetics demonstrated partial alignment consistent with their defined professional roles, while secondary-level nursing education provided essential foundational knowledge. Non-formal education programmes offered advanced or specialist content; however, the content, objectives, learning outcomes, and duration of such education varied considerably, making them difficult to compare and limiting evaluation of their impact on competency development. This variability highlights the absence of a unified national competency structure and the need for greater standardisation across all educational pathways.

Conclusion: This audit provides a strategic evidence base for the development of a national competency framework in wound care. Establishing standardised competencies across healthcare professions will strengthen interdisciplinary collaboration, improve patient safety, and ensure equitable, high-quality wound care throughout Slovenia.

EP434 Mapping wound care education in family medicine curricula: a cross-sectional study from Bosnia and Herzegovina

Andrea Bilić[1], Tamara Sinožić[2]

[1]Primary Health Care Center Mostar, Mostar, Bosnia and Herzegovina, [2]Primary health care, Rijeka, Croatia

Aim: To analyse the presence, structure and gaps in wound-care education within undergraduate and postgraduate family medicine curricula in Bosnia and Herzegovina (BiH), using a structured questionnaire developed for a parallel study conducted in Croatia.

Method: A descriptive cross-sectional study was conducted using a structured questionnaire distributed to the heads of family medicine departments at the medical faculties in Mostar, Sarajevo and Zenica. The questionnaire explored the extent of wound-care teaching at the undergraduate level (lectures, seminars, skills training), its integration in postgraduate specialty training, and perceived barriers to implementing structured wound-care education. No responses were obtained from the faculties in Banja Luka, Foča or Tuzla.

Results / Discussion: None of the three responding faculties reported having dedicated undergraduate lectures, seminars or practical sessions focused on chronic wound management. Wound-related content appears only fragmentarily within other courses, without defined learning outcomes or standardized teaching hours.

Postgraduate family medicine training similarly lacks mandatory wound-care rotations, supervised clinical practice or requirements for scholarly work on wound-related topics. Reported barriers include limited numbers of trained educators, insufficient curricular time, and inadequate institutional support.

These findings are consistent with international research documenting significant global deficits in wound-care education, which negatively affect provider competence and patient outcomes.

Conclusion: Wound-care education in family medicine programmes across BiH is markedly underdeveloped, leaving a critical gap in the preparation of frontline primary-care clinicians. Establishing a standardized curriculum that integrates theoretical instruction and hands-on clinical training—supported through collaboration with wound-care centres and the EWMA GP Network—is essential to improving competency and ensuring higher-quality wound care in the primary-care setting.

EP183 Pilot evaluation of an AI-driven simulation tool for postgraduate wound care education

Hermione Shea[1], Amna Mazeh[1], Benjamin Bullen[1], Zahra Aziz[1], Joel Moore[1], Peta Tehan[1]

[1]Monash University, Alfred Health, Melbourne, Australia

This pilot study aimed to evaluate wound care students' satisfaction with and perceived learning value of an artificial intelligence (AI) driven virtual patient simulation, developed to enhance communication skills and cultural humility.

Following completion of two AI-driven virtual patient scenarios, students enrolled in Graduate Certificate and Diploma units [Semester 1, 2025] were invited to complete a voluntary and anonymous survey. Eight out of eighty students responded (10% response rate). The survey included 5-point Likert-scale items and open-ended questions exploring engagement, feedback, and perceived value. Quantitative data were analysed with descriptive statistics. Agreement threshold was pre-determined to be 75% selecting 'Agree' or 'Strongly Agree' per item. Open-ended responses were thematically analysed.

All respondents (n=8) agreed that the simulation provided a realistic patient interaction and was engaging (both Agree 87.5%, Strongly Agree 12.5%). All agreed that the feedback improved their communication skills (Agree 87.5%, Strongly Agree 12.5%). Seven students (87.5%) expressed interest in accessing additional AI-based scenarios to explore clinical cases that would otherwise be unavailable in real-world placements. Thematic analysis identified psychological safety, accessibility, and authenticity as benefits. Participants stated: "I did not feel embarrassed if I said something wrong", "It allows more time to prepare, and I can pause at any time", and "The way the simulation integrated patient emotions, cultural nuances, and communication challenges made it feel very authentic."

Preliminary findings suggest that AI-driven simulations may provide an engaging and psychologically safe environment for wound care students to practice essential communication and supported self-management skills. However, the low response rate limited generalisability. Further research, improved response rate, performance measures and longitudinal assessment of skill transfer to clinical practice is needed to validate these findings.

EP184 Integrating wound care into medical school curriculum using artificial intelligence

Shreya Asher [1], Dhruv Vajipayajula[1 2], Sahil Suresh[1 2], Karen Panetta[3], Berri Jaque[4], James Baleja[4], Richard Freeman[1], Lisa Gould[1 5], Ira M Herman[1 2 6 7]

[1]Tufts University School of Medicine, Boston, United States, *[2]Tufts University Graduate School of Biomedical Sciences, Boston, United States*, *[3]Department of Electrical and Computer Engineering, Tufts University, Medford, United States*, *[4]Department of Medical Education, Tufts University School of Medicine,, Boston, United States*, *[5]Department of Surgery, Tufts Medical Center, Boston, United States*, *[6]Department of Developmental, Molecular, and Chemical Biology, Tufts University, Boston, United States*, *[7]Center for Innovations in Wound Healing Research, Tufts University, Boston, United States*

Aim: Wound care teaching remains underrepresented in medical school curricula despite its clinical importance. Understanding wound repair, tissue remodeling, and regenerative processes is essential not only because of the burden of wound related diseases, but also because wounds provide a natural bridge between foundational knowledge with clinical practice across all organ systems. Simultaneously, emerging applications of artificial intelligence (AI) offer unique opportunities to provide personalized curricula where structured teaching may be limited. This project aims to demonstrate a model for integrating the teaching of wound pathophysiology and management into multiple phases of the medical curriculum through an AI platform.

Method: We built an interactive case platform using Gemini-2.0, Google's large language model, and fed it case data. We prompt Gemini to engage with the user in various roles, including patient, family member, or translator, allowing users to obtain histories, order tests, and make diagnoses. The platform evaluates the user's performance and provides feedback. Collaboration with medical education faculty and students helped identify curricular gaps and integration opportunities.

Results / Discussion: A case library of 5 unique wound presentations was fed to an AI-driven simulator. Clinical history, wound biology, morbidity modifiers, and social determinants of health were combined into adaptive narratives. Early internal validation shows the model accurately reviewed concepts on multiple biological levels and generated feedback based on clinical reasoning. We also built a pilot case of a complex, mixed arterio-venous wound modelled on an existing instructional format.

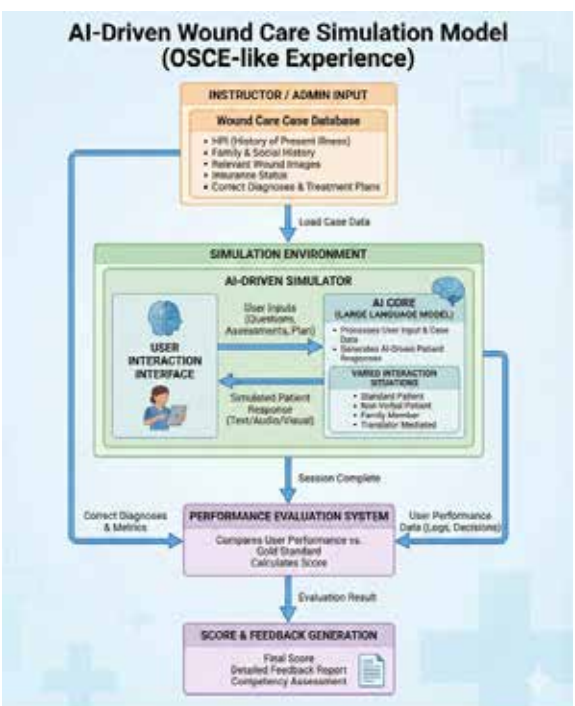

Figure 1: Case Library and Model Workflow. Adapted from Google Nano Banana Pro

Conclusion: Our AI-driven educational model provides a resource-conscious, scalable approach for reintegrating complex, multisystem wound content while supporting development of clinical reasoning skills.

EP185 Usability of a mobile application prototype to support teaching the wound assessment and treatment process

Lidiany Felix[1], Laize Lemos[2]

[1]Universidade Federal de Campina Grande, Paraíba, Brazil, *[2]Universidade Federal de Campina Grande, Campina Grande, Brazil*

Aim: Evaluate the usability of a mobile application prototype to support the teaching of wound assessment and treatment processes. The educational content of this app is based on the letters of the acronym TIMERS, internationally recognized as a practical guide for the systematic approach and management of chronic and difficult-to-heal wounds. Each letter of this acronym refers to the main obstacles that delay or prevent healing.

Method: Applied methodological study with a quantitative approach. To assess the usability of the application, the System Usability Scale (SUS) and Smartphone Usability Questionnaire (SURE) instruments were used. Nine undergraduate nursing students, seven nursing professors, and three professors working in the field of Information Technology (IT) participated in the evaluation process. The research was approved by the Ethics and Research Committee.

Results / Discussion: The application was developed on a hybrid platform and initially made available for the Android operating system. The prototype was built with a simple, attractive, and easy-to-use interface, consisting of the following topics: assessment, treatment, coverage, and multiple-choice quiz questions. JavaScript and HTML programming languages were used for the app interface, and the Firebase database was used for information storage. The app had an average overall usability score of 77.5 points (teachers), 93.8 points (students), and 104.5 points (IT).

Conclusion: The application demonstrated good usability and has potential for use in educational support. Future studies will be necessary to evaluate students' acquisition and retention of knowledge about wound assessment and treatment.

EP186 Rationalising education provision at an acute trust in the United Kingdom (UK)

Alexandra Bishop[1]

[1]University Hospitals Plymouth NHS Trust, Plymouth, United Kingdom

Aim: To outline the redesign of tissue viability (TV) education at a 1,000-bed acute hospital with ~12,000 staff and a 3.44 WTE TV team.

Method: An internal review was undertaken after identifying that the TV team delivered approximately 130 hours of education annually, with inconsistent coverage across clinical areas and frequent cancellations due to limited capacity. The review examined current training provision, referral patterns, and pressure ulcer (PU) incidence to determine the adequacy of existing education. Findings were used to co-develop a revised model with clinical educators, matrons, and senior leaders.

Results / Discussion: Several care groups were receiving minimal or no face-to-face teaching from a TV specialist, and the content and duration of sessions varied significantly between areas. During this period, referrals to the TV service increased—including cases that would not normally require specialist input—alongside a rise in PU incidence. These trends suggested that current education provision lacked reach, consistency, and effectiveness.

A new train-the-trainer model was introduced. A senior TV specialist now delivers a structured half-day session covering wound assessment, dressing selection, and PU prevention and care to clinical educators and ward/department managers. Standardised resources are provided to enable these leaders to deliver consistent, focused local training and support staff more confidently.

Feedback has been highly positive, highlighting the clarity, relevance, and opportunity for discussion. All attendees reported increased confidence in their TV knowledge and would recommend the training to colleagues.

Conclusion: Specialist-led education for all staff was not feasible. The train-the-trainer approach has created a scalable, standardised model that strengthens local capability. It is anticipated that this will lead to more appropriate referral patterns and a reduction in PU incidence.

EP435 Bridging knowledge gaps in skin tear management: Educational needs of senior nursing students in a multicenter study

Azize Ozdas Gundogan[1], Hatice Erdem Onder[2], Dilek Sari[3], Nihal Taskiran[4], Derya Uzelli[5]

[1]Afyonkarahisar Health Sciences University, Afyonkarahisar, Türkiye, *[2]Burdur Mehmet Akif Ersoy University, Burdur, Türkiye*, *[3]Ege University, İzmir, Türkiye*, *[4]Aydin Adnan Menderes University, Aydın, Türkiye*, *[5]Izmir Katip Celebi University, İzmir, Türkiye*

Aim: Maintaining skin integrity is a critical nursing responsibility, yet skin tears (STs) remain under recognized in practice. Despite their importance, undergraduate nursing curricula provide limited instruction on the prevention and management of STs. To assess senior nursing students' knowledge of STs, and identify educational and experiential factors influencing their competence.

Method: This multicenter cross-sectional study was conducted among 610 senior nursing students from four universities. Data were collected using the Student Information Form and the Turkish version of the Skin Tear Knowledge Assessment Instrument.

Results / Discussion: Students demonstrated moderate knowledge level (mean= 8.62±2.74; 50.7%). Higher scores were associated with female gender, elective wound care courses, and clinical exposure to ST cases ($p < .05$). Only 7% of respondents considered their knowledge sufficient, and 81% expressed a need for further training.

Conclusion: The findings highlight curriculum gaps in ST management, emphasizing the need for structured, competency-based education using simulation and case-based learning.

EP187 Student perceptions of digital learning tools in chronic wound education

Jelena Kevrić[1], Oliver Jurić[2]

[1]Secondary Medical School Ante Kuzmanic, Zadar, Croatia, *[2], Zadar, Croatia*

Aim: Digital educational resources are increasingly incorporated into wound-care teaching due to their accessibility and ability to present complex content in an engaging way. This study aimed to explore student satisfaction with digital learning materials related to chronic wound management and to examine how these materials complement the textbook *Chronic Wounds* used in teaching.

Method: A cross-sectional survey was conducted among fourth-year medical vocational students enrolled in the course *Chronic Wounds*. Data were collected through an anonymous questionnaire containing closed and open-ended items assessing clarity, usefulness, motivational value, and perceived impact on practical readiness. Students also evaluated the textbook regarding structure, readability, and relevance. The digital content included concise explanations, clinical photographs, and short instructional videos designed to support interactive, visually driven learning.

Results / Discussion: Students rated the digital resources as clear, engaging, and highly beneficial for understanding wound-healing processes and differentiating chronic wound types. Visual components substantially enhanced comprehension and confidence when preparing for practical exercises. The textbook was perceived as well-organized and informative, while the combined use of digital and written materials was viewed as the most effective learning strategy. Students recommended expanding video demonstrations and adding additional clinical cases.

Conclusion: Digital educational resources improve motivation, engagement, and conceptual understanding in wound-care education. Integrated with a well-structured textbook, they form an effective blended-learning approach that strengthens student preparedness for clinical practice.

EP189 "Entre Nós": An interdiciplinary decision making tool for complex wounds - from educational management to clinical pratice

Juliana Lucinda dos Santos[1], Lys Santos[2], Sergio Passio[3]

[1]Entre Nós, Santo André, Brazil, *[2]Alianca Medica Vascular Ltda, Rio de Janeiro, Brazil*, *[3]Wounds Thermography, Montevideo, Brazil*

Aim: The management of complex wounds requires accurate clinical decision-making and effective collaboration among health professionals. The digital tool Between Us was developed from the clinical experience of a Brazilian nurse and integrates practical knowledge with an educational strategy designed to strengthen interdisciplinary collaboration and continuous learning in wound care.

Objective: To describe the development, preliminary validation, and early implementation of the Between Us tool to support interdisciplinary decision making in complex wound management.

Method: This descriptive exploratory study adopted qualitative and quantitative approaches, including tool development, educational evaluation, and Delphi validation. The tool is organized into five pillars.

- Welcome focused on identifying educational needs and conducting a literature review addressing wound etiologies, advanced therapies, and decision-making models.
- Connect consisted of weekly international clinical meetings held over five months (80 hours) between professionals from Brazil and Angola during the COVID-19 pandemic, enabling interdisciplinary discussions on wound physiology and treatment decisions.
- Reflect included multidisciplinary educational groups involving nursing, nutrition, podiatry, and vascular surgery. A total of 180 health professionals participated in structured activities including pre-questionnaires, case discussions, literature review, and practical learning, followed by post-questionnaires to evaluate knowledge acquisition.
- Integrate involved the development of clinical algorithms and decision matrices validated through a two-round Delphi process with 12 interdisciplinary specialists (consensus ≥70%).
- Regenerate incorporated continuous feedback and content updates.

Results / Conclusion: Preliminary implementation indicates improved confidence in clinical decision-making and strengthened interdisciplinary collaboration, suggesting potential as an educational and clinical decision support framework for complex wound care.

EP190 The structural gaps in wound care: A national diagnosis of committee implementation in Portugal

Ondina Martins[1], Katia Furtado[2], Carlos Casaquinha[3], Pedro Gaspar[4]

[1]Infarmed, Lisboa, Portugal, *[2]Unidade Local de Saúde do Alto Alentejo, Comprehensive Health Research Center, CARE – Centro de Investigação em Saúde e Ciências Sociais, Portalegre, Portugal*, *[3]Sociedade Portuguesa de Feridas, Portalegre, Portugal*, *[4]Instituto Politécnico de Leiria, Leiria, Portugal*

Aim: Assess the national context regarding the establishment and operational status of Wound Prevention and Treatment Committees (WPTCs) within Portuguese healthcare institutions and propose a legal framework that formally legitimizes and regulates their functioning.

Method: A diagnostic instrument (questionnaire) was developed and administered across public and private healthcare facilities. The instrument focused on determining the committee's existence, organizational reporting structure, regulatory approval, core composition, allocated institutional time, and scope of activities, such as issuing guidelines and organizing training. A total of 34 responses were obtained.

Results / Discussion: Complex wounds account for a substantial clinical burden, yet the study confirmed organizational fragility: only 44% of responding institutions reported having a formal WPTC. Among the existing committees, most (87%) were appointed by the Board of Directors, and 66.6% possessed an approved internal

regulation. WPTCs function as multidisciplinary bodies, commonly integrating Nurses (95.83%), Physicians (87.50%), and Pharmacists (83.33%). Operational effectiveness appears high among those established: 91% organize relevant training, 87% deliberate on therapeutic options, and 83% issue guidelines. However, the significant non-existence rate (approximately 56% lacking institutional committees) underscores widespread structural implementation gaps.

Conclusion: These findings confirm a substantial gap in the formalization of WPTCs across Portuguese institutions. Since high-quality wound care relies on integrated team approaches, formal legal definition and institutional mandate are critical priorities. This measure would ensure the establishment of standardized local intervention models, ultimately improving prevention and treatment outcomes nationwide.

EP191 Closing the loop: A responsible artificial intelligence solution for evidence-based wound care decision support

Tania Santos[1], Lourdes Hidalgo[1], Kátia Furtado[1], Elaine Song[2], Catherine T. Milne[2], Tiffany Hamm[2], Jeffrey Mize[2]

[1]ELCOS, Sociedade Portuguesa de Feridas, Arronches, Portugal, *[2]Wound Reference, Inc, San Francisco, United States*

Aim: Clinicians encounter average of 11 clinical questions daily, most of which remain unanswered. While artificial intelligence (AI) holds promise, unconstrained generative AI for diagnoses or treatment plans presents significant risks of patient harm and malpractice liability. In typical clinical decision-making, AI achieves an accuracy of only ~52%, frequently failing to identify life-threatening conditions.

To mitigate these risks and provide reliable, evidence-based answers in wound care, we aimed to develop a responsible, AI-powered, point-of-care clinical intelligence solution leveraging a Portuguese wound care society's digital clinical pathway.

Method: Using Design Thinking, the solution was developed as a module within a decision support platform.

One year after the society turned their printed pocket guide library into a comprehensive, multi-media digital clinical pathways library, an evaluation revealed that while 86% of members found the pathways helpful, access was cumbersome.

To solve these issues, a proprietary closed-loop AI model was utilized to retrieve, aggregate, and generate answers strictly from the Society's interactive digital pathway library.

User feedback optimized the interface across multiple iterations.

Results / Discussion: The resulting mobile-responsive module successfully leverages AI-powered search and generative answers that are vetted, evidence-based, and reliable. Members can instantly find trusted answers, linked back to the peer-reviewed pathways. Unlike open-AI models, this closed-loop solution effectively curbs hallucinations, providing only referenced and society-vetted answers. Additionally, the platform can optionally collect de-identified pathway data to generate insights on cost-effective interventions for your population.

Conclusion: A responsible AI-powered clinical intelligence solution for wound care was successfully developed, with the potential to significantly enhance point-of-care decision-making for society's members. Generative AI should supplement - not replace - human judgment, requiring responsible use and robust oversight.

EP192 Experience and perceptions of healthcare professionals regarding the use of OSCE for the assessment of clinical skills: A mixed-method study

Elisa Spaziani[1], Angela Peghetti[1], Stefano Durante[1], Giuseppe Iacobacci[1], Manuela De Rosa[1], Carlotta Zanetti[1], Carmela Martella[1], Tiziana Greco[1], Annalisa Andrei[1], Silvio Quirini[1]

[1]Professional Development and Implementation of Research in Health Professions Unit, IRCCS Azienda Ospedaliero-Universitaria di Bologna, Bologna, Italy

Aim: The training of healthcare professionals is essential for enhancing clinical skills. The use of simulated contexts facilitates learning and professional confidence. The Objective Structured Clinical Examination (OSCE) is described as a structured and objective method that enables the evaluation of a professional's technical, cognitive, and relational skills. Debriefing is a key phase of simulation where participants receive feedback regarding the quality of the simulation. The implementation of the OSCE within corporate training programmes would help strengthen the value of continuing professional development in healthcare.

This study aims to assess healthcare professionals' perceptions of using OSCE to evaluate clinical skills in advanced wound management after a corporate training course.

Method: The study design is a mixed-method convergent triangulation approach. The study sample included 24 Wound Care representatives who attended a 34-hour blended course (3.5 hours in the classroom, 30 hours of self-learning, 0.5 hours of OSCE assessment). Data collection and analysis follow independent yet integrated phases to ensure interpretive depth. The Debriefing Assessment for Simulation in Healthcare (DASH) scale has been used in the quantitative phase to assess participants' perceptions of the quality of the post-simulation debriefing. Semi-structured interviews have been conducted to explore satisfaction, challenges, weaknesses, and strengths.

Results / Discussion: The scores obtained from the DASH scale and the information gathered during the interviews provided insights on the OSCE. The use of the OSCE enables the hospital trust and the healthcare professional benefit in terms of clinical safety and reflective self-learning. Furthermore, any critical issues will be used to improve the training pathway.

Conclusion: Integrating the OSCE into corporate training programmes will help strengthen clinical reasoning among healthcare professionals.

EP436 Skin tear model for reapproximation training

Tanvir Siddique[1], Haja Muhamad[1], Alan Smith[1], Jessica Senior[1]

[1]University of Huddersfield, Huddersfield, United Kingdom

Aim: Skin tears (ST) are common partial or full separation skin wounds found prevalently in elderly patients because of their fragile skin due to abrasion (1). Currently, there is limited assessment awareness and practice equipment, leading to inconsistent management approaches (2). Here, we have developed a polymer-based, sustainable, and cruelty free ST model, which allows practical reapproximation training to improve quality of care.

Methods: ST models were made by tailoring natural polymers that have mechanical properties comparable to human skin. Relative layers resembling fragile epidermis, and weaker dermis were formulated and characterized and the representation of type I, II and III tears were established based on clinician input, also featuring a range of skin tones. Further polymers were then used in specific concentration to mimic subcutaneous layers which was loosely adhered to the skin. Uneven texture and easily disrupted dermal-epidermal junction of the ST model were relevant to clinical practice, involving ST assessment, creation of different tears, cleansing, or debriding necrotic flap if required, and wound edge reapproximation.

Results: Mechanical testing was undertaken to match the mechanical strength which was sufficient to mimic the frail nature of elderly skin. Feedback was provided from multiple sources, including tissue viability specialists, dermatologists, and podiatrists, and models have since been integrated into teaching resources at multiple academic institutions, healthcare trusts and businesses worldwide.

Conclusion: All 3 types of skin tears defined by recognised governing bodies and educational outlets have allowed the practiced of skin tears reapproximation using our ST models. This research offers a low-cost, realistic educational tool to enhance clinical training in skin tear assessment and management, leading to improved patient outcomes and reduced wound care burdens.

EP193 Developing interactive wound models for healthcare training and education

Jessica Senior[1], Karen Ousey[2], Leanne Atkin[3], Samantha Holloway[4], Alan Smith[1]

[1]Institute of Skin Integrity and Infection Prevention, University of Huddersfield, United Kingdom, *[2]Omniamed Communications, London, United Kingdom*, *[3]Mid Yorks NHS Trust, Mid Yorks, United Kingdom*, *[4]University of Cardiff, Cardiff, United Kingdom*

Aim: Our research aims to generate a range of true-to-life wound models to allow trainee healthcare professionals to practice necessary wound preparation techniques before facing patients in the clinic. These interactive wound simulations intend to look, feel and behave more realistically compared to current training resources such as cadavers, pigs' feet and fruit peel, and are more accessible, ethical, and cost-effective.

Method: A multidisciplinary team was formed comprising vascular nurse consultants, tissue viability nurses and tissue engineers towards generating different wound models. Chronic wounds were engineered using sustainable biomaterials in a range of skin tones, representing a wound void complete with underlying healthy granulation tissue, slough, exudate and debridable necrosis, as seen in patients in the clinic (Figure 1a). Skin tears type I, II and III were developed to allow skin reapproximation training and treatment (Figure 1b), the mechanical properties of the models were matched to those of skin wounds, and a panel of 20 wound care experts and their trainees were asked to provide critical feedback on model suitability.

Results / Discussion: Using feedback from institutions, trusts and businesses to enhance our wound models, our simulation training aids receive excellent feedback on their realism and functionality, and they are now being utilized in high demand in sharp debridement courses, conference workshops and wound care product demonstrations. Most importantly, our end users have described the models as an "excellent learning tool", a "very useful simulation aid", and commented "how things have improved from using oranges".

Conclusion: Providing realistic training opportunities holds potential in contributing to a more skilled and confident wound care workforce, subsequently reducing wound healing timelines and ultimately leading to improved patient outcomes.

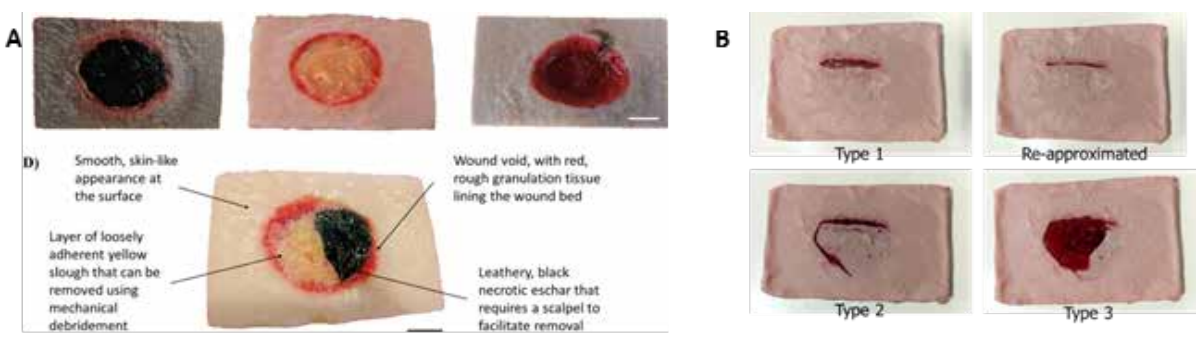

Figure 1 – Interactive wound models as training tools including A) chronic wounds in various skin tones and B) skin tears type 1, 2 and 3

EP194 Empowering healthcare professionals through education: Antimicrobial resistance and technology integration

Natalia Barros[1], Fabiana Oliveira[1], Jessica Morato[1], Jessica Dantas[1], Alessandra Miranda Garcia Storti[1], Mariana Ferreira[1]

[1]Essity do Brasil, São Paulo, Brazil

Aim: To present the results of an educational and scientific project aimed at healthcare professionals from public and private institutions in Brazil, focusing on the prevention and management of antimicrobial resistance (AMR) and the integration of innovative technologies, based on EWMA and JWC Guidelines.

Method: This is a scientific initiative promoted by the industry, consisting of 17 theoretical and practical modules covering all topics addressed in international AMR consensus guidelines. The training sessions were conducted between January and November 2025, involving professionals from different regions of Brazil. Activities included in-person workshops, online classes, case studies, scientific discussions, and simulated practices, with knowledge assessment before and after each module

Results / Discussion: More than 1,000 professionals were trained, with an average increase of 80% in knowledge about AMR and biophysical technologies, according to pre- and post-training evaluations. High adherence to practices recommended in the guidelines was observed, including strategies for reducing microbial load and preventing healthcare-associated infections. The integration of theory and practice contributed to greater clinical safety and standardization of protocols in participating institutions.

Conclusion: The implementation of educational programs based on international guidelines proved effective in expanding knowledge and promoting changes in clinical practice, strengthening the prevention of antimicrobial resistance and encouraging the use of innovative technologies in care. This scientific initiative reinforces the role of the industry as a partner in continuing education and in improving healthcare outcomes

---

EP195 Patient and caregiver perceptions of discharge instructions for postoperative wound care: A prospective study

Lima Priscila[1], Baccas Samantha[1], Nascimento Márcia[1], Cazado Fabiane[1]

[1]AACD, São Paulo, Brazil

Aim: To evaluate patient and caregiver understanding of postoperative wound-care instructions at hospital discharge, their confidence in performing home wound care, the professionals involved in health education, and the timing at which education was provided.

Method: This prospective quantitative study included patients who had undergone corrective surgery for neuromuscular scoliosis. Eligible participants had received standardized discharge instructions and were able to complete a telephone interview; for individuals under 18 years of age or with cognitive impairment, the caregiver was interviewed. Exclusion criteria included transfer to another service, prolonged hospitalization (>15 days), surgical reintervention, or absence of standardized discharge education. Data collection consisted of chart review, structured pre-discharge education delivered by the nursing team, and follow-up interviews conducted between postoperative days 10 and 15. Data were organized in anonymized spreadsheets and submitted to statistical analysis.

Results / Discussion: A total of 59 participants were included, with a mean age of 14.7 years; cerebral palsy was the most prevalent diagnosis (59.3%). All participants reported having understood the wound-care instructions, and 98.3% felt confident performing dressing changes and wound hygiene. Nursing professionals provided most of the education (93.2%). Although comprehension rates were high, 44.1% experienced minor postoperative complications at home, primarily exudate and mild dehiscence. No cases of surgical site infection or readmission were identified. These findings indicated that structured discharge education supported safe home wound management, even within a clinically complex neuromuscular population.

Conclusion: The study demonstrated that structured, nurse-led educational strategies enhanced caregiver preparedness and contributed to the prevention of severe postoperative wound complications. The results highlight the importance of standardized discharge education to promote safety, autonomy, and continuity of care after hospitalization.

EP196 The influence of digital communication and marketing by a Brazilian specialist society on the expansion of stomaltherapy: A five-year overview

Suzana Aparecida da Costa Ferreira[1 2], Adriane Aparecida Faresin[1 2], Ivan Rogerio Antunes[1], Sonia Dantas[1], Viviane Helena[1], Vera Lucia Conceição Gouveia Santos[1 2]

[1]Brazilian Association of Stomatherapy (SOBEST), São Paulo, Brazil, *[2]School of Nursing, University of São Paulo (EEUSP), São Paulo, Brazil*

Aim: Scientific associations emerged to strengthen professional contact and knowledge exchange, emphasizing their role in stimulating and disseminating scientific knowledge. In Brazil, there are 4,148 stomal therapists. The Communication and Marketing Department (DECOM), composed of five enterostomal therapists, reports to the society's board and develops strategies to disseminate stomal therapy ethically and effectively nationwide. Digital media have become prominent in spreading scientific knowledge and supporting the teaching–learning process. The society has 18 regional sections of stomal therapy nurses, and DECOM supports the dissemination of their activities. Understanding how these communication strategies are implemented is essential to assess their contribution to professional development and nationwide knowledge dissemination. Therefore, this study aims to report DECOM's experience in disseminating scientific activities nationally to nursing professionals.

Method: Descriptive study conducted from January 2021 to December 2025 on DECOM's actions in managing national scientific dissemination through the institutional website and social media. Organization, sharing, creation, and data extraction were carried out using digital tools such as Excel®, Word®, PowerPoint®, and Canva®, with board authorization.

Results / Discussion: A total of 1,642 publications were produced on the website and disseminated through social media, averaging 328.4 publications per year. Instagram reached 46.5 thousand followers, with a 612.28% increase in publication reach. Facebook, with 19,000 followers, showed a 66.75% increase in page views. On LinkedIn, 3,175 followers and 1,642 publications were recorded.

Conclusion: The growth in access and followers across social media demonstrates the effectiveness of the society's dissemination efforts, indicating opportunities to expand educational content through new digital strategies.

EP197 Low duration, long-lasting impact: validating intensive courses to build local wound care expertise in low-resource regions

Alvise Montanari[1], James Nduati Ngoyo[2], Franco Bassetto[1]

[1]University of Padua - Department of Neuroscience - Unit of Plastic Surgery, Padova, Italy, *[2]Diabetes Foot Foundation Kenya, Nairobi, Kenya*

Aim: In low-income countries, chronic ulcers are a growing challenge for local healthcare providers. Due to the shortage of physicians in rural areas, nursing staff are primarily responsible for managing even the most complex cases. Furthermore, when volunteer surgical missions perform high-complexity reconstructive surgery on these patients, the procedures are often not followed by adequate postoperative management. How can proper theoretical and practical training be provided to local personnel?

Method: In April 2024, our team organized a pilot intensive wound care course for nursing staff and students at a rural hospital in Kenya. A second edition followed it in 2025.

Results / Discussion: The four-day course was structured into a theoretical part and a practical one. The theoretical portion, led by an international faculty team—partly in person and others remotely via Zoom—covered topics from the anatomy and pathophysiology of common wounds and chronic ulcers to diagnostic and management protocols, culminating in the use of advanced wound care dressings. In the afternoons, hands-on practical sessions were held under the guidance of tutors in outpatient clinics and operating rooms. Pre- and post-course tests were administered to quantify the benefit of the training. The results were validated by a follow-up quiz six months later. The initial quiz scored only 30% of correct answers; the ratio grew to 95% at the end of the course and remained at 85% at the six-month follow-up.

Conclusion: Short, intensive courses have proven to be a valuable tool for training local nursing staff in rural areas of low-income countries in advanced wound management techniques and the use of advanced dressings.

EP198 Eksodos - migrant population access to wound/health care

Elisabete Saunite[1]

[1]*ELCOS - Sociedade de Feridas Portuguesa, ULS Algarve - Unidade Local de Saúde Algarve, Lagos, Portugal*

Aim: Eksodos aims to promote access to wound/health care for migrant populations identifying the health professional difficulties attending this population.

Method: Eksodos followed the qualitative study methodology proposed by the Joanna Briggs Institute, searches were conducted in scientific databases (MEDLINE/PubMed, Cochrane, Ebsco) and grey literature (RCAAP, Google scholar) including studies focusing migrants, health/wound care access and health professionals. The development of the study progressed in a Health Local Unit, whose study population included nurses, doctors, and clinical secretaries. The semi-structured interview was chosen for data collection.

Results / Discussion: The results identify communication as the main difficulty expressed by all the health professionals due to the immense variety of languages they face daily. This outcome is consistent with those obtained by other authors, demonstrating that communication difficulty is the main obstacle to be overcome by health professionals and a barrier bounding migrant population access to wound/health care.

Conclusion: It is evident that language diversity represents one of the greatest obstacles to migrants' access to wound/health care. The global migration determines the host country to develop strategies to include and integrate migrants, adhering to the international guidelines of the United Nations and stipulated in the Charter of Human Rights, on behalf of the legally protected right of accessibility to healthcare. To address the needs identified by health professionals, interdisciplinary and interinstitutional activities were implemented in close collaboration with the community which include the provision of translation devices to healthcare units for regular and daily use, communicational techniques courses for health professionals, and documents prepared in various languages to facilitate migrants' access to health services. Eksodos is an ongoing community intervention empowering health professional's migrant population assessment.

EP199 Validation of assistive technology for the prevention of MARSI in adults and elderly

Adrieli Oliveira[1], Paula Freitas[2], Natalia Barros[3], Márcia Freire[4]

[1]*Hospital Zilda Arns, Curitiba, Brazil*, [2]*Universidade Federal do Espirito Santo, Espirito Santo, Brazil*, [3]*Essity Brasil, São Paulo, Brazil*, [4]*Universidade Federal do Paraná, Curitiba, Brazil*

Aim: This is a technical production aimed at addressing an existing gap in skin care for hospitalized adults and elderly patients: Medical Adhesive-Related Skin Injuries (MARSI). To validate an educational booklet for nurses focused on MARSI prevention in a reference hospital for elderly care.

Method: The content validation of the booklet took place in July 2025 with nurse evaluators who have expertise in the field, including stomatherapists and dermatology specialists. The analysis of results was based on the Content Validity Index (CVI). The study was approved by the Research Ethics Committee (CAAE: 88516525.3.0000.0102).

Results / Discussion: An online form using a Likert scale for agreement and importance was applied. The form used for booklet validation achieved an overall CVI of 0.97, indicating content validity. The e-book was updated according to the evaluators' suggestions, which were accepted. The technical product was educational, produced, validated by experts, and finalized. The booklet consists of nine chapters covering topics from skin structure to adhesive selection techniques, application, and removal. An interactive product was chosen, including QR codes to access explanatory videos on the topic.

Conclusion: After validation by the evaluators, adaptations were made according to the relevance analysis. Thus, a technical product for MARSI prevention was developed. It is scientifically up-to-date and has potential and consistency to disseminate the best information, indicating updated care practices to be implemented by healthcare teams in institutions. The goal is to maintain skin integrity, prioritizing preventive care for MARSI lesions.

EP200 Evaluating the Scott Triggers risk assessment tool

Lisa Peterson[1], Julie Chou[1], Jeffrey Fine[1], Yukari Oshiro[1], Sarina Fazio[1]

[1]*UC Davis Health, Sacramento, United States*

Aim: This study aims to evaluate the sensitivity and specificity of the Scott Triggers risk assessment tool to correctly identify an adult's risk of intraoperative pressure injury.

Method: We conducted a retrospective cohort study to identify the diagnostic accuracy of two versions of the Scott Triggers tool to predict development of intraoperative pressure injury. We extracted data of all patients who underwent surgery at an academic medical center between 2021-2023. The ST tool uses x variables to identify risk where body mass index (BMI) is used if serum albumin values are unavailable. ST scores were generated for each patient retrospectively and sensitivity and specificity was calculated.

Results / Discussion: A total of 13,495 patients were included in the cohort, X (%) of whom developed an intraoperative pressure injury. The sensitivity and specificity of the ST tool using BMI was 77.9% and 42.3%, compared to the sensitivity and specificity of the ST tool using the serum albumin sensitivity and specificity (78.9% and 18.4%).

Conclusion: The Scott Triggers tool using a BMI is slightly less sensitive but more specific than using serum albumin. Utilizing this risk assessment tool for surgical patients with BMI instead of serum alumin is more likely to identify patient's risk of an intraoperative pressure injury.

EP202 Wound dressing biocompatibility: Extracts from the future

Laura Ocego[1], Carlo Di Iulio[2], Leah Williams[2]

[1]*Convatec, Lexington, United Kingdom*, [2]*Convatec, Lexington, United States*

Aim: Many biocompatibility studies and requirements are often geared towards well known materials or long-term devices such as implants where minimal challenge occurs when extracted. Polymeric material extraction can prove challenging as significant swelling, degradation and change can occur, which can lead to an extractables profile that is not clinically relevant (i.e., due to device and method incompatibility).

Method: A novel fixtures method holds future promise for challenging materials such as hydrogels and soft polymers, generating extracts what are representative of an exaggerated patient chemical exposure profile for biological testing and toxicological risk assessment, while avoiding compromising the device in ways not seen under clinical use.

Results / Discussion: Device degradation was significantly minimized while physical destruction of the test articles was eliminated when compared with generating extracts using traditional extraction methods. Given the orientation of the dressing within the fixture, the extraction solvent only contacts the dressing from the wound contacting side whilst also allowing for full saturation within the layers; the nature of this solvent contact more accurately represents the worst-case patient exposure seen in a clinical settings.

Conclusion: The results presented here demonstrate that device integrity is maintained when extracting using a fixture when compared to using a polybag; also, the number of particulates was significantly reduced as demonstrated through visual observation and NVR analysis. Studies on the chemical profiling of extracts have also shown similar chemical profiles with a reduction in foreign body and degradants. Initial *in vivo* studies, which have historically failed from traditional 10993-12 extractions, have determined the possibility of generating extracts compatible for use with this testing.

E-HEALTH

EP437 Digital transformation in wound care: "Conexões que Curam", a user-centered digital health ecosystem to strengthen skin health and wound-care practice

Dioney Neves[1], Camila Safranski[1]

[1]*Missner, Blumenau, Brazil*

Aim: To present the structure and purpose of *Conexões que Curam*, a Brazilian digital health ecosystem dedicated to skin health and wound care. Developed to reduce knowledge gaps, expand access to high-quality information, and minimize fragmentation of educational resources, the platform integrates scientific evidence, clinical tools, professional interaction, and curated learning within a single digital environment**.**

Method: The ecosystem was created through a multidisciplinary and human-centered design process involving nurses, UX designers, marketing specialists, and analytics professionals. Its conception was driven by user experience insights, professional profiles, and unmet needs identified in the Brazilian wound-care landscape. Beyond its core pillars—Skin, Technology, and Science—the platform offers a logged-in area where professionals can connect, participate in forums, access video classes, and share clinical cases. Additional components include a catalog of scientific journals with descriptions, submission guidelines, fees, and deadlines; and a dedicated section highlighting global scientific societies active in dermatology, skin integrity, and wound healing. The platform also provides decision-support tools, research summaries, guidelines, and accessible learning pathways for users who may struggle to locate or interpret scientific literature.

Results / Discussion: Early observations indicate that the ecosystem reduces information fragmentation and improves access to reliable, evidence-based content. By integrating scientific updates, community interaction, and practical tools, the platform has the potential to strengthen clinical reasoning, support standardization of care, and foster scientific engagement.

Conclusion: *Conexões que Curam* represents an innovative and comprehensive e-Health initiative in Brazil, advancing wound-care education, clinical decision-making, scientific literacy, and professional connectivity across the skin-health community.

EP203 User experience on a randomized controlled trial with a clinical decision support system for chronic wound management in primary care

Diana Herrera-Valenzuela[1]

[1]*Centro Tecnolóxico de Telecomunicacións de Galicia - Gradiant, Vigo, Spain*

Aim: To assess user experience during a randomized controlled trial (RCT) of a clinical decision support system (CDSS) for selecting products for local treatment of healable chronic wounds.

Method: A RCT was conducted in 18 primary care facilities: 12 in the experimental group and 6 in the control group. Over 7 months, nurses recruited patients and followed wound evolution. Perceived effort was assessed at study initiation, midterm, and final using NASA-TLX; the experimental group also evaluated CDSS usability with the System Usability Scale (SUS).

Results / Discussion: Seventy-three patients with 107 wounds were included. Fifty-seven nurses participated, 33 using the CDSS. Effort evaluation was completed by 31 participants at study initiation (54.4%), 39 midterm (68.4%), and 33 final (57.9%). Across all assessments, the control group reported higher workload in five dimensions (physical, mental, time, effort, frustration), while performance scores were similar. Usability was assessed by 17 participants at study initiation (51.5%), 23 midterm (69.7%), and 21 final (63.6%). SUS scores showed no significant differences ($p=0.69$) but increased from 73.13±23.59 (midterm) and 74.41±17.56 (baseline) to 78.21±17.48 (final).

Conclusion: The CDSS demonstrated good usability throughout the study, with SUS scores consistently above the 68-point threshold. A learning curve was seen, as usability improved after five months of use. Compared to current practice, CDSS use reduced perceived mental, physical, time, effort, and frustration workload when making decisions on local treatment for healable chronic wounds.

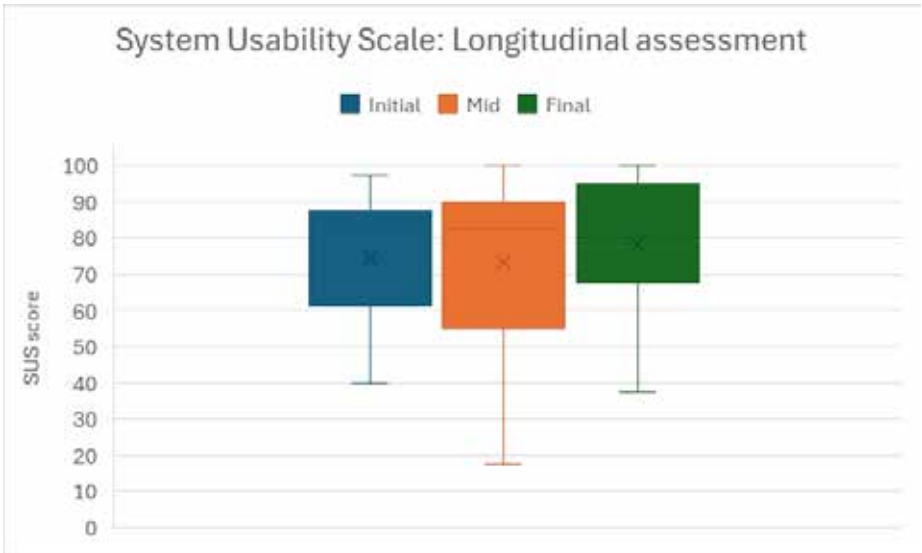

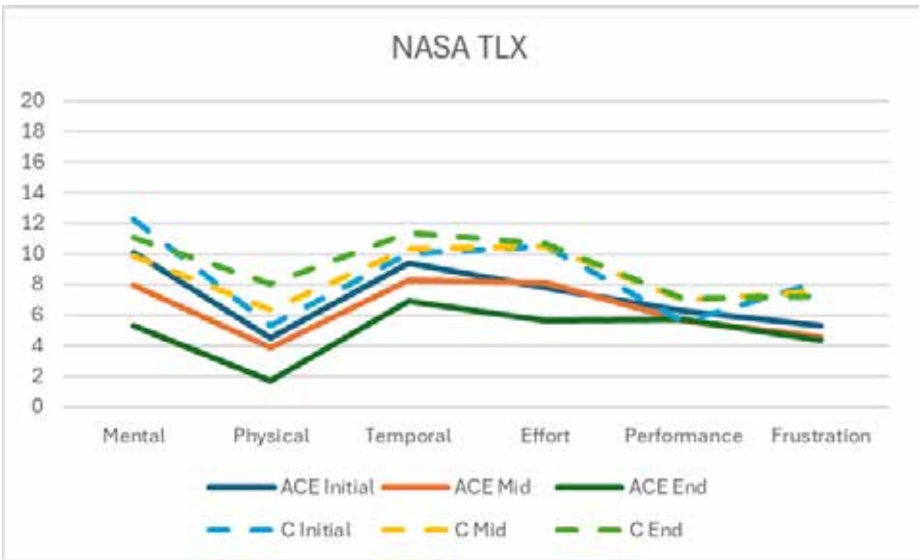

EP204 Hospital–community communication in chronic ulcers: Barriers, patient experience, and the role of digital platforms

Serena Corraro[1], Alessandra Michelucci[2], Bianca Cei[2], Antonella Vietina[2], Angelo Capodici[3], Agata Janowska[2], Marco Romanelli[2], Valentina Dini[2]

[1]University of Pisa, Dermatology department, Pisa, Italy, *[2]University of Pisa, Department of Dermatology, Sant'Anna School of Advanced Study, Interdisciplinary Center of Health Science, PISA, Italy*, *[3]Sant'Anna School of Advanced Study, Interdisciplinary Center of Health Science, Pisa, Italy*

Aim: To assess communication gaps between hospital- and community-based wound care services and to explore patient-reported needs, experiences, and perceptions regarding continuity of care in chronic lower-limb ulcers.

Method: Two complementary cross-sectional surveys were administered:

(1) 20 healthcare professionals (25% physicians, 75% nurses) from hospital and community settings; (2) 20 patients with chronic lower-limb ulcers.

Professional data explored communication effectiveness, barriers, and the perceived usefulness of shared digital tools. Patient data included demographics, ulcer duration, access issues, perceived understanding, continuity of care, and satisfaction. Quantitative variables were summarized descriptively; qualitative responses underwent thematic analysis.

Results / Discussion: Professionals rated hospital–territory communication as moderate (mean 3.9/5), with lower adequacy of community follow-up (3.05/5). Reported barriers included lack of a unified contact person, limited shared platforms, and difficulties transferring images or clinical data. The usefulness of image sharing (4.6/5) and a dedicated digital platform (4.75/5) was considered very high.

The 20 patients were predominantly older adults, mostly over 75 years, with balanced sex distribution. Most reported ulcer durations exceeding one year. Access challenges—especially waiting times, booking difficulties, and limited communication with the general practitioner—were frequently noted. Despite this, patients rated understanding of their condition positively (around 4/5) and expressed high satisfaction with care. Qualitative comments highlighted fragmented pathways, insufficient follow-up, and unclear instructions for home management, reflecting professionals' concerns.

The combined analysis shows clear convergence: both groups describe communication gaps and fragmented care, reinforcing the need for interoperable digital tools.

Conclusion: Both surveys reveal substantial discontinuity in chronic ulcer care. A shared digital platform enabling secure image exchange, standardized documentation, and timely communication may strengthen coordination, improve patient experience, and increase overall care efficiency.

EP205 Multimodal artificial intelligence for diabetic foot ulcer assessment and management

Tohid Amadeh[1], Ali Amadeh[2], Negin Mohebbi[2], Negin Chakoshkar[2], Amirreza Jamshidbeigi[3], Alireza Azarparand[1], Mohammad Zolfaghari[2]

[1]Department of Computer Science, Azad University of Karaj, Karaj, Iran, Karaj, Iran, *[2]Department of Nursing, School of Nursing and Midwifery, Karaj Branch, Islamic Azad University, Karaj, Iran, Karaj, Iran*, *[3]Department of Medical-Surgical Nursing, Faculty of Nursing and Midwifery, Mashhad University of Medical Sciences, Mashhad, Iran, Mashhad, Iran*

Aim: To evaluate the performance of a multimodal artificial intelligence (AI) system designed to analyze foot-ulcer characteristics and generate structured, guideline-aligned management recommendations by integrating image analysis, clinical metadata and rule-based decision logic.

Method: A retrospective dataset of 2000 de-identified foot-ulcer cases located distal to the ankle was collected over two years. Each record contained a wound photograph and structured clinical inputs describing location, tissue type, exudate, infection indicators, perfusion status, callus, suspected Charcot changes and bone or tendon exposure. Informed consent for use of images had been obtained. Wound-care specialists annotated ulcer etiology (neuropathic, ischemic, neuroischemic or mixed) and recommended management plans. A multimodal vision-language model based on a transformer architecture (LLaMA-Vision) was fine-tuned using combined image and metadata inputs. The system produced etiology classification, depth and infection/ischaemia indicators required for Texas wound staging, and recommendations for debridement technique, primary and secondary dressing selection, complementary therapies and referral thresholds. A rule-based layer reflecting established clinical decision pathways was applied to refine outputs. Model performance was evaluated using an independent 400-case test set.

Results / Discussion: Overall accuracy was 87.6%. Agreement with expert clinicians was 98% for referral need and 98% for secondary dressing selection. Accuracy reached 95.5% for wound-edge assessment, 90.9% for tissue-type identification and 86.4% for osteomyelitis-risk estimation. Performance for primary dressing (81.8%), debridement type (77.3%) and complementary therapies (72.7%) was moderate. The system reliably detected infection, ischaemic signs and deep-structure exposure, and rule-based logic reduced clinically inconsistent outputs.

Conclusion: The multimodal system showed clinically meaningful performance in characterizing ulcer features and supporting guideline-concordant management decisions, highlighting its potential as a decision-support tool in routine foot-ulcer assessment.

EP206 Teaching chronic wound management in german medical skills labs - first steps towards a structured framework

Inga Sellmann[1], Prof. Cornelia Erfurt-Berge[2]

[1]SkillsLab des Universitätsklinikums Essen, FAU Erlangen, Essen, Germany, *[2]Uniklinik Erlangen, FAU Erlangen, Hautklinik, Erlangen, Germany*

Aim: Chronic wounds represent a frequent and complex clinical problem, yet structured teaching on wound management is inconsistently integrated into undergraduate medical education in Germany. In contrast to acute wound care, the current status of teaching about chronic wound management remains unclear. As medical skills labs play a central role in teaching practical competencies, this study aimed to assess the current teaching landscape of chronic wound management within German medical skills labs.

Methods: Following an inter-university pilot workshop with representatives from six German medical skills labs in 2025, a structured online questionnaire was developed. The survey assessed the existence of teaching formats for chronic wound management, their organizational setting, and general course characteristics. Specific questions were also asked about challenges during implementation. At the time of analysis, responses from 25 medical skills labs across Germany were available and included in this evaluation.

Results: Of the 25 participating skills labs,12 reported that no specific teaching on chronic wound management is currently offered. One additional site started initial plans for a course. Twelve skills labs provide wound-specific teaching with eight of them integrated into the curriculum, while four offer non-curricular courses. The courses show similarities regarding core content, tutor numbers, group sizes, and frequency per semester. All are based on peer-teaching, while participants are partially multiprofessional in two of the courses. The main obstacles cited were financial resources and a lack of specialist expertise.

Conclusion / Outlook: This pilot survey demonstrates substantial heterogeneity and gaps in the teaching of chronic wound management within German skills labs. Based on these findings, qualitative interviews with skills lab tutors and the development of a structured, transferable course framework are planned.

EP207 Rethinking clinical trial design workflow in wound care: a domain-specialized AI approach

Michal Lazniewski[1], Markus Rothmaier[2], Bithi Chatterjee[2], Itai Frenkel[2], Rafal Powalski[1], Remigiusz Kinas[1], Jan Topinski[1], Ran Frenkel[2], Tomasz Jetka[1]

[1]Ingenix.AI, Warsaw, Poland, *[2]Polaroid Therapeutics AG, Schlieren, Switzerland*

Aim: Clinical trial design remains time-consuming, low-yield, and insufficiently supported by current technologies. Existing trial-focused models are narrow and task-specific, while generalist Large Language Models (LLMs) struggle with extended reasoning and may hallucinate plausible, yet incorrect content, an unacceptable limitation for critical trial planning and risk assessment. To address this, we developed a domain-specialized AI system designed to support researchers in clinical development and generate traceable, scientifically coherent hypotheses or study design.

Method: Our reasoning AI utilizes a multi-agent architecture, in which specialized agents retrieve and synthesize information from product development documentation, publications, patents or regulatory resources. The system is trained on expert-guided scenarios to orchestrate agents' actions and enable structured, transparent reasoning. This domain-focus training allows iterative output refinement and produces end-to-end proposals for a clinical trial plan with full traceability, providing a foundation for study design.

Results / Discussion: We evaluated the AI capabilities on a research case. Our test case involved designing a clinical study plan for a quaternary polyethyleneimine-based wound dressing. Key sections of the protocol were proposed using the AI system and compared with general-purpose LLMs. The system produced more complete and appropriate proposals, offered clearer reasoning and highlighted facts that supported a more robust study concept.

The results were proposed to be incorporated by Polaroid Therapeutics into a clinical study plan, illustrating how such systems accelerate and strengthen early conceptualization of clinical trials.

Conclusion: This AI platform demonstrates how a trial-aware, domain-specialized multi-agent AI can enhance planning of clinical trials when given access to relevant knowledge. Moreover, such systems can support teams to rethink early development, reduce uncertainty, and accelerate product certification, ultimately improving patients' life quality.

EP208 Teccurar: Designing a socio-environmental impact digital platform for wound care education and decision support in a middle-income country

Melissa Moraes Silva[1 2], Luisa Ciucci Biagioni[1], Francisleny Vieira[1], Veronica Valentim[1 3], Marcela Vieira[1 3], Carlos Henrique Pereira Mello[4], Matheus Brendon Francisco[4]

[1]TecCurar, HCITec, Itajubá, Brazil, *[2]HCITec, Itajubá, Brazil*, *[3]IVES, Itajubá, Brazil*, *[4]Unifei, Itajubá, Brazil*

Aim: To describe the development of a clinician-led digital platform for wound care education and decision support at technology readiness level (TRL) 2 in a middle-income country, and to identify main challenges and enablers.

Methods: We performed a formative study over 12 months combining design workshops with wound care clinicians, review of guidelines and digital tools, and outputs from an ideation programme, incubator and internationalisation pathway. Requirements were defined for three components: adaptive learning pathways with active methodologies and gamification; a structured wound registry with image capture and clinical–economic data; and dashboards linking outcomes to resource use and socio-environmental indicators. Perceived technical, regulatory, organisational and impact-measurement barriers were documented prospectively.

Results: The process generated a conceptual architecture integrating case-based educational tracks for multiple professional profiles, digital wound records for primary and specialised care, and management views to monitor healing, prevent complications and support appropriate use of resources. The socio-environmental model focused on reducing preventable amputations and hospital admissions, optimising dressing and resource use, and minimising avoidable patient travel. Major early challenges were translating clinical protocols into feasible digital workflows; limited experience with software architecture, interoperability and data protection; defining clinical, economic and environmental indicators; and identifying sustainable business models without diluting the impact mission. Enablers included collaboration between clinicians and technical partners, entrepreneurship training, mentoring and institutional support for clinical validation.

Conclusions: A clinical team can initiate a socio-environmental digital platform for wound care at low technology readiness level but must navigate substantial technical, regulatory and business-model uncertainties. Integrating clinical, economic and environmental outcomes from the outset may help align digital wound care innovation with value-based and sustainable care.

HEALTH ECONOMICS & OUTCOME

EP210 Transforming access to advanced wound care: Payment strategies and systemic challenges in outpatient services – a scoping review

María Luisa Cortés Barría[1], Carlos Pinto Candia[2]

[1]ConvaCare Clinics, Santiago, Chile, *[2]Instituto de Salud Pública Universidad Andres Bello, Santiago, Chile*

Aim: Chronic wounds impose a significant yet underestimated global burden, consuming 2–5% of national health budgets and presenting mortality rates comparable to cancer. Despite this impact, research and policy investment remain disproportionately low. This review aimed to identify prevalent payment mechanisms for outpatient advanced wound care and assess implications for cost-effectiveness, coverage, and access.

Method: A scoping review was conducted following Joanna Briggs Institute guidelines. Literature from PubMed, ScienceDirect, and grey sources was screened using PCC strategy (Population: adults; Concept: payment and reimbursement mechanisms; Context: outpatient advanced wound care). Forty-seven publications were included, covering North America, Europe, Oceania, Asia, and Latin America.

Results / Discussion: Payment models show marked heterogeneity across regions.

- U.S.: Transitioning from fee-for-service to value-based healthcare (VBHC), introducing bundled payments and quality-linked incentives to improve outcomes and reduce costs.
- Europe: Reimbursement for dressings and services, but regional disparities persist.
- LATAM & Australia: Face critical gaps, including lack of standardized codes and limited coverage, restricting access to innovative technologies.
- Cost drivers: Nursing time drives most costs (~74%), while advanced technologies—despite higher initial costs—consistently demonstrate savings by accelerating healing, reducing complications, and preventing hospitalizations.
- Clinical impact: Evidence highlights that optimized protocols and VBHC models can deliver measurable economic and clinical benefits, improving patient quality of life and reducing systemic burden.

Conclusion: Chronic wounds must be recognized as a distinct chronic condition to ensure equitable access and sustainable financing. Strategic adoption of VBHC, harmonized coding, and robust cost-effectiveness research are essential to prevent escalating costs and poor outcomes. Targeted can deliver measurable reductions in systemic burden and improve patient-reported outcomes.

EP211 Hard to heal wounds: Treatment costs and quality of life when using electric stimulation therapy

Jane Hampton[1], Mette Riis[1], Winnie Schjott[1]

[1]Aarhus Health and Care, Aarhus, Denmark

Aim: To assess cost effectiveness and effect on patients' quality of life when using a microcurrent electrical stimulation therapy (EST) device on stalled wounds.

Method: An observational study of community patients with hard-to-heal wounds who received EST for 12 days. Wound area was assessed every 14 days for 16 weeks. Patients reported wound pain (VAS) and completed a 'Wounds-Quality of Life' form on day 1, at week 4. Weekly treatment costs were estimated based on frequency of dressing changes, nursing time used and product costs, prior to and during the study.

Results / Discussion: 48 patients, with 52 wounds were included. Median wound duration was 30.0 weeks. During 2-weeks of EST, wound area reduced by a median of 31%. At 16-weeks 27 (50%) wounds were healed, within a median of 9,7 weeks. 10 wounds (20%) were more than 75% smaller.

Treatment frequency had reduced at week-6 from 2.3 to 1.6, resulting in 170 (20%) fewer dressing changes over 16 weeks. Compared to baseline costs the additional expense of EST became cost-neutral at week-8, with an estimated 41% reduction in treatment costs over 16 weeks.

There was an overall improvement in quality of life (0.27 difference) at week-4, whilst patients with wounds > 16 weeks duration reported above average improvement (diff. 0.36). Patients with moderate/severe wound pain experienced a clinically meaningful pain reduction (median VAS 7.0 to 3.2) and a meaningful improvement in quality of life (diff. 0.53).

Conclusion: Considerably improved healing times makes microcurrent EST a cost-effective treatment for hard-to-heal wounds. Its effect on both healing and pain reduction gives a meaningful improvement to patients' quality of life.

EP438 Mepilex Border Post Op dressings evaluation

Louise Wall[1], Kelly Phillips[1]

[1]Mexborough Elective Orthopaedic Centre, Doncaster and Bassetlaw Teaching Hospital Foundation Trust, Doncaster, United Kingdom

Aim: To compare the performance of Mepilex Border Post-Op (Mölnlycke Health Care) to previously used dressings (Opsite Post Op and Post Op Visible (Smith & Nephew)) on the closed incision sites of low-risk hip and knee surgery patients.

Method: An evaluation was completed within at an Elective Orthopaedic Central of Excellence (MEOC) department over a two-month period. The patients included had hip or knee surgery. The wounds were all primary intention closed incision wounds.

Mepilex Border Post Op dressing was a dressing of choice to evaluate due to its features:

- highly absorbent
- easy to apply
- flexible and conformable dressing for surgical wounds, moulds to skin without sticking and protects surrounding skin
- 14 days wear time

Results / Discussion: 24 patients included, Patients were discharged either day 1 or day 2 post operatively. All dressings were reported to remain intact with no leakage.

- 1 patient removed dressing prior to 14 days due to strike throug.
- No recorded wound infections
- There were no Skin concerns during wear time or on removal.

The cost analysis during the evaluation showed a 50% reduction in cost with the usage of Mepilex post op against the Smith and Nephew post op dressings. This was mainly due to the 14 day wear time.

Conclusion: The evaluation showed good staff engagement to perform the evaluation, theatre staff who applied the dressing feedback was easy to apply and expressed how well the dressing contoured well around the knee joint.

Undisturbed wound healing benefits:

- Optimised healing
- Reduced risk of contamination/surgical site infection
- Cost savings (12 month period cost saving £3,041.12)
- Clinician time savings

EP212 Advanced wound care consultancy service within a hospital setting as a strategy torespond to current challenges and enhance skills

Lisa Lissandron[1], Chiara Tonello

[1]Azienda Ospedaliera Università di Padova, Padova, Italy

Aim: To design and implement an Advanced Wound Care Consultancy Service within a hospital setting, with the objectives of optimizing human and economic resources and enhancing institutional knowledge regarding the management of skin lesions.

Method: The organizational structure of the service was developed around five core wound-care domains:

- Clinical
- Education and Training
- Research
- Management
- Communication

Across these domains, three levels of professional expertise were defined:

- Level 1: Unit-based Wound Care Nurse Specialist
- Level 2: Hospital Network Wound Care Nurse Specialist
- Level 3: Advanced Practice Nurse with Professional Function, serving as Hospital Wound Care Coordinator

Results / Discussion: The project was launched in May 2025 following the appointment of two Level-3 Hospital Wound Care Coordinators. Subsequently, Unit-based Level-1 Wound Care Nurse Coordinators were identified. Among them, nurses with advanced clinical and educational expertise in wound management were selected to establish a hospital-wide support network, thereby defining the Level-2 professional group.
Key organizational activities included:

- Defining the typology of consultancy services
- Integrating specific service codes into the hospital's consultation request system
- Establishing a dedicated Wound Care cost center
- Developing a monitoring database for wound-care activities
- Presenting a standardized hospital-level consultancy model
- Implementing a pilot project in surgical departments starting October 15, 2025

Conclusion: In a context of constrained nursing resources, establishing a structured consultancy service represents a strategic approach to improving care pathways by maximizing existing professional competencies in wound care. The proposed model emphasizes specialization, continuous training, and organizational and technological innovation to address current challenges and ensure high standards of wound management across the hospital.

EP439 Impact of negative pressure wound therapy with instillation compared to standard negative pressure wound therapy and traditional gauze layer dressing on cost in the treatment of acute traumatic wounds

Dimas Milcheski[1], Ashley Collinsworth[2], Siobhan Lookess[2], Rafael Santos Jr[1], Bruna Amaral[1], Rolf Gemperli[1]

[1]Faculty of Medicine, University of São Paulo, Sao Paulo, Brazil, *[2]Health Economics and Outcomes Research, Solventum, Maplewood, United States*

Aim: There is increasing evidence supporting the clinical effectiveness of negative pressure wound therapy with instillation and dwell (NPWTi-d) but limited economic data regarding its impact on care costs. The aim of this health economics study was to examine differences in overall and wound-related inpatient costs for patients with acute

traumatic wounds who received NPWTi-d versus costs for patients who received layered gauze dressing or traditional negative pressure wound therapy (NPWT).

Method: Overall hospitalization costs and inputs to model wound-related costs were obtained from a recently published single-center randomized controlled trial of patients treated with NPWTi-d, NPWT, or gauze layer dressings for acute traumatic wounds and hospital and country-level cost data. The total per patient wound-related cost was calculated as the sum of the cost of mean hospital length of stay (LOS) for the duration of wound-related therapy, wound-related surgical procedures, and cost of wound therapy.

Results / Discussion: Total overall cost of hospitalization was lower for patients who received NPWTi-d ($7,814) compared to patients who received NPWT ($7,890) or gauze layer dressing ($9,735). When analyzing modeled wound-related costs only, NPWTi-d also showed a cost advantage. Wound-related cost per patient for NPWTi-d was $3,390, representing an 18.3% reduction compared with NPWT ($4,149) and a 20.7% reduction compared with gauze dressing ($4,275). Differences were due to reductions in wound-related LOS and surgeries.

Conclusion: The results from this economic study demonstrate a potential cost savings with use of NPWTi-d compared to NPWT and gauze layer dressing in patients with acute traumatic wounds due to reductions in wound-related surgical procedures and wound-related LOS. These findings corroborate existing evidence suggesting potential cost savings of NPWTi-d in complex wound management.

EP213 Transforming wound management: Clinical and workflow improvement in acute care settings

Ron Sotomayor[1], Kimberly Klein[1], Jeffrey Chiu[1]

[1]*AdventHealth Orlando, Orlando, United States*

Aim: Nearly half of hospitalized patients have wounds requiring frequent, painful dressing changes, often prolonging hospital stays and increasing readmissions, creating a need for efficient solutions that lessen nursing workload while improving healing outcomes.

Method: A large United States (US) academic hospital system piloted an extended wear (< 30 days) novel transforming powder dressing (TPD) in effort to improve outcomes related to wound healing rates, pain levels, dressing frequency, complications, and nursing time.

Evaluations encompassed acute and chronic wounds: two quality improvement (QI) projects for post operative wounds, a randomized controlled trial (RCT) for diabetic foot ulcers (DFUs), a retrospective review of recalcitrant pressure injuries, and a nursing efficiency study.

Results/Discussion: TPD demonstrated consistent clinical and operational improvements. In a QI study of general surgery patients (n=12), patients experienced a pain and related medications decreased by 80+%; wound assessments by 66%/week. A colorectal QI study (n=10) similarly showed reduced pain, with a 78% reduction in dressing frequency. All patients healed without readmissions in both studies. A retrospective pressure injury study (n=21) documented complete healing of Stage 2–4 pressure injuries previously unresponsive to standard care with 11 total applications. In a RCT involving 135 DFU patients, TPD patients experienced 51% faster wound area reduction with 67% fewer dressing changes and 59% lower pain scores. A nursing efficiency study (n=76) across wound etiologies showed weekly dressing time decreased from 2.6 hours per patient to <20 minutes. No product related complications were reported in across studies.

Conclusion: TPD is now being deployed regionally across this hospital system as part of a broader strategy to enhance outcomes, shorten length of stay, reduce costs, and optimize nursing workflow.

EP214 Wound care competence among primary health care physicians in Western Uusimaa

Réka Sayeda[1], Katariina Noronen[2], Kirsi Isoherranen[3]

[1]Espoonlahti Health Centre, Western Uusimaa Wellbeing Services County, Espoo, Finland, *[2]Helsinki University Hospital, Vascular Surgery Department, Helsinki, Finland*, *[3]Helsinki University Hospital, Helsinki Wound Healing Centre, Helsinki, Finland*

Aim: To evaluate healthcare professionals' opinions regarding the wound care competence of primary care physicians.

Method: Online questionnaire was sent to primary care physicians and nurses involved in wound care in Western Uusimaa Wellbeing Services County.

Results / Discussion: The survey received responses from 67 physicians and 112 nurses. 58 % of physicians reported that nurses call them for consultations, and they have only a few minutes to make decisions. 76 % of physicians felt their wound care competence was insufficient. 52% did not consider the patient care pathway for wound patients to be safe and effective. 45% of physicians wait four weeks or longer before referring patients to specialized care when a wound fails to heal, and 9% did not know where to refer patients. 91% expressed a need for further training in wound care.

Nurses' responses revealed that 33% felt that physicians' consultation responses were generally inadequate for ongoing care. 71% believed that health center physicians lacked sufficient knowledge and understanding of wound care. Additionally, 48% of nurses felt that they themselves lacked adequate wound care competence, and 85% expressed a need for further training.

Conclusion: The survey highlights gaps in wound care competence among primary health care physicians. The findings underscore the need for training programs to enhance physicians' skills and knowledge in wound management. Addressing these gaps is crucial for improving patient outcomes and ensuring safe, effective care pathways.

EP440 Accelerating healing: A clinical evaluation of a standardised pathway for hard to heal wounds using proven evidence-based solutions

Tessa Anders[1], Georgina Ellis[2], Rebecca Hodges[2], Laura Hindwood[2], Ciara Murphy[2]

[1]Northamptonshire NHS Foundation Trust, Northamptonshire, United Kingdom, *[2]Urgo Medical, Leicestershire, United Kingdom*

Aim: With an ageing population and rising caseloads, chronic wounds pose a major challenge, with up to 63% unhealed after 12 months, causing prolonged suffering and increased costs (Guest et al., 2020). A Tissue Viability Service review revealed significant variation in wound care, likely due to inconsistent clinical knowledge and skills. A standardised wound healing pathway was introduced to support decision-making, reduce variation, and improve outcomes.

Method: The pathway promotes evidence-based practice and consistent decision-making following patient assessment (Greco et al. 2021). For infected wounds, a antimicrobial dressing was recommended for debridement, biofilm disruption, and infection control (Meaume et al., 2014; Dalac et al., 2016). For clean wounds or post-infection, a TLC-NOSF dressing was used to reduce MMPs and support healing (Lazaro et al., 2019; Sigal et al., 2019). Three community nursing teams piloted the pathway with wounds of varied aetiologies and durations. Outcomes measured: time to healing (up to 20 weeks), wound area reduction, and infection resolution.

Results / Discussion:

- 52 patients, 55 wounds; average 5 co-morbidities per patient
- 19 wounds presented with infection
- 22 patients excluded due to incomplete data or hospitalisation
- 30 wounds healed within 4–10 weeks
- 3 wounds showed 65% reduction by 20 weeks

A TLC-NOSF dressing which provides wound hygiene and healing support was used. (National Institute of Healthcare Excellence, NICE, 2023). The pathway was renamed The Wound Healing Pathway to clarify criteria.

Conclusion: Early, evidence-based intervention improved outcomes, reduced NHS costs, and eased resource demand.

EP215 Early outcomes of implementing a new multilayer foam dressing in an acute setting: Assessing clinical and financial impact through value-based procurement

Maria Hughes[1], Jo Wilkins[2], James Fisher[2], Rebecca Rodger[2]

[1]Countess of Chester Hospital NHS Foundation Trust, Chester, United Kingdom, [2]Convatec Technology Centre, Deeside, United Kingdom

Aim: To demonstrate the clinical and economic impact of introducing a multilayer foam dressing* within a value-based procurement (VBP) framework, focusing on improving wear time through effective exudate management, enhanced adhesive performance, and reduced need for dressing layering.

Method: 28 patients (31 wounds) were evaluated across two care settings at the Countess of Chester NHS Trust over a 3-year period using a standardised assessment form. Objectives for changing to the foam dressing were: improved exudate control, extended wear time, reduced need for primary and secondary dressings, enhanced adhesion, and decreased maceration. Following formulary inclusion, a phased site-wide implementation supported by education and training was completed. Post-implementation analysis compared monthly volumes and spent for silicone foams, gelling fibres, and alginates across the respective months of 2023/24, 2024/25 and 2025/26 (year-to-date).

Results / Discussion: Clinical objectives were met in 98% of cases (30/31). Dressing changes were reduced in 84% of wounds (26/31), and 96% achieved reduced need for additional dressings (25/26). All evaluations (100%) rated the new dressing more effective than previous options. Post-implementation analysis showed a 27% reduction in foam volumes and 70% in gelling fibre/alginate volumes over three years. Corresponding spend decreased by 24% for foams and 74% for gelling fibres/alginate dressings.

Conclusion: Introducing a multilayer foam dressing* within a VBP framework improved clinical outcomes and optimised resource utilization, reducing dressing changes and overall expenditure. These findings support structured, evidence-informed procurement strategies that prioritise value over lowest upfront cost and drives sustainable improvements in wound care.

Reference:

*ConvaFoam™ dressings

EP216 Prevalence and predictive modelling of complex wounds in Alentejo, Portugal: Evidence for targeted care strategies

Katia Furtado[1], Pedro Gaspar[2], Carlos Casaquinha[3], Carla Breu[4], Nelson Mestrinho[5], Regina Candeias[6], Paulo Infante[7]

[1]Unidade Local de Saúde do Alto Alentejo, Comprehensive Health Research Center, CARE – Centro de Investigação em Saúde e Ciências Sociais, Portalegre, Portugal, [2]Instituto Politécnico de Leiria, Leiria, Portugal, [3]Sociedade Portuguesa de Feridas, Portalegre, Portugal, [4]Unidade Local de Saúde do Litoral Alentejano, Santiago do Cacém, Portugal, [5]Unidade Local de Saúde do Alentejo Central, Évora, Portugal, [6]Unidade Local de Saúde do Baixo Alentejo, Beja, Portugal, [7]Departamento de Matemática , Universidade de Évora, Évora, Portugal

Aim: This study aimed to characterize the prevalence and contributing factors of complex wounds across four Local Health Units (ULS) in the Alentejo region of Portugal. The goal was to understand the clinical and contextual factors associated with wound complexity and develop reliable predictive models for identifying patients at high risk of prolonged evolution.

Method: Data were gathered using a validated instrument focused on patient characteristics, wound factors and care organization. Statistical analysis involved a Generalized Additive Mixed Model to explain structural effects, and predictive models, including penalized regression, were utilized and validated via nested cross-validation to assess risk anticipation.

Results / Discussion: Complex wounds accounted for approximately one-third of all wounds observed. A significant portion of wound management (56%) occurs outside hospital or primary care centers, typically at the patient's home. Modelling confirmed that complex wounds follow predictable patterns of cumulative risk. The most critical risk predictors identified included wound typology, specifically leg ulcers and diabetic foot, their location in the lower limbs, and the use of a wheelchair. The validated predictive model demonstrated high discriminatory power (AUC=0.854), effectively identifying the top 20% of high-risk patients. Importantly, spatial analysis indicated that variation in complex wound rates stemmed primarily from operational differences rather than geographical clusterization, suggesting opportunities for organizational improvement.

Conclusion: These findings confirm the substantial clinical and resource burden imposed by Leg Ulcers and Pressure Ulcers, which should guide training and resource allocation. Integrating predictive risk modeling into clinical governance allows health units to anticipate complex cases, focus surveillance on high-risk cohorts, and optimize resource allocation effectively. Prioritizing prevention and targeted treatment based on data is crucial for improving care quality and outcomes.

EP217 Regulatory classification does not predict real-world effectiveness of cellular, acellular, and matrix-like products (CAMPS) in hard-to-heal lower-extremity ulcers: A 2.65 million episode medicare analysis

William Tettelbach[1 2 3], Travis Tucker[4]

[1]Duke University School of Medicine, University of Health Science - Department of Podiatric Medicine, RestorixHealth, Durham, United States, *[2]RestorixHealth, Metairie, United States*, *[3]Western University of Health Sciences - Department of Podiatric Medicine, Pomona, United States*, *[4]Woodside Analytics, St. Petersburg, United States*

Aim: CAMPs are widely used for lower-extremity diabetic ulcers (LEDUs) and venous leg ulcers (VLUs), yet reimbursement frameworks often assume that the FDA regulatory category 361, 510(k), or premarket approval (PMA), reflects differences in clinical performance. Evidence validating these assumptions is limited. This study evaluated whether regulatory classification predicts real-world effectiveness and how episodes treated with these technologies compare with standard of care (SOC) alone.

Method: Using a CMS limited data set (2016–2024), we analysed 2.65 million LEDU and 745,411 VLU episodes. CAMP-treated episodes were assigned to regulatory categories and matched with SOC using four-way matching on age, sex, comorbidities, time to treatment, debridement depth, and episode year. Episodes receiving CAMPs were stratified by regulatory categories, and 4-way 1:1 matching was used to balance cohorts across age, comorbidities, episode year, time to treatment, and debridement depth. Bonferroni correction addressed multiple comparisons.

Results / Discussion: Regulatory classification did not meaningfully predict clinical outcomes. Across matched LEDU (n=3,585/group) and VLU (n=2,492/group) cohorts, differences among PMA, 510(k), and 361 products were mainly non-significant. In contrast, all CAMP groups significantly outperformed SOC. CAMP-treated episodes showed lower mortality (LEDUs: 9.5–11.1% vs 12.7% SOC; VLUs: 10.0–12.2% vs 13.2% SOC), fewer amputations, and substantially reduced ED, ICU, and CCU utilization. Benefits were consistent across wound sizes. SOC episodes showed slightly shorter length-of-treatment (LOT) but substantially higher complication rates.

LEDU episode comparisons to SOC (n=3,585/cohort)					2- way comparison					
	SOC	PMA	510k	HCTP	SOC v PMA	SOC v 510k	SOC v HCTP	PMA v 510k	PMA v HCTP	510k v HCTP
Matching Variables*	*Mean*	*Mean*	*Mean*	*Mean*	*p-values*					
Days to Start Treatment	110.8	116.1	116.7	114.7	0.044	0.024	0.117	0.820	0.612	0.458
Age	69.5	69.7	69.7	69.7	0.488	0.497	0.434	0.990	0.926	0.916
Male Gender	64.2%	64.2%	64.2%	64.2%	1.000	1.000	1.000	1.000	1.000	1.000
CCI score	4.8	4.8	4.8	4.8	0.558	0.683	0.704	0.859	0.837	0.977
DB20	20.3%	20.3%	20.3%	20.3%	1.000	1.000	1.000	1.000	1.000	1.000
Outcomes	Mean	Mean	Mean	Mean						
Episode LOT	256.5	279.4	263.5	271.1	0.000	0.173	0.005	0.003	0.112	0.146
Total Paid Dx	$25,022	$25,259	$26,880	$26,268	0.747	0.015	0.092	0.025	0.150	0.399
Total Paid	$34,468	$33,461	$35,553	$34,626	0.288	0.272	0.867	0.025	0.190	0.319
Major Amputation	5.3%	2.7%	3.5%	2.8%	0.000	0.000	0.000	0.055	0.665	0.137
Minor Amputation	15.7%	14.0%	13.7%	13.9%	0.050	0.018	0.033	0.682	0.865	0.811
Outpatient Visits	13.9	21.8	20.2	20.8	0.000	0.000	0.000	0.003	0.047	0.254
CAMPS LOT		39.10	33.02	46.41				0.000	0.000	0.000
CAMPS Applications		2.72	2.74	3.37				0.735	0.000	0.000
ED Visits (days)	1.41	0.99	1.04	0.97	0.000	0.000	0.000	0.166	0.647	0.073
Readmission (days)	0.37	0.20	0.23	0.21	0.000	0.000	0.000	0.086	0.718	0.177
Inpatient Visits (days)	1.45	1.03	1.07	0.99	0.000	0.000	0.000	0.314	0.268	0.038
ICU	0.37	0.27	0.27	0.25	0.000	0.000	0.000	0.689	0.299	0.154
CCU	0.11	0.10	0.09	0.09	0.099	0.006	0.031	0.283	0.596	0.604
Mortality	12.7%	11.1%	10.2%	9.5%	0.031	0.001	0.000	0.235	0.030	0.322

LEDU, lower extremity diabetic ulcer. SOC, standard of care, PMA, premarket approval product. 510k, 510(K) approved product. 361- 361 regulated CAMP. Charlson Comorbidity. DB20, debridement episodes with an ulcer over 20 cm^2. LOT, length of treatment. ICU, intensive care unit. CCU, cardiac care unit. Matched Groups, N=3,585/cohort

Conclusion: The FDA regulatory pathway does not predict real-world CAMP effectiveness in Medicare beneficiaries with hard-to-heal ulcers. CAMPs, regardless of category, consistently reduce mortality, amputations, infections, and hospital utilization compared with SOC alone. These findings challenge reimbursement models tiered by regulatory category, as outcomes across these technologies appear statistically similar.

EP218 An organizational model for wound care specialist nurses: Integration of outpatient services, specialist consultations, and territorial network

Giulia Vidotto[1], Gaetano De Angelis[2], Umberto Cazzaro[2], Bertulli Gianluca[2], Sara Maria Lupi[2], Lina Carmela Ognibene[2], Vittoria Azzimonti[2], Stefania Biondo[2]

[1]Ospedale San Raffaele, Milan, Italy, *[2]Ospedale San Raffaele, Milano, Italy*

Aim: Chronic wounds are a growing healthcare challenge requiring timely, specialized interventions. To address this, we developed an organizational model for nurse-led wound care clinics to improve continuity of care, optimize resources, and strengthen collaboration between hospital and community services. The model reflects the evolution of a wound care service that has been established for 16 years within an Italian hospital with 1,200 beds.

Method: Implemented in collaboration with the Health Directorate and Quality Office, the model includes three components: (1) outpatient wound care clinics managed by specialist nurses, where patients are referred after hospital assessment; (2) multidisciplinary consultations with infectious disease, vascular, orthopedic, rheumatology, and dermatology specialists; and (3) a territorial network ensuring follow-up and home care. Data on patient flow, wound types, and referral pathways were collected over six months.

Results / Discussion: The model streamlined patient management and reduced waiting times for specialist input. Approximately 80% of patients were referred from surgical departments, 10% from autoimmune disease units and internal medicine. During the study period, 150 multidisciplinary consultations were activated: 25% infectious disease, 20% vascular surgery, 30% orthopedic, 15% rheumatology, and 15% dermatology.

Conclusion: This organizational model demonstrates that nurse-led wound care clinics, supported by specialist consultations and a territorial network, enhance efficiency and quality of care for chronic wound patients

EP219 Therapeutic success indicators in hard-to-heal wounds: Effectiveness of a specialized ambulatory care model

Michele Rocha[1], Saskia Fleury[1], Magali Thum[1]

[1]ConvaCare Clinic, São Paulo, Brazil

Aim: To evaluate the clinical outcomes and effectiveness of an integrated care model based on structured healing indicators in a specialized ambulatory service for hard-to-heal wounds.

Method: A retrospective descriptive study was conducted in a specialized wound care ambulatory clinic in Brazil, including 82 patients over a 9-month period in 2025, referred by a private health insurance provider. No individual clinical or sociodemographic data were used. Wound complexity was classified as low, medium, high, or special, using an institutional scale. Monthly-stratified clinical indicators included: evolution of complexity, infection rate, hospital readmission rate, and Net Promoter Score (NPS). Interventions included technical wound cleansing, debridement when indicated, targeted antimicrobial management, advanced technologies, and patient education, following standardized protocols based on international guidelines (Murphy, 2022; IWII, 2022).

Results / Discussion: Medium complexity was the most frequent category (N = 32; 39%). A total of 84% of active patients progressed within the estimated healing time. The rate of new infections was <1.5%, and 5% of patients required hospital readmission due to wound-related complications. The use of structured clinical indicators enables effective monitoring of therapeutic outcomes and supports clinical decision-making (Pruim, 2022). The mean healing time was 43.6 days. The mean monthly NPS was 98%, reflecting high patient satisfaction with the specialized nursing-led service.

Conclusion: The use of structured clinical indicators combined with an integrated, specialist-led care model proved effective in accelerating healing, reducing complications, and enhancing patient experience. These findings support the role of standardized, indicator-driven wound management

EP220 Entrepreneurship and nursing in wound care in the Brazilian context: potentialities and challenges

Lidiany Felix[1], Vivian Silva[2]

[1]Universidade Federal de Campina Grande, Paraíba, Brazil, *[2]Universidade Federal de Campina Grande, Campina Grande, Brazil*

Aim: Understanding the potential and challenges of Brazilian nurses who are entrepreneurs in the field of wound care.

Method: An exploratory, descriptive study with a qualitative approach, guided by the Consolidated Criteria for Reporting Qualitative Research (COREQ), conducted through semi-structured interviews with 16 Brazilian nurses who are entrepreneurs in the field of wound care. Sampling was performed using a virtual snowball technique. The interviews were transcribed and analyzed according to Bardin's content analysis technique.

Results / Discussion: The following factors were identified as enhancing entrepreneurial activities: professional autonomy and a broad scope of practice; the holistic perspective of nurses; the increasing demand for nursing care among the population; and an innovative thought model. The factors that hinder entrepreneurial activity include: fear of becoming an entrepreneur; insufficient support during the academic process; social unawareness of the entrepreneurial potential in nursing, along with the professionals' lack of self-awareness; and inadequate preparation and absence of encouragement from the nursing council in promoting entrepreneurial professionals.

Conclusion: The field of wound care offers great potential for nursing entrepreneurship in Brazil, driven by professional autonomy, demand for specialized care, and nurses' holistic approach. However, structural and cultural barriers remain, such as fear of entrepreneurship, lack of preparation in undergraduate programs, and lack of institutional incentives. Training and support strategies are needed to consolidate this area as an autonomous and valued field of practice. The results of this research highlight the need to integrate entrepreneurship into nursing education guidelines in Brazil. Such discussions are crucial for strengthening regulatory frameworks and public policies that encourage advanced and autonomous nursing practice in wound care.

EP441 AI-driven tools in wound care: A systematic review of cost-effectiveness

Wan Zuraini Mahrawi[1]

[1]*National Cancer Institute Malaysia, Putrajaya, Malaysia*

Aim: To evaluate the cost-effectiveness of artificial intelligence (AI)–driven tools in wound care management, focusing on interventions in which AI constitutes the primary functional mechanism.

Method: A systematic review was conducted across four academic databases to identify completed studies evaluating AI-driven wound care tools with reported economic or resource-related outcomes. A total of 41 records were screened using predefined eligibility criteria. Studies were eligible if they involved patients with acute, chronic, surgical, pressure-related, or burn wounds; applied AI technologies such as machine learning, deep learning, or computer vision as the core intervention; and reported comparative economic, cost, or resource utilisation outcomes. Following screening, 12 articles were included and analysed descriptively.

Results / Discussion: Across the 12 analysed articles, AI-driven wound care tools demonstrated consistent workflow efficiencies, with reductions of approximately 77–80% in staff time required for wound assessment and surveillance. Direct cost savings were reported in selected studies, including lower treatment costs over a 12-month period in a randomised trial of AI-supported remote wound consultation and estimated annual savings exceeding one million currency units from reduced treatment delays in burn wound management. Clinical improvements, including faster wound healing and fewer amputations, supported potential downstream cost savings, particularly in remote or resource-limited settings. However, formal cost-effectiveness analyses were limited, study time horizons were short, and sensitivity analyses were infrequently performed. One comprehensive rapid review concluded that available evidence remains insufficient to establish definitive cost-effectiveness across diverse healthcare environments.

Conclusion: AI-driven wound care tools may be cost-effective under specific conditions, particularly where automation reduces staff workload or specialist access is limited. Nevertheless, methodological limitations prevent generalisable conclusions, underscoring the need for robust, long-term economic evaluations.

HOME CARE

EP442 The family's role in continuing pressure ulcer care at home after hospital discharge

Ali Alibrahim[1], Bander Gohal[2]

[1]Department of Wound Care, Ministry of Health , Jizan Health Cluster, Jizan, Saudi Arabia, *[2]King Fahd Hospital Jizan, Jizan, Saudi Arabia*

Aim: To evaluate the impact of structured family involvement on the healing progress of a stage 4 sacral pressure ulcer after hospital discharge, and to examine how targeted caregiver education contributed to continuity of home-based care.

Method: A case study approach was used to observe an adult patient discharged with a slough-covered stage 4 sacral pressure ulcer. Before discharge, the family received structured education on pressure-relief techniques, daily wound observation, and the purpose of modern dressing principles. Caregivers performed routine home care while maintaining regular communication with the clinical team. Weekly assessments documented wound size, tissue characteristics, comfort levels, and caregiver adherence to the care plan.

Results / Discussion: Over a three-month follow-up period, the wound demonstrated steady improvement, transitioning from sloughy tissue to full granulation and complete closure. No complications were recorded, and the patient reported increased comfort and stability. The family demonstrated consistent adherence to positioning routines and monitoring practices, contributing to sustained wound progress. The findings support existing evidence that well-prepared family caregivers can enhance continuity of care and reduce the risk of delays in healing when managing complex wounds at home.

Conclusion: Structured caregiver education and active family engagement played a key role in the successful healing of a stage 4 sacral pressure ulcer following discharge. The case underscores the importance of family-centered approaches in promoting continuity of care and improving outcomes in home-based pressure ulcer management.

EP222 Evaluating patient-centred strategies for the management of complications following aesthetic treatments

Esther van der Wel-Luijendijk[1 2]

[1]Erasmus MC, Rotterdam, Netherlands, *[2]Careyn, Delft, Westland, Schiedam, Netherlands*

Aim: To investigate the therapeutic value and feasibility of a self-applied, tube-dispensed wound dressing for managing complex wounds resulting from aesthetic surgery complications, particularly in situations where clinical follow-up may be limited and enhanced patient self-care is essential.

Method: This case series includes four patients with wound complications after cosmetic procedures, initially treated in private clinics with limited postoperative guidance. An enzyme alginogel was incorporated into the wound care regimen and after instructions from a wound care professional, patients performed dressing changes independently at home. Wound healing time, ease of use, self-care comfort and relative costs compared with traditional care were assessed during outpatient visits.

Results / Discussion: All patients were able to clean and apply the dressing themselves without difficulty. They experienced no pain during or between dressing changes and noted rapid wound improvement, which further supported treatment adherence.

Where private clinics initially advised paraffin gauze, often adhering to the wound bed and causing discomfort, the enzyme alginogel combined with a silicone contact layer prevented adherence and enabled painless dressing changes. With dressing changes two to three times per week, healing progressed quickly. Improved self-care, higher adherence, and more efficient wound healing collectively reduced long-term costs compared with conventional management.

Conclusion: Home care services are observing a growing number of young patients presenting with postoperative complications from aesthetic procedures.

This case series underscores the need for improved postoperative wound care guidance in private cosmetic clinics, particularly in relation to suitable dressing choices. The approach used enabled rapid healing, painless dressing changes, and empowered patients to manage their care independently. These findings suggest that a patient-centred wound-care strategy can support both improved clinical outcomes and more cost-effective care.

EP223 Use of an enzymatic antimicrobial alginogel in wound management: Expert opinion from Brazilian specialists in home care

Priscilla Sckarlat[1], Pedro Henrique Malagoli[1], Erika Fernandes[2], Jhonatan Alves Sousa[1], Amanda Daniela Belinelo[1], Marcelo Henrique Zanato[1]

[1]UNIREGEN Teaching and Research Institute Ltd., BRASÍLIA, Brazil, [2]AKHOS Specialized Medicine, Brasília, Brazil

Aim: To describe the perception of wound-care specialists regarding the use of enzymatic alginogel in wound management, emphasizing its applicability in home-care settings and the remote guidance of patients and lay caregivers.

Method: A descriptive study based on the collection of expert opinions from nursing professionals through an electronic survey. The questionnaire addressed professional profile, experience in wound management, use of enzymatic alginogel in the home environment (including remote guidance for lay caregivers), perceived clinical benefits, and perception of antimicrobial activity. Responses were analyzed in pairs by the authors to synthesize findings and identify consensus patterns.

Results: Most respondents, predominantly specialists, reported high applicability of enzymatic alginogel in home care, highlighting its ease of instruction and handling by patients and lay caregivers, including via telemonitoring. Advantages commonly cited included appropriate consistency, smooth spreadability, atraumatic removal, and low probability of application errors. Reported clinical benefits included effective exudate control, odor reduction, pain relief, support for enzymatic debridement, and accelerated granulation tissue formation. Respondents also perceived favorable antimicrobial activity, inferred from improvement in local signs and symptoms and positive wound progression, reinforcing its safety and effectiveness for home use. Additional comments emphasized good patient acceptance, increased caregiver confidence, and potential reduction in face-to-face visits, thereby promoting autonomy and family engagement when supported by appropriate professional guidance (Table 1).

Table 1

Category Evaluated	Findings Reported by Specialists
Respondent profile	Predominantly nurses specialized in wound care and/or stomatherapy.
Home-care applicability	Reported as highly applicable; easy to instruct and easy for patients and lay caregivers to use, including through telemonitoring.
Product physical–functional characteristics	Appropriate consistency; smooth spreadability; atraumatic removal; low probability of application errors.
Observed clinical benefits	Effective exudate control; odor reduction; pain reduction; support for enzymatic debridement; accelerated granulation tissue formation.
Perception of antimicrobial action	Improvement in local signs and symptoms consistent with antimicrobial activity; overall favorable wound progression.
Ease of remote guidance	High level of safety and clarity in guiding lay caregivers via telehealth; good understanding and execution of care.
Patient and caregiver acceptance	Good acceptance; increased caregiver confidence; greater autonomy and family engagement in the care process.
Impact on care delivery	Potential reduction in the number of in-person visits without compromising care quality.

Conclusion: Enzymatic alginogel proved to be a safe, user-friendly, and clinically effective option for wound management in home-care settings, contributing to continuity of care, treatment adherence, and improved clinical outcomes. These findings highlight its potential as a valuable resource for nursing practice across in-person, hybrid, and remote care models.

EP224 Outcomes of hospital-at-home care for cellulitis patients receiving home parenteral antibiotic therapy

Peixuan Lin[1]

[1]*Fu-jian home care, Doctoral Student, School of Nursing, Chang Gung University, Taoyuan, Taiwan, Taoyuan, Taiwan*

Aim: To describe the feasibility and short-term outcomes of home-based parenteral antibiotic therapy for cellulitis within aHospital-at-hom(HaH) service.

Method: We conducted an observational review of all patients enrolled in our HaH programme between 1 June and 1 December 2025. Patients with a clinical diagnosis of cellulitis received home-based quinolone antibiotics and integrated wound care provided by a multidisciplinary home care team. We recorded length of stay (LOS) in HaH, discharge destination, and unplanned readmissions within 14 days.

Results / Discussion: A total of 29 patients were admitted to HaH during the study period, of whom 7% had cellulitis. The mean LOS for cellulitis patients was 8 days. All cellulitis patients completed the planned course of home antibiotic treatment and were discharged in stable condition to continued community-based home care. No unplanned readmissions or escalations to in-hospital acute care occurred within 14 days after discharge (14-day readmission rate 0%).

Conclusion: In this small pilot cohort, HaH delivery of parenteral quinolone therapy for cellulitis appeared feasible, safe, and associated with favourable short-term outcomes, with no early readmissions. These findings highlight the contribution of home-based acute antibiotic therapy to wound management pathways and warrant confirmation in larger comparative studies.

EP225 Improving healing and workforce efficiency: A specialist home-based wound care approach

Lauren Thorpe[1]

[1]*University Hospitals Coventry & Warwickshire, Coventry, United Kingdom*

Aim: To describe the design, implementation, and evaluation of the Coventry Community Wound Healing Team (CWHT), a specialist home-based wound care model developed to address inequities in healing outcomes for housebound patients and reduce pressure on community nursing services.

Method: Following the CWHT launch in 2022, a service review assessed its impact. The model employed a skill-mixed team led by a wound healing clinical nurse specialist, including registered nurses, wound care sisters, and healthcare assistants. Patients received up to 12 weeks of specialist home-based care, during which community nursing input was paused. Referrals were clinically triaged, and care plans focused on two outcomes: healing potential and living well with a wound. Data were collected via clinical assessment, wound outcome measures, patient-reported quality-of-life (QoL) tools, workforce metrics, and staff reflections. A one-month snapshot evaluated early

Results / Discussion: The CWHT demonstrated significant improvements in wound and patient outcomes. One-month data showed: 76% reported improved QoL; 69% reduced pain; 76% required fewer face-to-face visits; 84% had reduced exudate and improved wound bed condition; and 100% achieved treatment concordance with reduced lower-limb oedema. Across the wider review, the service released over 17 hours of registered nursing time per week back to community teams. Five patients achieved full healing during their 12-week episode, with two more healing shortly after. Staff reported improved wellbeing supported by psychological sessions, and specialist oversight reduced clinical risk.

Conclusion: The Coventry CWHT improved access to specialist wound care for housebound patients while enhancing healing outcomes, patient experience, and workforce efficiency. This innovative model offers a scalable framework for regions facing workforce shortages and rising demand for complex wound care.

EP229 A topical desiccating agent in the organization of Dutch home care based wound treatment

Uulkje Bron[1], Saskia Van der Graaf-Ijsselstein[1], Brenda Vlemminx[1], Alex Westra[1], Jannie Jongedijk[1]

[1]*QualityZorg B.V., Nieuw-Vennep, Netherlands*

Aim: Evaluate the organisational impact and clinical feasibility of using a topical desiccating agent, TDA, in home-care wound management, including comparison with established hospital-based wound management trajectories.

Method: A prospective service evaluation was conducted by seven nurse practitioners (NP) and wound consultants in the Netherlands to determine whether TDA could be safely and effectively integrated into home-care wound treatment. Eighty patients with 100 chronic wounds received TDA application as part of routine primary wound care. The procedure consisted of a 60-second application of TDA directly onto the wound bed, followed by rinsing. Nurses recorded wound characteristics, tissue response, pain scores and hospital referral. Unlike hospital management, which typically involves sharp debridement under specialist supervision, TDA was applied by NP and wound consultants during routine home visits without surgical instrumentation. The primary outcome was organisational impact, defined as the ability to manage wounds within the community rather than in a hospital setting while maintaining clinical progression.

Results / Discussion: TDA appeared effective in reducing visible biofilm burden, chronic wound pain and facilitating removal of devitalised tissue. Nurses observed improved wound appearance and transition to granulating tissue. Patients reported reduced wound pain and increased comfort after treatment. The majority of wounds were successfully managed at home, preventing hospital visits while achieving comparable clinical outcomes. Comparability was assessed through documented progression to granulation, reduction in slough, pain reduction and absence of infection-related hospital escalation, consistent with expected post-debridement trajectories in the Hospitals in Northern Netherlands where the nurse specialist provide the needed secondary care.

Conclusion: TDA can be used safely and effectively in home-care wound management, supporting decentralised care delivery and reducing reliance on hospital-based services while maintaining expected clinical outcomes.

EP443 Home-based care for a patient with venous leg ulcer: A case study on the impact of social determinants of health on the treatment trajectory

Yuan Chun Lo

[1]*Tzu Chi University, Hualien, Taiwan, Hsiao-Chun Home Care Clinic, Taitung, Taiwan, Hualien, Taiwan, Taiwan*

Aim: This case study elucidates the factors contributing to the prolonged chronicity of a rural patient's venous leg ulcer (VLU) by identifying key Social Determinants of Health (SDOH). It further evaluates how an integrated home-based nursing and medical intervention mitigated barriers to treatment accessibility and optimized healing outcomes.

Method: A qualitative case study methodology analyzed the seven-year non-healing trajectory of a 77-year-old man with a VLU in a rural community. Data were obtained through home visits, comprehensive wound assessments, and review of the patient's care-seeking history. An SDOH framework guided the evaluation of changes in treatment accessibility, adherence, and healing outcomes before and after referral to interprofessional home-based care.

Results / Discussion: SDOH-related barriers - including constrained healthcare accessibility, transportation deficiencies, low health literacy, and exposure to misinformation - significantly contributed to delayed wound healing and increased psychosocial and financial burden. Improper wound care practices and reliance on non-medical products further impeded recovery. Following referral by a community pharmacy, systematic wound management

delivered by a certified Family Nurse Practitioner (FNP) and a wound care–trained home care nurse, supported by home medical services, markedly improved continuity of care, accessibility, and adherence. This integrated approach resulted in complete ulcer resolution within two months.

Conclusion: This case highlights the substantial influence of SDOH on the intractability of VLUs in rural populations. Integrated home-based interprofessional care—coordinated and led by a certified home care nurse—effectively reduced access barriers, improved treatment adherence, and enabled timely wound resolution. These findings underscore the importance of expanding FNP-led services and strengthening community-based wound care models to reduce health inequities and improve clinical outcomes in underserved rural communities.

EP226 A new paradigm in diabetic foot treatment: Clinical safety and economic impact of an outpatient surgery model

Nermine Habib[1], Dino D'Errico[1]

[1]*Swiss Diabetic Foot Centers GmbH, Fribourg, Switzerland*

Aim: Diabetes mellitus and its complications impose a major economic burden on healthcare systems, with diabetic foot disease representing one of the costliest sequelae due to high rates of hospitalisation, and complications. Strategies that reduce inpatient stays while maintaining safety are therefore essential.

Method: We retrospectively analysed 54 diabetic patients treated between 2024 and 2025 in an outpatient setting for diabetic foot complications. Procedures included surgical debridements, minor amputations, and minimally invasive osteotomies. All patients received structured postoperative care: specialised wound-care nurses performed local wound management every 1–2 days, weekly outpatient medical evaluations were conducted, and telemedical surgical consultations were available whenever uncertainties arose. Total treatment costs, including outpatient surgery and home-based care, were calculated.

Results / Discussion: The average cost of outpatient surgery combined with home care ranged between 1300 and 1800 Euros per case. In contrast, expected costs based on Swiss DRG tariffs for comparable patients - with significant comorbidities and typically requiring prolonged inpatient care - would be at least tenfold higher (minimum 10'000 Euros) per hospitalisation. These findings align with European health-economic analyses showing markedly higher expenditures for inpatient diabetic foot management. Most patients expressed a preference for outpatient care when offered both options.

Conclusion: Outpatient surgical management of diabetic foot complications is feasible and safe when implemented in carefully selected patients within a structured care pathway supported by specialised a wound-care nurses and accessible telemedical review. This model is consistent with existing evidence demonstrating lower costs with comparable outcomes and has the potential to significantly decrease the economic burden associated with diabetic foot disease.

EP227 Hospital-to-home transition and care coordination in wound management: Cost-effectiveness evaluation in a Brazilian specialized service

Michele Rocha[1], Saskia Fleury[1], Magali Thum[1]

[1]*ConvaCare Clinics, São Paulo, Brazil*

Aim: To evaluate, through aggregated indicators, the performance of a specialized service in coordinating wound care following hospital discharge.

Method: A descriptive retrospective study was conducted using operational indicators from January to November 2025. Variables analyzed included: total home visits (n = 3,638), cases referred through hospital discharge (**n** = 32; 0.88%), wound complexity distribution (25% high, 14% special, 29% medium, 19% low), wound etiology, rehospitalization due to wound complications, and mean time to discharge (44 days). No individual clinical or sociodemographic data were collected.

Results / Discussion: Pressure injuries were the most prevalent etiology (29%), followed by ulcers in people with diabetes (14.9%). Rehospitalization due to wound-related complications remained <1%, a rate lower than that reported in international post-discharge monitoring studies (Murphy, 2022; IWII, 2022). The mean duration of follow-up until discharge (87 days) was consistent with international benchmarks. A predominance of medium and high complexity cases (54%) underscores the relevance of specialized care coordination. International evidence highlights that standardized protocols, such as the Wound Hygiene framework (Murphy, 2022) and IWII recommendations (IWII, 2022), contribute to reducing complications and improving outcomes during care transition. In this context, a Brazilian private service led exclusively by stomatherapists coordinates ambulatory and home-based wound care.

Conclusion: Care coordination led by stomatherapists demonstrated to be a safe and potentially cost-effective wound management model, with low complication rates, clinical stability, and optimized care trajectories in the home-care setting.

EP228 Use of multi-component multi-layer bandage systems with application indicators to improve results in the treatment of venous ulcers by non-specialized personnel

Carlo Rivellini[1]

[1]AIUC, SIC, SICVE, AFI, Italy

Aim: This work present the results of the systemic use of a multicomponent pressure-controlled bandaging system for the management of patients with phlebostatic and lynphatic wounds by non-specialized personnel with the aim of demonstrating its greater ease of application and effectiveness compared to traditional systems.

Method: 78 patients (25 with a BMI >35) with non-healing phlebostatic and lymphatic ulcers were treated at home. All patients had previously undergone compression therapy, which was performed in varying degrees by untrained healthcare professionals. The bandaging system introduced was a multicomponent compression bandage with pressure indicators that guided application of the bandage for proper lengthening and overlapping, thanks to its particular ease of use and good patient tolerability, as well as its ease of combination with various dressings, including negative pressure. Sixty enrolled patients had phlebostatic and lymphatic wounds (38 with primary saphenous reflux and 22 with post-obstructive deep circulation reflux) and 18 had mixed wounds but with good arterial flow on Doppler. Wound management did not change significantly compared to the period before enrollment.

Results / Discussion: All enrolled patients experienced significant clinical improvement in approximately 30 days, with a 90% wound healing rate within six months. At the end of the study period, healthcare professionals confirmed the bandage's ease of use and good application safety, while patients reported good tolerability.

Conclusion: The use of multicomponent bandages in this study confirmed that it is possible to significantly improve the effectiveness of compression therapy, even when performed by non-specialized personnel and at home. This was due to increased healthcare professionals' confidence and reduced fear of applying the correct amount of pressure to the bandages.

INFECTION

EP231 Effect of antiseptics in a 2D wound model with and without staphylococcus aureus infection

Leon Wolpert[1], Jörg Tittelbach[1], Cornelia Wiegand[1]

[1]*Department of Dermatology, Jena University Hospital, Jena, Germany*

Aim: Antiseptic treatment is critical for infection control in wounds but may impair healing due to cytotoxicity. This study evaluated the antimicrobial efficacy, biocompatibility, and wound healing effects of selected antiseptics in a 2D wound model under sterile conditions and S. aureus infection.

Method: Octenidine (OCT), polyhexanide (PHMB), chlorhexidine digluconate (CHX), silver nitrate ($AgNO_3$), and PVP-iodine (PVPJ) were tested. Antimicrobial activity was assessed via microplate laser nephelometry (MLN), biocompatibility via ATP-based luminescence, and wound healing via scratch assay with hematoxylin staining and digital imaging. Cytokines IL-1α, IL-6, IL-8, and TGF-β were measured in supernatants.

Results / Discussion: OCT, PHMB, and CHX showed strong antimicrobial activity (IC_{50}: 1.77, 0.63, 0.82 µg/mL), $AgNO_3$ and PVPJ were less effective. Biocompatibility varied: CHX and PHMB tolerated higher concentrations (IC_{50}: 71.4 and 11.96 µg/mL), while OCT and $AgNO_3$ were more cytotoxic. Scratch assays without infection showed dose-dependent healing inhibition, except for PVPJ. S. aureus infection caused cell death and blocked wound closure. OCT and PHMB at 1–2 µg/mL partially prevented infection and supported cell layer regeneration; higher doses were cytotoxic. CHX at 1 µg/mL was beneficial, 2 µg/mL cytotoxic; 0.5 µg/mL insufficient. $AgNO_3$ and PVPJ lacked concentrations that were simultaneously antimicrobial and safe.

Conclusion: Antiseptic treatment can control bacterial infection while supporting healing if optimally dosed. Careful selection and dosing are essential, highlighting the importance of antiseptic stewardship.

EP444 The importance of regularly reviewing clinical tools to support the implementation of best practice to ultimately promote improved patient outcomes in wound care

Kelly Phillips[1], Michaela Delahunty[2]

[1]*Doncaster and Bassetlaw Teaching Hospitals NHS Foundation Trust, Doncaster, United Kingdom*, [2]*Rotherham, Doncaster and South Humber NHS Foundation Trust, Doncaster, United Kingdom*

Aim: To support the response from wound outcomes and the application of evidence-based practice in wound care provisions for cleansing.

Method: A 4-week wound infection audit was repeated in a complex wound clinic, which concluded an increase in wound infections over the last 12 months from 1.3% to 3.5%. The local wound bed preparation pathways and supporting guides were reviewed to ensure they remained current with the latest evidence/recommendations. Best practice statements and Consensus Documents were reviewed. It identified that a new International Wound Infection Institute (IWII 2025) document for therapeutic wound and skin cleansing had been published and the pathways and guides required updating.

Results / Discussion: Implementing evidence-based practice is fundamental to improving clinical outcomes, patient safety and quality of care. Evidence-based practice is not always delivered, therefore pathways and formularies are vital in providing a tool to help drive change (Wounds UK, 2023). The IWII recommendations provided information for practice regarding cleansing, reinforcing wound cleansing as a significant component in preventing and managing wound infection and preparing wounds for healing. Pathways and guides were updated to reflect IWII guidance to ensure early diagnostics and interventions continued to reflect evidence, aligning the local formulary.

Conclusion: This process reinforced the critical role therapeutic cleansing plays in infection prevention and healing, highlighting the importance of regularly reviewing patient outcomes and reviewing clinical tools to support the implementation of best practice to ultimately promote improved patient outcomes, clinical safety, and quality of care in wound management.

EP232 Influence of drain characteristics and other known risk factors on surgical site infection occurrence in plastic surgery patients

Na Young-cheon[1], Jong Won Rhie[1], Hyeon Hee Lee[1], Hyemi Lee[1], Seoul Lee[2]

[1]Department of Plastic and Reconstructive Surgery, Wonkwang University Hospital, Iksan, Korea, Rep. of South, [2]Pharmacology, Wonkwang University, Iksan, Korea, Rep. of South

Aim: Drains are hypothesized to cause surgical site infections (SSIs). However, research is scarce on how to reduce SSIs after drain placement. We analyzed the association between specific drain characteristics and the occurrence of SSI. We also evaluated the effects of other known risk factors in patients undergoing plastic surgery to reduce SSIs.

Method: We retrospectively reviewed the medical charts of 531 patients who underwent plastic surgery with drain placement between January 2017 and January 2022. Data were analyzed using the chi-square test or Fisher exact test for categorical variables and the Mann-Whitney U test or t-test for numerical variables.

Results / Discussion: SSI incidence was higher in closed drains (15.4%) than in open drains (8.0%). SSIs also occurred more often after delayed drain removal. For open drains, early removal did not decrease SSI incidence. For closed drains, SSI incidence was markedly high when the drain was removed after 6 days. Furthermore, bacterial culture results tended to differ before and after SSI occurrence more frequently in the open drain group. Among the known risk factors for SSIs, smoking, albumin concentration, and wound status were confirmed as significant.

Conclusion: Drain removal time was a significant risk factor for SSIs. With open drains, it is important to assess whether SSI occurs at the beginning of drain placement. A higher probability of retrograde infection was confirmed with open drains. Closed drains should be removed within 6 days after placement.

Table 1. Patient distribution according to drain characteristics

	SSI present	SSI absent	Total	P-value	χ^2
Type of drain				0.009	6.911
Open drain	20 (8.0)	231 (92.0)	251 (100)		
Closed drain	43 (15.4)	237 (84.6)	280 (100)		
Total	63 (11.9)	468 (88.1)	531 (100)		
No. of drains				0.072	3.237
One	49 (10.8)	404 (89.2)	453 (100)		
Two	14 (17.9)	64 (82.1)	78 (100)		
Total	63 (11.9)	468 (88.1)	531 (100)		
Time to drain removal (day)	6.24±3.61	4.75±3.78		0.003	

Values are presented as number (%) or mean±standard deviation.
SSI, surgical site infection.
The chi-square test was performed for the type and number of drains, and the t-test was performed for time to drain removal.

Table 2. Patient distribution by drain type and time to drain removal

Darin type	Drain removal time (day)	P-value
Open drain	2.31±1.79	<0.001
Closed drain	7.26±3.58	

Values are presented as mean±standard deviation.
An independent two sample t-test was performed.

Table 3. Bacterial culture results performed before and after the occurrence of surgical site infection

Darin type	Bacterial culture results, No. (%)		
	Same	Different	Total
Open drain	9 (45)	11 (55)	20 (100)
Closed drain	25 (58.1)	18 (41.9)	43 (100)

EP445 Our results of using polyhexanide 0.04% in implant-related wound infections

Nesrin Tan Baser[1], Mevlüt Akbulut[1], Kıvılcım Selen[1]

[1]*University of Health Sciences, Gulhane Research and Training Hospital, Ankara, Türkiye*

Aim: Both titanium and silicone implants are widely used in reconstructive surgery with high satisfaction rates. However, polymicrobial biofilm formation on implant surfaces is considered the main risk factor leading to implant failure. Early microbial colonization can often occur during the surgical procedure of implant placement. Therefore, biofilm formation can begin in the early stages of postoperative healing. Consequently, it manifests as a continuous discharge through fistulas formed. If this condition is not treated, it leads to a lengthy process involving implant removal and reconstruction several months after antibiotic therapy. Polyhexanide is a cationic polymer with comprehensive antimicrobial and antiviral activity. It has been shown to inhibit microbial growth and penetration. This response is irreversible, and infectious agents cannot adapt to or develop resistance to polyhexanide. We used this product in chronic wound dressings due to its antimicrobial properties and used it in implant infections.

Method: Patients who underwent reconstruction with titanium material (3) and silicone implants (4) presented with a non-healing discharge from a small fistula e in the third week after surgery. Cultures were taken from these discharges. A wound solution containing 0.04% polyhexanide was administered every other day by entering the fistula tract.

Results / Discussion: Culture results showed P. Aeruginosa, Klebsiella pneumoniae, Acinetobacter Baumannii. Since there were no clinical signs of infection in the patients, systemic antibiotic treatment was not initiated. The discharge ceased within 2-3 weeks. The fistula tracts closed.

Conclusion: The 0.04% polyhexanide composition of the product we used dissolved the biofilm layer, preventing wound drainage and ensuring closure of the fistula opening. This spared patients from a process requiring implant removal and subsequent reconstruction 3-4 months later.

EP233 Exploring the roots of pediatric chronic osteomyelitis in sub-saharan africa: Barriers to timely diagnosis and treatment in Ethiopia, Malawi, and Nigeria

Emily Powis[1], Arinzechukwu Nwagbata[1], Elena Montgomery[1], Shravya Kakulamarri[1], Rachid Barry[1], Brittany Sacks[1], Samuel Paek[1], Ibrahim Saidu[2], Mengistu Gebreyohanes Mengesha[3], Nicholas Lubega[4], Leonard Banza[5], Yuchen Liu[1], Kiran Agarwal-Harding[1]

[1]*Harvard Global Orthopaedics Collaborative, Boston, United States*, [2]*Ahmadu Bello University Teaching Hospital, Zaria, Nigeria*, [3]*Hawassa University Comprehensive Specialized Hospital, Hawassa, Ethiopia*, [4]*Beit-CURE Children's Hospital, Blantyre, Malawi*, [5]*Kamuzu Central Hospital, Lilongwe, Malawi*

Aim: To identify system-level, social, and cultural factors contributing to delayed diagnosis and inadequate treatment of pediatric chronic osteomyelitis (COM) in Ethiopia, Malawi, and Nigeria.

Method: A mixed-methods study was conducted among 45 pediatric patients and their caregivers recruited from tertiary and district hospitals. Participants completed standardized demographic and health surveys assessing socioeconomic circumstances, healthcare access, and prior treatment history. Semi-structured interviews explored care-seeking pathways and psychosocial impacts. An inductive thematic analysis approach was used to identify common patterns across settings.

Results / Discussion: Key barriers to timely COM diagnosis and treatment were consistent across contexts. Under-resourced health systems contributed to frequent misdiagnosis and ineffective early management, with 78% of participants remaining undiagnosed before arrival at a higher-level facility. Most children presented with advanced, long-standing disease. Limited availability of medications, surgical services, and trained personnel resulted in recurrent delays. Cultural beliefs and reliance on traditional medicine further complicated care, often influenced by community pressure or frustration with prior medical encounters. Economic vulnerability intensified disease burden. Food insecurity ranged from 20% in Ethiopia to 83% in Malawi, and many families experienced substantial impoverishment related to transportation costs, loss of income, prolonged caregiving responsibilities, out-of-pocket costs, and school

dropout. Children frequently faced social isolation and stigma, although families consistently demonstrated resilience and maintained hope for recovery.

Conclusion: Pediatric COM in Sub-Saharan Africa reflects a cycle of delayed diagnosis, inadequate early management, and significant social and economic strain. Strengthening diagnostic capacity, improving referral pathways, and supporting community-focused education may reduce delays and improve outcomes.

EP446 Multimodal wound care in infection continuum management: Supporting antimicrobial stewardship by employing a multimodal approach to limit progression through the infection continuum

Kelly Phillips[1], Martha Williams[2], Katie Wallace[3]

[1]Doncaster and Bassetlaw Teaching Hospitals NHS Foundation Trust, Doncaster, United Kingdom, *[2]Community Tissue Viability Service Oxford Health Foundation Trust, Oxford, United Kingdom*, *[3]Regent Square General Practice, Doncaster, United Kingdom*

Aim: Collaboratively evaluate the impact of commencing an alginogel multimodal wound management approach to limit progression through the Infection Continuum to support Antimicrobial Stewardship. To establish if a multimodal wound management approach is deemed an effective early intervention in wound infection management which is easy to use across all settings.

Method: A multimodal product combining debridement, enzymatic antimicrobial activity, and moisture balance was used across 3 different settings (community care, primary care and secondary care outpatients setting). The limiting of progression through the Infection Continuum was determined by the reduction or removal of signs and symptoms linked to biofilm and bacteria presence present to the wound and patient.

Results / Discussion: The initial data (6 patients) shows an average wound duration prior to the product being implemented was 12 weeks, with the primary treatment aim as a wound filler and the second to prevent biofilm formation. All patients were able to have 50:50 ration of healthcare professional (HCP) involvement and self-care, with all showing signs of infection/biofilm with delayed wound healing. All wounds followed local wound hygiene pathway, with 33% (n=2) having mechanical debridement performed. 83% (n=5) of patients healed during the treatment period. All HCP stated that the change in treatment more effective than previous treatment with wound-related stress reduced in 83% (n=5) patients and HCP recommended the use of the product.

Conclusion: Findings suggest an alginogel-based multimodal approach supports early infection control, enhances healing, reduces wound-related stress, and is practical across care settings, indicating value for antimicrobial stewardship and routine clinical use overall.

EP234 No ESKAPE: Clinical and in vitro evidence for honey-based antimicrobial therapy

Daniela Chrysostomou[1], Adéla Holubová[2], Frank Wagener[3], Niels Cremers[4], Andrea Pokorná[5]

[1]Health@45, Johannesburg, South Africa, *[2]DiaPodi care, Sobeslav, Czech Republic*, *[3]Radboudumc, Nijmegen, Netherlands*, *[4]Maastricht University Medical Centre +, Maastricht, Netherlands*, *[5]Masaryk University, Brno, Czech Republic*

Aim: The ESKAPE pathogens (*Escherichia coli, Staphylococcus aureus, Klebsiella pneumoniae, Acinetobacter baumannii, Pseudomonas aeruginosa,* and *Enterococcus faecium*) pose an increasing global threat due to their multidrug resistance (MDR) and biofilm-forming capacities. With limited antimicrobial options available, alternative treatments are needed. This study evaluated the *in vitro* and clinical efficacy of medical-grade honey (MGH; L-Mesitran) against ESKAPE pathogens.

Method: The *in vitro* antimicrobial activity of MGH was assessed against all ESKAPE species using a standardized PET test (EU-PHARMA 04/2022:50103) with additional strains and alternative timepoints (6h, 24h, 2, 3, and 7

days). Twelve patients with hard-to-heal wounds and confirmed ESKAPE infections were prospectively included to assess the clinical efficacy. MGH-based dressings were changed twice per week; wound odour, infection indicators, debridement progression, granulation formation, and healing timelines were monitored.

Results / Discussion: MGH eliminated all ESKAPE species *in vitro* within 6h, except *E. faecium*, which required 24h. Clinical infections involved *E. coli* (n=7), *S. aureus* (n=6), *K. pneumoniae* (n=2), *A. baumannii* (n=2), *P. aeruginosa* (n=4), and *E. faecium* (n=6), along with 13 additional non-ESKAPE pathogens. Most wounds contained multiple species, with an average of 3.33 pathogens, including 2.25 ESKAPE species. Wound odour consistently abated after 1 dressing change, attributed to reduced bioburden and the shift from malodour-producing proteins to odourless carbohydrate metabolism provided by MGH. Autolytic debridement and infection control were typically evident within 2 weeks. Healthy granulation tissue gradually developed by 2-4 weeks, and full healing was achieved within 3-6 months.

Conclusion: MGH demonstrated rapid *in vitro* and clinical eradication of ESKAPE and other pathogens. These findings support MGH as a potent therapeutic option in hard-to-heal infected wounds and its potential for global MDR challenges.

EP447 Assessment of general practitioners' knowledge on the diagnosis and management of chronic wound infections: a cross-sectional study

Helmi Ernandes[1], Olfa Smaoui[2], Sahar Zelfani[1], Ikbel Kooli[1], Sahar Sallem[1], Ameni Bellaaj[1], Lamia Ammari[2]

[1]Mohamed Kassab Institute of Orthopedics, Manouba, Tunisia, *[2]La Rabta Hospital, Tunis, Tunisia*

Aim: To evaluate general practitioners' (GPs) knowledge and practices regarding the diagnosis and management of chronic wound infections in community settings.

Method: A descriptive cross-sectional online survey was conducted between September and December 2024 among community-based GPs. Participation was voluntary and anonymous. The questionnaire explored diagnostic criteria, microbiological sampling methods, and antibiotic prescription patterns. Data were analyzed using descriptive statistics and chi-square tests ($p < 0.05$)

Results / Discussion: A total of 114 GPs completed the survey. The mean age was 44 ± 9 years, and 58.8% (n = 67) had less than 10 years of clinical experience. Only 63.2% (n = 72) correctly identified the main clinical indicators of infection (erythema, increased exudate, odor, delayed healing). Regarding microbiological diagnosis, 36.8% (n = 42) recognized that tissue biopsy or deep aspirate is the preferred sampling technique, while 49.1% (n = 56) still indicated superficial swabbing, and 14.9% (n = 17) performed no sampling prior to antibiotic initiation. Empirical antibiotics were prescribed without microbiological confirmation in 55.3% (n = 63) of cases, most frequently amoxicillin–clavulanate (47.4%, n = 54) and fluoroquinolones (21.9%, n = 25). The duration of therapy exceeded recommendations in 39.5% (n = 45), and only 27.2% (n = 31) reported using local antiseptic measures. GPs who had attended wound-care training within the past two years (n = 39, 34.2%) showed significantly higher diagnostic accuracy and adherence to guidelines (82.1% vs. 58.7%, $p = 0.016$).

Conclusion: Significant gaps persist in GPs' diagnostic and therapeutic management of chronic wound infections, particularly in microbiological sampling and antibiotic use. Expanding targeted education and promoting evidence-based diagnostic practices are crucial to improve care quality and antimicrobial stewardship.

EP235 Modulating and sampling diabetic foot ulcer infections with ceramic wound dressings

Sana Shah[1], Jason Ashworth[1]

[1]*Manchester Metropolitan University, Manchester, United Kingdom*

Aim: Ceramic wound dressings provide a novel alternative to traditional medicated dressings for wound infection management. Ceramic dressings are reported to immobilise and remove bacteria from the wound, whilst lacking disadvantages (poor drug delivery/uptake, antimicrobial resistance) associated with medicated dressings.

The aims of this study were to investigate ceramic dressings as potential wound microbiome sampling devices and evaluate their biofilm removal capability in the context of diabetic foot ulcer (DFU) infections.

Method: Ceramic dressings were applied to multi-species biofilms in *ex vivo* models of DFU infections for 24 or 48 hours using clinical isolates from DFU patients with mild, moderate or severe infections. Bacterial recovery counts (n=9) were determined from spent dressings and equivalent biofilm sampling with M40 swabs. Residual biofilm counts (n=9), alongside imaging of spent dressings by scanning electron microscopy (SEM) and confocal microscopy, were used to assess biofilm removal. Spent dressings and swabs from infected DFU patients were processed for 16S sequencing of wound microbiomes.

Results / Discussion: There was significant ($P<0.05$) biofilm removal in DFU infection models following application of dressings for 24 hours (mild/moderate>70%; severe>60%) or 48 hours (mild/moderate>80%; severe>75%). Bacterial recovery and SEM/confocal assessments confirmed predominant bacterial sequestration by ceramic spheres, with substantially higher (9.4 to 51.9%) biofilm sampling efficiencies achieved from dressings than swabs (4.2 to 13.4%).

Microbiome analysis indicated narrower species diversity in DFU patients with severe infections compared to those with mild/moderate infections. Compared with corresponding swab sampling at the same wound site, dressings consistently demonstrated greater ($P<0.05$) bacterial abundance (dressing:swab=14.2) and diversity (dressing:swab=2.8).

Conclusion: Ceramic wound dressings were highly effective at DFU-associated biofilm reduction and might be a preferential sampling device for DFU microbiome investigations.

EP448 Microbiological isolation patterns in chronic wounds: A case series supporting topical antimicrobial stewardship

Sejla Kotoric Keser[1], Dzemilja Gacanovic[1 1]

[1]*Asa Hospital, Sarajevo, Bosnia and Herzegovina*

Aim: To present a case series of chronic wounds and evaluate how microbiological findings guided the use of topical antimicrobial strategies and debridement in the absence of systemic infection.

Method: Three chronic wound cases (>6 weeks) were analyzed: a diabetic foot ulcer, a venous leg ulcer, and a stage 3 pressure injury. Microbiological sampling was performed post-debridement, in line with EWMA recommendations. The wound bed was irrigated with sterile saline, and samples were collected using the Levine swab technique from a 1 cm^2 area of viable tissue under firm pressure. Swabs were processed within 2 hours, with aerobic and anaerobic cultures incubated at 35-37 °C. Isolates were identified using biochemical testing and the automated system VITEK® 2 (bioMérieux). Patients received topical antimicrobials (cadexomer iodine, PHMB gel, silver foam) and routine sharp debridement. Systemic antibiotics were not used in the absence of clinical signs of systemic infection. Wound area and microbiological profile were monitored for 6–10 weeks.

Results / Discussion: All wounds showed 49–59% area reduction within 6–10 weeks. Initial polymicrobial colonization (*Staphylococcus aureus*, *Pseudomonas aeruginosa*, *Proteus mirabilis*, *Enterococcus* spp.) shifted to monomicrobial flora or absence of Gram-negative organisms following topical treatment. No reinfection or adverse effects related to topical antimicrobials were observed.

Conclusion: Microbiology-guided topical antimicrobial therapy combined with debridement improved healing outcomes and reduced microbial burden while avoiding systemic antibiotic use. Larger controlled studies are warranted.

EP236 An old idea revisited: Bacteriophage therapy against antibiotic-resistant eskape-bacteria in a 3D human biofilm model

Nicolas Krüger[1], Sophie Charlotte Liegenfeld[1], Mandy Dittmer[1], Maria Geffken[1], Univ-Prof. Dr. Ewa Klara Stürmer[1]

[1]Universitätsklinikum Hamburg-Eppendorf, Hamburg, Germany

Aim: Bacteriophages are regaining attention as a promising alternative to conventional antibiotics in the fight against multidrug-resistant bacteria. Due to their high specificity and ability to lyse target pathogens, bacteriophage may provide effective treatment options for chronic wound infections. Although several case reports and *in-vitro* studies have demonstrated their therapeutic potential, translational models are required to validate phage efficacy and safety under clinically relevant conditions.

Method: A human plasma-based translational biofilm model incorporating buffy coat and *P. aeruginosa* PA14 was established. Phage lysates were isolated and enriched using optimized environmental protocols. The infected model was treated daily with two different lysates and their combination ("phage cocktail") and analysed after 24, 48, and 72 hours. Treatment effects were evaluated using confocal laser scanning microscopy, quantitative suspension assays, and image cytometry to assess bacterial reduction and biofilm structure.

Results / Discussion: The bacteriophage treatments led to a significant decrease in bacterial cell count and biofilm volume. Combined treatment with multiple bacteriophages did not result in higher eradication rates, suggesting that overall phage concentration primarily determines therapeutic efficacy. Nevertheless, phage cocktails remain of high clinical relevance, as they can broaden host range and provide robustness against bacterial resistance development within complex wound microbiomes.

Conclusion: Specific bacteriophages effectively reduce *P. aeruginosa* growth in a translational model, supporting clinical observations of successful phage therapy. Further studies addressing infection dynamics, immune interactions, and long-term stability are essential to pave the way for personalized phage-based approaches. Given the global rise of antimicrobial resistance, bacteriophages should once again be considered as a complementary or alternative therapeutic strategy.

EP237 Improving pathogen detection in non-healing wounds: A clinical evaluation of sonicated dressings and swabs

Adéla Holubová[1], Niels Cremers[2], Martin Krause[3], Jana Matějková[4], Andrea Pokorná[5]

[1]DiaPodi Care, spol. s r.o., Soběslav, Czech Republic, Soběslav, Czech Republic, *[2]Department of Gynecology and Obstetrics, Maastricht University Medical Centre, Maastricht, the Netherlands, Triticum Exploitatie BV, Maastricht, the Netherlands, Maastricht, Czech Republic*, *[3]Medical College, Department of Nursing, Prague, Czech Republic, Prague, Czech Republic*, *[4]Laboratory Synlab Czech s.r.o, Prague, Czech Republic, Military Health Institute, Ministry of Defence of the Czech Republic, Prague, Czech Republic, Prague, Czech Republic*, *[5]Department of Health Sciences, Faculty of Medicine, Masaryk University, Brno, Czech Republic, Brno, Czech Republic*

Aim: Non-healing wounds are frequently colonized by biofilm-forming microorganisms and are often associated with underlying comorbidities. Accurate microbiological diagnosis is essential for guiding targeted antimicrobial therapy. Prior investigations showed that sonication fluids from wound contact-materials may increase identification in number of pathogens than conventional swabs techniques. To assess whether sonication fluids derived from different sampling materials enhance bacterial detection in non-healing wounds.

Method: A prospective observational case study included seven patients with heterogeneous non-healing wounds treated with Hydroactive dressings (n = 7). Five microbiological samples were collected per patient:

1. Conventional wound swab (Levine technique, Amies medium)
2. Sonication fluid from used dressing (sterile tube)
3. Sonication fluid from the used dressing inoculated into blood culture bottles

4. Sonication fluid from a swab stick inoculated into blood culture bottles
5. Sonication fluid from a swab stick (sterile tube)

The number and diversity of pathogens were compared across the different sampling methods.

Results / Discussion: Across all samples, the conventional wound swab yielded the highest pathogen count (n = 22). Sonication fluid from swab sticks transported in sterile tubes demonstrated a nearly equivalent detection rate (n = 21). Lower pathogen presence was observed in blood culture bottles containing sonicate from dressings (n = 18) and from swab sticks (n = 16), followed by sonication fluid from dressings in sterile tubes (n = 14).

Conclusion: Sonicated swab samples detected pathogens at rates comparable to standard swabs, suggesting that sonication may both enhance microbiological accuracy and reduce the strictness required in conventional swab sampling techniques for non-healing wounds.

EP238 Prototype gelling fiber dressings incorporating quaternary polyethyleneimine demonstrate superior anti-microbial activity compared to commercial products

Bithi Chatterjee[1], Alexandria Kidd[2], Michelle Rudden[2], Jose Manuel Rey[1], Sandro Ferrari[1], Markus Rothmaier[1], Matthew Hardman[2], Holly Wilkinson[2], Ran Frenkel[1]

[1]Polaroid Therapeutics AG, Schlieren, Switzerland, *[2]Wound Innovation Institute, The University of Hull, Hull, United Kingdom*

Aim: To determine the anti-microbial characteristics of prototype gelling fiber wound dressings incorporating quaternary polyethyleneimine (QPEI) polymers designed with functional groups to enhance antimicrobial potency and prevent leaching into the wound bed. The functional characteristics of QPEI-incorporated prototype gelling fibers were evaluated relative to other commercially available gelling fibers containing silver.

Method: Prototype QPEI-dressings were assessed for anti-microbial efficacy against key wound pathogens *Staphylococcus aureus* and *Pseudomonas aeruginosa in vitro* using modifications of the EN 17854 test method. Characteristics evaluated included anti-microbial efficacy against high bioburden, durability of anti-microbial activity, as well as speed of action. *In vivo* efficacy (wound and dressing bioburden assessment) was also evaluated in a murine wound infection model.

Results / Discussion: *In vitro*, prototype QPEI-dressings effectively controlled increasing *S. aureus* inoculum densities (up to $1x10^9$ CFU) compared to silver-based comparator dressings and QPEI-free controls. Moreover, the anti-microbial effect of prototype QPEI-dressings was sustained over repeated daily challenges for up to seven days. Importantly, prototype QPEI-dressings exhibited significantly faster anti-microbial kinetics as compared to silver-containing dressings. Finally, prototype QPEI dressings were significantly more effective at managing *S. aureus* wound infection *in vivo* relative to dressings containing silver.

Conclusion: These findings indicate that prototype QPEI-wound dressings may provide a superior approach to preventing or controlling bacterial infections within the wound. Crucially, QPEI polymers act through a unique physical mechanism that, unlike traditional silver dressings, may limit the development of antimicrobial resistance. The rapid and sustained antimicrobial activity and the ability of prototype QPEI-dressings to manage high bioburdens may lead to better outcomes for patients with chronic wounds. Clinical studies will be required to confirm these promising *in vitro* and *in vivo* results.

EP239 Evaluation of 100% chitosan dressings in the management of complex non-healing wounds, in a community setting

Jacqueline Dark[1], Eva Harris[1]

[1]*HCRG Care Services Limited, Swindon, United Kingdom*

Background: Chronic, non-healing wounds present a significant challenge in community care. Common issues include persistent infection, pain during and between dressing changes, friable tissue prone to bleeding and trauma caused by frequent dressing removal and reapplication. These complications often prolong healing time, increase frequency of nursing visits, and negatively impact patient quality of life.

Aim: The evaluation assessed how 100% chitosan dressings with Bioactive Microfibre Gelling technology can manage complex wounds. Healing speed, frequency and duration of dressing changes, haemostatic effect, antimicrobial protection, and atraumatic removal, were assessed.

Method: 5 community-based patients with complex, slow-healing wounds were treated with the dressings. Measurements, clinical photography, and qualitative nursing feedback recorded progress.

Dressings were applied as a primary dressing according to patients' wound needs.

Results / Discussion: Dressings provided effective exudate management, maintaining a moist healing environment. Hemostatic properties helped control bleeding from friable wound beds. Pain and trauma during dressing changes were noticeably reduced. Dressing change frequency decreased significantly, reducing clinical burden of healthcare services, and improving patient comfort.

All signs of wound persistent infection resolved within 2-4 weeks. Mean average wound % reduction was 80% (32-day mean average).

Patient	Wound surface onset	Wound Surface Area % Reduction	Duration of Treatment (Days)
1	900mm^2	72%	42
2	5950 mm^2	95%	24
3	848 mm^2	100%	17
4	875 mm^2	54%	44
5	Multiple scattered erosions	Visual Improvement: reduced bleeding/ trauma.	

Conclusion: The dressings demonstrated positive outcomes in healing rates, patient comfort, and reduced clinical burden. Further, larger-scale evaluation could confirm its potential as a multi-functional, cost-effective dressing for community wound management.

EP240 Assessing the speed of antimicrobial activity of a nitric oxide-generating dressing against antibiotic-resistant wound pathogens

Tilly Coleborn[1], Emma Griffiths[1], Kate Meredith[1], Daniel Metcalf[1]

[1]*Convatec, Deeside, United Kingdom*

Aim: Hard-to-heal wounds, such as diabetic foot ulcers, are at high risk of developing infection. A nitric oxide (NO)-generating dressing (NOGD) has been designed to generate antimicrobial NO within the dressing. The aim of this study was to evaluate the speed of antimicrobial activity of NOGD against multidrug-resistant *Pseudomonas aeruginosa* (RPA) and methicillin-resistant *Staphylococcus aureus* (MRSA) using an *in vitro* direct inoculation model.

Method: An adapted version of the AATCC 100 antimicrobial susceptibility standard method was used. Dressings were inoculated with ~1×10^6 colony-forming units (CFU) of challenge microorganism and incubated at 35±3°C for 5, 10, 15 or 30 minutes, or 1, 4, or 24 hours. Viable counts were determined at these timepoints using dressing extracts after neutralisation of nitric oxide activity. A non-antimicrobial dressing served as control throughout the test period.

Results / Discussion: NOGD demonstrated rapid antimicrobial activity, reducing RPA to undetectable levels (<30 CFU) within 1 hour and MRSA to undetectable levels within 4 hours. Initial rapid reductions were evident at just 10 minutes for RPA and 15 minutes for MRSA. The non-antimicrobial dressing maintained bacterial viability throughout.

Conclusion: NOGD provides rapid and sustained antimicrobial activity against clinically relevant resistant pathogens, achieving rapid reduction in minutes and complete kill within hours. Gaining rapid source control in locally infected wounds is an appealing prosect for clinicians, especially in wounds at high risk of infection complications. The speed of action of NOGD has the potential to support improved infection prevention and resolution in hard-to-heal wounds.

EP449 Epidemiology of nosocomial wound and bloodstream infections in hospitalized burn patients: A 5-year retrospective study

Yu-Chuan Tseng[1], Chiung-Tzu Hsiao[1], Meng-Yu Cheng[2], Cho-Han Wu[3 4], Po-Ren Hsueh[1 2 3]

[1]Department of Laboratory Medicine, China Medical University Hospital, taichung city, Taiwan, *[2]Department of Infectious Diseases, Department of Internal Medicine, China Medical University Hospital, Taichung City, Taiwan*, *[3]College of Medicine, China Medical University, taichung city, Taiwan*, *[4]Burn Center, Department of Surgery, China Medical University Hospital, Taichung City, Taiwan*

Aim: To investigate the distribution of pathogens causing nosocomial wound infections and bloodstream infections (BSIs) in hospitalized burn patients.

Method: This retrospective study included burn patients admitted between September 2020 and November 2025. Wound and blood culture isolates were analyzed using standard microbiological methods, and the time to first positive culture was recorded.

Results / Discussion: A total of 163 hospitalized burn patients were included, of whom 80 had positive pus cultures, yielding 196 nosocomial isolates. The leading pathogens were methicillin-resistant *Staphylococcus aureus* (MRSA, 19.4%), carbapenem-resistant *Acinetobacter baumannii* (CRAB, 15.8%), and *Pseudomonas aeruginosa* (10.2%). Other common isolates included *Klebsiella pneumoniae*, *Enterococcus faecalis*, *Enterobacter cloacae*, and *Escherichia coli*.

Among the 80 patients with positive wound cultures, 22 also had positive blood cultures, yielding 40 bloodstream isolates. The most frequent bloodstream pathogens were MRSA (20.0%) and CRAB (20.0%), followed by *Enterococcus faecium* (12.5%) and *Pseudomonas aeruginosa* (10.0%). Fungal pathogens, including *Candida* species and *Trichosporon asahii*, were also identified. Some bloodstream isolates were identical to the corresponding wound isolates. The median time from admission to BSI was 9.5 days (IQR, 7–12 days).

Conclusion: Multidrug-resistant organisms, particularly MRSA and CRAB, predominated in both wound infections and BSIs among hospitalized burn patients. In this retrospective cohort, wound colonization was observed at a median of 7 days after admission and was followed by BSI with identical pathogens within approximately 3.6 days, defining a critical window for early intervention. MRSA and CRAB each accounted for 20.0% of all BSIs, ranking as the two most frequent bloodstream pathogens in this population, while CRAB further reflects the substantial burden of resistant Gram-negative pathogens in hospitalized burn patients.

EP241 Assessing the sustained antimicrobial activity of a nitric oxide-generating dressing using antibiotic-resistant wound pathogens in a repeated inoculation model

Tilly Coleborn[1], Emma Griffiths[1], Kate Meredith[1], Daniel Metcalf[1]

[1]*Convatec, Deeside, United Kingdom*

Aim: Hard-to-heal wounds, such as diabetic foot ulcers, are at high risk of infection. A nitric oxide (NO)-generating dressing (NOGD) has been designed to generate antimicrobial NO within the dressing. The aim of this study was to evaluate the sustained nature of the antimicrobial activity of NOGD following repeated inoculations of antibiotic-resistant pathogens into the same dressings over 168 hours.

Method: An *in vitro* direct inoculation model adapted from the AATCC 100 antimicrobial susceptibility standard method was used. The same test dressings were directly inoculated then re-inoculated with ~10^6 colony-forming units (CFU) of multidrug-resistant *Pseudomonas aeruginosa* (RPA) or Methicillin-resistant *Staphylococcus aureus* (MRSA) at 0, 24, 48, 72 or 144 hours. Viable counts on dressing extracts, after neutralisation of nitric oxide activity, were conducted at 1, 4 or 24 hours after each inoculation/re-inoculation. A non-antimicrobial dressing served as control throughout the 35±3°C, 168-hour test period.

Results / Discussion: NOGD consistently reduced both RPA and MRSA counts to near or below detection (<30 CFU/dressing) within 24 hours of each inoculation/re-inoculation, often within 1–4 hours, demonstrating rapid and sustained antimicrobial efficacy. After the final re-inoculation at 144 hours, both RPA and MRSA were still reduced by at least 4 $\log_{10}$ within 24 hours. The non-antimicrobial dressing maintained bacterial viability throughout. These results confirm the sustained antimicrobial activity within NOGD under prolonged and repeated bacterial challenge.

Conclusion: NOGD demonstrated rapid and sustained antimicrobial protection against resistant pathogens over extended periods, highlighting its potential in managing hard-to-heal wounds with ever-present infection risk.

EP242 Systematic review on antimicrobial resistance: The role of biophysical technology and the RAM 2025 Consensus

Natalia Barros[1], Alessandra Miranda Garcia Storti[1], jessica Morato[1 1 1]

[1]*Essity do Brasil, São Paulo, Brazil*

Aim: To synthesize the available evidence on strategies for the prevention and management of antimicrobial resistance (AMR), with emphasis on biophysical technology and the recommendations of the RAM 2025 Consensus, aiming to identify innovative approaches for microbial load control in wounds.

Method: A systematic review conducted in international databases (PubMed, Scopus, Cochrane Library), including studies published between 2015 and 2025. Articles addressing physical mechanisms in AMR control, such as the use of dialkylcarbamoyl chloride (DACC), and international guidelines (EWMA, JWC) were selected. The analysis included clinical trials, integrative reviews, and scientific consensus documents.

Results / Discussion: The review identified consistent evidence that technologies with a physical mechanism, such as DACC, reduce microbial load through hydrophobic adsorption without inducing resistance, representing a safe alternative to the indiscriminate use of antimicrobials. Clinical studies demonstrated a reduction in healthcare-associated infections and a lower risk of resistant strain selection. The RAM 2025 Consensus reinforces the need to integrate non-pharmacological strategies, continuous education, and evidence-based protocols to mitigate AMR.

Conclusion: Biophysical technologies represent a significant advancement in addressing antimicrobial resistance, aligned with the recommendations of the RAM 2025 Consensus. Incorporating these approaches into clinical protocols can optimize outcomes, reduce adverse events, and contribute to sustainable practices in infection control.

EP450 Clinical evidence supporting PHMB foam in antimicrobial stewardship and wound healing

Alex Lawton[1], Rachel Burns[1], Rebecca Forder[1]

[1]*Advanced Medical Solutions Ltd, Winsford, United Kingdom*

Aim: To summarize clinical evidence for the effective use of a PHMB Foam dressing* in the treatment of infected chronic and acute wounds, and wounds at risk of infection.

Method: An open-label, single arm trial at one investigational site with subjects with moderate to heavily exuding chronic and acute wounds was executed. This was conducted according to approved protocol, GCP principles, Declaration of Helsinki and ISO14155. In total 185 patients were recruited with a variety of chronic and acute superficial wounds that were infected or at risk of infection. PHMB dressings were applied with a weekly follow up. Dressings were changed according to clinical need up to 6 weeks when the assessment ended.

Results / Discussion: Treatment of a variety of infected wounds exhibited a 81.4% reduction in the signs and symptoms of infection when treated with the antimicrobial dressing. Clinicians saw 94.6% of wounds showed measurable wound healing progress. 98.8% of clinicians found the exudate management by the dressing enhanced peri-wound skin condition, reducing devitalized tissue and promoting wound progression/healing through a moist environment.

Conclusion: The clinical use of PHMB Foam dressing in the treatment of a variety of chronic and acute infected wounds, and wounds at risk of infection has demonstrated that it reduced infection whilst managing exudate, and promoting wound progression.

*ActivHeal PHMB Foam dressing

EP243 A multimodal dressing NO-generating: An option for both acute and chronic wounds

Francesca Pasquali[1], Mara Roncali[1], Ilaria Cerino Badone[1], Alessandra Demartini[1]

[1]*ASLAL, Alessandria, Italy*

Aim: In high-risk populations—such as immunocompromised, immobile, elderly individuals, or those with diabetes or circulatory disorders—compromised innate immunity and suboptimal antimicrobial treatments pose serious health challenges. This study evaluates the clinical effectiveness of a multimodal nitric oxide (NO)-generating dressing in managing acute and chronic wounds, focusing on pain reduction, accelerated healing, and antimicrobial benefits without systemic antibiotics.

Methods: Eight patients received treatment with the NO-generating dressing. Four reported complete pain resolution during work and dressing changes; the remaining four were pain-free due to diabetic neuropathy, including one with Chronic Inflammatory Demyelinating Polyneuropathy (CIDP). No systemic antibiotics were used. Clinical assessments at baseline and follow-up examined wound bed condition, periwound skin integrity, and healing progression.

Results/Discussion: Significant improvement was evident within 72 hours. Wounds decreased by approximately one-third with each dressing change, and margins contracted toward the center. Periwound skin remained healthy, wound edges closed progressively, and wound beds were clean. The NO-generating dressing demonstrated strong antimicrobial and antibiofilm activity, disrupting biofilms and eradicating microorganisms in hard-to-heal wounds such as diabetic foot ulcers. Complete healing occurred within 12 weeks, potentially reducing social costs by minimizing absenteeism. Pain reduction in non-neuropathic cases improved quality of life. Its robust antibiofilm properties offer a critical advantage against antibiotic resistance - a major global health concern.

Conclusion: The NO-generating multimodal dressing is a safe, effective solution for acute and chronic wounds, including complex diabetic ulcers. By accelerating healing, alleviating pain, and delivering potent antimicrobial action without systemic antibiotics, it optimizes resources and supports efforts to combat antibiotic resistance.

EP245 Challenging the limits of limb preservation in advanced lower limb necrotizing fasciitis

Mohamed Zaied[1]

[1]*Faculty of Medicine, Kafrelsheikh University, Kafrelsheikh, Egypt*

Aim: To challenge the traditional assumption that extensive lower-limb necrotizing fasciitis mandates early amputation, and to demonstrate that limb salvage is achievable even when more than 50% of the soft-tissue envelope is destroyed.

Method: A prospective case series of 46 patients aged 10–50 years presenting with advanced lower-limb necrotizing fasciitis involving >50% of the limb soft tissue was conducted. Diabetes mellitus was present in 50% of cases.

All patients underwent immediate, radical surgical debridement, including excision of necrotic skin, subcutaneous tissue, and deep fascia, with serial re-exploration and re-debridement until complete infection control was achieved. Empirical broad-spectrum intravenous antibiotics covering gram-positive, gram-negative, and anaerobic organisms were initiated on admission and subsequently tailored based on microbiological cultures.

Once sepsis was controlled, all wounds were managed with negative pressure wound therapy (NPWT) to accelerate granulation and wound stabilization, followed by split-thickness skin grafting as definitive reconstruction.



Fig 1: Case showing extensive NF and stages of extensive debridement, dressing, VAC, grafting, complete healing of wounds and achieving of limb salvage.

Results / Discussion: Limb salvage was achieved in 42 of 46 patients (91.3%), despite extensive tissue loss and high-risk comorbidity. Only four patients (8.7%) required above-knee amputation, exclusively due to persistent, treatment-resistant infection.

Conclusion: Extensive lower-limb necrotizing fasciitis, even when exceeding 50% soft-tissue destruction and complicated by diabetes, does not mandate primary amputation. Radical debridement, early broad-spectrum antibiotics, NPWT, and staged reconstruction can reliably achieve limb preservation in the vast majority of patients. These results demand a redefinition of amputation thresholds and support a limb-first, salvage-oriented strategy in advanced necrotizing fasciitis.

PHD RESEARCH-IN-PROGRESS

EP808 Prevalence survey and quality of care analysis for complex wounds in the university acute care hospital sector

Leah Dörr[1]

[1]*Universitätsklinikum Bonn, Zentrales Wundmanagement, Bonn, Germany*

Stage of PhD: Leah Dörr (APN Wound care) has been completing her doctoral studies at

University Witten/Herdecke since 202. The doctoral program and the pilot study for the research project have now been completed.

Background: Due to unreported cases and varying/missing prevalence data on chronic

wounds in the acute hospital sector, the potential of this sector to solve the known care deficit remains unclear. However, this sector represent a previously untapped resource for addressing the lack of diagnostics and structured care concepts for people with chronic wounds.

Aims: The primary aim of the research project is to record the point prevalence of acute and

chronic wounds in a German university hospital. This should provide figures on whether and to what extent this sector has potential in addressing the national care deficit for chronic wounds. The secondary aim is to record the quality of care for hospitalized patients with acute and chronic wounds in acute care in order to determine the extent to which the hospital sector is already being exploited and what barriers currently exist.

Methods & Current progress: A cross-sectional and partial survey study will be conducted

2026 to prospectively evaluate patient data from the University Hospital Bonn (UKB) quantitatively. The study protocol for this was tested in a pilot study in the fourth quarter of 2025.

Nex steps: The pilot study already showed that patients with chronic wounds could be

detected through observation, despite the small number of participants (n = 20). Based on the experiences of the pilot study, the area of reporting on affected individuals and their chronic wound care situation needs to be adjusted.

Anticipated impact/translation: The results of the study will be used to uncover unreported

cases, make structured data usable, and develop improved nurseled pathways for patients with chronic wounds in German acute care hospitals where the APN role is still new.

Ethics: The ethics vote of the University of Bonn has been obtained on September 11, 2025,

under file number 2025-334-BO.

EP810 Artificial intelligence-mediated clinical judgement in nursing: A sequential multimethod experimental study on pressure injury prevention in intensive care

José Alves[1], Carla Pais-Vieira[1], Paulo Alves[1]

[1]*Center for Interdisciplinary Research in Health, Faculty of Health Sciences and Nursing, Catholic University of Portugal, Porto, Portugal*

Stage of PhD: Year 3 – Empirical Design Phase

Background: Pressure injuries (PIs) remain a frequent and largely preventable complication in intensive care units, where prevention relies on nurses' clinical judgement under conditions of uncertainty, time pressure and high cognitive load. While artificial intelligence (AI) has been extensively studied for risk prediction, critical gaps remain in understanding how AI-mediated information shapes nurses' reasoning processes, confidence and cognitive workload during preventive decision-making. Current research predominantly evaluates decision outputs or algorithmic accuracy, overlooking the cognitive and judgement-related mechanisms through which AI may support, or inadvertently disrupt, clinical practice in wound care.

Aim: To examine how AI-mediated informational support influences nurses' clinical judgement processes, decision quality, confidence and cognitive workload during PI prevention in intensive care.

Methods & Current Status: This PhD adopts a sequential multimethod design. Phase 1 (completed) comprised two scoping reviews on AI-based PI prediction and AI support for clinical judgement in nursing. Phase 2 (ongoing) focuses on the development and content validation of realistic intensive care PI prevention vignettes. Phase 3 will analyse nurses' questions during interaction with a clinical chatbot to identify cognitive support needs and develop a taxonomy of judgement-related informational demands. Phase 4 involves a controlled pilot simulation study in which nurses assess clinical vignettes with and without standardised AI support. Outcomes will include judgement quality, decision confidence and objective neurocognitive indicators of cognitive workload derived from electroencephalography.

Anticipated Impact: By shifting focus from algorithmic performance to nurses' clinical judgement processes, this project will generate practice-oriented evidence to inform the design of cognitively aligned, ethically grounded and clinically usable AI decision-support systems for PI prevention. Findings will identify what information, when, and in which format AI support most effectively strengthens nurses' judgement under high cognitive load. The project is expected to reduce unwarranted variability in preventive decision-making, enhance patient safety, and support responsible AI integration into wound care practice, professional education and evidence-informed clinical guidelines.
Ethics: Ethical approval and informed consent will be obtained prior to data collection. All procedures will comply with data protection regulations, including secure handling of neurophysiological, simulation and interaction data.

OP158 Development and validation of a cross-platform mobile application for prescribing compression garments

Ruben Molina Carrilo[1]

[1]*Catalan Health Institute, Barcelona, Spain*

Stage of PhD: Final-year PhD candidate; currently conducting the fourth and final study phase.

Background: Medical compression garments are central to managing leg ulcers and lower-limb oedema, but the high degree of personalization, the variety of materials, and limited specific training make precise and consistent prescribing difficult. Many healthcare professionals feel uncertain when recommending compression due to lack of experience, continuing education, and consensus. No validated digital algorithm currently supports this decision-making process. A validated tool could transform care by providing compression garment recommendations based on clinical data and expert consensus.

Aims: To develop and validate a cross-platform mobile application that assists healthcare professionals in the personalized selection of compression garments for patients with diverse therapeutic needs.

Specific aims are: (1) to develop an algorithm based on a synthesis of scientific evidence and validate its content using the Delphi method; (2) to design and program an interactive cross-platform mobile application that implements this algorithm; and (3) to evaluate the accuracy of the algorithm by comparing compression garment recommendations made by healthcare professionals with and without the application.

Methods & Current progress: The study is conducted in four phases: (1) scoping and integrative reviews of the literature on the use and effectiveness of medical compression garments; (2) algorithm development based on review findings and expert consensus using the Delphi method; (3) development of a cross-platform mobile application, followed by a usability study; and (4) construct validity, using a quasi-experimental study to evaluate the effectiveness and reliability of the algorithm in clinical practice. The project is currently in the fourth phase, with ongoing recruitment.

Next steps: Completion of recruitment and data analysis for the fourth phase, followed by manuscript preparation and thesis writing.

Anticipated impact/translation: A more precise and user-friendly recommendation process is expected to increase the frequency and appropriateness of compression garment prescriptions, enhance healthcare professionals' confidence and engagement with compression therapy, and improve patient adherence. The algorithm and mobile application are available in Spanish, German and English.

Ethics: The study has been approved by the Research Ethics Committee and evaluated by the Spanish Agency of Medicines and Medical Devices (AEMPS).

EP811 AI-enhanced educational model to improve nursing students' knowledge of wound bed assessment

Rúben Encarnação[1]

[1]*Centre for Interdisciplinary Research in Health, Faculty of Health Sciences and Nursing, Universidade Católica Portuguesa, 4169-005, Porto, Portugal, Cardiology Intensive Care Unit, São João Local Healthcare Unit, 4200- 319, Porto, Portugal, Porto, Portugal, Porto, Portugal*

Stage of PhD: Early stage (analysis completed; ADDIE design phase in progress).
Supervisors: Dr. Paulo Alves; Dr. João Reis.
Background: Accurate wound bed assessment is a critical nursing competency and a key determinant of diagnostic accuracy, care planning, and the monitoring of healing outcomes. Despite its clinical relevance, gaps in nursing students' knowledge and confidence are consistently reported. Artificial intelligence (AI), particularly through chatbot-based learning, offers new opportunities to support interactive, accessible, and personalized educational strategies.

Aims: To develop and evaluate the effectiveness of an AI-supported educational model in improving nursing students' knowledge of wound bed assessment.

Methods & Current Status: This PhD project follows the ADDIE instructional design model.

1. Analysis: A scoping review titled *"Artificial intelligence in wound care education: Scoping review"* (DOI: 10.1016/j.nedt.2025.106872) has been published.
2. Design (ongoing): A scoping review is being finalized to inform a focus group with wound care experts, and an instrument will be constructed to assess nursing students' wound bed assessment knowledge.
3. Development (pending): Development of the AI chatbot and educational materials will begin after integrating expert input.
4. Implementation (planned): A quasi-experimental pilot study with pre-/post-test design will be conducted with undergraduate nursing students to evaluate feasibility and learning outcomes.
5. Evaluation: Guided by the Kirkpatrick Model (Levels 1–3), focusing on satisfaction and knowledge acquisition.

Next Steps: Conduct the expert focus group, complete the assessment instrument, and initiate the development of the chatbot and learning materials.

Anticipated Impact/Translation: This project addresses a critical educational need in wound care by delivering an evidence-based, scalable model that strengthens wound bed assessment competencies through AI-enhanced learning. Intended for national implementation and with strong potential for international adoption, the tool aims to improve clinical reasoning and diagnostic accuracy, elevate care standards, and advance evidence-based practice. Moreover, it supports the global expansion of digitally mediated learning, aligning with United Nations Sustainable Development Goals 4 and 9.

Ethics: Ethical approval has been submitted to the Ethics Committee for Health of the Universidade Católica Portuguesa and is currently pending.

OP159 Exploring biomarkers for early skin tissue damage in vulnerable skin sites: Implications for precision health

Amanda Feldt[1]

[1]*Clinical Department of Geriatrics and Palliative Medicine in Linköping, Region* Östergötland*, Linköping, Sweden, Department of Health, Medicine and Caring Sciences, Linkoping University, Linköping, Sweden*

Supervisors: Sara Bergstrand, Peter Worsley, Bijar Ghafouri & Mats Lowén.

The skin is a complex organ essential for tissue homeostasis through its barrier, immune, and inflammatory functions, and early tissue damage may occur before visible changes are apparent. The etiology of early skin damage caused by mechanical loading and chemical irritants remains incompletely understood, and pressure ulcers and incontinence-asociated dermatitis (IAD) are often difficult to differentiate despite demanding different treatments. Misclassification may result in delayed healing and increased patient burden. This thesis investigates early inflammatory skin responses associated with routine use of oronasal facemasks in hospital settings and with IAD. The identification of reliable biomarkers may improve diagnostic precision and enable targeted, condition-specific care, addressing both knowledge gaps and patient outcomes.

The **overall aim** of this thesis is to identify and validate combinations of biomarkers for early skin damage following the routine use of face masks, as well as for incontinence-associated dermatitis (IAD), and to explore clinical nursing strategies to improve the early detection and treatment of skin damage in patients with vulnerable skin.

I am currently conducting my fourth and final study, two studies have been published and the third is under review. The studies employ varied **methodological approaches** *(Figure 1).* The studies demonstrate practical nursing strategies and identify potential biomarkers and sampling windows that differentiate inflammatory responses in IAD and mechanical loading. Collectively, this work lays important groundwork for future biomarker discovery, with potential to enable objective skin health monitoring and to advance understanding of individual thresholds for skin tissue damage.

Ethical approval was not required for Study I, as it did not involve procedures covered by the Ethical Review Act (2003:460) and no personal data under the GDPR were collected; nevertheless, all studies were conducted in accordance with the

Declaration of Helsinki and relevant Swedish legislation. Studies II–IV were approved by the Swedish Ethical Review Authority.

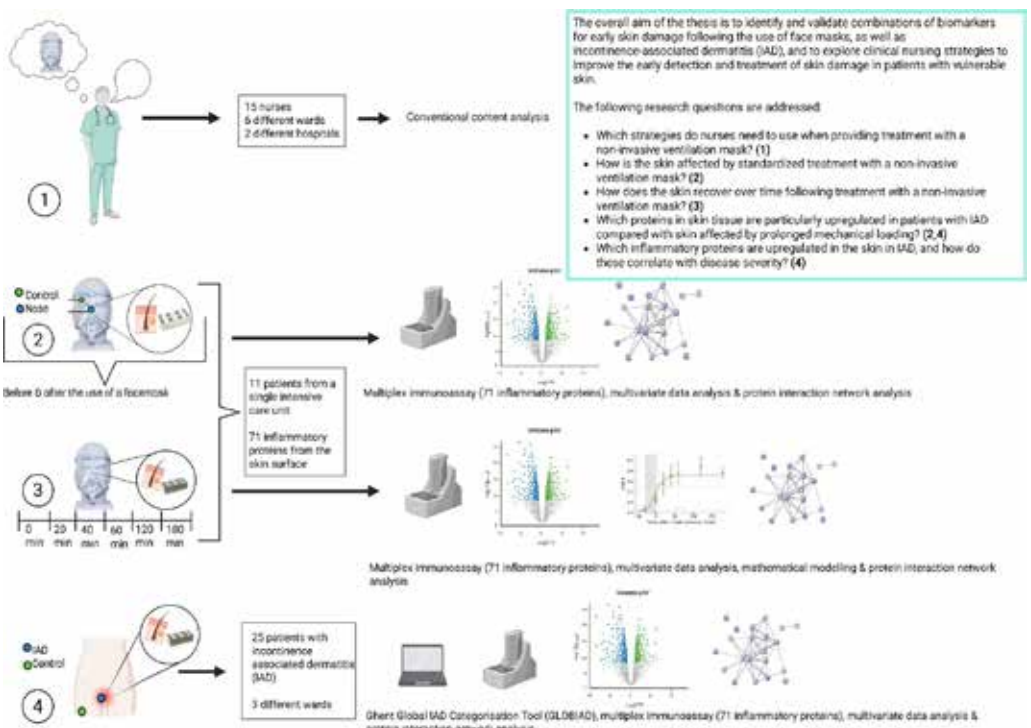

Figure 1. Schematic overview of the four studies included in the thesis, illustrating the specific research aims and methods applied in each study.

EP812 Effect of fractional ablative CO_2 laser on the healing process of venous leg ulcers: Protocol and early-stage development of a clinical investigation study

Victor Gadea Lopez[1]

[1]*Dermatology and Tissue Regeneration Research Unit, Health Research Institute La Fe, Valencia, Spain*

Stage of PhD: Second-year PhD candidate.

Background: Venous leg ulcers (VLU) are the most common chronic lower-limb wounds and pose substantial clinical and economic challenges. Despite advances in compression therapy, many VLUs remain difficult to heal. Fractional ablative CO_2 laser has shown potential benefits in tissue regeneration, collagen synthesis, and modulation of cytokines and growth factors involved in wound repair. Previous studies have reported favourable outcomes in non-healing wounds of various etiologies, no clinical investigation has specifically assessed its use in venous ulcers. This project aims to generate new evidence supporting its potential role as an adjunctive therapy in VLU management.

Aims: The primary aim is to determine the efficacy of fractional ablative CO_2 laser in promoting healing in adult patients with VLU. Secondary aims include evaluating pain, quality of life, bacterial load, and documenting procedure-related complications.

Methods & Current Progress: This single-centre, evaluator-blinded clinical investigation of a medical device will recruit 36 adults randomized 1:1 to an intervention group (CO_2 laser + standard care) or a control group (standard care). Randomisation will be stratified by the presence of significant incompetent perforator veins. All participants will undergo vascular assessment including Ankle-Brachial Index (ABI) and venous duplex ultrasound.

Laser therapy will be delivered monthly (50 mJ, 5% density, fractional ablative mode) alongside optimal wound care and 40 mmHg compression. Follow-up will occur weekly or biweekly, including clinical assessment, photography, hyperspectral imaging (TIVITA), pain scoring, and bacterial load analysis.
The study is currently in the preparatory phase. The protocol, regulatory documents, data collection tools, SOPs, and multidisciplinary workflow have been completed.

Recruitment has not yet begun.
Next Steps: Initiate recruitment, deliver monthly laser sessions, and collect clinical, imaging, and microbiological data over six months.

Anticipated Impact/Translation: If effective, CO_2 laser may accelerate healing, reduce care demands, and improve quality of life. Findings could support future multicentre studies and guide clinical implementation.

Ethics: Ethical approval will be obtained, and all participants will provide written informed consent.

OP160 Use of ultrasound by advanced practice nursing in the assessment of complex and long-term wounds in primary care. A study with a quantitative and qualitative approach

Alvaro Vilela Pajaro[1]

[1]*University of Lleida (UdL), GRECOCAP Research Group (IDIAP), Lleida, Spain*

Stage of PhD: Fourth year of doctoral studies (data collection and analysis in progress).
Background: Chronic wounds pose a clinical and economic challenge, requiring accurate assessment to guide treatment and prevent complications. Ultrasound helps evaluate key structures and healing processes, yet its use by nurses remains limited. Still, evidence shows it is a promising tool for advanced practice nursing.
Aims:

1. Analyse the current knowledge and available evidence on the use of ultrasound in the assessment, diagnosis, treatment, prevention, and follow-up of chronic wounds.
2. Determine the ultrasound signs that help in the prevention, assessment, and follow-up of chronic wounds.
3. Compare the differences in ultrasound values between different types of wounds and their progression.

Methods: Design: A mixed-methods project that includes a scoping review, a quantitative descriptive study with over 100 patients, and a qualitative component with healthcare professionals who treat wounds.

Current Status: The scoping review has been completed following the PRISMA-ScR guidelines and using tools from the Joanna Briggs Institute (JBI). The descriptive and qualitative studies are ongoing, with data and variable collection in progress

Next steps:

- Complete the data collection.
- Develop the study results.
- Integrate all the results to develop an evidence-based implementation framework for ultrasound in advanced nursing practice.

Anticipated impact / Translation: This project will generate evidence for the integration of ultrasound into advanced practice for the management of chronic wounds. Its results may:

- Improve diagnostic accuracy and early detection of complications.
- Optimize clinical decision-making and individualized care planning.
- Facilitate more objective and systematic monitoring of wound progression.
- Contribute to the design of specific training programs.
- Increase healthcare system efficiency through better management of chronic wounds.

Ethics:

- Ethical approval has been obtained from the Ethics Committee, and all data are anonymized and managed in accordance with current ethical standards and data protection regulations.

Supervisor:

- Joan Enric Torra i Bou (University of Vic, GNEAUPP)
- Laura Martinez Rodriguez (University of Barcelona)

Photographs

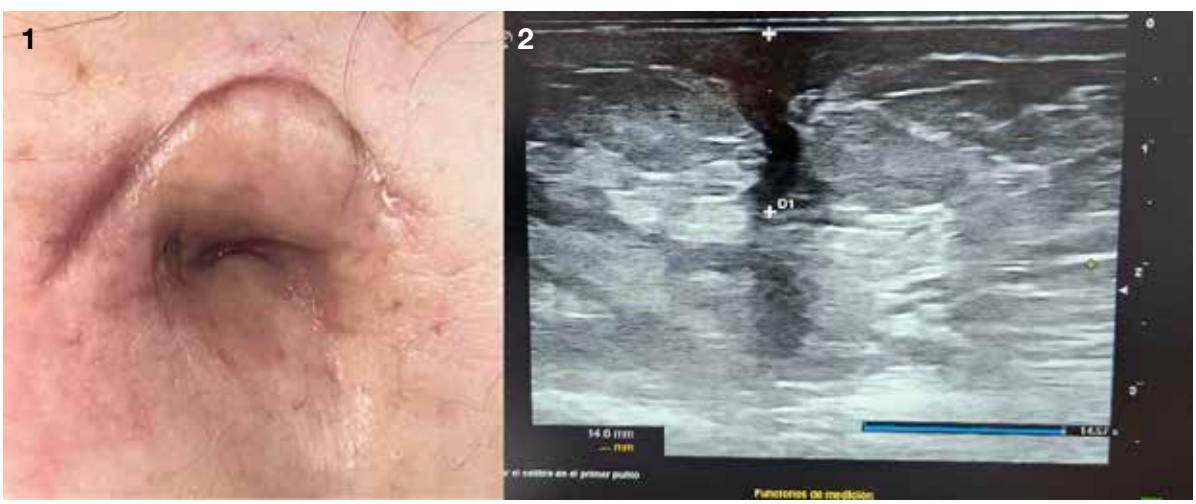

1. Image of a wound with abundant exudate, preventing exploration of the cavity.
2. Ultrasound image showing a depth of 1.5 cm, with no presence of tunneling.

EP813 A cell-free strategy for diabetic wound healing: Secretome from deciduous tooth MSCs as a promising therapeutic approach

Lívia Bitencourt Pascoal[1], Gisele Mara Silva Goncalves[1], Gabriele Guarieiro[1], Dayane Melo[1], Vanessa Pellegrini[1], Jéssica dos Santos Jacinto[2], Lício Augusto Velloso[3], Eliana Pereira Araujo[2]

[1]Pontifical Catholic University of Campinas (PUC-Campinas), School of Life Sciences, Faculty of Veterinary Medicine, [2]School of Nursing, Universidade Estadual de Campinas, Campinas, Brazil, [3]Obesity and Comorbidities Research Center, Universidade Estadual de Campinas, Campinas, Brazil

Aim: To evaluate the healing potential of the secretome derived from mesenchymal stem cells (MSCs) extracted from human deciduous tooth pulp in an experimental model of diabetes.

Method: Diabetes was induced in C57BL/6J mice using a low dose of streptozotocin. After confirmation of hyperglycemia, animals were anesthetized and subjected to a surgical procedure in which a 6-mm punch biopsy was used to create a full-thickness excisional wound, stabilized with a circular suture and silicone rings. The mice were then divided into two groups: one treated with a placebo-containing hydrogel and the other with a hydrogel enriched with the MSC secretome. All wounds were covered with Tegaderm dressings. Treatments were applied daily until complete closure in the secretome-treated group. Wounds were photographed every 48 hours for healing assessment. After cutaneous closure, animals were euthanized, and wound tissues were collected for real-time PCR, histological evaluation, and Masson's trichrome staining. Ethical Approval: All procedures were approved by the Institutional Animal Care and Use Committee (CEUA), under protocol CEUA nº 001/2025.

Results / Discussion: Mice treated with the secretome-containing hydrogel exhibited significantly faster wound closure compared with placebo-treated controls. Histological analyses revealed a more intense inflammatory infiltrate in the control group, characterized by abundant macrophages and polymorphonuclear cells. In contrast, secretome-treated wounds displayed increased fibroblast activity, enhanced collagen deposition, and tissue organization consistent with a more advanced healing stage.

The placebo group showed incomplete re-epithelialization, with keratinocytes migrating toward the wound center, whereas secretome-treated wounds presented a fully formed and well-organized epidermis across the entire lesion.

Conclusion: The secretome from deciduous tooth pulp MSCs significantly improved wound healing in diabetic mice by accelerating closure, reducing inflammation, and promoting tissue regeneration. These findings highlight its potential as a promising cell-free therapeutic strategy for the treatment of diabetes-impaired wounds.

EP814 Management of pressure ulcers in intensive care units: Development and evaluation of an educational model

Sofia Vieira1

[1]Universidade Católica Portuguesa – Faculdade de Ciências da Saúde e Enfermagem/ Porto: Portugal, Centro de Investigação Interdisciplinar em Saúde (CIIS)/ Wounds Research Lab/ Porto: Portugal., Porto, Portugal

Stage of PhD: Project under development.

Background: Pressure ulcers (PU) are highly prevalent yet preventable complications in critically ill patients, associated with increased morbidity, prolonged hospitalisation and higher healthcare costs. In Intensive Care Units (ICUs), risk is amplified by clinical instability, immobility and extensive device use. Effective prevention requires specialised knowledge; however, evidence indicates persistent knowledge gaps among nurses. The lack of validated ICU-specific assessment tools and personalised digital education highlights the need for innovative, evidence-based educational solutions.

Aims: To develop, implement and evaluate a personalised digital educational model for PU prevention in ICUs, informed by individual performance on the DecubICUs-test.

Methods and Current Progress: The project is structured into four phases. Phase 1, a retrospective epidemiological study of PU in ICU (2017–2023), is complete. Phase 2 involved the translation, cultural adaptation and psychometric validation of the DecubICUs-test, alongside a national assessment of ICU nurses' knowledge (n = 123), has also been completed. Phase 3, currently underway, focuses on developing and validating the digital educational model through: (a) a focus group to identify unmet learning needs; (b) a modified Delphi study to validate and categorise clinical PU images; (c) a Delphi study to validate educational content; and (d) development of asynchronous e-learning modules hosted on Moodle, based on international standards and the ADDIE framework. Phase 4 consists of a pilot study.

Next Steps: Publication of the DecubICUs-test validation study and the national study assessing ICU nurses' knowledge; execution of the focus group and Delphi rounds; development and validation of instructional modules; and implementation of the pilot phase.

Anticipated Impact: This project will provide the first validated ICU-specific knowledge assessment instrument in Portugal and generate an innovative, personalised digital educational model. Expected outcomes include improved clinical decision-making, reduction in PU incidence and strengthening of advanced education and research in wound care.

Ethics: The study complies with all ethical and legal requirements, ensuring informed consent, anonymised and secure data handling, and continuous ethical monitoring.

Supervisors: Prof. Paulo Alves and Prof. António Mostardinha.

EP820 Prevalence of asymptomatic peripheral arterial disease and associated risk factors among hospitalised patients: A cross-sectional study in Singapore

Nanthakumahrie Gunasegaran[1]

[1]*Singapore General Hospital, Singapore, Singapore*

Background: Early identification of peripheral arterial disease (PAD) is difficult due to the absence of early symptoms, with many patients lacking classic features such as intermittent claudication or rest pain.

Aims: This study aimed to (i) assess the prevalence of hospitalised patients at risk of asymptomatic PAD using ankle-brachial index (ABI) and (ii) identify the demographic and clinical risk factors associated with asymptomatic PAD patients.

Methods: A cross-sectional study was conducted in the inpatient general wards of a tertiary acute hospital from February 2024 to April 2025. Using purposive sampling, patients aged ≥50 years, admitted to the Department of Internal Medicine were recruited. Demographic data (age, gender, ethnicity, and body mass index), smoking status, comorbidities and clinical diagnoses were collected. ABI measurements for both lower limbs were obtained using a handheld Doppler device. PAD risk was defined as an ABI <0.99 in either limb, while an ABI of 1.00–1.40 indicated no risk.

Descriptive statistics summarised patient characteristics and ABI values. The prevalence was calculated as the proportion of patients with borderline or abnormal ABI readings.

Results: A total of 122 patients were recruited, and the prevalence of PAD risk was 32% (n=39). No statistically significant associations were found between PAD risk and patient demographics. PAD risk among patients with musculoskeletal disease was 45.2%, with a borderline chi-square value ($\chi^2 = 3.33$, $p = 0.07$) and an increased odds ratio (OR = 2.20, 95% CI 0.93–5.06). PAD risk among patients with hypertension was 38.2% with an odds ratio suggesting higher PAD prevalence among hypertensive patients (OR = 2.22, 95% CI 0.96–5.14). Mean ABI values were significantly lower among at-risk limbs as compared to normal limbs (Right lower limb: t= 6.46, p<0.001, Left lower limb: t= 7.72, p<0.001).

Conclusion: Asymptomatic PAD risk was common among hospitalised adults aged ≥50 years, highlighting a substantial burden that may remain undetected without routine screening. Targeted ABI assessment in high-risk patients may enable earlier identification, timely intervention, and improved prevention of PAD-related complications.

OP161 Optimizing endotracheal tube repositioning frequency to prevent oral mucosal membrane pressure injuries in intensive care units: A randomized controlled trial

Ecem Ozdemir[1], Fatos Korkmaz[2], Necla Dereli[3]

[1]*Ankara University Cebeci Campus, Ankara, Türkiye*, [2]*Hacettepe University, Ankara, Türkiye*, [3]*Atatürk Sanatorium Training and Research Hospital, Ankara, Türkiye*

Stage of PhD: Fundamentals of Nursing PhD – Research-in-Progress (pre-recruitment phase).

Background: Medical device–related pressure injuries (MDRPIs) remain a major challenge in wound care, particularly in intensive care units (ICUs) where critically ill patients are continuously exposed to life-sustaining medical devices. Injuries occurring on mucosal surfaces, defined as mucosal membrane pressure injuries (MMPIs), differ from skin pressure injuries in both pathophysiology, prevention. Among mechanically ventilated patients, endotracheal tubes (ETTs) are a frequent cause of oral MMPIs due to sustained pressure, repetitive micro-movement on fragile oral mucosa. Evidence indicates that most oral MMPIs develop within the first 72 hours of intubation. Although international guidelines recommend regular device assessment and repositioning, they provide limited guidance on the optimal frequency of ETT repositioning, resulting in wide variation in clinical practice.

Aims: This study aims to evaluate whether different ETT repositioning frequencies influence the incidence of oral MMPIs in adult ICU patients.

Methods & Current Progress: This prospective, parallel-group randomized controlled trial will be conducted in three anesthesia ICUs. Adult patients requiring mechanical ventilation with an APACHE II score ≤24 will be enrolled, stratified into two severity subgroups (≤20 and 21–24). All participants will receive standardized oral care, ETT fixation, routine mucosal assessment; the only difference between groups will be the frequency of ETT repositioning. Based on power analysis, 254 patients will be recruited. Ethical approval procedures, site preparation are ongoing, staff training materials have been developed.

Next Steps: Next steps include finalizing ethical approvals, initiating patient recruitment, completing staff training, monitoring adherence to the repositioning protocol.

Anticipated Impact / Translation: By focusing on a modifiable, nurse-led intervention, this study is expected to generate evidence to define an optimal, patient-tailored ETT repositioning frequency. Findings will support the development of practical wound-prevention protocols and may contribute to future guideline updates on MDRPI prevention in critical care.

Ethics: The study will be conducted in accordance with the Declaration of Helsinki. Written informed consent will be obtained, data confidentiality will be ensured.

EP800 Artificial intelligence-assisted wound management: perspectives of Australian healthcare professionals

Sarah Montalto (Hulbert-Lemmel)[1]

[1]*Monash University, Clayton, Australia*

Title of project: Artificial intelligence-assisted wound management: perspectives of Australian healthcare professionals.

Stage of PhD: Commenced September 2024, part-time.

Background: Wound management is a vital skill in healthcare professionals' practice. The introduction of artificial intelligence (AI) into wound management approaches will dramatically influence clinical practice. The experience of healthcare professionals using AI tools in wound management is vital to understanding the viability of computer-aided care.
Aim: The proposed study aims to explore the perspectives of Australian healthcare professionals in AI-assisted wound care. The study will focus on healthcare professionals, including nurses, doctors, specialists and allied health professionals who work clinically with AI integrated into their practice. The barriers and enablers to AI-assisted wound management, including wound assessment, diagnosis, and management plans in various care settings, and healthcare professionals' awareness of AI-related clinical practice guidelines and policies will be reviewed.
Methods: A qualitative descriptive study. Aiming to conduct individual, semi-structured interviews with healthcare professionals.
Current progress: Since commencing my PhD in September 2024, I took maternity leave from 3rd of January to 14th of February, 2025. To date, I have:

- Prepared a successful abstract application for publication online and submitted an e-poster to be displayed at EWMA conference, Barcelona, Spain, March 2025.
- Submitted a manuscript from my master's research, which is under review with a Wiley Journal.
- Submitted the scoping review protocol in the Wound Practice and Research journal, which has been accepted for publication in the first 2026 edition.
- Commenced the data extraction and drafted a scoping review manuscript.

Next steps:

- Recruit healthcare professionals for semi-structured individual interviews.

Anticipated impact statement:

- To gain knowledge, insight and understanding of the perspectives of Australian healthcare professionals in AI-assisted wound care. The findings of this project could help develop clinical practice guidelines and educational materials in AI-assisted wound care.

Ethics (if applicable):

- Drafted an interview guide and supporting documents in preparation for ethics application submission by February 2026 with The Monash University Human Research Ethics Committee (MUHREC).

OP150 Randomized trial of adjunctive cold atmospheric plasma for diabetic foot or venous leg ulcers (COSMAS)

Mikaella Loizou[1], O.Bakker[1]

[1]*Sint Antonius Ziekenhuis Utrecht, Utrecht, Netherlands*

Stage of PhD: Year 2/3.

Background: Chronic wounds such as diabetic foot ulcers (DFUs) and venous leg ulcers (VLUs) represent a major clinical and economic burden due to delayed healing, high recurrence rates, and prolonged treatment. Despite adherence to standard wound care (SWC), many patients do not achieve timely wound closure.
Aims: Cold atmospheric plasma (CAP) is an emerging, CE-certified technology with antimicrobial and tissue-stimulating properties. Preclinical studies have shown CAP to reduce bacterial biofilm and increase pro-healing growth factors such as Vascular Endothelial Growth Factors. Early clinical trials suggest that CAP may accelerate healing, but data from larger studies remain limited. We aim to conduct a pragmatic study on the clinical effect of CAP for DFU and VLU patients. The protocol was based by previous studies and optimized for patient relevance with a longer follow up and real-world inclusion criteria.

Methods & Current progress: We are conducting a multicentre, open-label, randomized controlled trial to evaluate the clinical and cost-effectiveness of CAP as an adjunct to SWC. Around 500 adult patients with slow or non-healing DFU or VLU will be enrolled and randomized 1:1 to receive either SWC alone or SWC plus CAP, stratified by wound type and study site. The intervention group receives CAP therapy twice weekly via homecare professionals, in addition to SWC, for up to 12 weeks or until complete wound closure. The follow-up period is 180 days. The primary endpoint is ulcer-free survival days. Secondary outcomes include time to wound healing, recurrence, pain, infection, quality of life, adverse events, and cost-effectiveness. The study is currently at the recruitment phase since November-2025.

Next steps: The recruitment will continue until October-2027.

Anticipated impact: We aim to provide high-quality evidence on the clinical benefits and economic value of CAP therapy in DFUs and VLUs. If effective, CAP could represent an innovative addition to standard wound care that enhances healing and reduces healthcare social and economic burden.

OP151 Preventing diabetes-related foot ulcers trough data-driven custom-made footwear

Isabella Gigante[1]

[1]*Amsterdam UMC, Amsterdam, Netherlands*

Supervisors: Jaap J. van Netten & Sicco A. Bus

Stage of my PhD: Mid-late phase.

Background: Diabetes-related foot ulcers (DFUs) are a leading cause of lower-limb amputations. Custom-made footwear can positively affect foot biomechanics and usability through its protective design features which help lower ulcer risk. However, ulcer recurrence rates are still high. Currently, patient adherence is compromised, and lower shoe usability and comfort may play a role here. Also, compromised footwear fit may increase the risk of (non-plantar) foot wounds.

Aims: To develop evidence-based custom-made footwear designs for people at high risk of foot ulceration, to reduce plantar and non-plantar pressure, improve adherence, and thereby lower the risk of DFUs.

Methods and current status: The PhD-project consists of four scientific studies that develop and translate evidence into a clinical footwear design strategy for DFU prevention.

Study 1 is a systematic review and knowledge-gap analysis to assess which footwear components reduce pressure and affect usability, and to identify gaps in footwear research.
Status: knowledge-gap analysis submitted, review in final phase.

Study 2 is a cross-sectional study that objectively measures non-plantar pressure, to assess differences between poor versus good-fitting footwear, with future application in dorsal wound management.
Status: data collection ongoing.

Study 3 is a secondary data analysis, that quantifies and links patient-reported footwear satisfaction to footwear design features.
Status: analysis ongoing.

Study 4 combines findings from studies 1-3 into an updated, evidence-based, data-driven footwear design protocol which is evaluated in a prospective before-and-after study to assess its effectiveness.
Status: protocol being finalized.

Next steps: To translate the evidence and measurement tools developed in this PhD into clinical practices.

Impact statement: This project matters for wound care because it provides evidence-based tools to guide patient-centred footwear prescriptions for those at high-risk of developing foot ulcers. It guides researchers, clinicians, and technicians in addressing footwear knowledge gaps, design, and assessment, with the aim of developing the best footwear for the high-risk foot. Together, this creates a design strategy to improve usability, footwear adherence, and help prevent ulcer recurrence.

EP815 Topical deferoxamine (DFO) for Diabetic cutaneous wound healing in animal models: A systematic review and meta-analysis

Daniel Müller[1], Jens Klotsche[2], Robert Sabat[3], Paula Hoff[4], Timo Gaber[5]

[1]Charité - Universitätsmedizin Berlin, Berlin, Germany, [2]German Rheumatism Research Centre (DRFZ) Berlin, Leibniz Institute, Berlin, Germany, [3]Charité - Universitätsmedizin Berlin, Coporate Member of Freie Universität Berlin and Humboldt Universität zu Berlin, Department of Dermatology, Venerology and Allergology, Berlin, Germany, [4]Charité - Universitätsmedizin Berlin, Coporate Member of Freie Universität Berlin and Humboldt Universität zu Berlin, Department of Rheumatology and Clinical Immunology, MVZ Endokrinologikum Berlin am Gendarmenmarkt, Berlin, Germany, [5]Charité - Universitätsmedizin Berlin, Coporate Member of Freie Universität Berlin and Humboldt Universität zu Berlin, Department of Rheumatology and Clinical Immunology, German Rheumatism Research Centre (DRFZ) Berlin, a Leibniz Institute, Berlin, Germany

Stage of PhD: MD/PhD candidate at Charité – Universitätsmedizin Berlin. We previously published a preclinical meta-analysis on locally administered deferoxamine (DFO) in fracture healing in Advanced Science (Journal Impact Factor: 14.1). This project is the second evidence-synthesis study within the PhD programme and evaluates topical DFO for cutaneous diabetic wound healing. Together, both meta-analyses will be synthesized and integrated into the dissertation.

Background: Chronic, non-healing wounds are a major health burden. Diabetes mellitus is a key driver through vascular dysfunction, neuropathy, and impaired tissue oxygenation. Current wound care optimizes the local environment, but does not directly address impaired neovascularization. Deferoxamine (DFO; desferrioxamine) is a clinically approved iron chelator that can stabilize HIF-1α, enhance VEGF signalling, and sequester redox-active iron. These mechanisms may promote angiogenesis and support tissue regeneration.

Aims: Our research aims to determine whether topical DFO improves cutaneous wound healing in diabetic animal models, to synthesize the existing preclinical evidence, and to inform clinical translation.

Methods & current status: This systematic review and meta-analysis was prospectively registered on PROSPERO (CRD420251172142). We included controlled in vivo studies using diabetic mice and rats with full-thickness cutaneous wounds treated with topical DFO delivery systems. The primary outcome was wound closure, reported as the percentage of the initial wound area healed at predefined time points. The secondary outcome was CD31-positive vessel density as a histological marker of neovascularization. Risk of bias was assessed using the SYRCLE risk-of-

bias tool, and meta-analyses were performed with planned subgroup and sensitivity analyses. Screening, data extraction, risk-of-bias assessment, and initial meta-analyses are complete, showing promising pooled effects (↑ *attached forest plot*).

Next steps: The remaining subgroup and sensitivity analyses will be finalized, followed by completion of the peer-reviewed manuscript.

Anticipated impact/translation: This prospectively registered meta-analysis will clarify the efficacy of topical DFO, identify key effect modifiers for this angiogenesis-targeted therapy, highlight translational gaps, and inform the design of robust confirmatory preclinical studies and early-phase clinical trials, supporting the development of innovative DFO-loaded delivery systems for diabetic wound therapy.

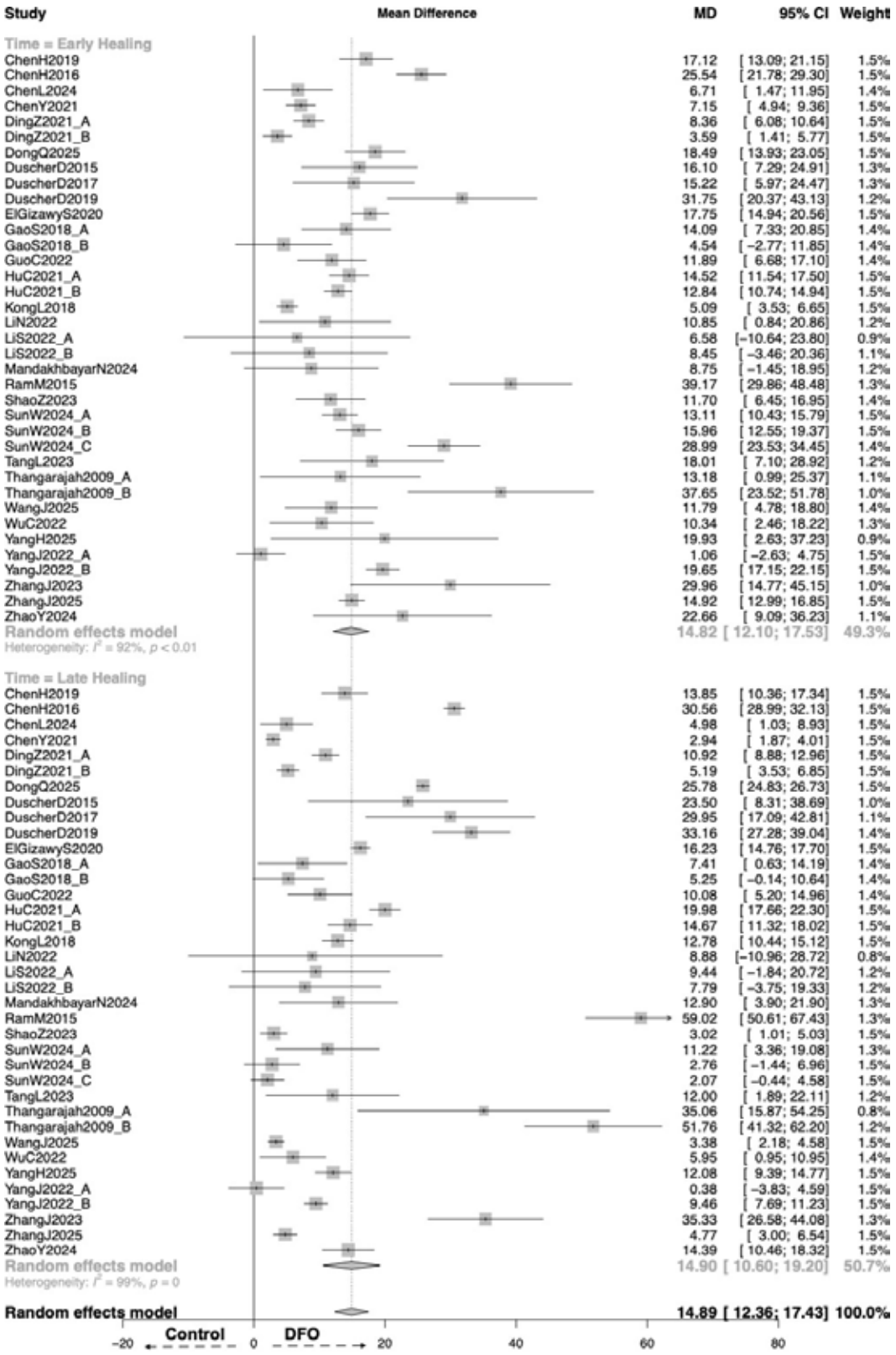

Figure: Forest plot of wound closure (%) comparing DFO-treated vs control groups in diabetic animal models. Subgroups represent measurement time points closest to 7 (Early Healing) and 14 (Late Healing) days post-wounding. Overall, DFO significantly accelerates wound healing (MD: 14.89%, 95%-CI: 12.36 – 17.43; p < 0.0001), with substantial heterogeneity.

OP152 Bridging the gap in surgical wound care by nurses in a low-resourced setting: A multi-method study

Gayani P Gamage[1], Sanjeewa Seneviratne[2], Georgia Tobiano[3], Josepine Lovegrove[3], Brigid. M Gillespie[3]

[1]*Griffith University, Queensland, Australia*, [2]*Faculty of Medicine, University of Colombo, Colombo, Sri Lanka*, [3]*NHMRC Centre of Research Excellence in Wiser Wound Care, School of Nursing and Midwifery, Griffith University, Gold Coast Campus, Queensland, Australia*

Stage of PhD: Data analysis.

Background: Nurses are primarily responsible for performing wound care in collaboration with the multidisciplinary team. Yet, little is known about surgical wound care in low-resourced settings, including Sri Lanka.

Aims: To describe the surgical wound care practices and knowledge of nurses and to explore the barriers and facilitators for evidence-based wound care in a Sri Lankan tertiary care hospital.

Methods and current progress: This multi-method study consists of three phases. In Phase 1, an integrative review was conducted to synthesise published literature on surgical wound care of acute care nurses. This review was conducted following Whittemore and Knafl's methodology, and the manuscript has been published*. Phases 2 and 3 were conducted in the general surgical wards of a 3000-bed tertiary care hospital in Sri Lanka. Phase 2 aimed to assess nurses' surgical wound care practices and knowledge. A prospective observational study was conducted using direct observation of wound care episodes between registered nurses (RNs) and post-surgical patients, along with an audit of medical records. A convenience sample of registered nurses (RNs)(n=63) and a consecutive sample of 250 post-surgical adult patients within 30 days post-surgery were participants. An observational tool developed based on clinical practice guidelines (CPGs) and a context-specific chart audit tool were used for data collection. A survey was conducted among RNs to assess surgical nurses' self-reported knowledge of surgical wound care. A previously used survey tool was used after contextual adaptation and forward and backward translation. Phase 3 aimed to explore nurses' perspectives on barriers and facilitators for evidence-based surgical wound care. A descriptive qualitative study was conducted using a purposive sample of RNs. Data collection was done using face-to-face interviews up to the data saturation point using an interview guide. Data collection for Phases 2 and 3 is completed.

Next steps: Data analysis of Phases 2 and 3.

Anticipated impact/translation: The study will provide a foundation for developing targeted interventions that can influence the nurses' adherence to CPGs, knowledge and contextual improvements needed for low-resourced settings.

Ethics: The Ethics Review Committees of the respective hospital in Sri Lanka and Griffith University, Australia.

OP153 Host–microbe interactions in human ex vivo wounds and the modulatory role of silk membranes

Sophie Charlotte Liegenfeld[1]

[1]*University Medical Center Hamburg-Eppendorf, Department of Vascular Medicine, Hamburg, Germany*

This mid-stage PhD project (ongoing since April 2024) investigates how clinically dominant wound pathogens interact with human skin in a wound environment and how biomaterials can modulate these processes. Chronic wounds are frequently dominated by *Staphylococcus aureus* and *Pseudomonas aeruginosa*, which drive inflammation, tissue destruction, biofilm formation, malodour, and healing failure. Yet their direct effects on human skin remain poorly defined, as most experimental systems rely on animal models or simplified *in vitro* assays that do not reproduce human tissue architecture. At the same time, the clinical need for bioactive wound dressings such as silk-based membranes is increasing in response to problematic healing, yet their mechanistic effects on host–pathogen dynamics remain largely unexplored.

The project aims use an established translational human *ex vivo* wound model to characterize pathogen-specific interactions of *S. aureus* and *P. aeruginosa* with human skin, to compare host responses such as tissue damage and inflammatory signaling, and to determine how silk membranes modulate these interactions and healing-relevant processes. Human skin from fully anonymized surgical discard material is processed into a standardized *ex vivo* wound model and inoculated under controlled conditions. Bacterial colonization and biofilm formation are analyzed using microbiological assays and microscopy, while host responses are assessed by histology, barrier integrity, and molecular markers of inflammation and tissue stress. Ex vivo wound models from 3 donors have been generated for bacterial infection and silk membrane integration and are currently under analysis. Ongoing work focuses on identifying pathogen- and host-specific genes involved in host-mediated responses to infection.

Next steps include comparative pathogen analysis, quantitative mapping of host responses, mechanistic assessment of silk membrane effects, and preparation of the first manuscript. By linking pathogen biology, human tissue response, and biomaterial performance in a single translational system, this project directly informs wound education, enables clinically relevant research, and supports evidence-based development of targeted wound therapies. All experiments comply with institutional and national ethical regulations and use only anonymized surgical discard tissue.

OP154 Proactive therapy of acute radiation-induced skin injury in head and neck cancer

Paweł Głuszak[1 2], Jakub Pazdrowski[3 4], Joanna Kaźmierska[5 6], Aleksandra Dańczak-Pazdrowska[1]

[1]*Department of Dermatology, Poznan University of Medical Sciences, Poznan, Poland*, [2]*Doctoral School, Poznan University of Medical Sciences, Poznan, Poland*, [3]*Department of Head and Neck Surgery, Poznan University of Medical Sciences, Poznan, Poland*, [4]*Department of Head and Neck Surgery, Greater Poland Cancer Center, Poznan, Poland*, [5]*Department of Electroradiology, Poznan University of Medical Sciences, Poznan, Poland*, [6]*Department of Radiotherapy II, Greater Poland Cancer Center, Poznan, Poland*

Year 2/4. The systematic review, meta-analysis, and retrospective analysis, are being finalized. The prospective randomized study is ongoing.

Acute radiation-induced skin injury (aRISI) is the most frequent complication of radiotherapy (RT), affecting up to 100% of patients treated for head and neck cancer (HNC). Skin reactions often progress from erythema to moist desquamation, pain, and ulceration, leading to impaired quality of life and potential interruptions of oncological treatment. Despite its clinical relevance, aRISI is not consistently managed as a wound, and prevention strategies vary widely between centers. Evidence supporting proactive therapy remains limited, and data on patient-specific risk factors are fragmented, limiting the implementation of personalized prevention strategies in practice.

The aims of this PhD project are to identify risk factors for severe aRISI, to evaluate the efficacy and safety of proactive topical therapy, and to prospectively assess proactive treatment using topical glucocorticosteroids (tGCS) and topical tacrolimus (tTAC). This study is the first to evaluate tTAC as both a proactive therapy and a treatment option for aRISI.

A systematic review and meta-analysis of randomized controlled trials was conducted to evaluate proactive tGCS in patients undergoing RT for HNC. In parallel, a retrospective analysis was performed to identify risk factors for severe aRISI. The prospective study randomizes patients into four groups with or without proactive therapy using either tGCS or tTAC, followed by reactive treatment if aRISI develops. To date, more than 30 patients have been enrolled, and preliminary results indicate delayed onset of skin injury in patients receiving proactive therapy.

The next phase includes publication of the meta-analysis and retrospective results, completion of patient recruitment to a target of 80 to 120 participants, and final outcome analyses of the prospective study.

This project reframes aRISI as a predictable and preventable wound. By combining risk stratification with proactive intervention, it supports the development of personalized wound prevention strategies that reduce severe skin injury, improve quality of life, and help maintain uninterrupted cancer treatment. The results are directly applicable and are expected to inform future guideline development in wound care and supportive oncology.

The study was approved by the local bioethics committee.

OP155 The clinical and cost-effectiveness of an artificial intelligence-synthesized nursing care bundle in preventing medical device-related pressure injuries

Aleyna Uçanbelen, Ayişe Karadağ

PhD Stage: Year 3/5 PhD Candidate.

Background: Medical device–related pressure injuries (MDRPIs) are recognized as preventable harms, yet their incidence continues to rise alongside the use of medical devices. This reflects a gap not in awareness, but in implementation: guideline-recommended preventive measures are inconsistently applied at the bedside due to time pressure, competing clinical priorities, and the lack of practical, standardized workflows. Consequently, MDRPIs remain an avoidable source of patient harm, prolonged hospitalization, and healthcare costs. There is a critical need for prevention strategies that are evidence-based, feasible, reproducible, and easily integrated into routine care.
Aims: This project aims to develop an AI-synthesized, evidence-based, implementable and monitorable nursing care bundle to evaluate its clinical effectiveness and cost-effectiveness versus standard care in preventing MDRPIs.
Methods & Current Status: The project uses sequential phases. First, a systematic search (2016–present) will identify studies reporting MDRPI preventive interventions. Full texts will undergo AI-assisted evidence synthesis using structured prompting to extract and consolidate intervention components into a preliminary nursing care bundle. Second, content validity will be established through a two-round Delphi consensus process with approximately 12 experts in MDRPI prevention. Third, nurses will receive standardized training, and implementation fidelity will be prospectively monitored (adherence ≥95%). Finally, the finalized bundle will be evaluated against standard care in a randomized controlled trial (primary outcome: MDRPI incidence). A parallel economic evaluation will estimate prevention-related and hospitalization costs to calculate incremental cost-effectiveness ratios. Currently, the systematic literature search is underway, and data collection forms have been developed.
Next Steps: Finalize the bundle through evidence synthesis and Delphi consensus, then initiate randomized trial and economic evaluation.
Anticipated Impact: The study will deliver an AI-synthesized evidence-informed MDRPI prevention approach designed for real-world feasibility and high adherence. By evaluating both effectiveness in a randomized trial and incremental costs at the patient level, the project will generate actionable evidence to guide nursing practice, support implementation decisions, and reduce preventable harm and resource burden.
Ethics: Approved by the Institutional Biomedical Research Ethics Committee.

OP156 Offloading with additive manufactured insoles using optimally tested designs

Niloofar Sedighi[1]

[1]*Glasgow Caledonian University, Glasgow*

Supervisors: Dr Ruth Barn, Dr Gordon Hendry, Dr Jari Pallari.

Stage of PhD: Final year.

Background: Diabetes-related foot ulcers remain a major healthcare burden worldwide and leading cause of lower-limb amputation. Plantar pressure redistribution is essential in preventing diabetic foot ulceration, yet conventional insoles often lack sufficient personalisation, adaptability during healing, sustainability, and user adherence. Emerging technologies such as 3D scanning, plantar pressure measurement, computational modelling and additive manufacturing offer new opportunities to develop adaptive, efficient and sustainable offloading solutions.

Aims: This PhD aims to conceptualise, design, optimise, manufacture and test a novel personalised insole capable of effectively redistributing plantar pressure in people with diabetes at risk of foot ulceration.

Methods & current progress: The research follows a four-study framework.

Study 1 (completed) is a qualitative focus-group study exploring patient experiences, perceptions and adherence factors related to prescribed insoles; findings directly inform design features.

Study 2 (completed) is an experimental study exploring the compressive characteristics of an adjustable 3D printed foaming TPU as an alternative to medical grade foam.

Study 3 (ongoing) involves designing and optimising multiple insole concepts using individual foot shape and plantar pressure data from 15 controls. CAD modelling and iterative 3D printing are used to optimise geometry, materials and offloading performance.

Study 4 (planned) is a pre-clinical pressure evaluation of the functional prototypes and user feedback in 15 people with moderate–high ulcer risk.

Next Steps: Finalise prototype optimisation, complete pre-clinical testing, analyse pressure outcomes and user feedback, and establish a scalable, sustainable manufacturing workflow.

Anticipated impact: This research will deliver a clinically relevant, adaptable and sustainable personalised insole solution with potential to reduce plantar pressure at ulcer-prone sites, and support earlier intervention in diabetic foot care. The findings may inform future clinical trials and translation into routine podiatry and orthotic practice.

Ethics: Ethical approval has been granted by the GCU School of Health and Life Sciences ethics committee (reference number HLS/AHP/25/002).

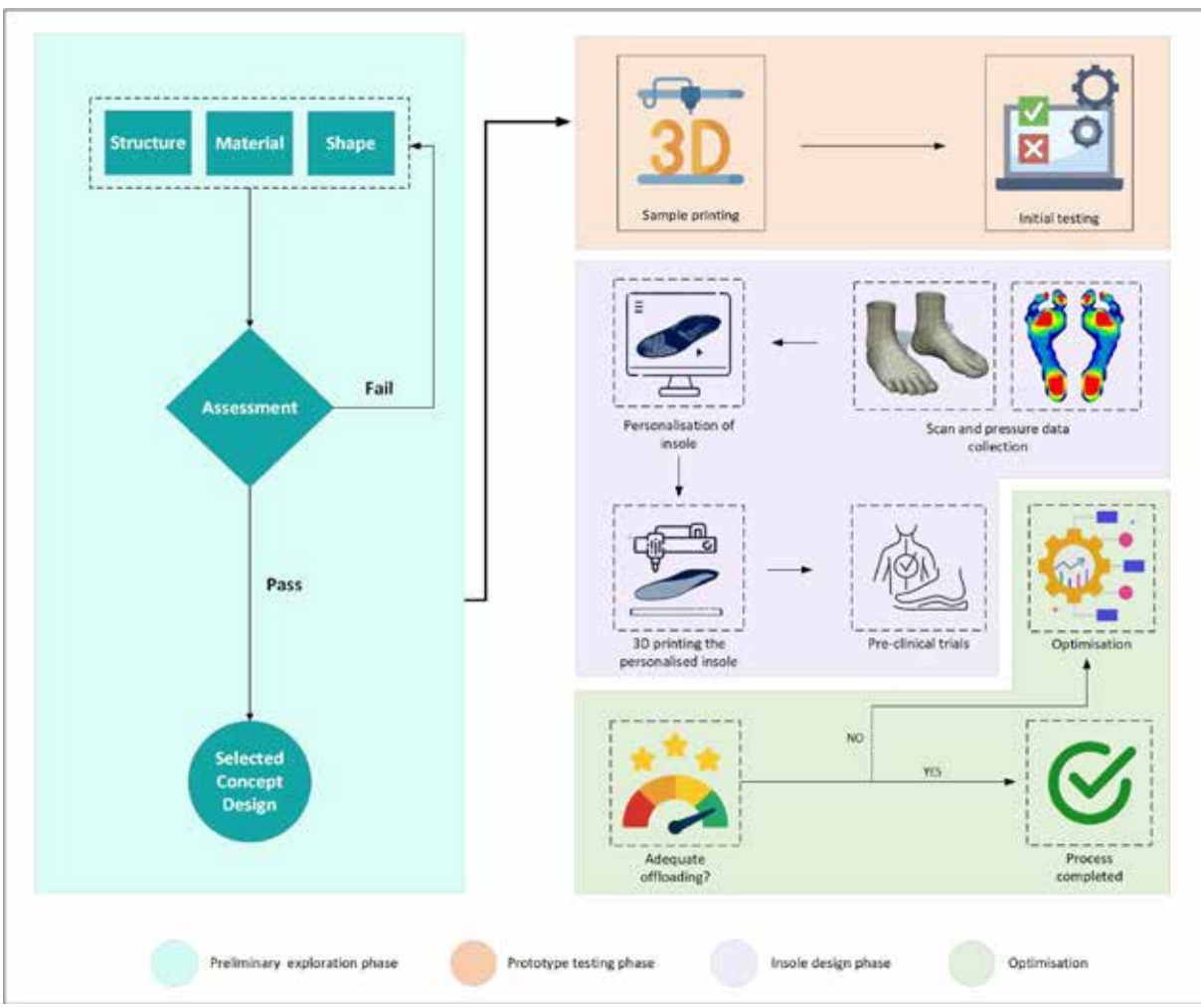

Figure 1. The process of design to manufacturing of the novel personalised insole

EP801 From healing to remission: evidence-based transition footwear design for diabetic foot ulcer prevention

Kamran Shakir[1], Giulia Rogati[2], Alberto Leardini[2], Lisa Berti[1], Paolo Caravaggi[2]

[1]Department of Biomedical and Neuromotor Sciences - DIBINEM, Alma Mater Studiorum - Universita di Bologna, Bologna, Italy, [2]Movement Analysis Laboratory and Functional Evaluation of Prostheses, IRCCS Istituto Ortopedico Rizzoli, Bologna, Italy

Supervisors: Prof. Lisa Berti, Dr. Alberto Leardini, Dr. Paolo Caravaggi, Giulia Rogati.

PhD Stage: 3rd year.

Background: Diabetic foot ulceration affects up to one-third of people with diabetes, with 40% experiencing recurrence within one year of healing. The transition from therapeutic offloading during active ulceration to long-term preventive footwear represents a critical window (the transition phase) in which selecting inappropriate footwear can trigger re-ulceration. In fact, footwear prescription during this phase remains largely empirical, as no validated methodology exists to assess how specific midsole and outsole characteristics affect plantar pressure offloading and foot biomechanics.

Aims: To develop and validate evidence-based novel transition footwear by investigating how midsole/outsole components influence plantar pressure distribution, comfort, stability, and lower limb joint kinematics in healthy individuals and people with diabetes at ulceration risk.

Methods & Current Status: The study employs a four-phase translational design from laboratory validation to clinical application. Phase one involves developing a validated modular footwear setup enabling isolated testing of footwear components, in collaboration with industry partner Podartis SRL (Italy). Phase two tests the material properties of current therapeutic footwear components using standardized mechanical testing, with preliminary data collected at Vibram SRL (Italy). Phase three will quantify the biomechanical effects of these components in 20 healthy participants through in-shoe pressure analysis and gait assessment. Phase four will validate the findings in 20 people with diabetes at risk of ulceration through a cross-sectional trial at the Rizzoli Orthopedic Institute, Italy.

Next Steps: Submit the MFS validation study to a peer-reviewed journal, finalize material characterization, begin biomechanical testing, and conduct patient-based clinical trial during a 2026 secondment at Amsterdam UMC, a leading diabetic foot care center of Europe.

Anticipated Impact: This work will deliver the first systematic evidence linking footwear design specifications to clinically relevant biomechanical outcomes in ulcer prevention. Healthcare providers will gain validated design principles, and a working prototype will enable evidence-based prescriptions, potentially reduce recurrence rates, and improve quality of life.

Ethics: Local ethical committee approval is under review (AVEC #647/2025/Sper/IOR).

EP816 Research and development of new technologies for the treatment and management of wounds

Davide Griffa[1 2], Michela Starace[1 3], Davide Melandri[1 2]

[1]Department of Medicine and Surgical Sciences, University of Bologna, Bologna, Italy, [2]Burn Center - Dermatology Unit Cesena/Forlì, AUSL Romagna, Bufalini Hospital, Cesena, Italy, [3]Dermatology Unit, IRCCS Sant'Orsola-Malpighi Hospital, Bologna, Italy

Stage of PhD: 3rd year.

Background: Wounds represent a growing global healthcare challenge and remain a major issue in wound management and public health, requiring multidisciplinary and resource-intensive care pathways and generating a significant clinical and economic burden for healthcare systems.

Aims: This research project aims to investigate and develop innovative technologies for wound treatment, with a specific focus on the clinical application of blue light therapy (BL) and the integration of artificial intelligence (AI) in wound care.

Methods & current status: The primary objective of the project is to conduct a prospective controlled clinical trial evaluating the effects of BL in the treatment of wounds. The study is being carried out at the Burn Center of "M. Bufalini" Hospital in Cesena (AUSL Romagna, Italy). A total of 25 patients with burn injuries eligible for autologous skin grafting are enrolled, corresponding to 50 donor sites. An intra-patient comparison is performed between donor sites treated with standard of care (SoC) combined with BL and those treated with SoC alone. The clinical trial evaluates healing time, wound bed characteristics (Wound Bed Score), perceived pain (Numerical Rating Scale), incidence of infections, local reactions, and scar quality. The study is currently in the active enrollment and data collection phase. An additional objective involves the development and training of AI algorithms for a mobile application designed for objective and automated wound assessment. Ongoing activities focus on wound segmentation and quantitative automated evaluation of wound area, depth, and margins.

Next steps: Include completion of data collection, robust statistical analysis, and publication of the clinical results. Further refinement and external validation of the AI system are planned to ensure clinical reliability, scalability and usability for healthcare professionals.

Anticipated impact/translation: The project aims to support the integration of innovative technologies, such as BL and AI, into routine clinical practice to improve wound management optimize clinical decision making, and enhance patient outcomes.

Ethics: The Romagna Ethics Committee (CEROM), Italy, has approved the research protocol related to BL.

Supervisors: Prof Davide Melandri, Prof Michela Starace.

EP802 Clarifying and improving wound care pathways in Finnish primary care through joint nurse–physician clinic

Réka Sayeda[1]

[1]*Western Uusimaa Wellbeing Services County, Espoo, Finland*

Stage of PHD: Year 1 (≈15% completed); baseline survey and data collection preparation underway.

Background: Chronic wounds demand long-term, resource-intensive care and are associated with complications, reduced quality of life, and high costs. In primary care, limited time and knowledge from physicians may contribute to unclear patient pathways and delayed diagnostics and referral, thus prolonging healing.

Aims: To identify competence and pathway gaps among primary care nurses and physicians in Western Uusimaa (LUVN) and Helsinki. To evaluate whether a structured joint nurse–physician wound clinic improves outcomes, experience, and resource use.

Methods & current status: The project consists of three phases. Phase I is a cross-sectional clinician survey, assessing perceived wound-care competence, collaboration, and pathway clarity from primary care physicians and nurses. Phases II and III evaluate an intervention. The intervention is the launch of a joint clinic in early 2026 at Espoonlahti Health Centre, where retrospective and prospective patient-level data from electronic health records and patient-reported outcome/experience measures (PROM/PREM) are collected. Primary outcomes are wound-care episode length (healing time) and visit/consultation frequency; secondary outcomes include PROM/PREM and staff workflow satisfaction. Baseline–follow-up comparisons will use predefined cohorts (e.g., November 2025 vs. November 2026), with an additional assessment after 18 months to account for implementation learning.

Next steps: Establish and proliferate practices of the joint clinic, complete baseline clinician and patient cohorts, collect PROM/PREM at implementation and follow-up, and perform 12-month resource and cost analyses.

Impact statement: A clearer pathway and joint nurse– physician assessment are expected to shorten healing times, reduce wound-care visits, improve patient quality of life and supporting cost-effective care. Inspired by our guiding principle *"We are changing the world- one wound at a time"*, this model unites the appropriate expertise exactly when it matters, reducing patient burden, and supporting a more meaningful and fulfilling clinical work for health-care professionals.

EP803 Creation, evaluation and assessment of the perceived acceptability of an algorithm for the development of a patient health passport for the management of patients with diabetic foot ulcers: A mixed-methods study

Liliana Morais[1], Pinar Avsar[1], Hannah Wilson[1], Zena Moore[1]

[1]*Royal College of Surgeons Ireland, Dublin, Ireland*

Introduction: Diabetic foot ulcers are a serious complication of diabetes, responsible for 85% of diabetes-related amputations. A major concern is the high mortality rate after amputation, with estimates reaching as high as 70%. Despite multidisciplinary care being recommended, communication gaps and fragmented services persist.

Patient health passports have been recently implemented in some health care settings to address these issues, and a digital patient health passport may offer a practical, inclusive, and effective approach to support coordinated DFU management.

Methods: This multiphase, mixed-methods study aims to create and establish the content validity and to evaluate the perceived acceptability of an algorithm for the development of a digital patient health passport for the management of patients with diabetic foot ulcers. The overall study comprises five phases. Phase 1 involves a systematic review to evaluate the impact of using a patient health passport on health outcomes among adults with diabetes and to explore patients' perceptions of patient health passport use. Phase 2 focuses on the design of the digital patient health passport using qualitative focus groups to identify barriers and facilitators to diabetic foot ulcer management and to determine the content, structure and functionalities of the digital patient health passport algorithm. Phase 3 involves the design and development of the patient health passport algorithm. Phase 4 concerns establishing content validity through a consensus group to finalise the digital patient health passport algorithm content. Phase 5 explores stakeholders 'perceived acceptability of the digital patient health passport algorithm.

Conclusion: The proposed study will provide valuable insights into creation, content validation and perceived acceptability of an algorithm for the development of a digital patient health passport for the management of patients with diabetic foot ulcers.

Findings are expected to inform future strategies to enhance communication, coordination and continuity of care, ultimately supporting improved patient outcomes.

EP804 Innovative technologies and advanced nursing assessment in the management of chronic wounds at risk of infection

Sara Sandroni[1]

[1]*Azienda USL Toscana sudest, Arezzo, Italy*

PhD stage: Late-stage PhD candidate in Nursing Science and Public Health, University of Rome Tor Vergata.

Background and aims: Chronic wounds of different aetiologies represent a significant clinical and public health burden, particularly when complicated by colonization or infection. Despite the increasing availability of innovative wound care technologies, their implementation remains heterogeneous and often insufficiently supported by structured nursing assessment and comparative evidence. This PhD project aims to evaluate innovative technologies for the management of chronic wounds at risk of infection, while strengthening the role of standardized, evidence-based nursing assessment in clinical decision-making and patient outcome improvement.

Methods and current status: The PhD research was structured into three phases. The first phase consisted of a comprehensive review of international literature on emerging technologies for the treatment of chronic wounds with suspected or confirmed infection, focusing on clinical effectiveness and safety. The second phase involved a multicentre observational study aimed at validating wound assessment scales used to identify and monitor infection risk, assessing their reliability and predictive value. The third phase is an ongoing randomized controlled trial, currently in the advanced stage of data collection, comparing selected innovative wound care technologies with standard of care. Primary outcomes include wound healing time, infection control, and patient-reported quality of life.

Next steps: Next steps include completion of data collection, final statistical analysis, and integration of findings to develop clinically applicable recommendations and decision-support tools.

Anticipated impact and translation for wound care: The project is expected to support evidence-based adoption of innovative wound care technologies, promote validated assessment tools, and inform standardized care pathways, education, and implementation strategies.

Why this research matters for wound care: By integrating technological innovation with advanced nursing assessment, this research addresses key gaps in chronic wound management, enhances translation of evidence into practice, and supports improved outcomes for patients with complex chronic wounds.

EP806 Diabetic foot literacy and clinical practice in Portugal - A nationwide survey of primary care professionals. Preliminary results

Natalia Santos[1]

Paulo Alves PHD, Oporto Catolic University; Susana Pedras PHD, Oporto Lusiada University; Inês Madanelo, MD; Margarida Abrantes, PHD, Coimbra University, Gulherme Tralhão, PHD, Coimbra University

[1]*Medicine Faculty of Coimbra University, Oporto Catolic University, Coimbra, Portugal*

Stage of PHD: Collecting data phase.

Background: Emerging evidence suggests that iron metabolism may play a pivotal role in the pathogenesis of diabetic foot complications. This doctoral investigation is predicated on this hypothesis. Concurrently, with diabetic foot prevention as a primary objective, this research also assesses the state of the art and the practical translation of existing knowledge into daily clinical practice in Portugal. It is within this dual framework—bridging biological insights with the evaluation of healthcare professionals' literacy and diabetic foot management guidelines applicability—that this study is developed.

Aim: Asses the current state of literacy levels, formative needs and the applicability of diabetic foot guidelines, namely Portuguese General health direction (DGS) Norma 011/2011, before release of its 2025 update, and International Working Group on Diabetic Foot (IWGDF) 2023 guidelines, among primary care general practitioners and nurses.

Methods & Current Progress: A nationwide cross-sectional study was conducted between September and November 2025 using Qualtricsâ anonymous online surveys distributed to general practitioners (GP) and nurses. Preliminary results show high professional maturity (60% >15 years experience) and risk awareness (83.3%). However, a "know-do gap" exists: while ~74% use clinical protocols, only 26.5% perform full screenings on >90% of patients. Furthermore, 100% of GPs and 86.3% of nurses reported insufficient foundational training.

Next Steps: Evaluation of the implementation of the new 2025 DGS guidelines and track improvements in literacy and screening adherence.

Anticipated Impact/Translation: This work establishes a critical baseline for identifying adherence difficulties regarding best-practice guidelines. By addressing these barriers, the study aims to promote institutional clinical excellence, enhance patient quality of life, and ultimately reduce future amputation rates. Overwhelming consensus (>95%) highlights the urgent need for an effective Integrative Care Network to optimize patient referral pathways.

Ethics: The study was conducted in accordance with the Declaration of Helsinki.

EP807 Educational Intervention for nursing professionals to prevent skin tears in hospitalized adults and older adults: A quasi-experimental study

Heidi Marie Hevia Campos[1], Vera Lucia Conceição Gouveia Santos[2]

[1]*Universidad de Sao Paulo, Viña del Mar, Chile*, [2]*Sao Paulo University., São Paulo, Brazil*

Purpose and Background: Skin tears (STs) are a prevalent and often underestimated problem in hospitalized adults and older adults, compromising patient safety, prolonging recovery, and increasing healthcare costs[1]. Evidence indicates that structured educational interventions for nursing staff effectively enhance preventive practices, thereby improving care quality [2,3,4].

Aims: To evaluate the effects of an educational intervention on nurses' knowledge regarding classification, risk factors, prevention and treatment of ST, and analyze associations between sociodemographic and professional variables and knowledge levels.

Methods: A quasi-experimental study was conducted in four public hospitals in Chile. Participants included nurses providing direct clinical care. A structured educational program on ST classification, risk factors, prevention, and treatment—based on current evidence and international guidelines—was implemented. Knowledge was assessed using the OASES instrument, which was translated and validated into Chilean Spanish[5]. Measurements were taken before, immediately after, and three months following the intervention. Data were analyzed using Linear Mixed Models, chi-square tests, and Pearson correlations. Ethical approval was obtained. The intervention included all groups, a PowerPoint presentation at the workplace, followed by a workshop with clinical case analysis, group discussion, presentation of findings, and feedback from the principal investigator.

Results: A total of 116 participants' mean age was 33 years, with an average of 7 years since undergraduation and in professional practice. The educational intervention produced a statistically significant improvement in OASES scores, confirming an increase in knowledge immediately post-intervention, with a partial decrease after three months. The most significant knowledge gains were observed in core aspects of ST prevention. Wound-specific training was the only variable significantly associated with higher knowledge scores, while age, years since graduation, and clinical experience showed no correlation.

Conclusion: The educational program effectively improved nurses' knowledge of ST prevention, reinforcing that specialized knowledge requires structured, evidence-based, and continuous professional education in wound care.

References

1. Tiggelen, H., Alves, P., Ayello, E., Bååth, C., Baranoski, S., Campbell, K., Dunk, A. M., Gloeckner, M., Hevia, H., Holloway, S., Idensohn, P., Karadağ, A., Langemo, D., LeBlanc, K., Ousey, K., Pokorná, A., Romanelli, M., Santos, V. L. C. de G., Smet, S., ... Beeckman, D. (2021). Development and psychometric property testing of a skin tear knowledge assessment instrument (OASES) in 37 countries. *Journal of Advanced Nursing*, *77*(3), 1609–1623. https://doi.org/10.1111/jan.14713
2. Campos, H. H., Silva, C. V. B. da, Takahashi, J. A., Cardoso, M. M. de A., Mazzachiodi, L. R., Woo, K., & Santos, V. L. C. de G. (2025). Educational interventions to improve knowledge among nurses in the prevention of skin tears in hospitalised adults and older adults: a scoping review. *International Wound Journal*, *22*. doi:10.1111/iwj.70240
3. Peters, M. D. J., & Campbell, J. M. (2014). The effectiveness of treatments for skin tears in older people: a systematic review protocol. *JBI Database of Systematic Reviews and Implementation Reports*, *12*(11), 127–140. https://doi.org/10.11124/jbisrir-2014-1923
4. Wang, Guandong et al. "Assessing Skin Tear Knowledge Among Nurses: A Multi-centre Cross-Sectional Survey." *Journal of clinical nursing* vol. 34,4 (2025): 1409-1419. doi:10.1111/jocn.17463
5. Campos H.H., Alviña P., Silva, C. V. B. da ., Beeckman D., Santos, V. L. C. de G. (2025). Translation and Content Validity of the Skin Tear Knowledge Assessment Instrument (OASES) into Chilean Spanish (accepted in the journal Advances on Skin and Wound Care, not yet published.)

EP817 Characterization of endogenous bacteriophages from chronic wound biofilms and evaluation of their therapeutic potential against wound pathogens

Nicolas Krüger[1]

[1]*Universitätsklinikum Hamburg Eppendorf, Hamburg, Germany*

Background: Chronic wounds are frequently covered with persistent bacterial biofilms that sustain inflammation and reduce the efficacy of antimicrobial therapy. The growing prevalence of multidrug-resistant pathogens further limits treatment options and underlines the need for alternative or complementary antimicrobial strategies.

Bacteriophages (phages) are highly specific viruses capable of replicating at the infection site, disrupting biofilms and eradicating bacterial colonisation, making them promising candidates for wound infection management. However, phage performance in human-relevant wound models remains insuffi-ciently explored, particularly in combination with standard antiseptic treatments.

Aims: This project aims to identify phages derived from chronic wound biofilms, characterize them, and evalu-ate their therapeutic potential against wound pathogens in translational wound models, both as mono-therapy and in combination with antiseptics.

Methods & Current Status: Various phages with ESKAPE bacteria as hosts were isolated from biofilm samples of chronic wound pa-tients using plaque assay techniques. Phage–host interactions have been investigated in infection assays. Selected phages have been characterised through transmission electron microscopy (morphologically) and host range assays. Therapeutic efficacy has been assessed in two translational systems: a plasma-based WBC–biofilm model (LH-Biom) and an *ex-vivo* human skin model. These studies included bacterial load analysis (QSM), structural analysis using fluorescence microscopy, image cytometry, and histological analysis of the *ex-vivo* model. Phages have demonstrated activity against ESKAPE bacteria in these hu-man-based models.

Next Steps: Further characterisation of selected phages, including whole-genome sequencing, screening for virulence factors, pH and heat stability, and lytic activity tests, will be continued. This will be followed by systematic evaluation of phage–antiseptic combination therapies, focusing on antimicrobial efficacy, phage stability, and cytotoxicity in our translational models.

Translational Impact: This work advances wound care research by developing phage-based strategies to control biofilms and resistant pathogens while aiming to minimize tissue and probiotic toxicity, contributing to more effective and sustainable infection management in chronic wounds. The project provides preclinical data on wound-derived phages in human-relevant models, reducing reliance on less specific animal skin models.

EP818 Qualitative and molecular characterization of bacterial interspecific interaction in connection with the treatment of antimicrobial substances in an inoculated wound model

Mandy Dittmer[1]

[1]*Dept. of Vascular Medicine, University Medical Center Hamburg-Eppendorf, Hamburg, Germany*

Bacterial biofilms are one of the biggest problems associated with wounds that are difficult to heal. Up to 75% of all chronic wounds are covered with biofilms. The production of a biofilm protects microorganisms. The matrix of extracellular substances (EPS) serves as protection against dehydration and, at the same time, as a kind of fortress against external influences (antibiotics, antiseptics, etc.) and the host's immune system. Biofilms often consist not of a single species, but of a consortium of different microorganisms. Among the most common species are Pseudomonas aeruginosa and Staphylococcus aureus, but fungi such as Candida albicans can also be found in wounds.

Competitive and synergistic effects can occur between these microorganisms, but their significance for biofilm formation, spatial organization, and therapeutic response is not yet fully understood.

The aim of this work is to investigate a wound biofilm model consisting of human plasma, immune cells, and the microorganisms to be studied, thus representing infected wound debris. With the help of fluorescence-labeled microorganisms such as P. aeruginosa, S. aureus, and C. albicans, growth, temporal development, and spatial

distribution can be investigated. Fluorescence-labeled strains allow for two-dimensional and three-dimensional analysis using laser scanning microscopy at defined time points. In addition, the influence of antimicrobial substances is investigated by performing treatments at different time points after inoculation and biofilm formation.

In addition, ten clinical wound debris obtained during sharp debridement will be analyzed in detail at the molecular biological level. Metagenome and metatranscriptome analyses will be used for this purpose, allowing conclusions to be drawn about both the taxonomic composition of the microbial communities and their functional activity. The data obtained will enable a comprehensive characterization of the microorganisms present in chronic wounds, including species that cannot be detected or can only be detected insufficiently using conventional cultivation methods.

This combination of high-throughput molecular biological methods and experimental wound biofilm models is intended to provide new insights into the composition, interactions, and therapeutic resistance of polymicrobial wound biofilms.

EP819 Mechanically active dressings for accelerated healing and reduced scarring

Edward Rees[1]

[1]*Heriot-Watt University, Edinburgh, United Kingdom*

Background: Wounds place a major burden on patients and healthcare systems, causing discomfort, restricted movement, and high treatment costs. Excessive scarring and wound re-opening are common problems strongly influenced by the mechanical forces acting on a wound during healing.

Conventional stitches reduce these forces, demonstrating the importance of tension-shielding, but provide fixed support that does not change as the skin recovers. Consequently, there is increased risk of scarring and re-injury. Mechanically active dressings (MADs) can overcome this by enabling adjustable tension-shielding, though current designs have yet to achieve true adaptability.

Aim: We aim to develop an adaptive MAD that modulates wound tension by varying air pressure within channels embedded in silicone. This will enable investigation of dynamic wound loading strategies to improve healing outcomes.

Methods and Current Progress: MADs were manufactured from biocompatible silicone elastomers (Ecoflex) using 3D-printed moulds for casting and laser-cut fibrous materials for shape control. A pneumatic pump, solenoid valves, and pressure gauge - controlled by an Arduino Due - enabled controlled inflation and deflation to induce shape change. Channel geometry and fibre reinforcement directed deformation along predefined axes, focusing on unidirectional tension across an incisional wound. Mechanical performance was assessed using camera-tracking and tensile force measurements. Ex-vivo testing was conducted on porcine skin with a 4 cm incision, mounted under physiological tension before MAD application and execution of tension-modulating protocols. Preliminary results demonstrate repeatable, pressure-dependent offloading of applied pre-strain (~15%), enabling analysis of time-dependent mechanical effects and uniform wound-edge approximation without adhesive delamination. Visualised surface stretches enabled evaluation of relative skin loading.

Next Steps: Ongoing work will refine multi-axial controllability to enable patient-specific wound customisation. Increasingly complex wound models will be developed prior to progression to in vivo trials, where correlation with healing outcomes will validate clinical potential.

Anticipated Impact/Translation: By providing adaptive tension shielding, MADs have the potential to reduce wound re-opening and scarring, while preserving mobility in extensive wounds, with associated reductions in clinical and economic burden. In parallel, the device enables investigation of wound mechanical stimulation beyond current MAD or conventional tension-shielding approaches, thus informing future research.

OP157 Transcutaneous oxygen pressure measurements of the plantar side of the foot: Expanding the possibilities of trans cutaneous oxygen pressure

Jens Peder Paludan[1]

[1]*Regional Hospital Central Jutland, Viborg, Denmark*

Background: Trans cutaneous oxygen pressure ($TcPO_2$) is well used in the prediction of wound healing. Despite this, little knowledge exists regarding measurements on the plantar side of the foot, where increased skin thickness might impair measurements.

Aim: The aim of this study was to assess the feasibility of $TcPO_2$ measurements on the plantar foot surface, and to establish a method for verifying measurement validity.

Method: Eight healthy male participants had the following examinations performed: Systolic toe and ankle blood pressure, $TcPO_2$ baseline measurement, $TcPO_2$ measurement with 100% oxygen inhalation for 10 minutes, and $TcPO_2$ measurement after end of oxygen inhalation.

Results: Baseline $TcPO_2$, measurements on the lower leg, ankle, dorsal foot and on the medial arch (range 39-76 mmHg) showed comparable results. $TcPO_2$ measurements on the lateral arch were numerically higher (range 67-100 mmHg). Measurements performed on the metatarsal and medial and lateral heel showed the highest values (range 40-111 mmHg). During oxygen inhalation a large median percentage increase in $TcPO_2$ was measured on the lower leg, ankle, and on the dorsal side of the foot (136%, 136% and 105% and respectively). On the medial and lateral arch, an increase in oxygen tension was observed (80% and 54% respectively). Measurements performed on the metatarsal, medial heel and lateral heel, showed a slight increase in oxygen tension (11%, 1% and 1% respectively). A Wilcoxon test showed that the increase in oxygen tension was significant on the following locations: Lower leg, ankle, dorsal foot, metatarsal, medial arch and lateral arch.

Conclusion: $TcPO_2$ seems feasible on the plantar foot, and oxygen inhalation may be used to verify measurements.

LEG ULCER

EP246 Pain perception and management during chemical debridement with a topical desiccating agent

Polina Shabes[1], Waseem Garabet[1], Sven Tilhein[2], Hubert Schelzig[1], Julian-Dario Rembe[1]

[1]Department of Vascular and Endovascular Surgery, University Hospital of Duesseldorf, Duesseldorf, Germany, *[2]Department of Anesthesiology, University Hospital of Duesseldorf, Duesseldorf, Germany*

Aim: The aim of this study was to investigate pain management during the application of a novel topical desiccating agent (TDA) composed of methanesulfonic acid (MSA) and dimethyl sulfoxide (DMSO). MSA/DMSO has been identified as an effective chemical debridement option capable of removing biofilms and necrotic tissue, thereby promoting wound bed preparation and healing. However, its application may occasionally cause a transient sharp pain sensation, depending on the patient's individual sensitivity. This study aimed to assess the prevalence and intensity of application-associated pain and to evaluate two practical strategies for its management.

Method: A single-centre, retrospective case-series design was employed to assess pain associated with MSA/DMSO treatment. Two local anaesthetic techniques were tested to alleviate pain: a topical anaesthetic cream and tumescent local anaesthesia (TLA). Pain levels were recorded using the visual analogue scale (VAS) before, during, and five minutes after treatment. Additional data on wound-related pain, pain during dressing changes, and during the last sharp debridement were collected. Analgesic medication use before and during treatment was also documented. Patients with peripheral neuropathy were excluded to ensure reliable pain assessment.

Results / Discussion: Twenty patients receiving TDA treatment were included. Anaesthetic application occurred 20 minutes before debridement. Chemical debridement caused variable pain (VAS 0–10), but both anaesthetic techniques significantly mitigated discomfort leading to a pain intensity during TDA comparable with conventional sharp debridement, thus resulting in non-inferiority concerning pain ratings.

Conclusion: Pain during chemical TDA debridement can be effectively managed through simple, ready-to-use local anaesthetic methods. Overall, MSA/DMSO treatment was well tolerated, demonstrating comparable or even lower pain levels than sharp debridement, supporting its integration into routine wound care practice.

EP453 Biofilm removal in hard-to-heal wounds using a topical desiccating agent: A rapid noninvasive evaluation with nitrocellulose membrane and alcian blue staining

Hajime Matsumura[1], Rei Omura[2], Reina Matsumura[3], Kazuki Shimada[4], Takako Komiya[4 4], Miki Fujii[4]

[1]Tokyo Medical University, Toikyo, Japan, *[2]Kumagaya-Geka Hospital, Saitama, Japan*, *[3]Fukaya Red Cross Hospital, Saitama, Japan*, *[4]Tokyo Medical University, Tokyo, Japan*

Aim: Chronic hard-to-heal wounds frequently stall due to biofilm on the wound surface. Debridement is essential for wound-bed preparation but confirming biofilm removal typically requires invasive methods. We evaluated a topical desiccating agent (TDA; DEBRICHEM) using a rapid, non-invasive wound-blotting technique (CC step, SARAYA Co., Ltd., Japan) with nitrocellulose membrane and Alcian Blue staining to visualize biofilm in clinical settings.

Method: Seven male patients (56–78 years) with clinically diagnosed chronic wounds containing biofilm were treated with TDA. The agent was applied to the wound surface and margins for one minute. Biofilm detection was performed immediately before treatment, immediately after, and one week later using wound blotting. Post-treatment wound management was based on clinical judgment.

Results / Discussion: Before TDA application, all wounds tested positive for biofilm. Immediately after TDA treatment, all cases became negative for biofilm, indicating complete removal. One week after treatment, all wounds again tested positive for biofilm. Nevertheless, wound-bed preparation was significantly improved, enabling progression toward wound closure: one patient underwent skin grafting after one week, three after two weeks, another two after three weeks, and one achieved closure by direct suturing after four weeks.

Conclusion: In chronic and hard-to-heal wounds, TDA completely removed biofilm and improved wound healing. Moreover, the biofilm-blotting method proved to be a rapid and practical tool for non-invasive biofilm assessment. The cause of the recurrence of a positive result one week later remains unclear, though possibilities include contamination, biofilm reformation due to bacteria in deep tissue, or a false-positive detection result. Further investigation is warranted to determine strategies for maintaining biofilm-free wound conditions after TDA treatment.

EP248 Clinical history of venous leg ulcers: A retrospective analysis of 352 cases from specialised outpatient clinic

Paulina Mościcka[1], Katarzyna Cierzniakowska[2], Justyna Cwajda-Białasik[1], Tomasz Zieliński[3], Arkadiusz Jawien[4], Maria Teresa Szewczyk[1]

[1]Department of Perioperative Nursing, Faculty of Health Science, Ludwik Rydygier Collegium Medicum in Bydgoszcz, Nicolaus Copernicus University in Toruń, 85-821 Bydgoszcz, Poland, Outpatient Clinic for Chronic Wound Management, University Hospital No 1 in Bydgoszcz, Poland, Bydgoszcz, Poland, *[2]Department of Perioperative Nursing, Faculty of Health Science, Ludwik Rydygier Collegium Medicum in Bydgoszcz, Nicolaus Copernicus University in Toruń, 85-821 Bydgoszcz, Poland, Department of General and Minimally Invasive Surgery, University Hospital No 2 in Bydgoszcz, Poland, Bydgoszcz, Poland*, *[3]Centre for Statistical Analysis, Nicolaus Copernicus University in Toruń, 87-100 Toruń, Toruń, Poland*, *[4]Department of Vascular Surgery and Angiology, Ludwik Rydygier Collegium Medicum in Bydgoszcz, Nicolaus Copernicus University in Toruń, Poland, Bydgoszcz, Poland*

Aim: The aim of this study was to analyze the chronicity of venous leg ulcers (VLU) based on the clinical history of patients treated at a specialized outpatient clinic.

Method: The retrospective analyses of administrative data has been done. This retrospective study included patients treated between 2020 and 2023 with a diagnosis of I83.0 or I83.2 according to ICD-10. From an initial cohort of 672 individuals, 352 met the inclusion criteria: the clinical documentation has been completed from the first visit and a normal ankle–brachial index (ABI 0.9–1.3). Patients with missing data or abnormal ABI values were excluded from the analysis.

Results / Discussion: Among the 352 included patients, 104 (29.5%) were younger than 60 years at the time of admission (initiation of care). This group included 8 men below 40 years and 18 women below 50 years of age. Bilateral ulcers were identified in 11 patients (7 women and 4 men). Ulcers occurred more frequently on the left leg (52.6%) in our sample. The longest documented duration of a single ulcer reached 54 years (woman, 78 years old) In 26.9% (n´35) of patients, the current ulcer had persisted for 10 to 60 years. Across the entire group, a total of 522 ulcer recurrences were recorded, ranging from 1 to 9 episodes per patient. On average, every second patient had experienced at least one VLU recurrence during their lifetime.

Conclusion: A detailed analysis of the clinical history of VLU can provide a better understanding of the course of the disease, support therapeutic decisions, and serve to assess the effectiveness of treatment methods.

Keywords: Chronic venous insufficiency, venous leg ulcer, clinical history, retrospective study

EP249 Combining evidence, clinical insight, and economic benefits in the management of leg ulcers

Louise Patullo[1], Elizabeth Merlin-Kwan[1]

[1]NHS, Cheshire, United Kingdom

Aim: To demonstrate the clinical efficacy of Technology Lipido-Colloid Nano-Oligosaccharide Factor (TLC-NOSF) and support clinician confidence in its use, in alignment with the extensive evidence base underpinning the technology. While evidence-based practice remains fundamental, insights gained through direct clinical application can further substantiate published data and enhance clinical confidence.

Secondary objectives include evaluating potential cost efficiencies associated with reduced time-to-healing.

Method: A structured data collection tool was developed to systematically capture baseline clinical information prior to initiating the TLC-NOSF technology treatment. Weekly reviews and data recording were undertaken until complete wound healing, up to a maximum of 12 weeks, or until follow-up was discontinued due to adverse events.

Ongoing monitoring of the dataset enabled timely support and targeted education where required during the project period.

Results / Discussion: Data was collected for thirteen patients, including a comparative subgroup of five patients in which the only variable between treatments was the wound contact layer.

Results demonstrated measurable improvements in wound healing and associated cost efficiencies.

While some advanced dressings incur higher unit costs, earlier healing reduced nursing time, clinic visits and overall resource utilisation. Accelerated healing also lessened the personal and socioeconomic burden on patients, including pain, reduced mobility, and time away from work or daily activities.

These findings emphasize the importance of clinical efficacy and potential cost savings in product selection and decision-making.

Conclusion: Despite higher unit costs the results demonstrate positive clinical outcomes and overall cost-efficiencies. While local results engaged staff, improving confidence and adoption of best practice, the long-term benefits are improved healing rates, reduced clinical workload, and enhanced patient outcomes which support the continued integration of TLC-NOSF into practice.

EP454 Initial management of leg ulcers in community settings: Proposals for a new algorithm for general practitioners

Sophie Blaise[1], Sylvie Meaume[2], Nou Howaldt Monira[3]

[1]Alps University Hospital, Service de Médecine Vasculaire, Grenoble, France, *[2]Hôpital Rothschild (AP-HP), Service Gériatrie, Dermatologie, Unité Plaies & Cicatrisation, Paris, France*, *[3]Hôpital Saint Eloi, CHU, Service Médecine Vasculaire, Montpellier, France*

Aim: Venous leg ulcers (VLUs) affect 1% of people in developed countries, leading to significant healthcare costs and disability. High compression (>40mmHg) is the gold standard, but delays in vascular assessment can delay proper treatment. The ankle–brachial pressure index (ABPI) is used to exclude peripheral arterial disease, though its reliability may vary, especially in diabetic patients. Mild compression (≤20mmHg) has been proposed as a safe interim solution, helping prevent venous hypertension and improving patient adherence before confirming venous aetiology.

Methods: In this paper, written by a group of expert physicians in the field of compression therapy, we propose a pragmatic approach to compression during the initial phase of LU management to optimise patient care and wound healing outcomes.

Results: Guidelines support early mild compression in the absence of arterial 'red flags' (notably chronic limb-threatening ischaemia, CLTI), followed by an increase in compression once venous pathology is confirmed. In France, where only 6.5% of general practitioners perform ABPI, timely vascular assessment is often impractical, leading to delayed interventions. After clinical elimination of any contraindication(s) (such as CLTI, severe neuropathy and/or atypical ulcers with a lack of healing despite hypergranulation), an effective strategy should involve the immediate initiation of mild compression, conducting vascular assessment within 4–6 weeks, and transitioning to high compression if needed and if the patient is able to tolerate it. Hence, mild compression can also be beneficial for patients who do not tolerate high compression.

Conclusion: Given the need to balance safety, efficacy and tolerance, mild compression can be a valuable first-line strategy before specialised intervention, and while waiting for ABPI measurement availability as part of a complete vascular assessment.

EP250 Antimicrobial control first: fibroin scaffold is not enough in infected wounds

Sophie Charlotte Liegenfeld[1], Niklas Philipp Straub[1], Mandy Dittmer[1], Nicolas Krüger[1], Jan Tinson Strenge[2], Arianna Delle Coste[2], Sophie Charlotte Rhode-Wedrich[3], Univ-Prof. Dr. Ewa Klara Stürmer[1]

[1]University Medical Center Hamburg-Eppendorf, Department of Vascular Medicine, Hamburg, Germany, *[2]University Medical Center Hamburg-Eppendorf, Department of Oral and Maxillofacial Surgery, Hamburg, Germany*, *[3]University Medical Center Hamburg-Eppendorf, Department of Plastic, Reconstructive and Aesthetic Surgery, Hamburg, Germany*

Aim: Chronic and/or bacteria-infected wounds remain refractory because biofilm development hinders fibroblast migration and reepithelialization. In contrast, non-infected wounds can heal if the physiological microenvironment is stabilized. Silk fibroin is a promising, additive-free biodegradable biomaterial whose morphology may differentially support repair. We compared two different silk fibroin-based matrices in a standardized human *ex vivo* wound model under non-infected and infected (chronic-like) conditions.

Method: Full-thickness human skin punches (8 mm) received a central 3 mm wound and were maintained at an air–liquid interface. Disks of cast fibroin membrane or electrospun fleece were press-fitted into the wound. In infected cohorts, *Staphylococcus aureus* or *Pseudomonas aeruginosa* inocula were applied. Tissues were harvested over 20 days for blinded histology (H&E, Gram). Investigated parameters were reepithelialization, the bacterial distribution within the tissue, and the infection dynamics with and without fibroin matrices.

Results / Discussion: In non-infected wounds, both constructs accelerated healing significantly versus controls. Membranes consistently supported rapid, near-continuous reepithelialization, forming a smooth migratory substrate and early barrier. Fleeces yielded more dermal interaction, with cellular infiltration along fibers; however, with slower epithelial closure than membranes. Under infected, chronic-like wound conditions, neither format overcame microbial burden: epithelial closure was not achieved, and Gram stains indicated persistent colonization.

Conclusion: Silk fibroin morphology dictates context-specific benefits: membranes act as “runways” for keratinocytes, while fleeces function as permissive 3D scaffolds for ingrowth. However, both effects collapse under infection, underscoring that bioburden control is a prerequisite to scaffold success. These data argue for morphology-guided material selection in clean wounds (membrane to close, fleece to integrate) and for combining fibroin constructs with effective antimicrobial strategies when chronic infection is present.

EP251 Evaluation of clinical signs of chronic venous insufficiency in patients treated with multicomponent calamine compression therapy

Jose García[1], Lucia Avalos Tarifa[2], Montserrat Del Peso Vidal[3], Carmen Alba Moratilla[4], Mercedes Martinez[5], Ana Maria Falcón[6], Remedios Nieto Carrilero[7], Lucía Herreros Sáez[8], Miguel Angel Mellado[9], Mª Mar Izquierdo[10], Rosa Carracedo Martin[11], Silvia Romero Moreno[12]

[1]C.S.I Calpe, ALICANTE, Spain, *[2]C.S. Dr. Ignacio Osuna Gómez, Córdoba, Spain*, *[3]Clinca Ruber Internacional, Madrid, Spain*, *[4]Udima, Valencia, Spain*, *[5]C.S. San Esteban de Gormaz, Soria, Spain*, *[6]U. de Heridas Área V del Hospital Virgen Del Castillo, Yecla, Spain*, *[7]Gerencia de Atención Integrada de Albacete, Albacete, Spain*, *[8]Gerencia de Atención Integrada de Albacete., Albacete, Spain*, *[9]Gerente Heridea, Palencia, Spain*, *[10]Enfermera consulta de UCA, Soria, Spain*, *[11]Unidad funcional de heridas Complejas Centro de salud de Capuchinos, Salamanca, Spain*, *[12]Residencia para Mayores Los Royales, Soria, Spain*

Aim: To evaluate the clinical signs of Chronic Venous Insufficiency (CVI) in patients treated with multicomponent compression therapy using calamine bandages, and to assess the effect of this therapy on the Dermatology Life Quality Index (DLQI).

Method: A quasi-experimental, repeated-measures case series study without a control group was conducted over five weeks. The study included 32 patients presenting with clinical signs of venous insufficiency, classified as C3 to C6 according to the Clinical Etiological Anatomical Pathophysiological (CEAP) classification. The Venous Clinical

Severity Score (VCSS) and the DLQI were used to measure outcomes. Parameters measured included the reduction in edema, ulcer healing, and the decrease in dermatological clinical signs. Compressive therapy was applied using a multicomponent system consisting of a calamine bandage and a short-stretch self-adhesive bandage, achieving a pressure of approximately 40 mmHg.

Results / Discussion: Thirty-two patients were evaluated. Results showed a mean decrease in ankle circumference of 2.85 cm and calf circumference of 3.44 cm. Mean VCSS scores decreased significantly from 15.81 at baseline to 6.75 at the end of the study. Similarly, mean dermatological quality of life scores (DLQI) decreased from 11.3 to 2.95, with the difference in means being highly significant for both scores.

Conclusion: Multicomponent compressive bandaging with calamine-impregnated dressings is effective in reducing edema and clinical signs of inflammation/infection. It substantially improves dermatological quality of life and reduces the clinical severity of venous disease. Furthermore, this therapy facilitates the healing of venous ulcers and reduces associated dermatological manifestations.

EP252 Use of microcurrent EST device* in challenging venous leg ulcers of long duration is both clinically effective and cost-saving

Francesca Russell[1], Lauren Sapnik[2], John Posnett[3]

[1]Oxford Health Community NHS Trust, Abingdon Community Hospital, Oxford, United Kingdom, *[2]Oxford Health NHS Trust, Marcham Road, Oxford, United Kingdom*, *[3]Health Economist, York, United Kingdom*

Aim: To explore the impact of a microcurrent, single-use, portable electrical stimulation therapy (EST) device* on patients with challenging non-healing venous leg ulcers (VLUs) of long duration, which have not healed despite gold standard care.

Method: Eight patients with 11 longstanding VLUs (mean duration >5 years, range 0.5 to 17 years) were treated with EST* for a pre-programmed 12-day duration and followed up to 13-weeks post-treatment. Consumables costs (dressings, bandages, analgesics) for 13 weeks prior and 13 weeks post-treatment were recorded and used to estimate the difference in annual treatment costs pre- and post- EST.

Results / Discussion: Progress to healing was noted in all wounds after treatment. Between baseline and end of follow up, wound area reduced by an average of 50%, wound pain reduced from 9/10 to 4.5/10 and quality of life (QoL) [1] score increased from 12/100 to 62/100. Analysis based on the reduction in wound area post-EST suggests that 9 of the 11 wounds would heal within 12 months.[2] Total consumables spending in the 12-months prior to EST* was £30,214. Because of the expected improvement in healing, in the 12 months post EST, total spending including the cost of EST was estimated to be £21,254, a potential annual saving of £815 per wound. Extrapolating these cost savings across the expected[3] current case -load of non-healing VLUs in the Oxford district nursing team (n=109) could equate to an annual consumables saving of £88,835.

Conclusion: Adoption of EST* reduced pain, improved wound healing and QoL, supporting the current roll out of the Transforming Wound Care Programme (Health Innovation Network) which incorporates the National Wound Care Strategy recommendations. EST* also reduced expenditure on consumables.

EP253 Chronic leg ulcer care for people who inject drugs within a low-threshold social support setting

Jerneja Cater[1]

[1]Homeless Assistance and Self-Help Association Kralji ulice, Ljubljana, Slovenia

Aim: To demonstrate how continuous wound care delivered in a low-threshold social support setting, combined with coordinated pathways to external healthcare services, supports improvement or healing of longstanding chronic leg ulcers and management of comorbid health problems associated with injection drug use.

Method: A 12-month observational study was conducted in a low-threshold social support programme and included 26 adults with a history of injecting drug use and chronic leg ulcers. Wound care was provided three times weekly. At each visit, wounds were assessed. Use and effect of compression therapy were evaluated, and attendance at dressing sessions and specialist diagnostic appointments recorded. Clinical records were reviewed to describe wound-healing progress in relation to dressing regularity, compression therapy and social support.

Results / Discussion: Improvement occurred when several elements aligned: the presence of a low-threshold programme providing social support, access to modern dressings, regular dressings, consistent compression therapy and accompaniment to diagnostic procedures and medical visits. With combined social and clinical support, many chronic leg ulcers stabilised or improved, and some healed. Continuity of care remained challenging, as unstable living conditions, ongoing drug use and limited self-management often disrupted treatment. Sustaining engagement required flexible support that exceeded standard wound-care practice.

Conclusion: Low-threshold programmes provide a safe entry point for people who avoid conventional healthcare due to stigma, allowing them to seek help and receive immediate medical support. By building trust and acting as a bridge to specialist services, they enable more consistent treatment. Within this supportive framework, some chronic leg ulcers heal while others show meaningful improvement. This integrated approach lowers the risk of severe complications, including amputation and life-threatening infection, and enhances overall quality of life.

EP254 Stable ozonides and zinc oxide: effectiveness and adverse events of two bandages in comparison

Roberto Cassino[1], Simone Toscano[1], Francesca Mistò[1], Maria Castoldi[1], Stefania Chiarenza[1]

[1]"Zucchi" Clinical Institutes, Vulnology Center, Monza, Italy

Aim: Bandage materials often cause periwound skin problems; it should be better using "medicated" bandages (especially zinc oxide), which require long treatment periods and often lead to allergic reactions. With this work, we want to demonstrate the effectiveness and safety of a new "medicated" bandage Ozoile®-based, a pool of stable ozonides derived from olive oil*, in comparison with zinc oxide bandage.

Method: 70 patients with leg ulcers were enrolled, divided into two groups of 35 each. Cleansed, fibrinous, and critically colonized ulcers were included; infectious and necrotic ulcers were excluded. Cachectic, neoplastic and terminally ill patients were excluded. Treatment was a 3-layers "high-stiffness" bandage: medicated bandage (OzoGroup-Ozoile®/ZnOGroup-Zinc Oxide), cotton bandage, and self-adherent "short stretch" bandage. Bandage change once/twice a week according with the exudate. Observation period: 8 weeks. Treatment efficacy (lesion and periwound skin), patient discomfort and adverse events were evaluated.

Results / Discussion: OzoGroup: 34 out of 35 patients (97.2%) healed within 6 weeks; one dropout (2.8%) due to patient discomfort (itching); no pain or other adverse events. ZnOGroup: 19 out of 35 patients (54.3%) healed within 6 weeks; 9 dropouts (25.7%): 6 due to allergy development (17.1%) and 3 due to worsening (8.6%). Evaluation of perilesional skin: inflamed in 11 ZnOGroup patients (31.4%), intact in all OzoGroup patients.

Conclusion: This work demonstrates the superior effectiveness of the Ozoile®-based bandage in comparison to the zinc oxide bandage, not only regarding the healing of lesions, but also about safety, given the almost total absence of adverse events/worsenings (only 1 case of itching).

*Rigenoma Bandage (Erbagil, Italy)

EP455 Real-world effectiveness of ON101 topical cream in venous leg ulcer management: A multinational retrospective study

Irene Wang[1], Brock Liden[2], Sanjay Sharma[3], Mohamed Sharkawy[4], Minghsun Liu[5]

[1]Oneness Biotech Co., Ltd., Taipei, Taiwan, [2]Cutting Edge Research LLC, Michigan, United States, [3]Department of Radiology (RPC), All India Institute of Medical Sciences, New Delhi 110029, India, [4]Vascular Surgery Department, Cairo University Hospital, Cairo, Egypt, [5]Woundtech Innovative Healthcare Solutions, Fort Lauderdale, Florida, United States

Aim: Venous leg ulcers (VLUs) are the most common chronic lower-extremity wounds. Due to venous hypertension, VLUs are associated with delayed healing, high recurrence, and long-term outpatient burden. ON101 is a topical cream designed to support skin regeneration in an optimized microenvironment. This retrospective multinational study assessed ON101's effectiveness and safety in VLU treatment.

Method: This retrospective, single-arm study included 10 patients with chronic VLUs at clinical sites in the United States, India, and Egypt. Seventy percent had CEAP class C6 disease, and mean ulcer size was 45.1 ± 110.8 cm^2. Patients received ON101 twice daily for 16 weeks after correction of venous hypertension using grade 3 compression stockings, venous surgery, or perforator ligation according to ulcer severity. Healing outcomes were compared with historical standard-of-care (SOC) data, and safety was monitored throughout treatment.

Results / Discussion: Eighty percent of patients achieved complete healing within 16 weeks, compared to 39% reported with SOC (p=0.0344). Median time to complete healing was 26.5 days, substantially shorter than the 90–180 days typically observed with SOC. Healing rates were consistently high across countries, with the USA showing completion in 3–13 weeks over 3–13 visits, India achieving healing in 6 weeks with 2 visits, and Egypt in 1–2 weeks with a single visit. No adverse events were reported, indicating an excellent safety profile.

Conclusion: ON101 topical cream showed rapid and safe healing performance in the treatment of VLUs after the correction of venous hypertension across diverse real-world settings. Its use was associated with reduced healing time and fewer clinical visits, supporting its role as an effective and practical option for VLU management in global wound care practice.

EP255 Time to wound closure after autograft or placental-derived allograft in venous leg ulcers: Post hoc analysis of ChronEx

Robert Snyder[1], Asi Haviv[1], Adam Singer[2]

[1]MediWound Ltd., Yavne, Israel, [2]Stony Brook University, Stony Brook, NY, United States

Aim: Effective wound bed preparation and timely wound closure are essential in managing chronic lower-extremity ulcers. Evidence describing healing trajectories after autograft or allograft use in VLUs is limited. This post hoc analysis assessed closure incidence and timing following grafting procedures in the ChronEx RCT.

Method: ChronEx randomized VLU patients to up to two weeks (eight daily applications) of BBD (bromelain-based debridement), placebo gel vehicle (PLC), or non-surgical standard of care (NSSOC), followed by 12 weeks with non-active dressings. Autograft or allograft use during follow-up was permitted per investigator judgement.

Complete closure was defined as 100% re-epithelialization without drainage or dressing need, confirmed at two weeks. Closure incidence and timing (mean, median, range) were summarized descriptively; no between-group statistical analyses were performed.

Results / Discussion: Nine patients received autografts (ESX n=5, PLC n=3, NSSOC n=1). Mean age was 68.2 years; median wound size 5 cm^2; wound age 36 weeks. All achieved complete debridement and full granulation coverage after the treatment phase. Overall, 78% reached complete closure within 12 weeks. Mean time to closure was 14 days (median 18.5; range 7-45).

Seven patients received placental-derived allografts (ESX n=2, PLC n=3, NSSOC n=2). Mean age was 71.4 years; median wound size 5.4 cm^2; wound age 19 weeks. Five achieved complete debridement and granulation coverage. Overall, 43% reached closure. Mean time to closure was 27.3 days (median 21; range 21–40).

Conclusion: Autografting after wound bed preparation yielded higher closure rates and faster healing (≈2–3 weeks), whereas allograft-treated wounds showed lower closure incidence and slower trajectories (≈3–6 weeks). These findings provide practical insight into expected healing timelines following grafting in VLU.

EP256 Improving care for patients with venous leg ulcers in the Netherlands: Insights from professionals in wound care

Stella Amesz[1], Femke Beekmans[2], Jennifer Reijntjens[3], Gini van der Heijden[4], Elise van den Helder[5], Caroline Klaver[6], Jorn Langereis[7], Arlien Van der Kleijn[8], Arianne Oberendorf[9], Marita Schlepers[10], Dominique Koobs[7], Esther van der Wel-Luijendijk[11], Jolet Wiering-Muurling[12]

[1]Deventer Ziekenhuis, Deventer, Netherlands, *[2]Zorgboog, Helmond, Netherlands*, *[3]Elkerliek kliniek, Helmond, Netherlands*, *[4]Eurocept Clinics, Rotterdam, Netherlands*, *[5]ZorgBrug, Gouda, Netherlands*, *[6]Amarijn, Middelburg, Netherlands*, *[7]Rode kruis Ziekenhuis, beverwijk, Netherlands*, *[8]Groene hart Ziekenhuis, Gouda, Netherlands*, *[9]Mölnlycke Healthcare,, utrecht, Netherlands*, *[10]UMCG, Groningen, Netherlands*, *[11]Careyn, Delft, Netherlands*, *[12]icare, Emmen, Netherlands*

Aim: Venous leg ulcers (VLU) are among the most time- and resource-intensive complex wounds. Despite high professional expertise, outcomes vary across settings. This study explored current clinical practices, challenges, and opportunities to improve VLU care in the Netherlands as part of an ongoing national improvement initiative.

Method: A mixed-methods approach was used, combining (1) thirteen semi-structured interviews with nurse practitioners, dermatology nurses, and wound consultants across hospital, community, and transmural settings; (2) an online survey assessing VLU management, collaboration, and perceived barriers in daily practice; and (3) a multidisciplinary consensus meeting with wound-care professionals to reflect on findings and define priorities for improvement.

Results / Discussion: Findings revealed a committed and experienced professional community with strong wound-care competencies and high job satisfaction. However, several structural challenges were identified: limited coordination between care levels, high time pressure, and variable access to diagnostic tools. Compression therapy, although being the gold standard for VLU and widely recognised as essential for wound healing, remains a significant obstacle. The identified barriers include patient discomfort, difficulties with self-management, and low adherence after healing. Recurrence rates were reported to range from 15% to 20% in hospitals to 60% to 70% in home care. The consensus meeting emphasised the need for patient education, user-friendly compression systems, integrated follow-up, and structured collaboration between care levels.

Conclusion: VLU care in the Netherlands is characterised by strong clinical expertise, though coordination between different levels of care could be improved. This ongoing project aims to develop evidence-based recommendations for a national, multidisciplinary wound-care pathway to improve outcomes, strengthen adherence support, and prevent recurrence.

EP257 Compression therapy in venous leg ulcers: insights intoadherence, effectiveness and barriers in dutch wound carepractice

Stella Amesz[1], Femke Beekmans[2], Jennifer Boeremboom[3], Gini van der Heijden[4], Elise van den Helder[5], Caroline Klaver[6], Arlien Van der Kleijn[7], Jorn Langereis[8], Arianne Oberendorf[9], Marita Schlepers[10], Dominique Koobs[8], Esther van der Wel-Luijendijk[11], Jolet Wiering-Muurling[12]

[1]Deventer Ziekenhuis, deventer, Netherlands, *[2]Zorgboog, Helmond, Netherlands*, *[3]Elkerliek Kliniek, Helmond, Netherlands*, *[4]Eurocept Clinics, Rotterdam, Netherlands*, *[5]Zorgbrug, Gouda, Netherlands*, *[6]Amarijn, Middelburg, Netherlands*, *[7]Groene Hart Ziekenhuis, Gouda, Netherlands*, *[8]Rode Kruis Ziekenhuis, Beverwijk, Netherlands*, *[9]Mölnlycke Healthcare, Utrecht, Netherlands*, *[10]UMCG, Groningen, Netherlands*, *[11]Careyn, Delft, Netherlands*, *[12]Icare, Emmen, Netherlands*

Aim: Compression therapy is essential in venous leg ulcer (VLU) care, yet adherence and daily use remain challenging. This study explored professionals' experiences with compression as part of a broader national assessment of VLU care.

Method: A descriptive survey on compression therapy was distributed among wound-care professionals across hospital, community, and transmural settings. Responses were analysed to evaluate adherence patterns, barriers to correct use, compression types applied, patient-reported outcomes, and continuation after healing. Findings were considered alongside interviews (n = 13) and a national practice survey.

Results / Discussion: Correct use of compression by patients was reported to occur often (57.2%) and sometimes (42.8%). Major barriers to adherence included discomfort or pain (the most commonly cited), difficulty applying and removing compression stockings, and lack of patient knowledge or instructions. Professionals estimated that 25–50% (43.9% of the professionals) or 51–75% (43.9%) of patients with uncomplicated VLU heal within 12 weeks with proper compression. Only a few reported a higher percentage (14.2%). Commonly used methods included multilayer bandages, therapeutic elastic stockings, and ulcer stockings. Continuation of compression after healing varied, from early discontinuation to long-term or permanent use. Most patients experienced symptom relief, particularly reduced pain and swelling, and also reported functional limitations, such as reduced mobility or difficulty dressing. These findings align with the main project's conclusions, which highlight adherence issues, inconsistent follow-up, and variability in compression practices across different settings.

Conclusion: Compression therapy is widely applied and effective, yet discomfort, practical challenges, and gaps in patient understanding limit its impact. Together with broader project insights, these findings emphasise the need for clearer guidance, improved usability, and more consistent national practice in VLU care.

EP258 Enhanced silver dressing improves slough and debridement in venous leg ulcers: Post hoc analysis of a randomized controlled trial

Rebecca Rodger[1], Jan Ljungqvist[1], Beate Paintner-Hanson[1], Janet Mackenzie[2]

[1]Convatec Technology Centre, Deeside, United Kingdom, *[2]Convatec Technology Centre, Lexington, MA, United States*

Aim: To evaluate slough and complete debridement outcomes from a randomised controlled trial (RCT)[1] comparing a carboxymethylcellulose dressing containing ionic silver, ethylenediaminetetraacetic acid and benzethonium chloride (CISEB)* versus a dialkylcarbamoyl chloride-coated dressing (DACC)† in hard-to-heal venous leg ulcers (VLUs).

Method: Patients with hard-to-heal VLUs were randomised 1:1 to receive CISEB or DACC for up to four weeks. VLUs not healed by week 4 were managed with standard of care for up to 12 weeks or until healed. Slough tissue percentage and complete debridement status were assessed at baseline and Days 14, 28, 42, 56, 70, and 84. Outcomes included relative slough reduction, proportion of wounds fully debrided, and time to complete debridement.

Results / Discussion: This post hoc analysis included 181 patients (CISEB: n=93; DACC: n=88). Baseline mean slough coverage was 37.6% for CISEB and 40.3% for DACC. At Day 14, the mean percentage slough reduction from baseline was 57.5% for CISEB vs 26.0% for DACC, representing a statistically significant difference ($p = 0.035$). Slough improvement persisted to Day 84, with the mean percentage reduction reaching 88.1% (CISEB) vs 74.6% (DACC). Complete debridement was observed in 50.5% (CISEB) vs 40.9% (DACC) at baseline and 95.7% vs 84.1% at Day 84 ($p = 0.005$). Median time to complete debridement was shorter for CISEB (14 days) compared to DACC (28 days).

Conclusion: CISEB demonstrated superior slough reduction and complete debridement compared with DACC. Faster debridement may help reduce infection risk and accelerate healing. These post hoc findings reinforce the RCT results and support the role of CISEB in managing hard-to-heal VLUs.

References:

[1] Beraldo S et al. *J Wound Care* 2025;34(3):170-178.

*Aquacel Ag+ Extra

†Cutimed Sorbact

EP259 Improving adherence to compression therapy in a tropical setting: Early outcomes of adjustable compression wrap for treatment and maintenance of venous disease

Cheng Cheng Karine Goh[1]

[1]Tan Tock Seng Hospital, Singapore, Singapore

Aim: Adherence to compression therapy remains a significant challenge in venous leg ulcer (VLU) management and the prevention of recurrence. This issue is amplified in the tropical setting, where higher temperatures and humidity make long-term compression bandaging uncomfortable and intolerable. Adjustable compression wraps utilizing inelastic short-stretch technology are emerging as a promising alternative toolkit due to their ability to provide 30-40mmHg compression and generally higher patient acceptance and satisfaction.

Method: This outpatient case series was conducted at a tertiary hospital's multidisciplinary wound clinic. Three patients referred for compression therapy were subsequently fitted for adjustable compression wraps following appropriate sizing and education on self-application. The primary outcomes assessed include wound size reduction and/or the circumference of the affected limb (ankle and calf). The secondary endpoints were patient acceptance, time to healing, and adverse events.

Results / Discussion: Three patients (mean age 58 years) were included, with two presenting with active ulcers and one referred for maintenance compression following ulcer healing, but poor compliance with compression stockings. One patient presented with a 1.5-year history of ulcers previously treated with multilayer compression bandaging and tubular bandage; the bilateral foot wounds (21cm^2 and 22.5cm^2 at baseline) showed minimal progress and remained largely stagnant. This patient was enrolled in an adjustable compression wrap, which was well tolerated throughout the 6 weeks, resulting in a 68.9% reduction in wound area. On average, we also observed effective oedema reduction, with calf circumference decreasing by an average of 4%.

Conclusion: Early results from a pilot trial indicate that adjustable compression wraps improve patient engagement, enhance adherence, and support better healing outcomes, even in tropical climates where traditional multilayer bandaging is often poorly tolerated.

EP456 Metagenomic and metatranscriptomic characterization of wound biofilms: Deeper insights beyond classical microbiology

Mandy Dittmer[1], Christian Müller[2], Nicolas Krüger[1], Sophie Charlotte Liegenfeld[1], Ifey Alio[3], Univ-Prof. Dr. Ewa Klara Stürmer[1]

[1]Universitätsklinikum Hamburg Eppendorf, Translationale Wundforschung, Hamburg, Germany, *[2]Universitätsklinkum Hamburg Eppendorf, Bioinformatik Facility, Hamburg, Germany*, *[3]Universität Hamburg, Abteilung Mikrobiologie und Biotechnologie, Hamburg, Germany*

Aim: Wound biofilms are detected in more than 75% of chronic wounds and represent a major challenge in wound healing. These microbial "fortresses," often composed of different bacterial species, are highly tolerant to antimicrobial treatment. When various microorganisms enter a wound, they not only interact with human tissue but also with

each other through synergistic or competitive mechanisms. In clinical routine, wound swabs and antibiograms are commonly used; however, it is known that approximately 99.8% of microorganisms cannot be routinely cultivated. Modern metagenome and metatranscriptome analyses therefore provide deeper and more comprehensive insights into the wound microbiome.

Method: Wound debris from 10 patients, removed by sharp debridement, was analyzed using metagenomic and metatranscriptomic methods. The results were compared with those from conventional routine microbiological swab testing.

Results / Discussion: Although a large proportion of the wound debris consisted of human genetic material, metagenomic analysis identified between 8 and 40 bacterial species per patient from approximately 30 genera. This provided more detailed information about the bacterial consortium than conventional microbiological swabs. Metatranscriptome analysis detected over 500 different genera, significantly exceeding the diversity revealed by metagenomics. In addition, these analyses offered valuable insights into pathogen activity and behavior.

Conclusion: Modern molecular techniques such as metagenome and metatranscriptome analyses enable a far more comprehensive characterization of microbial diversity in chronic wounds than traditional culture-based methods. While routine swabs detect only a small proportion of present microorganisms, molecular approaches reveal a highly complex and dynamic microbial community, including information on active gene expression. These deeper insights enhance our understanding of biofilm formation and pathogenic behavior and may significantly influence future diagnostic and therapeutic strategies for chronic wounds.

EP457 Fungi in chronic wounds - the underrepresented pathogens?

Mandy Dittmer[1], Sophie Charlotte Liegenfeld[1], Nicolas Krüger[1], Arianna Delle Coste[2], Maria Geffken[4], Ifey Alio[3], Univ-Prof. Dr. Ewa Klara Stürmer[5]

[1]Universitätsklinikum Hamburg Eppendorf, Translationale Wundforschung, Hamburg, Germany, *[2]Universitätsklinikum Hamburg Eppendorf, Department für Mund- Kiefer- Gesichtschirurgie, Hamburg, Germany*, *[3]Universität Hamburg, Abteilung für Mikrobiologie und Biotechnologie, Hamburg, Germany*, *[4]Universitätsklinikum Hamburg Eppendorf, Institut für Transfusionsmedizin, Germany*, *[5]Universitätsklinikum Hamburg Eppendorf, Hamburg, Germany*

Aim: Antimicrobial biofilms are a major problem in infected wounds. This does not necessarily have to be bacterial burden; fungal and yeast infections can increase the damage to the wounds and reduce the chances of healing. However, in clinical routine mycoses are widely underestimated. According to previous studies, about 20% of chronic wounds are colonized by fungi. It is well known that biofilms are more tolerant to antimicrobial treatments, but the composition of these communities and the resulting interactions can also have an influence. For example, Candida can exacerbate the (wound-) infection of *S. aureus* even though under normal conditions these are typical microbiome microorganisms.

Method: *C. albicans* and *S. aureus* were observed in single- and mixed species human biofilm models, which consisted of bloodplasma, immune cells and the specific microorganisms. Hereby the tolerance to antiseptics like octenidin-dihydrochloride/Phenoxyethanol and polyhexamethylene biguanide was examined using quantitative suspension method (QSM), and their spatial distribution in the biofilm was analyzed using confocal laser scanning microscopy.

Results / Discussion: In our study, the presence of *S. aureus* triggered an increase formation of (pseudo-) hyphae, which is known as a virulence factor of *C. albicans*. These hyphae can produce better penetration and invasion of the host tissue. This could also enable *S. aureus* to penetrate tissue more effectively, as it appears to adhere to the hyphae in the process.

Conclusion: Wound biofilms do not necessarily consist solely of bacteria. Fungi are also active in chronic wounds. However, due to their eukaryotic physiology, they react differently to antimicrobial substances and can form unfavorable alliances with bacteria.

EP262 Pilot study evaluating sub-bandage pressure of a new 3-in-1 compression bandage in healthy volunteers

Valentina Dini[1], Antonella Vietina[1], Alessandra Michelucci[1], Francesco Rizzello[1], Giovanni Mosti[2], Marco Romanelli[1], Angrit Namislo[3], Christine Böhm[3], Martin Abel[3]

[1]University of Pisa, Department of Dermatology, Pisa, Italy, *[2]Clinica MD Barbantini, Angiology Department, Lucca, Italy*, *[3]Lohmann & Rauscher GmbH & Co. KG, Neuwied, Germany*

Aim: To evaluate safety and performance of a new compression bandage[1] combining skin layer, padding layer and compression layer.

Method: In this prospective, monocentric Post-Market Clinical Follow up pilot study the investigational device and a comparator device were applied to legs of 22 healthy volunteers over the course of one week. Each participant had both bandages applied randomly to either leg. Sub-bandage pressures were measured directly after bandage application, after 1 and 3 days as well as after one week. Additionally, slippage of the bandages, wearing comfort and wearing tolerance as well as the occurrence of adverse events were assessed.

Results / Discussion: 19 out of 22 participants completed the study. Mean application pressures of both devices were well above 40 mmHg (investigational device: resting pressure 46±7 mmHg, working pressure 56±11 mmHg; comparator device: resting pressure 46±6 mmHg, working pressure 59±12 mmHg). The resting pressures dropped over the course of one week to 19±9 mmHg (investigational device) and 12±7 mmHg (comparator), while working pressures still reached 24±14 and 15±9 mmHg, respectively. Average bandage slippage was limited to less than 5 cm after 3 days for both bandages. Wearing comfort and tolerance of both bandages were rated similarly positively, except for the parameter 'itching', which was reported significantly more with the comparator device. No serious adverse events were reported.

Conclusion: Both compression devices maintained therapeutic working pressures and tolerable resting pressures over one week, while being well tolerated.

[1] Rosidal® 1C

EP263 Exploring the narrative of people with dark skin tones about their progression and experience of chronic venous insufficiency (CVI) of the lower limb: A qualitative descriptive study

Victoria Clemett[1], Jemell Geraghty[1], Neesha Oozageer Gunowa[2], Lukla Biasi[3], Sue Woodward[1]

[1]King's College London, London, United Kingdom, *[2]University of Surrey, Guildford, United Kingdom*, *[3]Guy's and St Thomas' NHS Foundation Trust, London, United Kingdom*

Aim: Chronic venous insufficiency (CVI) of the lower limb has notable disparities in severity and treatment outcomes across skin tones. However, the experiences of CVI in people with dark skin tones is under-explored. This study aimed to explore the patient journey and experiences of individuals within this population.

Method: Semi-structured interviews were conducted in patients with dark skin tones living with a venous leg ulcer (VLU), or their family members. Invitations to participate were shared through the "Be Part of Research" network, accessing interested people in leg ulcer research, through the local NHS Foundation Trust (community and hospital clinics) and on social media. Interviews were transcribed and analysed inductively using Braun and Clarke's thematic analysis framework. (Clinicaltrials.gov: NCT06798766, Ethical Clearance Reference: 25/EE/0091).

Results / Discussion: To date, seven patients (86% male) with dark skin tones and CVI of the lower limb living in the United Kingdom or their family members were interviewed between July to November 2025.

Interim analysis reveals frequent gaps in preventative strategies and inconsistent use of comprehensive lower limb assessments in primary and urgent care. Participants reported dismissed concerns. Some experienced barriers accessing general practitioner appointments.

Following referral to specialist services, patients expressed satisfaction, particularly valuing education about their condition and improved perceptions of treatment. However, cosmetic, functional and psychological needs remain unmet. Frustration arose from clinicians' expectations of appropriate healing times and their expectations, especially for working age individuals.

Conclusion: Experiences of people with dark skin tones living with lower limb CVI reveal significant gaps in prevention, early assessment and holistic care. Addressing these barriers through equitable, person-centred strategies and timely referral is essential to improve outcomes and reduce health inequities.

EP264 Cold atmospheric plasma disrupts biofilm-associated infection: Mechanistic in-vitro, porcine, and clinical fluorescence evidence from bench to bedside

Steven Jeffery[1]

[1]*Birmingham City University, Birmingham, United Kingdom*

Aim: Cold atmospheric plasma (CAP) is a non-pharmacological adjunct for complex wounds where infection, biofilm and impaired healing persist despite best-practice wound therapy. Multidrug-resistant (MDR) pathogens are increasingly relevant also in conflict-related injuries and civil disaster response, as seen in recent developments. A large-area occlusive plasma foil (CPT) was developed to deliver homogeneous CAP over extensive wound surfaces with consistent dosing and practical bedside application. This study analysed its antibacterial effectiveness and potential to support wound healing.

Method: CPT was evaluated in vitro, in a deep-dermal porcine MRSA wound model with established biofilm (24-72 h), and in a prospective self-controlled clinical study of chronic lower-limb wounds. Assays quantified CFU reductions in MDR isolates; porcine wounds were compared with sham dressings using microbiology and blinded histology. Clinically, fluorescence-based molecular imaging (MolecuLight®) tracked bacterial signals and tolerability.

Results / Discussion: In vitro, CPT produced rapid 10^6-10^7 CFU reductions within seconds across all tested resistant Gram-negative and Gram-positive strains. In the porcine model, plasma-treated wounds showed dose-dependent MRSA reduction and 72 h biofilm disruption, reaching 2.5 log10 reduction (≈99%) without macroscopic or histological damage. In molecular imaging of 20 patient wounds, fluorescence declined significantly over time ($p<0.001$) with significant paired conversion to fluorescence-negative status ($p<0.01$). The CPT foil was well tolerated with no treatment-related adverse events.

Conclusion: These findings provide a proof of concept for large-area CPT-CAP as an adjunctive biophysical therapy that reduces microbial burden including MDR pathogens, disrupts biofilm and may support wound-bed optimisation. In severe burns or other large area wounds, where infection control and graft-bed preparation are critical, CPT-CAP may offer an additional tool for an optimized wound therapy. Ongoing multicentre randomised evaluation (POWER study, expected mid-2026) will further define clinical utility, indications and treatment parameters.

EP458 Gentle efficiency: A clinician acceptability study of a debridement pad in european community-based wound care clinics

Izzy Rosewarne[1], Mats Wendel[1], Brigitte Bauer[1]

[1]*Mölnlycke Health Care, Gothenburg, Sweden*

Aim: Chronic wound healing can be delayed by the accumulation of slough/necrotic tissue and bacterial biofilm, which form physical barriers to granulation and re-epithelialisation of the wound. Debridement is used to remove these barriers and is a key component of chronic wound care. Choice of debridement modality is influenced by factors like wound type/size and available clinical expertise, but should also consider patient acceptance/pain tolerance. A survey of healthcare professionals (HCPs) was conducted to determine their level of satisfaction with a single-use debridement pad on chronic wounds.

Method: Surveys were conducted at high-volume wound care clinics in the UK, Czech Republic and the Netherlands. Survey respondents were asked to rate the performance of the debridement pad from "very dissatisfied" to "very satisfied" using two questionnaires, and follow-up interviews were conducted with HCPs to gather qualitative feedback.

Results / Discussion: 27 HCPs responded to the first survey, and 33 responded to the second. In pooled results, HCPs characterised the debridement pad as intuitive to use, with 69% of HCPs "satisfied" or "very satisfied" with the pad's performance. Ratings were similarly high for removal of senescent, dry skin and areas of hyperkeratosis of surrounding skin (67% "satisfied" or "very satisfied"). Importantly, 81% of respondents were "satisfied" or "very satisfied" with the pad's ability to perform low pain debridement. In follow-up interviews, the debridement pad was described as both more gentle and more efficient than comparable products.

Conclusion: The performance of the single-use debridement pad was rated highly across all categories surveyed, with most HCPs indicating that they were "satisfied" or "very satisfied" with its ease of use and performance, particularly with regard to pain free debridement.

EP265 Evaluation of TLC-NOSF dressings in the management of leg ulcers: A Brazilian primary health care case series

Lidiany Felix[1], Fabiana Carvalho[2], Daniela Alencar[2], Vanessa Azevedo[3], Bruna Rafaldini[3]

[1]Universidade Federal de Campina Grande, Campina Grande, Brazil, *[2]Secretaria Municipal de Saúde de Savador, Salvador, Brazil*, *[3]Urgo Medical Brasil, São José dos Campos, Brazil*

Aim: To evaluate the effectiveness of technology lipido-colloid nano-oligosaccharide factor (TLC-NOSF) dressings in the management of leg ulcers by assessing improvements in the RESVECH 2.0 score and the rate of healing in Brazilian Primary Health Care.

Method: This was a prospective, longitudinal, observational case series conducted from May to September 2024. Twenty patients with chronic leg ulcers were recruited from the Family Health Strategy in Salvador, Bahia, Brazil. Wounds were monitored using the RESVECH 2.0 questionnaire (pre- and post-treatment). Descriptive statistics, Wilcoxon signed-rank test, and Spearman correlation were applied.

Results / Discussion: Patients were predominantly over 50 years old, with balanced sex distribution, 90% with venous etiology, and typically chronic (mean 39.9 months). The TLC-NOSF dressing was applied twice weekly. Total treatment duration averaged 86.6 days (range: 12–160 days), resulting in an average healing rate superior to 80% of the lesion area. Clinical improvement was observed in 100% of patients (20/20), with no cases of worsening. The RESVECH 2.0 score reduced by over 13 points ($t(19)=14,85$; $p<0,0001$), indicating multidimensional improvement. The Wilcoxon test confirmed a statistically significant effect on the healing process ($Z = -3,93$; $p < 0,001$). The results found are consistent with current international guidelines that recommend the use of TLC-NOSF dressings in the treatment of patients with chronic lower limb wounds.

Conclusion: TLC-NOSF dressings demonstrated a positive impact on leg ulcer healing in Primary Health Care, promoting significant and clinically relevant improvement in RESVECH 2.0 scores. The study reinforces the potential of TLC-NOSF as an effective care technology for the global management of leg ulcers.

EP459 Evaluation of transforming powder dressing for treatment of chronic venous ulcers: Results of a randomized controlled trial and two observational case series

Rajiv Chander[1], Jonathan Allan[1], Barakat Abdelreheem[2]

[1]Division of Vascular Surgery, James J. Peters Veterans Affairs Medical Center, Bronx, United States, [2]Plastic and Reconstructive Surgery Department, Faculty of Medicine, Helwan University, Cairo, Egypt

Aim: Chronic venous ulcers (CVUs) heal slowly, recur frequently, and generate significant cost. Current standard of care (SOC) for CVUs is adequate compression and conventional dressings. A prospective randomized clinical trial (RCT) and two multi-site case series evaluated the role of transforming powder dressing (TPD) plus compression compared to SOC. Hydrated TPD forms an extended wear (up to 30 days), moist non-occlusive film that covers and protects the wound under compression.

Method: The RCT enrolled 60 subjects [TPD = 30; SOC = 30] with average wound duration of over 30 months. The two multi-site observational studies (n=7) compared TPD to conventional SOC in patients with persistent CVUs.

Results / Discussion: In the RCT, TPD showed higher healing rates than SOC at 12 weeks (43.3% vs 10.0%; p=.004) and 24 weeks (86.7% vs 40.0%; p<.001). TPD patients healed faster (16.7 vs 37.0 weeks; p<.001), required significantly fewer dressing changes (23.9 vs 196.0, p<.001), reported less pain (Visual Analogue Scale 1.4 vs 2.9; p<.001) and fewer pain medications (6.7% vs 36.7%; p=.005).

In the first observational series of patients (n=3) with recurring ulcerations who initially underwent conventional SOC, TPD was utilized on the reoccurring ulcers and patients served as their own control. TPD reduced healing time (15.1 vs 27.6 weeks) and decreased dressing changes from multiple to once weekly. In the second series (n=4), recalcitrant CVUs unresponsive to >6 months of SOC healed within 88 days after TPD conversion, with dressing changes reduced to once weekly.

Conclusion: TPD was associated with significantly higher healing rates, shorter duration to healing, less pain and pain medications, and decreased dressing changes compared to current SOC in the treatment of CVUs.

EP266 Use of hyaluronic acid (HA) and six amino acids (Glycine, L-Proline, L-Leucine, L-Lysine, L-Valine, L-Alanine) in injectable and powder form for the tratment of chronic vascular ulcers of the lower limbs refractory for over 10 years

Panfilo Di Gregorio[1]

[1]Asl1Abruzzo, Sulmona, Italy

Aim: The objective is to test the combination of hyaluronic acid (HA) + 6 amino acids in injectable and powder form in the treatment of vascular ulcers of the lower limbs that have been hard to heal for 10 years.

Method: Fifteen patients with stage III–IV vascular ulcers of the lower limbs were enrolled (10 men and 7 women; age range 60–77 years). Antibiotic therapy was prescribed according to wound swab results. Dressing was performed every three days an included first wound hygiene, then HA+6AA powder on the lesion and hydrofiber. Every third day, after applying lidocaine cream for 30 minutes, HA+6AA was injected into the ulcer once weekly and subsequently covered with HA+6AA powder and hydrofiber. A rigid compression bandage was applied in the limb.

Results / Discussion: All 15 treated patients showed progressive improvement, achieving complete healing within 10 weeks, regardless of ulcer etiology or size.

Conclusion: The combined use of HA and six amino acids, in both injectable and powder form, proved to be well tolerated and effective in healing chronic, hard-to-heal vascular ulcers that had persisted for over a decade.

EP267 Significant healing of a chronic vascular ulcer using a porous crystalline regenerative membrane: A case report

Luciana Mendes[1], Fabiana Vanni[2], Ana Beatriz Mendes[3], Larissa Moog[4]

[1]LM Medical, Salvador, Brazil, *[2]Secretaria Municipal de Saúde de Salvador, CurAtiva Clin, Salvador, Brazil*, *[3]Universidade Nove de Julho, São Paulo, Brazil*, *[4]Universidade Estácio de Sá Curitiba, Curitiba, Brazil*

Aim: To describe the clinical outcome of a porous crystalline regenerative membrane in the treatment of a long-standing chronic vascular ulcer refractory to multiple advanced therapeutic approaches.

Method: This descriptive case report involves an elderly female patient with a chronic vascular ulcer persisting for 19 years and associated metabolic risk factors. The lesion had previously been treated with several advanced wound care strategies, including modern dressings, laser therapy, and autologous stem cell skin grafting, without achieving sustained healing. Treatment was initiated with a porous crystalline regenerative membrane, in combination with the application of a barrier spray to the perilesional skin to prevent moisture-associated skin damage and maceration. Clinical follow-up focused on wound area reduction, granulation tissue formation, epithelialization, exudate control, and preservation of perilesional skin integrity.

Results / Discussion: After initiation of regenerative membrane therapy, the wound demonstrated marked and progressive clinical improvement. Substantial enhancement of granulation tissue, advancement of epithelialization, and effective exudate control were observed. During follow-up, an approximate 80% reduction in wound area was achieved. The perilesional skin remained intact throughout treatment, with no signs of maceration, supporting the effectiveness of the barrier strategy. Overall wound progression was considered significant, particularly given the prolonged chronicity of the ulcer and the history of previous therapeutic failure.

Conclusion: This case report suggests that a porous crystalline regenerative membrane may represent an effective therapeutic option for chronic vascular ulcers with long-standing evolution and resistance to multiple advanced treatments. The observed clinical outcomes support its potential role in advanced wound care strategies for complex vascular lesions.

NEGATIVE PRESSURE WOUND THERAPY

EP268 Negative pressure, positive outcomes: combination of single use npwt and hyaluronic acid in surgical wounds healing by secondary intention

Tuğçe Aksan[1], Ecem Eren[1], Ezgi Şanlı[1], Derya Uymaz[2], İbrahim Özata[2], Emre Balık[2]

[1]Koç University Hospital, Istanbul, Türkiye, *[2]Koç University School of Medicine, Istanbul, Türkiye*

Aim: This case series evaluated the efficacy of single-use, silicone-based negative pressure wound therapy (suNPWT) combined with hyaluronic acid (HA) powder in surgical wounds healing by secondary intention, focusing on exudate control, healing time, and tissue outcomes.

Method: Seven patients with dehisced incisions or stoma closure sites were treated using size-appropriate suNPWT devices. HA powder was sprinkled over the wound bed, and wounds with edges approximating (except P3) were supported with sterile strips. Dressings were changed based on the condition of the wounds.

Patients	Wound Type	Wound Size	Wound Characteristics	Products Used	Total Therapy Days
P1	Port placement site	3x2	Slough/fibrin, erythema, moderate exudate	suNPWT 15x15; HA	9
P2	Stoma closure	6x2	Edematous, moderate-high exudate	suNPWT 15x15; HA	14
P3	Stoma closure	5x4x3	Erythema, mild exudate	suNPWT 15x15; HA	13
P4	Abdominal incision	30x1x1	Erythema, moderate-high exudate	Conventional → suNPWT 10x35; HA	13
P5	Stoma closure	5x8x4	Moderate-high exudate	Conventional → suNPWT 15x15; HA	8
P6	Abdominal incision	2x1x4	Erythema, moderate-high exudate	suNPWT 10x20; HA	8
P7	Abdominal incision	5x10x3	Erythema, moderate exudate	Conventional → suNPWT 10x20; HA	11

Results / Discussion: All wounds healed completely without sutures, with no hypergranulation or hypertrophic scarring. Healing took an average of 11.1 days. Conventional NPWT was stopped in three cases due to discomfort. Literature shows epithelialization takes 57-104 days for secondary healing and 18-32 days after stoma closure. The fast, complication-free healing suggests suNPWT with HA promotes granulation and epithelialization.

Conclusion: suNPWT combined with HA powder offers a safe, comfortable, and effective solution for open surgical wounds, reducing healing time and enhancing tissue quality compared to conventional NPWT. Larger prospective studies are needed to verify these findings.

EP460 Negative pressure wound therapy in lower limb fractures: Evidence from systematic reviews and guidelines

Hsu-Tang Cheng[1]

[1]*Asia University Hospital, Taichung City, Taiwan*

Aim: Lower extremity fractures, particularly open tibial injuries, carry a high risk of infection and wound complications. Negative pressure wound therapy (NPWT) has been proposed as an adjunct to conventional dressings to improve soft tissue management. This study aims to synthesize current evidence on the effectiveness of NPWT in traumatic lower limb fractures.

Method: A review of recent systematic reviews, meta-analyses, and clinical guidelines was conducted, including studies by Kim and Lee (2019), Grant-Freemantle et al. (2020), Alves et al. (2024), Barone et al. (2024), and the AAOS guideline summary (Goldman & Tetsworth, 2023). Key outcomes evaluated included infection rates, reoperation, union rates, and timing of reconstruction.

Results / Discussion: Meta-analyses demonstrated that NPWT reduced deep infection rates, unplanned reoperations, and flap failure compared with conventional dressings. Evidence also highlighted the utility of NPWT as a temporizing measure prior to definitive soft tissue coverage. However, results were less consistent regarding union rates and long-term functional outcomes. While heterogeneity existed in fracture severity and NPWT protocols, pooled data support NPWT as superior in infection control and wound optimization.

Conclusion: NPWT is a safe and effective adjunct in the management of open lower limb fractures, particularly for infection prevention and soft tissue stabilization. Current guidelines endorse its use after major extremity trauma. Further high-quality randomized trials are needed to refine indications, standardize protocols, and evaluate cost-effectiveness in diverse patient populations.

EP269 Closed incision negative pressure therapy use evaluation following high-risk caesarean section in a middle east population

Haidar Aal Mussa[1], Siobhan Lookess[2], Hatem Abdelrahman[1], Hadeel Al-Khannaq[1], Lobna Hamouda[1], Alexa Russell[2], Aishah Abdullah[1], Minimole Amma[1]

[1]*Dibba Hospital, Diba Al-Fujairah, United Arab Emirates*, [2]*Solventum, Maplewood, United States*

Aim: Surgical site complications (SSCs) following caesarean section may impact maternal morbidity and mortality. Closed incision negative pressure (ciNPT*) has been used to mitigate post-surgical complications. However, limited evidence exists on ciNPT use over caesarean section incisions in the United Arab Emirates (UAE). The effect of ciNPT in the management of closed incisions following caesarean section was examined.

Method: Patients underwent caesarean section between 2022 and 2024 at a single acute care hospital in the UAE. All 82 patients underwent vaginal cleansing and received antibiotics prior to surgery. Pfannenstiel incision was used, followed by closure with subcuticular suturing. Patients received either traditional silver dressings (SOC, n=28) or ciNPT (n=54) for postoperative care. SOC dressings remained in place for 3-7 days, while ciNPT dressings were changed every 5-7 days. Patient and incision outcomes were assessed. Two sample t-tests compared continuous variables and Fisher Exact tests compared categorical variables.

Results / Discussion: No significant differences exist between the groups. The ciNPT group had a higher proportion of severely obese patients (body mass index > 40 kg/m^2) and patients who had two or more previous caesarean deliveries (p>0.05). The ciNPT group had a lower SSC rate compared to the SOC group (0/54 [0%] vs. 6/21 [21%], respectively; p=0.0011), as well as a lower number of surgical site infections (0/54 [0%] vs. 3/28 [11%]; p=0.037) and deep infections (0/54 [0%] vs. 3/28 [11%]; p=0.037).

Conclusion: ciNPT was well tolerated and may help improve clinical outcomes in high-risk patients undergoing caesarean delivery. Limitations include retrospective design and potential selection bias, as only high-risk patients were included in the study. Large-scale randomized trials are needed to confirm these findings.

EP461 Combined far-infrared therapy and negative pressure wound therapy in crush injury management

YuShan Shih[1], Chia Fan Lin

[1]*Cathay General Hospital, Taipei, Taiwan*

Aim: The management of complex crush injuries remains a challenge. Far-infrared (FIR) therapy has shown promising effects on blood flow and healing, but its combined use with negative-pressure wound therapy (NPWT) has not been reported. This report describes the combined use of FIR and VAC for a severe crush injury, detailing the clinical course and outcomes to evaluate the potential of this therapeutic approach.

Method: A 35-year-old woman sustained bilateral lower-limb crush and degloving injuries following a vehicular accident. She presented with open fractures of the first to fifth metatarsals in the left foot and, post-operation. The injuries resulted in subcutaneous soft tissue edema and dermal necrosis measuring approximately 20 × 20 cm. The patient underwent five surgical debridements and was treated with Biobrane. On postoperative day 8, FIR was initiated twice daily for 40 minutes per session. After 20 days, treatment transitioned to NPWT. Nutritional support included increased iron, protein, amino acids, and vitamin D3 (36,000 IU/day) to improve endothelial function.

Results / Discussion: By postoperative day 29, fracture wounds had healed, NPWT was removed, and Biobrane integration reached approximately 70% on the left foot and 90% on the right lower leg. Dressing changes were reduced from five times per day to once daily. Hemoglobin improved from 6.0 g/dL to 10 g/dL. The patient was able to stand, get out of bed, and mobilize with a wheelchair.

Conclusion: This case demonstrates that the synergistic combination of FIR and NPWT enhances wound repair, and it underscores the key role of integrated management—including vascular assessment, infection control, advanced dressings, targeted devices, and nutritional support—in managing complex wounds.

EP270 Transition from traditional negative pressure wound therapy to single use negative pressure wound therapy - a retrospective analysis of wound management experience in acute care

Connie Johnson[1], Sophie Berry[2], Jonathan Minton[2], Mandy Spitzer[3], Catherine McCarthy[2]

[1]*Penn Medicine Princeton Health, New Jersey, United States*, [2]*Smith+Nephew, Watford, United Kingdom*, [3]*Smith+Nephew, Fort Worth, United States*

Aim: Understanding of when to transition between traditional negative wound pressure therapy (tNPWT) and single use systems (sNPWT) to manage acute wounds is limited.[1] This retrospective study aimed to evaluate which wounds were transitioned from tNPWT to sNPWT in a real-world setting.

Method: A retrospective chart review of treatment pathways and clinical outcomes for all patients with wounds eligible for NPWT (tNPWT or sNPWT*) presenting at a single acute care facility in the USA from February 2023 to September 2024 was performed. All wounds were treated with continuous NPWT administered at either -80 or -120mmHg.

Results / Discussion: Electronic medical records for 27 patients were available for review. Mean duration of NPWT was 9.8 days (median 7 days; range: 3–60 days). Estimated daily mean wound area reduction was 5.8% (median value 3.2%) with improvements in wound volume also observed. Of the 27 wounds treated with tNPWT, 8 were successfully transitioned to sNPWT. No wounds were managed first line with sNPWT, although many were potentially suitable for this approach based on exudate levels, wound depth and wound area.

Conclusion: Approximately 30% of wounds included in this retrospective review of real-world practice were successfully transitioned from tNPWT to sNPWT, facilitating earlier hospital discharge without compromising clinical outcomes. No wounds were managed using first line sNPWT suggesting potential underutilization.

Reference:

1. Kirsner RS, et al. *Wounds*. 2020;32(12):328-333.

*tNPWT: RENASYS◊ TOUCH Negative Pressure Wound Therapy System, RENASYS◊-F Foam Dressing Kit with Soft Port, RENASYS◊ White Foam or RENASYS◊ AB Abdominal Dressing Kit with Soft Port, or sNPWT: PICO◊ 7 or PICO◊ 14 Single Use Negative Pressure Wound Therapy System (all systems: Smith+Nephew, UK)

EP271 Digit salvage therapy with integrated Chinese and Western medicine

Mingzhi Song[1]

[1]*Shanghai Key Laboratory of Orthopedic Implant, Department of Orthopedic Surgery, Shanghai Ninth People's Hospital, Shanghai Jiao Tong University School of Medicine, Shanghai, China*

Aim: To evaluate the feasibility of a staged, integrated approach combining nibbling debridement, negative pressure wound therapy, and a herbal ointment to avoid amputation in digit injuries with necrosis or infection.

Method: Five retrospective cases with typical lesions received our integrated traditional Chinese and Western medicine digit salvage therapy. These cases were with necrosis and defect or osteomyelitis. According to the patient's different lesion characteristics, we carried out the integrated treatment of traditional Chinese and Western medicine including nibbling debridement, negative pressure wound treatment (NPWT), herbal ointment, rehabilitation exercise and common surgical techniques.

Results / Discussion: We considered that precarious alive tissue (PAT) in the residual tissue of the lesion area was very important, especially for promoting tissue regeneration and repairing defects. By nibbling debridement, PAT can be accurately identified. NPWT could protect wound, control infection and fully absorb the effusion. The herbal ointment was used for dressing changes. While rehabilitation exercise is very important to promote the function recovery. Additionally, bone drilling, skin-grafting and immobilization were also used in different cases. The affected finger or toe healed completely during 1.5–18 months. All patients restored the movement function of the adjacent joints in the lesion area. There was no recurrence of infection or complaint of pain.

Conclusion: Therefore, traditional Chinese and Western medicine digit salvage therapy may offer an alternative to amputation in select cases. However, further research with larger sample sizes and controlled trials are still needed before wide application of this therapy.



Figure 1
A collage shows the various stages of the finger injury, treatment, and recovery. The top row demonstrates the progressive healing of the finger from severe injury to recovery. The middle row showcases the changes in X-ray images before and after treatment. The bottom row illustrates the preserved finger with a satisfactory appearance after combined therapy with NPWT, MEBO and immobilization. The subsequent rehabilitation exercises of the adjacent joint achieved functional compensation.

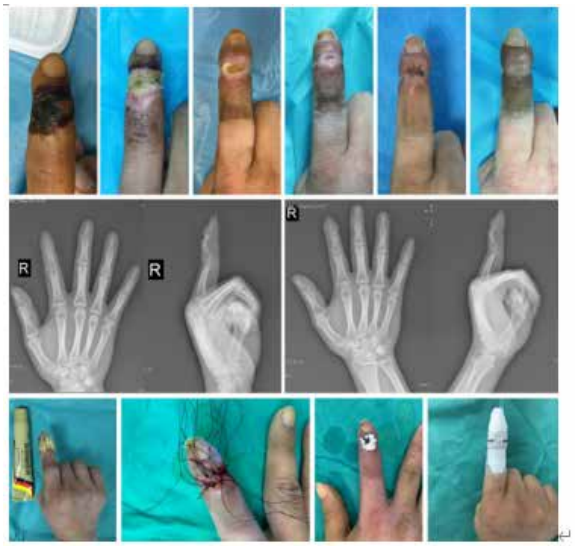

Figure 2
A collage illustrates the progression of the finger treatment. The first row displays the finger at different healing stages, showing the changes in the wound over the interphalangeal joint. The second row presents the changes in X-ray images before and after treatment. The third row depicts the application of MEBO ointment, skin graft, and the post-treatment condition of the finger.



Figure 3
A series of images demonstrates the progression of the finger treatment. The top row shows the progressive changes in the finger during the treatment course. The middle row presents X-ray projections of the hand from different angles before and after treatment. The bottom row illustrates the successful preservation of the patient's right middle finger following surgical exploration, meticulous debridement, NPWT and rehabilitation exercises.



Figure 4.
A series of images documenting a finger medical case. The top row demonstrates the progressive healing changes of a finger with a subungual abscess. The middle row displays radiographic images before and after treatment. The bottom row illustrates the complete recovery process achieved through nibbling debridement of necrotic tissue combined with NPWT and MEBO application.



Figure 5.
A collage displays multiple images depicting the progression of a condition affecting the foot. The top row illustrates the healing process of the foot, starting from an interdigital laceration and dorsal skin avulsion through to gradual recovery. The middle row presents radiographic images before and after treatment. The bottom row shows a series of photographs documenting the successful preservation of the patient's toes following immobilization with the plaster, medical infrared therapy, and topical MEBO application. The rehabilitation exercises were also carried out.

TABLE 1 Patient information.

Case number	Sex	Age, years	Pathogenesis	Main disease type	Lesion location	Exposed structures	Duration of treatment, months	Main therapeutic method
1	W	12	Injury caused by heavy objects	Infection and tissue necrosis	Distal interphalangeal joint and distal section of left indicative finger	Distal phalangeal bone, interphalangeal joint, residual tendon at the insertion of extensor tendon	18	Nibbling debridement, NPWT, MEBO, brace fixation and rehabilitation
2	M	38	Strapping wound	Tissue necrosis	Distal interphalangeal joint of the right index finger	Interphalangeal joint and extensor tendons	12	Nibbling debridement, NPWT, MEBO, skin graft and rehabilitation
3	W	58	Stab wound	Infection	Distal interphalangeal joint of right middle finger	Interphalangeal joint	2	Incision and drainage, nibbling debridement, NPWT, MEBO and rehabilitation
4	W	51	Stab wound	Infection	Distal section of left index finger	Distal phalangeal bone and nail bed	1.5	Incision and drainage, nibbling debridement, NPWT, MEBO and rehabilitation
5	M	59	Injury caused by heavy objects	Tissue necrosis	Right third toe and foot dorsalis	Interphalangeal joint, extensor toe tendon and distal phalanx	4	Nibbling debridement, NPWT, MEBO, brace fixation and rehabilitation

W: woman; M: man; NPWT: negative pressure wound treatment; MEBO: moisture burn ointment.

TABLE 2 Complete clinical information and timeline.

Case number	Occupation	Mechanism	Outside care	Pathogen	Family/ psychosocial	Final ROM	Timeline
1	Student	Crush by the school desk	Debridement + nail-bed sutures; antibiotics	*Staphylococcus aureus*	Accompanied by parents; schooling prioritized	PIP 0°–90°	Trauma → outside debridement/ sutures/antibiotics → presentation (~1 m) → serial debridement ×3 (q3–5 d) + NPWT → phalangeal drilling → deformity correction → rehabilitation → closure/end 18 m
2	Zipper factory worker	Work-related strap injury	Observation; multiple amputation recommendations	–	Occupational injury; preservation prioritized	PIP 0°–90°	Work injury → observation elsewhere (5 w) → presentation → debridement + NPWT → bone trim → free skin graft → rehabilitation → closure/end 12 m
3	Barbecue restaurant worker	Bamboo skewer puncture	Disinfection; 3 antibiotic courses; osteomyelitis on X-ray	*Bacillus aeruginosa*	Accompanied by employer; manual work demands	MCP 20°–60°	Puncture → outside antibiotics (6 w) → presentation (~2 m) → incision exploration + debridement → rinse catheter + NPWT → closure (8 w) → rehabilitation
4	Garment factory worker	Nail puncture by sewing machine	Initial disinfection; amputation advised elsewhere	*Staphylococcus aureus*	Desire for cosmesis and function; job-related needs	DIP 0°–90°	Puncture → swelling/pain → presentation (~1 m) → debridement + drainage → NPWT + rinse → MEBO → rehabilitation → closure (6 w)
5	Manual laborer	Wall collapse (crush)	K-wire fixation; skin reattachment; plaster; IR therapy; MEBO	–	Return-to-work considerations	MTP 30° ext./20° flex	Wall collapse → emergency fixation/suturing → necrosis (2–4 w) → fine debridement → NPWT ×3 (q5 d) → phalangeal drilling → MEBO → rehabilitation → closure (16 w)

IR: infrared; NPWT: negative pressure wound treatment; MEBO: moisture burn ointment; ROM: range of motion; DIP: distal interphalangeal joint; PIP: proximal interphalangeal joint; MCP: metacarpophalangeal joint; MTP: metatarsophalangeal joint; ext/flex: extension/flexion; bid: twice daily; q3–5 d/q5 d: every 3–5 days/every 5 days; m: month(s); w: week(s); d: day(s).

EP272 Quality improvement audit for hard-to-heal wounds using single-use NPWT

Eleni Zisimopoulou[1], Julia Seidl[2], Sylvia Festl[2]

[1]Smith & Nephew, Hamburg, Germany, *[2]Fachklinik Osterhofen, Osterhofen, Germany*

Aim: To evaluate the clinical effectiveness, patient related benefits and economic impact of a -80-mmHg single-use negative pressure wound therapy (sNPWT) device* in routine practice for hard-to-heal wounds.

Method: A Quality Improvement Audit (QIA) was conducted at a specialised amputation care and chronic wound facility in Germany between 27th May and 13th November 2025 using SnapSurveys (Bristol, UK) platform. Data were collected from 29 patients with hard-to-heal wounds. Each wound was documented before sNPWT initiation, weekly during therapy and after transition back to conventional dressings. sNPWT was discontinued once sufficient wound improvement or closure was achieved. Outcomes included wound-healing progression, wound-area reduction, dressing-change frequency, patient comfort/mobility and staff satisfaction.

Results / Discussion: Before sNPWT, ten wounds were clinically stagnant, ten showed delayed healing and five were deteriorating; four had no prior status. During sNPWT 14 out of 29 wounds fully healed, 14 showed measurable

wound-area reduction and one showed no response. Dressing changes decreased from 4.9/week pre-sNPWT to 1.7/week during therapy (65% reduction, p<0.01; paired t-test). After returning to standard dressings, dressing change increased to 2.4/week. This reduction highlights significant economic benefits, including lower use of dressings and substantial reduction in nursing time as well as being associated with greater patient comfort, reduced pain, and improved mobility benefits. Overall, the patients' experience and the staff satisfaction was high, with 96.4% rating the sNPWT device as good or very good.

Conclusion: This QIA demonstrates clinical effectiveness, improved patient experience and reduced resource use, supporting the integration of sNPWT as an efficient, practical and sustainable approach in real-world management of hard-to-heal wounds.

*PICO™ (Smith and Nephew, Hull, UK)

EP273 A prospective study on standard versus advanced wound dressings for the prevention of post-operative complications in post-bariatric plastic surgery

Ludovica Livieri[1], Luigi Annacontini[1 1], Vincenzo Verdura[1], Luigi Cagiano[1], Aurelio Portincasa[1], Domenico Parisi[1 1]

[1]Dipartimento di Chirurgia Plastica e Ricostruttiva, Foggia, Italy

Aim: The aim of this work is to compare the effectiveness of advanced versus standard dressings in reducing post-operative complications, accelerating wound healing times, improving cosmetic outcome, and patient satisfaction.

Method: The prospective, single-center, observational study enrolled 42 patients who underwent post-weight loss plastic surgery. In the pool of participants, 22 subjects received advanced dressings while 20 followed the standard protocol. Follow-up was personalized according to the type of intervention, the risk profile and the type of medication applied. Wound healing score, incidence of post-operative complications, and subjective satisfaction via Likert questionnaire were assessed. Statistical analyses included descriptive tests, bivariate analyses using chi-square and t-tests, logistic regression for complications, multiple linear regression for satisfaction, and Spearman correlation.

Results / Discussion: Patients treated with advanced dressings showed a significant reduction in the risk of complications and a higher healing score than the standard group. The correlation between recovery score and satisfaction was moderate and positive, while the linear regression model showed that the recovery score is a significant predictor of global satisfaction, even after adjusting for age, sex, BMI, pre-operative pathway and complications. In addition, the absence of comorbidities was confirmed as an additional protective factor.

Conclusion: The systematic adoption of advanced dressings in post-bariatric plastic surgery is associated with a lower incidence of complications, an acceleration of healing times and an increase in patient satisfaction. It is recommended to implement personalized protocols in high risk patients. Future studies will need to thoroughly evaluate cost-effectiveness analysis and include extensive follow-up to verify the durability of clinical outcomes.

EP274 The use of negative pressure wound therapy fortrunk wounds management - a clinical study

Camelia Tamas[1], Cristina Stanescu[2], Radu Tataru[1], Angela Tecuceanu[1], Irina Jemnoschi-Hreniuc[1], Catalina Pintilie[1]

[1]Grigore T. Popa University of Medicine and Pharmacy Iasi, Emergency Saint Spiridon County Hospital Iasi, Iasi, Romania, *[2]University Dunarea de Jos Galati, Emergency Saint Spiridon County Hospital Braila, Braila, Romania*

Aim: Soft tissue defects located on trunk, either acute or chronic, are often difficult to treat, are time and important resources consuming. Negative Pressure Wound Therapy (NPWT) devices demonstrated, already, their capacity to improve tissue cleansing and stimulate the vascular network to develop. Our clinical study describes the use of NPWT for trunk soft tissue defect reconstruction, both in acute and chronic wounds.

Method: We evaluated the efficiency of NPWT in 28 cases with trunk complex soft tissue defects which needed reconstruction with skin grafts. In all the cases (16 acute, 12 chronic wounds) we used NPWT to prepare the soft tissue defects for skin-grafting. Two different protocols were followed after skin-graft reconstruction: group 1 - classic dressing (vaselinated gause - 14 cases); group 2 - NPWT to protect the skin graft and to stimulate graft healing process (14 cases). We compared the duration of graft healing, pain level and the quality of scars for the two groups of patients. To compare local pain, constriction sensation and difficulty in daily patient mobilisation we used a scale with 5 levels.

Results / Discussion: The healing process duration was shorter for the patients from group 2: 14-12 days after the skin graft reconstruction, comparing with 20-18 days for the first group. The patients from the second group related less pain while walking or moving.

Immediately after the reconstruction, NPWT offered the best conditions for wound healing by reducing local edema, maintaining graft adhesion to the wound bed, stimulating new vessels to grow and nourish the skin graft.

Conclusion: NPWT provided a better quality of local healing, in a shorter time and with lower costs.

EP275 Evaluation of the efficacy and safety of silver-impregnated foam in negative pressure wound therapy for diabetic foot ulcers

Mehmet Mert HIDIROGLU[1], Hamdullah Yanik[2], Yasin Gulap[1], Eda Kural[1], Sımay Akyuz[1], Kerim Bora Yilmaz[3]

[1]Department of General Surgery, University of Health Sciences, Gulhane Training and Research Hospital,, Ankara, Türkiye, *[2]Department of Basic Oncology, Cancer Institute, Hacettepe University, Ankara, Türkiye*, *[3]Department of General Surgery, University of Health Sciences, Gulhane Training and Research Hospital,, Department of Medical and Surgical Research, Institute of Health Sciences, Hacettepe University, Ankara, Türkiye*

Aim: Silver-based products are frequently used in diabetic foot treatment to optimize infection control. Silver supports wound healing by reducing microbial load, suppressing inflammation, and stimulating granulation and epithelialization. Due to these properties, it has been incorporated into modern wound care products. In clinical practice, silver-impregnated foams have recently been preferred over standard foams within Negative Pressure Wound Therapy (NPWT). However, the possibility of silver accumulation and toxicity has raised concerns. This study evaluated the efficacy and safety of silver-impregnated foam NPWT in diabetic foot ulcers.

Methods: Pre- and post-treatment blood and urine silver concentrations were measured in patients undergoing silver-impregnated NPWT to assess toxic risk. Treatment efficacy was compared using flow cytometric analysis of tissue samples obtained before and after treatment from patients managed with conventional dressings (n=50), standard NPWT (n=40), and silver-impregnated NPWT (n=36). Changes in wound size were also documented.

Results/Discussion: Although silver concentrations increased after treatment, they did not reach toxic levels. Flow cytometry showed that CD38+, CD86+, CD206+, and CD209+ immune cell levels were highest in the silver-impregnated NPWT group, while the conventional dressing group showed the weakest response. These findings indicate that silver-impregnated foam NPWT promotes wound healing by enhancing M1 and M2 macrophage activity and exerting anti-inflammatory effects.

Conclusion: Silver-impregnated foam NPWT appears to be an effective and safe modality for diabetic foot ulcers. By increasing immune cell activity and supporting granulation tissue, it offers advantages over conventional dressings and standard NPWT in accelerating wound healing.

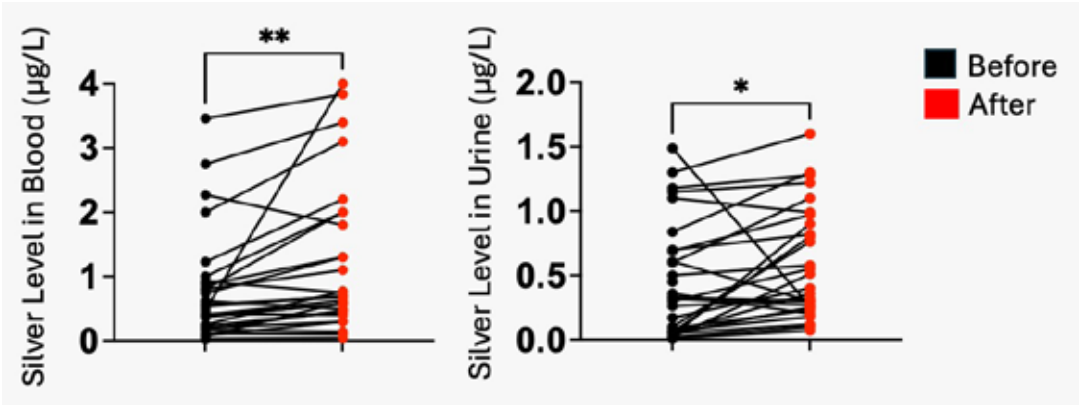

Figure 1. Silver Level in Blood and Silver level İn Urine

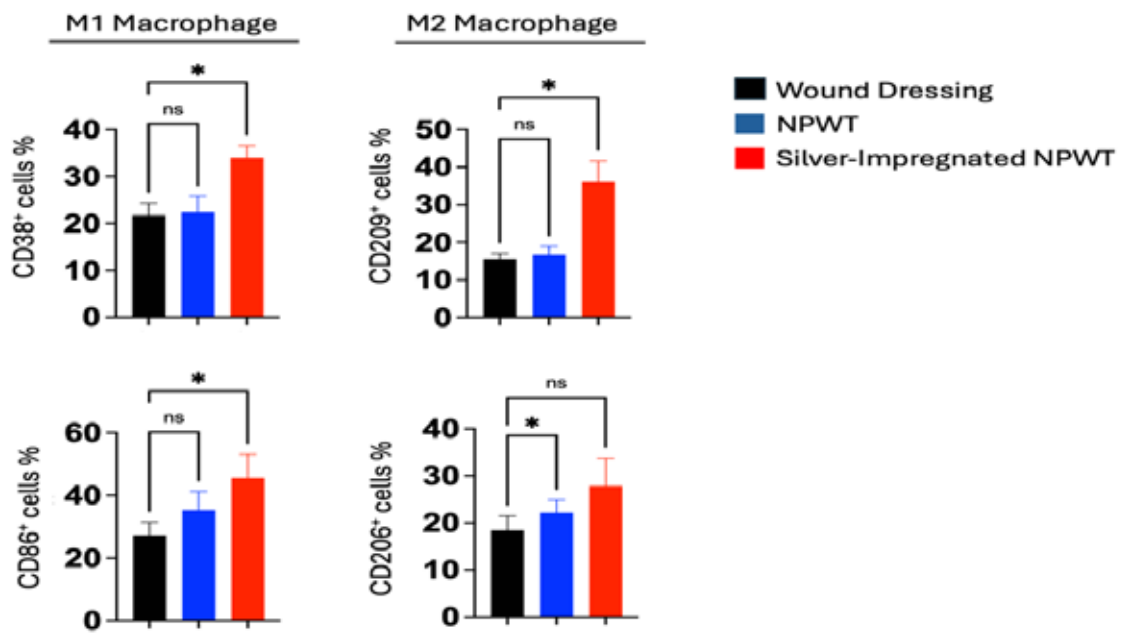

Figure 2. M1 and M2 macrophage profiles across treatments



Figure 3. Silver-Impregnated Foam in NPWT for Diabetic Foot Ulcers

EP462 Accelerated healing and improved patient outcomes with ON101 topical cream as an adjunct to NPWT in diabetic foot ulcers: Real-world study

James Liao[1], Mohamed Sharkawy[2]

[1]Oneness Biotech Co., Ltd., Taipei, Taiwan, [2]Vascular Surgery Department, Cairo University Hospital, Cairo, Egypt

Aim: Diabetic foot ulcers (DFUs) often require negative pressure wound therapy (NPWT) to reduce wound size and prepare the wound bed for closure or grafting, yet many ulcers fail to achieve timely closure. This study evaluated whether combining ON101 topical cream with NPWT improves healing outcomes compared with standard of care (SOC) plus NPWT.

Method: Patients received ON101+NPWT (n=5) or SOC+NPWT (n=18). All ulcers were managed under an etiologic-detection protocol addressing healing-retarding factors, which was considered mandatory for wound-closure success. Antibiotic therapy was provided as needed. ON101 ulcers were 20% Wagner grade 2 and 80% grade 3 (mean 60±49.4 cm^2), whereas SOC ulcers were Wagner grade 2 (mean 22.2±20.6 cm^2). In the ON101 group, ON101 was normally applied twice daily but, with NPWT, at 2–3-day dressing intervals. Outcomes included healing rate, time to closure, NPWT duration, amputation, rehospitalization, and mortality.

Results / Discussion: The ON101+NPWT group achieved 100% complete healing by week 16, compared with 5.6% in the SOC+NPWT group (p=0.0002). Mean time to healing was 5.6 weeks in ON101 group and 25.1 weeks in SOC group (p=0.000019). NPWT duration was 50% shorter with ON101 (2–3 vs 4–8 weeks). Over a 1-year follow-up, zero amputations, rehospitalizations, or deaths in ON101+NPWT group, whereas SOC+NPWT cohort had 22.2% amputations, rehospitalization in 88.9% of patients (mean 2.06 times), and 5.6% mortality.

Conclusion: In DFU patients receiving NPWT, adding ON101 enhances granulation and epithelialization, supporting faster healing, shorter treatment duration, and lower risks of amputation and morbidity. As an adjunct to NPWT, ON101 may streamline wound recovery, lessen healthcare burden, and improve patient quality of life, highlighting its clinical and economic values in advanced wound care.

EP463 Surgical site complications after revision total hip or knee arthroplasty: A prospective study of a single use negative pressure wound therapy system in a high-risk cohort

Philip Huang[1], Jennifer O'Connell[2], Liis Teene[2], John Timmons[2]

[1]OrthoIndy, Indianapolis, United States, [2]Molnlycke Health Care, Gothenburg, Sweden

Aim: Total hip arthroplasty (THA) and total knee arthroplasty (TKA) are increasingly common procedures. While rates of surgical site complications (SSCs) are relatively low in primary procedures, approximately one in 20 TKAs will require revision within 10 years, with rates of complications up to 15-fold higher with revision. Closed incision negative pressure wound therapy (ciNPWT) is increasingly used to prevent SSCs in patients undergoing revision arthroplasty. A study was undertaken to evaluate the performance of a canister-based, single-use, NPWT system following revision THA or TKA.

Method: The investigation was undertaken at 7 high-volume orthopedic centres in the USA. The primary endpoint was the proportion of patients with at least one SSC within 90 days of post-revision surgery. Secondary endpoints included the incidence of surgical site infection (superficial, deep, or organ space) dehiscence, haematoma, and seroma formation at 30 and 90 days, and drainage within 14 days.

Results / Discussion: A total of 105 patients were recruited. At 30 days post-operatively, 3 patients had experienced an SSC, none of which were deemed to be device-related. Importantly, skin was deemed 'healthy' by investigators at 99.0% of assessments, with no maceration, haematomas or seromas reported. Mild blistering was reported in 5 patients, but peri-wound skin was still deemed 'healthy' by investigators in two of those cases.

Conclusion: In this report of 30-day study findings, the canister-based NPWT system performed well after revision THA and TKA. Low SSC incidence and highly favourable outcomes relating to skin condition were reported. Systems that can reduce the risk of SSCs occurring in high risk patients while minimising skin blistering around the incision site are desirable to health care providers, payers and patients.

EP276 Neuromuscular scoliosis: Surgical wound outcomes comparing conventional dressings and incisional negative-pressure wound therapy

Lima Priscila[1], Yoneiama Isadora[1]

[1]AACD, São Paulo, Brazil

Aim: To evaluate postoperative wound complications in spinal surgeries by comparing conventional dressings with incisional negative-pressure wound therapy (iNPWT) in patients with neuromuscular scoliosis.

Method: A longitudinal, retrospective, exploratory, observational study was conducted including 100 patients who underwent spinal surgery between 2017 and 2021. Fifty patients received conventional dressings and fifty received iNPWT. Twenty-five clinical and surgical variables were assessed. Statistical analyses adopted a two-tailed α of 0.05 and a 95% confidence interval.

Results / Discussion: The overall complication rate was 37%, mainly consisting of wound exudate and suture dehiscence. Patients treated with conventional dressings experienced more complications during hospitalization (88.24%), while those receiving iNPWT had a higher proportion of complications after discharge (50%) ($p = 0.03$). No additional variables showed statistically significant differences. At one-year follow-up, surgical site infection was slightly more frequent in the conventional dressing group (14%) compared with the iNPWT group (12.24%). Although not statistically significant, the findings suggest that iNPWT may reduce exudate burden and postoperative infection risk, indicating a potential clinical benefit in this high-risk population.

Conclusion: Patients with neuromuscular scoliosis present high rates of postoperative wound complications. iNPWT demonstrated a trend toward lower infection rates and reduced exudate compared with conventional dressings, though without statistical significance. Studies with larger sample sizes are needed to confirm the effectiveness and potential superiority of incisional iNPWT in this surgical context.

EP464 Incidence of surgical site complications after primary total hip or knee arthroplasty: A comparison of silver-containing dressings with single use negative pressure therapy in a low-risk cohort

Philip Huang[1], John Pavia[2], John Timmons[2]

[1]OrthoIndy, Indianapolis, United States, *[2]Molnlycke Health Care, Gothenburg, Sweden*

Aim: Surgical site complications (SSCs) are expensive and cause significant mortality and morbidity. Single-use closed-incision negative pressure wound therapy (ciNPWT) systems may reduce SSCs in high-risk patients, but their benefit for low-risk patients is underexplored. An investigation was undertaken to compare the rate of SSC between low-risk cohorts treated with silver-containing dressings with silicone wound contact layer (SD) vs. ciNPWT following primary total hip arthroplasty (THA) or total knee arthroplasty (TKA).

Method: A retrospective registry study was conducted using a large dataset (Premier Database, approximately 700,000 patients) who had undergone primary THA or TKA in the USA between 2022-2024. Low-risk patients were defined as scoring <2 at the time of surgery on the Charleston Comorbidity Index. The primary endpoint was the difference in the proportion of subjects who developed at least one SSC within 90 days of surgery between those who had SD applied compared to those who had ciNPWT applied.

Results / Discussion: A total of 10,351 patients in the SD group and 921 patients in the ciNPWT were identified as low-risk; the uneven distribution between groups was resolved using propensity score matching. In the matched cohort, 4/921 (0.4%) of the SD group and 12/921 (1.3%) of the ciNPWT group experienced at least one SSC within 90 days, resulting in a risk ratio (RR) of 0.33. The primary analysis demonstrated non-inferiority of SD relative to ciNPWT ($p<0.01$). A sensitivity analysis confirmed the primary analysis.

Conclusion: SD was non-inferior to ciNPWT in the prevention of SSCs after primary THA or TKA surgeries in low-risk patients. These findings support the use of SDs as a cost-effective and practical alternative to ciNPWT in low-risk THA/TKA outpatients.

EP465 A prospective study to confirm the performance of a canister-based single-use negative pressure wound therapy system in low-to-moderately exuding chronic wounds

John Timmons[1], Beele Hilde[2]

[1]Molnlycke Health Care, Gothenburg, Sweden, *[2]Ghent University Hospital, Ghent, Belgium*

Aim: Between 1-2% of the world's population will experience a chronic wound over their lifetime, causing significant pain and socioeconomic burden. Negative pressure wound therapy (NPWT) is an established means for managing hard-to-heal chronic wounds including diabetes-related foot ulcers (DFUs), venous leg ulcers (VLUs) and pressure ulcers (PUs). A clinical investigation was undertaken to confirm the safety and performance of a canister-based NPWT system when used as intended in the management of low- to moderately-exuding chronic wounds for up to 28 days.

Method: A prospective non-comparative, multi-centre study was undertaken at 14 sites in seven European countries. The study covered a broad spectrum of wounds, reflecting the inclusion of both inpatients (67.7%) and outpatients (32.3%), with a composite and standardized primary outcome measure capturing variables like wound size and condition ('wound progression').

Results / Discussion: A total of 104 patients were recruited, with an average wound duration prior to study enrolment of 9.6 months. Overall, the primary outcome of 'wound progression' since the previous clinic visit was achieved in 76.3% of visits. DFUs showed improvement in 65.9% [95% CI 55-75.7] of visits, VLUs showed improvement in 85% [95% CI 76.9-91.2] of visits, and PUs showed improvement in 76.0% [95% CI 66.3-84.2] of visits. Reductions in both absolute and relative wound size were noted over the study period. Patients reported low pain scores at dressing changes, with very little trauma to the wound and surrounding skin reported at dressing changes.

Conclusion: The study findings indicates that, for the management of low-to-moderately exudating chronic wounds, canister-based NPWT is associated with favourable outcomes with respect to exudate management and wound progression. Patients reported minimal pain at dressing changes.

EP277 Single-use NPWT system with hydrofiber for the treatment of chronic, non-healing ulcers of any etiology

Carlo Rivellini[1]

[1]AIUC, SIC, SICVE, AFI, Italy

Aim: To evaluate the effectiveness of NPWT dressings in the topical treatment of patients with chronic, non-healing ulcers.

Method: Sixty-five patients were consecutively treated between November 2020 and November 2024 with only chronic, non-healing ulcers (venous, ischemic, and mixed ulcers) using Hydrofiber NPWT. Fibrinous tissue, eschar, and slough were removed from these non-healing wounds. Antibiotic therapy was initiated after a positive swab and the wounds were treated for underlying venous disease (bandaging, phlebotonics, lifestyle changes, weight loss, and surgical treatment of reflux) or ischemic disease (surgical or interventional revascularization and/or pharmacological treatment). All patients studied had one or more comorbidities and several risk factors for venous stasis or ischemic disease and ulceration. The dressing was changed when there was sufficient exudate to wet 50% of the dressing. If there was minimal or no exudate, the dressing was left in place for seven days. The dressing was applied under a bandage in 42 cases.

Results / Discussion: Clinical improvement of the wound was observed in all cases after 30 days, particularly in the wound bed, with increased debridement, increased vascularity, and a greater reduction in slough and exudate production, as well as a marked reduction in inflammation and periwound pain. Application of the dressing under a bandage was well tolerated by all patients and did not alter the device's performance.

Conclusion: Disposable NPWT devices offer a number of advantages and are able to provide sufficient negative pressure to the wound bed, with low weight and minimal impact on the patient's quality of life. They can also be used in combination with compression bandages for the treatment of venous leg ulcers.

NUTRITION

EP278 Impact of short-term oral nutritional support on malnutrition in patients with diabetic foot disease

Can Boztug[1], Fevziye Duygu Avlar[2], Hakan Uncu[2], Ömer Arda Çetinkaya[3]

[1]Ankara University Faculty of Medicine, Department of General Surgery, Ankara, Türkiye, *[2]Ankara University Faculty of Medicine, Department of General Surgery,, ankara, Türkiye*, *[3]Ankara University Faculty of Medicine, Department of General Surgery,, Ankara, Türkiye*

Aim: This study aimed to assess malnutrition risk in patients with diabetic foot disease using the NRS-2002 and CONUT scores prior to the initiation of oral enteral nutritional support and to evaluate changes in nutritional status following supplementation.

Method: Eight adult patients with diabetic foot disease followed at the General Surgery Department of Ankara University were included. Demographic characteristics, anthropometric measurements, and laboratory-based nutritional parameters were recorded. Seven patients were male (87.5%) and one was female (12.5%). The mean age was 64.5 years (range:54-75), mean BMI was 26.76 kg/m^2 (range:22.7–31.1), and mean unintentional weight loss within the previous three months was 11.4%.All patients received a four-week oral nutritional intervention consisting of an HMB–arginine–glutamine–containing formula and a high-protein, low–glycemic index supplement formulated for individuals with diabetes.NRS-2002 scores were obtained at baseline, while CONUT scores were recorded both before and after supplementation. Laboratory assessments included serum albumin,total lymphocyte count and total cholesterol.

Results / Discussion: At baseline, all patients demonstrated high malnutrition risk (CONUT ≥3).One patient (12.5%) died due to severe comorbidities and septic complications; seven patients (87.5%) completed treatment. The mean baseline NRS-2002 score was 3.25. The mean CONUT score decreased from 5.62 at baseline to 3.25 after supplementation. Overall, CONUT scores improved by an average of 49.25% (range: 11–75%), indicating a marked enhancement in laboratory-based nutritional status.

Conclusion: Malnutrition is highly prevalent among patients with diabetic foot disease and is associated with impaired wound healing, increased infection risk and higher amputation rates. Early recognition and targeted nutritional support should be considered integral components of multidisciplinary diabetic foot management. This study demonstrates that short-term, individualized oral nutritional supplementation significantly improves CONUT scores and reinforces the need for routine nutritional assessment in this patient population.

PAIN

EP279 Perceived stress, pain, and wound healing in hard-to-heal wounds: Brazil-Canada cohort study

Beatriz Costa Ferreira[1], Carol Viviana Serna Gonzalez[1], Tim Salomons[2], Kevin Woo[2], Vera Lucia Conceição Gouveia Santos[1]

[1]University of São Paulo - School of Nursing, São Paulo, Brazil, *[2]Queen's University, Kingston, Canada*

Aim: To identify and analyze the association between perceived stress, pain, and healing in patients with hard-to-heal wounds, comparing findings from two distinct healthcare contexts – Brazil and Canada.

Method: Secondary analysis of two primary cohort studies, one in Brazil and the other in Canada, both approved by ethics committees. Data were collected through interviews, wound examinations, and chart reviews, using sociodemographic and clinical forms, the Brief Pain Inventory (severity and interference scores), McGill Pain Questionnaire, Pressure Ulcer Scale for Healing (PUSH), and Perceived Stress Scale. Analyses included hypothesis testing and linear mixed-effects models, and the significance level for analyses was set at 5%.

Results / Discussion: A total of 54 participants were included, with equal proportions of men and women. No pain or stress measure was associated with PUSH scores ($p = 0.200$-0.967). Overall, 67.9% presented with lower-limb wounds. The distribution of wound etiology differed significantly between countries, with vasculogenic wounds predominating in Brazil and surgical wounds in Canada ($p < 0.001$). Wound duration was also significantly longer in Brazil (mean 1,592.8, SD = 3,103.8 days) than in Canada (mean 69.9, SD = 80.3 days; $p < 0.001$). Women reported higher stress and pain levels ($p = 0.004$–0.035), and Brazilian participants reported greater pain interference ($p = 0.044$).

Conclusion: The study did not identify an association between perceived stress, pain, and wound healing. These findings suggest that such relationships may not generalize to clinical settings characterized by heterogeneous wound etiologies, chronicity profiles, and care pathways. Men and women demonstrated different patterns in pain and stress perceptions. Additionally, significant differences between countries highlight contextual needs within the Brazilian healthcare system.

EP280 PHMB Foam: Atraumatic biofilm management in complex wounds

Camila Moraes[1], Marcelo Mendes[2], Dioney Neves[3], Camila Safranski[3]

[1]Dra Camila Mendonca - Enfermagem Avancada, guaxupé, Brazil, *[2]Cicatripelli, Belem PA, Brazil*, *[3]Missner, Blumenau, Brazil*

Aim: To evaluate the effectiveness of atraumatic cleansing in complex wounds using a polyhexamethylene biguanide (PHMB)-based foam in pain-sensitive patients.

Methods: A cross-sectional descriptive observational study was conducted following ethical approval and informed consent. Inclusion criteria comprised complex or chronic wounds with clinically visible biofilm, significant pain sensitivity or intolerance to standard cleansing, clinical indication for mechanical debridement, and ability to report outcomes. Baseline data included wound etiology, chronicity, and tissue characteristics. The protocol involved dressing removal, a 5-minute foam contact, and final irrigation with 0.9% saline. Procedural pain was assessed using a Visual Analogue Scale (VAS 0–10), and comfort immediately post-procedure via a 5-point Likert scale. Standardized photographs were obtained before and after cleansing.

Results/Discussion: Twenty-seven adults were included: venous ulcers (48.1%), mixed arterial–venous ulcers (18.5%), diabetic foot ulcers (14.8%), arterial ulcers (11.1%), and pressure injuries (7.4%). During the procedure the foam preserved structural integrity throughout contact, enabling consistent surface coverage, emollient effects, and controlled PHMB release. All participants reported VAS 0 during the procedure, and 100% rated maximum comfort (Likert 5). Post-procedure evaluation showed a visible reduction of surface debris and biofilm, softening of devitalized

tissue, improved visualization of viable tissue, and cleaner peri-wound skin. Biofilm reduction was based solely on visual clinical assessment; microbiological testing was not performed, precluding confirmation of antimicrobial efficacy.

Conclusion: PHMB-based foam can effectively cleanse wounds atraumatically, providing no procedural pain and high comfort. Further controlled studies, including microbiological and healing outcomes, are needed.

EP281 Effectiveness of topical treatment for pain control in malignant fungating wounds in adults: systematic review

Yesly Johana Rincón Torres[1], Suzana Aparecida Da Costa Ferreira[2], Carol Viviana Serna Gonzalez[1 1], Vilanice Alves[2], Vera Lucia Conceição Gouveia Santos[2], Sandra Guerrero Gamboa[1]

[1]Universidad Nacional de Colombia, Bogota, Colombia, *[2]USP, Sao Paulo, Brazil*

Aim: To synthesise evidence on the effectiveness of topical treatments, compared with alternative topical or systemic therapies or no treatment, for pain control in adults with malignant fungating wounds-MFWs.

Method: Quantitative experimental and analytical observational studies assessing topical therapies for pain control in adults with MFWs were included. Articles in English, Portuguese, and Spanish were considered without date limits. Studies scoring below 70% methodological quality using Joanna Briggs Institute (JBI) tools were excluded. A comprehensive search of published and unpublished literature was conducted up to February 2025. Due to heterogeneity, findings were synthesised narratively, and certainty of the evidence was assessed using the GRADE approach.

Results: Four Randomised Controlled Trials involving 188 participants met the criteria. High-certainty evidence (⊕⊕⊕⊕) showed that 5% lidocaine–prilocaine cream and 0.2% topical morphine reduced pain intensity; topical morphine lowered Numerical Rating Scale scores from 5.9 to 2.5 versus placebo. Moderate-certainty evidence (⊕⊕⊕o) indicated no primary analgesic effect from antimicrobial agents. All studies reported unclear blinding of outcome assessors, posing detection bias. Small samples and clinical heterogeneity limited generalisability and precluded meta-analysis. No study evaluated patient-centred outcomes such as quality of life.

Conclusion/Recommendations: Lidocaine–prilocaine and topical morphine are supported by high-certainty evidence as effective and safe topical analgesics for MFW-related pain. Antimicrobial agents should not be used for primary pain control. More rigorous trials are needed to strengthen certainty and assess quality-of-life outcomes. Use lidocaine-prilocaine for procedural pain; use topical morphine for sustained background pain; reserve antimicrobial treatments for odour or infection, not analgesia.

POST-MARKET SURVEILLANCE

EP501 Real-life experience using birch bark extract (Filsuvez) in children with dystrophic and juntional epidermolysis bullosa in a UK national referral centre

Janet Hanson[1], Sumaiya Alauddin[1], Maria L Bageta[1], Pablo Lopez Balboa[1], Gabriela Petrof[1], Anna Martinez[1]

[1]*Great Ormond Street Children's Hospital, London, United Kingdom*

Aim: To analyse the post-marketing use of birch bark extract (Filsuvez®) in daily clinical practice and determine its efficacy, tolerability and safety in children with dystrophic and junctional epidermolysis bullosa (EB).

Method: A London National Paediatric EB service evaluated patient experience using birch bark extract after NICE approval in August 2023. Eligible patients were offered treatment for 8 weeks on non-infected EB wounds and completed a survey designed to elicit feedback on wound healing, pain, itch, amount used and any side effects.

Results / Discussion: Of the total number of patients who used Filsuvez® (n=33), 22/33 (66.6%) gave positive feedback and are still using it. Wound healing was better or much better in 16/22 (72.7%) , itching improved in 11/22 (50%), while only 7/22 (31.8%) reported improvement in wound pain. Among patients who discontinued Filsuvez® 11/33(33.3%), most (7/11; 63.6%) felt it either made wounds larger or did not improve them, while others experienced increased itching (5/11; 45.5%), more pain (4/11; 36.4%), more exudate (4/11; 36.4%), overall worsening (4/11; 36.4%) and increased inflammation (3/11; 27.3%).

Conclusion: Although published data on Filsuvez® seemed promising, in our experience about a third of patients discontinued due to worsening or lack of improvement. Most patients still on treatment have found quicker wound healing, in line with recent publications. Due to the single use policy of each 23.4g tube and its high cost, we suggest limiting the first prescription to 6-8 weeks and then evaluating its effectiveness, rather than issuing a 6 month supply to avoid waste whilst we await more real-life experience.

EP577 A prospective clinical study on the microbiological wound-cleansing performance of hypochlorous acid irrigation and gel formulations in chronic wounds

Peter Kurz[1], Vasantha Kronberger[1]

[1]*WPM Wundpflegemanagement GmbH, Bad Pirawarth, Austria*

Aim: Chronic wounds often harbour persistent bacteria and troublesome coatings that hinder healing. This study explored how well a hypochlorous acid (HOCL*)-based irrigation solution, an HOCL* gel, and their combined use can reduce microbial load, odour, and devitalised tissue—while remaining comfortable for patients.

Method: In a prospective, monocentric study (June 2024–April 2025), adults with chronic wounds were assigned to four treatment approaches: HOCL* irrigation, HOCL* gel, a combination of both, or saline as control. Quantitative wound swabs were taken before and after a 15-minute wet phase to measure changes in colony-forming units. Additional endpoints included qualitative microbiology, odour, wound-coating reduction through quantitative image analysis, and patient-reported tolerability.

Results / Discussion: Among 95 participants, the combination of HOCL* solution and gel stood out: it produced a statistically significant drop in bioburden (median log10 CFU 5.0 → 4.0; p = 0.005) and notably reduced *Staphylococcus aureus*, the most common pathogen in this cohort. While HOCL* solution alone showed a trend towards microbial reduction, neither gel nor saline produced measurable effects. All HOCL* treatments—unlike saline—effectively reduced devitalised tissue. Tolerability was high across all groups, with only mild transient burning reported in the combination group. No serious adverse events occurred.

Conclusion: HOCl-based treatments outperformed saline across all endpoints and were well tolerated, thereby establishing them as a crucial component in state-of-the-art chronic wound management.

*Granudacyn, PGF GmbH

PRESSURE ULCER

EP466 Reducing hospital acquired pressure injury (HAPI) in the critical care unit (CCU): a collaborative multi-hospital initiative in Singapore

Suyi Guan[1], Rhona Ak Thar[2], Quanzhen Dou[3], Jing Yin Wong[4], Yu Boon Yeong[4], Saw Meng Tung[3], Tsui Voon Ong[1], Lee Ming Chng[5], Anny Soe[4]

[1]Mount Elizabeth Novena Hospital, Singapore, Singapore, *[2]Mount Elizabeth Hopspital, Singapore, Singapore*, *[3]Gleneagles Hospital, Singapore, Singapore*, *[4]Mount Elizabeth Hospital, Singapore, Singapore*, *[5]Parkway East Hospital, Singapore, Singapore*

Aim: This project aimed to reduce the occurrence of HAPI in CCUs from 0.4 per 100 admissions to zero per 100 CCU admissions across the four private hospitals in Singapore through sustainable clinical, administrative and collaborative approach.

Method: A systematic strategy was implemented by establishing a team of wound care experts to support staff through education, standardization of practices, and evidence-based interventions guided by the Plan-Do-Study-Act (PDSA) methodology. A dedicated team of full-time Wound Management Nurses with specialized training spearheaded the initiative. Training programs included HAPI prevention during on-boarding, basic and advanced wound care courses, and the appointment of wound resource nurses in each department.

Practical tools such as a quick reference guide with wound care guidelines and incontinence-associated dermatitis management algorithms were introduced. The Modified Braden Scale and SSKIN bundle served as visual aids for staff to implement early preventive measures. Quality improvement projects targeted specific challenges in the CCU setting, such as Reducing Medical Device-Related Pressure Injuries at Facial Areas, yielding measurable success. Sustainability was reinforced through collaborative events, including the biannual Wound & Pain Symposium and the annual Stop Pressure Injury Day, recognized staff contributions and promoted awareness for HAPI prevention.

Results / Discussion:

By October 2024, CCU pressure injury incidence fell to 0.11 per 100 admissions, a significant decrease from 0.4 in 2023.

Conclusion: This collaborative and administrative initiative effectively reduced HAPI in CCUs across the 4 private hospitals in Singapore. Beyond improving patient outcomes, this project provides a scalable and adaptable model for other departments and healthcare institutions to adopt.

EP282 Comparison of two risk assessment scales for predicting pressure injuries in surgical patients and identification of independent predictors: A prospective observational study

Hao-Wei Li[1]

[1]Taipei Tzu Chi Hospital, Buddhist Tzu Chi Medical Foundation, New Taipei City, Taiwan

Aim: To identify independent predictors of pressure injuries (PIs) in surgical patients undergoing general anesthesia and to compare the predictive validity of the Braden Scale with the Scott Triggers Tool.

Method: This prospective observational study included 500 adult patients undergoing surgery lasting over two hours with general anesthesia at a medical center in eastern Taiwan. Patients with pre-existing PIs were excluded. Preoperatively, demographic data were collected, and both the Braden Scale and Scott Triggers Tool were administered. Intraoperative variables were extracted from anesthetic records. The primary outcome, new-onset PIs, was assessed at 24, 48, and 72 hours postoperatively. Multivariable logistic regression was used to identify independent predictors. The predictive validity of the two scales was compared using Receiver Operating Characteristic (ROC) curve analysis to calculate the Area Under the Curve (AUC).

Results: Multivariable logistic regression identified four independent risk factors for PIs: a prior history of PIs, intraoperative vasopressor use, prone positioning, and an American Society of Anesthesiologists (ASA) score > 3. The

ROC analysis demonstrated poor predictive performance for both instruments. The Braden Scale yielded an AUC of 0.655, while the Scott Triggers Tool showed a slightly higher but still poor AUC of 0.676. Both values are below the benchmark for acceptable discrimination (<0.70).

Conclusion: Both the Braden Scale and the Scott Triggers Tool demonstrated inadequate predictive validity for PIs in this surgical patient cohort. This suggests that reliance on these scales alone is insufficient for risk stratification. Clinically identified factors, particularly intraoperative vasopressor use and prone positioning, are more critical for accurate risk assessment. Integrating these specific perioperative factors into clinical evaluation, beyond scale scores, is essential for implementing effective prevention strategies.

EP283 Feasibility of UNO+ negative pressure wound therapy in elderly and outpatient patients with foot pressure ulcers: A retrospective case series

Seung-eun Hong[1]

[1]Ewha Women's University, Ewha Women's University Seoul Hospital, Seoul, Korea, Rep. of South

Aim: Pressure ulcers of the foot region are common in bedridden elderly patients with limited mobility. When ulcers progress to stage III or beyond, surgical reconstruction is often required. However, many elderly patients with multiple comorbidities are unsuitable for surgery, making conservative management necessary yet challenging. Negative Pressure Wound Therapy (NPWT) is effective for complex wounds, but conventional devices are bulky and hospital-based, restricting outpatient use. This study evaluated the feasibility and clinical outcomes of UNO+, a portable NPWT system, for advanced foot pressure ulcers in elderly, non-surgical patients treated in an outpatient setting.

Method: A retrospective case series was conducted between September 2024 and August 2025. Eleven elderly patients (age range: 62–89 years) with stage III or IV foot pressure ulcers, all deemed unsuitable for surgical reconstruction, were treated with UNO+ NPWT. Demographics, comorbidities, wound characteristics, treatment duration, and clinical outcomes were analyzed.

Results / Discussion: All patients demonstrated progressive wound healing with granulation tissue formation and reduction in wound size. Complete closure was achieved in 7 cases (63.6%) within an average of 11 weeks. The remaining 4 patients achieved >50% reduction in ulcer dimensions and improved wound bed quality, enabling transition to simpler dressings. No device-related complications were observed. These results suggest that portable NPWT can overcome limitations of conventional systems in outpatient care.

Conclusion: UNO+ NPWT demonstrated feasibility and clinical benefit in treating advanced foot pressure ulcers in elderly, non-surgical patients. Its portability, reduced dressing burden, and enhanced patient comfort make it a practical alternative in outpatient management. Further comparative studies against conventional NPWT are warranted to validate these findings.

EP467 Prevalence of pressure injury, predictors among adult hospitalized patients in Oman

Fatma Al Maskari[1 2], Nasser Al Salmi[1 1], Huda A' Noumani[1 1], Maen Aljezawi[3 3], Joshua Muliira[1]

[1]Sultan Qaboos University, Muscat, Oman, *[2]Sultan Qaboos Universityoma, Muscat, Oman*, *[3]Al al-Bayt University, Mafraq, Jordan*

Aim: This study aimed to investigate the prevalence and predictors of pressure injuries (PIs) among adult hospitalized patients in Oman. This study assessed the incidence of hospital-acquired pressure injuries HAPI, and the use of medical equipment that contributes to PIs.

Method: This was a cross-sectional multicentre study using a descriptive and correlational design. Data were gathered from four hospitals in Oman, with a total sample of 169 patients. The prevalence of PIs was assessed using both point and period prevalence measures, while potential predictors were identified through chi-square tests and multivariate logistic regression analysis.

Results / Discussion: The PI point prevalence was 8.7%, with 4.2% HAPIs. Hemoglobin levels predicted PI development (OR = 0.059, p = 0.019), cancer was a significant predictor of PI development (OR = 4.328, 95% CI: 1.225-15.291, *p* = 0.023), and ventilator use (OR = 0.211, *p* = 0.001).

Conclusion: The study emphasizes the significant frequency of PIs among Omani adult hospitalized patients. Despite well-established risk factors for PI development, this investigation discovered additional predictors such as hemoglobin status, cancer comorbidities, and ventilator use. Furthermore, high-calorie, high-protein diets have been recognized as effective preventive approaches for the development of PI. The findings indicate that Omani hospitals require better clinical practices, preventive interventions, and updated guidelines to reduce PIs and enhance patient outcomes.

EP284 The effects of nursing care package implementation on pressure injuries prevention in the intensive care unit

Sevda Önen[1], Ozlem Dogu[1]

[1]Sakarya Universty, Sakarya, Türkiye

Aim: The study was conducted to evaluate the effect of an algorithm-based care package prepared in the intensive care unit on the prevention of pressure injuries.

Method: The study design was planned retrospectively and semi-experimentally and consists of two phases. In the first phase, the care package was developed, nurses were trained on its use, and the care package was implemented. In the second phase, the effectiveness of the care package was evaluated. In this phase, the incidence of pressure injuries was compared between the intervention group (December 2019-April 2020) and the control group (May-September 2019) during the pre-intervention period. The study sample consisted of a total of 80 patients admitted to the general intensive care unit. The retrospectively selected control group (n = 40) had the same characteristics as the intervention group (n = 40).

Results / Discussion: The findings revealed that the proportion of individuals who developed a pressure injury was higher in the control group as of the 7 th day. Pressure injuries developed in 8.52 ±3.24 days in the control group and 11.00 ± 2.21 days in the intervention group (p< 0.05). The incidence rate of pressure injuries was calculated to be 30.43% in the pre-algorithm period and 17.5% in the period during which the algorithm was applied. There was a significant difference in the incidence rates of pressure injuries (p< 0.05) between the two periods.

Conclusion: Adopting evidence-based practices and using care packages prepared accordingly improves the quality of care provided by nurses. It also contributes to the prevention of pressure injuries and the reduction of healthcare costs.

EP285 Clinical evaluation of a β-sitosterol–enriched moisture-retentive herbal ointment for pressure ulcer healing: Comparative randomized study

Jeffrey Putra[1], Dianita Angeline[2], Fajar Mahayasa[3]

[1]Universitas negeri Yogyakarta, Yogyakarta, Indonesia, *[2]Universitas Negeri Yogyakarta, Yogyakarta, Indonesia*, *[3]Prima Medika Hospital, Bali, Indonesia*

Aim: This study compared clinical efficacy of a β-sitosterol–based moisture-retentive herbal ointment with a hydrocolloid dressing in the management of Stage II–III pressure ulcers among hospitalized patients in a tertiary center.

Method: A single-center, parallel-group, randomized controlled trial was conducted from January 2022 to December 2024. Adults aged ≥18 years with Stage II–III pressure ulcers of at least two weeks' duration and adequate perfusion (ankle–brachial index ≥0.70) were included. Participants were randomized 1:1 to receive either the β-sitosterol herbal ointment applied once daily with secondary non-adherent dressing or a hydrocolloid dressing changed every 2–3 days. Standard co-interventions included pressure off-loading, nutritional optimization, moisture control, and infection

management. The primary outcome was percent wound area reduction (PAR) at week 4 measured using the Kundin length×width method with a transparent grid. Secondary outcomes included time to complete epithelialization, simplified Bates–Jensen score, pain (Numeric Rating Scale), and direct medical costs.

Results / Discussion: A total of 86 patients were enrolled (43 per arm); mean age 63 years, 55% diabetic, and 72% with sacral/lower back ulcers. At week 4, the mean PAR was 54.2 ± 27.6% with the herbal ointment versus 41.1 ± 29.8% with hydrocolloid (mean difference + 13.1%, p = 0.011). Complete closure by 12 weeks occurred in 62% versus 44% (HR 1.58, p = 0.041). Pain reduction and cost-per-healed ulcer were also greater in the herbal group, with comparable safety.

Conclusion: The β-sitosterol–based herbal ointment demonstrated superior healing and earlier epithelialization compared with hydrocolloid dressing, offering a cost-effective and biologically active alternative for pressure ulcer management in tertiary settings.

Table 1. Clinical Outcomes of β-Sitosterol Herbal Ointment vs Hydrocolloid Dressing (N = 86)

Outcome	β-Sitosterol Herbal Ointment (n = 43)	Hydrocolloid Dressing (n = 43)	Difference / p value
Baseline area (cm², median [IQR])	6.4 [3.2–10.1]	6.0 [3.0–9.7]	Not significant
Percent area reduction (Week 4)	54.2 ± 27.6 %	41.1 ± 29.8 %	+13.1 %, p = 0.011
Complete epithelialization ≤ 12 weeks	62 % (26/42)	44 % (19/43)	HR 1.58 (95 % CI 1.02–2.45), p = 0.041
Mean time to closure (days)	56 ± 21	74 ± 26	p = 0.03
Pain reduction (NRS 0–10)	−2.1 ± 1.9	−1.1 ± 1.8	p = 0.004
Clinical infection (≤ 4 weeks)	9 %	18 %	RR 0.50, p = 0.16
Total cost to closure (IDR, mean ± SD)	≈ 2,200,000 ± 1,050,000	≈ 2,600,000 ± 1,250,000	−400,000 (95 % CI −850k to +50 k), p = 0.08
Adverse events (%)	12 % (mild maceration 7 %, dermatitis 5 %)	15 % (maceration 12 %, odor 3 %)	Not significant



DAY 1



WEEK 4

EP286 Effective management of refractory wounds using evidence-based dressing selection: A clinical case series

Huiwon Seo[1]

[1]*Korea University Medical Center, Seoul, Korea, Rep. of South*

Aim: To evaluate the effectiveness of individualized, targeted dressing strategies in promoting healing of refractory pressure injuries across diverse clinical contexts.

Method: Three male patients (aged 37–74 years) with chronic pressure injuries unresponsive to previous treatment were managed using individualized dressing approaches based on wound condition.

- Case 1: A 74-year-old patient with stage 4 pressure injury after cranioplasty developed excessive granulation tissue following necrotic tissue removal. Application of a DACC dressing effectively controlled hypergranulation and promoted epithelialization, and the patient was discharged with significant wound improvement.

- Case 2: A 59-year-old patient awaiting heart transplantation with ischemic cardiomyopathy had a stage 3 heel pressure injury that stalled despite foam dressing. Use of an MMPs inhibitor dressing reactivated the healing process, achieving complete wound closure.

- Case 3: A 37-year-old paraplegic patient post-epidural abscess surgery presented with a deep tissue injury on the right trochanter. After partial debridement, a honey-based dressing was applied to facilitate autolysis of residual necrotic tissue, resulting in successful debridement and progressive healing.

Results / Discussion: In all cases, the selected dressings addressed the predominant healing barriers - hypergranulation, protease imbalance, and residual necrosis - leading to wound progression and closure without complications.

Conclusion: Individualized, evidence-based dressing selection based on wound etiology and tissue characteristics is effective in managing refractory pressure injuries. This approach supports clinical decision-making and contributes to improved healing outcomes in complex wound management.

EP287 Analysis of the characteristics of device related pressure injuries (DRPI)

Minkyung Kim[1]

[1]*Samsung Medical Center, Seoul, Korea, Rep. of South*

Aim: This study aimed to identify the characteristics of device-related pressure injuries (DRPI) in hospitalized patients and to provide foundational data for their prevention and management.

Method: Adult patients with a Braden Scale score of 16 points or less, indicating high risk for pressure injuries, who were admitted to the general wards of a tertiary hospital in South Korea between January 1 and September 30, 2021 were included. During the study period, a total of 50 cases of DRPI were reported.

Results / Discussion: DRPI occurred most frequently on the ears (58%), followed by the nose (24%), legs (10%), and feet or toes (6%). Stage 2 pressure injuries were the most common (62%), followed by deep tissue pressure injuries (24%), and stage 3 injuries (2%). Mucous membrane pressure injuries accounted for 10% of cases. Devices associated with DRPI included KF94 masks (48%), high-flow nasal cannulas (16%), oxygen nasal cannulas (8%), nasogastric tubes (8%), and oxygen masks (4%). The average time from device application to injury development was 6.8 days. DRPI developed most rapidly with high-flow nasal cannula use (4 days), followed by oxygen nasal cannulas and oxygen masks (4.5 days each).

Conclusion: Patients with low Braden scores who require oxygen-delivery devices, especially those applied to anatomically vulnerable areas such as the ears and nasal bridge, should be closely monitored. Regular skin assessment and early preventive interventions are essential for reducing DRPI incidence.

EP288 Global, regional, and national levels and trends in the burden of pressure ulcer from 1990 to 2019: A systematic analysis for the global burden of disease 2019

Aobuliaximu Yakupu[1], Xingang Wang[1], Chunmao Han[1]

[1]Department of Burns & Wound Care Center, the Second Affiliated Hospital of Zhejiang University, School of Medicine, Hangzhou 310009, China., Zhejiang Key Laboratory of Trauma, Burn, and Medical Rescue, Zhejiang University, Hangzhou 310009, China, Hangzhou, China

Aim: To determine the level, trends, and burden of PU worldwide and to provide an essential foundation for building targeted public policies on PUs at the national, regional, and global levels.

Method: The incidence, disability-adjusted life years (DALYs), and deaths of PUs in 204 countries and regions from 1990 to 2019 were calculated and stratified by sex, age, geographical location, and sociodemographic index (SDI). The estimated annual percentage change (EAPC) of incidence, DALYs, and deaths was calculated to evaluate the temporal trends.

Results / Discussion: A total of 3,170,796 new cases (95% uncertainty interval (UI), 3,499,729-2,875,433 cases) of PU were identified globally in 2019, more than 55% of which were among male individuals, and most of the new cases were concentrated in those 75-90 years of age. The burden of PU measured in DALYs was 481 423 (95% UI, 583 429-374 334) in 2019, 73% and 27% of which could be attributed to years of life lost (YLLs) and years lived with disability (YLDs), respectively. The burden increased gradually from 1990 to 2019 (from 267 846 [360 562-211 024] to 481 423 [95% UI, 583 429-374 334]).

Conclusion: A total of 24 389 deaths were attributed to PU (95% UI, 31 260.82-17 299). The EAPC of incidence, DALYs, and deaths were negative in most regions, the age-standardized rate (ASR) of incidence, DALYs, and deaths were considered to be decreasing in most of the regions, and the EAPCs were negatively correlated with the SDI levels, universal health coverage (UHC), and gross domestic product (GDP), which shows that the ASRs of PU decreased as the economy developed and countries' healthcare system performances improved.

EP289 Incidence of perioperative pressure ulcers in surgical patients admitted to intensive care units

Tamara Bicudo[1], Rhavenna Oliveira[1], Fabiana Ramos[1], Graziela Almeida[1], Karime Oliveira[1], Rúbia Alencar[1], Aglécia Budri[1 2], Marla Avila[1]

[1]São Paulo State University (UNESP), Botucatu, Brazil, *[2]Royal College of Surgeons in Ireland (RCSI), Dublin, Ireland*

Aim: To identify the incidence of perioperative pressure ulcers (PUs) in surgical patients admitted to intensive care units (ICUs).

Method: This longitudinal study was conducted at a tertiary care hospital in Brazil, between May and June 2024. Adults of both sexes, aged 18 years or older, who underwent elective surgical procedures of any speciality, with a planned duration of at least 120 minutes, including those who were admitted to the ICU within the first 24 hours postoperatively, were included. Clinical data collection and visual skin assessments were performed during the preoperative period and throughout the first three postoperative days in surgical, neurological, and cardiac ICUs, as well as in medical wards for patients transferred after the first 24 hours postoperatively.

Results / Discussion: The incidence of perioperative PUs was 12.9% (n=4) among 31 patients who required intensive care in the postoperative period. Among the identified lesions, 50% were located on the buttocks, and all were classified as stage 1. One ulcer was detected within the first 24 hours, and three within the first 48 hours after surgery. Among affected patients, 75% underwent cardiac surgery, the mean surgical time was 333.75 minutes (95% CI: 264.27–403.22), and 75% were considered at high risk for PU development according to the ELPO scale.

Conclusion: The incidence of perioperative PUs observed in our study was lower than that reported in the literature; however, an important observation was the timing of ulcer development, with the majority being identified within 48 hours postoperatively. These findings may suggest a cumulative effect of tissue damage initiated during surgery in patients with more severe clinical conditions requiring critical care in the postoperative period.

EP468 Predicting the cut-off point for interface pressure in pressure injury according to the support surfaces

Kyung Hee Park[1]

[1]*University of Suwon, Hwaseong-si, Gyeonggi-do, Korea, Rep. of South*

Aim: This study aimed to investigate the interface pressure (IP) of patients using a standard hospital mattress and foam mattress as support surfaces and present cut-off points for interface pressure in patients who exhibited skin changes.

Method: A total of 189 inpatients enrolled from 6 general wards and 3 intensive care units at a Korean University Hospital. Skin changes were classified, and peak IP at the sacral and occipital regions was measured using a pressure scanner. Differences in IPs according to mattress type were analyzed using independent t-tests. The receiver operating characteristic curve was constructed to determine the cut-off point, and the area under the curve with a 95% confidence interval was obtained using the Stata 15.1. program.

Results / Discussion: The IP for a standard hospital mattress was significantly higher than that of a foam mattress. The cut-off points for IP at the sacral region were 52.90 mmHg and 30.15 mmHg for a standard hospital mattress and foam mattress, respectively. The cut-off point for IP at the occipital region was 36.40 mmHg for a foam mattress.

Conclusion: Using IP measurements to prevent pressure injuries is important and employ individualized interventions based on the cut-off points for different support surfaces.

EP469 Extending wound care clinician-led education through an AI-enhanced HAPI FAQ library

Catherine T. Milne[1], Elaine Song[2], Kathy Whiston Lemm[2], Natalie Shon[3], Tiffany Hamm[2], Jeffrey Mize[2]

[1]*Connecticut Clinical Nursing Associates, Bristol, United States*, [2]*WoundReference, Inc., San Francisco, United States*, [3]*Hofstra University, Hempstead, NY, United States*

Aim: Pressure ulcers/injuries (PUs/PIs) present a significant challenge in healthcare globally[1-3]. In Europe, PUs/PIs have a prevalence of 10.8% and are recognized as the primary burden stemming from preventable patient harm[2]. Similarly, in the United States, PUs/PIs are among the 14 targeted hospital-acquired conditions[3]. Despite established prevention guidelines, avoidable hospital-acquired pressure injuries (HAPIs) persist[3]. To enhance wound care clinician-led education and ensure continuous evidence-based support for staff nurses, we aimed to develop a HAPI Frequently Asked Questions (HAPI-FAQ) library - a curated, reliable resource integrated within a clinical decision-support platform.

Method: HAPI-FAQ leverages an AI-powered clinical intelligence system that generates answers exclusively from information within a peer-reviewed knowledge base with linked references and thereby reduces erroneous or inaccurate hallucinatory AI responses. Twenty FAQ prompts were developed based on the lowest-scoring topics from three years of nurse competency assessments, and focused on staging, prevention methods, wound description, and treatments. Four WOC nurses and one nurse administrator tested the tool and provided feedback, which informed refinements to content/user interface.

Results / Discussion: Seventy-five percent of evaluators rated usability as 5/5 (“very easy to access/use”) and all rated answer accuracy as 5/5 (“highly accurate”). Participants anticipated using the tool 1-3 times/week and estimated staff nurses might use it 4-8 times/week. All respondents rated the likelihood of recommending it to colleagues as 5/5 (“very likely”).

Conclusion: An AI-enhanced, evidence-based HAPI-FAQ library was successfully developed, offering reliable, referenced guidance to support clinicians in educating staff and improving bedside decision-making. This tool has the potential to strengthen consistency in assessment and documentation of PUs/PIs while helping healthcare facilities align with evolving regulatory and quality-reporting expectations.

EP470 Effectiveness of supine repositioning strategies for preventing intraoperative acquired pressure injuries: A meta-analysis

Saad Wasti[1], Hammad Javaid[1], Areesha Wasti[2], Hammad Naveed[1], Juwairia Mehmood[1], Asma Rafi[1]

[1]King Edward Medical University, Lahore, Pakistan, *[2]Continental Medical College, Lahore, Pakistan*

Aim: Intraoperative acquired pressure injuries (IAPIs) are tissue damages occurring during surgery, with high incidence and economic burden. Emerging prevention strategies include supine repositioning strategies (SRS), such as micro-movement (MM) and curvilinear supine positioning (CSP), which redistribute pressure and reduce injury risk. This review aims to evaluate their effectiveness in preventing IAPIs, to guide intraoperative surgical protocols.

Method: We searched PubMed, Scopus, Cochrane, Embase, Web of Science, regional article indexes and ClinicalTrials.gov till July 17, 2025 for randomized controlled trials (RCTs) comparing SRS to standard-of-care. Review Manager was used for analyses, pooling outcomes as risk-ratios (RR) with 95% confidence-intervals (CI). I^2 statistics were used to evaluate heterogeneity.

Results / Discussion: Included trials originated from Chinese and Iranian surgical settings. 57.8% of the participants were male, and mean ages varied from 52-58 years. Repositioning strategies significantly reduced the overall pressure injury incidence within one day postoperatively (RR 0.15, 95% CI [0.06-0.35], P<0.0001). Both curvilinear positioning (RR 0.08, P=0.002) and micromovement (RR 0.21, P=0.004) were effective. Stage 1 pressure injuries were also significantly reduced overall (RR 0.20, 95% CI [0.08-0.49], P=0.0005) and by both strategies individually. Stage 2 injuries showed a significant overall reduction (RR 0.20, 95% CI [0.05-0.92], P=0.04), but subgroup analyses were not statistically significant. Heterogeneity was absent across all statistical analyses (I^2=0%).

Conclusion: This meta-analysis suggests that curvilinear positioning and micromovement can significantly reduce early postoperative pressure injury incidence. These low-cost, feasible strategies hold substantial potential for improving intraoperative patient safety and outcomes. Further large-scale trials are needed to strengthen evidence, particularly for advanced-stage injuries.

EP290 Pressure ulcer preventive measures and bundles in home environments: A scoping review

Fabiana Ramos[1], Julianne Caroline Ferreira[1], Rhavenna Oliveira[1], Marla Avila[1], Juliane Andrade[1], Aglécia Budri[1 2], Rúbia Alencar[1]

[1]São Paulo State University (UNESP), Botucatu, Brazil, *[2]Royal College of Surgeons in Ireland, Dublin, Ireland*

Aim: To identify, explore, and map the literature on pressure ulcer preventive measures and bundles in home environments.

Method: This scoping review followed the Joanna Briggs Institute (JBI) methodology (2022) and the PRISMA-ScR guidelines. The protocol was registered on the Open Science Framework (OSF): https://osf.io/m5gvn. Eligibility criteria were based on the Participants–Concept–Context (PCC) framework. This review considered original (quantitative, qualitative or mixed methods) studies with adult or older individuals with reduced mobility, bedridden or chairfast, receiving interventions to prevent pressure ulcers in home settings. Studies exploring preventive measures or bundles for pressure ulcers prevention in the home environment were included, with no time restriction. Studies were excluded if they involved existing pressure ulcers, addressed only medical device-related pressure ulcers, or were case reports, event summaries, or unavailable in full. Only studies published in English, Portuguese, or Spanish were considered.

Results / Discussion: A total of 13 studies published between 2009 and 2024 were included, with most conducted in European countries (7/13). The interventions occurred in home environments. Eleven studies described multiple preventive strategies; however, none explicitly identified them as “bundles. Two studies implemented a single intervention (repositioning), and two reported structured bundles. The number of interventions ranged from two to seven, with repositioning being the most common. Given the variability across studies, findings were categorized by intervention type (Figure 1).

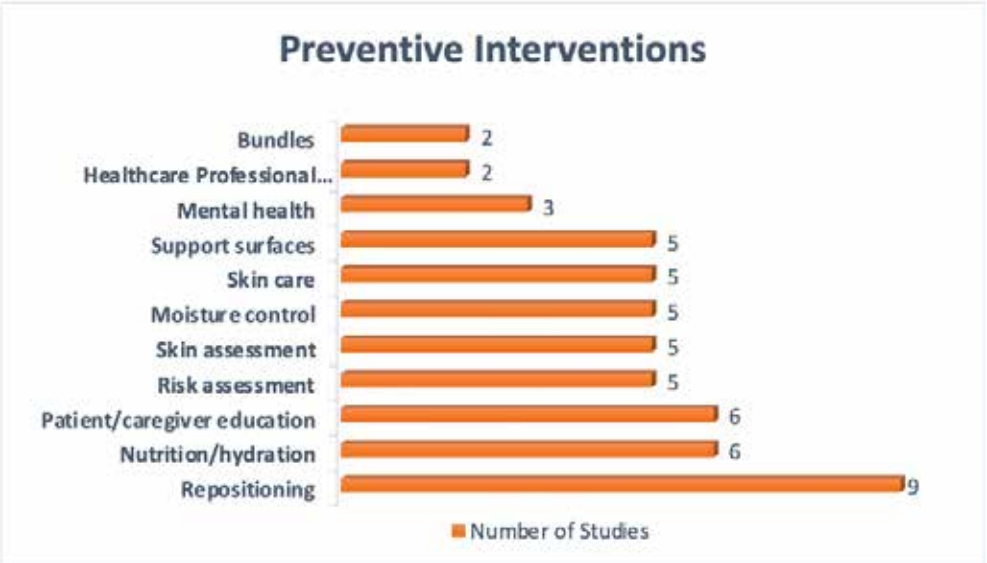

Figure 1. Preventive measures used among included studies.

Conclusion: Preventive actions were largely fragmented and showed limited standardization across studies. Strengthening public health policies and systematically integrating community healthcare professionals are essential to enhance caregiver support through structured education, emotional guidance, and the implementation of prevention bundles tailored to home care contexts.

EP291 Clinical evaluation of a pressure management Surface (PMS) that automatically uses AI algorithms to adjust to the patient's weight and position

Joan Enric Torra i Bou[1], Marta Casals Zorita[2], Maria Garriga Ylla[3], Maria Neus Farré Cobos[3], Sandra Criach Navarro[3], Marta Ferrer Solà[1]

[1]TR2Lab Research Group, IRIS CC, Universitat de Vic-Universitat Central de Catalunya, Vic, Barcelona, Catalunya, Spain, Unitat de Ferides Complexes, Hospital Universitari de la Santa Creu, Consorci Hospitalari de Vic, Vic, Barcelona, Catalunya, Spain, Vic, Spain, *[2]TR2Lab research group. IRIS CC, Universitat de Vic-Universitat Central de Catalunya., Unitat de Ferides Complexes, Hospital Universitari de Vic, Vic, Barcelona, Catalunya Spain, Vic, Spain*, *[3]Consorci Hospitalari de Vic, Vic, Barcelona, Catalunya, Spain, Vic, Spain*

Aim: Specialised pressure management surfaces (PMS) are a highly useful resource in the prevention of pressure injuries (PI). The incorporation of AI algorithms into PMS can facilitate their use and effectiveness.

Method: To evaluate the use of a PMS in hospital and intermediate care patients, in the prevention of PIs and in the resolution of pre-existing injuries. Patients at risk of PI were included. The PMS under evaluation is a autonomous dynamic mattress that utilises AI-driven algorithms and high-precision sensors to continuously monitor each patient's weight, height, and position. Based on these parameters, the system autonomously adjusts and individualises the support surface settings supporting consistent, individualised care.

Methods: An open-label, non-comparative study was designed in an acute care hospital and two intermediate care centres. The incidence of PI and the evolution of pre-existing PI were considered as clinical response variables. The study was approved by the ethics committee.

Results / Discussion: The sample consisted of 61 patients, The PMS was used a total of 1071 days, with an average of 17.45 days. 2 Patients developed new PI. The incidence rate of LPP was 3.27%. Eighty-one per cent of the pre-existing PIs healed or improved with the use of PMS.

Conclusion: The PMS under evaluation has proven to be effective both in reducing the incidence of LPP and in improving pre-existing injuries, demonstrating its cost-effectiveness in the prevention and treatment of PI.

EP472 Comparative study of topical dialkylcarbamoyl chloride versus polyamide with silver dressings in critically colonized or infected pressure ulcers: Partial analysis of a randomized clinical trial

Dimas Milcheski[1], Rafael Santos Jr[1], Bruna Amaral[1], Rolf Gemperli[1]

[1]*Faculty of Medicine, University of São Paulo, Sao Paulo, Brazil*

Aim: To compare the effectiveness of dialkylcarbamoyl chloride (DACC) dressings versus polyamide with silver dressings in critically colonized or infected stage III–IV pressure ulcers requiring surgical management.

Method: This prospective randomized clinical trial included patients with stage III–IV pressure injuries indicated for surgical treatment. Participants were randomized to receive either a DACC-based dressing (n = 11) or a silver-impregnated dressing (n = 11) after initial debridement. On postoperative day 7, patients underwent repeat debridement, deep tissue culture collection, and assessment for flap closure. Clinical evolution, microbiology, laboratory parameters, and complications were monitored for 28 days.

Results / Discussion: Mean age was 43.5 years (SD 14.2; 95% CI 38.7–49.0). Wounds were longstanding (mean 60.5 months; median 72). Most lesions were sacral (65.2%), and osteomyelitis was present in 60.9% of cases. Groups were comparable except for age, with the DACC group being older ($p = 0.046$). Initial cultures were positive in 65.2% of wounds, increasing to 76.2% on day 7, predominantly polymicrobial. No significant microbiological or laboratory differences were observed between groups. Minor dehiscence occurred in two different patients in the DACC group (18.2%) and in none of the silver-treated wounds. All were minor and managed conservatively. No major dehiscence, flap loss, or reoperation occurred. Fisher's exact test showed no significant differences, consistent with the small sample size. Prior studies similarly reported comparable outcomes between DACC and silver dressings.

Conclusion: In this interim analysis, DACC and silver dressings showed equivalent early outcomes in critically colonized or infected stage III–IV pressure injuries undergoing surgical reconstruction. Both were safe and clinically effective. A larger sample is needed to clarify potential differences in complication rates.

EP292 Pressure ulcer prevalence in Ghana: a cross-sectional survey

Richard Owusu[1], Zena Moore[1], Declan Patton[1], Pinar Avsar[1]

[1]*Royal College of Surgeons in Ireland, Dublin, Ireland*

Aim: To determine the prevalence of pressure ulcers (PU) and the preventive practices employed in a large teaching hospital in Ghana.

Method: A cross-sectional observational study was conducted in October 2025, following ethical approval. Consenting adults meeting the inclusion criteria were randomly selected. Two trained nurses assessed 240 inpatients using a modified European Pressure Ulcer Advisory Panel (EPUAP) Minimum Data Set. Skin integrity was evaluated using visual skin assessment and sub-epidermal moisture (SEM) measurements. Additional data included patient demographics, Braden scores, and PU prevention practices.

Results / Discussion: All participants were Black; most were men (n=152, 63%) and aged 19–59 years (n=166, 69%). Overall PU prevalence was 11.7% (n=28). Of these, 36% (n=17) were Stage 2, 21.3% (n=10) Stage 3, 30% (n=14) Stage 4, 8.5% (n=4) Stage 1, and 4.2% (n=2) unstageable. The sacrum was the most common site (17%). PU prevalence was highest in units with reduced mobility: Stroke Unit (100%), High Dependency Unit (44.4%), Intensive Care Unit (42.9%). PU increased markedly among participants with high-risk Braden scores (≤12). SEM values aligned with Braden scores; however, several participants with mild-to-moderate Braden scores reported pain and had elevated SEM readings, suggesting early tissue damage despite lower risk categorisation. Among those with PU, 89.2% (n=25) had at least one abnormal SEM value (≥0.6), indicating underlying inflammation. Abnormal SEM readings were recorded at the right heel 56.2% (n= 135), left heel 61% (n= 146), and sacrum 68% (n=164).

Conclusion: This study provides the first documented PU prevalence data from Ghana and highlights significant patient safety concerns. Findings underline the urgent need to strengthen prevention strategies and institutional support to improve PU outcomes.

EP293 Treating large and hard-to-heal pressure ulcers with supplemented medical-grade honey

Georgios Papanikolaou[1], Konstantina Bouranta[2], Filipa Cromao[3], Niels Cremers[4]

[1]GP-PlasticSurgery Clinic, Ioannina, Greece, *[2]3rd Local Health Center, Ioannina, Greece*, *[3]Triticum Exploitatie BV, Maastricht, Netherlands*, *[4]Department of Gynecology and Obstetrics, Maastricht University Medical Centre, Maastricht, Netherlands*

Aim: Large and deep pressure ulcers (PUs) can evolve into chronic wounds, requiring innovative treatment options to achieve complete wound healing. We present our experience with the use of medical-grade honey (MGH) for the conservative treatment of large and chronic PUs.

Method: Nine patients (7♀/2♂) developed 10 PUs (5 sacro-coccygeal, 2 gluteal, 3 greater trochanteric) due to permanent immobility (6/9, 67%) or prolonged immobility post-hospitalization (3/9, 33%). PUs were stage III (8/10, 80%) and stage IV (2/10, 20%). The average age of the patients was 84 years (range, 71-94 years), and they all had several comorbidities (mainly dementia, cardiovascular and metabolic diseases). All wounds were considered large (>4cm) and chronic (>4 weeks). All wounds were treated with MGH ointment[1], MGH-impregnated non-adherent dressing[2]. Dressing changes were performed every 2-3 days, depending on the amount of exudate.

Results/Discussion: The median length of the ulcers was 8.0cm (average:8.2cm, range:5-12cm), and the median width was 6.5cm (average:6.9cm, range:5-10cm). The presence of healthy granulation tissue was evident after a median of 3.5 weeks (average:4 weeks, range:1-8 weeks). The median time to complete healing was 13 weeks (average:15.5 weeks, range:5-32 weeks). The MGH products resolved clinical signs of infection, induced autolysis of the necrotic debris, and promoted tissue regeneration. No complications during the treatment were observed, and the quality of life for both the patients and their relatives was markedly improved.

Conclusion: MGH-based products[1,2] present strong healing and broad-spectrum antimicrobial properties, able to effectively treat large and hard-to-heal PUs. Thus, MGH can be recommended as monotherapy or complementary therapy for treating PUs.

References:

[1]L-Mesitran Ointment (Triticum Exploitatie BV, Maastricht, the Netherlands)

[2]L-Mesitran Tulle (Triticum Exploitatie BV, Maastricht, the Netherlands)

EP294 Terminal ulcers in end-of-life care: a scoping review

Ilaria Saguatti[1], Romina Baldessarini[1], Dalia Caleffi[1], Domenico Cannizzaro[1], Paola Ferri[1]

[1]University of Modena and Reggio Emilia, Modena, Italy

Aim: To clarify the concept of the unavoidability of terminal ulcers, understand the terminology used and describe what is currently known about diagnostic criteria and assessment tools, prevention, management and aetiology of these wounds as well as clinicians' understanding of the phenomenon.

Method: A scoping review was conducted. Following Arksey and O'Malley's framework and Joanna Briggs Institute guidelines, we systematically searched the PubMed, Scopus, CINAHL, Embase, Google Scholar, ProQuest databases, up to March 2025, with no time or methodological limitations. The review included studies that explicitly referenced terminal injuries occurring at the end of life, written in English. The study encompasses all patients in all healthcare settings. A narrative synthesis was performed.

Results / Discussion: Twenty-six studies were included in the analysis. The review summarises the extensive range of terminology applied to terminal ulcers and identifies several potential aetiologies. Diagnostic criteria were outlined, and considerations regarding the prevention, management, and professional education were discussed. The need for validated assessment tools and clearer diagnostic standards was highlighted. These ulcers are considered unavoidable; however, they are often misdiagnosed as pressure injuries, thus effective palliative care and palliative wound care are not provided and prevalence data is missed.

Conclusion: This review maps the current evidence on terminal ulcers and identifies significant gaps. Future research should focus on healthcare professionals' training and on the early recognition and prevention of these lesions to promote dignity in end-of-life care. Nurses are responsible for the proper identification and management of terminal wounds, which raises ethical concerns about the quality of care. Although correct identification may impact reimbursement, the priority remains ensuring the best possible care and a dignified end-of-life process.

EP295 Convolutional neural network–assisted classification of pressure injury severity for nursing assessment

Canan Karadas Ardic[1], Feyyaz Alpsalaz[1]

[1]*Yozgat Bozok University, Yozgat, Türkiye*

Aim: To develop and evaluate an automated deep-learning model capable of classifying pressure injury stages from wound images, and to explore its potential contribution to nursing decision-making by providing rapid and standardised wound assessment.

Method: A publicly available Kaggle dataset of 181 valid pressure injury images was used. A hybrid deep-learning architecture combining a ResNet-based Convolutional Neural Network (CNN) and a Vision Transformer (ViT) was implemented to capture detailed local tissue patterns and global contextual features. To address severe class imbalance, extensive data augmentation and SMOTE-based feature oversampling were applied, expanding the dataset to 3,060 images across six ulcer stages. The model was trained and evaluated using balanced train–validation–test splits. Performance was assessed through accuracy, precision, recall, F1-score, confusion matrix and multi-class ROC–AUC analysis.

Results / Discussion: The hybrid CNN–ViT model achieved 94% overall accuracy and a macro F1-score of 0.94, outperforming standalone CNN (91%) and ViT (88%) architectures. ROC–AUC values ranged from 0.937-1.000, confirming strong discriminative capability across all stages. The model performed particularly well in identifying Stage IV, SDTI and Unstageable ulcers, which are clinically critical for timely intervention. Automated staging has the potential to support nurses by reducing inter-observer variability, enabling faster wound evaluation and improving communication within care teams. Integrating such a tool into digital nursing documentation or mobile decision-support systems may enhance workflow efficiency and promote more consistent bedside assessment.

Conclusion: The proposed hybrid deep-learning approach demonstrates strong potential as a nursing-oriented tool for objective, rapid and standardised staging of pressure injuries. Its clinical relevance lies in supporting accurate assessment, strengthening communication across care teams, and contributing to moretimely and evidence-based pressure injury management.

EP296 Pressure injury preventive mattresses in pediatric patients: A scoping review

Enes Şimşek[1], Remziye Semerci Şahin[1]

[1]*Koç University, Istanbul, Türkiye*

Aim: To evaluate the effectiveness of pressure injury preventive mattresses in pediatric patients, identify knowledge gaps, and provide recommendations for clinical practice.

Method: Research was conducted in PubMed, Medline (OVID), Scopus, Web of Science, and CINAHL databases for studies published until December 2024. The review followed the PRISMA-ScR guidelines, and the inclusion criteria encompassed randomized controlled trials, cohort studies, quasi-experimental studies, and finite element modeling focusing on PI preventive mattresses in pediatric patients aged 0–18 years.

Results / Discussion: A total of 10 studies were included, involving various methodologies such as randomized controlled trials, cohort studies, and finite element modeling. Air mattresses demonstrated superior pressure redistribution, reducing peak pressure points by up to 29.2% compared to foam mattresses. Fluidized positioners

effectively decreased PI incidence by 2.67 times when used in prevention bundles. Gel mattresses showed moderate effectiveness, while foam mattresses were cost-effective but less efficient in high-risk patients. Additionally, foam dressings were beneficial in preventing device-related PIs.

Conclusion: The review highlights the efficacy of air mattresses, fluidized positioners, and gel mattresses in preventing PIs in pediatric patients. A multifaceted approach, integrating advanced support surfaces with risk assessment tools, can significantly reduce PI incidence. Future research should focus on long-term outcomes, cost-effectiveness, and standardized protocols for pediatric PI prevention.

EP297 The difficulties on management of pressure injuries encountered by pediatric nurses working in intensive care units in Turkiye: A descriptive qualitative study

Enes Şimşek[1], Remziye Semerci Şahin[1]

[1]Koç University, Istanbul, Türkiye

Aim: To explore the experiences and perceptions of pediatric intensive care nurses regarding pressure injury prevention and management, focusing on identifying challenges, barriers, and system-level vulnerabilities in clinical practice.

Method: A descriptive qualitative design based on naturalistic inquiry was adopted. Data were collected from 28 pediatric intensive care nurses in Turkey between January and June 2025 using structured tools with demographic forms and open-ended questions. Participants were recruited through purposive sampling via social media and professional WhatsApp groups. Data saturation was reached, and analysis followed Downe-Wamboldt's content analysis framework.

Results / Discussion: Two main themes and six sub-themes emerged. The themes were: (1) Clinical Outcomes of Inadequate Training and Protocol Deficiencies, and (2) Structural Vulnerabilities and Compensatory Improvisation in Pediatric Care Delivery. Sub-themes highlighted issues such as unsupported decision-making, educational inadequacies, protocol misalignment, resource limitations, improvised care strategies, and the emotional burden.

Conclusion: The study highlights the urgent need for pediatric-specific protocols, consistent access to equipment, and hands-on training to bridge theory and practice. Institutional efforts must address structural and educational gaps to support nurses and improve care quality. The findings are crucial for developing targeted educational programs, revised clinical protocols, and policy reforms aimed at reducing the incidence of pressure injuries and improving overall nursing care quality in pediatric settings.

EP298 Effective intraoperative pressure injury risk assessment in surgical patients: A comparative study

Mehtap Adıgüzel Akbaba[1], Nermin Ocaktan[2], Nuran Aysen Pamir Aksoy[2], Ükke Karabacak[3]

[1]Graduate School of Health Sciences, Acibadem Mehmet Ali Aydinlar University, MSc, RN, PhD Student, istanbul, Türkiye, *[2]Department of Nursing, Faculty of Health Sciences, Acibadem Mehmet Ali Aydinlar University, MSc, RN, Assistant Professor, istanbul, Türkiye*, *[3]Department of Nursing, Faculty of Health Sciences, Acibadem Mehmet Ali Aydinlar University, Professor, istanbul, Türkiye*

Aim: Accurate assessment of pressure injury risk during the intraoperative period is of critical importance. This study was designed to compare three pressure injury risk assessment tools used during the intraoperative period—the Braden Scale, the 3S Intraoperative Pressure Injury Risk Assessment Scale, and the Scott Triggers Pressure Injury Risk Assessment Tool.

Method: The study was conducted as a descriptive and prospective design across two different healthcare institutions between March and August 2025. A total of 120 patients who met the inclusion criteria—operative duration ≥3 hours, age over 18 years, and voluntary participation—were included in the study. Patient data were

collected using a data collection form, the Braden Risk Assessment Scale, the 3S Intraoperative Pressure Injury Risk Assessment Scale, and the Scott Triggers Tool.

Results / Discussion: Patients were assessed for pressure injuries immediately upon admission to the post-anesthesia care unit. Pressure injuries occurred most frequently in urology cases (30%), and all were Stage I. Patients who developed pressure injuries had significantly higher 3S scores than those without injuries (15.43 ± 2.21 vs. 14.18 ± 2.14; t = -2.986, p = 0.003). The AUC values for the 3S, Scott Triggers, and Braden scales were 0.66, 0.52, and 0.58, respectively. The 3S Scale demonstrated moderate discriminatory power (p = 0.012), whereas the Scott Triggers and Braden scales showed discrimination levels close to chance.

Conclusion: The findings indicated that all three scales can be used to assess pressure injury risk; however, the 3S Scale may be a more suitable tool for surgical patients due to its significant association with intraoperative factors.

EP299 Continuous 120-minute changes in back skin microclimate among older adults lying on urethane mattresses

Mikiya Wakabayashi[1], Natsuki Hata[1], Miku Aoki[1], Junko Yotsuya[1]

[1]*University of Fukui, Eiheiji, Japan*

Aim: To describe continuous 120-minute changes in back skin microclimate among older adults lying on urethane mattresses, and to identify characteristics that may help explain observed variations.

Method: Thirteen residents of a long-term care facility underwent microclimate monitoring. Participants who used a urethane mattress and did not undergo caregiver-initiated repositioning during the monitored period were included (n = 8). Back skin temperature and absolute humidity were recorded each minute for 120 minutes. Ten-minute interval change rates (Δ0–10 to Δ110–120) were calculated. Head-of-bed (HOB) elevation, clothing material, bedding, and airflow direction were documented to assist interpretation of inter-individual differences.

Results / Discussion: The eight included participants (mean age 87.5 ± 3.4 years) showed increases in temperature and humidity, with notable variation.

Temperature: Δ0–10 ranged from +1.4% to +6.6%, followed by slower increases. The mean rise was +2.5°C (+7.5%). Higher HOB angles and frequent small upper-limb movements were associated with larger increases.

Humidity: Absolute humidity increased by an average of 4.0 g/m^3 (+19%). Δ0–10 ranged from +4.8% to +17.3%. Clothing material showed no consistent influence. Participants with frequent upper-limb movements or higher HOB angles showed greater fluctuation after 30 minutes. The participant exposed to swing-mode airflow (ID11) showed one of the smaller overall increases, though not the smallest. Resident and environmental characteristics contributed to differences in microclimate change.

Conclusion: Back skin microclimate increased over 120 minutes, with variation partly explained by posture, clothing, bedding, and airflow. Because repositioning is recommended at intervals of up to four hours, increases within 120 minutes suggest that microclimate deterioration may occur earlier. Continuous microclimate assessment may support individualized pressure ulcer prevention strategies.

EP473 The acceptability, appropriateness and feasibility of prophylactic dressings among at-risk older adults in a residential care setting: A quality improvement study

Queen Edede[1], Declan Patton[1 1], Pinar Avsar[1], Vishnu Renjith[1]

[1]*Royal College of Surgeons, Dublin, Ireland*

Aim: This quality improvement project (QIP) aimed to estimate the prevalence of pressure ulcers (PUs) among residents identified as being at risk, evaluate the feasibility of integrating the SSKIN care bundle with prophylactic silicone multilayer dressings and sub-epidermal moisture (SEM) scanning, and explore resident and staff perspectives on acceptability, appropriateness, and feasibility of this combined prevention approach.

Method: Ethical approval was obtained in December 2025. The project was conducted across four residential care wards. All participant and staff information leaflets and consent forms were completed before data collection. Twenty-one participants aged ≥65 years were enrolled in Phase One and monitored for four consecutive days, with daily skin assessments, SEM delta measurements, and prophylactic dressing integrity checks. Fidelity to the combined prevention bundle was evaluated using indicators including SEMdelta values, dressing status, and skin integrity outcomes. Phase Two analysed questionnaire responses from 47 residents and staff regarding their experiences and perceptions of the care bundle.

Results / Discussion: All residents maintained intact skin throughout. Adherence to the care bundle including SSKIN components, silicone dressings, and SEM scanning was high: sacrum adherence was 98.1%, right and left heel adherence were 40.95% and 39.05%, influenced by heel dressing displacement. Recruitment and retention rates were 72.4% and 95.24%. Questionnaire findings indicated favourable acceptability, feasibility, and appropriateness among residents and staff (AIM 18.44; IAM 18.33; FIM 18.22). Resident-only scores were also positive (AIM 17.25; IAM 17.15; FIM 17.40).

Conclusion: This QIP demonstrates that integrating the SSKIN care bundle with prophylactic silicone dressings and SEM scanning is feasible in residential care. Positive feedback from residents and staff indicates that this combined approach is acceptable, appropriate, and supports early PU prevention.

EP474 A systematic review on the impact of care bundles on the incidence of pressure ulcers among at-risk older adults

Queen Edede[1], Declan Patton[1], Pinar Avsar[1], Vishnu Renjith[1], Zena Moore[1], Tom O'Connor[1]

[1]Royal College of Surgeons, Dublin, Ireland

Aim: This systematic review aimed to determine the impact of care bundles on the incidence of pressure ulcers (PUs) among at-risk older adults through a systematic review and meta-analysis.

Method: A systematic search was conducted in PUBMED, CINAHL, Scopus and Cochrane in May 2025. Studies were eligible if they focused on care bundle interventions designed to prevent PUsin older adults. Two reviewers independently screened titles, abstracts, and full texts, with verification by a third reviewer. Quality appraisal was performed using the evidence-based librarianship (EBL) checklist. Meta-analysis was conducted for studies with comparable methodologies, whereas highly heterogeneous studies were reported narratively.

Results / Discussion: The search strategy identified 1,482 citations of which 11 studies met the inclusion criteria, comprising randomized controlled trials, quasi-experimental studies, quality improvement projects, and observational designs. Care bundles typically included structured skin assessment, repositioning schedules, pressure redistribution strategies, and moisture management. Two meta-analyses found no statistically significant differences between care bundles and usual care, with wide confidence intervals and high heterogeneity limiting certainty. In contrast, a third meta-analysis reported that patients receiving care bundles overall odds ratio for PU development was 0.45 (95% CI: 0.33 to 0.61; $p< 0.00001$), indicating that patients receiving the care bundle were 55% less likely to develop a PU compared to those receiving usual care. Evidence-Based Librarianship (EBL) quality scores ranged from 64% to 96.5%, with the majority (n = 8) scoring ≥75%, reflecting strong methodological quality.

Conclusion: This systematic review demonstrates that the implementation of care bundles has the potential to lower PU incidence in older adults. Given the substantial heterogeneity and variation in study designs, the results should be interpreted with caution.

EP300 Medical device-related pressure injuries in pediatric intensive care patients: A prospective, descriptive study

Bilgi Gülseven Karabacak[1], Senanur Şimşek[2], Bilge Tezcan[3], Tülay Yakut[4], Demet Demirkol[5]

[1]Marmara University Faculty of Health Sciences, Istanbul, Türkiye, *[2]Marmara University Insitute of Health Sciences, Istanbul, Türkiye*, *[3]Edirne Sultan 1. Murat Public Hospital, Edirne, Türkiye*, *[4]Istanbul University Hospital Pediatric Intensive Care Unit, Istanbul, Türkiye*, *[5], Istanbul, Türkiye*

Aim: To investigate the risk factors, prevalence, and characteristics of medical device-related pressure injuries in pediatric intensive care patients.

Method: This prospective descriptive study was conducted in the pediatric intensive care unit of a university hospital in western Turkey between November 2024 and June 2025. A total of 110 pediatric patients were observed, with the first assessment performed within 24 hours of admission and continued daily. Data were collected using the Pediatric Intensive Care Patient Information Form, the Medical Device-Related Pressure Ulcer Diagnosis Form, and the Braden Q Pressure Ulcer Assessment Scale for Children.

Results / Discussion: Medical device-related pressure injuries developed in 6.4% (n=7) of pediatric intensive care patients. The cheek area was the most commonly injured site (28.5%). Vast majorty of the injuries were stage 1 (71.4%), most commonly associated with CPAP masks (42.8%) and nasogastric tubes (n=28.5%). The Braden Q score was significantly lower in children who developed medical device-related pressure injuries (13.58±2.96), while the mean score was 19.14±3.32 in those who did not develop injuries (p=0.001). A statistically significant difference was found in the incidence of pressure injuries between orally fed children and enterally fed children (p<0.05). No injuries related to medical devices developed in orally fed children.

Conclusion: Incidence of medical device-related pressure injuries were moderate with mainly occurrence on the face and in early stages. Lower Braden Q scores were a significant indicator of injury risk, and enterally fed children required additional preventive measures. The results underscore the importance of regular risk assessment, close monitoring, and proactive nursing care to minimize device-related pressure injuries in pediatric intensive care settings.

EP301 Prevention in action: Training strategy to achieve zero pressure injuries

Camila Moraes[1], Camila Paladino[2], Lima Priscila[2], Kelly Ono[2], Camila Anastacio[3]

[1]Dra Camila Mendonca - Enfermagem Avancada, guaxupé, Brazil, *[2]AACD, Sao Paulo, Brazil*, *[3]Hartmann, Sao Paulo, Brazil*

Aim: This study aimed to implement and evaluate a knowledge translation strategy using realistic simulation to prevent pressure injuries related to surgical positioning in a high-volume orthopedic surgical center.

Methodology: A pre- and post-training clinical study was conducted with 80 healthcare professionals, including nurses, surgical technicians, surgeons, and anesthetists. The Prevention in Action program followed a structured development cycle: Initiation: recognizing the hospital's pressure injury problem; Planning: introducing a Five Steps Training Course to instill patient safety awareness; Execution: developing realistic simulations in the clinical environment, identifying at-risk patients implementing risk assessment (ELPO Scale), justifying protective interventions; Monitoring: tracking pressure injuries during the first 72 postoperative hours per patient, and quantify hospitals incidence of injuries; Closure: certifying hospitals demonstrating reduced injury rates; and diffusion, replicating the program across other institutions.

Results: Prior to training, the incidence of surgical positioning-related pressure injuries in the hospital was 60%. Following the program and three months of monitoring, the incidence decreased to 0%. Participants demonstrated increased adherence to prevention protocols and awareness of best practices, illustrating the effectiveness of simulation-based training in translating evidence into routine clinical care.

Conclusion: Realistic simulation is a highly effective, scalable strategy for pressure injury prevention, bridging the gap between evidence and practice. Structured, multidisciplinary simulation programs can dramatically improve patient outcomes, enhance team performance, and establish a culture of safety. The Prevention in Action model offers a replicable framework for hospitals seeking to achieve zero incidence of positioning-related pressure injuries and represents a significant advancement in patient safety education.

EP302 Outcomes of deep tissue pressure injury in critical patients

Kathleen Aparecida Paulino[1], Flavia Sales Leite[1], Marcele Liliane Pesavento[1], Amanda Brandão[1]

[1]Hospital Israelita Albert Einstein, São Paulo, Brazil

Aim: To identify the outcomes of Deep Tissue Pressure Injury (DTPI) acquired in critically ill patients.

Method: A retrospective cross-sectional study was conducted in a private hospital in São Paulo with adult patients hospitalized in an Intensive Care Center (ICC) from January 2022 to December 2023 who developed DTPI. Data were collected from medical records and statistical analysis was performed.

Results / Discussion: During the period, 202 pressure injuries (PI) occurred in the ICC, including 80 DTPI, of which 43 originated in the Intensive Care Unit (ICU). Adherence to preventive dressing was 79%, and to repositioning every two hours was 32,26%. Eighty percent developed an injury.

The most affected regions were sacral (n=25; 31,25%), gluteal (n=16; 20%), and heel (n=19; 23,75%). Treatment most frequently involved hydrogel dressings (n=72; 90%), silicone foam (n=69; 86,25%), and low-level laser therapy (n=48; 60%).

Regarding reclassification at outcome, injuries were resolved (n=34; 42.5%), DTPI (n=19; 23,75%), Stage 2 PI (n=16; 20%), Stage 1 PI (n=3; 3,75%), unstageable PI (n=7; 8,75%), and Stage 4 PI (n=1; 1,25%).

The sample totaled 62 critically ill patients, with a DTPI prevalence of 0,27% in the ICC. Clinical characteristics included hemodialysis (45,16%), corticosteroid therapy (54,84%), urinary incontinence (50%), and enteral nutrition (45,16%). Among the 36 ICU patients, sedation (66.66%), mechanical ventilation (66.66%), and vasopressor use (52,77%) were notable.

Outcomes included hospital discharge (n=34; 54,84%), death (n=27; 43,55%), and one patient remaining hospitalized. Among discharged patients, 60% had resolved injuries, whereas among those who died, 35% had DTPI.

Conclusion: DTPI in critically ill patients represents a major challenge, and the occurrence of never events reinforces the need to strengthen preventive measures, treatment strategies, and professional education.

EP303 Synthesising the evidence for patient and public involvement in pressure ulcer research: A scoping review

Hannah Wilson[1], Aglecia Vitoriano[1], Liane Teixeira[1], Pinar Avsar[1], Linda Nugent[1], Niamh Dillon[1], Declan Naughton[1], Wendy Chaboyer[2], Tom O'Connor[1], Carmel Sharkey[1], Sharon Latimer[2], Declan Patton[1], Zena Moore[1]

[1]Royal College of Surgeons in Ireland (RCSI), University of Medicine and Health Sciences, Dublin, Ireland, *[2]Griffith University, Gold Coast, Queensland, Australia*

Aim: This scoping review synthesised pressure ulcer (PU) research to identify the stage(s) of the research cycle that patient and public involvement (PPI) was incorporated, understand participatory methods employed to facilitate PPI, describe the impact of PPI and understand terminology used to describe PPI.

Method: A search was performed across nine electronic databases until March 2025. Studies with an objective to prevent or treat PUs, that actively involved people with lived experience of PUs as PPI contributors during the research lifecycle were included. Articles were independently screened and pre-defined data were extracted by two authors. Results were synthesised using the Patterns, Advances, Gaps, Evidence for practice and Research recommendations framework. Two PPI contributors collaborated across each stage of this review.

Results: Twenty studies were included, with a median of 6.5 (1-48) PPI contributors. PPI contributors were involved in a median of 2.5 (1-6) research stages (Figure 1). Participatory methods ranged from structured frameworks to flexible, adaptive engagement strategies such as workshops/consultations. The impact of PPI was reported across 80% (n=16) of studies, with majority of impacts reported in the research quality/relevance domain (Figure 2). Limited use of the Guidance for Reporting of Patients and the Public checklist was observed (5%, n=1). Multiple terminology was used to describe PPI (Figure 3).

Conclusion: While PPI is increasing in recent years, there is still a wide variation in how PPI is reported and integrated into PU research. Future PU research should aim to involve PPI contributors from the beginning to the end of the research lifecycle for maximal impact. Reporting checklists can support transparent and consistent reporting of PPI in PU research.

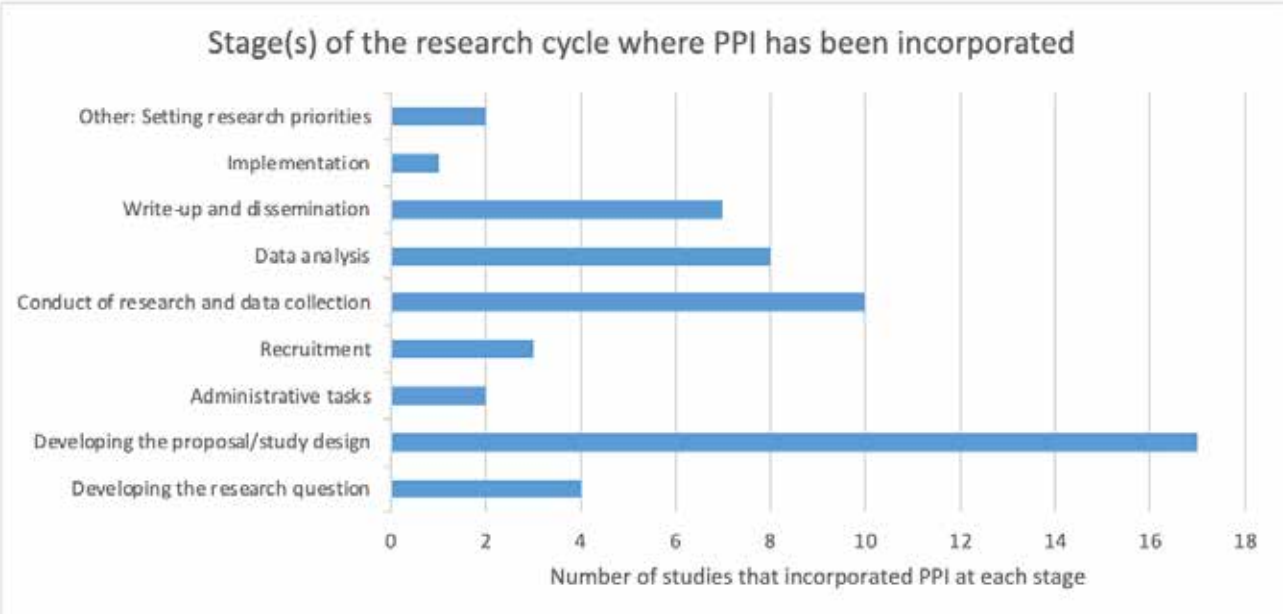

Figure 1

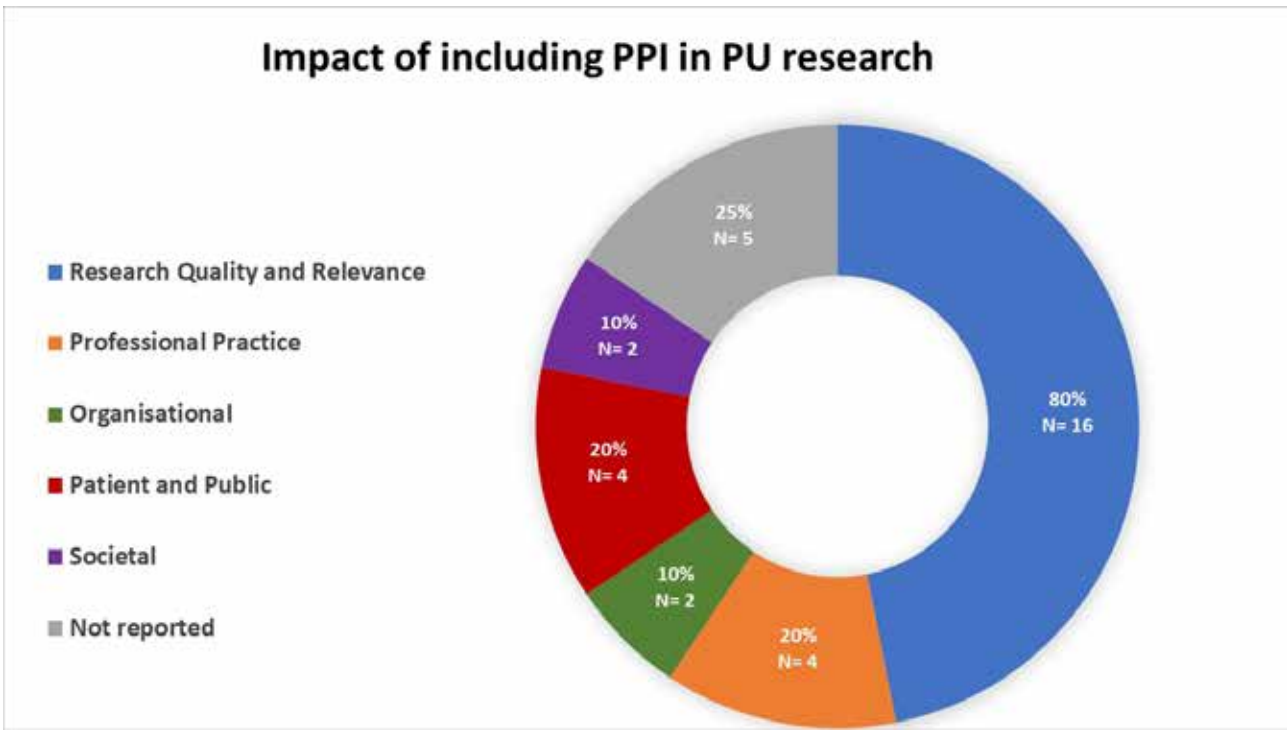

Figure 2

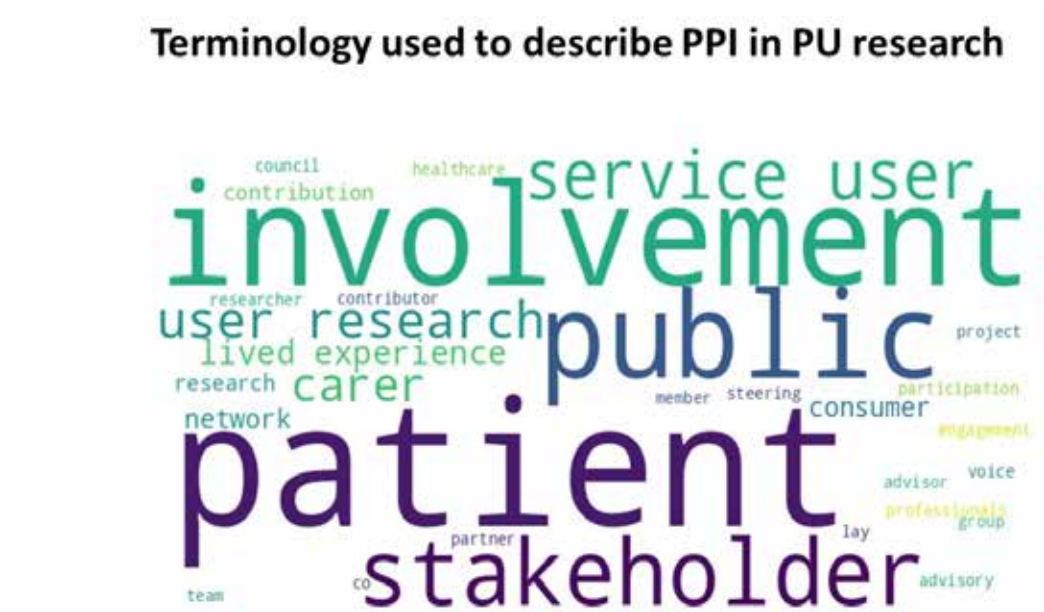

Figure 3

EP475 Development of a basic guide to post-operative stoma care

Ana Paula dos Santos Albuquerque[1], Quézia Dominique[1], Layane de Lima Góis[1], Priscilla Sckarlat[2]

[1]Regional Hospital of Agreste / Pernambuco State Health Department, Nursing Clinic specializing in wound care, Caruaru, Brazil, *[2]Uniregen, Brasília, Brazil*

Aim: To develop a guide to patient care for stoma patients, intended for nurses working in post-operative care. The proposal arose from the observation of the need for scientific resources focused on the perioperative period, with an emphasis on the post-operative care of patients with stoma. This perception was strengthened by experience in clinical practice during surgical nursing residency. The guide aims to support the decision-making of professionals, offering a scientific basis and contributing to nursing care.

Method: This is a qualitative study to develop a guide to stoma care for nurses working in surgical clinics. To develop this material, an active search was conducted in the following databases: Virtual Health Library (BVS), Latin American and Caribbean Literature in Health Sciences (LILACS), and Scientific Electronic Library Online (SciELO). Scientific articles, manuals, and guidelines published between 2009 and 2021, in Portuguese and English, addressing patient care with ostomies were included.

Results / Discussion: Based on the integrative review and study selection, the Basic Guide to Patient Care with Ostomies was developed, divided into: Introduction to the topic, Legal aspects related to patients with ostomies, Postoperative care, and Final considerations. The material reinforces the relevance of care for patients with ostomies and highlights the role of the nurse in this context.

Conclusion: Postoperative hospital care for patients with ostomies is primarily provided by nurses. Therefore, it is essential that these professionals possess up-to-date, evidence-based knowledge to make decisions during hospitalization, ensuring effective care and contributing to a safe transition to hospital discharge.

EP304 Pressure injury management among nurses: A cross-sectional analysis of knowledge, attitudes and practices

Emine Sezgünsay[1], Caglayan Ates Yigit[2], Gülcan Emir[2], Serdar Kaya[2], Zeynep Aksu[2]

[1]İzmir University of Economics, Faculty of Health Sciences, Department of Nursing, İzmir, Türkiye, [2]Antalya Kepez State Hospital, Antalya, Türkiye

Aim: This study aimed to examine nurses' knowledge, attitudes and practices related to the prevention of pressure injuries and to identify factors influencing these levels.

Methods: This descriptive and cross-sectional study included 118 nurses working in a public hospital. Data were collected using a Descriptive Information Form, the Pressure Ulcer Knowledge Assessment Instrument, the Attitude Towards Pressure Injury Prevention Scale, and the Pressure Injury Prevention Practices Evaluation Form. Statistical analyses were conducted using SPSS 21, and descriptive statistics and regression analyses were applied.

Results / Discussion: Of the participating nurses, 74.6% were female and 72% held a bachelor's degree. A total of 36.4% had 7-14 years of professional experience, and half were employed in intensive care units. Additionally, 59.3% reported providing pressure injury care at least ten times per week. The mean knowledge score was 10.5 ± 0.31, the mean attitude score was 42.62 ± 0.47, and the mean practice score was 29.86 ± 0.54. Regression analysis demonstrated that higher knowledge levels were significantly associated with more positive attitudes toward pressure injury prevention ($\beta = 0.436$, $t = 5.219$, $p = 0.000$). Moreover, increased attitude scores significantly predicted improved preventive practices ($\beta = 0.356$, $t = 4.109$, $p = 0.000$).

Conclusions: Although nurses exhibited high attitude and practice scores regarding pressure injury prevention, their knowledge scores were comparatively low. The findings indicate that improved knowledge positively influences both attitudes and preventive practices. Strengthening structured and continuous in-service education programs may support nurses' capacity to prevent pressure injuries more effectively.

EP476 Gamified educational strategy for pressure injury prevention campaign

Lima Priscila[1], Baccas Samantha[1], Nascimento Márcia[1], Cazado Fabiane[1]

[1]AACD, SÃO PAULO, Brazil

Aim: To describe the application of gamification as an educational strategy in a pressure injury prevention campaign using the preventive measures Bundle.

Method: In November 2023, a gamified campaign was conducted in a hospital targeting healthcare professionals. The activity consisted of an "Escape Room" game in three stages: (1) Scenario and Material Preparation: Simulated hospital bed and surgical room scenarios with Braden scale sheets, UV light, and training mannequins; (2) Game Development: participants solved puzzles related to each preventive measure of the Bundle, including skin inspection, patient repositioning, support surfaces, multilayer silicone coverage, and nutrition/hydration; (3) Evaluation and Feedback: participants completed a QR code questionnaire with options: A) met expectations and was fun, B) interesting and promoted teamwork, C) did not enjoy the activity.

Results / Discussion: A total of 65 professionals participated in 12 sessions over two days. Feedback was highly positive: 68% chose option A and 32% option B, indicating that the gamification-based approach was well received and effectively promoted learning. The activity also enhanced engagement, motivation, and teamwork. Gamification proved an interactive method to reinforce knowledge of pressure injury preventive measures.

Conclusion: The gamified educational strategy effectively increased knowledge, engagement, and adherence to pressure injury prevention principles among healthcare professionals. This approach can be replicated in other hospital settings as an innovative method for training, fostering motivation, teamwork, and integration of multidisciplinary teams, ultimately contributing to continuous improvement in clinical practice.

EP305 Economic evaluation of a multilayer silicone foam dressing in the prevention of hospital-acquired sacral pressure ulcers in at-risk patients: A UK perspective

Lloyd Atkinson[1], Leo Nherera[2], Neil Askew[2]

[1]Smith + Nephew, Hull, United Kingdom, *[2]Smith + Nephew, Fort Worth, TX, United States*

Aim: Pressure ulcers are estimated to affect approximately 200,000 hospitalised patients in the UK each year, substantially impacting patient quality of life and contributing significantly to healthcare costs. Due to an ageing population, the incidence of hospital-acquired pressure ulcers (HAPUs) is projected to increase over the next decade. Therefore, improvements in current practices should be sought to address this growing problem, which could deliver significant savings in healthcare resources by reducing costs associated with pressure injury treatment. Using evidence from a randomised controlled trial, we aimed to develop a health economic evaluation comparing the use of a multilayer silicone foam dressing in addition to standard practice (SP) versus SP alone in preventing HAPUs in at-risk patients from a UK perspective.

Method: Using UK-specific model inputs from published literature, we developed a decision-analytic model to estimate the expected costs of implementing the dressing alongside SP. The resulting base-case evaluation was tested for robustness via one-way sensitivity analysis (OWSA) and probabilistic sensitivity analysis (PSA).

Results / Discussion: The resulting analyses found the use of a multilayer silicone dressing to be cost-saving, i.e. it led to a reduction in HAPUs with reduced overall spend, and was the dominant strategy compared with SP. The estimated savings of £220 per patient remained stable when tested in sensitivity analyses (OWSA and PSA). The PSA showed that in 93.4% of simulations the intervention remained cost-saving, demonstrating that the model is robust.

Conclusion: Our findings indicate that the use of a multilayer silicone dressing is not only cost-effective but is also likely to reduce overall spending from a UK payer perspective by reducing costs associated with treating HAPUs.

EP306 Fast-track treatment algorithm for patients with EPUAP stage IV pressure ulcers

Marcin Malka[1]

[1]PODOS Wound Care Clinic, Warsaw, Poland

Aim: To develop a fast-track treatment algorithm for patients with EPUAP stage IV pressure ulcers.

Method: Starting in October 2024, 15 patients (7 women, 8 men; mean age 36.5 years) with stage IV pressure ulcers were treated on an outpatient basis using an innovative algorithm. Key elements included multidisciplinary collaboration (dietitian, physiotherapist, nurse, surgeon) and assessment of transcutaneous oxygen pressure (TcpO2). Only patients with TcpO2 values above 40 mmHg at the wound edges were qualified for wound closure with an antibiotic-releasing implant.

Results / Discussion: The average time to complete wound healing from surgery was 42 days (range: 15–160 days). Patients with properly implemented prevention, monitored TcpO2, adequate nutrition, and wounds in the proliferative phase may be considered for simple reconstructive procedures. This approach can help avoid complex, costly, and high-risk operations in the operating theatre, limiting treatment to simple wound suturing in an outpatient setting.

Conclusion: Appropriate diagnostic methods enable the qualification of selected patients with pressure ulcers for simple wound suturing with an antibiotic implant, reducing both the costs and risks of treatment.

EP307 An observational study relating to the risk of developing pressure ulcers among women undergoing labour and childbirth in the maternity setting

Aine Curtis[1 2], Zena Moore[1], Linda Nugent[1]

[1]School of Nursing and Midwifery, RCSI, University of Medicine and Health Sciences, Dublin, Ireland, *[2]Maternity Unit, Our Lady of Lourdes Hospital, Drogheda, Co. Louth, Ireland*

Aim: The prevalence of pressure ulcers (PUs) in the general population is well documented, however, specific data relating to the development of PUs among women undergoing labour and childbirth is lacking. Although not as common as in other populations, the development of a PU in these women is none the less devastating and is considered an adverse event. In order to place this subject into context, this study aimed to determine the prevalence of PUs and associated risk factors in this population.

Method: An observational cross-sectional prevalence study was undertaken and included women who experienced labour and childbirth. Data were collected using subepidermal moisture assessment (SEM), visual skin assessment, Braden risk assessment, skin tone evaluation, and pain scores. Data were also collected regarding the nature of the labour and delivery and individual patient demographic variables.

Results / Discussion: Of the 133 women included 22.5% (n=30) had red heels (but blanchable erythema) (R heel: 22.5%, n; 30, L heel: 17.2%, n; 23). In total 51.8% (n=69) had an abnormal SEM delta ≥0.6 (R heel: 45.8%, n=61; L heel: 36%, n=48; sacrum: 21%, n=28). Risk factors associated with an abnormal SEM delta included: lower segment caesarean section, induction of labour, and gestational diabetes.

Conclusion: This is the first prevalence study in Ireland in this population, and PU development, as identified using SEM assessment, is a problem in this cohort. Thus, investment in prevention strategies is warranted and will be the focus of an interventional study in this clinical setting.

PREVENTION

EP477 Prevention of medical adhesive-related skin injuries (MARSI) via multidisciplinary interventions and online educational content

Joel Soon[1], Catherine Loo[2], Valerie Lim[1], Mary Jojie[1], Li Sun[1], Chunyin Ho[1], Darryl Lim[1], Harsha Pitumpe[1], Jacqlyn Lam[1], Nadiah Jamil[1], Ling Ong[1], Winnie Soo[1], Shuhua Cheng[1], Peishi Lew[1]

[1]Changi General Hospital, Singapore, Singapore, *[2]Tan Tock Seng Hospital, Singapore, Singapore*

Aim: Medical adhesive-related skin injuries (MARSI) are preventable yet common complications during the removal of groin compression bandages after transfemoral lower limb angioplasty. They lead to increased patient discomfort, prolonged hospital stays, and higher healthcare costs.

Method: We implemented multidisciplinary interventions and developed online educational content for junior medical staff aimed at the prevention of MARSI from removal of groin compression bandages after transfemoral lower limb angioplasty. Interventions were completed in May 2022. We monitored MARSI rates amongst 317 consecutive patients between June 2021 to May 2023 requiring removal of compression bandage after transfemoral lower limb angioplasty. MARSI incidence rates were analysed with Poisson regression analysis.

Results / Discussion: The interventions resulted in a significantly sustained decrease in MARSI incidence from 2-4 events per month (pre-intervention) to less than 1 event per month (post-intervention) (P-value <0.05). Interventions included the use of adhesive-remover spray, frequent re-education of rotating junior medical staff both in-person and via the use of an online educational video on removal technique.

Conclusion: Multidisciplinary interventions and online educational content were effective in preventing MARSI in our institution. Future studies are warranted to assess the cost-effectiveness and generalizability of these interventions.

EP308 Implementation of a practice guideline to reduce pressure injuries in hospitalized children: A quality improvement project

Lydia Bauernfeind[1], Stefan Schoenstein[1], Julia Wistl[2], Simon Schönbrunner[2], Christian Rester[1]

[1]Deggendorf Insitute of Technology, Faculty of Applied Healthcare Sciences, Deggendorf, Germany, *[2]Children´s Hospital Dritter Orden Passau, Passau, Germany*

Aim: A pressure injury (PI) is an adverse event that increases the suffering of children and can also increase the risk of complications. There are also significant economic implications for healthcare systems, as PIs lead to prolonged hospital stays and higher costs. Studies have already shown that the implementation of evidence-based guidelines prevents up to 95 % PIs. These results show the high relevance of implementing prevention strategies to achieve a zero incidence of PI in pediatric inpatient care. Therefore, this study aimed to reduce pressure injuries in hospitalized children through a multi-step quality improvement project.

Method: We conducted a single-center study at a mixed neonatal and pediatric intensive care unit in Germany. The implementation process followed the seven steps of Evidence-Based Practice according to Melnyck et al. Patient data were collected retrospectively from medical records before (n=185) and after (n=218) the implementation process. Statistical analyses using SPSS version 29.0 included multiple-response analyses, Pearson chi-square test and phi coefficient.

Results / Discussion: There was a significant increase in PIs when respiratory support ($p < 0.001$), parenteral nutrition ($p < 0.001$), or inotropic drugs ($p < 0.001$) were necessary. In addition, more PIs were recorded in patients diagnosed with prematurity, and the incidence of PI increased with longer ICU stay. After the education of nurses, a significant increase in risk assessments performed was achieved ($p < 0.001$). After the quality improvement project, grade 2 PIs were completely avoided.

Conclusion: Preventing pressure injuries offers numerous benefits. Our study demonstrates that implementing various measures and training nursing staff results in a higher frequency of PI-risk screenings, a zero incidence of grade 2 PIs and better documentation.

EP478 Skin lesions related to the use of medical adhesives (MARSI): an integrative review

Adrieli Oliveira[1], Márcia Freire[2], Paula Freitas[3], Lucas Rezende[4 5], Aline Ramalho[6], Natalia Barros[7]

[1]Hospital Municipal do Idoso Zilda Arns, Curitiba, Brazil, *[2]Universidade Federal do Paraná, Curitiba, Brazil*, *[3]Universidade Federal do Espírito Santo, Departament of Nursing, Vitória, Brazil*, *[4]Universidade Federal do Rio de Janeiro, Rio de Janeiro, Brazil*, *[5]Centro Universitário Salesiano, Vitória, Brazil*, *[6]Hospital Sirio Libanês, São Paulo, Brazil*, *[7]Essity, São Paulo, Brazil*

Aim: To identify the incidence and prevalence of Medical Adhesive-Related Skin Injury (MARSI) and the scientific evidence that may support prevention strategies.

Method: This is an integrative review with a search conducted in the following databases: CINAHL, PubMed, Scopus, BVS, and Web of Science, carried out in February 2024, based on a question structured using the PICo acronym model.

Results / Discussion: The final sample consisted of 14 articles published between 2019 and 2023. For analysis purposes, the studies were organized into four thematic groups: preventive care for MARSI (n = 6; 42.85%), incidence (n = 4; 28.57%), incidence associated with preventive care (n = 2; 14.28%), and prevalence (n = 2; 14.28%). A prevalence of MARSI of 22.7% was observed in critically ill patients, while the highest incidence identified was 34.6%, predominantly related to mechanical injuries. Regarding care, the studies highlight preventive strategies such as applying a barrier film before using adhesives, employing specific adhesive removers to minimize pain and reduce MARSI occurrence during removal, and training the healthcare team on proper application and removal techniques.

Conclusion: The studies report that skin injuries are commonly found in at-risk patients, particularly in intensive care units and at age extremes; however, their incidence can be reduced through individualized care, appropriate product selection, and training of the healthcare team, achieving awareness among all stakeholders, including patients and families.

EP309 Standardized pressure injury prevention protocol and education improve nursing practice and outcomes in the intensive care unit: A quality improvement project

Juman Shin[1]

[1]*Catholic Kwandong University International St. Mary's Hospital, Incheon, Korea, Rep. of South*

Aim: To evaluate the effectiveness of a standardized pressure injury prevention protocol and nurse education program on nursing performance, knowledge, and clinical outcomes in intensive care units (ICUs) of a tertiary hospital in South Korea.

Method: A multidisciplinary quality improvement project was implemented across three ICUs (700 beds total) from March to November 2024. The intervention included: (1) development and implementation of a standardized preventive dressing protocol for high-risk anatomical and device-related sites; (2) blended learning combining online and hands-on wound care education; and (3) continuous monitoring by wound care nurse specialists. Pre- and post-intervention surveys assessed nursing performance in pressure injury prevention and knowledge competency. Clinical indicators, including pressure injury incidence and worsening rate, were compared with 2023 data.

Results / Discussion: Eighty-five nurses completed pre- and ninety completed post-intervention assessments. Mean nursing performance improved from 78.8% to 95% (+16.2%), and mean knowledge scores increased from 65.3 to 89.2 (+23.9 points). Knowledge regarding wound staging, moisture balance, and device-related injury prevention showed the greatest improvement (up to +67 points). The hospital-wide rate of worsening pressure injuries decreased from 26.3% (2023) to 17.6% (2024), and stage III–IV injury incidence declined from 1.92‰ to 0.5‰. Nurses reported increased confidence and protocol adherence above 90%.

Conclusion: Implementation of a standardized pressure injury prevention protocol, combined with structured education and active wound nurse leadership, significantly improved nurses' knowledge, preventive performance, and clinical outcomes in ICUs. This project demonstrates that protocol-driven, nurse-led QI initiatives can effectively reduce severe pressure injuries and establish sustainable best practices in critical care settings.

EP310 Knowledge on pressure ulcer prevention: psychometric validation of the PUKAT 2.0 for Brazil

Leticia Seltenreich[1], Bruna Velozo[1], Marcelli Vocci[2], Meire Castro[1], Helio Miot[1], Aglécia Budri[1 3], Luciana Abbade[1]

[1]*São Paulo State University (UNESP), Medical School,, Botucatu, Brazil*, [2]*National Institutes of Health, Bethesda, United States*, [3]*School of Nursing & Midwifery. Royal College of Surgeons in Ireland Skin Wounds and Trauma Research Centre, Dublin, Ireland*

Aim: To validate the psychometric properties of the Brazilian Portuguese version of the Pressure Ulcer Knowledge Assessment Tool (PUKAT 2.0).

Method: A methodological study was conducted with 203 nurses and 130 undergraduate nursing students using an online questionnaire. Psychometric evaluation included reliability (test–retest and internal consistency) and item validity (difficulty, discrimination index, and distractor quality).

Results/Discussion: The median score was 57% (IQR 48%–65%). Reliability was adequate, with an intraclass correlation coefficient of 0.808 (95% CI 0.616–0.910; p<0.001) and internal consistency of 0.75 (95% CI 0.71–0.79). Item difficulty (P-value) ranged from 0.31 to 0.92, and discrimination indices (rbis) from 0.21 to 0.59. Distractor quality varied between 0.01 and 0.45, indicating adequate performance of response options.

Performance varied across the 23 items, revealing important knowledge gaps in both groups—particularly on etiological concepts and prevention strategies, similar to findings in recent international studies using PUKAT 2.0.

Differences between nurses and students were statistically significant ($p < 0.001$), with higher scores among nurses, aligning with previous studies indicating the influence of clinical experience on knowledge of pressure ulcer prevention. Although knowledge levels were higher among professionals, evidence suggests a weak association between theoretical knowledge and clinical practice.

Conclusion: The Brazilian-Portuguese PUKAT 2.0 demonstrated strong psychometric performance, including adequate reliability, construct validity, and consistent dimensionality with theoretical domains of pressure ulcer prevention knowledge. The instrument effectively identifies specific knowledge gaps among nurses and students and may support educational strategies, research applications, and quality improvement initiatives. Its use can guide targeted interventions and continuing education, contributing to enhanced preventive practices in diverse care settings.

EP479 Nurses' knowledge and clinical implementation of antimicrobial stewardship (AMS) in hospital-based wound care

Heidi Weedaege[1]

[1]*Hogeschool Vives, Kortrijk, Belgium*

Aim: Antibiotic misuse has contributed significantly to Antimicrobial Resistance (AMR), a major global health threat projected to cause ten million deaths annually by 2050 (O'Neill, 2016; WHO, 2021). Incorrect use of topical antimicrobials in hospital wound care further exacerbates this issue (IWII, 2022). Antimicrobial Stewardship (AMS) provides a framework for the responsible use of antimicrobial agents (Dellit et al., 2007; WHO, 2019). This study aims to assess AMS knowledge, attitudes, and clinical practice among specialized wound care nurses in Flemish hospitals.

Method: A quantitative questionnaire was used to evaluate the AMS-related knowledge, attitude, and clinical practice of specialized wound care nurses. Prior to distribution across 48 Flemish hospitals, a pilot study was conducted, yielding 15 initial responses.

Results / Discussion: Analysis of the 15 pilot responses indicates substantial gaps in AMS-related knowledge and awareness among wound care nurses. Respondents expressed a strong need for education and formal guidance. Notably, the clear interest in standardized Flemish AMS guidelines suggests that such structured resources would likely be well adopted and beneficial in clinical practice.

Conclusion: The pilot study highlights important deficiencies in AMS knowledge and clinical application among wound care nurses, underscoring the need for the full-scale study. Ultimately, the findings will support the development of clear guidelines and targeted educational interventions to enhance antimicrobial decision-making in wound care and reduce the risk of AMR.

EP311 A survey of healthcare practitioners and hospital leadership following adoption of a pressure injury prevention bundle at hospitals in Saudi Arabia

Hossameldin Aboellil[1], Ali Alibrahim[2], Rehab Aldossari[3], Sonya Dick[4]

[1]*Mölnlycke Health Care, Riyadh, Saudi Arabia*, [2]*Jizan health Cluster, MOH, King Fahd Centeral hospital, Jizan, Saudi Arabia*, [3]*King Fahad Specialist hospital, wound care committee, Dammam, Saudi Arabia*, [4]*Mölnlycke Health Care, kentucky, United States*

Aim: Pressure injuries (PI) affect healthcare costs and patient quality of life. There is a substantial burden of PIs in healthcare facilities in Saudi Arabia, where PI incidence rates as high as 38.6%[1] and 39.3%[2] have been reported in acute and intensive care settings, respectively. Pressure Injury Prevention (PIP) product bundles that include prophylactic dressings, turning and positioning devices, and heel support devices may promote cross-functional team-based PIP in these high-risk patient populations. This study aimed to assess the uptake and impact of PIP bundles in hospitals in Saudi Arabia and identify barriers to adoption.

Method: Two surveys were developed for healthcare practitioners (HCPs) and hospital leadership (HLs) in Saudi Arabia, focused on PIP bundle adoption and observed outcomes. Results were collected anonymously using a secure online survey platform.

Results / Discussion: 99 HCPs and 21 HLs participated at 26 hospitals in Saudi Arabia. Team-based PIP bundles were familiar to 87% of HCPs surveyed, with 85% reporting full integration of bundles into ICU protocols. Almost all HCPs (90%) and HLs (84%) reported that integration was neutral to easy, with staff training and budgets identified as barriers to bundle uptake. A high proportion of HCPs (89%) and HLs (95%) reported noticing a reduction in pressure injuries with PIP bundle adoption. Of HCPs and HLs, 96% and 90% (respectively) would recommend the bundle to other hospitals, and 50% of HLs plan to expand their use within the year.

Conclusion: Feedback from HCPs and HLs suggest that PIP bundles are easy to adopt and result in a noticeable reduction in pressure injuries. More educational training and resources may improve adoption and ease of use of PIP bundles.

EP480 Integrated prevention and treatment of pressure injuries in institutionalized older adults: An evidence-based synthesis from a Brazilian long-term care facility

Luciana Mara Cardoso Andrioti Alves[1], Adilson da Silva[1], Andreia Santana[1], Juliana Lucinda dos Santos[1]

[1]*Senior Sabedoria e Vida Long-term Care Facility, São Paulo, Brazil*

Aim: Pressure injuries (PIs) remain highly prevalent in institutionalized older adults, particularly in the context of immobility, frailty and nutritional deficits. Recent studies indicate that multimodal care bundles integrating risk assessment, skin care, pressure redistribution and targeted nutrition outperform isolated interventions.

To evaluate the implementation of combined preventive, clinical and nutritional strategies for PI management in a long-term care facility (LTCF), comparing observed practices with contemporary evidence.

Method: A narrative synthesis derived from a case study in a São Paulo LTCF hosting 31 older adults. Interventions were mapped against international guidelines, systematic reviews and recent trials in nutrition and wound healing. Core components included structured risk assessment, skin care optimization, scheduled repositioning, high-specification support surfaces, staff governance and individualized nutritional plans (30-35 kcal/kg/day, 1.2-1.5 g protein/kg/day, specific supplementation).

Results / Discussion: The LTCF implemented 15 of 18 recommended evidence-based measures (93.75%). Strong adherence was observed for repositioning, gentle cleansing and hydration protocols, daily skin inspection, nutritional screening and interdisciplinary oversight. Protein targets and supplementation strategies were adjusted as recommended. Throughout the observation period, the LTCF achieved a 0% incidence of new PIs, a result aligned with the adoption of complete care bundles supported by optimized nutrition. Findings show operational feasibility and high consistency with best-practice guidelines.

Conclusion: Integrating nutritional strategies with structured skin care and pressure-redistribution technologies demonstrated strong preventive and clinical impact in institutionalized older adults. Sustained success requires standardized bundles, continuous auditing and coordinated multiprofessional action.

Regular protocol audits, GRADE-based local adaptation, and expanded clinical research combining nutrition and multimodal interventions in geriatric populations are recommended.

EP312 Enhancing IAD recovery in older adults: Early outcomes using HASH and a structured skin care bundle in a geriatric ward

Chin Yen Lee[1], Yun Ying Ho[1], Jacob Abraham[1], Ummu Atirah Muhammad[1]

[1]*Hospital Tengku Ampuan Afzan, Ministry of Health Malaysia, Kuantan, Malaysia*

Aim: Incontinence-associated dermatitis (IAD) remains a persistent challenge in geriatric care, particularly among frail, immobile, and moisture-exposed older adults. Effective prevention and treatment require consistent, evidence-based strategies. Hypochlorous Acid-Based Silicone Hydrogel (HASH) is emerging as a promising addition to skin care bundles due to its antimicrobial, anti-inflammatory, and barrier-enhancing effects.

This case series evaluates the real-world impact of a structured IAD management bundle—featuring HASH, ripple mattress support, perineal hygiene and a 2-hourly clock-turn schedule—on skin outcomes among older adults admitted to the geriatric ward.

Method: A prospective case series was conducted involving geriatric inpatients diagnosed with any grade of IAD. Exclusion criteria included existing pressure injury, terminal prognosis, inability of turning, or refusal of participation. The protocol included HASH application to the sacral/perineal region three times daily, pressure redistribution with a ripple mattress, perineal hygiene and a standardized 2-hourly repositioning routine. Outcomes assessed were changes in IAD severity, days to improvement, continence pattern, frailty level (CFS), and nutritional/functional risk factors.

Results / Discussion: Three patients (mean 69-year-old) were enrolled. Two presented with double incontinence, and frailty ranged from CFS 6 to 8. All three patients showed visible improvement within 5–7 days of initiating the protocol.

Conclusion: Implementation of a structured IAD care bundle incorporating HASH demonstrated encouraging improvements in most older inpatients. These early findings support further investigation of HASH-based protocols in larger geriatric cohorts.







EP313 Pressure mapping of wound dressings: What is it really telling us?

Alice Beni[1], Natascia Mennini[1]

[1]*Department of Chemistry "Ugo Schiff", University of Florence, Florence, Italy*

Aim: To develop a reproducible, standardizable approach for pressure mapping of foam wound dressings, focusing on their ability to redistribute pressure and reduce high peaks, thereby preventing the occurrence of pressure ulcers.

Method: A pressure mapping system was employed to quantify the distribution of externally applied loads by different dressings. Downward pressure was applied via an off-the-shelf apparatus with metal spheres of varying diameters. Measurements were taken with a commercially available sensor pad (24 × 24 cm; 10-827 mmHg), recording maximum pressure, average pressure, and contact area, visualized with graphs and colour-coded heat maps.

Results / Discussion: Although previous studies employed a 75 mm sphere (1.7 kg), the resulting pressures reached the apparatus's upper limit for most dressings, masking differences and preventing meaningful comparison. Using a 60 mm sphere (878 g) and a 75 mm hemisphere (854 g) kept values within the calibrated range and yielded more consistent measurements. Nonetheless, variations in applied load and other factors unpredictably influenced pressure distribution and outcomes.

Conclusion: Downward pressure alone provides only a coarse comparative assessment and cannot fully characterize dressings' pressure-relieving properties. Relative performance depends on experimental conditions, highlighting that results under one setup may not translate to others. Shear and friction are essential to capture subtle differences. Integrating pressure mapping with computational analysis could provide a more comprehensive evaluation framework and should be considered when developing standardized testing methods.

EP314 Impact of skin guardians' actions in preventing pressure injuries

Danivea Poltronieri[1], Amanda C.M.A.G. Brandão[1], Maria Emilia Gaspar Ferreira Del Cistia[1], Simone Brandi[1]

[1]*Albert Einstein Hospital, São Paulo, Brazil*

Aim: To evaluate the impact on reducing the incidence of acquired pressure injuries in a hospital setting through the implementation of a team specialized in pressure injury prevention.

Method: This is an experience report from a large private hospital. The intervention consisted of implementing a specialized pressure ulcer prevention team, composed of nursing assistants and technicians called "skin guardians," who received specific theoretical and practical training. These professionals monitor adherence to pressure ulcer prevention practices implemented by their peers and ensure it aligns with the standard of excellence practice advocated by institutional protocols based on best evidence. Data were collected in the 12 months prior to implementation and in the 24 months following, through systematic audits based on the National Database Nursing Quality Indicator (NDNQI) guideline and reported on the PressGaney platform. The outcome analyzed was the incidence density of pressure ulcers per 1,000 patient-days.

Results / Discussion: After implementation, a 36.57% reduction in pressure ulcers was observed (from 3.09 to 1.96 per 1,000 patient-days).

Conclusion: The implementation of skin guardians contributed to the early identification of risk factors for pressure ulcer development, standardization of preventive practices, team engagement, and reduction of pressure injuries, reinforcing the importance of specialized training, care alignment, and continuous monitoring. These results are consistent with studies that have demonstrated similar reductions with the implementation of skin champions, specialized teams, and structured bundle-based initiatives. Replication of this model in other institutions is recommended as an improvement strategy. Team involvement and leadership support were important factors in the success of the initiative.

EP315 Efficacy of a new blend of hyaluronate and six amino acids in a spray formulation in pressure injuries prevention

Roberto Cassino[1], Agnieszka Kopniak[2], Alina Ilisan[2], Anna Montauro[3], Caterina Riggi[3]

[1]"Zucchi" Clinical Institutes, Vulnology Center, Monza, Italy, [2]"Heliopolis Residences" Korian Nursing Home, Binasco, Italy, [3]"Villa Antea" Korian Nursing Home, Vidigulfo, Italy

Aim: At the 2018 EPUAP Meeting, we presented a study in preventing pressure injuries, comparing a silver spray powder with a blend of hyaluronic acid (HA) and four aminoacids (AA - glycine, proline, leucine, lysine) in spray formulation. Today, the HA+AA blend has been enriched with two aminoacids, valine and alanine; the aim of this study is to demonstrate its effectiveness, especially in comparison with the previous formulation.

Method: 100 patients over 80 years (mean age 87.8) and with Norton Score 12 or less were enrolled: 72 without skin lesions and 28 with "blanchable erythema" (Linda Russell's Stage 0); patients with "non-blanchable erythema", cachectic, cancerous and terminally ill were excluded. All patients used memory foam mattresses and standard positioning schedule (every 2 hours). The sacral and trochanteric areas were analyzed and treated with three sprays of hyaluronic acid and six aminoacids blend in spray formulation*, applied every morning, at each diaper change, and every evening. Observation period: 4 weeks. The possible onset of pressure injuries, patient discomfort and/or pain, and any adverse events were evaluated.

Results / Discussion: Only two patients out of 72 that had no lesions developed a "blanchable erythema"; three of the 28 patients with "blanchable erythema" remained unchanged, while the other 25 completely healed. Overall, the study concluded with 95 patients without lesions and 5 with "blanchable erythema." No discomfort/pain reported. No adverse events occurred.

Conclusion: The hyaluronate + 6 aminoacids blend demonstrated superior efficacy to the previous mixture (4 aminoacids) and prevented pressure injuries development in all patients. The absence of adverse events and discomfort demonstrates not only its efficacy but also its safety.

*Vulnamin 6 Spray (Professional Dietetics, Italy)

EP316 Point prevalence of lower limb oedema and ulceration among nursing and residential home residents

Katie Harrison[1], Kate Shirlow[1], John Stephenson[2], Leanne Atkin[1 2]

[1]Mid Yorkshire Teaching NHS Trust, Wakefield, United Kingdom, [2]School of Human and Health Sciences, University of Huddersfield, Huddersfield, United Kingdom

Aim: Chronic lower-limb oedema is an under-recognised and under-managed condition, associated with significant morbidity and cost to healthcare systems. There is an absence of robust data regarding the true prevalence of lower-limb oedema in UK care homes. This study aimed to determine the prevalence of lower limb oedema and ulceration in residential and nursing homes across one UK integrated care system, and to assess oedema severity and use of compression therapy.

Method: A cross-sectional point-prevalence audit was conducted across 20 care homes during a 1-day period. NHS nursing staff used the modified Fukazawa method to determine the presence and severity of lower-limb oedema for all eligible residents. The presence of ulceration (defined as per the National Wound Care Strategy), use of compression therapy, mobility, capacity status and demographic data were recorded. Data was analysed descriptively.

Results / Discussion: Data was collected from 591 residents across 20 homes (98.3% participation). The mean age was 84.7 years and 70.7% were female. 54.5% lacked capacity, and only 25.4% walked unaided.

- Over half (50.3%) of residents had lower limb oedema and approximately half of these had moderate to severe oedema (grade ≥2 or non-pitting).
- 9.1% had active lower-limb ulceration.

- Use of compression therapy was very low, with only 1.01% of those with oedema and 5.67% of those with ulceration receiving appropriate evidence-based compression.

Conclusion: This study reveals a high burden of lower-limb oedema in UK care homes, alongside very low use of therapeutic compression. This highlights the need to develop strategies for proactive oedema screening and pathways for the provision of compression therapy, which could substantially reduce avoidable ulceration, infection and hospital admission in this vulnerable population.

EP317 Incidence of MARSI in a reference hospital for elderly care

Adrieli Oliveira[1], Paula Freitas[2], Lucas Dalvi Armond Rezende[2]

[1]Hospital Zilda Arns, Curitiba, Brazil, *[2]Universidade Federal do Espirito Santo, Espirito Santo, Brazil*

Aim: The creation of a specific quality indicator for MARSI is essential to reduce its occurrence and impact. It enables monitoring and improvement of preventive care, such as skin preparation, appropriate adhesive selection, and correct application and removal techniques.

Method: An active search was conducted among all patients hospitalized in the institution from November 16 to 23, 2025, including those in the intensive care unit, inpatient unit, and emergency department.

Results / Discussion: The active search was carried out by a wound, ostomy, and continence nurse and two elderly health residents. Skin assessment involved examining areas where adhesives are applied, such as the chest, thighs, arms, face, and sacral region. To identify the at-risk population, the total number of patients who used adhesives during the seven-day observation period was determined (n=730). Data collection was performed based on findings recorded in medical charts and spreadsheets for indicator monitoring, resulting in seven new MARSI cases during this period. Incidence was calculated as the total number of new cases divided by the total number of patients using adhesives, multiplied by 100, yielding a result of 0.95.

Conclusion: The institution showed a low incidence indicator compared to the literature, considering that the adhesives used were nonwoven fabric acrylic tapes and polyurethane film for catheter and dressing fixation, with standardized use of bandages for fixation in wounds on upper and lower limbs. The service also has a specialized professional leading care efforts.

EP318 Pressure mapping to evaluating intraoperative pressure injury risk

Lisa Peterson[1], Julie Chou[1], Blythe Durbin-Johnson[1], Sarina Fazio[1]

[1]UC Davis Health, Sacramento, United States

Aim: The purpose of this project was to evaluate different pressure offloading tools for surgical patients in supine position, as well as patient specific and surgery specific risk factors for intraoperative pressure injuries.

Method: The purpose of this project was to evaluate different pressure offloading tools for surgical patients in supine position, as well as patient specific and surgery specific risk factors for intraoperative pressure injuries.

Results / Discussion: No pressure measurement was significantly correlated with the Munro risk assessment tool (preoperative plus intraoperative) and not significantly correlated with Munro (intraoperative) although a trend was seen with area under the pressure-time curve (AUC) of P= 0.051. Scott Triggers risk assessment tool showed no significant difference between low and high risk patients in relation to pressure results. After adjusting for ASA and total surgery time, a one-hour increase in surgery time was associated with a 28% increase in AUC (P = <0.001).

For body mass index (BMI), a 10-unit increase was associated with a 6% increase in average peak pressure (P= 0.0002). There was no statistical significance for the pressure offloading devices used (dynamic air mattress, static air cushion and memory foam overlay), however, the AUC values varied by device but did not have a significant p-value.

Conclusion: Surgical time and BMI are significant pressure injury risk factors for surgical patients, however, a larger data pool is necessary to understand the efficacy of pressure offloading devices.

EP320 Improving antimicrobial stewardship and patient care in a diabetic foot clinic

David Nelson[1]

[1]*Brightwake Ltd, nottingham, United Kingdom*

Aim: The author aimed to reduce inappropriate antibiotic use within their treatment area. In response to rising global concerns about antimicrobial resistance, the author introduced an antimicrobial stewardship approach and evaluated its impact on practice. They also sought to ensure healing outcomes were maintained by following the clinical progress of a patient with a diabetic foot ulcer.

Method: An MRSA pathway (Fig. 1) was developed and implemented in a specialist diabetic foot clinic. This pathway considered clinical signs and symptoms of potential wound infection, recommended appropriate antibiotic duration, and incorporated measures such as body washes, nasal sprays, and antimicrobial soaks. It also advised scheduling MRSA-positive patients at the end of clinic sessions and reinforced hand hygiene.

A six-month audit of antibiotic requests and rejections (Table 1) was undertaken to assess whether introducing an antibiotic request form could reduce inappropriate prescribing. Clinician education on correct antibiotic use was also provided.

Results / Discussion: Antibiotic requests decreased from 45 in April to 16 in September following implementation of the pathway and request form (Fig. 1 and 2). Increased training and awareness of antimicrobial resistance further reduced inappropriate requests and rejections (Table 1).

A patient pathway (Table 3) demonstrated that appropriate antibiotic use and adherence to the pathway could be achieved without compromising wound-healing outcomes

Conclusion: Implementing the MRSA pathway, antibiotic request form, and clinician education effectively reduced inappropriate antibiotic use without affecting wound-healing outcomes. This demonstrates that clear guidance and improved awareness can strengthen antimicrobial stewardship in clinical practice.

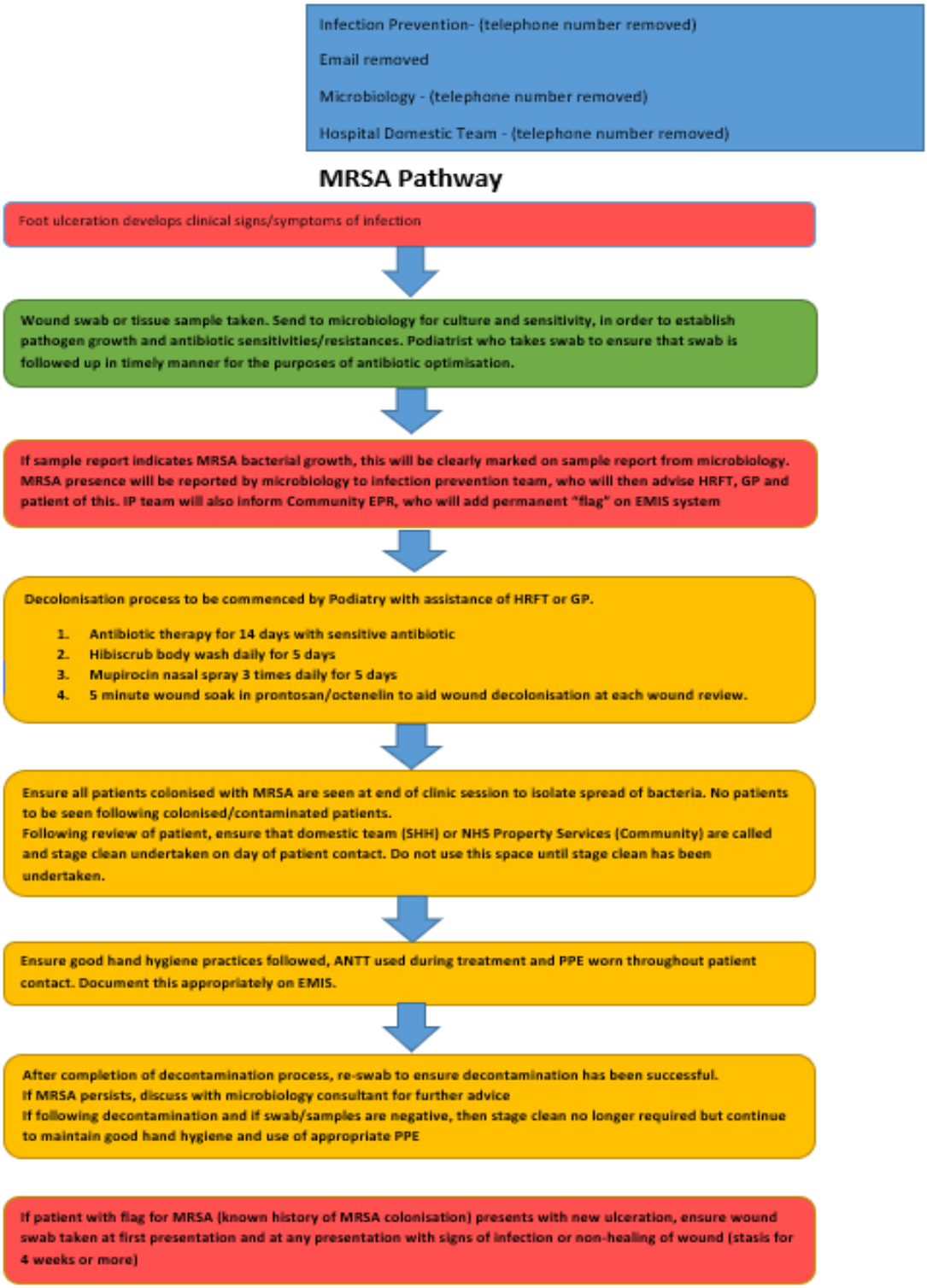
Infection Prevention- (telephone number removed)
Email removed
Microbiology - (telephone number removed)
Hospital Domestic Team - (telephone number removed)
MRSA Pathway
Foot ulceration develops clinical signs/symptoms of infection
Wound swab or tissue sample taken. Send to microbiology for culture and sensitivity, in order to establish pathogen growth and antibiotic sensitivities/resistances. Podiatrist who takes swab to ensure that swab is followed up in timely manner for the purposes of antibiotic optimisation.
If sample report indicates MRSA bacterial growth, this will be clearly marked on sample report from microbiology. MRSA presence will be reported by microbiology to infection prevention team, who will then advise HRFT, GP and patient of this. IP team will also inform Community EPR, who will add permanent "flag" on EMIS system
Decolonisation process to be commenced by Podiatry with assistance of HRFT or GP.
1. Antibiotic therapy for 14 days with sensitive antibiotic
2. Hibiscrub body wash daily for 5 days
3. Mupirocin nasal spray 3 times daily for 5 days
4. 5 minute wound soak in prontosan/octenelin to aid wound decolonisation at each wound review.
Ensure all patients colonised with MRSA are seen at end of clinic session to isolate spread of bacteria. No patients to be seen following colonised/contaminated patients.
Following review of patient, ensure that domestic team (SHH) or NHS Property Services (Community) are called and stage clean undertaken on day of patient contact. Do not use this space until stage clean has been undertaken.
Ensure good hand hygiene practices followed, ANTT used during treatment and PPE worn throughout patient contact. Document this appropriately on EMIS.
After completion of decontamination process, re-swab to ensure decontamination has been successful.
If MRSA persists, discuss with microbiology consultant for further advice
If following decontamination and if swab/samples are negative, then stage clean no longer required but continue to maintain good hand hygiene and use of appropriate PPE
If patient with flag for MRSA (known history of MRSA colonisation) presents with new ulceration, ensure wound swab taken at first presentation and at any presentation with signs of infection or non-healing of wound (stasis for 4 weeks or more)

Fig 1

Table 1

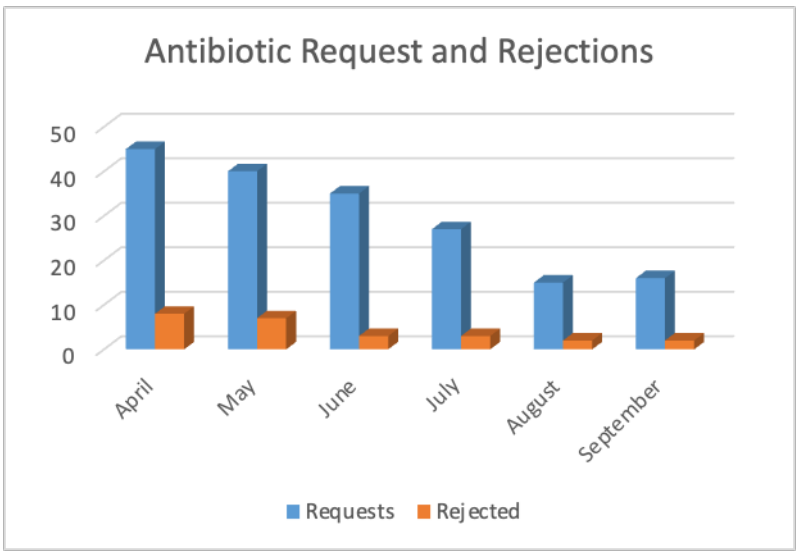

NHS Podiatry Antibiotic Request Form

Patient Details	
Full Name	
Address	
NHS No.	
Date of Birth	
Telephone Number	
Special Requirements	
Weight (kg)	

Clinical Details	
Relevant Medical History	
Current Repeat Medication	
Allergies	
Clinical signs of infection	
Photo taken	Y [ ] N [ ]
Sample taken	Y [ ] N [ ]
Management to date	

Referrer Details	
Name	
Designation	
Is patient aware of antibiotic request?	
Planned/ongoing management	

Fig 2

Table 3

Age	79
Comorbidities	Diabetic foot ulcer, Chronic kidney disease stage 3, Diabetic maculopathy, Background diabetic retinopathy, Ischaemic heart disease, Type 2 diabetes, presented at GP with foreign object in his foot.
Wound	Right Foot
Fig 3 (17/2/25) 	Fig 4 (4/3/25)  ,
Fig 5 (25/4/25) 	Fig 6 (23/5/25) 
Treatment	Assessment, Cleansing, debridement, honey dressing, superabsorbent dressings, IV antibiotics, diabetes management, microbiology, X-ray

EP321 An innovative treatment using sterile hyaluronic acid injections to reduce foot ulcer reccurence in patients with diabetes: a pilot study

Catherine Hughes[1], Cynthia Formosa[2]

[1]Curacorn Limited, Greater Manchester, United Kingdom, 2University of Malta, Malta

Aim: To evaluate whether plantar injection of hyaluronic acid using the Curacorn® technique reduces ulcer recurrence in high-risk patients with diabetes.

Method: This pilot study included 14 patients with type 2 diabetes and a history of recurrent, healed plantar ulcers. Patients underwent multiple treatments with a specific hyaluronic acid gel implanted beneath previous ulcer sites using the Curacorn® technique. Follow-up was conducted over 6–12 months to assess ulcer recurrence.

Results / Discussion: Fifty percent of patients experienced no ulcer recurrence during follow-up. These patients received a higher total volume of hyaluronic acid compared with those who developed recurrence (mean 7.4 ml vs.

3.9 ml). In patients with recurrence, ulcers reappeared after an initial ulcer-free period of approximately six months. The findings suggest that adequate restoration of plantar cushioning through sufficient gel volume may be a key factor in preventing recurrence. Compared with traditional strategies such as prolonged off-loading or surgery, this minimally invasive technique may offer advantages in safety, reversibility, and patient tolerance.

Conclusion: Plantar implantation of hyaluronic acid using the Curacorn® technique was associated with a reduction in ulcer recurrence in this high-risk diabetic cohort, particularly when adequate gel volumes were administered. These preliminary results support further investigation of this novel, minimally invasive preventive approach in larger controlled studies.

PROFESSIONAL COMMUNICATION

EP527 Impact of a complex wound care center in primary care in Portugal: Six years of activity (2018–2024)

Carlos Mateus[1], Sara Magalhães[2], Adelina Valfreixo[2], José Canas[2]

[1]Unidade Local de Saúde Amadora Sintra, Universidade de Évora, Portugal, Escola Superior de Saúde da Cruz Vermelha Portuguesa, Sintra, Portugal, *[2]Unidade Local de Saúde Amadora Sintra, Sintra, Portugal*

Aim: To evaluate the clinical, operational, and educational impact of the Complex Wound Care Center (CWC) of Sintra (Portugal) from 2018 to 2024, analyzing patient characteristics, activity indicators, outcomes, and recurrent organizational constraints.

Method: A retrospective descriptive study based on annual activity reports from 2018 to 2024. Data collected included demographic characteristics, wound etiology, number of consultations, healing times, clinical outcomes, referral patterns, training activities, and staffing. Comparative analysis was performed across the different reporting periods.

Results / Discussion: Between 2018 and 2024, the CWC followed over 580 patients, delivering more than 8,000 consultations. In the most recent biennium (2023–2024), 123 patients were assessed (62% male; mean age 66.6 years), mostly referred by Family Health Units (71%). The most frequent etiologies were venous leg ulcers (33%), diabetic foot ulcers (20%), mixed etiology ulcers (15%), and onychocryptosis (10%). Approximately 68% of patients achieved complete healing within 90 days, with overall treatment times reduced by up to 53% in some periods. More than 80% of cases reached successful discharge, with very low rates of major amputations or hospitalizations. The team also delivered over 3,000 hours of training to healthcare professionals and students, community-based foot-care education, and developed multiple educational tools. Persistent limitations included insufficient human resources, restricted access to electronic clinical records, and the inability to conduct on-site assessments in primary care units.

Conclusion: The CWC has demonstrated a sustained and significant clinical impact on the management of complex wounds in primary care, improving healing outcomes, reducing complications, and strengthening clinical practice within the health system. Further consolidation requires workforce reinforcement, improved interinstitutional coordination, and investment in digital clinical infrastructures.

EP584 Burnout among healthcare professionals: A systematic review and meta-analysis of recent evidence (2019–2025)

Luciana Mara Cardoso Andrioti Alves[1], Adilson da Silva[1], Andreia Santana[1], Juliana Lucinda dos Santos[1]

[1]Senior Sabedoria e Vida Long-term Care Facility, São Paulo, Brazil

Aim: This study aimed to synthesize recent evidence on the prevalence, risk factors, and intervention strategies associated with burnout among healthcare professionals involved in the prevention and management of pressure injuries (PI). Given the high emotional and physical demands of PI care - particularly in older adults and critical care environments - this review explores its determinants and identify effective approaches to prevention and support.

Method: A systematic review was conducted following PRISMA guidelines. Searches were performed in PubMed, SciELO, and SpringerLink for studies published between 2019 and 2025. Eligible studies included healthcare professionals involved in direct PI care and used validated instruments to assess burnout, predominantly the Maslach Burnout Inventory (MBI). Twelve studies met the inclusion criteria, representing approximately 150,000 participants across nursing, medicine, physiotherapy, and allied health fields.

Results / Discussion: Burnout prevalence varied widely, ranging from 11.2% to 67%, with higher rates in intensive care environments, where burnout affected 41% of physicians and 44% of nurses. Identified risk factors included long working hours, insufficient resources, high emotional burden, and the demanding nature of PI care. Individual interventions such as mindfulness and coaching showed modest, short-term benefits, while organizational interventions - work redesign, improved staffing, psychological support programs, and enhanced training - demonstrated greater potential for sustained impact. These findings reinforce that burnout in PI care is multifactorial, strongly linked to organizational dynamics, and directly associated with decreased quality of care and increased risk of complications.

Conclusion: Burnout among professionals caring for PI is a critical and growing concern. Sustainable organizational strategies, combined with targeted individual support, are essential to protect workforce well-being and ensure high-quality PI prevention and management.

QUALITY OF LIFE

EP322 Premature aging skin manifestations in Down's syndrome-trisomy 21

Marwa Adam[1]

[1]Kordofan University, Sudan Medical Specialisation Board, Saudi Commission for Health Specialties, Riyadh, Saudi Arabia

Aim: The study aimed to explore the various dermatological manifestations of premature aging in Down Syndrome (DS) people.

Method: Site of the study was a school for DS students, named Sudan Centre for Down syndrome (SCDS). Which was the only specified place for DS in Sudan. Out of 60 students. Only 24 students applied to the study A control of 21 of normal population was set. I Used the Score for Intrinsic and Extrinsic Skin Aging (SCINEXA) (modified) for assessing the aging process, Modified Fitzpatrick scaling system for assessing the facial wrinkling and the Busso scale for hands.

Results / Discussion: The results showed obvious acceleration of premature aging signs. The most dermatological findings in DS group were Miliaria 45.8%, nail ridging 375%, Subungual hyperkeratosis 25%, Chelitis 25%, PPK 20_8%, followed by impetigo 16.7% and Dermatophagia 16.7% There was significant association between having a child with DS and an older mother age. Paternal diabetes and hypertension were remarkable in DS group, but less significant than maternal age at birth.

Conclusion: There was a true accelerated aging process in DS group. Paternal diabetes and hypertension obviously had a role for having a baby with DS but less significant than the maternal age.

EP481 Home-based management of cancer fungating wounds: Improving quality of life for patients in rural India

Aditya Manna[1]

[1]*Mas Clinic & Hospital, Tamluk, India*

Aim: To develop and implement a home-based, low-cost, and compassionate model for managing cancer fungating wounds in rural India, aiming to improve symptom control, comfort, and overall quality of life for patients with limited access to specialized palliative care services.

Method: A descriptive observational study was conducted through the MAS Home Care Program in East Medinipur District, West Bengal, from January 2023 to September 2024. Forty-eight patients with advanced cancers and fungating wounds (mainly breast, head & neck, and cervical cancers) were included. A multidisciplinary home care team—comprising an oncology social worker, nurse, and family caregiver—was trained in wound hygiene, odor and exudate control, pain relief, and infection prevention using locally available materials. Regular home visits, telephonic follow-ups, and psychosocial counseling were provided to both patients and caregivers.

Results / Discussion:

Symptom relief: 85% of patients reported reduced odor and exudate.

Pain control: Improved in 70% of patients with consistent topical and systemic analgesia.

Psychological well-being: 76% of families expressed reduced distress and improved coping.

Caregiver satisfaction: 90% rated the home-based approach as “highly satisfactory.”

Affordability: Average monthly wound management cost was approximately ₹600 (≈ €7).

Conclusion: This community-based home care model demonstrates that with proper guidance, family empowerment, and low-cost resources, cancer fungating wounds can be effectively managed at home. The approach not only alleviates physical symptoms but also restores dignity, reduces stigma, and improves psychosocial well-being. Integrating such models into national cancer and palliative care programs can help reduce inequalities and strengthen rural cancer care delivery in India and other low-resource settings.

EP323 The multidimensional impact of complex wounds on family systems: A scoping review

Lourdes Muñoz-Hidalgo[1], Elisabete Rodrigues[2], Sandra Catarina Fonseca Simões da Silva[3]

[1]*USF Cruz de Celas - ULS Coimbra, ELCOS-Sociedade Portuguesa de Feridas, Coimbra, Portugal*, [2]*SESARAM (Portugal), Funchal, Portugal*, [3]*Santa Maria Health School, RISE Health, Porto, Portugal*

Aim: To map, critically analyze, and synthesize available scientific evidence regarding the impact o**n** complex wounds on families, identifying the affected domains and challenges faced.

Method: This scoping review followed the methodology proposed by de Joanna Briggs Institute. Searches were conducted in scientific databases (CINAHL, MEDLINE/PubMed, Cochrane) and grey literature (RCAAP, Google Scholar) to include studies focusing on families and informal caregivers of individuals with complex wounds.

Results / Discussion: Nineteen studies were included, demonstrating that complex wounds are more prevalent in adults and older people (51-80 years), often presenting with low education levels and comorbidities. Venous leg ulcers and pressure ulcer were the most frequently identified wound types, informal caregivers, predominantly women over 60, who cohabit with the patient, assume most of the care. Complex wounds have a transversal impact, affecting the family´s structure (fragility of support networks, domestic reorganization), development (interference with normative life cycle transitions, isolation, suffering), and intergenerational conflicts). Strong affective bonds and emotional support were identified as protective factors.

Conclusion: The presence of a complex wound profoundly affects the family system, resulting in significant caregiver burden and alterations in family dynamics across physical, emotional, social, and economic dimensions. It is essential

for Family Health Nursing to adopt a family-centered approach, promoting competences and resources, with the Family Health Specialist Nurse playing a crucial role in minimizing negative impacts and promoting collective well-being.

EP324 The new multimodal approach in the treatment of deep dermal and full thickness facial burns - psychological impact & social reintegration

Panche Taskov[1], Daniela Taskov[2], Zorin Crainiceanu[1]

[1]1.University of Medicine and Pharmacy "Victor Babes", Timisoara Romania, 2.Plastic and Reconstructive Surgery Department Casa Austria, County Emergency Clinical Hospital "Pius Branzeu", Timisoara Romania, Timisoara, Romania, *[2]Plastic and Reconstructive Surgery Department Casa Austria, County Emergency Clinical Hospital "Pius Branzeu", Timisoara Romania, Timisoara, Romania*

Aim: Deep facial burns are often a challenge, especially due to the fact that they are often associated with respiratory tract burns that lead to the rapid destabilization of the patient.

The preservation of viable facial layers, especially the viable dermis are essential for spontaneous epithelization.

Carrying out the affected tissue debridement as quickly as possible is essential, especially in the case of burns on the face, where early debridement promises a better aesthetic and functional result.

Method: A single-centre retrospective observational study was performed in 5 years period (2020-2025), comprised 15 adults with deep partial/full-thickness facial burns treated with EDNX.

In this study 10 patients (66.7 %) were male and 5 patients (33.3 %) female, 3 of them with airways burns, ABSI (media) 7,6, the facial cohort showed a mean age of 35.6 ± 10.8 years, average %TBSA was 23.8 ± 7.0, with 6 ± 2 % TBSA of the face treated by EDNX.

Results / Discussion: All patients with deep partial/full-thickness facial burns achieved full epithelialisation within three weeks, reflecting the high vascularity of facial skin synergised with dermis-sparing debridement.

Functional assessment revealed preserved eyelid excursion, oral competence and cervical extension, a notable advance over traditional excision outcomes that often necessitate later scar-release procedures.

Conclusion: Off-label facial application EDNX is safe, delivers significantly shorter length of stay relative to injury size, while preserving dermal tissue that translates into superior long-term scar quality and clinically advantageous alternative to early tangential excision.

Facial use eliminates grafting, accelerates healing and yields near-normal scar indices at one year, with high patient satisfaction intact facial function and faster occupational reintegration and also an increased quality of life.

EP325 A product-design framework for chronic wound management: creating solutions that empower, inform, and connect patients

Alisa Kolganova[1 2], Louise Kiernan[3], Shavini Stuart[2]

[1]School of Design, University of Limerick, Limerick, Ireland, *[2]Holst Centre, TNO, Eindhoven, Netherlands*, *[3]University of Limerick, Limerick, Ireland*

Aim: This study applied product design methodologies to shaping new ideas for more effective, economical and sustainable solutions in chronic wound care. The project centered on empowering patients & clinicians within the user journey, to explore how 'empowerment' is defined across these different groups.

Method: The work was carried out following the double diamond design framework with initial research being carried out by engaging with various stakeholders. A questionnaire tailored to four separate stakeholder groups was sent out to acquire initial insights into the topic. Interviews with clinical professionals including tissue viability, community and public health nurses were conducted. Informal caregivers, friends, family members and those who have previously

experienced long-term wounds were also interviewed for further in-depth understanding. Observations, problems and needs from research were thematically analyzed and organized into themes that formed a design guide.

Results / Discussion: Feedback from research across participant groups (61.5% healthcare professional input) directed the ideation of the project. Potential solutions addressed needs in three key areas: accessible education and guidance, accurate wound assessment and monitoring as well as improved comfort and safety. Findings suggested digital solutions, reducing smell, exudate, and pain are among directions for further development.

Conclusion: Employing a product design methodology into wound care research can aid the development of new practices and ideas. This approach is not commonly used when considering cause and effect within engineering teams. It ensures that emerging solutions are grounded in the real needs, behaviours, and experiences of stakeholders. Ultimately, incorporating design-driven thinking into chronic wound care has the potential to generate more effective, inclusive, and sustainable solutions that improve quality of life and empower those living with non-healing wounds.

EP326 Flap reconstruction of complex natal cleft pilonidal sinus wounds: Outcome study

Shola Adeniran[1], Justin Alberts[1]

[1]West Suffolk Hospital, Bury St. Edmunds, United Kingdom

Aim: Natal cleft pilonidal sinus often result in distressing chronic discharging complex wounds whose treatment can be challenging and whose recurrence rate following surgery can be high, especially in failed previous surgery cases. We aim to present the outcome of gluteal fasciocutaneous flap used for reconstructing defects resulting from first-time surgery and from cases of failed previous surgery.

Method: Records of patients who had gluteal fasciocutaneous flap reconstruction as first treatment for complex pilonidal sinus disease and for cases of failed previous surgery were reviewed and data extracted analysed. Outcome of this treatment method is presented with illustrative photographs.

Results / Discussion: 8 patients underwent the stated surgical procedure: all were male with ages ranging from 19-57 years. All but one patient had recurrent disease, with 2-17 previous operations. There was one case of flap tip necrosis but all wounds ultimately healed nicely with no disease recurrence during a follow up period of 8-36 months. All patients reported much improved quality of life and satisfaction with outcome of their operation.

Conclusion: Use of gluteal fasciocutaneous flap for reconstructing defects of adequately excised initial and recurrent natal cleft pilonidal sinus is a simple, safe and durable method for successfully treating both types of cases. It can result in zero recurrence rate, satisfactory outcome and markedly improved quality of life.

EP482 The use of enzym alginogel by chemo related dermatitis

Abeltje Schmidt[1]

[1]Prinses Maxima Center, Utrecht, Netherlands

Aim: Incontinence-associated dermatitis (IAD) is a common complication in children undergoing chemotherapy. Beyond erythema, IAD in this population can progress to severe skin breakdown and ulcerations on the buttocks, often requiring substantial analgesia and prolonged healing. Because chemotherapy commonly induces diarrhea, wound healing will be delayed by definition.

Method: Pediatric patients with moderate to severe IAD were registered alongside their diagnoses and chemotherapy regimens. It was observed that diaper-dependent children with neuroblastoma or acute lymphoblastic leukemia (ALL)—especially those treated under infant protocols—almost invariably developed severe IAD as a chemotherapy side effect. Since dressings are difficult to fix to the buttock area, enzym alginogel was evaluated as a topical option for open or broken skin. In a case report documented its application for buttock lesions in this patients group.

Results / Discussion: This approach of enzym alginogel proved effective in managing IAD lesions graded 2A–2B on the Globiad scale. Treatment was painless, easy for parents to apply, and allowed gentle enzymatic debridement when needed. It could be safely reapplied multiple times after diaper changes and combined with adjunctive therapies such as local morphine gel for pain control or antifungal cream if indicated.

Conclusion: Recognizing which chemotherapeutic agents most frequently associated with severe IAD allows early initiation of enzym alginogel when the skin requires more than barrier protection alone. The treatment can be safely performed at home by parents, providing both wound care and pain relief. This approach supports faster recovery of buttock skin, earlier restoration of an effective barrier, and improved comfort and care continuity in pediatric oncology patients. When wounds are closed you can go back to the barrier cream again.

EP328 Changes in wound treatment with improvement in healing and Quality of Life outcome

Stine Hansen[1]

[1]*Faaborg-Midtfyn kommune, Faaborg, Denmark*

Aim: To evaluate the impact of single-use negative pressure wound therapy (sNPWT) on patient quality of life and healing outcomes in wounds at risk of non-healing.

Method: Data was collected in a Danish community including knowledge about the wound and risk factors before intervention with sNPWT. Quality of life was measured with the Wound-QoL survey form before intervention and after two weeks of sNPWT. Follow up data (wound size and treatment) was collected weekly until complete healing or up to 8 weeks whichever came first. No patient identifiers were recorded in this evaluation.

Results / Discussion: Data on 23 wounds were analyzed, 13 wounds had been clinically assessed as delayed, 5 were static and 5 were judged to be deteriorating. Risk-factors indicating that the wound would become hard to heal were identified in 21 patients. Prior to intervention, dressings were changed on average 3.8 times per week. During the intervention numbers of dressing changes reduced to average 1.8 times per week and 0.8 once the wound returned to standard care. Within the 8 weeks follow up out of the 23 wounds, 16 were documented as healed, 6 had seen an area reduction and 1 did not respond to treatment. Numbers of dressing changes per week was reduced with more than 50% when introducing sNPWT. The impact of the wound on quality of life decreased by more than 0.5 points, representing a clinically meaningful improvement for patients.

Conclusion: In patients with stalled wounds and risk-factors for their wound to become hard to heal, sNPWT helped facilitate healing and improve quality of life.

EP483 Exploring the experience of patients with chronic, complex, or hard-to-heal wounds throughout their care pathway

Nerea Bugallo García[1], Paula Ibañez de Haro[1], Marta Fernandez Ruiz[1], Sendoa Ballesteros Peña[1], Eztizen Miranda Bernabe[1], Nahikari Peñafiel Herrera[1]

[1]*Osakidetza, Bio Bizkaia, OSi Barakaldo - Sestao, Bilbao, Spain*

Aim: To explore how patients and their families experience the treatment and follow-up of complex chronic wounds, identifying needs, barriers, and opportunities to humanise healthcare delivery.

Method: A qualitative phenomenological study conducted between May and October 2025. Thirty-six participants were interviewed using semi-structured interviews. Purposive sampling considered wound type, age, sex, geographic location, and care setting. Interviews were transcribed verbatim and analysed through inductive coding, identification of meaning units, and thematic grouping using Atlas Ti. Study credibility was ensured through investigator triangulation, theoretical saturation, and partial member checking.

Results / Discussion: Four principal themes emerged: 1) Care trajectory, characterised by fragmentation between primary care and specialist units; 2) Relationship with healthcare professionals, where empathy, clear communication, and coordination fostered trust and adherence; 3) Biopsychosocial impact, including functional limitations, emotional burden, and identity changes; 4) Support and coping, highlighting the role of family, social networks, and personal resilience strategies. Delays, poor continuity, and inadequate communication generated frustration and mistrust, whereas person-centred care promoted wellbeing and engagement.

Conclusion: Living with complex wounds extends beyond clinical management, profoundly affecting emotional, social, and relational domains. Enhancing care coordination, continuity, specialised training, and person-centred approaches is essential to optimise care and humanise clinical practice.

EP329 The psychological impact of living with chronic leg wounds: a patient-centred perspective

Dr. Mary Collins[1]

[1]*RCSI, European Coaching & Mentoring Council (EMCC), Psychological Society of Ireland (PSI), Dublin, Ireland*

Aim: This evidence piece aims to provide a comprehensive, patient-centred examination of the psychological, emotional, and social impacts of chronic leg wounds, with a focus on excessive wound exudate. It aims to integrate the Biopsychosocial Model, the PERMA-H wellbeing framework, and resilience theory to offer practical, evidence-based strategies for improving psychological support in wound care.

Method: narrative, multidisciplinary review was conducted, drawing on contemporary wound-care literature, psychological research, and clinical guidelines (including EWMA). Qualitative data were gathered through interviews and a focus group with healthcare professionals, alongside patient interviews capturing perspectives on living with chronic wounds. These insights were synthesised with theoretical frameworks to produce an integrated set of recommendations and a psychological triage tool.

Results / Discussion: Findings revealed that chronic leg wounds exert profound psychological and social effects, including shame, depression, social withdrawal, and diminished identity, particularly when associated with malodour, leakage, and persistent pain. The Biopsychosocial Model highlighted the interplay between physical symptoms, emotional distress, and environmental barriers, the PERMA-H framework illustrated how chronic wounds undermine wellbeing across emotional, social, and physical domains. Resilience emerged as a crucial protective factor that can be strengthened through targeted interventions such as autonomy-building, strengths-based reframing, social support, and structured resilience programmes. A traffic-light triage system is proposed to support timely identification and escalation of psychological needs.

Conclusion: To optimise healing and patient wellbeing, wound care must extend beyond physical treatment to include proactive psychological support. Integrating holistic assessment, resilience-building strategies, and structured psychological triage can significantly enhance patient outcomes and quality of life.

EP330 Integrating patient quality-of-life preferences in wound care decision-making

Magali Nys[1], Joost Vankeirsbilck[2]

[1]*Department of Wound Care, Regionaal Ziekenhuis Tienen, Tienen, Belgium*, [2]*Department of General and Abdominal Surgery, Regionaal Ziekenhuis Tienen, Tienen, Belgium*

Aim: To explore how integrating patient quality-of-life (QoL) priorities through shared decision-making influences treatment selection and clinical outcomes in traumatic lower-leg degloving injuries with skin damage extending to the fascia.

Method: This prospective case series included three women aged 69, 83, and 95 years presenting with clinically comparable lower-leg injuries. Within 0–5 days following emergency management, a structured clinician-guided

interview was conducted using predefined QoL domains, including independence, mobility, comfort, hospitalisation preference, social support, and financial capacity. Shared decision-making involved patients, family members and healthcare professionals from community and residential care settings. Treatment decisions were made by balancing clinical indications with patient-defined goals and feasibility of care in the living environment.

Results: Despite similar wound characteristics, QoL priorities differed and guided treatment selection. The 69-year-old patient valued rapid recovery and minimal dressing frequency, leading to surgical flap repositioning followed by negative pressure therapy (healing: 15 weeks). The 83-year-old community-dwelling patient prioritised autonomy and anxiety reduction. Treatment followed an ISTAP category 2 skin tear protocol with flap repositioning and silicone contact layer fixation (healing: 9 weeks). The 95-year-old nursing home resident emphasised comfort and participation in daily activities. Conservative daily wound care with an enzyme alginogel dressing was chosen (healing: 11 weeks). All patients received compression therapy, education on leg elevation, and skin care guidance. Treatment adherence was complete, and wounds healed in alignment with individual QoL goals.

Conclusion: Comparable traumatic wounds may require different therapeutic pathways when patient-defined QoL priorities are systematically integrated into decision-making. A structured shared decision-making approach may enhance adherence while enabling clinically effective, person-centred wound care and may serve as a reproducible framework for integrating QoL into wound management.

EP331 The impact of chronic wounds on patients' daily functioning and well-being

Oliver Jurić[1], Jelena Kevrić[2], Renata Jović[3]

[1]General Hospital Zadar, Zadar, Croatia, *[2]Secondary Medical School Ante Kuzmanic, Zadar, Croatia*, *[3]Zadar, Croatia*

Aim: Chronic wounds can profoundly influence patients' physical well-being, emotional stability, and capacity to engage in everyday activities. By examining these aspects, the analysis aims to capture the broader lived experience of individuals beyond the observable clinical characteristics of the wound. The aim of this study was to evaluate how chronic wounds affect multiple dimensions of health-related quality of life using the Wound-QoL-17 framework.

Method: A cross-sectional study was conducted from January to November 2025, enrolling 50 adult participants with various types of chronic wounds. The Wound-QoL-17 instrument was used to assess physical symptoms, emotional distress, activity limitations, and the broader impact of chronic wounds on routine functioning. Descriptive analyses were performed to identify the most affected domains.

Results / Discussion: Pain was identified as the most burdensome symptom, followed by malodour, sleep disturbances, and movement-related discomfort. The greatest impact occurred in the *Physical symptoms* and *Daily activities* domains, indicating substantial disruption to functional capacity and everyday routines. Participants also reported emotional fatigue, persistent worry regarding wound deterioration, and fear of further injury, reflecting a considerable psychological burden. Chronic wounds negatively affected independence and social participation, with many individuals requiring assistance in performing routine tasks. Long-term therapeutic demands—including frequent dressing changes, scheduled clinical reviews, and prolonged recovery—further contributed to diminished well-being and reduced overall quality of life.

Conclusion: Chronic wounds significantly compromise physical, emotional, social, and functional dimensions of patients' lives. These findings underscore the need for integrated, patient-centred wound care models that incorporate effective symptom management, psychosocial support, and targeted patient education to improve overall quality of life.

EP332 Quality of life: From zero to 101 years-stop the injuries

Francesca Pasquali[1], Alessandra Demartini[1 1], Carmen Rita Rizzella[1]

[1]ASLAL, Alessandria, Italy

Aim: To evaluate the efficacy, safety, and tolerability of autologous skin micrografts in patients with complex wounds and assess their potential to accelerate healing while preserving quality of life. Wound management should prevent social and psychological limitations, ensuring that wounds do not interfere with play, interaction, or daily activities.

Methods: For the first time in Europe, after the favorable outcomes obtained in 13 adult patients, a case study was conducted on 3 pediatric patients with complex wounds of different etiologies. The procedure involved minimally invasive harvesting of autologous skin, mechanical disaggregation, and application of micrografts to the wound bed. Clinical assessment included time to complete healing, peri-procedural pain, need for anesthesia or sutures, postoperative complications, and parent–child involvement through informed consent. Strategies minimized procedural anxiety and discomfort.

Results: Complete healing was achieved within 4–12 weeks. No major complications, immune reactions, or infections occurred. Procedural pain was 0 in all cases, and no sutures were required. In one paraplegic child with a dorsal lesion exposing the spinal column, the procedure was performed without general anesthesia, using only topical lidocaine cream and adhesive closure strips; the patient remained conscious and cooperative. Clinical improvement in all patients was associated with accelerated tissue regeneration, high tissue compatibility, reduced inflammation, and excellent tolerability.

Conclusion: Autologous micrograft technology showed favorable outcomes in pediatric wound management, with complete healing in 4–12 weeks, excellent tolerability, and no major complications. The minimally invasive approach, with zero reported pain and no need for sutures or general anesthesia, supports its potential as a safe, effective therapeutic option to enhance healing and quality of life in pediatric and adult populations.

EP333 Barriers and enablers to the use of patient-reported outcome measures (PROMS) in healthcare: An umbrella review

Stacey Bradshaw[1], Peta Tehan[2], Benjamin Peterson[3]

[1]Monash University, Australian Institute of Lymphoedema, Queensland Health, Rockhampton, Australia, *[2]Monash University, Melbourne, Australia*, *[3]Central Queensland University, Rockhampton, Australia*

Aim: The umbrella review aims to synthesise evidence examining the barriers and enablers which impact on the use of PROMs in healthcare settings.

Method: A robust search strategy was developed, and systematic searches were conducted across five databases (Scopus, Cochrane Library of Systematic Reviews, MEDLINE, CINAHL, and AMED), with additional articles obtained through Google Scholar. This included articles published up to March 2025.

Results / Discussion: A total of 10,490 articles were screened, with 12 meeting inclusion criteria. Themes pertaining to barriers and enablers were identified, including patient factors, health professional factors, infrastructure, value/benefit, tool specific factors, and organisational factors. Key barriers were identified as a lack of time, staff, training, equipment, and organisational support, and being burdensome to patients and health professionals. An additional barrier was that stakeholders failed to derive the intended value from PROMs. Key enablers were identified as organisations addressing these issues through broad consultation in the planning phase, selection of a PROM suitable to the intended population, and ongoing training.

Conclusion: The successful implementation of PROMs in clinical practice is reliant on a robust change management approach which engages stakeholders from the point of inception. Integration of PROMs should be supported by a policy framework that considers the impact on the end user.

EP334 Barriers and enablers to the use of patient-reported outcome measures (PROMS) in wound care

Stacey Bradshaw[1], Peta Tehan[2], Benjamin Peterson[3]

[1]Monash University, Australian Institute of Lymphoedema, Queensland Health, Rockhampton, Australia, *[2]Monash University, Melbourne, Australia*, *[3]Central Queensland University, Rockhampton, Australia*

Aim: To determine the most commonly used PROMs in wound care, and how they are implemented, as well as to describe the barriers and enablers to their use in this clinical area.

Method: A cross-sectional survey was disseminated to wound care clinicians of any professional background around the world via purposive snowball sampling. Survey questions were derived from a systematic review of the literature, and collected data on demographics, clinical practice settings, use of PROMs, and perceived barriers and enablers to PROM use. Descriptive statistics were used to explore the data, primarily frequencies for the categorical data.

Results / Discussion: Of the 115 valid responses, 80% were female, 53% were from a nursing background, 55% had post graduate qualifications, and 88% were from Australia. Community and outpatient services were reported to be the primary workplace for 66% of the respondents, and 97% were involved in chronic wound management. The most significant barriers to PROM implementation were additional workload and time. The key enablers were noted to be PROMs that were quick to administer, easy to score, and involved patient and clinician consultation in the planning phase.

Conclusion: Healthcare professionals working in wound care identified barriers and enablers to PROM implementation that mirror those of the broader healthcare setting. Successful implementation is best supported from an organisational level, with robust, consultative planning and change management processes.

EP484 Experiencies and satisfaction of patients with complex wounds: A phenomenological study using net promoter score (NPS)

Paula Ibañez De Haro[1], Marta Fernandez Ruiz[1], Nerea Bugallo[1], Zohartze Larizgoitia[2], Sendoa Ballesteros Peña[1], Eztizen Miranda Bernabe[3]

[1]Osakidetza, Bilbao, Spain, *[2]Osakidetza, Barakaldo, Spain*, *[3]Bio Bizkaia, Bilbao, Spain*

Aim: The aim was to explore and understand the lived experience of patients and families affected by chronic, complex, hard-to-heal wounds, focusing on their likelihood of recommending services and their satisfaction with care received in both Primary Care and a specialised wound unit. It also sought to evaluate the usefulness of the Net Promoter Score (NPS) as a nursing assessment tool capable of capturing subjective perceptions across care levels effectively.

Method: A qualitative phenomenological study was conducted using purposive sampling between May and October 2025. Thirty-six adults were interviewed in video formats after recruitment from specialised wound units. Verbatim transcripts were analysed around two central themes: satisfaction with treatment and likelihood of recommending the service. Four NPS-based questions (0–10) were applied: recommendation of the specialised wound unit (NPS1), recommendation of the Primary Care centre (NPSA1), satisfaction with treatment in the wound unit (NPS2), and satisfaction with treatment in Primary Care (NPSA2).

Results / Discussion: The mean values (m±SD) reflect this pattern: NPS1 is 9.7±0.7, NPS2 is 9.5±0.8, NPSA1 7.7±2.4 and NPSA2 7.4±2.7. NPS1 reached 92 and NPS2 83, indicating high patient satisfaction and consistently positive experiences. In contrast, primary care scores showed greater variability and lower overall ratings, with NPSA1 at 13 and NPSA2 at 16. Overall, satisfaction with the wound care unit clustered in higher ranges, while primary care experiences showed greater dispersion and heterogeneous perceptions.

Conclusion: The NPS proved valuable in complementing a phenomenological approach, quantifying subjective perceptions and highlighting contrasts between care settings. The findings indicate higher satisfaction and an increased likelihood of recommending the specialised wound unit, emphasising its positive influence on the experience of individuals living with complex wounds.

EP485 Consensus statements for the biopsychosocial care of patients with epidermolysis bullosa South Africa: Part 2

Toni Roberts[1]

[1]*DEBRA South Africa, Cape Town, South Africa*

Aim: To develop comprehensive transdisciplinary consensus statements for the care of patients with EB. This article (Part 2) presents 24 consensus statements focused on the biopsychosocial aspects of EB care. Part 1 addressed diagnostic and clinical management and resulted in 16 consensus statements.

Method: In collaboration with patients and families, the transdisciplinary team of experts developed consensus-based statements through a modified Delphi process. This iterative process involved three consensus rounds with an 80% agreement threshold for each action point to ensure validity and reliability.

Results / Discussion: In total, 24 consensus statements were endorsed. These included holistic patient and family care; cultural considerations; educational inclusion; paediatric and emergency care; psychosocial care; nutritional; gynaecological and ophthalmic support; occupational therapy; physiotherapy and orthopaedic; dental and podiatric management.

Conclusion: Comprehensive transdisciplinary care is essential for addressing the holistic needs of patients with EB and their families, particularly in resource-limited and culturally diverse settings.

Authors: Antoinette V. Chateau, David Blackbeard, Carol Hlela, Martie Wege, Anne Armour, Thirona Naicker, Ncoza Dlova, Serantha Foolchand, Angela Chetty, Sarah Ainsworth, Cassidy-Mae Shaw, Reshmee Lachman, Carl-Heinz Kruse, Kavir Rajkumar, Pieter Mare, Andile Mchiza, Heidi Shanahan, Toni Roberts, Shuaib Kauchali, Colleen Aldous.

EP486 Evaluating and adapting an integrated wound-care service to local population needs: a mixed-methods review

Jennifer MacKey[1]

[1]*Mid Yorkshire Teaching Trust, Wakefield, United Kingdom*

Aim: The author works as a specialist wound-care practitioner covering both primary and secondary care. The local area has a diverse demographic profile: 44.8% of residents identify as Christian, 37.3% have no religion, and 11.5% are Muslim. Unemployment is high, with 70,025 residents currently out of work. Given these factors, the author sought to evaluate the existing wound-care service and innovative ways to meet local needs.

Method: A survey was completed by patients, with detailed tracking of three patients (Figures 1–6). Survey questions addressed factors such as the number of dressing changes per week and the impact of the wound on activities of daily living. Patient satisfaction with the care received was also recorded.

Results / Discussion: Figures 1–6 show the healing progression of the three focus patients, all of whom received honey as the primary dressing.

- Patient 1: (Left above knee amputation site) Patients main issue was pain. (Fig 1 & 2)
- Patient 2: (Right Knee dehisced surgical wound): Faced potential job loss if unable to return to work by Christmas. (Fig 3 & 4).
- Patient 3: (Debridement of left perianal gangrenous tissue) Moved to a downstairs living arrangement due to mobility issues caused by the wound.(Fig 5 & 6)

The questionnaire results showed:

60% of patients rated the service “excellent”.

40% rated the service as “very good”

90% of patients found that their wound had an impact of their activities of daily living.

Conclusion: The survey showed that tailored wound-care support improved patient outcomes, reduced dressing needs, and enhanced quality of life. This highlighted the value of patient feedback in shaping responsive, area-based care.

Fig.1



Fig. 2



Fig. 3



Fig. 4



Fig.5



Fig. 6



SURGICAL APPROACHES

EP489 Clinical utility of multi-layer micronized acellular dermal matrix (mADM) in full-thickness skin grafting for facial defects

Ye-eun Nam[1], Yong Seon Hwang[1], Hwanjun Choi[1]

[1]Plastic and reconstructive surgery, Soonchunhyang Cheonan University Hospital, Cheonan, Korea, Rep. of South

Aim: Acellular dermal matrix (ADM) is conventionally applied in split-thickness skin grafts (STSG), particularly in poorly vascularized beds. However, in well-vascularized areas such as the face, multi-layer application of micronized ADM (mADM) may enhance outcomes in full-thickness skin grafts (FTSG). This study evaluates the clinical and aesthetic utility of multi-layer mADM in facial reconstruction following skin cancer excision.

Method: A retrospective study was conducted at Soonchunhyang University Hospital, Cheonan. 55 patients underwent facial reconstruction after wide excision of skin cancer. 30 patients received FTSG with multi-layer mADM, and 25 received conventional FTSG without mADM. All procedures were performed by a single surgeon. Aesthetic outcomes were assessed from the immediate postoperative period through 6 months, using both patient satisfaction surveys and physician-rated cosmetic scoring.

Results / Discussion: No significant difference in pathologic depth of skin cancer was observed between the groups. However, the mADM group demonstrated superior cosmetic outcomes and higher patient satisfaction throughout the follow-up period. Multi-layer mADM effectively restored soft tissue volume, mimicking local flaps, with layer thickness tailored to the defect's depth and contour.

Conclusion: Multi-layer micronized ADM enhances aesthetic outcomes in FTSG for facial defects, offering a reliable alternative to flaps in select cases. This technique is particularly useful for small to moderate defects with adequate blood supply and clean wound beds, providing flap-like volume without flap-related complications, sush as mushroom deformity.

EP490 One-stage reconstruction of full-thickness alar defects with a folded nasolabial island flap

Ye-eun Nam[1], Hwanjun Choi[1]

[1]Plastic and reconstructive surgery, Soonchunhyang Cheonan University Hospital, Cheonan, Korea, Rep. of South

Aim: The reconstruction of large full-thickness alar defects requires complex surgical procedures that are usually performed in two stages, with concomitant disadvantages in terms of patient trauma, surgical risk, and cost. This study presents a functional folded nasolabial island flap (FNIF) that can be used to repair large-sized full-thickness alar defects in a straightforward manner.

Method: This retrospective study included seven patients who received a FNIF for a full-thickness alar defect between January 2007 and December 2020. The FNIF is different from the conventional nasolabial flap in that it is folded and twisted to achieve nostril reconstruction with a satisfactory three-dimensional mucosal lining in a single stage. The cosmetic and functional results of FNIF were evaluated by both patients and physicians.

Results / Discussion: The age ranged from 51 to 82 years (mean, 65.6 years). The causes of the defects were squamous cell carcinoma, basal cell carcinoma, and trigeminal trophic syndrome. The nostril lining did not collapse, there was no hypertrophic scarring, and air movement through the nostrils on the flap side was normal. Overall, FNIF produced excellent aesthetic and functional outcomes, with minimal patient discomfort. There were no postoperative complications.

Conclusion: Compared with existing reconstruction methods for large full-thickness alar defects, FNIF can easily achieve aesthetic and functional success in a single-stage procedure. It provides satisfactory results for both the patient and the surgeon.

EP335 Surgical approaches for partial breast reconstruction using CWPF

Mohamed Soffar[1]

[1]*Faculty of Medicine Alexandria University, Alexandria, Egypt*

Aim: We report our experience of CWPF in breast reconstruction with surgery details, complications, different locations of the tumor and outcomes.

Method: This was a prospective observational cohort study of patients who had undergone breast conservation surgery (BCS) plus, CWPF reconstruction. A survey was done to analyze patient satisfaction at about 6 months after completion of radiotherapy.

Twenty patients had CWPF based reconstruction in 2 years.

Results / Discussion: 30 % of patients had lateral intercostal artery perforator (LICAP) flap, 5% had lateral thoracic artery perforator (LTAP) flap, 10% had combined LICAP plus LTAP, 30% patients had anterior intercostal artery perforator (AICAP) flap and 25% had thoracodorsal artery perforator flap (TDAP).

Tumor excision cavity defect was of the lateral quadrants in 65%, central quadrant in 10% and medial quadrants in 25% of patients.

No patient had complete flap loss, one patient had partial wound dehiscence, two patients developed surgical site infection, and two patient developed seroma at the donor site. 90% of patients were satisfied with the scar, 100% were comfortable going out in public and regain their life, and 95% were happy with the treated breast in comparison to the opposite breast. and felt that in retrospect their decision not to have a mastectomy was correct.

Conclusion: Partial breast reconstruction using chest wall perforator flaps (CWPF) is an option with very satisfactory results.

EP336 The lateral antebrachial neurocutaneous flap with determining the location of the distal perforator branches of the radial artery for treating hand soft tissue defects

Hien Tran[1]

[1]*Hospital for Traumatology and Orthopaedics, Ho Chi Minh, Viet Nam*

Aim: This study aimed to determine the appropriate distal perforator location of the radial artery as the pivot point of the flap for treating hand soft tissue defects, contributing to the evaluation of this flap's effectiveness in covering hand defects.

Method: The prospective case series study used the lateral antebrachial neurocutaneous flap to identify the appropriate distal perforator location of the radial artery as the pivot point for covering hand soft tissue defects with exposed tendons or bones.

Participants were followed for at least 6 months, the longest follow-up being 29 months. The study was conducted at the Hospital for Traumatology and OrtOrtaedics, Ho Chi Minh City, Vietnam.

Results / Discussion: 33/35 flaps (94.3%) survived. 2/35 flaps experienced distal superficial necrosis. The pivot point was located 4 cm above the radial styloid process (26 flaps), 6 cm above the radial styloid process (9 flaps).

The flap covered in various sides of the hand defects without complications and sequelae in the donor sites and hand wounds.

Conclusion: The lateral antebrachial neurocutaneous flap with determining the location of the distal perforator branches of the radial artery, is a valuable option for covering hand defects without complications and sequelae in the donor sites and hand wounds.

EP337 Clinical outcomes and applicability of serratus anterior muscle flap with split thickness skin graft in thin resurfacing reconstructive surgeries

Youn Hwan Kim[1]

[1]*Department of Plastic surgery, Hanyang University Medical Center, Seoul, Korea, Rep. of South*

Aim: This retrospective study evaluates the efficacy of the serratus anterior muscle (SAm) free flap combined with a split thickness skin graft (STSG) for thin resurfacing in reconstructive surgery, presenting an alternative to pure skin perforator flaps.

Method: A retrospective review was conducted of 18 patients between January 2015 and December 2023.The study cohort comprised 7 women and 11 men, aged 31-80 years, addressing defects caused by infection, malignancy, burn, and trauma, located in various body parts. The research analyzed information related to patient characteristics (age and gender), BMI, etiology and location of the defect, usage of Acellular Dermal Matrix, recipient vessel, dimensions of the flap, pedicle length, operation time, any complications, and the duration of follow-up.

Results / Discussion: Results demonstrated the successful application of the SAm flap in all cases, with an average flap dimension of 38.21 cm2 and pedicle length of 7.3 cm. All the flaps survived successfully without venous congestion. The average operation time was 122.1 minutes. The study underscores the SAm flap's adaptability, versatility, and minimal donor site morbidity.

Conclusion: It concludes that the SAm flap, in conjunction with STSG, is a viable alternative for thin resurfacing in reconstructive surgery. However, limitations such as the small sample size and procedural variability suggest the need for further research to fully establish the flap's potential in diverse surgical contexts.

EP338 Chronic scrotal eczema misdiagnosed for years: Extramammary paget's disease successfully treated with alt island flap reconstruction

Seong Hwan Kim[1]

[1]*Department of Plastic and Reconstructive Surgery, Kangnam Sacred Heart Hospital, Hallym University College of Medicine, Seoul, Korea, Rep. of South*

Aim: Extramammary Paget's disease (EMPD) is a rare intraepithelial adenocarcinoma that often masquerades as chronic dermatitis, leading to significant delays in diagnosis and treatment. This study aims to present a case of long-standing scrotal eczema ultimately diagnosed as EMPD and to describe the diagnostic process and successful surgical management using an anterolateral thigh (ALT) island flap.

Method: A 55-year-old and a 63-year-old male each presented with persistent pruritic erythematous scrotal lesions that had been treated at local clinics for approximately nine and seven years, respectively, without meaningful improvement. Both patients visited our dermatology department in March 2025 due to refractory symptoms. They were subsequently referred to our department in April 2025, where repeat punch biopsies were performed to confirm the diagnosis and evaluate lesion extent. After EMPD was definitively diagnosed in both cases, wide local excision of the affected scrotal skin was planned. Reconstruction was performed using an anterolateral thigh (ALT) island flap to provide durable coverage and maintain functional contour.

Results / Discussion: In both patients, repeat biopsies confirmed non-invasive EMPD without dermal invasion. Each underwent wide excision followed by ALT island flap reconstruction. Postoperative recovery was uneventful, and both patients achieved complete remission and were discharged in good condition. These cases highlight the diagnostic difficulty of EMPD, which can mimic benign chronic dermatitis for years. Persistent or treatment-resistant scrotal eczema should prompt consideration of EMPD, and repeated biopsy may be necessary for accurate diagnosis.

Conclusion: Long-standing, treatment-resistant scrotal dermatitis should raise suspicion for EMPD. Repeated biopsy, accurate diagnosis, and timely surgical excision with flap reconstruction can result in curative outcomes and excellent postoperative recovery.

EP339 Use of dermal matrices as reconstructive option after cutaneous tumor excision

Giuliana Elisabetta Bruno[1], Massimo Rizzo[1], Cristiano Parise[1]

[1]*Università Degli Studi di Torino, Orbassano, Italy*

Background: Dermal matrices are valuable adjuncts in reconstructive dermatologic surgery. These bioengineered scaffolds provide a three-dimensional framework that supports cellular infiltration, neovascularization, and tissue remodeling.

Aim: Evaluate the effectiveness of dermal matrix in patients undergoing surgical excision of cutaneous neoplasms where direct closure was not feasible.

Method: An observational study was conducted on 18 patients selected according to age, comorbidities, tumor size, and location. Mean age was 77.8 years (range 66-88), with mean defect size of 28.5 cm^2 (range 4-120). Histology included 12 basal cell carcinomas and 6 squamous cell carcinomas, classified as pT1 (11), pT2 (6), and pT3 (1). Lesions were mainly located on the lower limb (14 cases). Patients presented multiple comorbidities, including rheumatoid arthritis, scleroderma, severe psoriasis, renal neoplasms, chronic lymphocytic leukemia, coronary artery disease, atrial fibrillation, chronic renal failure, dialysis, and severe obesity. **Procedure:** Tumor excision followed by reconstruction with a double-layer porcine collagen dermal matrix. In 8 patients, partial coverage with a sliding flap was added. Follow-up performed at 5 and 10 days, then weekly until closure.

Results / Discussion: Early matrix detachment occurred in one patient with scleroderma, who healed by secondary intention. Four patients required reapplication of the matrix; one case, partial re-epithelialization was evident at removal. Dermal matrix use provided effective pain control and rapid re-epithelialization. Fourteen patients healed within 10 weeks, while 4 with larger defects required a second application - healed within 20 weeks. No local or systemic infections were observed, and scar outcomes were satisfactory without hypertrophy.

Conclusion: Dermal matrices represent a reliable reconstructive option after tumor excision, reducing donor site morbidity, facilitating wound healing in difficult anatomical regions, and improving cosmetic outcomes.

EP341 SVF from adipose tissue in hard-to-heal wounds

Giuliana Elisabetta Bruno[1], Massimo Rizzo[1], Cristiano Parise[1]

[1]*Università Degli Studi di Torino, Orbassano, Italy*

Aim: evaluate efficacy of autologous SVF in promoting tissue regeneration in non-healing lesions. SVF (stromal vascular fraction) from adipose tissue contains a heterogeneous mix of cells, including adipose-derived stem cells, releasing factors that reduce inflammation, promote healing, and stimulate angiogenesis.

Method: A pilot study was conducted between January and October 2025 on 10 patients with chronic ulcers: venous (6), mixed (1), and sclerodermic (2), all persisting for more than six months with poor progression. The mean age was 69 years (range 50–87), and the mean initial lesion area was 38.1 cm^2 (range 10–72).

Patients underwent lipoaspiration under local anesthesia. SVF was harvested using a dedicated kit, processed by microfiltration (120 nm) and centrifugation, then purified and infiltrated peri- and intralesionally after debridement. A porcine-derived collagen dermal substitute was applied as scaffold.

Data**:** Weekly measurements were performed at baseline, 4 weeks, and 8 weeks.

Results / Discussion: Healing occurred in 2 patients, while 8 showed improvement. Minor adverse events included one abdominal wall hematoma and one case of perilesional erythema with early matrix detachment. After 4 weeks, 8 patients demonstrated significant reduction in lesion area (mean 17.8 cm^2, range 2–40), while 2 showed no change. At 8 weeks, 2 patients were healed and the remaining 8 had marked reduction (mean 5.6 cm^2, range 0.25–16).

SVF infiltration, rich in mesenchymal cells and growth factors, promotes tissue regeneration by modulating inflammation and stimulating neovascularization. The time required for granulation varies among patients and may take weeks; delayed response should not be considered treatment failure.

Conclusion: This minimally invasive approach demonstrated accelerated healing and re-epithelialization with few side effects in hard-to-heal lesions.

References:

Hy-tissue SVF®

EP491 Abdominal wall reconstruction: Literature review and algorithm proposal

Dimas Milcheski[1], Rafael Santos Jr[1], Vitor Patriota[1], Flávia Viana[1], Rolf Gemperli[1]

[1]Faculty of Medicine, University of São Paulo, Sao Paulo, Brazil

Aim: To review anatomical, clinical, and technical factors influencing abdominal wall reconstruction and to propose a structured algorithm integrating literature evidence and institutional experience for managing complex abdominal wall defects.

Method: A narrative literature review was conducted using PubMed, SciELO, and EMBASE, including studies published from 2018 onward. Search terms included “abdominal wall reconstruction,” “abdominal wall anatomy,” “myocutaneous flap,” and “surgical flaps.” Classic anatomical references were consulted for foundational concepts. Evidence on nutritional status, perioperative risk, and the role of negative-pressure wound therapy (NPWT) was incorporated. An institutional algorithm was developed combining literature findings with the experience of a Brazilian reference center.

Results / Discussion: Abdominal wall defects result from incisional hernias, trauma, infection, or oncologic resection and require individualized planning based on defect origin, size, patient comorbidities, and tissue availability. Nutritional impairment, obesity, and hypoalbuminemia increase the risk of postoperative complications, including infection, delayed healing, and mortality. When primary closure is not feasible or clinical instability contraindicates immediate reconstruction, NPWT functions as an effective bridge therapy. Meta-analyses demonstrate reduced surgical-site infection (RR 0.512) and dehiscence (RR 0.581), as well as shorter hospital stay and lower readmission rates with NPWT. Definitive reconstruction options include primary closure, local or regional flaps, component separation, mesh reinforcement, and microsurgical free flaps, selected according to defect depth, extent, and anatomical region. The proposed algorithm stratifies defects into partial and full-thickness and guides reconstruction based on anatomical location and available tissues.

Conclusion: Abdominal wall reconstruction remains a complex surgical challenge requiring multidisciplinary management, precise anatomical understanding, and careful patient optimization. The integration of NPWT, appropriate flap selection, and structured decision-making algorithms contributes to improved outcomes and reduced complications.

EP342 Intact acellular fish skin graft placement after bone resection for limb salvage

Mary Bridge[1], Garismar Ramirez[1], John Lantis[1]

[1]Icahn School of Medicine at Mount Sinai, New York, United States

Aim: To evaluate the utility of placing intact fish skin graft in the foot after removing infected bone in limb salvage cases.

Method: Patients who were identified with osteomyelitis that were going to undergo primary bone resection and closure over that wound were enrolled longitudinally. All patients were treated in the operating room with regional or general anesthesia. All patients had perioperative antibiotics tailored to the residual bone margin pathology. All patients underwent a single stage surgical incision and removal of the infected bone(s). Fenestrated intact fish skin graft was then rolled and placed into the defect left by the excised bone. The primary incision was closed with vertical mattress nonabsorbable suture. Negative pressure was not employed

Results / Discussion: We present postoperative post-operative radiographs and MRIs of 3 of 13 patients treated in this manner. All 13 patients went on to complete healing over the course of 8 weeks. Interestingly digit and foot length was maintained with this technique. No patient required repeat bone resection or additional surgical intervention for infection control. These outcomes suggest that adjunctive acellular fish skin graft placement may help stabilize the post-resection environment, supporting soft-tissue regeneration and preventing infection. In some radiographs what appears to be bony replacement of the margins of the fish skin can be seen.

Conclusion: The preserved extracellular matrix structure and omega-3–rich lipid content of the fish-skin graft may contribute to angiogenesis, modulation of local inflammation, and enhanced cellular ingrowth, which are mechanisms that may be especially beneficial following osseous resection in contaminated or compromised fields. The fact that digital and foot length is maintained even at 16 weeks post resection is notable.

EP343 The absence of basement membrane in overlapped acellular dermal matrix promotes tissue integration

Jun Ho Lee[1]

[1]*Yeungnam University, Daegu, Korea, Rep. of South*

Aim: In implant-based breast reconstruction (IBBR), acellular dermal matrix (ADM) is commonly used for implant coverage and volume supplementation. Overlapping of ADMs often occurs, but the impact of the basement membrane (BM) on tissue integration in this context remains unclear. Therefore, this study aimed to histologically evaluate how BM presence affects long-term tissue integration in overlapped ADM constructs using a mouse model.

Method: Forty-eight rats were randomly assigned to three groups: single-layer ADM with BM facing the implant (G1), overlapped ADM with BM retained between layers (G2), and overlapped ADM without BM between layers (G3). Silicone–ADM constructs were implanted subcutaneously, and histological analyses were conducted at 3- and 6-months post-implantation to assess host cell infiltration, angiogenesis, immune response, and extracellular matrix (ECM) retention.

Results / Discussion: At 6 months, G3 demonstrated significantly enhanced vessel formation and myofibroblast infiltration in both outer and inner ADM layers compared to G2. Immune cell infiltration ($F4/80^+$ macrophages and $CD3^+$ T cells) was also elevated in G3 at 3 months, but became comparable across groups by 6 months. ECM components, including collagen type I and elastin, were better preserved in the inner layer of G3 than G2, which showed signs of ECM degradation.

Conclusion: In overlapped ADMs, eliminating the BM between layers enhances host cell infiltration and ECM retention, supporting improved tissue integration. Although further clinical studies are warranted in IBBR, these findings suggest potential benefits, such as reducing complications and improving patient satisfaction.

EP344 A novel functional excision strategy with a posterior thigh “book-cover” flap for complex medial thigh lymphedema defects

Uzay Cambaz[1], Okan Gürsoy[2], Tahsin Acartürk[1]

[1]*University of Pittsburgh, Pittsburgh, United States*, [2]*Istanbul University, Istanbul Faculty of Medicine, Istanbul, Türkiye*

Aim: To present a novel surgical method for massive localized lymphedema (MLL) of the medial thigh using a functional excision combined with a posterior thigh fasciocutaneous “book-cover” flap designed to achieve tension-free closure and minimize wound complications.

Method: Patients with medial-thigh MLL unresponsive to conservative therapy underwent single-stage excision and reconstruction using a posteriorly based fasciocutaneous flap. Eleven patients were treated (7 unilateral, 4 bilateral), totaling 15 operated extremities; bilateral procedures were staged six months apart. In 13 extremities, adjunctive liposuction was performed to debulk fibrotic adipose tissue and facilitate soft-tissue mobilization. The mass was

mobilized with the legs abducted, incorporating the anterior and medial components into the excision while preserving the posterior component as the planned flap. A bimanual "cracking" technique allowed controlled separation while maintaining deep fascia and selected subcutaneous planes to protect lymphatic and neurovascular structures. The flap was designed to mirror the dimensions of the resected tissue, enabling advancement in a book-cover fashion for complete closure without excessive tension. Resected tissue was examined histopathologically.

Results / Discussion: All patients reported improvements in mobility, hygiene, and overall quality of life. No flap necrosis, wound dehiscence, infection, or major wound complications occurred. Thigh contour and skin texture were preserved without deformity. During long-term follow-up, no recurrence of lymphedema was observed, and no cases of malignancy, including angiosarcoma, were identified in the excised specimens or operative sites.

Conclusion: This novel combination of functional excision and posterior thigh "book-cover"-flap reconstruction provides a safe, reliable, and anatomically favorable approach for managing complex medial-thigh MLL defects. The method offers tension-free closure, reduces wound morbidity, and maintains contour, representing a valuable alternative to traditional elliptical excision techniques.

EP345 The ovine forestomach matrix: A preliminary experience

Roberta Carpenito[1], Carlotta Scarpa[1], Franco Bassetto[1]

[1]Plastic and Reconstructive Unit, Padova, Italy

Aim: In order to verify the safety and efficacy of the ovine forestomach derived matrix in the treatment of post-oncological excision.

Method: We selected 30 patients, ranging in age from 30 to 95 years old, affected by post-oncological excision. All patients have been treated with ovine forestomach derived matrix 5x5 cm wet by saline and covered with an antiadherent dressing as secondary dressing.

We checked the patients after one week and, if necessary, we performed the same kind of dressing every week for a month waiting for histologic analysis.

Results / Discussion: In our study all the lesions have been skin grafted except 2 cases in which we obtained a spontaneous rehepitelization. We obtained a well-vascularized neodermis after one application, also with exposed structures. In 1 case after 10 days, we noticed partial detachement of the dermal matrix on the forearm due to haematoma, which was evacuated. No other complications have been described.

Conclusion: The ovine forestomach derived matrix can be a good choice in the treatment of postoncologic excision. We didn't notice any adverse events and the dressing procedure has been easy and unpainful for the patient.

EP346 Acellular fish skin graft versus full thickness skin graft: A comparative study of oculofacial reconstructive outcomes

John Nguyen[1], Galaxy Desire[1], Molly Shott[1], Peyton Powroznik[1], Diane Wang[2], Vlad Codrea[1]

[1]West Virginia University, Morgantown, United States, *[2]Emory University, Atlanta, United States*

Aim: To compare the outcomes for patients with oculofacial skin cancer resection receiving either acellular fish skin graft (FSG) or full-thickness skin graft (FTSG) for reconstruction.

Method: A retrospective chart review was performed on patients treated with FSG or FTSG for oculofacial reconstruction between January 2022 and October 2025. Demographics, smoking and diabetes status, diagnosis, defect location, graft size, and complications were evaluated. Outcomes were analysed using the Scar Cosmesis Assessment and Rating (SCAR) scale.

Results / Discussion: 20 patients had repairs using FTSG while 10 patients had FSG. Mean age was 70.9 ± 13.4 years in FTSG and 66.1 ± 12.7 years in FSG. 30% of patients were female in FTSG while 50% were female in FSG. Indications included: BCCA, SCCA, melanoma, and trichoepithelioma. Location of defects included eyelid (50% in FTSG and 30% in FSG), canthus (45% in FTSG and 30% in FSG) and eyebrow (5% in FTSG cases and 40% in FSG). Average defect size were 762.4mm2 FTSG and 504.9mm2 in FSG group. Body mass index were 27.6 in FSTG and 29.5 in FSG, and type II diabetes were present in 30% for both groups. Smoking was in 15% in FTSG and 30% in FSG. 20% of FSG had more than one application of FSG graft. No post-operative complications were seen, and all had good wound healing and cosmetically acceptable results.

Conclusion: Acellular FSG are shown to be promising skin graft substitutes in patients (including those who are diabetic and smokers) with oculofacial defects with no donor site morbidity and admissible cosmetic outcomes and functional recovery.

EP347 The effects of autologous punch-grafting on hard-to-heal wounds management: A systematic review

Tannaz Faregh[1]

[1]*Tehran University of Medical Sciences, Tehran, Iran*

Aim: This study aims to illustrate holistic aspects of punch-graft using in management of chronic hard-to-heal wounds through reviewing updated evidence.

Method: A literature search was conducted in the databases EMBASE, MEDLINE, and SID besides Google Scholar search engine with proper terms/keywords in both English and Persian languages for period between January 2020 and January 2025. This review included all abstract-available articles which investigated all punch-graft types effects on nonhealing wounds but case reports, commentaries, letters to editor, non-English/Persian studies, articles assessed punch-graft effects in combination therapy with other treatments, and studies on atypical wounds or dermatological lesions without ulcers were omitted. The Preferred Reporting Items for Systematic Reviews and Meta-analyses 2020 (PRISMA) guidelines were followed.

Results / Discussion: Finally, 9 eligible studies were included which were prospective, quasi-experimental studies, randomized-controlled trials, retrospectives and cohorts. The different methods using in studies were micro-punch, hair-follicle containing, and typical ones. This technique was assessed mainly in patients with venous, diabetic, and post-operative ulcers also there were scare studies on Martorell, traumatic, and arterial wounds. punch-grafting effects on hard-to-heal wounds are categorized in 4 scopes: 1.Wound healing(decreasing area/volume of wounds, promoting restoration of stratified layers and critical dermal-components, and dampening inflammatory-response)- 2.Complications(reducing pain, opioid consuming, scar formation, risk of infection as compared to conventional methods)- 3.Patients' experience(high satisfaction rate, enhanced life-quality but not significantly)- 4.Cost-effectiveness(reducing treatment-sessions and hospitalization, cheaper than usual care).

Conclusion: punch-grafting should be considered over usual care for early treatment of painful and nonhealing chronic wounds as a promising, convenient and usable method even in outpatient settings. Although, conducting further randomized-clinical trials to make comparison between punch-grafting and other interventions is recommended.

EP348 Management of hard-to-heal wounds using autologous punch-grafting: A case-series

Tannaz Faregh[1], Reza Ghorbani[2], Sarah Parsaei[3]

[1]Tehran University of Medical Sciences, Tehran, Iran, *[2]Cardiff university, Karaj, Iran*, *[3]Alborz University of Medical Sciences, Karaj, Iran*

Aim: This study aimed to evaluate the effects of punch-grafting in management of chronic hard-to-heal wounds.

Method: This study involving 4 patients with chronic hard-to-heal wounds (2 stage3-pressure injuries (PI) and 2 neuro-ischemic diabetic foot ulcers (DFU)) treated with punch-grafting was conducted 2023-2025. Inclusion criteria were male/female patients aged >18y with chronic nonhealing wounds which were not responded to conventional treatment more than 6 months and exclusion criteria were local infection, untreated osteomyelitis, and critical ischemia.

All wound beds were prepared using sharp-surgical and autolytic debridement along with vacuum-therapy. Then, wounds were grafted with 4mm-punches from the donor site (anterolateral aspect of the thigh). The first 4 dressing-changes carried-out every 3days. The both donor and grafted wounds were covered with Alginate and absorbent dressings according to wound-exudate. Subsequent to this 12day period, all patients were followed up weekly until wound healing (defined as complete epithelization without any drainage confirmed at least 10 days after closure) occurred.

Results / Discussion: All patients included in this study were men with chronic nonhealing wounds for more than 1 year. Using punch-grafting technique was successful in adhering and complete re-epithelization was achieved for all of them in 3-4 weeks. Wound area reduction (WAR) was roughly 40% at 4-weeks. Donor-site healed within 15-18days. No adverse-effects were registered through the follow-up period.

Conclusion: Although autologous punch-graft is an easy procedure in outpatient settings that enhances healing process and reduce wound-closure time in chronic hard-to-heal wounds and can be considered as an alternative method instead of unsuccessful conservative treatment, further research with high-quality methodologies is still needed to confirm the potential benefits of this procedure.

EP349 Chemical debridement of necrotic tissue accelerates systemic recovery in severe diabetic foot infections: Exploratory comparative evidence for a paradigm shift in wound management

Hikmet Erhan Güven[1], Lara Kavasoğlu[1]

[1]University of Health Sciences, Ankara Etlik City Hospital, General Surgery Chronic Wounds and Diabetic Foot Department, Ankara, Türkiye

Aim: To assess whether a topical desiccating agent (TDA; DEBRICHEM) can accelerate systemic recovery in patients with severe diabetic foot infections, including necrotizing fasciitis, by rapidly reducing necrotic tissue burden and disrupting biofilm.

Method: An observational comparative cohort study included 86 patients with severe diabetic foot infections (TDA n=18, excluding one unrelated mortality; controls n=68). All patients received standard surgical and medical management. In the TDA group, DEBRICHEM was applied intraoperatively to chemically debride necrotic tissue. Systemic biomarkers—LRINEC score, C-reactive protein (CRP), and blood glucose—were recorded at baseline and during follow-up (Days 0, 7, 14, and 21). Outcomes were compared descriptively between groups.

Results / Discussion: Baseline severity was comparable across groups. TDA-treated patients demonstrated more rapid systemic stabilization: LRINEC scores decreased by over 3 points within 7 days, compared with <2 points in controls. CRP levels decreased by ~50% by Day 7 and approached near-normal levels by Day 21, whereas controls remained elevated (>100 mg/L). Despite presenting with higher initial hyperglycemia, TDA patients achieved near-normal glucose levels by Day 21, in contrast to controls, who remained dysregulated. These findings suggest that

chemical desiccation of necrotic tissue and biofilm may interrupt the pathophysiological cycle driving severe DFU progression, offering a mechanistically distinct alternative to standard sharp debridement.

Conclusion: This exploratory evidence indicates that TDA may accelerate systemic recovery in severe diabetic foot infections, including necrotizing fasciitis. By rapidly collapsing necrotic tissue and biofilm, TDA appears to modify infection trajectories and improve inflammatory and metabolic parameters. Larger controlled studies are warranted to confirm these transformative clinical implications.

EP350 Is there a correlation between time since presentation of foot ulcers and ulcer healing after minimally invasive metatarsal osteotomies?

Nermine Habib[1], Dino D'Errico[1]

[1]*Swiss Diabetic Foot Centers GmbH, Fribourg, Switzerland*

Aim: Foot ulcers have devastating complications such as amputations but also a substantial clinical and economic burden. Minimally invasive metatarsal osteotomies (DMMO) have shown to be an effective method for treating recalcitrant ulcers under metatarsal heads (MTH).

The aim is to evaluate if healing time after DMMO is correlated to duration since presentation of foot ulcers.

Method: In a prospective study, n= 10 patients presenting with plantar grade 1A or 2A according to the Wagner and Armstrong Classification were included. The time since presentation varied in all of the cases: 2 weeks (recurrent ulcer), 2 months, 6 months and over 2 years. The ulcers were of the same size but with different thickness.

Three patients with neuropathic ulcers and one with a diabetic foot ulcer. Eight were MTH 5 ulcers, one MTH4 and one MTH3

An MRI was performed in all of the cases and signs of osteomyelitis were not seen.

Results / Discussion: All ulcers recovered with an average healing time of 12.3 days (range, 10-14) days since surgery. No acute complications were recorded.

Conclusion: Even though the study is limited by the small number of cases, it nevertheless demonstrated that the time since presentation of the ulcer is not correlated to the healing time after DMMO.

EP351 A minimally invasive revolution: Safety and feasibility of an outpatient mis model for diabetic foot disease

Nermine Habib[1], Dino D'Errico[1]

[1]*Swiss Diabetic Foot Centers GmbH, Fribourg, Switzerland*

Aim: Diabetic foot complications - including diabetic foot ulcers (DFUs), diabetic foot osteomyelitis (DFO), and Charcot neuroarthropathy - are major contributors to morbidity and lower-limb amputations, with substantial clinical and economic burden. Minimally invasive surgery (MIS) has emerged as a limb-preserving strategy that reduces soft-tissue trauma, postoperative infection risk, and recovery time, offering particular benefits in diabetic patients with impaired wound healing. This study evaluates the safety, feasibility, and early outcomes of MIS procedures performed in diabetic patients treated in a Swiss foot-surgery clinic.

Method: Between 2023 and 2025, 96 diabetic patients were managed, of whom 91 underwent MIS in an outpatient setting. Procedures included minimally invasive metatarsal osteotomies (DMMO/DMOO), percutaneous flexor and extensor tenotomies, proximal phalanx osteotomies, interphalangeal arthrodeses, percutaneous Achilles tenotomies, and osteophyte removal for recurrent pressure ulcers or Charcot-related deformities. Outcomes assessed were postoperative complications, weight-bearing ability, ulcer evolution, and time to functional recovery.

Results / Discussion: MIS procedures were well tolerated, with low postoperative complication and infection rates. Most patients achieved immediate or early weight bearing, demonstrating faster recovery compared with traditional open surgery. MIS provided effective offloading and deformity correction, supporting ulcer healing and reducing recurrence. These findings align with existing evidence favouring MIS for diabetic foot disease with lower complications compared to open surgery.

Conclusion: MIS appears to offer significant advantages for diabetic patients, enabling earlier mobility, faster recovery, and low complication rates. These early results support MIS as a promising limb-preserving approach for deformity, pressure lesions, and recalcitrant ulcers. Larger studies are needed to determine long-term outcomes and refine patient-selection criteria.

EP492 Retrograde laser access to pathologic veins in patients with venous ulcers

Ismayil Asgarov[1]

[1]Olimp Hospital, Baku, Azerbaijan

Aim: Venous ulcer is one of the most common chronic wounds of the lower extremity. In standard treatment, endovenous laser ablation (EVLA) performed through an antegrade approach is frequently preferred. However, in certain anatomical situations, retrograde access may provide advantages in terms of procedural ease and faster wound-healing rates. This study evaluates the clinical effectiveness of the retrograde approach.

Method: A total of 37 patients with venous ulcers, aged between 47 and 76 years, were included in the study. 28 were female and 9 were male. Ulcer sizes ranged from 1 to 7 cm. Distribution of ulcer location: 24 patients had ulcers located at the distal one-third of the tibia, 5 patients had ulcers involving both the distal and middle one-third, 8 patients had lesions spreading over a 4-cm area. Additionally, 6 patients had infected wounds. Retrograde EVLA was performed in 21 patients, while 16 patients underwent only antegrade intervention.

Results / Discussion: Patients who underwent retrograde EVLA experienced significantly less postoperative pain. Moreover, wound-healing time was faster compared to the antegrade group. The procedure was technically easier and associated with low complication rates.

Conclusion: For patients with distally located venous ulcers, retrograde EVLA into the pathologic vein is a safe, comfortable, and effective alternative to the standard antegrade approach.

EP493 Osteo-distraction angiogenesis added to revascularization in ischemic foot wounds: A meta analysis and systematic review

Nitish Thirugnanasambandam[1], Arthur Tarricone[1], Lawrence A. Lavery[1], Joseph Alderete[1], Allen Gee[2]

[1]University of Texas Health San Antonio, San Antonio, United States, *[2]Mount Sinai Morningside, New York, United States*

Aim: Peripheral Arterial Disease is one of the main factors that contributes to poor healing and leg amputation. Often revascularization is sub-optimal. Gavriil Illizarov was a Soviet surgeon that developed an external fixation system (distraction osteogenesis technique) in 1951 to increase osteogenesis and angiogenesis to treat complex fractures. The technique uses distraction of an osteotomy to increase system stem cells and angiogenic growth factors. Osteo-distraction (ODA) angiogenesis is a novel option to stimulate angiogenesis as an adjunct to revascularization that has only been reported in papers from the People Republic of China. Our aim was to evaluate clinical outcomes in patients treated with ODA plus revascularization versus revascularization alone.

Method: We completed a meta-analysis of English and Chinese papers (N=326 subjects). We extracted pain scores, wound healing, and amputation rates. Random-effects models were applied, with continuous outcomes pooled as mean differences and dichotomous outcomes as odds ratio, each with 95% confidence intervals. Heterogeneity was assessed with I^2. All analysis was performed in RevMan 5.4

Results / Discussion: Four studies were included in our study. For each outcome, three of the four studies provided usable data for pooling. ODA combined with revascularization resulted in greater pain reduction (MD -1.64[-1.73, -1.55]), higher odds of wound healing (OR 3.25[1.84, 5.73]), and lower odds of amputation (OR 0.42[0.20, 0.91]) compared with revascularization alone. Heterogeneity was low across all pooled outcomes.

Figure 1 (Analysis 1.1)

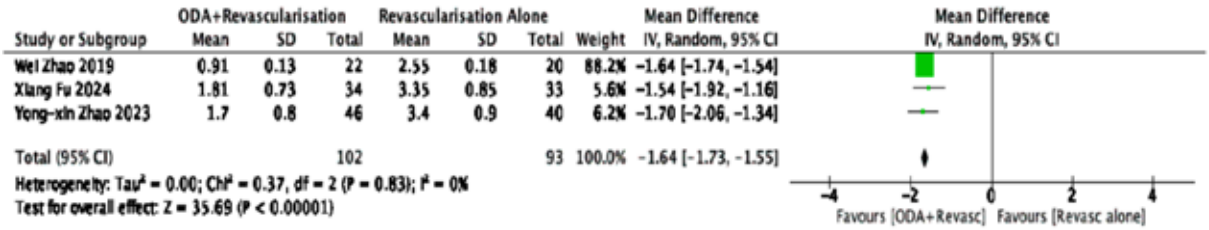

Caption

Forest plot of comparison: 1 Osteo-Distraction+Revascularisation vs Revascularisation Alone, outcome: 1.1 Pain (VAS).

Figure 2 (Analysis 1.2)

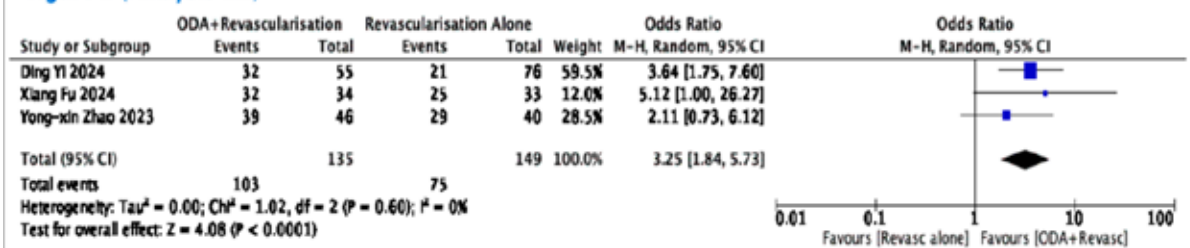

Caption

Forest plot of comparison: 1 Osteo-Distraction+Revascularisation vs Revascularisation Alone, outcome: 1.2 Wound healing.

Figure 3 (Analysis 1.3)

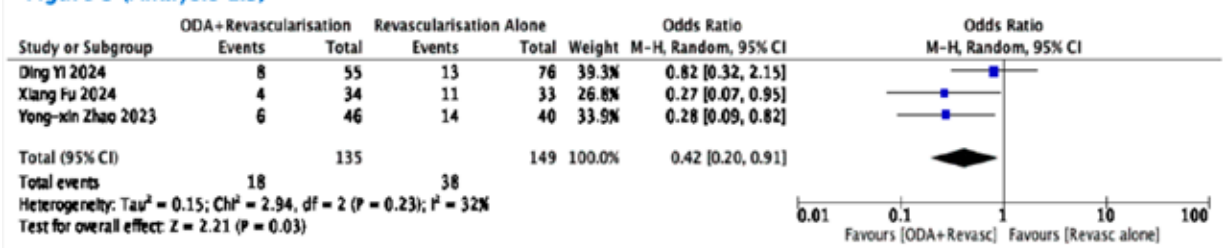

Caption

Forest plot of comparison: 1 Osteo-Distraction+Revascularisation vs Revascularisation Alone, outcome: 1.3 Amputation.

Conclusion: Combining osteo-distraction angiogenesis with revascularization may provide clinical benefits, producing better pain control, higher healing rates, and few amputations.

EP353 Periosteal distraction angiogenesis to treat non-healing foot ulcers: A meta analysis and systematic review

Arthur Tarricone[1], Lawrence A. Lavery[1], Joseph Alderete[1], Nitish Thirugnanasambandam[1], Allen Gee[2]

[1]University of Texas Health San Antonio, San Antonio, United States, [2]Mount Sinai Morningside, New York, United States

Aim: Periosteal Distraction Angiogenesis (PDA) promotes angiogenesis by controlled periosteal elevation. This technique has been used by oral surgeons to increase osteogenesis to treat bone defects in the mandible and forehead. Recently, Chinese surgeons have used the technique to increase angiogenesis to heal foot ulcers. Existing studies suggest postoperative gains in perfusion and symptoms. To evaluate pre- to post-operative changes in pain, temperature and Ankle Brachial Index (ABI) after PDA in patients with non-healing lower-extremity ulcers.

Method: A literature search of PubMed, Embase, Scopus and the Cochrane Library was conducted in accordance with PRISMA guidelines. Studies were included if they reported extractable paired pre- and post-operative outcomes after PDA in patients with non-healing lower extremity ulcers in English or Chinese. Outcomes extracted included wound healing, pain, skin temperature and ABI. Data were extracted and independently reviewed by two reviewers. Continuous outcomes were pooled using random-effects analysis. Mean differences were calculated for each endpoint, and heterogeneity was assessed with I^2. All analysis was performed in RevMan 5.4.

Results / Discussion: Four studies met criteria and included a total of 124 patients. All studies reported a high proportion of healed wounds. Mean proportion of healed ulcers was 96.83%. Pain, skin temperature and ABI were the only outcomes with extractable paired data across at least three studies and were eligible for pooling. PDA significantly reduced pain (MD -4.76 [-5.03, -4.50]), increased skin temperature (MD 4.07 [3.01,5.12]) and improved ABI (MD 0.17 [0.03,0.32]).

Figure 1 (Analysis 1.1)

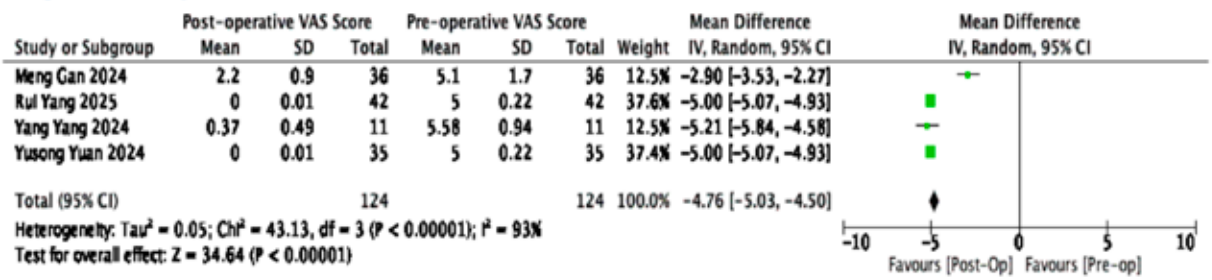

Caption

Forest plot of comparison: 1 Post-operative vs Pre-operative outcomes after Periosteal Distraction, outcome: 1.1 Pain (VAS).

Figure 2 (Analysis 1.2)

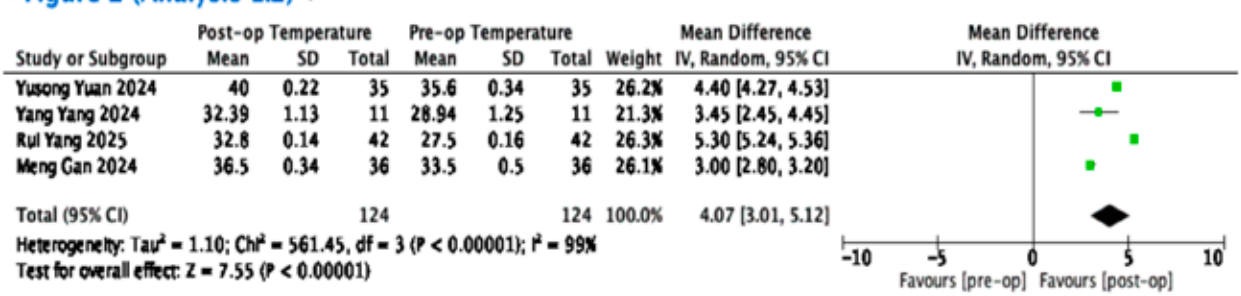

Caption

Forest plot of comparison: 1 Post-operative vs Pre-operative outcomes after Periosteal Distraction, outcome: 1.2 Temperature.

Figure 3 (Analysis 1.3)

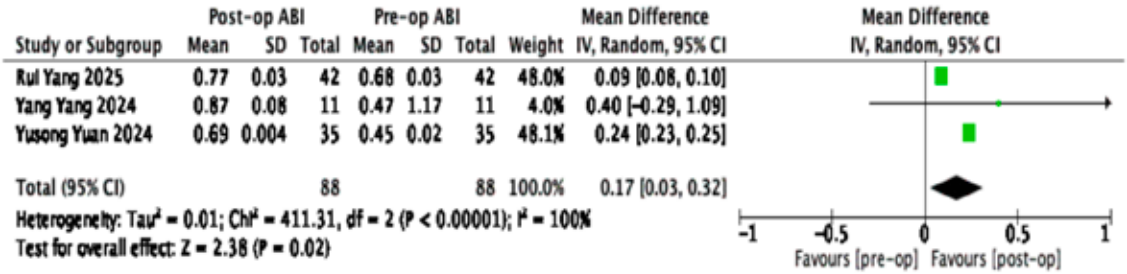

Caption

Forest plot of comparison: 1 Post-operative vs Pre-operative outcomes after Periosteal Distraction, outcome: 1.3 Ankle Brachial Index (ABI).

Conclusion: PDA is a novel approach to improve ulcer healing. PDA produced meaningful improvements in symptoms and perfusion parameter among patients with non-healing ulcers. All studies reported a high proportion of healed wounds.

EP494 Improving healing in breast oncologic, plastic and reconstructive surgery: Outcomes with an oxygen enriched interactive dressing, a multicenter prospective study

Giuseppe Guarro[1], Romano Maffia[1], Nicolò Luraschi[1], Marino Cordellini[1], Cesare Magalotti[2]

[1]Department of Plastic and Reconstructive Surgery, USL Umbria 1, Perugia, Italy, *[2]Breast Unit, Azienda Sanitaria Territoriale, Pesaro Urbino, Italy*

Aim: Authors describe effectiveness of an oxygen-enriched, oleic-based interactive dressing in enhancing postoperative healing, reducing complications, and improving patient-reported outcomes across oncoplastic and post-bariatric breast surgery.

Method: A prospective comparative study including 512 patients (376 oncoplastic procedures and 136 post-bariatric reduction/mastopexy surgeries) was performed between 2021 and 2024 in two Italian centers. Each patient received a traditional dressing on one breast and an interactive dressing on the other. Outcomes assessed included wound-healing progression (planimetric analysis), pain (VAS), infection rate, scar quality (POSAS), and patient satisfaction (BREAST-Q). Statistical significance was set at $p<0.05$.

Results / Discussion: The interactive dressing showed faster healing, with 85.1% of treated sites achieving full re-epithelialization by week 4 versus 57.4% with traditional dressings. Pain reductions were noted at day 7 (–28%) and day 30 (–44%). Infection rates were lower with the interactive dressing (2.4% vs 8.2%). POSAS assessments demonstrated superior pigmentation, relief, and pliability. BREAST-Q scores indicated consistently higher satisfaction relating to comfort, scar appearance, and overall postoperative experience. Results were homogeneous across both surgical groups, suggesting broad applicability of the oxygen-enriched microenvironment.

Conclusion: The interactive dressing improved healing dynamics, reduced pain and infection risk, and enhanced patient satisfaction in both oncoplastic and post-bariatric breast surgery. These findings support its integration into modern breast surgery wound-care protocols.

EP354 Regenerative medicine and the strategic role of wound care nurses: The experience of a highly specialized center

Stefania Chiarenza[1], Maria Teresa De Rose[1], Beatrice Mosca[1], Stefano Ghislanzoni[1], Maria Castoldi[1], Simone Toscano[1], Francesca Misto'[1], Francesca Turrini[1]

[1]Istituti Clinici Zucchi Di Monza, Monza E Brianza, Italy

Aim: Chronic and hard-to-heal wounds are a significant challenge for wound care professionals. Regenerative medicine represents a valuable resource to promote rapid healing or significant reduction of the wound area. Wound Care Nurses (WCNs) hold a central role: they are responsible for wound bed preparation, identification of candidates for intervention, post-operative follow-up and evaluation of tissue evolution.

Method: Our multidisciplinary team (surgeons and nurses with advanced competencies in wound care and regenerative medicine) has developed a treatment pathway for patients with hard-to-heal wounds. They both identify eligible patients for intervention, and the surgeon proceeds with the application of dermal substitute (following debridement if necessary). The patient is hospitalized for 3 days, and the nurse monitors the application site to detect possible complications (infection, early degradation). After discharge, WCN monitors the application site twice weekly.

During 2024, 930 patients were taken into care, of which 488 followed this protocol. Inclusion criteria included: chronic wounds, extensive wounds, cavitary or difficult-to-heal wounds, as well as lesions of neoplastic origin (following excision and histological results).

Results / Discussion: The success rate of regenerative medicine was 89%: complete healing in 53% of cases and reduction of wound area ≥80% in an additional 36%. WNCs identified early signs of infection in 6% of cases, allowing for timely treatment. Additionally, they identified the possibility of early removal resulting in optimization of treatment timelines. Reducing healing times allowed reduction of management costs and improved patient quality of life.

Conclusion: This high success rate was possible thanks to collaboration between highly specialized surgeons and nurses. WCNs, with their advanced competencies, represents a key figure in ensuring safety, personalization, and continuity of treatment.

EP355 Patient outcome and postoperative wound complications after primary vs. secondary fasciotomy in non-traumatic reperfusion compartment syndrome depending on preoperative ischemia time

Waseem Garabet [1], Katharina Beckamp[1], Polina Shabes[1], Hubert Schelzig[1], Julian-Dario Rembe[1]

[1]University Hospital Duesseldorf, Heinrich-Heine University (HHU), Düsseldorf, Germany

Aim: Reperfusion compartment syndrome is a severe complication following lower-extremity revascularization, potentially resulting in irreversible tissue damage, limb loss or life-threatening outcomes. Decision-making on fasciotomy—particularly its timing—remains critical to mitigate ischemic injury while avoiding postoperative complications, extended hospitalization, follow-up procedures or major amputation. This study analyzed short- and medium-term outcomes after fasciotomy, with emphasis on preoperative ischemia duration and procedure timing as prognostic indicators.

Method: A retrospective review of patients treated with therapeutic or prophylactic fasciotomy for reperfusion compartment syndrome at Düsseldorf University Hospital (2010–2021) was conducted. A 71-parameter database (including demographics, ischemia duration, operative timing, wound-healing outcomes, complications and hospitalization) enabled descriptive statistics and correlation analyses.

Results / Discussion: In total, 141 patients (59.57% male) underwent 321 fasciotomies; 71.05% were prophylactic and 28.95% secondary. Preoperative ischemia time remained <6 hours in only 17.73% of cases. Mean interval between revascularization and secondary fasciotomy was 37.5 ± 6.8 hours. Wound complications occurred in 90 procedures (28.04%), and 21 patients (14.9%) required major amputation. No significant difference in wound complication rates was noted between primary and secondary fasciotomy (28.05% vs. 28.28%; p = .4120); however,

secondary fasciotomy was associated with significantly delayed wound closure (29.71 ± 10.6 vs. 15.09 ± 2.76 days; p = .0386) and prolonged hospitalization (25.3 ± 2.1 vs. 32.9 ± 3.3 days; p = .0281).

Conclusion: Although complication and amputation rates did not differ between fasciotomy strategies, delayed fasciotomy correlated with extended healing and hospital stay. Given these findings and existing evidence, favoring early or prophylactic fasciotomy may be justified to minimize ischemic sequelae while reducing postoperative burden.

EP356 Minimally invasive venous surgery and multicomponent bandaging as a of choice strategy in the wound patients with chronic lymphedema and venous reflux: a retrospective study

Carlo Rivellini[1]

[1]*AIUC, SIC, SICVE, AFI, Italy*

Aim: We retrospectively analyzed patients with lymphedema and primary varicose veins, lipodermatosclerosis, and wound treated with a 1470 nm endovenous laser (ELVeS protocol) and multi-component multilayer bandage. The objective was to evaluate the safety of the method in a high-risk patient population and its efficacy in terms of ulcer healing.

Method: 57 patients with lymphedema and varicose veins complicated by lipodermatosclerosis and ulceration were consecutively treated. The surgical procedure was performed under tumescent local anesthesia in the operating room. All patients were treated with a 1470 nm diode laser using a dual-ring fiber. All patients underwent synchronous treatment of tributary varices using traditional surgical techniques, sclerotherapy, and combined techniques. Simultaneous treatment of both limbs was performed in 23 patients, while simultaneous treatment of multiple saphenous trunks in the same limb was performed in 12 patients. A multi-component bandage with pressure indicators was used in all patients for correct positioning in the post-operative period.

Results / Discussion: The success rate of the ELVeS procedure was 100% and the bandage was well tolerated in all patients; ulcer healing rate was 100% over a period of 1 to 5 months, with a recurrence rate of 5.7% over 12 months of follow-up.

Conclusion: The ELVeS protocol has proven to be safe and effective in the treatment of venous reflux even in patients with lipohermatosclerosis and ulceration and the combined use of multicomponent bandaging with landmarks further improved outcomes in patients with lymphedema in terms of edema reduction and ulcer healing.

STOMA

EP487 Influence of nursing interventions on the quality of life of individuals/families with intestinal stomas: Scoping review

Liliana Miranda[1], Ana Barbosa[1], Anabela Pereira[1]

[1]*Higher School of Health of the Portuguese Red Cross-Alto Tâmega-Chaves, Chaves, Portugal*

Aim: Map the scientific evidence on the influence of nursing care on the quality of life of people with intestinal stomas.

Method: Scoping review in accordance with the recommendations of the Joanna Briggs Institute and PRISMA guidelines. Search conducted in the following databases: EBSCOhost Online Research Databases (CINAHL Complete; MEDLINE Complete; Cochrane Plus Collection; Nursing & Allied Health Collection; MedicLatina); Psychology and Social Science Journals (PSYCLINE); Scientific Electronic Library Online (SciELO); ELSEVIER; National Library of Medicine (PubMed) and Virtual Health Library (LILACS).

Results: Nursing care positively influences the adaptation of individuals/families with intestinal ostomies to their new condition and, consequently, improves their quality of life. There is agreement on the importance of teaching before and after surgery. The articles that emerged from the literature review were grouped into four categories: teaching-learning process, body image, emotional lability of the individual/family, and family/community. The results also highlight sexuality as the dimension that most influences quality of life, spirituality as the most effective tool for overcoming emotional vicissitudes, and support groups as structures that promote social reintegration.

Conclusion: The nurse's interventions with the person/family with an intestinal ostomy are directed at the process of adaptation, self-care, identification of complications, and social reintegration, and are carried out in an individualised, personalised, and holistic manner, positively influencing the quality of life of the person/family with an intestinal ostomy. Nursing interventions influence the quality of life of individuals/families with intestinal stomas, as they assist in the complex process of change and adaptation, promoting self-care skills and adaptation to the new living conditions through interventions focused on physical, emotional, psychological, socio-professional, economic, family, and sexual components.

TRANSLATIONAL SCIENCE

EP357 Functional muscle recovery with 3D cell printed muscle tissue

Young Joon Jun[1]

[1]*Seoul St Mary Hospital The Catholic University of Korea, Seoul, Korea, Rep. of South*

Aim: Volumetric muscle loss (VML) is an irrecoverable injury generally more than 20% muscle loss. The decellularized extracellular matrix (dECM) approach has been extensively investigated. In this study, we developed pre-vascularized muscle tissue constructs for VML treatment using muscle dECM (mdECM) bioink through 3D cell printing. The regenerative capability of muscle tissue constructs was evaluated through implantation in a rat model of the VML defect.

Method: Human muscle cells and human umbilical vein endothelial cells (HUVECs) were encapsulated in mdECM and vascular-derived dECM (vdECM) bioink. Pre-vascularized skeletal muscle constructs were fabricated in the gelatin granule reservoir. To create the models of VML injuries, 10-week-old Sprague Dawley rats were anesthetized, and 40% of the tibialis anterior muscle was removed from each rat. The 3D cell printed muscle constructs were implanted and sutured at both ends. Masson's Trichrome staining, immunofluorescence staining, and functional assessment were conducted at four weeks post-impanation.

Results / Discussion: In vitro assessments showed that the pre-vascularized muscle tissue construct that was formed by a coaxial nozzle (coaxial group) exhibited enhanced contractile force and myotube and endothelial network formation. In vivo results revealed that the muscles treated with the coaxial group greatly improved de novo muscle fiber regeneration, vascularization, and innervation. Most importantly, the pre-vascularized muscle tissue construct achieved 85% functional recovery in VML injuries. Conclusion: In this study, we developed a pre-vascularized muscle construct using 3D cell printing and a coaxial nozzle. We expect that these results will provide a blueprint for the future development of engineered human-scaled muscle tissues for VML injury treatment.

EP495 Assessment of hard-to-heal lower leg wounds with Near-Infrared fluorescent imaging

Emil Schmidt[1], Kari Clifford[2], Jan Johnstone[3], Jolanta Krysa[4]

[1]University of Otago, Dunedin, New Zealand, *[2]University of Otago, Dept of surgery and Critical Care, Dunedin, New Zealand*, *[3]University of Otago, Dept of Surgery and Critical Care, Dunedin, New Zealand*, *[4]University of Otago, Dept of Surgery and Critical Care, Dunedin, New Zealand*

Aim: Near-infrared fluorescent (NIRF) imaging is a diagnostic tool to provide a means to visualize wound perfusion, tissue viability, and healing progress. Our aim was to explore the diagnostic potential of this modality.

Objectives: This case series explores the application of NIRF imaging in assessment of hard to heal wounds.

Methods: We conducted a 12-week non-randomized observational study, a subset of an ongoing interventional study. Participants with hard-to-heal lower limb wounds received multi-disciplinary wound care. NIRF imaging using Indocyanine green contrast was performed prior to treatment, at six, and twelve weeks. Visual assessment and quantitative analysis of fluorescent intensity within a region of interest were summarized.

Results: Seventeen participants were included, with a mean (SD) age of 64(9) years. Forty-seven percent were diabetic, and 45% had peripheral arterial disease. Wound size changes ranged from 23% to -95%. Changes in wound healing in patients whose intensity reduced had reduction in wound size and increased granulation. Increasing intensity was observed in three patients requiring further treatment for pathology that is not visually observable.

Conclusions: Utilizing near-infrared technology allows for the visualization of revascularization and wound healing progress prior to observable changes in hard to heal wounds. Increasing intensity in dye can provide insight into inflammation sites that may not be visual to the practitioner. Incorporating NIRF imaging into chronic wound management may facilitate timely interventions.

EP359 Can microbial diversity predict chronicity? Translational insights from elephant wound ecology

Giggin T[1], John Martin KD[2], Syam Venugopal[3], Anil KS[3], Sreeranjini AR[3], Aravindakshan TV[4], Ambily R[3], Narayanan MK[2]

[1]Kerala agricultural University, Kerala Veterinary and Animal Science University, Thrissur, Kerala, India, *[2]Kerala Veterinary and Animal Science University, Thrissur, Kerala, India*, *[3]Kerala Veterinary and Animal Sciences University, Thrissur, Kerala, India*, *[4]Aravali Veterinary College, Sikar, Rajasthan, India*

Aim: Chronic wounds in humans persist within complex polymicrobial biofilms in which microbial diversity and ecological balance influence healing. This study aimed to characterise the wound microbiome of captive Asian elephants (*Elephas maximus*) and interpret how microbial diversity and community structure reflect multifactorial influences-anthropogenic, environmental, and host-related-that act as parallel drivers of chronicity in human wounds. This dataset represents the first 16S rRNA-based metagenomic characterisation of wound microbiota in a megafaunal species and provides translational insight into biofilm ecology and environmental determinants of chronicity.

Method: Bacterial communities from elephant wounds were analysed using 16S rRNA amplicon sequencing. Taxonomic composition and alpha- and beta-diversity indices were computed. Clinical wound characteristics were concurrently recorded using smartphone-based planimetry and infrared thermography to contextualise microbial patterns with wound status.

Results / Discussion: The microbiome revealed high bacterial diversity comprising *Staphylococcus*, *Pseudomonas*, *Finegoldia*, and diverse environmental genera. Several taxa commonly associated with human chronic wounds and hospital environments were detected, suggesting microbial exchange at the human-animal interface. The coexistence of commensal, opportunistic, and environmental species indicated a stable but dysbiotic biofilm community shaped by external and host factors rather than a single pathogen. These ecological features resemble those described in human chronic-wound microbiomes.

Conclusion: Microbial diversity shaped by environmental and anthropogenic interactions appears to underpin chronic wound persistence. Elephant wound ecology thus offers a translational model for studying chronic-wound microbiology and biofilm stability, underscoring shared ecological principles that govern chronicity across species.

P360 Proregenerative modulation of the wound microenvironment by a biomaterial based on a natural deep eutectic system

Maria Belen Olivares[1], Paulina Hernández[1], Paz Cárcamo[2], Constanza Cárcamo[2], Paola Campodonico[1]

[1]Instituto de Ciencias e Innovación en Medicina. Facultad de Medicina Clínica Alemana-Universidad del Desarrollo, Santiago, Chile, *[2]Facultad de Ciencias de la Vida. Escuela de Ingeniería en Biotecnología. Universidad Andrés Bello, Santiago, Chile*

Aim: This study aimed to elucidate the cellular mechanisms underlying the biological activity of a betaine–urea natural deep eutectic system (BU-NADES), a liquid biomaterial developed for debridement and antibiofilm treatment of cutaneous ulcers. In a pilot clinical trial in venous ulcer patients, BU not only reduced bacterial burden but also produced a pronounced acceleration of wound closure, suggesting additional pro-regenerative actions beyond osmotic debridement. Here, we investigated the effects of BU on inflammatory signalling, fibroblast migration, and angiogenesis.

Method: The anti-inflammatory activity of BU_NADES was assessed using an *in vitro* inflammation model in primary human dermal fibroblasts and human macrophages (THP-1 and THP1-dual), evaluating cytokine expression and activation of the NF-κB pathway. Migration and angiogenesis were examined using three-dimensional extracellular matrix–based models with fibroblasts and EA.hy926 endothelial cells, respectively.

Results / Discussion: BU induced a dose-dependent suppression of LPS induced IL1b, TNFα, IL8, and IL6 levels and significantly attenuated LPS-induced NF-κB activation, demonstrating a robust anti-inflammatory effect. In 3D migration assays, BU-driven extracellular matrix reorganization doubled the number of migrating fibroblasts compared with collagenase. Additionally, BU significantly restores angiogenic network formation altered by incubation with LPS+TNFa, indicating a favourable modulation of pro-repair cellular dynamics. These findings, supports its capacity to act as a debriding agent while simultaneously modulating the cellular microenvironment.

Conclusion: BU-NADES functions as a new multifunctional biomaterial combining debridement with anti-inflammatory regulation through NF-κB downmodulation stimulation of fibroblast migration and angiogenic activity. These actions provide a mechanistic explanation for the accelerated wound healing observed clinically, position BU as a translational platform for advanced wound management.

EP361 Oil-based matrix dressings in wound care: A systematic review of clinical effectiveness and safety

Sara Sandroni[1], Angela Peghetti[2]

[1]Azienda USL Toscana Sudest, Arezzo, Italy, *[2]IRCCS Azienda Ospedaliero Universitaria Di Bologna, Bologna, Italy*

Aim: This study aims to systematically evaluate the clinical effectiveness and safety of oil-based matrix dressings in the management of acute and chronic wounds.

Method: A systematic review is conducted in accordance with PRISMA guidelines. The following databases are searched: PubMed/MEDLINE, Scopus, Web of Science, and CINAHL, covering the period from January 2000 to January 2025. Search terms include combinations of: oil-based matrix, lipid matrix dressing, impregnated dressings, wound care, and chronic wounds. Randomized controlled trials, observational studies, and systematic reviews evaluating oil-based matrix dressings in adult patients with acute or chronic wounds are included. Primary outcomes are wound healing rate, pain, infection rate, and local tolerability. Two independent reviewers perform study selection, data extraction, and quality assessment using validated tools (CASP and MMAT).

Results / Discussion: Preliminary screening indicates that oil-based matrix dressings are mainly investigated in acute wounds. Available evidence shows that these dressings support the maintenance of a moist wound environment, facilitate atraumatic dressing removal, and contribute to pain reduction during dressing changes. The antimicrobial effect described in the literature appears to be mainly indirect, related to physical protection of the wound bed and optimization of the local microenvironment rather than to intrinsic antimicrobial activity. No relevant cytotoxic effects emerge from the studies analyzed so far. However, heterogeneity in study design, wound etiology, and outcome measures may limit the feasibility of a quantitative meta-analysis.

Conclusion: Oil-based matrix dressings currently appear to represent a safe and well-tolerated option for wound management, particularly with regard to patient comfort and protection of the wound bed.

EP496 Inflammation-Responsive Hydrogel Accelerates Diabetic Wound Healing through Immunoregulation and Enhanced Angiogenesis

Fang He[1]

[1]*Department of Burns & Wound Care Center, The Second Affiliated Hospital of Zhejiang University School of Medicine, Hangzhou, China*

Aim: To overcome the hostile microenvironment that limits vascular endothelial growth factor (VEGF) efficacy in diabetic wounds by developing an inflammation-responsive hydrogel, and to evaluate its ability to promote angiogenesis and accelerate healing.

Method: An inflammation-responsive hydrogel (IRGel) co-loaded with Prussian blue nanoparticles (PBNPs) and VEGF was synthesized using hyaluronic acid derivatives. Its physicochemical properties, injectability, self-healing capacity, and reactive oxygen species (ROS)-triggered drug release profile were characterized. Biocompatibility, ROS-scavenging, and anti-inflammatory effects (including macrophage polarization) were assessed in vitro. Therapeutic efficacy was evaluated in a db/db type 2 diabetic mouse full-thickness wound model, with wound closure, histological analysis, immunohistochemistry, and transcriptomic sequencing as key outcomes.

Results / Discussion: The hydrogel demonstrated excellent biocompatibility, rapid gelation, and inflammation-triggered release of PBNPs. In vitro, the PB&VEGF@IRGel effectively scavenged ROS and promoted macrophage polarization from M1 to M2 phenotype. In diabetic mice, hydrogel treatment significantly accelerated wound closure compared to controls. Histology revealed enhanced re-epithelialization and collagen deposition. Immunofluorescence confirmed reduced oxidative stress, decreased pro-inflammatory markers (IL-6, TNF-α), increased M2 macrophages (ARG1+, CD206+), and significantly higher density of new blood vessels (CD31+). Transcriptome analysis indicated upregulation of angiogenesis-related pathways and downregulation of inflammatory pathways.

Conclusion: An inflammation-responsive hydrogel co-delivering PBNPs and VEGF was successfully developed. It reprograms the diabetic wound microenvironment by mitigating oxidative stress and inflammation, thereby preserving VEGF bioactivity. This dual-action strategy significantly enhances angiogenesis and accelerates wound healing, representing a promising therapeutic platform for diabetic chronic wounds.

EP362 Implementation of a marsi prevention bundle in central venous catheter care

Paula Freitas[1], Aline Ramalho[2], Kelly Jahana[2], Eliane Mazocoli[2], Danielle Barreto[2], Renata Gonçalves[2], Alessandra Marin[2], Lucas Rezende[2]

[1]Universidade Federal do Espirito Santo, Vitoria, Brazil, *[2]Sirio Libanes Hospital, São Paulo, Brazil*

Aim: To describe the development and implementation of a multidisciplinary guideline for the prevention of MARSI in central venous catheters, incorporating technologies and standardized processes.

Method: The guideline was developed by a multidisciplinary team composed of wound, ostomy, and continence nurses, vascular access specialists, and infection control experts. The process included evidence review, analysis of available technologies in the market, and mapping of institutional risk factors. The proposal resulted in a preventive bundle consisting of seven elements: skin assessment, risk stratification, dressing selection, optimized skin preparation, standardized application and safe adhesive removal, and continuous team education.

Results / Discussion: The guideline established criteria for dressing selection: chlorhexidine-impregnated films for low-risk adults; silicone films for patients with multiple MARSI risk factors, as well as for neonates and infants. Differentiated antisepsis protocols were incorporated according to age group and skin condition. Implementation involved interactive training, monitoring dashboards, and integration with infection and MARSI indicators.

Conclusion: The guideline represents an institutional advancement by integrating evidence, technological innovation, and standardized practices. The adoption of this approach has the potential to reduce complications, optimize patient experience, and strengthen the safety culture.

EP363 Implementation of the crefc score as a clinical triage tool in multidisciplinary wound care consultations: Study protocol

Ester Malcato[1], Sara Magalhães[2]

[1]ULSSM, APTFeridas, Lisbon, Portugal, *[2]ULS Amadora, APTFeridas, Lisbon, Portugal*

Aim: To implement and evaluate the CREFC score (Complex Wound Referral Criteria, composed of 14 validated clinical indicators) as a structured clinical triage tool for identifying and classifying wound complexity. The aim is to analyze its feasibility, discriminatory capacity, and contribution to appropriate referrals, simultaneously determining the most appropriate location for patient follow-up—primary healthcare, specialized community teams, or multidisciplinary wound care consultations, offering a structured model aligned with international best practices.

Method: Design: Prospective observational multicenter study.

Location: Specialized wound care units of the National Health Service.

Participants: All patients referred over a period of 9 months.

Procedures: Referrals will be assessed using the CREFC score (0–28 points). Sociodemographic data, wound type, wound duration, comorbidities, criteria met, and time to consultation will be collected using a Microsoft Forms questionnaire. The classification of criteria allows for the identification of scores: low (0–7), moderate (8–14), and high (15–28) complexity.

Analysis: Descriptive statistics, score distribution, association between score level and wound type, feasibility indicators (completion time, missing data rate).

Results / Discussion: The CREFC score is expected to increase the consistency of referrals, identify more complex cases early, and improve the coordination of the multidisciplinary team. Additionally, it is anticipated that it will contribute to a more appropriate level of care, facilitating the definition of the most suitable location for each patient's follow-up. Furthermore, it aims to support its future integration into digital health systems.

Conclusion: This protocol proposes a pragmatic and evidence-based approach to standardizing the referral and assessment of complexity in wound care, in line with EWMA's strategic vision of reinventing wound management through structured tools and interdisciplinary care models.

EP364 Efficacy of anti-inflammatory, anti-bacterial and pro-regenerative bioactive inks on fibroblast proliferation in the presence or absence of chronic wound exudates

Nicole Schöfmann[1], Gabriela Cabral[1], Beatriz Palla[2], Oliver Etzold[2], Damien Dupin[2], Magnus Ågren[3], Ewa Anna Burian[3], Klaus Kirketerp-Møller[3], Stine Ørts Pedersen[3], Frederik Plum[3], June Svendsen[3], Barbara Wolff-Winiski[1]

[1]Akribes Biomedical GmbH, Vienna, Austria, *[2]CIDETEC, Donostia-San Sebastián, Spain*, *[3]University of Copenhagen, Copenhagen, Denmark*

Aim: Exudates from chronic wounds (cWEs) transfer their clinical phenotype onto primary human fibroblasts in cell culture by impairing proliferation. Drugs and biologicals with potential for chronic wound therapy should be able to reverse this effect. Based on this rationale, we used this cell assay to investigate the effect of hyaluronic acid-based bioactive inks (BI) developed in the Horizon Europe FORCEREPAIR project. Those BI have been designed to be smart and multifunctional, 3D-printed, to combat bacterial infections and inflammation, promote healing and relieve skin tension.

Method: Exudates from 3 chronic venous leg ulcer patients were collected (24 hours) by hydrophobic polyurethane foam discs or from used bandages. Anti-inflammatory, anti-bacterial and pro-regenerative BIs were added to primary human dermal fibroblasts in the presence of these exudates. After 72 hours, cell proliferation was determined upon fixation and staining.

Results / Discussion: In the absence of cWEs, all three BIs promoted fibroblast proliferation. In the presence of three cWEs, all BIs had a positive effect on proliferation. With two cWEs, anti-inflammatory, anti-bacterial and pro-regenerative BI induced up to 30% increase in proliferation above the cWE level but did not totally reverse the cWE effect. With one cWE, all bioinks led to total rescue of proliferation in a dose-dependent fashion with the pro-regenerative bioink having the strongest effect, boosting proliferation beyond the level of control cells.

Conclusion: The effect of BIs is highly dependent on the cWE sample. This is similar to results reported for platelet derived growth factor and silver sulfadiazine, leading to the assumption that patient-specific factors must account for the differences. Future clinical studies will address the translatability of the *ex vivo* results to the clinic.

EP365 Global transcriptomic analysis of adipose tissues in primary and secondary lymphedema

Taehee Jo[1]

[1]Keimyung University School of Medicine, Daegu, Korea, Rep. of South

Aim: Lymphedema is characterized by persistent tissue injury, inflammation, and progressive fibrosis of subcutaneous adipose tissue, resulting in impaired tissue homeostasis and delayed wound healing. Although fibrotic remodeling of adipose tissue links lymphedema to chronic non-healing wounds, the underlying molecular mechanisms remain poorly understood. We performed unbiased global transcriptome analysis of adipose tissue from primary and secondary lymphedema patients to identify metabolic and signaling pathways associated with adipose tissue dysfunction in chronically injured lymphatic environments.

Method: RNA sequencing was performed on adipose tissues obtained from dermal backflow–negative (control) and dermal backflow–positive (lymphedema-affected) limbs of two primary and three secondary lymphedema patients. Paired-end sequencing (2×151 bp) was conducted using the Illumina NovaSeq 6000 platform. Reads were aligned using STAR, and gene expression was quantified with RSEM. Transcript per million (TPM) values were used for unsupervised hierarchical clustering, Gene Set Enrichment Analysis (GSEA) with Hallmark gene sets, and pathway analysis using the PANTHER overrepresentation test.

Results / Discussion: Hierarchical clustering revealed distinct global transcriptomic differences between control and dermal backflow–positive adipose tissues in both primary and secondary lymphedema. Myc target gene sets were significantly upregulated in control adipose tissue in both primary ($p < 0.0001$, FDR $q < 0.0001$) and secondary lymphedema ($p < 0.0001$, FDR $q = 0.004$). Glycolysis-related genes were also commonly enriched in control adipose tissue. PANTHER analysis identified fibroblast growth factor (FGF) signaling as the most significantly enriched upstream pathway.

Conclusion: Primary and secondary lymphedema share distinct transcriptomic alterations in adipose tissue associated with impaired regenerative capacity. Dysregulation of the FGF–Myc–glycolysis axis may contribute to wound chronicity in lymphedema and warrants further investigation as a potential therapeutic target.

WOUND ASSESSMENT

EP497 Impact of autofluorescence imaging on the effectiveness of debridement in wound care: A systematic review

Hsu-Tang Cheng[1]

[1]*Asia University Hospital, Taichung City, Taiwan*

Aim: This systematic review aimed to evaluate the impact of autofluorescence imaging (AFI) on the effectiveness of wound debridement, focusing on its role in detecting bacterial burden, guiding clinical decision-making, and improving wound care outcomes.

Method: A structured literature search through August, 2025 identified nine eligible studies that investigated the use of AFI in debridement of chronic wounds, diabetic foot ulcers, burns, and other skin ulcers. Studies were analyzed for their methodology, patient population, wound types, and reported outcomes, with emphasis on bacterial detection, reduction after AFI-guided debridement, and influence on subsequent interventions.

Results / Discussion: All included studies consistently reported that standard debridement alone may fail to identify residual bacterial contamination. AFI provided real-time visualization of bacterial fluorescence, prompting clinicians to perform more extensive debridement and ensuring more complete removal of bioburden. Post-debridement fluorescence imaging revealed significant bacterial reduction, though in several cases residual subsurface signals required additional intervention. Furthermore, AFI influenced clinical decision-making, such as cleaner selection and advanced therapeutic choices, particularly in diabetic foot ulcers and burn management. These findings highlight the role of AFI not only in enhancing diagnostic precision but also in modifying treatment strategies to optimize infection control.

Conclusion: Autofluorescence imaging represents a valuable adjunct to conventional wound debridement, improving bacterial detection and supporting more comprehensive clinical interventions. By enabling real-time visualization of bacterial load, AFI has the potential to enhance debridement effectiveness, reduce infection risk, and ultimately improve wound healing outcomes.

EP366 Development and implementation of an immunocompetent 3D in-vitro wound model for cutaneous regeneration research

Qvarnaki Suppiyar[1], Wiebke Ibing[1], Waseem Garabet[1], Markus Udo Wagenhäuser[1], Hubert Schelzig[1], Julian-Dario Rembe[1]

[1]*University Hospital Duesseldorf (UKD), Department of Vascular and Endovascular Surgery, Heinrich-Heine-University (HHU), Duesseldorf, Germany*

Aim: Establishment of a standardized, immunocompetent in-vitro 3D wound model for testing and investigating regenerative processes.

Method: The model consists of a collagen-based dermal component containing adult fibroblasts (NHDF) and monocytes (THP-1), as well as an epidermis composed of keratinocytes (HaCaT). Within the model, monocytes differentiate into M0 macrophages (precursor), followed by a controllable polarization of the macrophages into M1 (proinflammatory) or M2 (antiinflammatory) phenotypes using IFN-g/ LPS for M1 and IL-4/IL-13 for M2. Immunohistological (CD86/CD206 Ratio) and secretory profile (CCL-2) analyses are used to assess macrophage differentiation. Wounding is performed using a self-developed static device composed of commercially available components, allowing for standardized control over wound depth and positioning. The inflammatory milieu of a chronic wound is simulated by artificial (LPS, IFN-g) and hypoxic (3% O_2) stimuli.

Results / Discussion: The cells were successfully integrated into a cocultured dermal matrix, differentiated and cultivated for 21 days. Keratinocytes were successfully seeded onto the dermis. However, due to the use of HaCaT, limitations in the differentiation of individual epidermal layers were observed. Using the newly developed device,

variances in wound depth and position could be minimized. Analysis of the macrophage secretory profile within the model showed consistent results: increased proinflammatory CCL-2 secretion and CD86/CD206-Ratio in M1-models compared to the proregenerative M2-models.

Conclusion: Using this standardized approach, a successful wound model based on commercial cell lines was established. Compared to existing wound models and animal experiments this model offers ethical, economic and standardizable advantages for preclinical testing of new therapeutics in wound care. In future, the wound model is intended to enable the investigation of the effects of modern wound therapeutics in a realistic and standardized setting.

EP367 EXSUDATA: Wound assessment tool for moisture management

Dioney Neves[1], Camila Safranski[1]

[1]Missner, Blumenau, Brazil

Aim: To present the development of EXSUDATA, a structured digital and physical wound-assessment tool developed to apply as a clinical decision-support system designed to assist health professionals in selecting appropriate wound dressings based on tissue type and exudate level, thereby improving wound assessment and moisture management.

Method: Multidisciplinary team developed a digital matrix that integrates two primary clinical parameters: tissue classification and exudate level. Eight tissue types were defined (epithelial, granulation, dry necrosis, slough, friable tissue, hyperkeratosis, hypergranulation and first and second-degree burns). Four levels of exudation were established: absent, low, moderate and high. For each possible combination, evidence-based dressings options were assigned according to their absorptive and protective properties, aligns with international wound care guidelines. The tool was tested by wound care specialists in simulated clinical scenarios to validate usability and clinical coherence.

Results: The tool demonstrated high consistency among evaluators in the classification of wound characteristics and in the selection of accurate dressings. Users reported increased confidence in clinical decision-making, faster assessment times and improved standardization of documentation. The systems structure also support education purposes by reinforcing-evidence based reasoning.

Conclusion: this wound assessment tool contributes do the standardization of clinical practice and enhances decision-making related do exudate management. By integrating tissue type and exudation level into a structured algorithm, it offers a practical and user-friendly approach to selecting optimal dressings and promotive effective wound healing outcomes.

EP368 Performance comparison of cinnamon- and charcoal-based dressings in odour control: In-vitro and ex-vivo evaluation using an electronic nose

Sami Slimani[1], Romain Dubreuil[1], Victoria Michaels[2], Clemence Desjardin[2]

[1]Olfaktion, Grénoble, France, *[2]Cemag Care, Paris, France*

Aim: To compare the odour control performance of cinnamon and charcoal-based dressings using in-vitro chemical models and ex-vivo pig skin models, with odour quantification (a handheld electronic nose device).

Method: In-vitro model: malodours compounds (ammonia, ethylamine, propylamine) were diluted (0.1% to 0.0001%) and injected into a simulated wound environment (sterile gauze with or without the evaluated dressings). Odour intensity was measured using electronic nose, a 64-channel biosensor device with humidity/temperature correction, in triplicate. Ex-vivo model: pig skin was incubated at 37°C for 18-20 hours to promote native bacterial growth. A standard primary foam dressing was applied, followed by either a cinnamon, charcoal or no secondary dressing. Odour intensity was evaluated at baseline, during 7h, and on Days 1, 2, 3 and 6 post-application, in triplicate. Principal Component Analysis (PCA) was used to analyse olfactive signatures and visualize similarities and differences between samples.

Results / Discussion: In-vitro: Across all tested amines and dilutions, the cinnamon dressing consistently showed lower odour intensity signals compared to charcoal, even with pure malodorous compounds. Ex-vivo: After 7h, mean odour intensity was 30–40 radians for control and charcoal, compared to 0 radians for cinnamon dressing. By D6, mean intensity increased to 230 radians for control and charcoal groups, while remaining at 50 radians with cinnamon dressing. PCA revealed distinct clustering of olfactive signatures for each sample type, demonstrating unique chemical profiles and temporal progression, particularly in cinnamon dressing group.

Conclusion: Cinnamon-based dressings demonstrated superior odour control compared with charcoal-based dressings in both in-vitro and ex-vivo models. The handheld electronic nose offers a practical, objective method for point-of-care odour assessment. A clinical evaluation is planned to further validate these results.

EP498 Thermographic profiling of chronic lower limb ulcers: associations with etiology, perfusion patterns, and systemic inflammation

Bartosz Molasy[1], Małgorzata Wrzosek[2]

[1]Department of Surgical Medicine, Medical College, Jan Kochanowski University, Department of General Surgery, St Alexander Hospital, Kielce, Poland, *[2]Department of Pharmaceutical Sciences, Medical College, Jan Kochanowski University, Department of Biochemistry and Pharmacogenomics, Medical University of Warsaw, Warsaw, Poland, Kielce, Poland*

Aim: To comprehensively characterise thermographic patterns across major etiological subtypes of chronic lower limb ulcers and to evaluate whether wound-bed temperature and thermal gradients reflect systemic inflammation, perfusion status, and markers of clinical severity.

Method: This prospective observational study included 82 consecutive patients with chronic lower limb ulcers admitted to a tertiary wound care centre. Standardised infrared thermography was performed on day 0. Wound-bed temperature and temperature gradient (ΔT; wound-bed minus periwound area) were compared across etiologies (venous, diabetic, ischemic, traumatic, mixed, pressure). Non-parametric tests (Kruskal–Wallis) assessed between-group differences. Associations with systemic inflammatory markers (CRP, WBC, NLR), ulcer duration, and length of hospitalisation were analysed using Spearman correlation.

Results / Discussion: Clear and distinct thermal phenotypes were observed. Ischemic and diabetic ulcers demonstrated a pronounced “cold–hypoperfusion” profile, characterised by significantly lower wound-bed temperatures and strongly negative ΔT values, consistent with impaired microvascular perfusion. In contrast, venous and traumatic ulcers displayed a “warm–inflammatory” phenotype with elevated wound-bed temperatures and higher systemic inflammatory markers. ΔT correlated inversely with CRP ($\rho = -0.47$) and NLR ($\rho = -0.50$), suggesting that greater thermal asymmetry reflects higher inflammatory burden. Lower wound-bed temperatures and larger negative ΔT values were also associated with prolonged hospitalisation, indicating that thermographic patterns may reflect overall clinical severity and complexity of wound management.

Conclusion: Infrared thermography provides rapid, non-contact assessment of perfusion and inflammatory status in chronic lower limb ulcers. Distinct thermal signatures across etiological subtypes highlight its potential for enhanced diagnostic stratification. Thermal parameters, particularly ΔT, may serve as clinically useful indicators for early triage and guiding personalised treatment strategies.

EP369 Effects of Particular Matter on Wound Healing: An In Vivo Study

Hyeon Hee Lee[1], Jong Won Rhie[1], Na Young-cheon[1], Hyemi Lee[1], Seoul Lee[2]

[1]Department of Plastic and Reconstructive Surgery, Wonkwang University Hospital, Iksan, Korea, Rep. of South, [2]Pharmacology, Wonkwang University, Iksan, Korea, Rep. of South

Aim: Particulate matter (PM) is known to increase the risk of diseases in major organs and PM may also slow the complex process of wound healing. We investigated the effect of PM on wound healing in vivo.

Method: Twelve 10-week-old Sprague-Dawley male rats were punctured with three 8 mm-diameter holes each in the skin on their backs. The holes were divided into three groups according to treatment: PM 50 μg/mL(group A), PM 100 μg/mL(group B) and saline(control). For histologic analysis, three rats were sacrificed on each of the 1st, 3rd, 7th, and 28th days. Inflammatory cell infiltration and neovascularization were evaluated for comparison among groups.

Results / Discussion: Inflammation increased in groups A and B on day 1, but no significance was observed. On the 28th day, increased inflammation was observed in groups A and B compared to the control group, with significant difference. Angiogenesis increased in groups A and B compared to the control group on day 1, but no significance was observed. On the 3rd day, there was a decrease in group B, with statistical significance. On day 28, it was observed that angiogenesis significantly increased in group B compared to the control group.

Conclusion: Inflammation increased in the PM groups compared with the control group and angiogenesis decreased, then slowly increased in the PM groups compared with the control group. Our findings suggest that PM increases inflammation and delays angiogenesis in the wound healing process.



Figure 1. Wound creation on back of rat.

Table 1. Comparison of inflammation progression using the semi-quantitative scoring system

Inflammation	Control group (saline)	Group A (PM 50 μg/mL)	Group B (PM 100 μg/mL)	P-value (control vs. group A)	P-value (control vs. group B)	P-value (group A vs. group B)
Day 1	2.50±0.93	3.00±0.00	2.83±0.41	0.129	0.305	0.629
Day 3	3.00±0.00	3.00±0.00	2.75±0.46	-	0.161	0.161
Day 7	3.00±0.00	3.00±0.00	3.00±0.00	-	-	-
Day 28	1.00±0.00	2.00±0.00	1.50±0.55	<0.001[a)]	0.027[a)]	0.045[a)]

Values are presented as mean±SD. Scoring: 0, absence of inflammation; 1, presence of few inflammatory cells; 2, many inflammatory cells; 3, exaggerated inflammatory cellularity.
PM, particulate matter.
[a)]P<0.05 is considered statistically significant.

Table 2. Comparison of angiogenesis progression using the semi-quantitative scoring system

Angiogenesis	Control group (saline)	Group A (PM 50 µg/mL)	Group B (PM 100 µg/mL)	P-value (control vs. group A)	P-value (control vs. group B)	P-value (group A vs. group B)
Day 1	1.00±0.00	2.00±1.16	1.00±0.00	0.071	-	0.109
Day 3	2.88±0.35	2.88±0.35	2.14±1.07	-	0.029[a)]	0.029[a)]
Day 7	3.00±0.00	2.50±0.76	3.00±0.00	0.105	-	0.105
Day 28	0.50±0.55	0.50±0.58	1.83±0.98	-	0.004[a)]	0.008[a)]

Values are presented as mean±SD. Scoring: 0, normal vascularization; 1, discrete vascular formation; 2, moderate vascular formation; 3, high vascular formation.
PM, particulate matter.
[a)]P<0.05 is considered statistically significant.

EP371 AI-supported tissue assessment improves efficiency in nurse-managed wound care

Mehdi Shahbazi Azad[1], Mojgan Moein[1], Aniseh Matin[2]

[1]Al-Zahra Hospital,Isfahan University of Medical Sciences, Isfahan, Iran, *[2]Khanevadeh Home Nursing Service Center, Isfahan, Iran*

Aim: To evaluate the operational efficiency improvements achieved by integrating an AI-based tissue assessment system into a nurse-managed chronic wound clinic.

Method: A 12-week observational study was conducted in a nurse-managed outpatient chronic wound clinic using the Esfahan Executable Model and the 247 Standard Regimen. AI-supported tissue analysis (granulation %, slough %, necrotic %, and exudate level) was compared with routine manual assessment. Outcomes included assessment time, inter-nurse variability, clinic visit throughput, and accuracy of AI-based healing-trend prediction.

Results / Discussion: AI implementation reduced average assessment time from 4.6 minutes to 1.2 minutes per patient (74% reduction). Inter-nurse variability decreased by 48%. Clinic throughput improved by 22% without additional staffing. AI-based healing-trend prediction reached 87% accuracy, enabling earlier identification of non-healing wounds. Nurses reported reduced cognitive load and higher confidence in decision-making, particularly during high-volume days.

Conclusion: AI-supported tissue assessment significantly improves speed, consistency, and decision-making accuracy in nurse-managed wound clinics. This approach is low-cost, practical, and scalable for outpatient wound services in resource-limited settings.

EP372 Effectiveness and reliability of perdanakusuma II versus falanga score for chronic wound assessment before and after training in surgical residents

David Perdanakusuma[1], Inggrid Asali[1], Agus Budi[1]

[1]Department of Plastic Reconstructive and Aesthetic Surgery, Faculty of Medicine, Universitas Airlangga, Surabaya, Indonesia

Aim: To compare the effectiveness and reliability of Perdanakusuma II Score and Falanga Score for chronic wound assessment before and after structured training among surgical residents.

Method: A quasi-experimental pre–post study was conducted involving 41 surgical residents who independently assessed 20 anonymised chronic wound cases using both Perdanakusuma II and Falanga scoring systems before and after a standardized training session. Assessment accuracy was analysed using Wilcoxon signed-rank tests for pre–post changes within each method and Mann–Whitney tests for between-method comparisons. Effectiveness was

expressed as mean, median, and number of correct classifications, while reliability was explored through consistency of responses across cases.

Results / Discussion: Both scoring methods showed significant improvement in assessment accuracy after training (Wilcoxon p = 0.001 for each method). Perdanakusuma II yielded higher pre- and post-training scores than Falanga (pre-test mean 11.32 vs 8.34; post-test mean 13.49 vs 10.80; Mann–Whitney p = 0.001). In six of 20 wound cases, Perdanakusuma II demonstrated significantly greater accuracy, particularly for wounds where colour, inflammation, and exudate were critical determinants. Perdanakusuma II, with three visually oriented parameters, was easier to remember and apply, whereas the eight-parameter Falanga system remained more complex and less practical for early learners despite being valid and internationally established.

Conclusion: Structured training significantly improved chronic wound assessment using both Perdanakusuma II and Falanga scores, confirming that each is effective and reliable for educational use. Perdanakusuma II demonstrated superior pedagogical effectiveness, higher accuracy, and better practical adaptability, supporting its adoption as a primary scoring tool for chronic wound assessment and training. Simple, visually based scoring systems may enhance documentation, communication, and clinical decision-making in chronic wound management.

EP373 Diagnostic accuracy of infrared thermography for early detection of wound infections: Systematic review and meta-analysis

Justyna Cwajda Białasik[1], Andrea Pokorná[2], Marcos Leal Brioschi[3], Paulina Moscicka[1]

[1]Nicolaus Copernicus University in Torun, Torun, Poland, *[2]Department of Health Sciences Faculty of Medicine, Masaryk University, Brno, Czech Republic, Brno, Czech Republic*, *[3]Medical Thermology and Thermography Specialization, Sao Paulo University Medicine School Clinical Hospital, São Paulo, Brazil, Sao Paulo, Brazil*

Aim: To evaluate the diagnostic accuracy of infrared thermography (IRT) in the early detection of infection and wound-healing complications.

Method: This systematic review, conducted according to PRISMA guidelines, searched PubMed, EBSCO, Medline, CINAHL, Web of Science, Polska Bibliografia Lekarska, and Academic Search Ultimate without language or date restrictions. Eligible studies were observational studies and clinical trials assessing IRT for identifying wound-related complications, using clinical or microbiological confirmation as reference standards. wo reviewers screened records, and data were extracted on study characteristics. Risk of bias was assessed with the Downs and Black checklist. Where feasible, pooled estimates were calculated using bivariate random-effects models, and heterogeneity was evaluated with Chi-square and I^2 statistics.

Results / Discussion: The search identified 2,900 records; after deduplication, 1,850 titles and abstracts were screened, and 129 full texts were assessed. Thirty-two studies met inclusion criteria for qualitative synthesis, and twelve were included in quantitative analysis. The studies encompassed surgical wounds, venous leg ulcers, diabetic foot ulcers, pressure ulcers, and burns, with sample sizes ranging from 6 to 267 participants and varied IRT devices and imaging procedures. Considerable methodological and clinical heterogeneity limited the scope of meta-analysis. In studies assessing surgical site infections, early thermal abnormalities were consistently associated with an increased likelihood of infection, although temperature thresholds and definitions varied.

Conclusion: Infrared thermography shows promise for early detection of wound infections and healing complications, particularly in surgical populations. However, substantial heterogeneity in imaging protocols, device performance, and outcome definitions constrains generalizability. IRT may serve as a rapid, non-contact triage tool under standardized conditions, but further prospective studies using consistent methodologies and microbiological confirmation are required to validate its clinical applicability.

EP374 Infection risk assessment tools for hard-to-heal wounds: A scoping review

Juliana Maeda[1], Saskia Fleury[1 2], João Pedro Borges[3], Caroline Alcântara[1 4], Vera Lucia Conceição Gouveia Santos[1], Paula Nogueira[1]

[1]School of Nursing of University of São Paulo, São Paulo, Brazil, *[2]Convacare Clinic, São Paulo, Brazil*, *[3]School of Nursing of the University of São Paulo, São Paulo, Brazil*, *[4]Hospital Vila Nova Star - Rede D'Or, São Paulo, Brazil*

Aim: To map and analyze instruments and technologies for assessing the risk of infection in hard-to-heal wounds, available in the scientific literature.

Method: A scoping review was conducted following the Joanna Briggs Institute methodology. The guiding question was structured using the PCC strategy: Population: Chronic wound patients; Concept: Wound assessment tools and technologies; Context: Wounds at risk of infection. Searches were conducted in MEDLINE/PubMed®, CINAHL-Ebsco, Web of Science, Scopus, Embase, LILACS, and SciELO for papers published from 2014 to 2024 in English, Portuguese, and Spanish. Data were organized in the Rayyan application, in accordance with PRISMA-ScR guidelines. Two independent reviewers selected studies. Studies focusing on infection risk assessment tools for hard-to-heal wounds were included.

Results / Discussion: Of 13.441, 12 publications were included in the final sample. Identified studies comprised soft-hard technologies (58%), including risk assessment tools such as the WAR score and WIRE tool that assess local wound and systemic factors, alongside hard technologies (42%) such as fluorescence imaging and biomarker sensors. Despite advances in technologies and assessment tools for wound infection risk, challenges remain due to limited robust studies, high costs, and the need for standardization. Early identification and objective methods are vital to improving outcomes, guiding targeted interventions, and preventing unnecessary antimicrobial use.

Conclusion: The limited number of publications underscores the need for further research to develop innovative technologies and predictive models for infection risk in hard-to-heal wounds, as current tools are diverse and not standardized. The reliance on professional experience for risk identification may lead to varied approaches and complications, emphasizing the importance of establishing standardized assessment criteria to enhance diagnostic safety and optimize interventions.

EP375 End-stage skin failure: An AISLeC–SICP multisociety project for best practice in Italy

Valentina Vanzi[1 2], Rita Marson[3], Michela Guarda[4], Gianluca Castiello[5], Greta Ghizzardi[6]

[1]Research Interdepartmental Center for Research and Training (CIFAPPS), University of Rome Tor Vergata, Rome, Italy, *[2]Centre of Excellence for Nursing Scholarship (CECRI), Board of Nursing (OPI) of Rome, Rome, Italy*, *[3]Centro di Riferimento Oncologico – IRCCS Aviano, Pordenone, Italy*, *[4]Hospice S. Marco di Latina, Rome, Italy*, *[5]Intensive Care Unit and Surgical Department, IRCCS Policlinico San Donato, Milan, Italy*, *[6]Health Professions Directorate, Bachelor in Nursing Course, ASST Lodi, Lodi, Italy*

Aim: End-stage skin failure (ESSF) denotes cutaneous breakdown as a manifestation of multisystem decline near the end of life. Labels such as terminal ulcers, SCALE, and unavoidable pressure injuries reflect heterogeneous nomenclature and uncertain classification. Ongoing variability in terminology and difficulties in identification and assessment hinder surveillance and medico-legal clarity. This project offers practical guidance on recognising ESSF and aligning wound care with palliative care goals.

Method: A multisociety initiative (AISLeC–SICP) formed a joint working group. Methods included a targeted literature review, analysis of the Italian real-world context, and consultation with an international expert panel. Priority areas were identified via surveys and Delphi rounds to draft good-practice statements. Face and content validation in Italian was conducted in accordance with international guidelines for the translation/adaptation of tools for end-of-life skin assessment.

Results / Discussion: The AISLeC–SICP collaboration produced Italy-adapted good-practice recommendations and validated an Italian-language assessment tool. Best practices prioritise early whole-person assessment, prognosis-informed goals, comfort-focused care (including pain/odour), avoidance of non-beneficial interventions, clear documentation, interprofessional communication, and caregiver education.

Conclusion: Recognising ESSF reframes success from cure to comfort and dignity. Shared nomenclature, operational criteria, and pragmatic, nursing-led "less-is-more" guidance can standardise practice, reduce moral distress, and support equitable, person-centred care. Within this multisociety initiative (AISLeC–SICP), the collaborating scientific societies show how joint leadership can translate evidence into actionable recommendations that deliver concrete value for patients (less pain and burden, preserved dignity), professionals (a common language, more transparent medico-legal framework, reduced decisional conflict), and the health system (more appropriate resource use, consistent quality metrics, improved coding and surveillance).

EP376 Construction and validation of a multimodal prediction model for incision healing in single-port thoracoscopic surgery combining infrared thermography and visual imaging

Huiling Li[1], Minjie Ma[2], Hongying Jin[1], Xiaoyan Han[1]

[1]Gansu University of Chinese Medicine, The First Hospital of Lanzhou University, Lanzhou, China, *[2]The First Hospital of Lanzhou University, Lanzhou, China*

Aim: This study aims to develop a multimodal deep learning model that fuses smartphone-based visible light and infrared thermography (IRT) imaging to quantitatively predict healing outcomes of single-port VATS incisions, addressing the limitation of visual assessment in detecting deep tissue injuries.

Method: A prospective cohort of 200 single-port VATS patients was included. Standardized RGB and thermal images of incisions were collected on postoperative days 1, 3, and 7. A dual-stream CNN was developed to extract surface texture features from RGB images and thermal distribution patterns from IRT images. These features were fused for classification (Normal vs. Delayed/Infection). Performance (AUC, sensitivity, specificity) was compared against single-modality models and clinician assessment.

Results / Discussion: The multimodal model achieved superior predictive performance (AUC=0.92) compared to visual-only (AUC=0.78) and thermal-only (AUC=0.84) models. It identified 90% of delayed healing cases 48 hours earlier than visual signs appeared. Heatmaps indicated abnormal periwound temperature gradients, signifying subcutaneous inflammation from instrument traction, as key predictors.

Conclusion: The multimodal model provides a non-invasive, objective tool for early detection of healing complications in single-port VATS. By revealing subcutaneous inflammation through thermal-visual fusion, it enables timely intervention and personalized wound care, potentially reducing surgical site infections.

EP377 Near-infrared spectroscopy imaging to assess oxygen perfusion in wounds in comparison of polylactic acid treatment vs conventional treatment.

Mario Aurelio Martínez-Jimenez[1], Bertha Korhonen[2], Samuel Kolosovas-Machuca[1], Víctor Manuel Loza González[1], Ana Lorena Novoa-Moreno[1], Schira Ulmirch[1], Brocke Linden[1], Jose Ramirez-GarciaLuna[1]

[1]Hospital Regional De Alta Especialidad Dr. Ignacio Morones Prieto, Universidad Autónoma de San Luis Potosí, San Luis Potosí, Mexico, *[2]Faculty of Medicine at the University of Turku Finland, Turku, Finland*

Aim: Feasibility study was to determine if a non-contact, point-of-care near-infrared (fNIR) imaging device could provide an objective measure of wound resolution up to the time of closure with two types of treatment: conventional treatment (petroleum jelly gauze) vs. treatment with a polylactic acid membrane with follow-up visits once a week until wound closure.

Method: Patients included were treated at the Wound Clinic of the Central Hospital of San Luis Potosí, Mexico. Inclusion criteria were a time of evolution of 3 weeks, diameter between 2 and 5 cm, in any part of the body and any etiology, treated with PLA matrices or conventional treatment (jelly gauze).

Results / Discussion: The total patients was 63, 31 men and 32 women, mean age 48.57 years, 26 traumatic wounds, 10 pressure ulcers, 10 diabetic foot, and 17 with varicose ulcers, 46 superficial wounds, 17 deep wounds. Conventional treatment group consisted of 31 patients and 32 with the use of PLA. Initial mean wound oxygen was 76.12% (1.2 SD) in the conventional treatment group and 72.5% (1.5 SD) for the polylactic acid group, with p=0.5, Initial mean normal skin oxygen was measurend to 56.06% (1.1 SD) in the conventional group, and 59.43% (0.9 SD) in the PLA group, p= 0.05. Days of wound closure and days in which skin oxygen was equal to wound oxygen was 60.93 (5.5 SD) and 35.25 (2.9 SD), respectively (p= 0.05).

Conclusion: The incorporation of non-contact fNIR imaging at the point of care can help guide clinical decision-making to determine the optimal time to assess wound closure and to make decisions about the type of treatment a wound requires according to its progression.

EP499 Comparing subjective and infrared thermography-based temperature assessment in WASI score of chronic wounds

Eleni Kourtellari[1], Constantinos Koshiaris[2], Flavia Manzo Margiotta[3 4], Marco Romanelli[3], Valentina Dini[3], Christos C. Zouboulis[1]

[1]MVZ Dessau, Dessau, Germany, *[2]Department of Primary Care and Population Health, University of Nicosia Medical School, Nicosia, Cyprus*, *[3]Department of Dermatology, University of Pisa, Pisa, Italy*, *[4]Interdisciplinary Center of Health Science, Sant'Anna School of Advanced Studies, Pisa, Italy*

Aim: Wound Area Severity Index (WASI) is a clinical score designed to assess post-surgical wounds in hidradenitis suppurativa and predict healing time. It comprises four parameters: area, temperature, depth and wound bed condition, each graded 1-4, total score 4-16. This study evaluates whether WASI temperature parameter, assessed by palpation and comparison with contralateral healthy skin, provides an accurate estimate when compared with objective temperature measurements obtained using infrared thermography.

Method: In a cohort of chronic wound patients, demographic data, wound etiology and WASI score were recorded. In WASI, temperature is classified on an ordinal scale. Patients underwent non-invasive imaging using a VarioCAM® HD Head 880 MED / 30 mm camera (InfraTec, Dresden, Germany), a long-wave medical-grade infrared thermography system. Images of wound bed, perilesional and contralateral healthy skin were acquired. Temperature values were calculated as the mean of five repeated measurements and classified on ordinal WASI scale using literature-based cut-offs. Descriptive statistics summarized the sample and agreement between clinical and imaging-based classifications was quantified using Cohen's kappa (κ).

Results / Discussion: Twenty-one patients were recruited (mean age 80.5 years, SD 12.0; mean BMI 28.4 kg/m^2, SD 9.7); 71.4% were female. Wound etiologies included mixed arterial-venous (23.8%), venous (14.3%), post-surgical (14.3%), post-traumatic (4.8%), post-thrombotic (4.8%), pressure ulcers (33.3%) and pyoderma gangrenosum (4.8%). Using WASI, 38.1% of wounds were normothermic and 61.9% hypothermic. Agreement between thermography-based classifications and WASI was weak (κ=0.364 pressure ulcers; κ=0.385 other aetiologies).

Conclusion: WASI temperature assessment showed weak concordance with objective thermography (κ<0.50). Given the small cohort and narrow cut-offs, results should be interpreted cautiously. Larger studies are needed to validate these findings and determine whether thermography aligns with WASI temperature scoring.

EP378 Improving Precision in wound measurement: Traditional manual methods versus ai-powered assessment tools

Luis Gerardo Morales Galina[1], Priscila Cantú Saucedo[2]

[1]*Hospital Médica Campestre, León, Guanajuato, Mexico*, [2]*Essity Health & Medical México, Ciudad de México, Mexico*

Aim: To compare the accuracy, reliability, and clinical usability of traditional ruler-based wound measurement versus an AI-based digital wound assessment method in real-world clinical practice. This study presents a comparative analysis between manual measurement using a standard ruler and AI-based wound measurement to determine differences in accuracy, reliability, and efficiency during routine clinical assessment.

Method: A prospective comparative study was conducted in outpatient and inpatient wound-care settings. Adult patients with acute or chronic wounds of various etiologies were included. For each wound, two measurement approaches were performed consecutively

Manual measurement: Wound length and width were obtained using a standard disposable ruler, following routine clinical practice. Measurements were taken by two independent clinicians to assess inter-observer variability.

AI-based digital measurement: A digital wound-assessment application powered by an artificial intelligence algorithm was used to capture wound images and automatically generate surface-area estimations. Two clinicians captured images independently to compare consistency and replicability.

Results / Discussion: Primary outcomes: Measurement accuracy (difference in length, width, and calculated area) Inter- and intra-observer variability, Time required to complete measurement.

Secondary outcomes: Clinician satisfaction and perceived usability, Identification of workflow advantages or barriers.

Conclusion: AI-based wound measurement demonstrated greater consistency and reduced inter-observer variation compared with traditional ruler-based methods. Digital assessment also showed potential to improve accuracy in wounds with irregular shapes and to streamline workflow by reducing the time required per measurement.

While manual measurement remains accessible and familiar to clinicians, AI-powered tools may offer a more reliable and standardized approach to wound assessment, supporting improved clinical decision-making. Further large-scale studies are warranted to evaluate long-term outcomes, integration in clinical pathways, and impact on treatment optimization.

EP380 Enzymatic debridement with alginate gel in the management of chronic ulcers: A case series

Batuhan Dağli[1], Bahar Eren[1]

[1]*University of Health Sciences Gulhane Traingin and Research Hospital, Ankara, Türkiye*

Aim: To evaluate the clinical outcomes of enzyme and alginate gel treatment in patients with chronic ulcers resistant to conventional therapy.

Method: A case series of approximately 10 patients with chronic ulcers (venous, diabetic, and pressure ulcers) treated with enzymatic and alginate gel therapy. Patient demographics, wound characteristics, treatment protocols, healing progression, and adverse events were documented over [treatment duration].

Results/Discussion: Treatment with enzyme and alginate gel resulted in effective debridement of necrotic tissue and fibrin slough in all cases. Wound size reduction was observed in all of patients, with complete healing achieved in most cases. The treatment was well-tolerated with minimal adverse effects. Improved granulation tissue formation and reduction in wound exudate were noted consistently. Combined enzyme and alginate gel therapy represents a promising approach for chronic ulcer management, facilitating autolytic debridement while maintaining an optimal moist wound environment.

Conclusion: Combin enzyme alginate gel therapy is effective for chronic ulcer management. Further controlled studies are warranted to establish standardized protocols and compare outcomes with conventional treatments.

EP381 Prediction of individual risk of postoperative wound infection (POWI) in vascular surgery - epidemiology and comparison of predictive scoring systems in a university cohort

Maria Hovhannisyan[1], Polina Shabes[1], Waseem Garabet[1], Hubert Schelzig[1], Julian-Dario Rembe[1]

[1]University Hospital Duesseldorf, Heinrich-Heine University (HHU), Düsseldorf, Germany

Aim: Postoperative wound infections (POWI) are a common postoperative complication and cause of increased morbidity, mortality, and prolonged hospitalization. However, there is currently no valid method (e.g., scores) for predicting the risk of POWI in German-speaking countries. The aim of this study is to compare different scoring systems for predicting POWI.

Method: A retrospective case-control study was conducted. Cases from the last 10 years with POWI following vascular surgery were included and a matched control cohort without POWI was generated. A total of over 40 items in 7 scores were collected and compared. The data was analyzed epidemiologically, and correlation, sensitivity, and specificity analyses were performed to compare the scores with each other.

Results / Discussion: A total of 162 cases with POWI and a corresponding comparison cohort of 85 controls were included. The gender distribution in the POWI cohort was 59.9% men (n=97) and 40.1% women (n=65) with an average age of 67.6 years (±11.2). Sixty-three percent of patients with POWI were older than 65 years. Nearly one-third of patients with POWI (29%) had a BMI > 30 (grade I obesity). A strong positive correlation with POWI was also found for the presence of type 2 diabetes (45.7%), coronary heart disease (47.5%), nicotine abuse (51.9%) and, particularly strongly, PAD (71.6%).

Conclusion: Several of the scoring systems examined allow for a correlative prediction of the occurrence of postoperative wound infection. The Surgical Site Infection Risk Score (SSIRS) and the GIVE Risk Prediction Model proved to be particularly accurate. Although this retrospective analysis shows the possibility of significant prediction, further prospective studies are necessary to determine its applicability in everyday clinical practice.

EP383 Development and validation of a hypergranulation tool for clinical use

Leanne Atkin[1], David Bosanquet[2], Jacky Edwards[3], Julian Howell[4], Leanna Ruprai[4]

[1]Mid Yorks NHS Trust, University of Huddersfield, Huddersfield, United Kingdom, *[2]South East Wales Vascular Network, Research & Development department in ABUHB, Honorary senior lecturer at Cardiff University, Cardiff, United Kingdom*, *[3]Ingenium Wound Consultancy, Northern Burn Care Unit, Ellesmere Port, United Kingdom*, *[4]Ennogen Healthcare, Dartford, United Kingdom*

Aim: Hypergranulation (HG) is well documented and a known barrier to wound healing. Accurate clinical assessment of wounds is crucial in managing HG and evaluating treatment response. Currently there is no standardised assessment for HCPs to assess the severity of HG.

Method: We have developed a prototype Hypergranulation Tool to be used in clinical practice, through a Delphi process involving wound care clinical experts. The Hypergranulation Tool allows assessors to grade HG within wounds as mild, moderate and severe, based on 5 separate parameters. A prospective multi-site observational study based in the United Kingdom of 80-100 adult and paediatric patients with HG within venous leg ulcers (VLU) or complex surgical wounds (CSW) will allow performance testing of the Hypergranulation Tool. Tissue viability nurses will assess the wounds with the Hypergranulation Tool across 2-4 clinic visits.

Results / Discussion: Data from the use of the tool will be compared with quantitative 3D analysis, patient reported outcome and patient interview data to help determine the validity of the Hypergranulation Tool in the clinical setting.

Conclusion: Results from the Observational Study will inform design changes to the Hypergranulation Tool as well as the design of HG intervention trials.

English Oral presentations

ACUTE WOUNDS

OP136 The development and content validation of The International Skin Tear Advisory Panel (ISTAP) skin tear data collection tool (ISTAP DC-Tool™)

Anika Fourie[1], Samantha Holloway[2], Cinthia Da Silva[3], Dimitri Beeckman[1], Pía Molina Chailán[5], Julia Bresnai[4], Mary Hill[6], Kimberley LeBlanc[7], Emmy Nokaneng[8], Jennifer Prentice[9], Ray Samuriwo[10], Steven Smet[1], Karen Ousey[11], Kirsty Mahoney[12]

[1]Ghent University, Ghent, Belgium, *[2]Cardiff University School of Medicine, Cardiff, United Kingdom*, *[3]University of Sao Paulo, Sao Paulo, Brazil*, *[4]Musgrove Park Hospital, Somerset, United Kingdom*, *[5]Guillermo Grant Benavente Hospital Concepción, Concepción, Chile*, *[6]NSWOC Integrated Home Care, Calgary Alberta, Canada*, *[7]NSWOCC, Toronto, Canada*, *[8]University of Pretoria – Steve Biko Academic Hospital Complex, Pretoria, South Africa*, *[9]Trojan Health and Hall & Prior Health and Aged Care Group, Perth, Australia*, *[10]Edinburgh Napier University Scotland, Napier, United Kingdom*, *[11]University of Huddersfield, Huddersfield, United Kingdom*, *[12]Cardiff University, Cardiff, United Kingdom*

Aim: Numerous studies have examined the epidemiology of skin tears. However, inconsistencies in definitions, classifications, and data collection methods underscore the need for a validated data collection tool. This study aimed to validate a skin tear data collection tool to ensure its reliability for clinical and research use. A secondary aim was to make the tool freely accessible for healthcare providers and researchers.

Method: The tool was developed based on the 2018 ISTAP Best Practice Recommendations (BPR) for preventing, assessing, and managing skin tears in aged skin. From June to October 2024, a multi-method validation process was conducted. Content Validity Ratio and Content Validity Index (CVI) were calculated to measure content validity. Face validity was assessed through qualitative feedback from 15 experts, who also offered suggestions for refinement.

Results / Discussion: The final tool comprises 22 questions related to patient demographics, clinical characteristics of the skin tear, risk factors, and contextual data. A CVI of 0.72 indicated acceptable validity. A two-round qualitative review with international experts resulted in consensus and the tool has now been incorporated as part of the second edition of the ISTAP BPR published in 2025.

Conclusion: The ISTAP DC-Tool™ is an open-access, evidence-based data collection tool for skin tears, validated by international experts. It was developed to support healthcare providers and researchers in gathering epidemiological data to inform clinical practice, drive quality improvement initiatives, and advance research in skin tear prevention and management. Since its launch, there have been numerous international requests to use the tool for research, educational purposes, or clinical practice implementation. Access can be requested via https://www.skintears.org/resources

---

OP003 Applying moist wound healing in fractional laser resurfacing: An argument based on burn care principles for optimal results

Xiang Huang[1]

[1]Nanxishan Hospital, Guangxi Zhuang Autonomous Region, Guilin, China

Aim: Fractional laser creates microthermal zones (MTZs), effectively micro-burns. Despite moist healing being the gold standard for burns, its application to laser wounds lacks robust evidence. This trial therefore validates whether applying these burn care principles to laser wounds improves clinical outcomes.

Method: In this prospective, evaluator-blind RCT, 80 patients undergoing standardized CO_2 fractional laser treatment were randomized 1:1. The experimental group (n=40) received a specific burn ointment to maintain a moist MTZ environment, while the control group (n=40) received petrolatum gauze. Primary endpoints were: 1) 72-hour pain VAS-

AUC; 2) MTZ re-epithelialization rate by dermoscopy; 3) objective PIH incidence at 1 month (colorimeter L* value); and 4) skin texture and scar scores at 3 months.

Results / Discussion: Compared to the control group, the experimental group demonstrated statistically significant superiority across all predefined endpoints (P<0.01). The experimental group achieved a 45% reduction in VAS-AUC, indicating superior and more sustained pain control. The mean re-epithelialization rate of MTZs was accelerated by 25%. Furthermore, the incidence of post-inflammatory hyperpigmentation (PIH) was significantly lower in the experimental group (4.6%) than in the control group (18.5%). At 3 months, the experimental group also showed significantly better scores for skin smoothness and scarring (Vancouver Scar Scale).

Conclusion: This study validates applying moist burn care to laser wounds, establishing a new evidence-based paradigm. This approach achieves superior pain, regeneration, and aesthetics, demonstrating how interdisciplinary integration advances plastic surgery.

OP004 Clinical study on the treatment of multiple finger electrical burns with regenerative wound ointment combined with acellular dermal matrix

Jun Li[1]

[1]*Ningxia Medical University/Ningxia Hui Autonomous Region People's Hospital, Yinchuan, China*

Aim: To investigate the clinical efficacy of regenerative wound ointment combined with acellular dermal matrix (ADM) in the treatment of multiple finger electrical burns.

Methods: 43 patients with bilateral finger electrical burns (127 injured fingers) admitted from 2022 to 2025 were enrolled (Table 1). The observation group underwent wound preservation, exposed phalangeal drilling, and ADM coverage, followed by regenerative wound ointment at 2 weeks postoperatively. The control group received standard debridement and ADM coverage, with autologous skin grafting at approximately 4 weeks when granulation tissue was adequate.

Results: Scar evaluation was performed using the Vancouver Scar Scale (VSS), including melanin, height, vascularity, and pliability; higher scores indicated more severe scarring (Table 2).

Conclusion: Regenerative wound ointment combined with ADM significantly shortens healing time, maximizes finger length preservation, reduces amputation and scarring, and improves finger function. This regimen is safe, effective, and clinically valuable for the management of digital electrical burns.

Table 1

Group	Damage current (n)		Number of Cases(n)	The number of injured fingers (n)
	<1000V	>1000V		
Observation group	20	1	22	64
Control group	21	1	21	63

Table 2

Group	Healing time (d)	1-month post-op VSS	3-month post-op VSS	Amputation of fingers/rate (n/%)
Observation group	11.50±0.58	5.33±0.33	1.83±0.37	1/1.57%
Control group	13.25±0.5	7.75±0.48	4.58±0.29	5/7.94%
P value	<0.05	<0.01	<0.01	<0.01



Case 1 Electrical Burns on Left Hand



Case 2 Electrical Burns on Both Hands

OP007 Healing trajectories and risk factors post-surgical abscess drainage

Joseph Wei Ern Teo[1], Ren Hong Por[1], Shaun Chan[2], Sadhana Chandrasekar[2], Chee Wei Lee[2], Zhiwen Joseph Lo[2]

[1]Singapore, Singapore, *[2]Woodlands Health Wound and Vascular Centre (Singapore), Singapore, Singapore*

Aim: This study aims to analyse and determine the demographic and clinical factors affecting the rate of abscess wound healing post-surgical drainage in a tertiary healthcare institution.

Method: From May 2024 to July 2025, 1033 patients underwent skin and subcutaneous tissue surgery at our institution. From these, 229 patients with 240 abscesses were selected. Inclusion criteria comprised patients with abscesses located at the neck, shoulder, axilla, breast, chest wall, abdomen, umbilicus, back, gluteal, and lower limb

regions that underwent surgical drainage, and followed up with documented healing of abscess cavity. Exclusion criteria comprised patients with genital, head, or foot abscesses. Clinical data of each patient was studied against the duration of wound healing using univariate and multivariate analysis.

Results / Discussion: 105 female and 124 male patients were included. Median age was 51 years. Median abscess area, cavity area, and days to healing were 11.78cm^2, 7.46cm^2, and 45 days respectively. Age, diabetes mellitus, hyperlipidemia, total white cell counts, C-reactive protein, latest HbA1c ≥ 8.0, abscess location, packing, culture, abscess area, cavity area, were all statistically significant ($p<0.05$) in affecting days to healing after univariate analysis. Back (n=83), gluteal (n=33), and axilla (n=33) abscesses were the most common. Abscesses packed with chlorhexidine-soaked ribbon gauze or Kaltostat, and MSSA-positive abscesses had the longest median days to healing. After multivariate analysis, only fever and cavity area post-surgery were statistically significant ($p<0.05$) in increasing the median days to healing after correcting for other variables.

Conclusion: For patients who underwent surgical abscess drainage, the mean duration to wound healing was 8.90 days per cm^2 of cavity area. Cavity area and fever are independently associated with increased post-surgery wound healing time.

Table 1: Welch's t-test of Categorical Variables

		Median Days to Healing (n ± IQR)	t-value	p-value	95% CI
Gender (n=240)	Male	44 ± 30	-1.53	0.128	-13.76, 1.74
	Female	45 ± 22.2			
DM (n=240)	No	42 ± 26	-2.56	**0.0112**	-18.34, -2.38
	Yes	51 ± 26			
Latest HbA1c >= 8.0 (n=155)	<8.0	45 ± 22.5	-2.15	**0.0354**	-21.80, -0.80
	>=8.0	54 ± 29			
Hypertension (n=240)	No	42 ± 25	-0.98	0.329	-11.45, 3.85
	Yes	49 ± 23.5			
Hyperlipidemia (n=240)	No	42 ± 25.5	-2.09	**0.0374**	-16.23, -0.49
	Yes	50 ± 24			
ESRF (n=240)	No	44 ± 24	-1.25	0.234	-23.35, 6.27
	Yes	63 ± 26			
IHD (n=240)	No	43 ± 23	-2.07	0.0546	-27.42, 0.30
	Yes	65 ± 14			
Fever (n=240)	No	43 ± 24	-1.99	0.0551	-41.92, 0.48
	Yes	55 ± 23			
Raised TW (>10.0x10$^9/L$) (n=222)	No	43 ± 24	-2.49	**0.0141**	-21.26, -2.43
	Yes	49 ± 29.5			
Raised CRP (>9.1mg/L) (n=136)	No	47 ± 22.5	-2.21	**0.0287**	-23.35, -1.30
	Yes	48 ± 29			

Table 2: Spearman's Correlation of Continuous Variables

	Median (n ± IQR)	Median Days to Healing (n ± IQR)	Spearman's rho	p-value	95% CI
Age (n=240)	51 ± 27	45 ± 25	0.182	**0.00467**	0.05, 0.31
BMI (n=202)	26.75 ± 7.53	45 ± 28.5	0.0320	0.650	-0.12, 0.18
Duration (days) (n=228)	7 ± 13.5	45 ± 25	0.0140	0.839	-0.13, 0.15
Abscess Area (n=236)	11.78 ± 13.98	45 ± 25	0.297	**3.49×10^{-6}**	0.17, 0.42
Cavity Area (n=222)	7.46 ± 11	45 ± 25.75	0.337	**2.59×10^{-7}**	0.21, 0.47

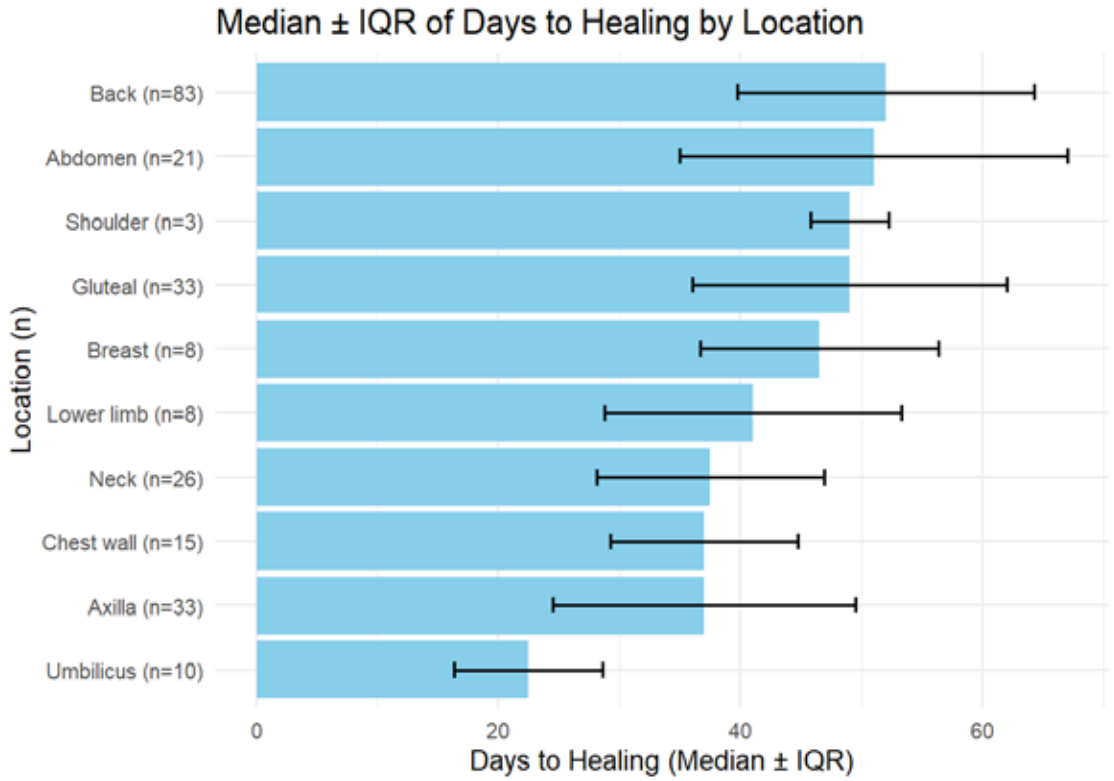
Median ± IQR of Days to Healing by Location
Back (n=83)
Abdomen (n=21)
Shoulder (n=3)
Gluteal (n=33)
Breast (n=8)
Lower limb (n=8)
Neck (n=26)
Chest wall (n=15)
Axilla (n=33)
Umbilicus (n=10)
Location (n)
0
20
40
60
Days to Healing (Median ± IQR)

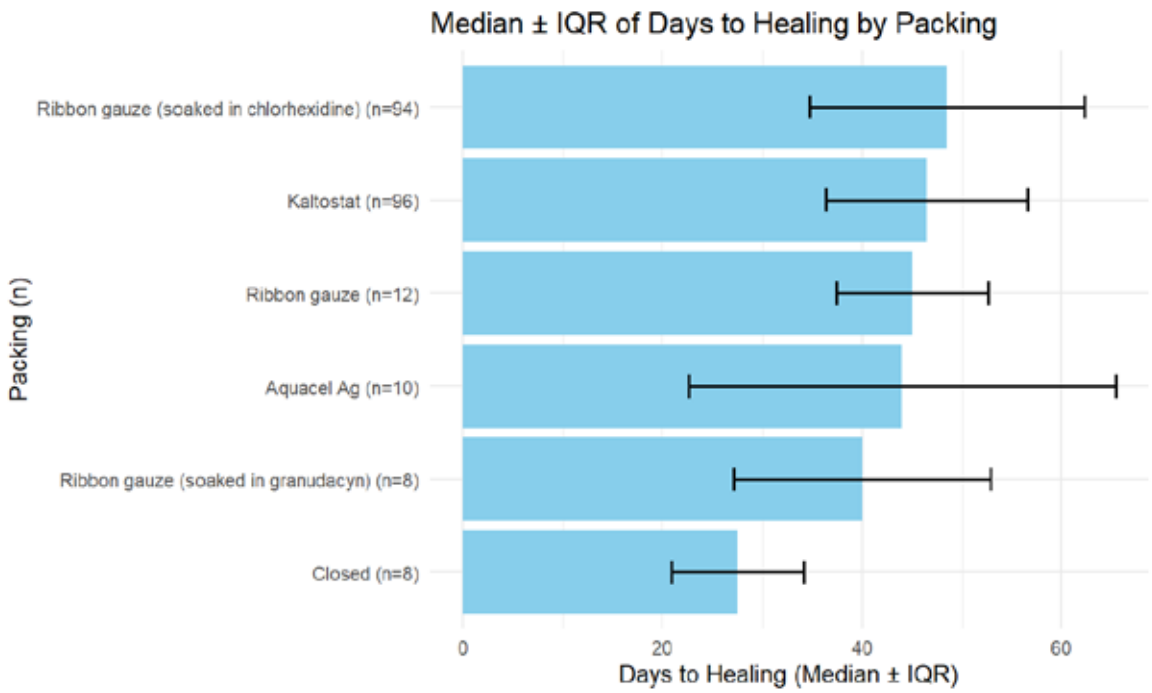
Median ± IQR of Days to Healing by Packing
Ribbon gauze (soaked in chlorhexidine) (n=94)
Kaltostat (n=96)
Ribbon gauze (n=12)
Aquacel Ag (n=10)
Ribbon gauze (soaked in granudacyn) (n=8)
Closed (n=8)
Packing (n)
0
20
40
60
Days to Healing (Median ± IQR)

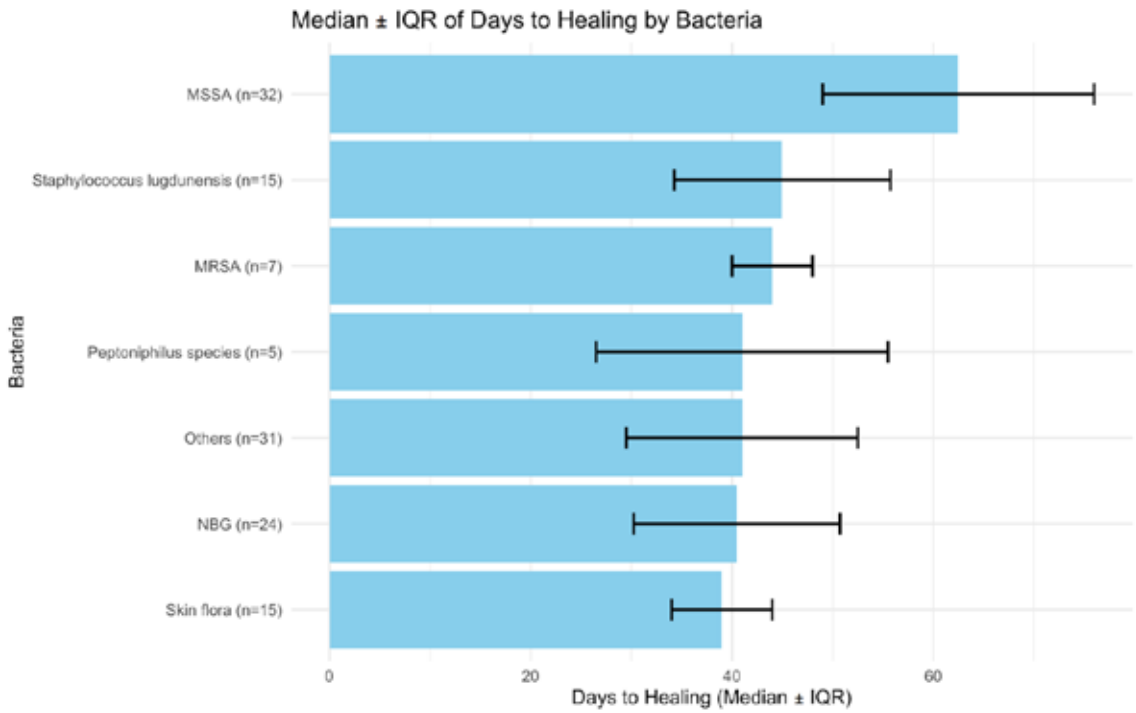

OP008 Invisible infections and infrared thermography: A pilot and feasibility study evaluating the utility of infrared thermography in predicting surgical site infections in acute, closed surgical wounds

Shreya Bhatt[1 2], Natalia Rios Turek[2], Arthur Lim[1 2], Bharadhwaj Ravindhran[1 2], Ian Chetter[1 2], Daniel Carradice[1 2], George Smith[1 2]

[1]Academic Vascular Surgical Unit, Hull, United Kingdom, *[2]Hull University Teaching Hospitals NHS Trust, Hull, United Kingdom*

Aim: To evaluate the utility of infrared thermography (IRT) in predicting surgical site infections (SSI) in acute surgical wounds.

Method: A prospective cohort study was conducted at a tertiary vascular unit over 4 months. Consecutive consenting adults undergoing clean/clean-contaminated lower limb surgery with primary wound closure were included. IRT was performed pre- and post-operatively on day 0, 2, 4 etc until discharge. The primary outcome was feasibility of perioperative IRT in vascular surgery (ease of use and acceptability to patients). Secondary outcomes included SSI within 30 days of procedure and IRT features correlating with severity of SSI (readmission, further antibiotics/surgeries).

Results / Discussion: 60 patients were recruited into the study. Median age was 70(35-76), 82.3% were male, 100% were Caucasian and 67% were current/previous smokers. The most common diagnoses were chronic limb ischaemia (61.3%), claudication (24.4%) and aneurysms (8.1%). Operations included lower limb bypass (32.3%), major amputation (29.1%) and femoral endarterectomy (19.4%). All patients received prophylactic antibiotics for 2(2-3) days. 49 patients were followed up at 30 days (3 deaths, 8 lost to follow-up). 8(16.3%) had diagnosed SSI by a GP/surgeon with 2(4.1%) readmissions and 2(4.1%) reoperations. All patients with SSI had visible cold spots in wounds compared to a healthy reference area, in the early postoperative period (D0-D5). All patients reported IRT was acceptable in routine clinical practice.

Conclusion: Early diagnosis of SSI remains a significant challenge. This study provides evidence that perioperative IRT is feasible and can detect changes preceding visible SSI. However, the trial is limited by low numbers of SSI and the loss to follow up (18.3%). Further, larger studies are needed to assess the role of IRT in SSI screening.

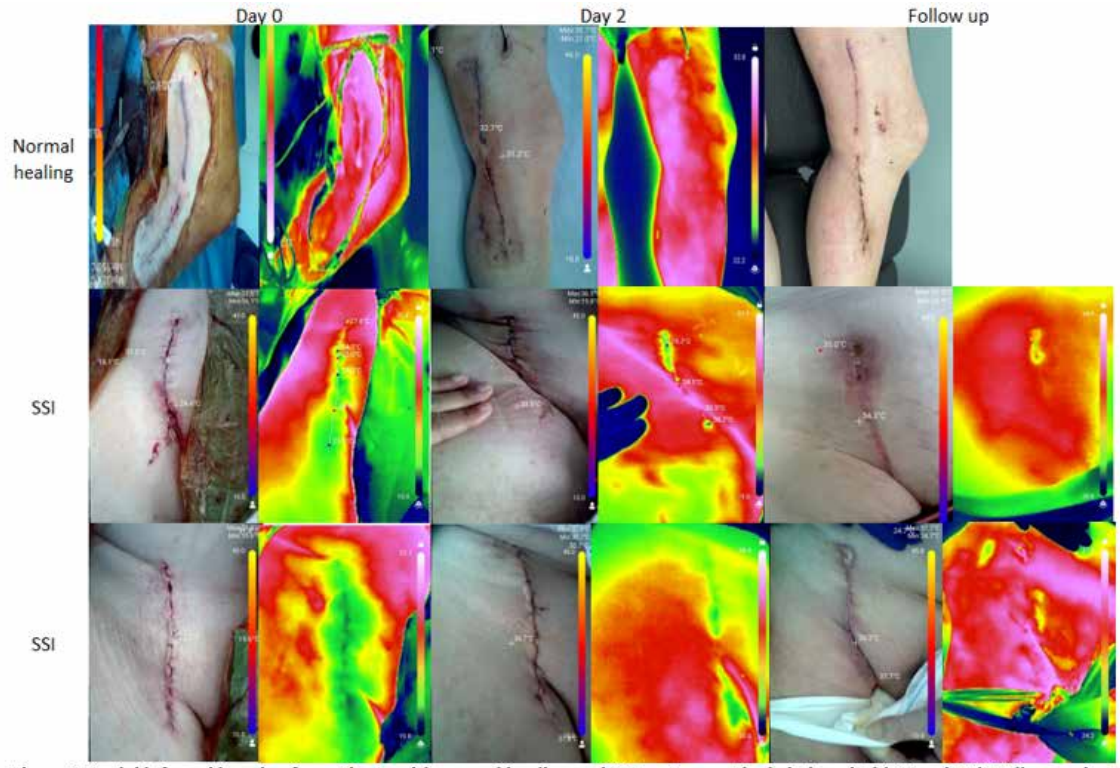

Figure 1: Serial infrared imaging for patients with normal healing and SSI post-operatively in hospital (D0 and D2). Follow up image for normal healing was taken at outpatient clinic on D30. Follow up infrared images taken for wounds that were readmitted to hospital with SSI.

OP009 Comparison of a macrophage-regulating topical agent (ON101) and Biodegradable Temporizing Matrix for small to moderate traumatic wounds

Dun Hao Chang[1], Jui-Ching Chen[2]

[1]Far Eastern Memorial Hospital, National Yang Ming Chiao Tung University, New Taipei City, Taiwan, *[2]Oneness Biotech, Taipei, Taiwan*

Aim: A macrophage-modulating topical agent (ON101) has demonstrated efficacy in diabetic foot ulcers, yet its role in traumatic wounds remains unclear. This study compares ON101 with a dermal substitute, Biodegradable Temporizing Matrix (BTM), in treating small to moderate traumatic full-thickness skin defects.

Method: Between January 2024 and August 2025, patients with traumatic full-thickness wounds were prospectively enrolled. Exclusion criteria were wound size >40 cm^2 or the need for autologous skin grafting. Patients were assigned to ON101 or BTM treatment based on clinical decision-making. The ON101 group applied the topical agent twice daily, whereas the BTM group underwent matrix implantation with silicone removal at 3–4 weeks followed by standard wound care. Demographics, wound characteristics, healing time, and complications were documented and analyzed.

Results / Discussion: Thirty-four patients were included: 11 treated with ON101 and 23 with BTM. Baseline characteristics, including age, sex, and wound size, were comparable across groups. The ON101 group demonstrated significantly faster wound healing compared with BTM (37.5 ± 20.0 vs. 65.2 ± 24.0 days, p = 0.002). Infection occurred less frequently with ON101 (9.1% vs. 26.1%), although this trend did not reach statistical significance (p = 0.38). The observed difference in healing time suggests a potential therapeutic advantage associated with macrophage regulation in traumatic wound management.

Conclusion: ON101 provided significantly shorter healing times and a trend toward lower infection rates compared with BTM in small to moderate traumatic wounds. These findings indicate that ON101 may serve as an effective, minimally invasive alternative to dermal substitutes for selected cases. Further studies with larger cohorts are needed to confirm these outcomes and guide treatment selection.

ATYPICAL WOUNDS

OP010 Neoplastic foot ulcers: A multicenter retrospective sudy

Agata Janowska[1], Valentina Dini[1], Marco Romanelli[1], Antonella Vietina[2], Paola Monari[3], Alessia Paganelli[4]

[1]Dermatology, University of Pisa, Pisa, Italy, *[2]Direzione Area Medicina, Pisa, Italy*, *[3]Dermatology, IRCCS Policlinico San Matteo Fondation, pavia, Italy*, *[4]Istituto Dermopatico dell'Immacolata – Istituto di Ricovero e Cura a Carattere Scientifico (IDI-IRCCS), Rome, Italy*

Aim: Our study aimed to define neoplastic foot ulcers based on patient demographics, clinical features, and histology to facilitate early diagnosis.

Method: We performed a multicenter, retrospective study analyzing clinical and histological data, focusing on neoplastic foot ulcers collected over the past 5 years.

We evaluated patients' demographic characteristics, clinical features, histological diagnosis, tumor onset, and ulcer site. Statistical analyses were conducted using SPSS software, v.30.

Results / Discussion: In total, 106 patients affected by foot skin ulcers were enrolled in the present protocol (52 women, 54 men). The mean age was 70.15 years. In most cases, the neoplastic ulcer was due to primary tumor ulceration. The dorsum of the foot was the most frequent location for neoplastic ulcers (66%). From a clinical perspective, most lesions were classified as ulcerated nodules (n=58), ulcerated plaques (n=8), or hypergranulating ulcers (n=25), all with thickened, atypical edges. Histological diagnoses included melanoma (n=45), non-melanoma skin cancers (n=34), benign tumors (n=18), and rarer malignancies (n=9). A statistically significant correlation was found between the histotype and the type of clinical lesion and between age and histotype. Median Breslow thickness for melanoma cases was 5.46 mm for dorsal localization and 5.68 mm for plantar localization. In 11 cases of melanoma, there was a history of previous trauma. Clinical presentation can provide clues to the suspected histology of neoplastic ulcers. All tumors originating from chronic ulcers were hypergranulating ulcers, whereas in primary tumors, we observed three distinct clinical aspects.

Conclusion: While typical foot ulcers have been extensively described in scientific literature, neoplastic foot ulcers are poorly characterized. The study provided preliminary data on the clinical and histological characteristics.

OP137 The lived experience of healthcare professionals caring for individuals with maligant fungating wounds

Susy Pramod[1], Vishnu Renjith[2], Samantha Holloway[3]

[1]The Christie NHS Foundation Trust, Cardiff University, Manchester, United Kingdom, *[2]Royal College of Surgeons in Ireland, Dublin, Ireland*, *[3]Cardiff University Schools of Medicine, Cardiff, United Kingdom*

Aim: The study aimed to explore the lived experiences of healthcare professionals (HCPs) caring for individuals with malignant fungating wounds (MFW), focusing on the emotional impact, unique perspectives, and coping strategies they employed.

Method: Drawing on Husserl's descriptive phenomenology approach, data were collected through semi-structured interviews with 10 purposively selected participants from a major cancer center in the UK. Ethics approval and informed consent were obtained prior to data collection.

Results / Discussion: The data were analysed using Colaizzi's seven-step method, which focused on understanding people's lived experiences. Colaizzi's seven-step analysis involved familiarisation, extracting significant statements, interpreting meanings, clustering themes, creating a comprehensive description, establishing the essential structure, and verifying that structure. Key meanings were derived from participants' significant statements, grouped into theme clusters, and then merged into overarching themes. Eight overarching themes emerged from the data analysis:1) Facing emotional strain while witnessing patients suffering 2) Acknowledging patients' concerns and providing compassionate support 3) Impact of wound odour on HCPs 4) Complexities in providing MFW care 5) Supporting

patients with kindness, transparency and holistic understanding 6) Emotional demands and resilience 7) Harmonising personal feelings with outward positivity 8) Empowering clinicians through training, skills and guidelines for MFW care.

Conclusion: The study shed light on the emotional and physical demands faced by HCPs when caring for individuals with MFW, underscoring the importance of resilience and the supportive role of multidisciplinary teams. Persistent issues like inadequate communication and fragmented care remain barriers to effective management. The study recommended wellbeing support and specialised training, alongside evidence-based guidelines, to unify national standards with local needs and ensure access to treatment

OP012 Infection under control?! Influence of wound antiseptics and wound irrigation solutions on regeneration processes in human ex vivo wound models

Sophie Charlotte Liegenfeld[1], Nele Pelzer[1], Mandy Dittmer[1], Nicolas Krüger[1], Arianna Delle Coste[2], Jan Tinson Strenge[2], Sophie Charlotte Rhode-Wedrich[3], Univ-Prof. Dr. Ewa Klara Stürmer[1]

[1]University Medical Center Hamburg-Eppendorf, Department of Vascular Medicine, Hamburg, Germany, *[2]University Medical Center Hamburg-Eppendorf, Department of Oral and Maxillofacial Surgery, Hamburg, Germany*, *[3]University Medical Center Hamburg-Eppendorf, Department of Plastic, Reconstructive and Aesthetic Surgery, Hamburg, Germany*

Aim: Chronic wounds are a growing socioeconomic problem and are often treated locally with antiseptics and wound irrigation solutions. These have different biocompatibility indices, determined by typical *in vitro* analyses, often showing favorable results regarding cytotoxicity toward human cells. However, especially with prolonged use (>14 days) they show delaying effects on wound healing in chronic wounds patients and harmful effects on surrounding human skin have been described in clinical practice. We investigated these differences in a translational setting using human skin.

Method: To evaluate the effects of wound irrigation solutions (NaClO/HClO) and antiseptics (octenidine [di] hydrochloride, PHMB) on wound healing, *ex vivo* models from human abdominoplasties were used. Skin punches with a central wound (2 mm) were created and—following clinical practice—treated every 48 hours with wound irrigation solutions/antiseptics. The effects were assessed histologically and immunohistochemically using H&E staining, TUNEL assay, and Ki67 staining.

Results / Discussion: A correlation between strong antimicrobial efficacy and a certain degree of cytotoxicity was demonstrated, contrary to claims. Due to their lack of residual activity (substantivity), the hypochlorous solutions (NaClO/HClO) showed lower cytotoxicity than the tested antiseptics. The latter, however, did not significantly delay the healing process, even though their biocompatibility index might suggest otherwise.

Conclusion: The differing effects of antiseptics on 2D cell cultures *in vitro* and in the human *ex vivo* model show *that in vitro* testing alone is insufficient to capture the full range of potential (negative) effects of antiseptics. In approval processes for wound-care products, a translational “human milieu” as a test setting should be mandatory. Antiseptic remanence and penetration in the wound bed may be favorable in continuously inhibiting bacterial grow and biofilm formation.

OP013 Retinal microvascular changes in patients suffering from Martorell hypertensive ulcers

Jesse Karppinen[1 2], Paula Summanen[3], Kirsi Isoherranen[2 4], Niina Matikainen[2 5]

[1]Helsinki University Hospital, Helsinki, Finland, *[2]University of Helsinki, Helsinki, Finland*, *[3]Helsinki University Hospital, Ophthalmology, Helsinki, Finland*, *[4]Helsinki University Hospital, Dermatology, Wound Clinic, Helsinki, Finland*, *[5]Helsinki University Hospital, Endocrinology, Helsinki, Finland*

Aim: We sought to characterize the retinal microvascular changes in patients suffering from hypertensive ischemic lower leg ulcer of Martorell (HYTILU).

Method: In this prospective, single-center cohort study, 17 patients suffering from HYTILU were recruited upon diagnosis. Retinal fundus photography was performed to characterize microvascular abnormalities. These were studied and graded for signs of diabetic and hypertensive retinopathy as well as arteriolosclerosis. Additionally, semi-automated software (Vesselmap, Imedos) was used to evaluate arterio-venous ratio (AVR). Results were compared with 66 age-matched controls without lower leg ulcers.

Results / Discussion: The mean age of patients suffering from HYTILU and controls in our study were 76,6 and 72,5 respectively. 82,4% (n=14) of patients had signs of hypertensive retinopathy grades 1-3, 64,7% (n=11) had retinal arteriolosclerosis stages 1-3 and 41,2% (n=7) presented with both. One patient had diabetic retinopathy. A reduced AVR (mean 0,75) was seen in patients suffering from ulcers. Regardless of the pathological changes in the retinal microvasculature, none of the findings statistically differed from the control group.

Conclusion: The study demonstrates that patients suffering from HYTILU commonly present with a variety of retinal microvascular abnormalities. However, the nature or severity of these changes did not suggest an association with HYTILU. Though fundus photography remains an efficient tool for evaluation for diabetic retinopathy, it does not seem to bring any additional value to diagnosis or follow-up of patients suffering from HYTILU.

OP015 Based on “Promoting pus discharge and removing necrotic tissue,” “Cultivating pus to promote granulation,” and “Skin smoothing and tissue regeneration” to treat postoperative wound healing of perianal

Shiyong Xin[1]

[1]Department of Proctology, The Second Affiliated Hospital of Liaoning University of Traditional Chinese Medicine, Liaoning, China

Aim: This study explores the mechanisms of action and clinical efficacy of a herbal ointment with regenerative properties, to verify whether it can reduce post-operative pain and shorten healing time, therefore providing new treatment ideas for postoperative wound management.

Method: A randomized controlled trial was conducted with 300 post-anorectal surgery patients enrolled. Patients were randomly divided to experimental group (n=200, treated with regenerative herbal ointment) and control group (n=100, treated with Traditional Chinese Medicine ointment-a standard of care for post-anorectal surgery patients in our hospital).

Clinical outcomes included anal pain, which was measured by using the Visual Analog Scale (VAS) on postoperative day 1, 7, 14; wound size on postoperative day 1, 14, 21; granulation tissue size on day 5, 7, 14.

Results / Discussion: The experimental group showed significantly lower VAS scores, smaller wound size, and faster granulation tissue growth compared with the control group (Table 1,2,3).

Table 1 Postoperative VAS score (points)

Group	Day 1	Day 7	Day 14
Experimental group	4.16 ± 1.99	2.26 ± 1.67	1.02 ± 1.15
Control group	5.27 ± 2.14	3.46 ± 1.66	3.46 ± 1.66

Table 2 Wound size (cm^2)

Group	Day 1	Day 14	Day 21
Experimental group	3.88 ± 2.49	1.07 ± 1.37	0.33 ± 0.71
Control group	3.59 ± 2.37	1.58 ± 1.76	0.75 ± 1.45

Table 3 Granulation tissue size (cm^2)

Group	Day 5	Day 7	Day 14
Experimental group	1.6 ± 0.54	1.53 ± 0.57	1.13 ± 0.62
Control group	1.39 ± 0.54	1.3 ± 0.68	0.8 ± 0.7

Conclusion: This regenerative herbal ointment maintains a moist healing environment and provides a protective barrier on wound therefore reducing post-operative pain, and it also provides nutrients to promote granulation tissue growth. This study results indicated that this ointment can be a valid and effective alternative for treating peri-anal wounds after anorectal surgery.

BASIC SCIENCE

OP119 Biopsy-integrated multi-omics reveals host-microbe interactions underlying chronic wound healing outcomes

Tim Jakobsen[1], Isabel Diaz-Pines Cort[1], Oana Palasca[1], Blaine Fritz[1], Anne Iversen[2], Klaus Kirketerp-Møller[3], Thomas Bjarnsholt[1]

[1]University of Copenhagen, Copenhagen, Denmark, *[2]Amager and Hvidovre Hospital, Hvidovre, Denmark*, *[3]Bispebjerg Hospital, Copenhagen, Denmark*

Aim: Although the chronic wound microbiome has been extensively characterized, the mechanisms by which microbial colonization and host responses influence wound progression and healing remain underreported. This study aims to define the host–microbe interactions that shape wound outcomes through in-depth, multi-layered analysis of tissue biopsies.

Method: Samples were collected as part of the Chronic Wound Characterization (CWC) study, a prospective observational cohort study including 12 patients undergoing surgical debridement and split-thickness skin grafting (STSG). To dissect molecular determinants of wound healing, we performed dual RNA-sequencing, targeted proteomics, and 16S rRNA sequencing. Longitudinal biopsies were obtained from wound centre, wound edge, debrided tissue, and healthy donor skin. I parallel, bacterial isolates from each timepoint were subjected to whole-genome sequencing and phenotypic characterisation. Tissue sections were used to visualize spatial bacterial distribution.

Results / Discussion: Transcriptomic and proteomic analysis revealed strong site-specific inflammatory signatures. Notably, patients with poor healing exhibited increased inflammation-related gene expression in donor skin but marked suppression of inflammatory pathways within the wound compared to good healers. These findings indicate site-specific immune regulation, where reduced pro-repair inflammation within the wound and heightened inflammation in healthy skin associate with poor healing. Phylogenomic analysis of cultured isolates (e.g., *Pseudomonas aeruginosa*) confirmed long-term persistence of single clonal lineages.

Conclusion: Our data show that tissue-specific immune regulation, rather than overall inflammatory burden, distinguishes good from poor healing outcomes, and that stable microbial communities persist within individual wounds. These findings underscore the value of biopsy-integrated multi-omics analyses for revealing mechanisms that influence healing trajectories and may guide the development of biomarkers or targeted therapeutic strategies.

OP120 Hypoxia as a driver of chronic inflammation: Functional mapping of macrophage polarisation in an immune-competent 3D wound system

Marah Roth[1], Qvarnaki Suppiyar[1], Wiebke Ibing[1], Waseem Garabet[1], Hubert Schelzig[1], Julian-Dario Rembe[1]

[1]University Hospital Duesseldorf, Heinrich-Heine University (HHU), Düsseldorf, Germany

Aim: Chronic wounds are characterised by persistent inflammation, impaired oxygen supply and dysregulated macrophage function. Hypoxia represents a central barrier to regeneration by sustaining M1-dominant inflammatory signalling, suppressing angiogenesis and delaying matrix deposition. To date, the mechanistic contribution of immune-regulatory cells and mediators under hypoxic conditions remains insufficiently understood. This project investigates how controlled hypoxia influences wound regeneration and immune dynamics in a fully immunocompetent 3D human wound model.

Method: An established 3D organotypic wound model composed of collagen-embedded fibroblasts, stratified keratinocytes and THP-1-derived macrophages (M0, M1, M2) were wounded and subsequently exposed to defined hypoxic conditions (1–3 % O_2) to replicate a chronically inflamed, vascularly compromised wound bed. Hypoxia-induced responses were quantified through gene and protein expression of HIF-1α, VEGF, endostatin, CCL2 and macrophage polarization markers (CD86/CD206).

Results / Discussion: Hypoxia accelerated M1 persistence and suppressed M2-associated resolution. In histological evaluation (HE staining), models under hypoxic conditions demonstrated delayed regeneration and increased pro-inflammatory marker profiles. Significantly elevated CD86/CD206 ratios were observed within the first 2 days after wounding under hypoxic conditions ($p<0.01$), while during the subsequent 5 days, ratio significantly declined, indicating successive cellular and model decay after initial pro-inflammatory peak. Especially M1-models thereby demonstrated significantly elevated levels of pro-inflammatory markers such as CCL2 or IL-1beta compared to normoxic conditions ($p<0.0013$).

Conclusion: This work provides a clinically relevant, ethically viable human 3D platform to investigate oxygen-dependent immune dysfunction without reliance on animal models. The model validity was demonstrated and displayed relevant pro-inflammatory, anti-regenerative microenvironment changes characteristic of hypoxic wounds. Understanding hypoxia-linked macrophage regulation and regenerative arrest could open translational pathways for targeted therapeutic immunomodulation in chronic ischemic ulcers.

BURNS

OP001 Effect of autologous fat transfer on acute burn wound healing: A randomized controlled trial

Ahmed Mohamed Abouzaid[1]

[1]*El-Gomhoria general hospital, Ministry of Health of Egypt, Louran Hospital, Private practice, Alexandria, Egypt*

Aim: To find a new modality that can improve burn wound healing with minimal scarring as well as less donor site morbidity.

Method: The study was a prospective, open-label single center, randomized control clinical trial included 100 patients with superficial and deep dermal burns from March 2019 to March 2020 randomized to AFG protocol consisted of a single injection of autologous fat grafting then dressed with nano fat (Group A) or conventional methods (Group B). Inclusion criteria included newly admitted burn patients with affected total body surface area (TBSA) (10%–25%) while exclusion criteria included burns patients with loss of subcutaneous fat, fascia, muscles and bones, inhalational burn, and burns in genitalia, perineum and peri-anal areas and co-morbidity(ies). Also, results were confirmed by histological analysis for samples from both groups by light microscopic examination, and flow cytometric analysis of the cluster of differentiation (CD) markers of mesenchymal stem cells markers CD 90, CD44, CD45, CD 73, and CD 34. (ClinicalTrials.gov Identifier: NCT03791710).

Results / Discussion: We found a significant reduction in total hospital stay days ($p = < 0.001$), less further skin grafting ($p = 0.003$), less contracture formation ($p = < 0.002$) improved scar texture ($p = < 0.001$) in group A compared to group B.

Conclusion: In a comparison between AFG protocol to the conventional methods in the treatment of acute burn wounds, AFG protocol was associated with significant clinical improvement in the form of lower hospital stay time, lower incidence of scaring or contracture and lower skin grafting use which was confirmed by serial photographic and histological assessment.

OP002 Wound healing effectiveness of Peperomia pellucida nanoemulsion compared with moist ointment and silver sulfadiazine in a rat burn model

Arya Prananda[1]

[1]*Faculty of Medicine Universitas Sumatera Utara, Adam Malik General Hospital Medan, The Clinic Beautylosophy, Medan, Indonesia*

Aim: To evaluate the wound healing effectiveness of *Peperomia pellucida* nanoemulsion (PPNE) compared with standard topical therapies—moist ointment and silver sulfadiazine—in a rat burn model, and to explore its potential as a novel plant-based therapy.

Methods: Thirty male Wistar rats were randomized into six groups (n = 5 each): normal control, negative control (untreated burns), moist ointment, silver sulfadiazine, PPNE 3%, and PPNE 5%. Standardized full-thickness burn wounds (1.5 cm) were created on the dorsum under anesthesia. Treatments were applied daily. Wound healing was assessed on days 3, 7, 14, and 21 by contraction rate, epithelialization time, histology (granulation, angiogenesis, collagen), and infection. Data were analyzed using ANOVA with post hoc testing.

Results: PPNE groups showed superior healing compared with standard therapies. By day 14, wound contraction reached 93% with PPNE 5% and 90% with PPNE 3%, versus 78% with moist ointment, 74% with silver sulfadiazine, and <70% in the negative control ($p < 0.05$). Complete epithelialization occurred fastest with PPNE 5% (14.8 ± 1.0 days) and PPNE 3% (15.4 ± 1.1 days), compared with moist ointment (18.0 ± 1.4) and silver sulfadiazine (19.0 ± 1.6). Histology confirmed denser collagen, more mature granulation, and higher vascularity in PPNE groups. No infections occurred.

Conclusions: PPNE, especially at 5%, significantly outperformed moist ointment and silver sulfadiazine by accelerating contraction, epithelialization, and tissue maturation. This provides the first experimental evidence supporting PPNE as an effective plant-derived nanoformulation for burn wound healing, with translational potential as an innovative and accessible adjunct in wound care.

OP005 Experience of moist healing strategy in treating severely burned patients

Xingang Wang[1]

[1]*The 2nd Affiliated Hospital of Zhejiang University School of Medicine, Hangzhou, China*

Aim: To explore the application value and key implementation points of the moist healing strategy in the early treatment of large-area burns, so as to optimize the treatment process and improve the prognosis of patients.

Method: Based on the moist healing and wound microenvironment balance theory, clinical data of patients with large-area burns treated in our department from 2020 to 2024 were analyzed. Key factors such as burn depth assessment (aided by debridement and new technologies), optimal intervention timing (priority to emergency treatment), appropriate wound management (tangential excision and eschar abrasion), selection of moist dressings (transgenic pigskin, allografts, VSD, etc.), and risk monitoring were emphasized.

Results / Discussion: A total of 47 patients with severely burned patients were included, with burn areas ranging from 35% to 93% TBSA. The clinical healing time was 10-35 days, all patients recovered and were discharged without sepsis. The moist healing strategy effectively prevented progressive wound deepening, reduced autologous skin graft area, and shortened the healing cycle.

Conclusion: The moist healing strategy is safe and effective for large-area burns, especially for second-degree/mixed-depth wounds. Scientific grasp of key implementation factors and standardized operation can significantly improve treatment effects. However, it only focuses on early wound management, and further optimization of strategies for different stages of burns is needed.

OP006 Management of severely burned adult patients: Strategies and clinical practice

Xingang Wang[1]

[1]*The 2nd Affiliated Hospital of Zhejiang University School of Medicine, Hangzhou, China*

Aim: To elaborate on the management strategies and clinical practice for severely burned adult patients at the 2nd Affiliated Hospital of Zhejiang University School of Medicine (SAHZU), aiming to improve treatment outcomes.

Method: This study analyzed the hospital's systematic approach, including burn severity assessment (area via Chinese Rule of Nine, depth, accompanying injuries) and stage-specific surgical interventions: decontamination/debridement in the shock stage, batch necrotic tissue removal with skin grafting (meshed, Meek, mixed auto-allo grafting) in infection/wound repair stages, and scar release/plastic surgery in rehabilitation. Typical cases were presented to verify efficacy.

Results / Discussion: SAHZU achieved a 2.5% mortality rate (2016-2022) in patients with ≥50% TBSA burns, far below the global weighted average of 10.4%. Eight typical cases (TBSA 92%-100%, III degree 48%-86%) showed clinical healing times of 25-72 days, with effective wound closure and favorable rehabilitation outcomes.

Conclusion: Managing severely burned patients is systemic. Early debridement and wound protection prevent wound deepening. Active surgical intervention for rapid wound closure is critical. Continuous rehabilitation throughout treatment ensures optimal functional and aesthetic recovery.

EP068 Comperative outcames of topical enzyme alginogel vs topical silver sulfadiazine in facial burns

Müge Sert[1], Alperen Pala[1], Rıdvan Erden[1], Selin Uyar[1], Gaye Filinte[2]

[1]*Kartal Dr.Lütfi Kırdar City Hospital, Istanbul, Türkiye*, [2]*University of Health Sciences, Kartal Dr.Lütfi Kırdar City Hospital, Istanbul, Türkiye*

Aim: This study aimed to compare healing outcomes, infection rates, and overall clinical performance of silver sulfadiazine and enzyme alginonel in the management of partial thickness facial burns.

Method: A retrospective analysis was conducted on 26 patients presenting with second degree facial burns between 2023-2025. Patients were equally assigned to topical silver sulfadiazine (n=13) or enzyme alginogel (n=13). Patients compared with epithelization time, rate of wound infection or colonization, frequency of dressing changes, reported discomfort, and early scar quality (using the Vancouver Scar Scale (VSS)) during follow-up. Comparative analysis focused on outcomes relevant to reconstructive wound care.

Results / Discussion: Enzyme alginogel demonstrated a faster median epithelialization time (6.2 days) and required fewer dressing changes. The silver sulfidiazine group has higher rates of delayed healing (8.4 days) and suspected infection. Mean Vancouver Scar Scale (VSS) scores were significantly lower in the enzym alginogel group (3.9) compared with the silver sulfadiazine group (6.9), indicating better overall scar quality—particularly in pigmentation, vascularity, and pliability domains.

Conclusion: For facial burns, where rapid healing and optimal aesthetic outcomes are essential, enzyome alginogel outperformed silver sulfadiazine across multiple parameters, including healing time and early scar quality measured by VSS.These findings support ezyme alginogel as a favorable topical agent for acute management of superficial and partial-thickness facial burns. Larger prospective trials incorporating long-term scar follow-up are recommended to strengthen evidence for clinical decision-making in reconstructive burn care.



DEVICES & INTERVENTION

OP018 Evaluating the clinical efficacy of a pulsed-current electrical stimulation device in the treatment of venous leg ulcers: A self-controlled service evaluation

Yu-Tung Fu[1], Steven Jeffery[2]

[1]University College London, London, United Kingdom, *[2]Pioneer Wound Healing and Lymphoedema Clinics, Eastbourne, United Kingdom*

Aim: Venous leg ulcers (VLUs) remain a global healthcare challenge, with a prevalence of 1.5–3% worldwide. While effective treatment options are limited, electrical stimulation therapies (EST) have recently emerged as promising approaches for accelerating wound healing and alleviating pain. This service evaluation aimed to assess the clinical efficacy of a single-use, portable pulsed-current electrical stimulation (PES) device in VLU patients in a real-world setting.

Method: A self-controlled service evaluation was conducted in the UK, including 20 VLUs. Each patient's wound served as its own control. Following a 4-week run-in period, patients received PES treatment for 12 days and were subsequently followed up for 6 weeks. Outcomes included percentage wound area reduction (PWAR), wound healing rate, pain intensity (numerical rating scale), and wound bed tissue composition.

Results / Discussion: PES treatment was associated with a statistically significant weekly increase in PWAR of 3.2% ($p = 0.006$), leading to a median PWAR of 38.0% at four weeks post-treatment. Female participants demonstrated a significant weekly reduction in pain scores of 2.15 points ($p = 0.022$), whereas no significant changes were observed in male participants ($p = 0.857$). The mean proportion of granulation and epithelial tissue increased significantly from 48.2% to 72.9% four weeks after the initiation of PES treatment ($p = 0.0024$).

Conclusion: PES demonstrated therapeutic potential in promoting wound healing, reducing pain, and improving wound bed composition in patients with non-healing, painful VLUs. These real-world findings support the multifaceted role of PES in VLU management and provide a foundation for further clinical evaluation.

OP019 The Plantar-Palmar Index with near infrared spectroscopy replaces the Ankle-Brachial Index for noninvasive evaluation of vascular perfusion and peripheral arterial disease

Jeffery Niezgoda[1]

[1]USUHS / William Carey College of Osteopathic Medicine, WebCME / Kent Imaging, RxOS Medical / Auxillium Health, Greendale, United States

Aim: The Ankle Brachial Index (ABI) is widely used for peripheral artery disease (PAD) diagnosis but is time-consuming, technically challenging, uncomfortable for patients, and often unreliable in diabetic populations. These limitations have led to the exploration of near-infrared spectroscopy (NIRS) as a non-invasive tool for assessing tissue perfusion. This study evaluated the Plantar-Palmar Index (PPI), a NIRS-derived metric, as a potential alternative to ABI.

Methods: A total of 90 limbs from 48 subjects were studied, including healthy controls, patients with prior foot ulcers, known PAD, and prior amputations. ABI and pulse volume recordings (PVRs) were obtained using the MESI mTABLET ABI Diagnostic System. NIRS imaging (SnapshotNIR, Kent Imaging, Calgary, Canada) was performed on plantar and palmar surfaces with subjects supine. Tissue oxygen saturation (StO_2) was measured, and PPI ratios were calculated (plantar StO_2 ÷ palmar StO_2).

Results: PVRs were categorized as Normal (n=48), Mild (n=32), Moderate (n=7), and Severe (n=3). PPI increased progressively with PAD severity: Normal 1.041, Mild 1.148, Moderate 1.457, Severe 1.570. Confidence intervals were non-overlapping across groups. ANOVA confirmed significant differences ($p<0.001$). Pairwise comparisons demonstrated statistical significance for all groups of PAD, Normal–Mild ($p<0.005$), Normal–Moderate ($p<0.001$), and Normal–Severe ($p<0.001$).

Conclusion: The study demonstrates that NIRS-derived PPI correlates with PVR-based PAD severity and may overcome key limitations of ABI. PPI offers a non-invasive, rapid, and reliable measure of perfusion that could enhance PAD screening and management. Further studies are needed to validate findings and establish clinical implementation.

OP020 Personalised compression therapy using real-time pressure monitoring in venous leg ulcers

Karen O'Rourke[1], Manuel Villegas-Martinez[2], Daphne Hazell[3]

[1]Home Wound Care UK, Bognor Regis, United Kingdom, *[2]Feeltect Limited, Spiddal, Ireland*, *[3]Home Wound Care, Bognor Regis, United Kingdom*

Aim: Effective compression therapy (CT) is central to venous leg ulcer (VLU) management, but maintaining optimal sub-bandage pressure remains challenging. Differences in application technique, patient comfort, and gradual pressure loss can result in sub-therapeutic compression and delayed healing. Real-time pressure monitoring offers a way to individualise treatment by ensuring consistent therapeutic pressure tailored to each patient.

Method: We conducted a real-world service evaluation introducing a wireless pressure monitoring system into routine CT for patients with chronic VLUs. Seventeen patients (23 limbs) received treatment using digital feedback to achieve target pressures that were individually adjusted for comfort and tolerance. Pressure data were transmitted daily, and patients or carers were trained to perform 'top-up' bandages when readings fell below nurse-defined thresholds. Wound healing progress was assessed using percentage area reduction (PAR) over time.

Results / Discussion: Patient engagement was high, with an average of 1.71 pressure readings transmitted daily. Mean sub-bandage pressure remained within the therapeutic range (40.3 ± 6.2 mmHg). Healing outcomes were positive: 19 of 23 limbs (82.6%) healed within the service period, with a mean healing time of 58 days. Mean PAR reached 71.8% ± 24.4% at 4 weeks and 96.1% ± 8.7% at 12 weeks. The average PAR per day was 1.95 ± 1.38%/day, showing high variability between limbs. Over half of patients or carers successfully performed top-ups, helping maintain target pressures.

Conclusion: Real-time pressure monitoring supports personalised CT by maintaining therapeutic pressure despite individual variability. This approach achieved high healing rates, improved patient engagement, and empowered self-management. Integrating real-time monitoring into routine care offers a practical way to optimise compression delivery and enhance outcomes in VLU management.

OP021 Retrospective review of 5318 patients with chronic lower extremity wounds treated with intermittent topical oxygen therapy

Dr. Mike Griffiths[1], Joann Lohr[2], Andrew J. M. Boulton[3], Anil Hingorani[4], Palma Shaw[5], Vincent Rowe[6], Lee C. Rogers[7], Anahita Dua[8]

[1]AOTI Ltd., Oceanside, United States, *[2]Wm. Jennings Bryan Dorn VA Medical Center, Columbia, SC, United States*, *[3]University of Manchester, Manchester Royal Infirmary, Manchester, United Kingdom*, *[4]New York University Langone Hospital-Brooklyn, Total Vascular Care, Brooklyn, NY, United States*, *[5]SUNY Upstate Medical University, Syracuse, United States*, *[6]David Geffen School of Medicine, Los Angeles, CA, United States*, *[7]University of Texas Health Science Center, San Antonio, TX, United States*, *[8]Massachusetts General Hospital, Boston, MA, United States*

Aim: To evaluate the effectiveness of a unique multi-modality therapy delivering noncontact cyclical compression with pressurized topical oxygen, intermittent topical oxygen therapy (ITOT), in the treatment of chronic lower extremity wounds.

Method: Data from 5318 patients treated between January 2023 and December 2024 for lower extremity wounds were retrospectively analyzed. Patients with incomplete data, or who were still on therapy were excluded, leaving a final cohort of 3126 patients, 89.4% (n=2794) male and 10.6% (n=332) female. Treated wounds included diabetic foot ulcers (72.2%, n=2257), venous ulcers (20.1%, n=628), arterial ulcers (7%, n=209), and atypical wounds (1%, n=32). Analysis included healing rates, retreatment rates, and complications. Mean patient age was 69.6 (±12.3) years. Mean pre-treatment wound age was 7 (±15.9) months, and mean number of wounds per patient was 1.1 (±0.4).

Results: 64.8% (n=2027) of wounds healed in 4.2 (SD±2.5) months, despite a mean pre-treatment wound age of 7 (±15.9) months. Need for retreatment due to wound recurrence was low, 2.7% (n=54), with a mean follow up time

of 13.9 (±4.9) months. Rates of hospitalization and amputation were 3.7% (n=115) and 6.1% (n=191) respectively, with subgroup analyses showing consistent healing rates. ITOT therapy significantly reduced amputation and hospitalization rates compared to historical standards.

Conclusion: Multi-modality ITOT is an effective, noninvasive, patient-applied therapy that synergistically addresses the root causes of wound chronicity: inflammation, edema, and tissue hypoxia. In this large cohort study, ITOT demonstrated superior wound healing outcomes in complex, comorbid populations, compared to those reported in population based real world studies. Results of this study support the durable healing outcomes demonstrated in previously published ITOT randomized controlled trial and real-world evidence studies.

OP022 A pilot feasibility study of infrared thermography in guiding intraoperative debridement and monitoring postoperative healing of chronic, open vascular surgical wounds

Shreya Bhatt[1 2], Natalia Rios Turek[2], Arthur Lim[1 2], Bharadhwaj Ravindhran[1 2], Ian Chetter[1 2], Daniel Carradice[1 2], George Smith[1 2]

[1]Academic Vascular Surgical Unit, Hull, United Kingdom, *[2]Hull University Teaching Hospitals NHS Trust, Hull, United Kingdom*

Aim: To evaluate the utility of infrared thermography (IRT) as an adjunct to clinical judgement in debriding chronic foot wounds.

Method: A prospective cohort study at a tertiary vascular unit recruited consecutive consenting adults undergoing debridement of foot wounds over 4 months. IRT was performed pre- and post-operatively on day 0, 2, 4 etc until discharge. The primary outcome was feasibility of IRT use (ease of use, acceptability to patients). Secondary outcomes were changes to surgical plan due to preoperative IRT features, need for repeat debridement or major amputation, and preoperative IRT features predictive of subsequent poor healing/amputation.

Results / Discussion: 55 patients were recruited into the study. Median age was 67(59-76), 70% were male, 98% were Caucasian and 62% were current/previous smokers. The most common comorbidities were diabetes (67%), cardiovascular disease (42%) and peripheral vascular disease (36%). 69.1% of patients underwent toe amputation, 14.5% had a trans-metatarsal amputation, 9.1% underwent heel debridement and 7.3% had multiple wounds debrided. 51 patients were followed up at 30 days (4 lost to follow-up). 11(21.6%) had further operations including 9(17.6%) debridements and 3(5.9%) major amputations. Preoperative IRT was able to identify cold spots correlating to abscesses and subcutaneous collections not visible to the naked eye. Intraoperative imaging helped visualise completeness of debridement of infected/necrotic tissue in the form of warm wound beds indicating adequate perfusion. Postoperative IRT was able to detect heterogeneity within wound temperature and healthy reference area which preceded impaired wound healing or further infection. All patients reported IRT was acceptable in routine clinical practice.

Conclusion: IRT is a feasible adjunct in debridement of infected/ischaemic foot wounds. Additional research to further define this role appears warranted.

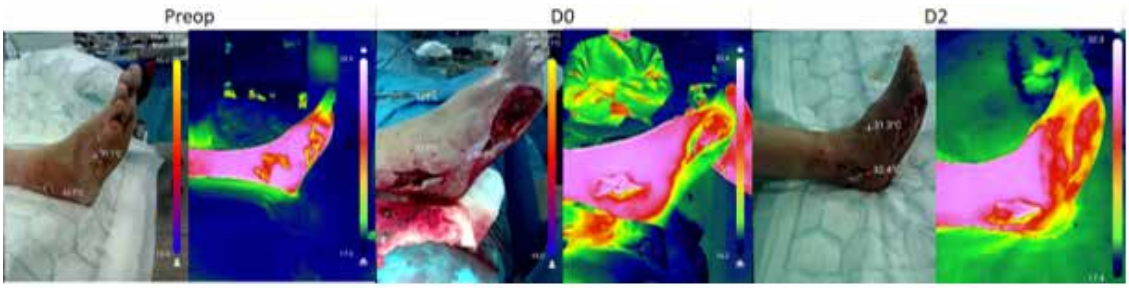

Figure 1: Serial infrared imaging of right foot pre-and post-operatively following 5th toe amputation and lateral malleolus debridement

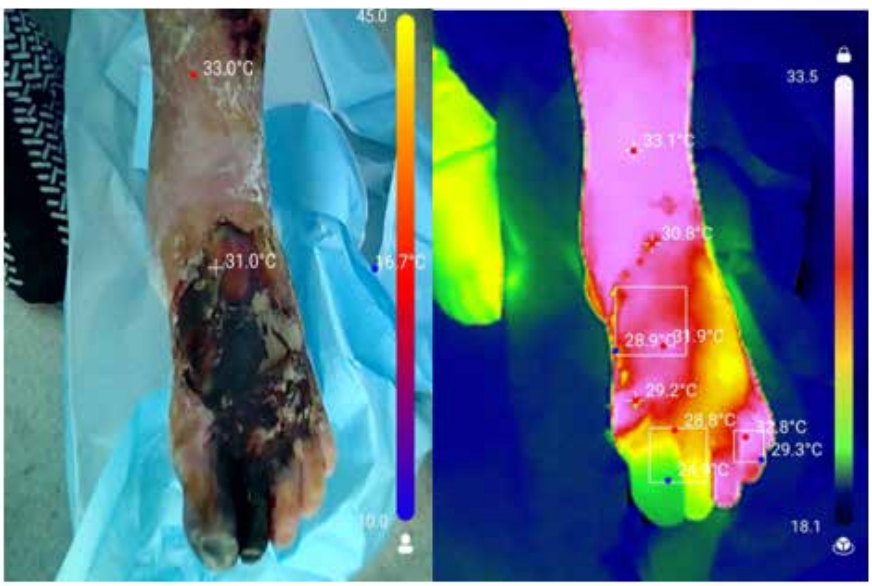

Figure 2: Infrared images of ischaemic foot wound demarcating areas of adequate perfusi from necrotic tissue prior to debridement.

OP023 Photobiomodulation induces prolonged enhancement of microvascular flow in diabetic foot ulcers but not in venous ulcers, as suggested by dynamic thermal imaging

Rose Raizman[1], S. David Gertz[2], David Ben Daniel[2], Rita Lo[1], Oshrit Hoffer[3], Lilach Gavish[2]

[1]Scarborough Health Network Centenary Hospital, Adjunct Lecturer Lawrence S. Bloomberg Faculty of Nursing, University of Toronto, Toronto, Canada, *[2]Institute for Research in Military Medicine (IRMM), Faculty of Medicine, The Hebrew University of Jerusalem, jerusalem, Israel*, *[3]Afeka Tel Aviv Academic College of Engineering Researcher, Tel Aviv, Israel*

Aim: Photobiomodulation (PBM) has been shown to accelerate healing, with the primary mechanism considered to be the enhancement of microvascular blood flow. Thermal imaging has been recognized as a reliable non-invasive method for assessment of microvascular flow. The purpose of this study was to compare acute microvascular response to PBM between venous and diabetic foot ulcers (VUs and DFUs respectively) as assessed by dynamic thermal imaging.

Method: In this prospective study, thirty-three chronic wounds (22 DFUs, 11 VUs) were evaluated in 20 patients (mean age 68±13 years; male-to-female ratio 15:16). PBM (808nm, 250mW peak-power, 15kHz, 1.1J/cm^2/min) was applied to the ulcer bed, ulcer margins, and the inguinal and popliteal lymph nodes. Thermal images were captured before treatment and every 5 minutes up to 30 minutes post-PBM. Minimal and maximal surface wound temperature were measured automatically with dedicated software.

Results / Discussion: The minimal temperature of the wound bed at baseline was 27.7±2.9°C, which was 3.9±2.0°C colder than that of the wound margins (p<0.001), regardless of wound type. Following PBM treatment, a significant increase in wound bed temperature was observed in DFUs, lasting at least 30 minutes post-PBM, but not in VUs (Temp [°C], mean±SD: DFU=2.10±2.25, p<0.001 by paired t-test; VU=0.68±2.490, p=0.385, DFU vs VU p=0.110 by 2-sample ttest). The response of DFUs to PBM correlated inversely with baseline temperature (β=–0.521, p=0.008; R^2=0.399 by Pearson correlation coefficient).

Conclusion: Thermal imaging suggests that photobiomodulation initiates an increase in microvascular blood flow subtending the enhanced healing of DFU. However, this was not the case with VUs suggesting that other mechanisms likely contribute to the accelerated healing of venous ulcers by this non-invasive modality.

OP024 Predictors of post-amputation complications in major lower limb amputations: The role of WIfI scoring and pre-amputation transcutaneous oximetry (TcPO2)

Julian-Dario Rembe[1], Muayad Aal-Jelo[2], Polina Shabes[1], Katharina Beckamp[1], Mansur Duran[3], Markus Udo Wagenhäuser[1], Hubert Schelzig[1], Waseem Garabet[1]

[1]University Hospital Duesseldorf, Heinrich-Heine University (HHU), Düsseldorf, Germany, *[2]Hospital zum Heiligen Geist, Kempen, Germany*, *[3]Marien Hospital Gelsenkirchen, Gelsenkirchen, Germany*

Aim: This study evaluates the predictive value of the WIfI (Wound, Ischemia, and foot Infection) classification system and pre-amputation transcutaneous oxygen pressure (TcPO2) measurements in forecasting post-amputation complications in major lower limb amputations (MLLA).

Method: A retrospective analysis was conducted on 132 MLLA patients with complete WIfI data and 87 patients with documented TcPO2 values. Associations between WIfI stage, TcPO2, and post-amputation outcomes—including healing time, surgical revisions, re-amputation, and wound complications-were assessed using statistical modelling and receiver operating characteristic (ROC) curve analyses.

Results / Discussion: Higher WIfI stages correlated with prolonged healing (WIfI 4 failure rate: 12.8%) but did not significantly predict complications. Unexpectedly, WIfI 2 patients had a 4.4-fold higher risk of revision (p=0.011) and 3.1-fold higher re-amputation risk (p=0.033) compared to WIfI 4. TcPO2 levels showed a significant relationship with healing outcomes, with a 36.9% failure rate in TcPO2 <15 mmHg. A TcPO2 cut-off of >46 mmHg optimized healing prediction (HR=2.81, p=0.004). **Conclusion:** TcPO2 is a stronger predictor of post-amputation complications than WIfI staging. A cut-off of >46mmHg at the amputation site is recommended to improve healing outcomes.

DIABETIC FOOT

OP057 Effect of Yinchen Qingjin Formula on inflammatory cytokines and clinical outcomes in diabetic foot tendon gangrene ulcers

Lei Zhang[1], Xia Zhu[1]

[1]*Department of Vascular Surgery, Shanghai University of Traditional Chinese Medicine Affiliated Yueyang Hospital of Integrated Traditional Chinese and Western Medicine, shanghai, China*

Aim: To evaluate the effects of Yinchen Qingjin Formula on inflammatory cytokines and clinical outcomes in patients with diabetic foot tendon gangrene ulcers (DFTG).

Method: This randomized controlled study enrolled 60 patients with DFTG (Xishi grade I–III), who were randomly assigned to a treatment group (n = 30) or a control group (n = 30). Both groups received standard care including glycemic control, blood pressure management, infection control, lipid regulation, nutritional support, and wound dressing. The treatment group additionally received oral Yinchen Qingjin Formula, while the control group received oral Xuefu Zhuyu capsules. Changes in serum inflammatory cytokines (CRP, TNF-α, IL-1β, IL-6, IL-8), clinical symptoms (swelling, exudation, secretion characteristics, granulation color, skin temperature, numbness), glycometabolic and lipid profiles, and overall clinical efficacy were assessed.

Results: After treatment, serum levels of CRP, TNF-α, IL-1β, IL-6, and IL-8 significantly decreased in both groups, with greater reductions in the treatment group ($P < 0.05$). Syndrome scores were significantly lower after treatment, especially in the treatment group ($P < 0.05$). The total effective rate was 93.3% in the treatment group and 86.7% in the control group ($P < 0.05$). Glycemic indices (FBG, 2hPG, HbA1c, GSP) improved significantly in both groups, with greater improvement in the treatment group ($P < 0.05$). Lipid profiles (TC, TG, HDL, LDL) and toe amputation rates showed no significant differences between groups ($P > 0.05$).

Conclusion: Yinchen Qingjin Formula effectively reduced serum inflammatory cytokine levels, improved wound healing, and enhanced clinical efficacy in patients with diabetic foot tendon gangrene ulcers, suggesting a promising adjunctive therapy for DFTG management.

OP058 Clinical outcomes of autologous platelet-rich fibrin versus conventional dressing in chronic diabetic foot ulcer management: A multicenter study

Jeffrey Putra[1], Yeremia Gerald[2], Mira Prawira[3], Fajar Mahayasa[4], Andreas Tandelilin[5], Shita Sudarsa[6], Dianita Angeline[1]

[1]*Universitas Negeri Yogyakarta, Yogyakarta, Indonesia*, [2]*Soedarso Hospital Pontianak, Kalimantan Barat, Indonesia*, [3]*Bali International Hospital, Bali, Indonesia*, [4]*Prima Medika Hospital, Bali, Indonesia*, [5]*Universitas Atma Jaya Yogyakarta, Yogyakarta, Indonesia*, [6]*Universitas Udayana, Bali, Indonesia*

Aim: To evaluate the effectiveness of autologous platelet-rich fibrin (PRF) compared with conventional dressing in promoting healing of chronic diabetic foot ulcers (DFUs).

Method: A prospective multicenter non-randomized controlled study was conducted across six hospitals from July 2023 to June 2025. Adult patients (≥18 years) with chronic DFU ≥ 4 weeks (Wagner grade 1–3, area 1–20 cm^2) received either weekly PRF membrane application plus standard wound care or standard wound care alone. Wounds were assessed weekly for 12 weeks using percentage area reduction, complete healing rate, and Simplified Bates-Jensen Wound Assessment Tool (SWAT) score. Data were analyzed using propensity-adjusted mixed-effects and Cox regression models.

Results / Discussion: A total of 186 patients were enrolled (PRF = 94, control = 92). Baseline characteristics were comparable between groups. At week 4, mean wound-area reduction was significantly greater in the PRF group (58.3 ± 26.7 %) than in controls (32.9 ± 24.1 %; $p < 0.001$). Complete healing at week 12 occurred in 65.9 % vs 39.1 % ($p = 0.002$). Mean healing time was shorter with PRF (56.8 ± 21.4 days) versus control (79.5 ± 25.2 days, $p < 0.001$).

SWAT improvement was also greater (–13.6 ± 6.1 vs –7.2 ± 5.8, p < 0.001). Adjusted hazard ratio for healing was 1.94 (95 % CI 1.29–2.91). No major adverse events were reported.

Conclusion: Autologous PRF significantly accelerates healing and improves tissue quality in chronic DFUs compared with conventional dressing. The technique is safe, low-cost, and feasible for integration into multidisciplinary wound care practice within resource-limited hospital settings.

Table 1. Clinical and Healing Outcomes of PRF versus Conventional Dressing in Chronic Diabetic Foot Ulcers (n = 186)

Variable	PRF Group (n=94)	Control Group (n=92)	p-value	Interpretation
Age (years)	56.8 ± 9.3	57.4 ± 8.7	0.63	Comparable baseline
HbA1c (%)	8.5 ± 1.1	8.4 ± 1.2	0.72	Similar glycemic control
Ulcer area (cm²)	8.2 ± 5.6	7.9 ± 5.3	0.78	Comparable wound size
Wagner grade 2–3 (%)	63.8 %	61.9 %	0.81	Similar ulcer severity
% Area reduction at week 4	58.3 ± 26.7 %	32.9 ± 24.1 %	<0.001	PRF markedly faster reduction
Complete healing by week 12	65.9 % (62/94)	39.1 % (36/92)	0.002	Significantly higher closure rate
Mean time to healing (days)	56.8 ± 21.4	79.5 ± 25.2	<0.001	Faster healing with PRF
ΔSWAT score (week 0–12)	−13.6 ± 6.1	−7.2 ± 5.8	<0.001	Greater improvement in wound quality
Pain score (VAS 0–10)	5.1 → 1.9	5.0 → 3.2	0.01	Better pain reduction
Amputation events	0	1 (1.1 %)	0.32	No difference; event unrelated
Adverse events (minor bleeding, allergy)	4.2 % transient bleeding	0	0.09	Mild, self-limiting only
Mean cost per healed ulcer (IDR)	1.18 million	1.45 million	0.04	18 % lower total cost
Adjusted hazard ratio for healing	1.94 (95 % CI 1.29–2.91)	Reference	0.001	PRF nearly doubles healing likelihood

OP041 Outcomes of patients admitted for infected diabetic foot attack: Difference between patients with and without peripheral artery disease

Federico Rolando Bonanni[1 2], Martina Salvi[2 3], Ermanno Bellizzi[2 3], Luigi Uccioli[3 4], Valeria Ruotolo[2], Aikaterini Andreadi[2 3], Alfonso Bellia[2 3], Davide Lauro[2 3], Marco Meloni[2 3]

[1]University of Rome Tor Vergata, Rome, Italy, *[2]Division of Endocrinology and Diabetology, Department of Medical Sciences, University Hospital Fondazione Policlinico Tor Vergata, Rome, Italy*, *[3]Department of Systems Medicine, University of Rome Tor Vergata, Rome, Italy*, *[4]Division of Endocrinology and Diabetes, Department of Systems Medicine, CTO Andrea Alesini Hospital, Rome, Italy*

Aim: The study aimed to assess the impact of peripheral artery disease (PAD) on the outcomes of patients admitted for infected diabetic foot attack (DFA).

Method: It is a retrospective observational study of consecutive patients admitted through the emergency department with diabetic foot ulcers (DFUs) complicated by moderate or severe infection, requiring urgent intervention from a multidisciplinary diabetic foot service in 2024. Based on the presence of PAD, patients were divided into two groups: those with neuro-ischemic DFA (PAD+), treated with prompt revascularization, and those with neuropathic DFA (PAD). The following in-hospital outcomes were evaluated: minor and major amputations; length of stay (LOS); mortality. Once discharged, patients were regularly followed as outpatients, and their six-month outcomes (healing, major amputation, and mortality) were analyzed.

Results / Discussion: Overall, 119 patients were included. The mean age was 67±13 years, most patients were male (75%) and had type 2 diabetes (92%) with a mean duration of 20±12 years; 84 (70.6%) patients with PAD were

compared to 35 (29.4%) patients without PAD. In-hospital outcomes for the two groups (PAD+ vs PAD-) were: minor amputation (41.7 vs 25.7%, p=0.09); major amputation (2.4 vs 2.8%, p=0.8); LOS (21±11 vs 14±11 days, p=0.004); mortality (3.6 vs 0%, p=0.1). The six-month follow-up outcomes were: healing (40.5 vs 90.6%, p<0.0001); major amputation (8.1 vs 3.1%, p=0.1); mortality (8.1 vs 0%, p=0.01), respectively.

Conclusion: In the context of infected DFA, PAD appeared to play a significant role only on hospitalization length, while having a greater influence on mid-term outcomes at the six-month follow-up, reducing healing chances and increasing mortality.

OP048 A comparison of the efficacy of nano-silver spray and chitosan-containing silver particle spray in the management of diabetic foot ulcers: A randomized clinical trial

Amir Hossein Abdi Dorbashi[1], Mohammad Reza Sohrabi[2], Yasaman Firouzi Etminan[3], Mohammad Mahdi Abdi Doorbash[4]

[1]Alborz Hospital, Karaj, Iran, *[2]islamic Azad University Tehran Medical Science, Tehran, Iran*, *[3]Alborz University Of Medical Science, Karaj, Iran*, *[4]Arak University Of Medical Sciences, Arak, Iran*

Aim: diabetic foot ulcer (dfu) is a debilitating and costly complication of diabetes, necessitating novel and effective therapeutic strategies. This study aimed to compare the efficacy of two topical sprays—pure nano-silver and a nano-silver-chitosan combination—in the healing of diabetic foot ulcers.

Method: in this triple-blind randomized clinical trial, 60 patients with diabetic foot ulcers (wagner grades 1 and 2) were randomly assigned to two groups of 30. The intervention group was treated with chitosan-containing silver particle spray, while the control group received pure nano-silver spray. Wound size and depth were measured weekly for 8 weeks. Data were analyzed using the generalized estimating equations (gee) model.

Results / discussion: although the chitosan-containing silver particle spray group initially had a larger mean wound size and higher esr levels, the gee analysis revealed a significantly greater weekly reduction rate in both wound size (β = -0.64, p = 0.006) and depth (β = -0.33, p = 0.029) compared to the pure nano-silver group. Furthermore, the complete healing rate was higher in the chitosan-containing silver particle spray group (56.7%) than in the pure nano-silver spray group (26.7%).

Conclusion: despite more challenging initial conditions in the chitosan-containing silver particle spray group, treatment with the combined nano-silver-chitosan spray resulted in a significantly higher rate of wound healing compared to pure nano-silver spray. The synergy between the antimicrobial properties of silver and the wound-healing characteristics of chitosan appears to be the key factor in this superiority.

OP033 Painful diabetic foot ulcer present in daily life though ignored in healthcare: An interview study

Anneli Ringblom[1], Ulla Hellstrand Tang[1], Paulin Andrell[1], Axel Wolf[1]

[1]Gothenburg University, Gothenburg, Sweden

Aim: To explore patients' experiences of pain related to diabetic foot ulcers (DFUs) and their perceptions of how pain and pain relief are assessed and managed in clinical encounters, with particular attention to the patient–provider relationship and patient involvement in care.

Method: A qualitative interview study was conducted with 13 adults living with ongoing painful DFUs. Participants were recruited from four clinical settings in a Swedish region. Semi-structured telephone interviews were performed between October 2024 and June 2025, audio-recorded, transcribed verbatim, and analysed using inductive qualitative content analysis.

Results / Discussion: Two main themes emerged: *A life ruled by pain* and *Being left alone*. Participants described

pain that dominated daily life, restricted mobility, disturbed sleep, and had significant emotional consequences such as anxiety, frustration, and social withdrawal. Many participants experienced insufficient pain assessment and management, limited communication about pain, and a lack of individualized treatment strategies. Unrelieved pain was linked to decreased trust in healthcare providers, reduced motivation for self-care, and avoidance of follow-up visits.

Conclusion: Pain in DFUs is common, debilitating, and often under-recognized in clinical practice. Persistent ulcer-related pain lasting more than three months should be classified as chronic pain, requiring a biopsychosocial approach and systematic pain assessment. Incorporating pain neuroscience education and mechanism-based treatment into routine DFU management may improve both clinical outcomes and patient well-being.

OP034 The role of carbon dioxide angiography in reducing contrast-induced nephropathy in diabetic foot patients undergoing endovascular treatment

Sadık Ahmet Uyanık[1], Erdem Birgi[2], Saffet Öztürk[1], Umut Asfuroğlu[1], Erdi Tangobay[1], Hikmet Erhan Güven[3]

[1]University of Health Sciences, Ankara Etlik City Hospital, Interventional Radiology Department, Ankara, Türkiye, *[2]University of Health Sciences, Ankara Training Hospital, Radiology Department, Ankara, Türkiye*, *[3]University of Health Sciences, Ankara Etlik City Hospital, General Surgery Chronic Wounds and Diabetic Foot Department, Ankara, Türkiye*

Aim: This study investigates the role of carbon dioxide (CO_2) angiography, delivered with an automated CO_2 delivery system, in decreasing the amount of iodinated contrast and preventing contrast-induced nephropathy (CIN) in diabetic foot patients who underwent endovascular revascularization.

Method: A total of 272 diabetic foot patients who underwent endovascular treatment for infra-inguinal chronic peripheral arterial disease were included in the study. Of these, 64 patients underwent endovascular intervention using CO_2 angiography, while 208 patients underwent endovascular intervention using only iodine-based contrast media (Table-1). The rates of CIN, the amount of contrast used, technical success and complication rates, and complications related to CO_2 usage were recorded.

Results / Discussion: The mean contrast volume used in the CO_2 group was significantly lower than in the control group (89.4±24.8 ml vs 24.3±13.3 ml; $p<0.001$). CIN was detected in 41 patients. The incidence of CIN was significantly lower in the ($p= 0.024$). In a subgroup of patients with CKD Stage 3-5, CIN incidence remained significantly lower in the CO_2 group (Table-2), and multivariate analysis identified CO_2 use as an independent protective factor (OR: 0.02, $p < 0.001$). Technical success rates were comparable between the groups (93.7% vs 93.2%; $p=0.892$). There were no major complications (Table-3) (Figures 1 and 2).

Conclusion: CO_2 angiography may play a crucial role in minimizing the risk of CIN in this specific population, who are more vulnerable to this complication and its associated increased morbidity and mortality. Further multicentred prospective studies are needed to better define the indications for CO_2 angiography in high-risk patients and to establish standardized protocols for its use.

Table 1. The demographic characteristics of patients

	Study group	Control group	p value
Age (mean) (SD)	67.81 (8.5)	65.5 (9.9)	0.893
Male sex (n/total)	48/64	152/208	0.760
CAD (n/total)	38/64	116/208	0.611
HF (n/total)	19/64	61/208	0.956
Anemia (n/total)	32/64	102/208	0.283
Hypertension (n/total)	23/64	123/208	0.101
Dyslipidemia (n/total)	41/64	109/208	0.442
Smoking (n/total)	29/64	83/208	0.157
CKD stage			<0.001
1	0	46	
2	0	107	
3a	3	40	
3b	39	9	
4	17	4	
5	5	2	
Wagner stage			0.079
1	3	36	
2	14	28	
3	11	48	
4	33	90	
5	3	6	
Rutherford stage			0.859
5	58	190	
6	6	18	
Wound infection (n)	25	86	0.069
HbA1c (mean) (SD)	8.5 (1.9)	8.1 (1.5)	0.217
Serum creatinine (mean) (SD)	2.21 (0.84)	1.06 (0.63)	<0.001
BUN (mean) (SD)	68.0 (35.6)	43.4 (16.3)	<0.001
GFR (mean) (SD)	32.5 (10.6)	71.4 (20.1)	<0.001

*CAD: Coronary artery disease; HF: heart failure; CKD: chronic kidney disease; BUN: blood urea nitrogen; GFR: glomerular filtration rate; n: number; SD: standard deviation

Table 2. CIN incidence in patients with CKD Stage 3a–5

CKD Stage 3a–5 Patients	CO_2 Group (n=64)	Contrast Group (n=55)	p-value
CIN (+), n (%)	4 (6.2%)	21 (38.2%)	<0.001
CIN (–), n (%)	60 (93.8%)	34 (61.8%)	

*CKD: Chronic Kidney Disease; CIN: contrast-induced nephropathy; n: number

Table 3. The features of the interventions and clinical outcomes

		Study group	Control group	p- value
Lesion level				
Femoropopliteal (n)		6	14	0.227
Below the knee (n)		30	99	
Combined (n)	*FP+BTK*	4	38	
	BTK+BTA	20	45	
	FP+BTK+BTA	4	12	
Total lesions treated (median) (min-max)		2 (1-5)	2 (1-5)	0.772
Mean procedure time (minute) (min-max)		57.2 (21-167)	49.2 (23-97)	0.018
Mean contrast dose (ml) (SD)		24.3 (13.3)	89.4 (24.8)	<0.001
Technical success (%)		93.7	93.2	0.892
Complications (n)	*Access site hematoma*	3	5	0.274
	Thromboembolic	1	0	
	Dissection	0	4	
	Perforation	2	7	
CIN (n/total); (%)		4/64; 6.2	37/208; 17.7	0.024

*FP: Femoropopliteal; BTK: below-the-knee; BTA: below-the-ankle; CIN: contrast-induced nephropathy.

SD: standard deviation; min-max: minimum-maximum; n: number

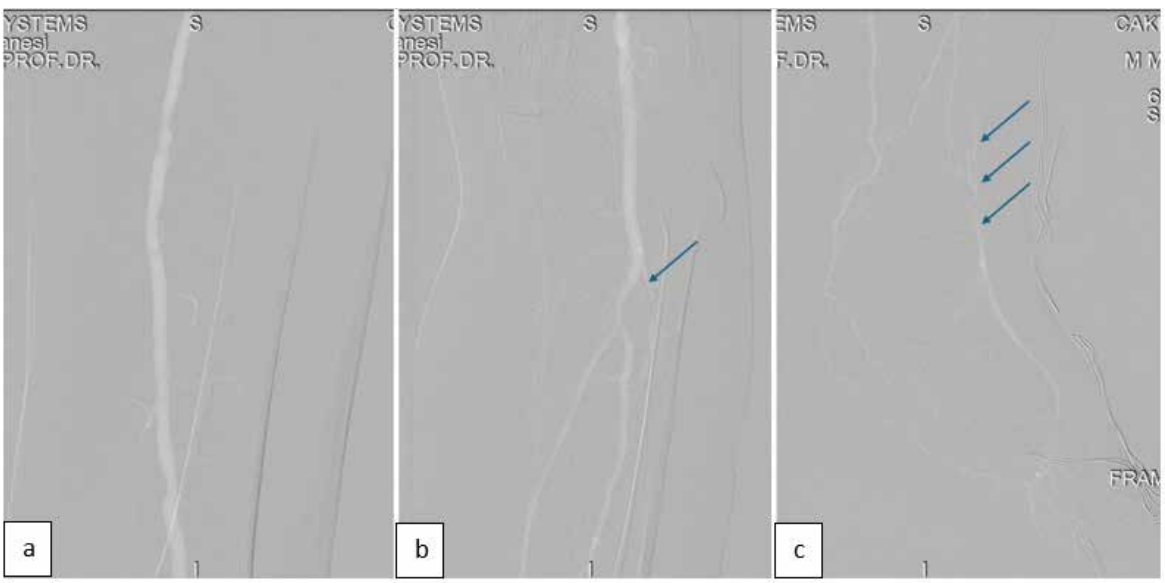

Figure 1:
After antegrade access, CO_2 angiograms showing:

a) Patent superficial femoral artery and popliteal artery
b) Occluded anterior tibial artery at its origin (arrow), patent peroneal artery and posterior tibial artery
c) Dorsalis pedis artery recanalizing from collaterals (arrows)

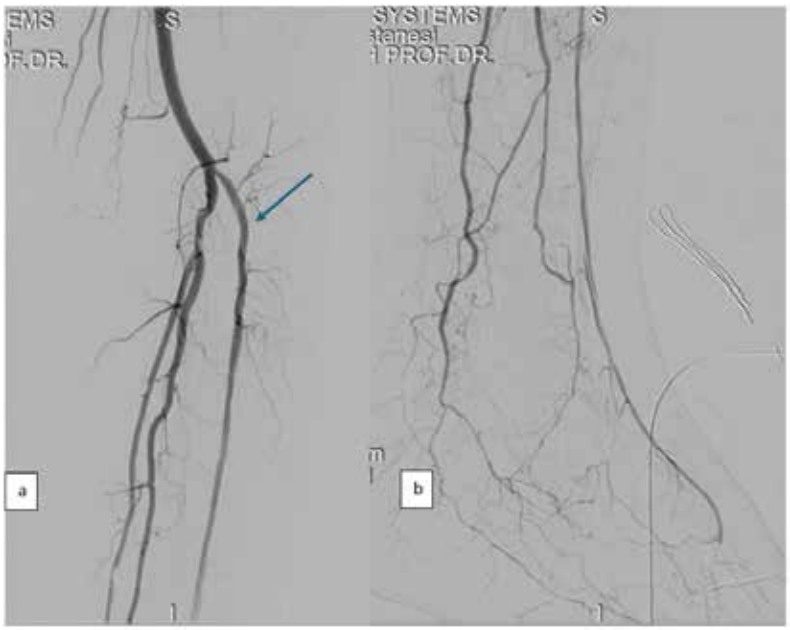

Figure 2:
Bubble formation due to patient movement led to poor CO_2 angiographic image and diluted contrast was given to obtain post-balloon angioplasty images (12ml of contrast was used)
a) Anterior tibial artery recanalized
b) Foot level image

OP035 Results of phase-2 randomized controlled "diamend" study with multi-targeting cell & gene therapy AUP1602-C in chronic neuro-ischemic diabetic foot ulcers

Prof. Alberto Piaggesi[1], Jacek Mikosiński[2], Elisabetta Iacopi[1], Dirk Lammers[3], Christine Kosch[4], Konrad Pańczak[5], Malwina Grobelna[6], Matteo Monami[7], Alessia Scatena[8], Marcin Malka[9], Marco Meloni[10], Christoph Schindler[11], Mirka Sanio[12], Jere Kurkipuro[12], Hanna-Riikka Kärkkäinen[12], Matleena Piiroinen[12], Igor Mierau[12], Laurent Décory[13], Juha Yrjänheikki[13], Haritha Samaranayake[12]

[1]Azienda Ospedaliera Universitaria Pisana, Pisa, Italy, *[2]NZOZ Mikomed, Łódź, Poland*, *[3]Institut für Diabetesforschung Muenster GmbH, Muenster, Germany*, *[4]Hausärztliche und Diabetologische Praxis, Pirna, Germany*, *[5]Lecran Centrum Opieki Nad Ranami, Wrocław, Poland*, *[6]Med-Polonia SP. Z O.O., Proznan, Poland*, *[7]Azienda Ospedaliero Universitaria Careggi, Firenze, Italy*, *[8]Azienda Usl Toscana Sud Est, Arezzo, Italy*, *[9]PODOS Klinika, Warsaw, Poland*, *[10]University of Rome Tor Vergata, Roma, Italy*, *[11]Hannover Medical School, Hannover, Germany*, *[12]Aurealis Therapeutics, Kuopio, Finland*, *[13]Aurealis Therapeutics AG, Zug, Switzerland*

Aim: To evaluate the safety and efficacy of AUP1602-C, a Gene-Therapy Medicinal Product for non-healing diabetic foot ulcers (DFUs), in a multi-center randomized, controlled (RCT) Phase-2 study.

Method: AUP1602-C consists of living Lactococcus cremoris bacteria genetically engineered to secrete human FGF-2, IL-4 and CSF-1, and promote wound healing by microenvironment modulation. Following a successful Phase-1 study (NCT04281992 / EudraCT 2018-003415-22), safety and efficacy AUP1602-C were evaluated in a 64-patient, standard-of-care (SoC) plus placebo-controlled patient and central-evaluator blinded, Phase-2 "DIAMEND" study (NCT06111183 / EU CT 2022-502048-10-00). AUP1602-C was administered topically once- or twice-a-week to non-healing, neuro-ischemic DFUs until complete wound closure or maximum for 12-weeks, on top of SoC, provided according to IWGDF guidelines. Efficacy endpoints included completed healing and wound area reduction at 20-weeks, with post-hoc focus on chronic ulcers over 3-months old.

Results / Discussion: In Intention-To-Treat (ITT) population, complete wound closure rate was 55% and 30% in AUP1602-C twice-a-week and once-a-week groups respectively, and 29% in the placebo group (+26% between placebo and AUP1602-C twice a week, n.s.). In Per Protocol Population (PP), complete closure rates were 56%, 32%

and 26% respectively (+30%, n.s.). Focusing on chronic ulcers above 3 months old, complete closure rates were 60%, 28% and 24% (+36%, p<0.05) in ITT Population, and 64%, 29%, 20% (+44%, p<0.05) in PP Population. No serious adverse reactions or safety concerns related to AUP1602-C were observed.

Conclusion: AUP1602-C, in first-ever Phase-2 study with a topical gene therapy, demonstrated to be superior to SoC in treating non-healing, neuro-ischemic DFUs in patients with chronic ulcers over 3-months old. Preparation for global pivotal study in this target population is under way.

OP049 Treatment of chronic wounds with cold plasma: A randomised, single-blind, placebo-controlled clinical study

Robert Strohal[1], Martina Mittlböck[2], Lisa Gebhardt[3], Gilbert Hämmerle[4]

[1]Federal Academic Teaching Hospital Feldkirch, Department of Dermatology, Feldkirch, Austria, *[2]Medical University of Vienna, Center for Medical Data Science, Vienna, Austria*, *[3]terraplasma medical GmbH, München, Germany*, *[4]Academic Teaching Hospital Bregenz, Central Ambulance of Wound Care, Bregenz, Austria*

Aim: To evaluate the efficacy and safety of cold atmospheric plasma (CAP) therapy in promoting healing of chronic wounds compared to placebo, both in the context of best practice wound care.

Method: A prospective, multicentre, randomized, single-blind, placebo-controlled trial was conducted in patients with chronic wounds. Seventy patients were allocated to receive either CAP treatment or placebo, in addition to standard wound care. The primary endpoint was wound area reduction; secondary endpoints included time to healing, tolerability, and adverse events.

Results / Discussion: CAP therapy resulted in a statistically significant reduction in wound area compared to placebo (p<0.0001), with faster rates of wound healing observed in the CAP group. Secondary endpoints, including wound pH normalization, pain reduction, and significant bacterial load decrease, were also achieved in the CAP group. CAP was well tolerated, with no significant safety concerns reported. These findings are consistent with other multicentre trials and clinical studies, which demonstrate that CAP accelerates wound closure, reduces bacterial load, and improves pain and quality of life in chronic wound patients. The antimicrobial and tissue-regenerative effects of CAP are attributed to the generation of reactive oxygen and nitrogen species, which modulate inflammation and promote angiogenesis.

Conclusion: Cold atmospheric plasma is a safe, well-tolerated, and highly effective adjunct to best practice wound care for chronic wounds, significantly accelerating healing without the need for additional therapies. These results support the integration of CAP into advanced wound management protocols for chronic, non-healing wounds.

OP036 Root cause analysis of diabetes-related lower limb amputations: Temporal assessment of a large UK tertiary service

Jordan Green[1], Rawan Jarkhi[2], Razan Altemeemi[2], Grace Collins[2], Lailatul Sarginan[2], Jill Halstead-Rastrick[3], David Russell[1 2]

[1]Leeds Teaching Hospitals NHS Trust, Leeds, United Kingdom, *[2]University of Leeds, Leeds, United Kingdom*, *[3]Leeds Community Healthcare NHS Trust, Leeds, United Kingdom*

Aim: To identify the causative factors implicating preventable diabetes-related minor and major lower extremity amputations (LEA) and compare temporal changes across two cohorts.

Method: A retrospective root-cause analysis (RCA) was performed on two cohorts: 1st January 2015 to 31st December 2015 (C1), and 1st October 2023 to 31st March 2024 (C2). Data was obtained across primary, secondary and community care records. The Yorkshire and Humber Diabetic Foot Network RCA tool (version 3) was used for data collection and assessment.

Results: 64 LEAs from C1 (50 minor, 14 major) and 70 LEAs from C2 (56 minor, 14 major) were included. 72.6% of minor and 50.0% of major LEAs were deemed preventable, with equal distributions across cohorts. For minor LEAs, delayed patient presentation was consistently most common (30% C1, 32% C2). Patient non-compliance increased from 12% to 29%, while delayed primary-care referral rose from 10% to 21%. Issues with poor antibiotic stewardship were noted only in C1 (18%). System-level delays, particularly delayed multidisciplinary foot team review, increased markedly from 2% to 36%. For major LEAs, patient-related delays were even more prominent; delayed presentation increased from 21% to 43%, and non-compliance rose from 14% to 71%. Delayed vascular referral (14% to 29%), investigations (7% to 21%) and interventions (14% to 21%) also increased, while antibiotic-related issues remained consistently absent.

Conclusion: Preventable amputations remain highly prevalent. There is a shift from primarily patient and antibiotic-related factors to substantial multidisciplinary and vascular pathway delays compounded by worsening patient compliance. This highlights the importance of maintaining robust support for diabetic foot services, with improvements at both service and patient level needed to reduce the health and economic impacts of preventable amputations.

OP037 Timing and predictors of ulcer recurrence following diabetes-related foot ulcer remission: Insights from a multidisciplinary foot service

Jordan Green[1], Emma Kirby[1], Erum Ahmad[1], David Russell[1 2]

[1]Leeds Teaching Hospitals NHS Trust, Leeds, United Kingdom, *[2]University of Leeds, Leeds, United Kingdom*

Aim: To quantify time-to-ulcer recurrence following remission of diabetes-related foot ulcers (DFUs) managed in a tertiary multidisciplinary service and to identify independent predictors of ulcer recurrence.

Method: A retrospective cohort study was conducted at a single UK tertiary hospital. All adults with a healed DFU discharged between 1st October and 31st December 2022 were included. Demographic, clinical, and ulcer-specific data were obtained from electronic health records. The primary outcome was time-to-DFU recurrence. Multivariable Cox proportional hazards were used to identify predictors of the outcome.

Results: 112 patients were included. All patients were followed up for 1 year with no loss to follow-up. 48.2% of the cohort experienced re-ulceration (n = 54), with a median time to recurrence of 136 days and a relatively linear incidence over time. The multivariable Cox model showed good overall fit (concordance = 0.711, Wald p = .04). Independent predictors of DFU recurrence were: female sex (HR 2.27, 95% CI 1.04 – 4.95, p = .039); history of ipsilateral minor lower limb amputation (HR 2.29, 95% CI 1.03 – 5.07, p = .041); peripheral neuropathy (HR 7.00, 95% CI 1.75 – 27.98, p = .006); and congestive cardiac failure (HR 10.07, 95% CI 3.44 – 29.43, p < .0001). No other demographic, clinical, or DFU-specific variables were significant predictors.

Conclusion: Our observations of time to DFU re-ulceration within a cohort have not been described before. High recurrence rates highlight the need for enhanced post-remission care, but most patients have a window of opportunity to initiate interventions. Identified high-risk groups may benefit from structured follow-up, personalised offloading strategies, and optimisation of cardiovascular comorbidities.

OP042 A model to predict failure of conservative treatment of patients with diabetes and osteomyelitis of the foot

Kor Hutting[1], Rimke Lagrand[2], Louise Sabelis[2], Tabby Ahmad[3], J. G. van Baal[4], Wouter Brekelmans[5], Meryl Gramberg[6], Vincent De Groot[6], Jarne Van Hattem[2], Martin Den Heijer[6], Willemijn Kortmann[7], Jaap van Netten[2], Max Nieuwdorp[2], Jean-Paul De Vries[1], Edgar Peters[6]

[1]University Medical Center Groningen, Groningen, Netherlands, *[2]Amsterdam UMC, Location AMC, Amsterdam, Netherlands*, *[3]Liverpool Hospital, Liverpool, NSW, Australia*, *[4]Ziekenhuis Groep Twente, Almelo, Netherlands*, *[5]Alrijne Hospital, Leiderdorp, Netherlands*, *[6]Amsterdam UMC, location VUmc, Amsterdam Movement Science (AMS), Amsterdam Institute for Immunity and Infectious Diseases (AII), Amsterdam, Netherlands*, *[7]Noord West Ziekenhuizen, Alkmaar, Netherlands*

Aim: There is no method to reliably assess remission of diabetic foot osteomyelitis (DFO) during treatment. This complicates deciding which patients require additional treatment to prevent relapse. The aim of this study was to develop a prediction model for failure treatment for DFO at 6 months follow-up, to improve decision-making after 6 weeks of culture-guided, conservative treatment without surgery.

Method: Data from 56 conservatively treated patients with DFO were obtained from a recent randomized controlled trial (NTR7582). We developed 2 prediction models, one with optimal discriminative performance (Model 1) and another with the fewest predictors yielding an area under the receiver operating curve (AUC) > 0.7 (Model 2). Predictors were selected using a stepwise backward selection process. Logistic regression with ridge regularization was applied, using 10-repeated 3-fold cross-validation for internal validation.

Results / Discussion: Treatment failures occurred in 27 (48%) patients. Duration of diabetes, chronic kidney disease, chronic limb threatening ischemia, plantar foot ulcer location, foot ulcer surface area, growth of gram-negative bacteria in bone biopsy culture, foot temperature asymmetry at 7 weeks and the results of two serum markers at 7 weeks (C-reactive protein and erythrocyte sedimentation rate) were predictors in Model 1. The AUC of Model 1 was 0.76. Model 2 had the following predictors: duration of diabetes, foot ulcer surface area, growth of gram-negative bacteria in bone biopsy culture and erythrocyte sedimentation rate at 7 weeks. AUC of Model 2 was 0.72.

Conclusion: We developed two prediction models for conservative treatment failures with acceptable discriminative performance. Long duration of diabetes, large foot ulcer surface area, growth of gram-negative bacteria in bone biopsy and elevated erythrocyte sedimentation rate help to predict unfavourable outcomes.

OP025 Imbalance of angiogenesis regulators and metalloproteinase activity in diabetic chronic wound healing

Oleg Petrenko[1]

[1]Bogomolets Medical Univercity, Kyiv, Ukraine

Aim: Chronic diabetic foot ulcers represent severe complications of diabetes mellitus (DM), accounting for up to 85% of purulent-necrotic lesions of the lower extremities. Impaired angiogenesis and extracellular matrix (ECM) remodeling are considered key factors in their poor healing. This study aimed to evaluate the levels of angiogenesis regulators - vascular endothelial growth factor (VEGF), hypoxia-inducible factor-1α (HIF-1α), and angiostatins - as well as the activity of matrix metalloproteinases (MMP-2 and MMP-9) in chronic wound tissue of diabetic patients.

Method: Dermal biopsies were collected from DM type II patients, following core bioethical standards of dignity, equity, and responsible care. VEGF, angiostatin, and HIF-1α levels in wound bioptates were determined by western blot analysis, while MMP activities were assessed using gelatin zymography assay.

Results / Discussion: Chronic diabetic wound tissue demonstrated a 2.5-fold reduction in VEGF compared to acute wound tissue ($P<0.01$), accompanied by elevated angiostatin levels, absent in non-diabetic wounds. MMP-2 and MMP-9 activities were increased approximately fivefold compared with intact skin. Expression of HIF-1α, a central regulator of hypoxia-driven processes, was elevated 4.4-fold in diabetic wounds compared to acute wounds ($P<0.01$).

Importantly, an inverse correlation between VEGF and HIF-1α levels was established in dermal biopsies from chronic lesions.

Conclusion: The findings suggest that angiogenesis in chronic diabetic ulcers is impaired due to reduced VEGF and excessive angiostatin production, which antagonizes proangiogenic signaling. Hyperactivation of MMP-2 and MMP-9 further disrupts ECM integrity, while elevated HIF-1α reflects maladaptive hypoxic responses. Together, these alterations contribute to defective vascularization and poor healing of ischemic diabetic ulcers. Targeting the imbalance between angiogenic regulators and MMP activity may represent a promising therapeutic strategy to improve wound repair in diabetic patients.

OP059 Efficacy of adjunctive regenerative ointment with tibial transports for diabetic foot ulcers

Haidong Liang[1]

[1]*Wound, Ostomy and Continence Nursing Clinic, the Second Hospital of Dalian Medical University, Dalian, China*

Aim: To assess whether adjunctive use of a regenerative wound ointment enhances the outcomes of transverse tibial bone transport (TTT) for diabetic foot ulcers (DFUs).

Method: In this study, 54 DFU patients undergoing TTT were randomized to receive either standard dressings (Control, n=27) or a β-sitosterol-based ointment (Experimental, n=27). The ointment was applied twice daily at a ~2 mm thickness and covered with sterile gauze. Ulcer area, pain (VAS), and Wagner grade were assessed preoperatively and at 1 and 2 months postoperatively.

Results / Discussion: The experimental group showed superior outcomes. At 2 months, the mean ulcer area was significantly smaller (0.5 vs. 2.1 cm^2, p<0.001), and VAS scores were lower (1.4 vs. 2.8, p<0.001). A significantly higher proportion of patients achieved an improvement in Wagner grade (77.8% vs. 44.4%, p=0.012).

Conclusion: Adjuvant regenerative ointment therapy with TTT significantly accelerates wound healing, reduces pain, and improves ulcer grade in DFUs compared to TTT alone, offering a valuable combined treatment strategy.

Comparison of Postoperative Clinical Outcomes Between the Two Groups (n=54)

Evaluation Metric	Time Point	Control Group (n=27)	Experimental Group (n=27)	P-Value
Ulcer Area (cm^2)	Preoperative	5.3 ± 1.7	5.0 ± 1.6	0.791
	1 Month Postop	3.6 ± 1.4	2.2 ± 1.0	**<0.001**
	2 Months Postop	2.1 ± 1.3	0.5 ± 0.6	**<0.001**
VAS Pain Score	Preoperative	6.4 ± 1.1	6.5 ± 1.2	0.852
	1 Month Postop	4.3 ± 1.2	2.9 ± 1.1	**<0.001**
	2 Months Postop	2.8 ± 1.0	1.4 ± 0.9	**<0.001**
Wagner Grade Improvement Rate (%)	2 Months Postop	44.4% (12/27)	77.8% (21/27)	**0.012**
Ankle-Brachial Index (ABI)	2 Months Postop	0.84 ± 0.10	0.86 ± 0.09	0.445
Transcutaneous Oxygen Pressure ($TcPO_2$, mmHg)	2 Months Postop	41.8 ± 5.5	43.5 ± 6.1	0.281



OP060 Outcome of the EXPLORER RCT based on current wound classification of SINBAD and WIfI: Improved healing in severe ulcers treated with nano-oligosaccharide factor (TLC-NOSF)

Chris Manu[1]

[1]*King's College Hospital, Denmark Hill, Diabetic Foot Clinic, London, United Kingdom*

Aim: Current international guidelines recommend the use of SINBAD and WIfI classification for DFU assessments. The double blinded EXPLORER RCT demonstrated an 18 points difference between the treatment group of SOC plus TLC-NOSF vs control group. Original EXPLORER RCT, inclusion eligibility and results were based on the Texas Classification. The aim was to assess the wound outcomes within EXPLORER based on a reclassification with SINBAD and WIfI.

Method: A retrospective reclassification and post-Hoc analysis of wounds treated within EXPLORER. Wound healing were compared between the TLC-NOSF and control groups for severe ulcers (SINBAD score ≥3) and less severe ulcers, as well as reclassification for the levels of WIFI scores. Then evaluated to ascertain if the results would be comparable if the latter two classification systems are utilised.

Results: All 240 patients were successfully reclassified with SINBAD; 52.5% had severe ulcers. Severe ulcers were more frequent in the NOSF group (57.9%) than in the control group (46.5%). Despite this imbalance, healing of severe ulcers remained superior with TLC-NOSF (43.8%) compared to control (24.5%). WIfI reclassification was possible for 237 patients (126 NOSF; 111 control). Among these, 26.2% of ulcers had a Low or Moderate WIfI amputation-risk score. The NOSF group included a higher proportion of Moderate-risk ulcers (8.7% vs 4.5%). Nevertheless, 20-week healing among Moderate-risk ulcers was markedly higher with TLC-NOSF (63.6%) than with control (20%).

Conclusion: The use of SINBAD or WIFI still supports treatment with TLC-NOSF for better ulcer healing rate, despite having a higher proportion of more severe ulcer compared to the control group. Thus, the need for a better uptake of TLC-NOSF treatment in this cohort.

OP038 Comparison of transcutaneous CO_2 therapy and standard wound treatment for diabetic foot ulcers: A multicentre controlled study

Igor Frangež[1 2], Helena Ban Frangež[1 2], Miloš Potkonjak[3], Skender Veliu[4], Željko Metelko[5], Julija Križaj[1]

[1]Department of Surgical Infections, University Medical Centre Ljubljana, Ljubljana, Slovenia, [2]Faculty of Medicine, University of Ljubljana, Ljubljana, Slovenia, [3]Department of Vascular Surgery, General hospital Novo mesto, Novo mesto, Slovenia, [4]Department of Surgery, General hospital Ptuj, Ptuj, Slovenia, [5]Polyclinic for Physical Medicine and Rehabilitation with Physical Therapy and Vascular Surgery, Neurology, and Endocrinology and Diabetology, Zagreb, Croatia

Aim: Diabetic foot ulcers (DFUs) are a common and severe complication of diabetes, often associated with underlying microvascular disease (MVD), which notably impairs tissue perfusion and delays wound healing. Existing therapeutic approaches largely target macrovascular dysfunction, while the contribution of microvascular impairment often remains insufficiently addressed. The aim of this multicentre randomized controlled study was to evaluate the effectiveness of transcutaneous carbon dioxide (CO_2) therapy in enhancing wound healing in patients with chronic DFUs and confirmed MVD.

Method: A total of 115 patients with chronic DFUs were included in the study. Of these, 76 were assigned to the group receiving CO_2 therapy and 39 to the control group. All patients received standard wound care in addition to their assigned treatment. Wound area was measured using a non-contact 3D laser scanner, and wound bed status was assessed using the Falanga score.

Results: Results showed significantly improved healing in the study group, with 64.5% of wounds achieving complete closure compared to 7.7% in the control group. Median wound area was reduced to 0.00 cm^2 in the study group vs. 0.80 cm^2 in the control group ($p < 0.001$), with a median healed area of 100% vs. 40% ($p < 0.001$). Patients receiving CO_2 therapy were 35 times more likely to achieve complete wound healing (OR = 35.392; $p < 0.001$).

Conclusion: Transcutaneous CO_2 therapy significantly improves wound healing outcomes in patients with DFUs and MVD, representing a safe and effective addition to standard treatment protocols.

OP043 Synthetic vs biologic matrix in high-severity diabetic foot limb salvage: A real-world cohort with severity-adjusted analysis and mobilization stress test

Marco Marcianò[1], Bianca Vicari[1], Isabella Campo[1], Paolina Venturelli[1], Valentina Lombardo[1], Francesco Maltese[1], Sefora La Sala[1], Giuseppe Carollo[1], Giuseppe Salamone[1], Giovanni Guercio[1]

[1]A.O.U.P. Paolo Giaccone, Università degli studi di Palermo, Palermo, Italy

Aim: Diabetic foot limb salvage in high-severity wounds requires dermal substitutes capable of maintaining structural integrity under infection, ischemia, and mechanical load. Comparative real-world evidence between fully synthetic and biologic matrices remains limited. This study assessed whether a synthetic bilayer device provides compared with a biologic matrix in complex diabetic foot.

Methods: A retrospective monocentric cohort (2023–2025) of 77 patients undergoing limb-salvage was analyzed. Patients were treated with either a synthetic dermal substitute (n=61) or a biologic matrix (n=16). Lesions were highly complex, with SINBAD scores 4–6 and a predominance of Texas University Classification stage D3. Primary outcomes were device removal for complication, epithelialization time, and coverage of exposed bone and tendons. Mobilization after surgery was recorded as a clinically relevant stress condition. Multivariable models adjusted for SINBAD and Texas stage.

Results: Despite comparable severity, the synthetic device showed markedly lower failure rates (9.8% vs 37.5%). After adjustment, the synthetic matrix remained independently protective (OR 0.15; p=0.010). Healing was significantly faster with the synthetic device (median 100 vs 198 days), with adjusted models indicating approximately 50% shorter epithelialization time (time-ratio ≈0.49; p=0.001). Tendon coverage strongly favored the synthetic matrix (86.9% vs 46.7%; adjusted OR 7.61; p=0.002), while bone coverage was similar. Mobilization acted as a mechanical "stress test": among mobilized patients, device failure occurred in 57% with the biologic matrix versus only 8% with the synthetic device (p=0.012). Mobilization itself did not prolong healing in the synthetic group.

Conclusion: In high-severity diabetic foot wounds, the synthetic dermal substitute demonstrated superior mechanical stability, faster healing, and markedly better tendon coverage, including under mobilization. These findings support mobilization-tolerant reconstruction strategies enabled by synthetic matrices.

OP050 Efficacy of bromelain-based debridement (BBD) in diabetic foot ulcers: A post hoc analysis

Robert Snyder[1], Adam Singer[2], Asi Haviv[1], Cyaandi Dove[3]

[1]MediWound Ltd., Yavne, Israel, *[2]Stony Brook University, Stony Brook, NY, United States*, *[3]Oregon Health & Science University, Potland, Oregon, United States*

Aim: Chronic wounds affect millions annually in the U.S. and impose substantial healthcare costs. Effective debridement is essential for initiating tissue repair. Bromelain-based debridement (BBD) has demonstrated safety and efficacy in burns and venous leg ulcers (VLU). This post hoc subgroup analysis evaluates BBD's performance in diabetic foot ulcers (DFUs) using data from a multicenter, assessor-blinded randomized controlled trial.

Method: Seventy-three patients with chronic lower-extremity ulcers (VLU, DFU, or traumatic) were randomized 2:1 to BBD 5% or a gel-vehicle (GV) control with once-daily applications for up to 10 sessions over two weeks, followed by 12 weeks of weekly follow-up. This analysis focuses on 19 DFU patients (12 BBD, 7 GV). Complete debridement (CD) was defined as ≥90% removal of non-viable tissue within two weeks or 100% removal anytime. Granulation was assessed clinically. Wound bed preparation (WBP) required CD plus ≥75% granulation, and wound closure required full epithelialization without drainage or dressings for two consecutive weeks. This exploratory subgroup was not powered for statistical significance.

Results / Discussion: Baseline characteristics were comparable (age 64 vs. 61 years; wound size 22 vs. 24 cm^2; duration 11 vs. 23 weeks). CD within two weeks occurred in 58% (BBD) vs. 14% (GV), and ≥75% granulation in 42% vs. 17%. WBP anytime was achieved in 75% (BBD) vs. 43% (GV); wound closure in 57% vs. 25%. Median time to CD was 23 vs. 128 days. Time to WBP 23.5 days vs. not reached for BBD and GV, respectively.

Conclusion: BBD provides clinically meaningful advantages in debridement and granulation in DFUs, achieving faster progression to WBP than GV. Findings support advancing BBD into larger phase II/III DFU studies.

OP051 Trends in hospitalization and amputations in diabetic foot ulcers in Germany 2019 to 2024

Steffen Wahler[1], Christiane Koll[2]

[1]St. Bernward GmbH, Hamburg, Germany, *[2]Diabetespraxis Blankenese, Hamburg, Germany*

Aim: Diabetic foot ulcers (DFUs) remain one of the most serious complications of diabetes mellitus, frequently leading to hospitalization and lower-extremity amputation. Global data indicate a five-year mortality of approximately 40–50% in individuals with DFU. Despite advances in multidisciplinary foot care, cohort data report lower-extremity amputation in 18–20% of DFU patients. Against this epidemiological background this study aimed to analyze current national trends in Germany regarding DFU-associated hospitalizations and minor and major amputations from 2019 to 2024.

Method: Retrospective nationwide health insurance data and hospital discharge statistics based on disease and procedure codes were analyzed for DFU patient hospitalizations, demographics and amputations. Descriptive statistics were used to assess temporal trends.

Results / Discussion: Between 2019 (56,908 cases) and 2024 (56,847 cases), DFU-related hospitalizations remained stable; however, a temporary decline to 50,480 hospitalizations occurred in 2022. The vast majority of patients had type 2 diabetes (94.8%), and 76.8% were male. Total hospital days decreased by 10.3%, with reduced mean length of stay from 15.6 to 14.0 days. In contrast, amputations increased from 23,046 to 23,378 (+1.4%). Major amputations rose from 2,720 to 2,917 (+7.2%), while minor amputations increased by 0.7%. In 2024, 96.0% of all amputated patients had type-2 diabetes, and 80.7% were male. Length of stay was 18.0 days for minor and 29.5 days for major amputations. These findings align with international literature reporting rising amputation risks despite stable hospitalization rates.

Conclusion: Although hospitalizations for DFU remained stable in Germany, amputation rates—particularly major amputations—continue to rise. These trends emphasize the need for earlier preventive interventions, optimized multidisciplinary care pathways, and continuous national monitoring.

EP111 The efficacy of topical hemoglobin spray in diabetic wound management

Chao-hsin Huang[1], Yur-Ren Kuo[1]

[1]Division of Plastic Surgery, Department of Surgery, Kaohsiung Medical University Hospital, Kaohsiung Medical University, Kaohsiung, Taiwan

Aim: Chronic diabetic foot ulcers and subsequent complications can have numerous negative impacts on patients' quality of life. The peripheral vasculopathy induced lack of oxygen supply to these regions could decrease wound healing. In this study, we report the efficacy of the topical hemoglobin spray, a topical spray containing hemoglobin, for the treatment of chronic diabetic foot wounds and follow the outcomes.

Method: Seven patients with an average age of 68.3 ± 9.8 years (range: 57-79 years) were presented Type II diabetes mellitus and chronic DFUs with lower limbs ischemia. Patients were received debridement, and endovascular intervention if poor circulation. After several weeks of wound care and adjunctive therapy, these patients still exhibited poor healing. The topical hemoglobin spray was then prescribed, and the wound was observed twice a week. The condition of the wounds, complications, healing progression, and other detailed information were documented.

Results / Discussion: Initial wound sizes of these patients were ranged from 1.5-12.5 cm^2. After receiving topical hemoglobin spray treatment for 2-7 months, all patients recovered well, and wounds healed uneventfully without noticeable side effects. None of the patients reported complications, including local wound inflammation or infection, at their follow-up 16months after completing their treatment.

Conclusion: Topical hemoglobin spray could be suitable to effectively increase the oxygen content in the hypoxic wound regions. In patients who were presented with chronic DFUs, topical hemoglobin spray is a good option for rescuing unhealed wound of ischemic limb.

OP052 Awareness regarding diabetic foot complication among diabetic patients in a tertiary care hospital, South India

Georg Gutjahr[1], Sankar Das[1], Malavika Krishnakumar[1], Dipu T S[1], Ulla Hellstrand Tang[2], Anneli Ringblom[2], Vivek Lakshmanan[1]

[1]Amrita Institute of Medical Sciences, Kochi, India, *[2]University of Gothenburg, Gothenburg, Sweden*

Aim: Diabetic foot complications remain a major cause of morbidity and lower-limb amputations among individuals with diabetes, particularly in regions with high disease prevalence such as India. This study aimed to analyze the level of awareness regarding diabetic foot care and its associated complications among diabetic patients who underwent transmetatarsal amputation in a tertiary care centre.

Method: A retrospective cross-sectional study was conducted in a tertiary care center in South India. Data from 100 diabetic patients who underwent transmetatarsal amputation were extracted from electronic medical records. Information on demographic characteristics, comorbidities, and responses standardized questionnaire (DiaFootQ) assessing foot care and complication awareness was analyzed. Regression analyses were performed to identify associations between awareness scores and specific comorbidities.

Results / Discussion: The median age of participants was 65 years, with hypertension (59%) and coronary artery disease (20%) being the most prevalent comorbidities. Overall awareness of diabetic foot complications was moderate (median score = 61), whereas foot care–specific awareness remained low. Overall awareness and lifestyle-related awareness were significantly associated with coronary artery disease ($p = 0.046$; $p = 0.034$). No other comorbidities showed significant associations. Notably, 86% of patients had never consulted a podiatrist, and 73% reported not drying between their toes. Age-related challenges were evident in nail care (43%) and exercise practices (38%). Influence analyses suggested poorer awareness among patients with CAD, CKD, and CVA, underscoring the clinical vulnerability of these subgroups.

Conclusion: This study demonstrates substantial deficiencies in diabetic foot care awareness among diabetes patients in South India. Targeted, culturally appropriate education and multidisciplinary care strategies are essential to enhance self-care, reduce foot complications, and prevent future amputations.

EP112 Early-stage management of diabetic foot burns: Prioritizing serial debridement and wound care to reduce graft failure

Alperen Pala[1], Gaye Filinte[2], Müge Sert[1], Selin Uyar[1], Rıdvan Erden[1]

[1]Kartal Dr.Lütfi Kırdar City Hospital, Istanbul, Türkiye, *[2]University of Health Sciences, Kartal Dr.Lütfi Kırdar City Hospital, Istanbul, Türkiye*

Aim: Diabetic foot burns are usually deep burns due to associated hypoesthesia. In order to avoid graft failure, frequent debridement and dressings are evaluated for wound care.

Method: This retrospective study included 25 patients with diabetes who sustained foot burns and were treated between 2023–2025. Patients were divided into two groups. Partial thickness burns(n:11) and deep burns(n:14). Instead of immediate grafting, all patients underwent an initial period of conservative management consisting of serial sharp debridement, advanced dressings, and close outpatient follow-up. Grafting was performed only when a well-vascularized wound bed was achieved or when epithelialization plateaued. Time to granulation, time to epithelialization or grafting, infection rates, and need for amputation were recorded.

Results / Discussion: 11 of the patients have partial-thickness burns at presentation but demonstrated delayed demarcation due to diabetic microangiopathy. 14 patients sustained deep foot burns due to diabetic-related hypoesthesia. Conservative wound care successfully supported progressive granulation in the majority of cases. Only 1 patient in the partial-thickness group required grafting, while 4 patients with deep burns ultimately underwent split-thickness skin grafting after wound-bed optimization. Infection rates were low in both groups (2 in the partial-thickness group and 4 in the deep-burn group), and no major amputations were required. Median time to complete

epithelialization or stable graft take was 12.3 days in the partial-thickness group and 15.2 days in the deep-burn group.

Conclusion: Delayed grafting combined with structured debridement and dressing-based wound optimization appears to be a safe and effective strategy for diabetic foot burns. This approach allows clear burn demarcation, minimizes unnecessary grafting, without increasing infection or complication rates.

OP026 Midfut: Multiple interventions for diabetic foot ulcer treatment randomised controlled trial (RCT)

Myka Ransom[1], Annah Muli[1], Rachael Gilberts[1], Stephanie Kuunal[1], Helena Meally[2], Nikki Dewhirst[1 3], Elizabeth McGinnis[1], Henrietta Konwea[4], Chris Bojke[4], Jane Nixon[4], David Russell[1 3]

[1]Leeds Institute of Clinical Trials Research, University of Leeds, Leeds Vascular Institute, Leeds Teaching Hospitals NHS Trust, Leeds, United Kingdom, *[2]University Hospitals Birmingham NHS Foundation Trust, Birmingham, United Kingdom*, *[3]Leeds Vascular Institute, Leeds Teaching Hospitals NHS Trust, Leeds, United Kingdom*, *[4]Leeds Institute for Health Sciences, University of Leeds, Leeds, United Kingdom*

Aim: Diabetic foot ulcers (DFUs) are a significant burden to patients and the NHS, with poor outcomes still being reported despite advances in treatment as usual (TAU). Earlier healing of DFUs improves patient outcomes and reduces treatment costs. The use of adjuvant therapy is limited by expense and lack of robust evidence. To determine the most efficient adjuvant therapy regimen, MIDFUT compared four treatment strategies comprising combinations of hydrosurgical debridement (HD), negative pressure wound therapy (NPWT), and decellularised cadaveric dermis (DCD) graft to TAU alone: HD, HD+NPWT, HD+DCD, HD+DCD+NPWT.

Method: MIDFUT was a multicentre, seamless Phase II/III, open, parallel, adaptive multi-arm multi-stage RCT with planned "drop-the-losers" interim analysis at 4 weeks to select best treatment strategies to be definitively evaluated up to 52 weeks post-randomisation.

Results / Discussion: The HD+NPWT strategy was deemed less clinically meaningful in practice – for efficiency, recruitment to that arm ceased early. 213 participants were recruited into the trial. For the primary Phase II endpoint, the proportion of DFUs achieving ≥50% wound area reduction at 4 weeks, no treatment arm signaled clinical benefit over TAU alone (20-30% vs 37.5% respectively). Therefore, no treatment arm met progression criteria to advance to Phase III. A higher proportion of participants in HD+DCD+NPWT experienced treatment-strategy related adverse events (17.5%) compared to HD (4.9%) and HD+DCD (7.3%).

Conclusion: The Phase II analysis did not uncover any clinical signal to justify taking any of the treatment strategies forwards for definitive evaluation. The adequacy of wound debridement in the trial warrants secondary analysis.

OP061 Clinical outcomes of osteotomy vs. conventional management for non-healing pressure ulcers of the great toe

Mafruha Nusrat Khan[1], Mohammad Mahbub Alam[2]

[1]BIRDEM General Hospital, Bangladesh Diabetic Wound and Foot care limitedt, Dhaka, Bangladesh, *[2]Bangladesh diabetic wound and Foot care limited, BIRDEM General Hospital, Dhaka, Bangladesh*

Aim: Non-healing pressure ulcers of the great toe are a challenging clinical problem, often associated with prolonged pressure, neuropathy, infection, and underlying comorbidities such as diabetes or peripheral vascular disease. This study aimed to compare the clinical outcomes of ostectomy versus conventional management in patients with non-healing great-toe pressure ulcers.

Method: This was a prospective comparative study conducted at a tertiary care hospital in Dhaka, from January 2024 to July 2025, involving 100 patients with non-healing pressure ulcers of the great toe who were allocated into two groups of 50 each. Data were analysed using SPSS version 26.0.

Results / Discussion: Group A showed significantly better healing outcomes, with higher complete healing at 12 weeks (84% vs 48%) and shorter healing time (10.4 vs 11.2 weeks). Recurrence was lower in Group A (12% vs 28%), and fewer required additional surgery (8% vs 24%). Minor complications were comparable, and no major complications occurred. Functional outcomes favored Group A, with more patients returning to normal footwear (76% vs 48%) and improved gait stability (80% vs 52%).

Conclusion: In this study, ostectomy demonstrated significantly higher healing rates and shorter mean time to healing compared with conventional management. Specifically, 80% of patients in the ostectomy group achieved complete ulcer closure within almost 10 weeks, compared with 52% in the conventional care group. Infection resolution and reduction in ulcer recurrence were also more favorable with ostectomy.

OP044 Ulcer recurrence impairs outcomes of patients with diabetic foot

Federico Rolando Bonanni[1], Martina Salvi[1], Marco Meloni[1], Luigi Uccioli[1], Aikaterini Andreadi[1], Alfonso Bellia[1], Davide Lauro[1]

[1]Division of Endocrinology and Diabetology, Policlinico Tor Vergata Hospital, Rome, Italy

Aim: The current study aimed to evaluate the incidence of ulcer recurrence in patients with diabetic foot and its impact on clinical outcomes. The research is retrospective observational study including a population of patients with diabetic foot ulcers requiring hospitalization managed between January to September 2024 in a tertiary level diabetic foot service. All patients have been treated by a local multidisciplinary protocol in the respect of international guidelines. At the admission, patients were divided in two groups: those with ulcer recurrence and those without ulcer recurrence. After six months of follow-up, the following outcomes were evaluated and compared between groups: healing, mortality, and major amputation.

Method: 205 patients were included. The mean age was 68.9 ± 12.3, the majority had type 2 diabetes (93.4%) with a mean diabetes duration of 20.9 ±12.6; 155 (75.6%) of patients reported ischaemic DFUs, and 158 (77 %) reported infections. There were not significant differences between the 2 groups at the assessment, except for the higher rate of ischaemic heart disease in recurrent patients when compared to not recurrent (50.7 vs 31.2%, p= 0.006).

Results / Discussion: Outcomes for DFU recurrence and not were: wound healing (47.7 vs 62.8%, p= 0.04), mortality (12.3 vs 4.3% p=0.03), and major amputation (4.6 vs 5%, p= 0.1) respectively.

Conclusion: Ulcer recurrence in diabetic foot patients requiring hospitalization is strongly associated with reduced chance of healing and mortality. These findings emphasize the need for intensive follow-up, comprehensive management of cardiovascular comorbidities, and a multidisciplinary approach to improve long-term prognosis in this vulnerable population.

OP027 Multicenter randomized evaluation of transforming powder dressing versus standard of care for Wagner grade 1 and 2 diabetic foot ulcers

Lawrence A. Lavery[1 2], Susan St. John[1], John St. John[1], Marcel de Souza Borges Quintana[1 3], Carolyn Yanavich[1], Jonathan Saxe[1 4]

[1]Altrazeal Life Sciences Inc., Addison, United States, *[2]UT Health San Antonio, Altrazeal Life Sciences Inc., San Antonio, United States*, *[3]Institute of National Infectology–Oswaldo Cruz Foundation, Altrazeal Life Sciences Inc., Rio de Janeiro, Brazil*, *[4]Ascension St. Vincent Hospital –Indianapolis, Altrazeal Life Sciences Inc., Indianapolis, United States*

Aim: Nearly 18.6 million people worldwide develop a diabetic foot ulcer (DFU) annually[1]. DFUs are a major diabetes complication, drive hospitalizations, precede lower-extremity amputations, and increase mortality risk.[1] Although DFU care standards are established, practice varies due to inconsistent dressing use and limited comparative evidence for advanced products. This Phase IV, multicenter, randomized clinical trial evaluated the effectiveness, usability, and resource implications of transforming powder dressing (TPD) compared with standard-of-care (SOC) dressings for treatment of chronic DFUs.

Method: Adults with Wagner grade 1–2 DFUs were randomized 1:1 to TPD or SOC at 11 U.S. sites with weekly follow-up for 12 weeks or until closure. The aim was to assess whether TPD could reduce wound management burden without adversely impacting clinical outcomes. The primary endpoint was complete re-epithelialization sustained for two consecutive visits; secondary endpoints included wound area reduction (WAR), dressing-change frequency, debridement needs, recurrence, and usability.

Results / Discussion: 135 participants were enrolled (mean age 62 years; 87% male). Baseline wound size was significantly larger in the TPD arm (~80% greater median wound area vs. SOC). Despite this, wound closure rates by Week 12 were comparable between groups. TPD achieved significantly greater weekly WAR (51% relative improvement; $p = 0.002$), reduced dressing changes by 67% ($p < 0.001$), and required 33% fewer debridements ($p = 0.01$). Pain scores during dressing changes were 59% lower in the TPD cohort ($p = 0.02$) patient satisfaction favored TPD, with >80% reporting superior ease, comfort, and convenience.

Conclusion: The TPD cohort demonstrated accelerated WAR, markedly lower treatment burden, and high user satisfaction, supporting its potential as an efficient, patient-centered option for DFU management across diverse clinical environments.

OP028 The DOMINO-DFU study (Diagnosis of Osteomyelitis: Investigation Optimisation in Diabetic Foot Ulcers) – Results of phase one: a multicentre observational cohort study

Hannah Mather[1], Myka Ransom[1], Henrietta Konwea[2], Joanna Dennett[1], Howard Collier[1], Jess Chan[1], Rachael Gilberts[1], Chris Bojke[2], Deborah Stocken[1], Jane Nixon[2], David Russell[1 3]

[1]Leeds Institute of Clinical Trials Research, University of Leeds, Leeds Vascular Institute, Leeds Teaching Hospitals NHS Trust, Leeds, United Kingdom, *[2]Leeds Institute for Health Sciences, University of Leeds, Leeds, United Kingdom*, *[3]Leeds Vascular Institute, Leeds Teaching Hospitals NHS Trust, Leeds, United Kingdom*

Aim: Osteomyelitis (OM) complicates 20% of diabetes-related foot ulcers (DFUs). Guidelines for diagnosis of OM in DFU are inconsistent, with variation in diagnostic practice and treatment thresholds between clinicians. The NIHR funded DOMINO-DFU study aims to describe a prospective cohort of DFU patients with high-risk clinical features for OM, including diagnostic criteria; initial treatment strategy; and clinical outcomes.

Method: In this multicentre prospective observational cohort, all referrals with new DFUs in participating centres were invited to join the cohort study. Participants with high-risk clinical features for OM (probe-to-bone (PTB)+/-soft tissue infection; ulcer depth ≥3mm; dactylitis; ulcer area ≥2cm^2; failure to heal >50% in 4weeks) were included in a high-risk subgroup. Follow-up was via clinical records at 12, 24 and 52weeks post-registration to the study.

Results / Discussion: 432 cohort and 244 high-risk participants were recruited across four UK DFU-multidisciplinary services. Cohort DFU healing was 41.9% at 12weeks and 69.0% at 52weeks. One-year mortality was 14.4% with 31.5% incidence of clinically diagnosed OM. The leading high-risk features for OM diagnosis were ulcer depth ≥3mm, PTB +ve and dactylitis. There was higher rate of X-ray (87.9% vs 35.3%), blood tests (34.1% vs 9.8%) and microbiological sampling (76.9% vs 12.4%) with OM diagnosis. OM was associated with lower ulcer healing (18.7%, 47.3% at 12, 52weeks respectively), minor amputation (29.7%) but not major amputation (2.2%). One-year mortality was 17.6%. The leading primary treatment was systemic antibiotics, leading to 72.5% OM remission at 52weeks.

Conclusion: The diagnosis of OM seems primarily clinically driven. A clinical diagnosis of OM increases the risk of delayed healing and minor amputation. Outcomes of medical management are in line with retrospective series.

OP045 Six-month outcomes of population-based diabetic foot screening: A case-cohort study of 17,974 primary care patients

Shaun Chan[1], Julia Zhu[2], Lixia Ge[3], Elaine Tan[2], Huiling Liew[4], Jeremy Hoe[5], Jaime Lin[1], Zhiwen Joseph Lo[1]

[1]Woodlands Health Wound and Vascular Centre, Singapore, Singapore, *[2]National Healthcare Group Polyclinic, Singapore, Singapore*, *[3]National Healthcare Group HQ, Singapore, Singapore*, *[4]Tan Tock Seng Hospital, Singapore, Singapore*, *[5]Khoo Teck Puat Hospital, Singapore, Singapore*

Aim: To evaluate 6-month outcomes of a population-based diabetic foot screening (DFS) programme in preventing diabetic foot disease and improving screening adherence within Singapore's primary care sector.

Method: This retrospective case-cohort study evaluated the effectiveness of a structured DFS programme among patients with diabetes mellitus at moderate-high risk of diabetic foot disease within National Healthcare Group Polyclinics. We compared outcomes between 7,774 participants enrolled in a structured DFS programme (1 Jan 2024 to 1 May 2024) and 10,200 patients receiving standard care (1 Jul 2021 and 1 May 2023). The intervention comprised risk-stratified surveillance with comprehensive foot assessments, patient education, and standardised referral pathways. The primary outcome was incident diabetic foot disease during 6-month follow-up. Secondary outcomes included lower-extremity amputations and screening adherence rates. Multivariable logistic and Poisson regression analyses were used to assess intervention effectiveness in diabetic foot disease prevention and identify factors associated with higher DFS compliance.

Results / Discussion: Programme participants demonstrated lower odds of developing diabetic foot disease compared with controls (adjusted odds ratio [aOR]: 0.64, 95% confidence interval [CI]: 0.56 - 0.73) and 79% higher screening adherence rates (incident rate ratio [IRR]=1.79, 95% CI: 1.71 - 1.87, p<0.001). High-risk patients were more likely to develop diabetic foot disease yet showed lower screening adherence (IRR: 0.92, 95% CI: 0.88, 0.97, p=0.002. Male gender (IRR=1.07, p=0.002) and advancing age (IRR=1.01, p<0.001) were associated with higher screening adherence.

Conclusion: Implementation of structured diabetic foot screening in primary care effectively prevented diabetic foot disease and improved screening adherence compared with standard care. However, the counterintuitive finding that high-risk patients showed lower screening participation identifies critical barriers that must be addressed to optimise programme effectiveness.

OP054 Effectiveness of sucrose-octasulfate impregnated dressing as first-line treatment in patients with diabetic foot ulcers

Marco Meloni[1], Serge Bohbot[2], Federico Rolando Bonanni[1], Martina Salvi[1], Beatrice Tellini[1], Luigi Uccioli[1], Davide Lauro[1]

[1]Tor Vergata University, Rome, Italy, *[2]Urgo Medical, Paris, France*

Aim: To evaluate the effectiveness of Technology Lipido-Colloid (TLC) dressing impregnated with sucrose-octasulfate (NOSF compound, Nano-Oligo-Saccharide Factor) as first line treatment in patients with diabetic foot ulcers (DFUs).

Method: The study is a prospective real-world study including consecutive patients affected by non-infected neuropathic/neuro-ischaemic DFUs with ulcer duration < 4 weeks, ulcer surface between 1 and 30 cm^2, absence of severe limb ischaemia (TcPO2 > 30 mmHg), without indication to reconstructive surgery (1st intention surgery or reconstruction of tendons, muscles and bone). After the first assessment, all patients have been treated with TLC-NOSF dressings in association to the standard of care according to international guidelines. The primary endpoint was considered the complete healing (100% re-epithelialization) after 20 weeks of treatment. Secondary endpoints were considered the healing time, the rate of wound area regression >50%, the safety of the treatment (local adverse events).

Results / Discussion: Overall, 40 patients were included. The mean age was 67 years, 32 (80%) patients were male, the majority had type 2 diabetes (97.5%), 28 (70%) had neuro-ischaemic DFUs, the mean ulcer area was 137

cm^2 (most of them were post-surgical wounds). After 20 weeks of follow-up, 27 (67.5%) achieved complete healing, the mean healing time was 126 weeks, 33 (82.5%) had a wound regression >50%. Additionally, 2 patients (5%) developed local adverse events (1 local infection, 1 skin aspecific inflammation); none of them required hospitalization.

Conclusion: TLC-NOSF dressings showed high rates of healing and acceptable healing time when used as first-line treatment in non-infected neuropathic and neuro-ischaemic DFUs. In addition, TLC-NOSF reported a good safety profile.

OP039 Effect of custom-made insoles on plantar sensory function in patients with diabetic foot: A 12-week prospective analysis

Yavuz Aslan[1], Yağmur Uysal[2], Esra Atılgan[2]

[1]University of Health Sciences, Department of Underwater and Hyperbaric Medicine, Sultan 2nd Abdulhamid Han Training and Research Hospital, Istanbul, Türkiye, *[2]Istanbul Medipol University, Institute of Health Sciences, Istanbul, Türkiye*

Aim: This study aimed to evaluate whether custom-made insoles designed to redistribute plantar pressure influence plantar protective sensory function in individuals diagnosed with diabetic foot.

Method: Twenty-three participants (mean age: 57.7 years; Type 1 diabetes: n=4, Type 2 diabetes: n=19) underwent pedobarographic assessment followed by fabrication of individualized custom insoles. Plantar sensation was evaluated using the 10-site Semmes–Weinstein Monofilament Test (SWMT) before insole use and after 12 weeks. Both feet were assessed at both time points. Pre–post sensory changes and right–left foot comparisons were analyzed using non-parametric tests due to the distribution characteristics of the data.

Results / Discussion: Pre–post comparison demonstrated no statistically significant change in SWMT scores in either the right foot ($Z = –0.782$, $p = 0.434$) or the left foot ($Z = –0.838$, $p = 0.402$). Minor fluctuations in mean sensory scores were observed but did not reach significance. At both baseline and follow-up, right–left comparisons also showed no significant differences ($p > 0.50$). Overall, a 12-week period of custom insole use neither improved nor deteriorated plantar protective sensation.

Conclusion: Custom-made insoles—which are widely used to reduce plantar pressure and prevent ulceration—did not produce measurable short-term changes in plantar sensory perception. Protective sensation remained stable over the 12-week period. Larger-scale, longer-term studies are needed to determine whether extended use may contribute to sensory adaptation or pressure-related neuroprotective effects.

OP029 Prospective study to evaluate diagnostic characterisitics of the probe to bone test to diagnose osteomyelitis in moderate and severe diabetic foot infections admitted to hospital

Lawrence A. Lavery[1], Arthur Tarricone[1], David Lavery[2], Nitish Thirugnanasambandam[1], Joseph Alderete[1], Allen Gee[3]

[1]University of Texas Health San Antonio, San Antonio, United States, *[2]Statistical Analytics, Denver, United States*, *[3]Mount Sinai Morningside, New York, United States*

Aim: To evaluate the probe to bone test (PTBT) to diagnose diabetic foot osteomyelitis (OM) in patients admitted to hospital for moderate and severe foot infections.

Method: This was a post hoc analysis of 233 patients evaluated in a randomized clinic study to assess negative pressure wound therapy with and without continuous irrigation in people with moderate and severe foot infections. We used bone biopsy with either a positive culture or histologic exam to define OM. Bone specimens were obtained in the operating room after soft tissue debridement and irrigation using clean instruments. PTB test was done at the time of hospital admission using a sterile wood probe.

Results / Discussion: As expected, the majority of the subjects had osteomyelitis (73.4%, n=171), and 134 (57.5%) had + PTBT and OM. Only 32 people (24.06%) had a +PTBT with no osteomyelitis. 37 people had OM and a - PTBT.

Diagnostic Statistics	
Sensitivity	0.78
Specificity	0.48
Positive Predictive Value	0.81
Negative Predictive Value	0.45
Accuracy	0.70
Positive Likelihood Ratio	1.51
Negative Likelihood Ratio	0.45
Diagnostic Odds Ratio	3.4
False Positive Rate	0.52
False Negative Rate	0.22

Conclusion: The pretest probability of osteomyelitis in people admitted to hospital is usually very high, as demonstrated in this study, and our results should be used with this specific patient population. Our results were not as robust as previous meta-analysis on this topic. Our results suggest that this should not be used as a "stand alone" diagnostic test to diagnose osteomyelitis.

OP030 Effectiveness of antibiotic-loaded calcium sulfate (ALCS) on infected foot ulcers: Impact on systemic antibiotic usage and healing rates

Caoimhe Joyce-Hearne[1], Roshni Patel[1], Vaishali Desai[1], Amina Ceesay-Jaiteh[1], Alpa Lakhani[1], Hany Zayed[1], Michael Robinson[1], Carolyn Hemsley[1], William Newsholme[1], Aaisha Saqib[1], Helen Rapley[1], Stephen Thomas[1], Prashanth Vas[1]

[1]*Guys and St Thomas Hospital, London, United Kingdom*

Aim: Difficult-to-heal diabetic foot ulcers (DFUs) are frequently complicated by chronic infection, leading to prolonged systemic antibiotic exposure. Local antibiotic delivery using biodegradable carriers may reduce systemic dependence while promoting healing. This evaluation assessed systemic antibiotic usage and wound outcomes following outpatient use of antibiotic-loaded calcium sulfate (ALCS).

Method: A prospective review of 66 consecutive patients attending a multidisciplinary diabetic foot clinic over 18 months (Oct 2023–Apr 2025) was undertaken. Key outcomes included systemic antibiotic use, ≥50% percentage area reduction (PAR) at 12 weeks, and complete healing.

Results / Discussion: Peripheral arterial disease was present in 51%, and 92% had diabetes. Wounds included chronic ulcers (55%), acute/post-surgical wounds (36%), and ulcers with no remaining surgical options (9%). Antibiotic loading comprised vancomycin, gentamicin, or combinations thereof, with 70% receiving vancomycin+gentamicin. Systemic antibiotics were not used in 44% at the time of ALCS application. Of these, 42% had systemic therapy stopped immediately prior. Among those not receiving systemic antibiotics, 25% achieved PAR ≥50% and 32% achieved complete healing (mean 16.5 weeks). Among those continuing systemic therapy, 37% achieved PAR ≥50% but only 23% fully healed (mean 20.1 weeks). Across the entire cohort, 63% achieved PAR ≥50% by 12 weeks. Complete healing occurred in 15% by 12 weeks, increasing to 37% by 24 weeks, and 50% by end of follow-up.

Conclusion: Outpatient ALCS use produced encouraging healing trajectories while substantially reducing systemic antibiotic exposure. These findings demonstrate that ALCS can be used safely and effectively in complex DFUs without compromising outcomes, supporting its potential role in antimicrobial stewardship and DFU management, and warranting further controlled evaluation.

OP062 Tenotomy - effective off-loading method for diabetic foot ulcer healing? (bicentral study)

Vladimíra Fejfarová[1], Tereza Didičová[1], Bedrich Sixta[2], Karol Sutoris[3], Veronika Woskova[1], Radka Jarosikova[1], Dominika Sojakova[1 1], Katarina Bebjaková[1], Andrea Němcová[1], Michal Dubský[1], Jan Mareš[4]

[1]Diabetes Centre, Institute for Clinical and Experimental Medicine, Prague, Czech Republic, *[2]Department of transplant surgery, Institute for Clinical and Experimental Medicine, Prague, Czech Republic*, *[3]Department of transplant Surgery, Institute for Clinical and Experimental Medicine, Prague, Czech Republic*, *[4]Statistical department, Institute for Clinical and Experimental Medicine, Prague, Czech Republic*

Aim: Patients with Diabetic foot syndrome are threatened by lower limb amputations (LLA). Most of them are preventable by appropriate comprehensive podiatric approach. One of curable surgical procedure able to off-load diabetic foot ulcers (DFUs) is tenotomy. The aim of our study was to assess the frequency of tenotomies performed in patients treated in two outpatient foot centres for toe DFUs and their impact on wound healing.

Method: Totally 259 patients with toe DFUs were enrolled into our bicentral study between 1.1.2024-31.12.2024 (mean age 66.8±11.3years, BMI 30.8±11.0 kg/m2, mean diabetes duration 25±12.4 years, HbA1c 58.2±18.3 mmol/mol, peripheral arterial disease (PAD) had 50.3 % of patients and 26% suffered from osteomyelitis). Patients were followed for 3 months. Basal epidemiologic characteristics, parameters of DFUs and wound healing outcomes were compared between those patients treated by tenotomy and patients treated conservatively by standard of care (SOC).

Results / Discussion: During the study period nearly 13% of study subjects underwent tenotomy (34/259). Patients with tenotomy were significantly younger (63.6±9.6 vs. 67.5±11.4;p=0.04), with shorter diabetes duration (17.4±9.9 vs. 26±13 years;p<0001) and DFUs (3.2±39 vs. 5.1±8.8 months;p=0.04), lower WIfI composite score (2.4±1.2 vs. 3.5±1.8;p<0001) and higher TcPO2 (51.4±15.7 vs. 408±17.6mmHg;p=0.0004) compared to conservatively treated subjects. No LLA were performed in a tenotomy group in contrast to 26.2% of patients treated by SOC. Nearly 53% of patients healed till 3 months after tenotomy in comparison with 44% of patients from SOC group(NS). However, patients after tenotomies healed significantly faster compared to the rest of patients (1.5±0.8 vs. 2±1.1months;p=0.006).

Conclusion: In contrast to SOC therapy tenotomy is able to reduce number of LLA and shorten the healing time in patients treated for toe DFUs.

NW24-09-00184, LX22NPO5104

OP055 Long-term limb salvage in patients with diabetic foot and no-option critical limb ischemia treated with autologous cell therapy

Ermanno Bellizzi[1], Luigi Uccioli[2], Federico Rolando Bonanni[1], Martina Salvi[1], Aikaterini Andreadi[1], Alfonso Bellia[1], Davide Lauro[1], Marco Meloni[1]

[1]University Hospital of "Tor Vergata", Rome, Italy, *[2]CTO A. Alesini, Rome, Italy*

Aim: Patients with diabetic foot ulcers (DFUs) and no-option critical limb ischemia (NO-CLI) have 30% of major amputation rate at 1-year when managed by the best of medical care. In addition, patients with ischaemic DFUs have 25% rate of 1-year limb ischaemia recurrence. The study aimed to evaluate the long-term outcomes of patients with DFUs and NO-CLI managed through peripheral blood mononuclear cells (PB-MNCs) therapy.

Method: This prospective, non-controlled study included diabetic patients with DFUs and NO-CLI after failed mechanical revascularization treated by adjuvant PB-MNCs therapy. PB-MNCs were administered along the wound related artery based on the location of target DFU. In addition, all patients have been managed by the standard of care in the respect of international guidelines. At 2 years of follow-up the following outcomes were evaluated: limb salvage, major amputation, mortality, hospitalization for recurrence of limb ischaemia.

Results / Discussion: Overall, thirty-four patients were enrolled (mean age 73.7 ± 8.9 years). Type 2 diabetes was present in 98.2% of cases, with a mean disease duration of 23.1 ± 9.8 years. An active infection was documented

in 90.2% of patients, while osteomyelitis was present in 56.8%. Gangrene was observed in 94.1% and desert foot in 45.4% of cases at baseline. At 24 months, limb salvage was achieved in 61.7% of patients, major amputation occurred in 8.8%, mortality was 26.4%, and ischemic recurrence was observed in 2.9% of patients.

Conclusion: Patients treated by PB-MNCs therapy showed low episodes of major amputation and hospitalization for recurrence of limb ischaemia in long-term follow-up when compared to literature data, supporting a potential role of this type of regenerative therapy in preserving limbs.

OP040 The hidden impact: Frailty and malnutrition in patients with diabetic foot ulcers

Levent Demir[1]

[1]*Kayseri city hospital, Kayseri, Türkiye*

Aim: Diabetic foot ulcers (DFUs) are a significant complication affecting over 30% of individuals with diabetes, leading to increased morbidity and mortality. This study investigates the relationships between frailty, nutritional status, and quality of life in patients aged 50 and older diagnosed with DFUs.

Method: A total of 100 participants with DFUs were prospectively included in the study, with assessments conducted using the Edmonton Frailty Scale and the Mini Nutritional Assessment Scale. Quality of life was evaluated using the EQ-5D-3L scale. Demographic data, concomitant diseases, medications, HbA1c levels, and participants' height, weight, and circumferences of the upper arm, calf, and waist were recorded. The data analysis was performed using statistical software.

Results / Discussion: The findings revealed that 50% of patients exhibited varying degrees of frailty, and 85% were at risk of malnutrition. Both frailty and malnutrition were associated with a significant decline in quality of life. Notably, patients with normal nutritional status reported higher quality of life scores compared to those at risk of malnutrition or malnourishment.

Conclusion: This study underscores the need for a holistic approach to managing DFUs that integrates frailty and nutritional status assessments. Targeted interventions addressing these factors are essential for improving health outcomes and enhancing the quality of life for individuals living with diabetes. The findings advocate a shift from a narrow focus on wound management to a broader, more comprehensive care strategy.

OP046 Intensive integrated prevention protocol reduces the risk of recurrence in patients with previous diabetic foot ulcer

Marco Meloni[1 2], Federico Rolando Bonanni[1 2], Giuseppe Lorusso[3], Emanuela Adriani[3], Laura Proietti[3], Laura Bergesi[3], Andrea Zimbile[3], Martina Salvi[1 2], Ermanno Bellizzi[1 2], Laura Giurato[3 4], Luigi Uccioli[3 4], Davide Lauro[1 2]

[1]*Department of Systems Medicine, University of Rome Tor Vergata, Rome, Italy*, [2]*Division of Endocrinology and Diabetology, Department of Medical Sciences, University Hospital Fondazione Policlinico Tor Vergata, Rome, Italy*, [3]*University of Rome Tor Vergata, Rome, Italy*, [4]*Division of Endocrinology and Diabetes, Department of Systems Medicine, CTO Andrea Alesini Hospital, Rome, Italy*

Aim: To assess the effectiveness of an intensive prevention protocol on the recurrence of diabetic foot ulcers (DFUs).

Method: The study is a retrospective observational study including patients with healed DFUs who were managed in a multidisciplinary diabetic foot service between 2015 and 2024. Included patients were divided into two groups: standard protocol (SP) group was managed with a standard integrated protocol based on international guidelines (prescription of therapeutic footwear, education, podiatric care, regular follow-up) and intensive protocol (IP) group was managed with an intensive protocol (standard prevention plus reinforced education on patients, caregivers and relatives, and close monitoring on the use of therapeutic footwear). Every patient was regularly visited every 3 months. At the one-year follow-up, DFU recurrence rates in both groups were recorded and compared.

Results / Discussion: Overall, 331 patients were included: 127 in the SP group and 204 in the IP group. The mean age was 72±8.4 years, most patients were male (68.4%) and had type 2 diabetes (93.8%); 86.2% reported peripheral neuropathy, 44.5% peripheral arterial disease, 84.7% foot deformities. No significant differences between the groups were reported at the assessment. The IP group showed higher adherence to therapeutic footwear use (95.8vs84%, p=0.001) and a higher rate of regular podiatric care (95.8vs74%, p=0.0002) than the SP group. After 1 year, the IP group reported a lower rate of DFU recurrence in comparison to the SP group (13.2vs37%, p>0.0001). At the multivariate analysis, close adherence to therapeutic footwear use and regular podiatric care resulted independent predictors of mid-term DFU remission.

Conclusion: An integrated and intensive prevention protocol seems to reduce the risk of DFU recurrence in the mid-term follow-up.

OP031 Out-patient antimicrobial therapy compared to standard care of diabetic foot infections

Arthur Tarricone[1], Nitish Thirugnanasambandam[1], David Lavery[2], Joseph Alderete[1], Lawrence A. Lavery[1]

[1]University of Texas Health San Antonio, San Antonio, United States, *[2]Statistical Analytics, Denver, United States*

Aim: To compare clinical outcomes in diabetic foot infections treated with traditional antimicrobial therapy or in an Out-Patient Antimicrobial Therapy program.

Method: This is a post hoc analysis from a prospective study of patients with diabetic foot infections. 91 patients were treated in our Out-Patient Antimicrobial Therapy (OPAT) program and 141 people were treated with the traditional antimicrobial therapy (TAT). Patients were started on broad spectrum antibiotics until culture directed therapy could be initiated. All subjects had deep infections and required surgical incision and drainage. At the time of surgery, deep tissue/ bone cultures were obtained, and antibiotics were changed after culture and sensitivity reported were complete. The OPAT program developed a patient and family education program, so parenteral antibiotics could be administered at home. OPAT patients were seen weekly in a podiatry and Infectious Disease collaborative clinic. Patients were followed for 12 months.

Results / Discussion: There was no difference in clinical outcomes as demonstrated in Table 1, including the proportion of healed wounds, re-infection, re-admission to hospital, the need for additional surgery or the need or level of amputation.

OUTCOME	OPAT YES (n=91)	Standard Care (n=141)	P Value
Healed	47 (51.6%)	86 (61%)	0.16
Re-ulceration	3 (3.3%)	9 (6.4%)	0.22
Re-admission	27 (29.7%)	52 (36.9%)	0.26
R-einfection	13 (14.3%)	33 (23.4%)	0.09
Surgery after re-admission	18 (19.8%)	27 (19.10%)	0.78
Amputation	5 (5.5%)	12 (8.5%)	0.41
Type of amputation:			
Toe	0	3 (2.1%)	0.46
TMA	3 (3.3%)	5 (3.5%)	0.46
BKA or AKA	2 (2.2%)	4 (2.8%)	0.46

Conclusion: OPAT is an effective program to provide antibiotic therapy after hospital discharge in patients with deep diabetic foot infections.

OP063 Results of treatment with the novel, non-removable and mobility-promoting offloading device fifi-sole: A retrospective cohort analysis

Dirk Hochlenert[1], Mira Mertens[1], Gerald Engels[2]

[1]Ambulantes Zentrum für Diabetologie, Endoskopie und Wundheilung, Köln, Germany, [2]St. Vinzenz-Hospital, Cologne, Germany

Aim: We developed and standardized a non-removable offloading device that can be fabricated at the patient's bedside by medical professionals who have completed an 8-hour training course. The device consists of a rigid fiberglass base with a structured application of up to seven layers of felt and is fixed to the foot. Patients are encouraged to maintain their usual activity levels to preserve quality of life and cardiovascular fitness. This retrospective analysis evaluates treatment characteristics and outcomes and compares them with treatments documented in the DFS Registry.

Method: We searched the electronic patient records at our centre for the term "Fifi" between January 1, 2021, and December 31, 2023. The 1st ulcer in a person was evaluated as index ulcer to find out treatment characteristics. The DFS-Register was searched for all patients with treatments starting in the same period, observation ending in both cases 31.3.2025.

Results / Discussion: A total of 199 patients were treated with the non-removable offloading device. In the DFS-register, treatments of 6402 patients were found.

	FiFi			Register		
	Avg	Median		Avg	Median	
Age	68,8	69		70,5	72	
Male			80,6%			68,4%
Female			19,4%			31,6%
DM Typ 1			4,6%			8,2%
DM Typ 2			93,5%			89,8%
Diabetes Duration	15,2	16,0		17,4	16	
Wight	96,2	93,0		92,2	91	
PVD			37,1%			35,7%
Infection			23,1%			35,0%
Osteomyelitis			10,2%			9,0%
Duration	173,9	117		194,7	112	
Major Amputation			0,9%			0,67%
Minor Amputation			2,8%			5,61%
Deceased			9,26%			6,44%

Conclusion: This retrospective analysis shows broadly comparable severity and outcomes between patients treated with this mobility-focused offloading approach and those in the general DFS Registry. The non-removable devices, integrating established offloading principles and allowing timely preparation, made it unnecessary to restrict walking.

OP032 Comparison of open and percutaneous tenotomy techniques for ulcerated hammertoes: Impact on wound healing and surgical outcomes

Mohamed Zaied[1]

[1]*Faculty of Medicine, Kafrelsheikh University, Kafrelsheikh, Egypt*

Aim: To evaluate two techniques for managing hammertoe ulcers, by comparing ulcer-healing time, postoperative infection, and surgical outcomes between open and closed tenotomy techniques.

Method: This randomized controlled prospective study was conducted at the Vascular Surgery Department, Kafr El-Sheikh University, between February 2024 and August 2025. A total of 118 diabetic patients (63 males, 55 females; age range 38–87 years) with hammertoe deformity and active ulcers, Patients were randomized (1:1) using computer-generated block randomization with sealed opaque envelopes into:

- Group A (n=59): Percutaneous closed flexor tenotomy
- Group B (n=59): Open flexor tenotom

Hypertension was present in 97 patients, and 78 ulcers were infected. Ulcers were most commonly located on the second toe (73 cases).

Patients were randomized into 2 Groups each contain 59 patients:

- Group A Closed Tenotomy: A percutaneous plantar puncture at the toe crease with tendon release using repeated picking and counter-tension.



Figure 1. Closed tenotomy for 2nd toe pedal ulcer

- Group B Open Tenotomy: in infected ulcers the tenotomy wound was intentionally left open for drainage.



Figure 2. Open tenotomy for tip ulcer and using the opening for draining

Outcomes:

- Primary outcome:
- Ulcer healing time (days)

Secondary outcomes:

- Postoperative secondary infection
- Need for further surgical intervention
- Toe amputation

Statistical Analysis: Data were analyzed using SPSS version XX. Continuous variables were expressed as mean ± SD and compared using Student's t-test. Categorical variables were analyzed using Chi-square test or Fisher's exact test. A p-value < 0.05 was considered statistically significant.

Results / Discussion: Mean ulcer healing time was significantly shorter in the closed tenotomy group compared to the open group (23 ± 6.4 days vs. 36 ± 8.1 days; $p < 0.001$). Secondary postoperative infection occurred in:

- 2 patients (3.4%) in the closed group
- 7 patients (11.9%) in the open group

This difference did not reach statistical significance ($p = 0.08$).

Two patients required distal phalanx excision, and no toe amputations occurred. In patients with preoperative infected ulcers, leaving the open tenotomy wound unclosed improved drainage and resulted in superior infection control.

Conclusion: Closed percutaneous tenotomy offers faster ulcer healing and a lower risk of secondary infection, making it the preferred technique in clean diabetic toe ulcers. The open technique retains a crucial role in infected ulcers, as the open wound enhances drainage and accelerates infection resolution. A selective, ulcer-driven approach provides optimal outcomes.

OP056 Bridging the adherence gap: Understanding patient barriers to therapeutic footwear use in diabetes

Rajesh Kesavan[1], Indira Priyadarshini[2], Sheela Sasikumar[2]

[1]Dr.RK Diabetic Foot and Podiatry Institute and Rakesh Jhunjhunwalla Amputation Prevention Center, Meenakshi Academy of Higher Education and Research, Chennai, India, *[2]Dr.RK Diabetic Foot and Podiatry Institute and Rakesh Jhunjhunwalla Amputation Prevention Center, Chennai, India*

Aim: To assess therapeutic footwear prescription patterns, adherence, and patient-reported barriers among individuals with diabetes.

Method: A cross-sectional survey was conducted among 325 diabetic patients at a tertiary foot care centre. Data were collected through face-to-face interviews using a validated structured questionnaire. Descriptive statistics were used to evaluate adherence, reasons for non-adherence, and complaints among footwear users.

Results / Discussion: Of the 325 patients, 60.3% had been prescribed therapeutic footwear. Among those prescribed, 67.9% were adherent, while 32.1% reported non-adherence. Key barriers included discomfort (30.1%), heaviness (22.2%), poor aesthetics (19%), and material issues (17.5%). Even adherent users reported challenges such as lack of washability (30.8%), high cost (30.8%), and cultural restrictions (24.8%). These findings highlight that adherence is shaped not only by patient behaviour but also by design suitability, comfort, and cultural norms.

Conclusion: Adherence is influenced by comfort, affordability, and cultural norms. Improving design suitability and offering structured patient counselling may strengthen preventive foot-care practices.

OP047 Ulcer free survival days: A new outcome of high importance and its translation to daily practice

Mikaella Loizou[1], Olaf Bakker[2]

[1]St.Antonius Ziekenhuis, Utrecht, Netherlands, *[2]Sint Antonius Ziekenhuis Utrecht, Utrecht, Netherlands*

Aim: Ulcer-free survival, also expressed as ulcer-free days (UFD) has been described in literature over recent years. However, it is rarely used as a primary endpoint to evaluate treatment effectiveness and sustained wound healing. In a population such as the diabetic foot ulcer population, the incidence of ulcer recurrence and new-ulcer formation is high. Therefore assessment of healing using a more sustainable and longitudinal outcome measure is warranted. The aim of this study is to prospectively investigate the UFD in the diabetic foot ulcer population of a specialized wound expertise center in the Netherlands.

Method: This prospective study included all the diabetic foot ulcers presented in the clinic during the years 2023 and 2024. Patients were followed for a period of 12 months. After a predefined screening and selection process, eligible patients were included in the final analysis. Ulcer-free survival days were calculated for each patient over the follow up period.

Results / Discussion: Of the approximately 700 patients assessed, 500 patients met the inclusion criteria and were included in the final analysis. Data analysis is currently being finalized. The primary analysis will focus on the median UFD in the overall population. Additionally, the one year UFD rate will be analyzed and compared to existing literature. Potential predictors of ulcer-free survival, including wound location, presence of peripheral arterial disease, cardiovascular, renal disease and other comorbidities will be evaluated for their association to UFD.

Conclusion: The study demonstrates that UFD is an outcome measure that has promising abilities to capture both clinical relevance and long-term patient-centered outcomes in diabetic foot care. The findings support the incorporation of UFD as a key outcome in upcoming future clinical research.

DRESSINGS

OP064 Bioactive chitosan-based powder with zno–ferulic acid nanoparticles as nature-inspired ecm mimetic therapy for wound healing

Dr. Hadi Zomorrodian[1], M. Raouf[1 2 3 4], Lucie Daniels[1]

[1]Aktischicht Wound Care Solutions, Frankfurt am Main, Germany, *[2]Aktischicht-Nano Fanavaran Narin Teb Co., Tehran, Iran*, *[3]Nanotechnology Research Center, Faculty of Pharmacy, Tehran University of Medical Sciences, Tehran, Iran*, *[4]Physical Chemistry I, Department of Chemistry and Biology & Research Center of Micro and Nanochemistry and (Bio) Technology (Cμ), University of Siegen, Siegen, Germany*

Aim: This study aims to develop and evaluate a protein/polysaccharide-based powder wound dressing. The formulation incorporates ferulic-acid (FA)–bioreduced zinc oxide nanoparticles (ZnO NPs) within a chitosan (CS), collagen (Col), and hyaluronic acid (HA) matrix. It is designed to enhance tissue regeneration, regulate reactive oxygen species, and provide antioxidant, anti-inflammatory, and antimicrobial protection for chronic, deep, irregular, and infected wounds.

Method: ZnO NPs were synthesized via FA-mediated bioreduction and incorporated into a CS/Col/HA matrix, followed by freeze-drying to obtain ZnO@FA-CS/Col/HA powder. Invitro tests included antioxidant (DPPH), anti-inflammatory (TNF-α and IL-6 ELISA in LPS-stimulated RAW264.7 cells), biocompatibility (MTT in L929 fibroblasts), hemocompatibility by haemolysis assay, and antibacterial activity (*S. aureus*, *E. coli*). Wound healing efficacy was evaluated in 18 male rats, randomly assigned to three groups (n = 6): untreated control, Altrazeal® control, and ZnO@FA-CS/Col/HA treatment for 28 days, with histological analysis of re-epithelialization, granulation, and collagen deposition. Data were analyzed using two-way ANOVA ($p<0.05$).

Results / Discussion: ZnO@FA-CS/Col/HA exhibited sustained FA release (69% over 48 h) and a swelling ratio ~19× its weight. Antioxidant activity increased from 57% (CS/Col/HA) to 82%, with strong anti-inflammatory effects reducing cytokine levels. FA coating lowered ZnO NPs toxicity, achieving excellent biocompatibility. Antibacterial efficacy reached 43% against E. coli and 47% against S. aureus. In vivo, diabetic rat wounds showed 93% closure by day 15, surpassing Altrazeal® (79%), with histology confirming enhanced angiogenesis, neutrophil regulation, and collagen deposition.

Conclusion: ZnO@FA-CS/Col/HA demonstrated sustained FA release, excellent swelling, and enhanced antioxidant, anti-inflammatory, and antibacterial properties, with high biocompatibility and hemocompatibility. In vivo, it significantly improved wound closure, angiogenesis, neutrophil regulation, and collagen deposition, highlighting its effectiveness for deep and chronic wound healing.

OP065 Assessing antibiofilm efficacy of silver-based wound dressings across three models

Magdalena Zaborowska[1], Julie Perry[2], Tina Hamberg[3]

[1]Mölnlycke Health Care, Gothenburg, Sweden, *[2]Mölnlycke Health Care, Oakville, Canada*, *[3]Mölnlycke Health Care, seavendorinvoice@molnlycke.com, Mölndal, Sweden*

Aim: Microorganisms living in structured communities called biofilms contribute to wound chronicity. Silver-containing dressings are often used when wound biofilm is suspected. A study was undertaken to evaluate the antibiofilm effect of six silver-containing dressings. Biofilm architecture varies with changing environments; thus three complimentary models were used to capture clinically relevant variability.

Method: Six gelling fibre dressings (A–F) were assessed in an agar plate model (APM). Two of these dressings (A[1] and B[2]) were also tested in a drip-flow reactor (DFR) and a collagen gel model (CGM). *Pseudomonas aeruginosa* and *Staphylococcus aureus* served as test organisms. A non-silver dressing (G[3]) was included as negative control in all models.

Results / Discussion: Dressings A and B were tested across all three models and efficacy varied by dressing, organism, model, and time. Dressing A achieved ≥1.4 log reductions in colony forming units (CFU) in all models, with lowest activity against *S. aureus* in APM at 72h and highest (7.4 log reductions) against *S. aureus* in CGM at 72h. Dressing B showed similar variability, with lowest reduction (0.8 log CFU) in APM and highest reduction (7.3 log CFU) against *S. aureus* in CGM. Dressings C-E[4] were tested in APM and reduced both *S. aureus* and *P. aeruginosa* CFU by ≥1.1 log units at 24h. Re-growth of *S. aureus* was noted at 72h with Dressings C and D. Dressing F reduced *S. aureus* CFU by ≥3.7 log units but did not reduce *P. aeruginosa* CFU at any time point.

Conclusion: Antimicrobial performance depended on dressing type, biofilm environment, organism, and exposure time, underscoring the need for multiple models to predict clinically relevant outcomes.

[1]Exufiber Ag+ (Mölnlycke HealthCare)

[2]Aquacel Ag+ Extra (Convatec)

[3] Exufiber (Mölnlycke HealthCare)

[4]Suprasorb Liquacel Ag (Lohmann & Rauscher International), Durafiber Ag (Smith & Nephew), UrgoClean Ag (Urgo Medical), Biatain fiber Ag (Coloplast)

OP066 Comparative wound healing dynamics using intact and particularized fish skin grafts

Anna-Lisa Pignet[1], Ines Fößl[1 2], Manuel Prevedel[1 2], Maximilian Moshammer[1 2], Anna Schwarz[1 2], Ana Villa-Garcia[1 2], Anita Eberl[3], Lars-Peter Kamolz[1 2], Elisabeth Hofmann[1 2], Petra Kotzbeck[1 2]

[1]Coremed, Graz, Austria, *[2]Coremed – Center for regenerative and precision medicine, Joanneum Research Forschungsgesellschaft Mbh, Graz, Austria*, *[3]Health– Institute for Biomedical Research and Technologies, Joanneum Research Forschungsgesellschaft Mbh, Graz, Austria*

Aim: Acellular fish skin grafts (FSG) have demonstrated clinical benefits in wound healing, including accelerated epithelialization and reduced contraction. However, the cellular and molecular mechanisms underlying these effects remain incompletely characterized. This study evaluated the impact of FSG on wound healing in a porcine full-thickness skin defect model, focusing on healing kinetics, tissue formation, and modulation of inflammatory signaling.

Method: Full-thickness excisional wounds were created in male Landrace pigs (mean weight 28.8 ± 2.8 kg; n = 7) and treated with either intact sheet FSG, particularized FSG, or left untreated. Wounds were assessed over 21 days by clinical documentation, thermography, histology, and molecular analysis of cytokines and contraction-associated markers (αSMA/ACTA2). The effect of secondary dressings (foam vs. fatty gauze) was also examined.

Results / Discussion: FSG-treated wounds exhibited accelerated tissue formation, with a 1.7–2.0-fold increase in granulation tissue thickness on days 5–9 compared to controls. Wound contraction was reduced, particularly in wounds treated with intact FSG. Cytokine profiling showed early upregulation of IL-1β, IL-6, and IL-8 at day 5, followed by decreased IL-6 and increased IL-10 at day 9, indicating a transition from pro-inflammatory to regenerative signaling. αSMA/ACTA2 expression kinetics supported reduced contractile activity in intact FSG-treated wounds. Secondary dressing type partially influenced cytokine responses, with fatty gauze promoting a more prolonged pro-inflammatory profile than foam.

Conclusion: In this translational pig model, intact and particularized FSG accelerated wound healing, enhanced tissue formation, modulated inflammatory dynamics, and reduced contraction. These data support the regenerative value of FSG in complex wound management and provide further insight into their mechanistic effects.

OP067 Evaluating functional dynamic hydrogels for improved healing in a porcine acute wound model

Johanna Einsiedler[1 2], Maximilian Moshammer[2], Anna Schwarz[1 2], Manuel Prevedel[1 2], Lena Tatschl[1], Manfred Bodenlenz[3], Reingard Raml[3], Alejandro Fernández Hernández[4], Helena Herrada-Manchon[4], Beatriz Palla[5], Oliver Etzold[5], Juliana Nunes[6], Thomas Birngruber[3], Damien Dupin[5], Petra Kotzbeck[1]

[1]Joanneum Research Forschungsgesellschaft mbH, Graz, Austria, *[2]Research Unit for Tissue Regeneration, Repair and Reconstruction, Division of Plastic, Aesthetic and Reconstructive Surgery, Department of Surgery, Medical University of Graz, Graz, Austria*, *[3]Joanneum Research Forschungsgesellschaft mbH, Health, Graz, Austria*, *[4]Fundación Idonial, Parque Científico y Tecnológico de Gijón, Gijón, Spain*, *[5]Cidetec, Basque Research and Technology Alliance (BRTA), Parque Científico y Tecnológico de Gipuzkoa, Donostia-San Sebastián, Spain*, *[6]Biogipuzkoa Health Research Institute, Biosurfaces and Biomaterials Group, Donostia-San Sebastián, Spain*

Aim: Chronic wounds remain a major clinical burden, largely driven by persistent inflammation and infection that delay tissue repair. Hydrogels are widely used in wound care due to their moisture retention, biocompatibility, and ability to support regeneration. Functional dynamic hydrogels equipped with anti-inflammatory, anti-bacterial, or pro-regenerative properties offer potential by actively modulating the wound environment.

Method: We evaluated novel 3D-printed dynamic hydrogels based on hyaluronic acid with bioactive functions. An acute wound model was established by creating twelve 0.8-mm deep, 3×3 cm wounds on the backs of six female landrace pigs (29.9 ± 4.2 kg). Wounds were treated with either hydrogel alone (HG), anti-bacterial (AB-HG), anti-inflammatory (AF-HG), or pro-regenerative hydrogel (PR-HG), with applications at baseline and day 5. Untreated wounds covered only with secondary dressing served as controls (CR). Wound size was monitored 21 days, with dressing changes, wound scoring, imaging, and biopsies on days 5, 9, and 14. Final evaluation and biopsy collection were performed on day 21. Samples were processed for histology and gene expression analysis.

Results / Discussion: All hydrogels supported wound closure and re-epithelialization within 21 days. PR-HG showed the most consistent early improvements, with smaller remaining wound areas at day 5 compared to CR and AF-HG. AB-HG achieved closure rates similar to controls. Histological scoring reflected these trends, showing earlier granulation and re-epithelialization in the PR-HG groups. AF-HG, however, appeared to delay early healing. Gene expression of inflammatory, angiogenic, and remodeling markers did not differ significantly between groups.

Conclusion: These results indicate that functional dynamic hydrogels, especially PR-HG, may provide a promising strategy for improving outcomes in hard-to-heal wounds. Future studies in chronic wound models will clarify their therapeutic potential.

OP068 A multicentre randomised controlled trial comparing dialkylcarbamoylchloride (DACC) coated postoperative dressings versus standard care in the prevention of surgical site infection in vascular surgery

Arthur Lim[1 2], Ross Lathan[1 2], Joshua Totty[3 4], Louise Hitchman[1 2], Joseph Cutteridge[1], Shreya Bhatt[1 2], Kate Adams[5], Phillipa Burns[5], Huang Chao[4], Leanne Cox[2], Daniel Carradice[1 2], Ian Chetter[1 2], George Smith[1 2]

[1]Academic Vascular Surgical Unit, Hull York Medical School, Hull, United Kingdom, *[2]Department of Vascular Surgery, Hull University Teaching Hospitals NHS Trust, Hull, United Kingdom*, *[3]Department of Plastic and Reconstructive Surgery, Hull University Teaching Hospitals NHS Trust, Hull, United Kingdom*, *[4]Centre for Clinical Sciences, Hull York Medical School, Hull, United Kingdom*, *[5]Department of Infectious Disease, Hull University Teaching Hospitals, Hull, United Kingdom*

Aim: To investigate the clinical effectiveness of dialkylcarbamoylchloride (DACC) coated post-operative dressings versus standard care in the prevention of surgical site infection in vascular surgery.

Method: This is a pragmatic, parallel-group, multicentre, randomised controlled trial. Participants aged ≥ 18 years undergoing clean or clean-contaminated lower limb vascular surgery with primary wound closure were randomly

assigned (1:1) to either DACC dressings or standard surgical dressings. Follow-up occurred at 1 month and 3 months post-surgery. The primary outcome was the incidence of surgical site infection (SSI); defined by the Centres for Disease Control and Prevention (CDC) criteria or a total ASEPSIS score of ≥ 21 within 30 days of surgery. Secondary outcomes include satisfactory wound healing (ASEPSIS ≤ 10), quality of life (SF-36 and EQ-5D-3L) at baseline, 1 month and 3 months, Bluebelle wound healing scores and time to return to normal activity.

Results / Discussion: Between June 2021 and June 2025, 722 participants were recruited across 13 vascular centers in the United Kingdom. Of the 722 randomised participants, 707 were randomised, and the primary outcome data was available for 688/722 (95.3%) participants. The rate of SSI in the DACC dressing group was similar compared to the standard dressing group (81/342 (23.7%) vs 81/346 (23.4%); risk ratio (RR): 1.01, 95% Confidence Interval (CI) 0.77-1.32; *p*=0.933).

Conclusion: The DRESSING Trial provides level 1 evidence showing no difference between DACC-coated dressings and standard dressings in the prevention of SSI in lower limb vascular surgery.

EDUCATION

OP069 The role of ambulatory nursing care in improving continuity of chronic wound management

Anna Hepa-Banasik[1], Magdalena Szatan[1]

[1]*Burn Treatment Center, Dr. Stanisław Sakiel, Siemianowice Śląskie, Poland, Siemianowice Śląskie, Poland*

Aim: Chronic wounds affect patients' physical, emotional, social, and economic well-being. Nurses play a pivotal role in patient education, equipping individuals with knowledge and skills to manage wounds at home. This study aimed to assess the impact of structured education within a comprehensive wound care program on patients' knowledge and self-management.

Method: A diagnostic survey was conducted using a custom questionnaire among patients treated for chronic wounds at the General Surgery Outpatient Clinic of the Dr. Stanisław Sakiel Burn Treatment Center in Siemianowice Śląskie, Poland. Data were collected between June 2023 and July 2024. At program entry, participants completed a 16-question survey evaluating baseline wound care knowledge. Patients in the Comprehensive Chronic Wound Treatment Program – Phase 2 (KLRP-2) repeated the survey about three months later to assess educational effects.

Results / Discussion: Analysis showed significant improvements in awareness and knowledge. Correct identification of protein sources increased from 39 to 72 responses, awareness of L-arginine's role in healing rose from 38 to 71, and knowledge of the ankle-brachial index (ABI) improved from 34 to 89. Understanding of compression therapy grew from 57.9% to 91.5%. Awareness of nicotine's harmful effects rose from 83 to 99. These findings confirm the effectiveness of targeted education in empowering patients and strengthening self-care practices.

Conclusion: Nurse-led educational interventions within structured programs substantially improved patients' understanding of wound care, including nutrition, compression, offloading, and risk factor control. Strengthening patient education supports complication prevention and better outcomes in chronic wound management. The results encourage wider use of similar educational strategies in comprehensive wound care programs internationally.

OP073 Effect of a mobile artificial intelligence–based clinical decision support system on nurses' clinical judgment in pressure injury care

Ye-Na Lee[1], Eun Jin Han[2]

[1]Department of Nursing, The University of Suwon, Hwaseong-si, Gyeonggi-do, Korea, Rep. of South, [2]Wound, Ostomy and Continence Nursing Unit, Severance HospitaL, Yonsei University Health System, Seoul, Korea, Rep. of South

Aim: This study developed and evaluated a mobile artificial intelligence–based clinical decision support system (AI-CDSS) to enhance nurses' clinical judgment and knowledge in pressure injury care. Pressure injuries reduce patients' quality of life, increase healthcare costs, and require accurate nursing assessment and evidence-based interventions, yet nurses often have difficulty making timely and consistent decisions in complex clinical environments.

Method: A mobile AI-CDSS was designed using a network-based instructional framework grounded in Tanner's Clinical Judgment Model. The system integrates clinical data entry, image-based pressure injury staging, evidence-based management guidelines, and reflective reports to guide nurses through the four judgment phases at the point of care. In a randomized controlled trial, 80 nurses from a tertiary hospital were allocated to an intervention group using the AI-CDSS or to a control group following existing educational materials and institutional guidelines. Outcomes were clinical judgment scores based on Lasater's Clinical Judgment Rubric, pressure injury nursing knowledge, user satisfaction, and system performance.

Results / Discussion: Compared with the control group, the AI-CDSS group showed significantly higher overall clinical judgment scores and subdomain scores, as well as greater improvement in pressure injury nursing knowledge. User satisfaction with usability, usefulness, and reliability was high, and the system demonstrated stable technical performance.

Conclusion: The mobile AI-CDSS improved nurses' clinical judgment and knowledge in pressure injury care and appears feasible as an innovative educational and decision-support tool for routine practice.

OP074 Burnout and job satisfaction among wound care staff: Implications for quality of care

Abdulaziz Binkanan[1]

[1]King Abdullah bin Abdulaziz University Hospital (KAAUH), Princess Noura University (PNU), Riyadh, Saudi Arabia

Aim: The study aimed to assess the prevalence of burnout and the level of job satisfaction among wound care professionals.

Method: A cross-sectional online survey was conducted among wound care staff. Participants provided demographic information and responded to standardised questionnaires measuring burnout and job satisfaction.

Results / Discussion: A total of 118 wound care professionals participated in the study. The results revealed alarming levels of burnout among wound care professionals, with many participants experiencing high disengagement (84.7%), exhaustion (83.1%), and burnout (79.7%). Job satisfaction scores were moderately low overall, highlighting the importance of addressing both burnout and job satisfaction in this workforce. Demographic factors such as age, gender, marital status, and working hours per duty showed no significant associations with burnout. However, differences were observed among professional roles, with nurses exhibiting lower burnout levels compared to other professions.

Conclusion: The study findings highlight the urgent need for targeted interventions to mitigate burnout and enhance job satisfaction among wound care professionals. These interventions are not only crucial for the well-being of wound care professionals but also directly impact the quality of care.

e-HEALTH

OP071 Empowerment-driven adoption of telemedicine across sectors in diabetic foot ulcer management

Susanne Søndergaard[1], Annette Høgh[2]

[1]Lovisenberg Diaconal University College, Oslo, Norway, *[2]Viborg Hospital, Dep. of Vascular surgery, Viborg, Denmark*

Aim: To explore how patient engagement and interaction styles shape use of the telemedicine (TM) platform Pleje.net® across diabetic foot ulcer (DFU) care settings.

Method: Patients' experiences with TM in DFU care are often evaluated through organisational or technical dimensions; however, these alone fail to capture person-centred factors influencing uptake. Patient expectations and interactional dynamics shape whether TM becomes integrated into routine care and achieves intended outcomes. This study used a realist evaluation drawing on 71 hours of ethnographic observation across home care, municipal nursing clinics and a hospital-based multidisciplinary wound care clinic. Using a Context–Mechanism–Outcome framework, the analysis examined how contextual factors and mechanisms influenced the use of key TM functions (image transfer, messaging, wound alerts) for DFU care.

Results / Discussion: The analysis revealed how empowerment operates as three key mechanism in patient engagement and TM use. 1) *Empowerment-driven alignment:* Patients who used TM images to ask targeted questions and articulate preferences gained self-efficacy, prompting faster cross-sectoral coordination and more consistent TM use. 2) *Empowerment through structured routines:* Patients who adopted TM-guided practices (planned image capture and symptom reporting) felt more involved, improving predictability and clinician trust in remote monitoring. 3) *Empowerment erosion:* When patients lacked digital confidence or felt uncertain about remote follow-up, empowerment was eroded, reducing control and prompting clinicians to increase contact, which decreased TM reliance and increased relational workload.

Conclusion: Empowerment emerged as a key mechanism shaping TM use. When patients felt confident and informed, they engaged more actively, enabling better coordination and continuity of care. These findings suggest that strategies to strengthen empowerment should be integrated into TM implementation, despite not being an initial study focus.

OP072 Integrating telemedicine and the Taipei Hospital App into a nurse-led wound care model in a regional hospital in Taiwan

Meng Chieh Lin[1 2], Hui-Erh Kuo[3], Shan-Hung Huang[3], Ming-Wei Liu[2 4], Ya-Han Tung[5]

[1]Department of Surgery, Taipei Hospital, Ministry of Health and Welfare, Department of Industrial Design, Tatung University, Taiwan, New Taipei City, Taiwan, *[2]Department of Industrial Design, Tatung University, Taipei, Taiwan*, *[3]Department of Surgery, Taipei Hospital, Ministry of Health and Welfare, New Taipei City, Taiwan*, *[4]Department of Plastic and Reconstructive Surgery, Taipei Hospital, Ministry of Health and Welfare, New Taipei City, Taiwan*, *[5]Department of Nursing, Taipei Hospital, Ministry of Health and Welfare, New Taipei City, Taiwan*

Aim: In Taiwan, around 510,000 people seek medical attention for complex wounds each year, creating substantial pressure on patients and healthcare systems. To enhance accessibility and continuity of care, a regional hospital established an integrated wound care center and a nurse-led telewound service in 2021. This study describes the implementation and early clinical impact of this telemedicine-based model, with emphasis on workflow design and integration of the Taipei Hospital App.

Method: A structured telewound workflow was established for eligible patients. Caregivers received instruction through a Line-based system adapted from hospital educational materials. Wound images and clinical updates were submitted via the Taipei Hospital App for secure data exchange, synchronous video consultations, and documentation. Nurses conducted remote assessments to evaluate wound stability and identify early deterioration,

providing immediate guidance or arranging in-person visits when required. Since 2025, nine patients have used the telemedicine platform, completing approximately 80 virtual visits.

Results / Discussion: The telewound service enabled 2–3 virtual follow-ups per patient monthly, markedly reducing travel burden, transportation costs, and waiting times. System responsiveness was reported as highly satisfactory, with rapid nurse–patient communication and timely clinical decisions improving continuity of care. Continuous monitoring further supported early identification of wound changes and prevention of complications. The nurse-led, app-supported workflow demonstrated strong efficiency and optimized resource utilization in a regional hospital setting.

Conclusion: This telewound care model provides a feasible, patient-centered, and sustainable approach to chronic wound management. By integrating nursing expertise with digital health technologies, it expands care access, reduces patient burden, and offers a scalable framework for regional hospitals advancing telemedicine and ESG-oriented healthcare.

HEALTH ECONOMICS AND OUTCOMES

OP075 Polypharmacy: A potential predictor for impaired wound healing and decreased health-related quality of life?

Stella Amesz[1]

[1]*Deventer Ziekenhuis, Deventer, Netherlands*

Aim: To demonstrate that patients with chronic wounds and polypharmacy have increased wound healing time compared to patients with chronic wounds without polypharmacy. A secondary aim is to study whether polypharmacy is associated with decreased health-related quality of life in patients and to create awareness for these patients.

Method: Patients with chronic wounds were included from within a home care organization. The EQ-5D-3L, a visual analogue scale, and the Wound-QoL were administered. The patients were divided into two groups based on age: group one younger than 60, and group two 60 years or older. In both groups, polypharmacy and wound healing time were assessed.

Results / Discussion: The sample included 378 patients. 72.8% of the participants had polypharmacy. The Mann-Whitney U test showed a statistically significantly increase in the time of wound healing in the polypharmacy group The polypharmacy group exhibited decreased health-related quality of life. When the sample was divided by age (59 years and younger; 60 years or older), a Mann-Whitney U test revealed a statistically significant difference in the time of wound healing between polypharmacy and non-polypharmacy only in the younger group.

Conclusion: Polypharmacy is an indicator of impaired wound healing, especially for patients younger than 60 years. This conclusion should help make wound professionals aware that they should expect increased wound healing time. Patients with chronic wounds and polypharmacy tend to have lower health-related quality of life.

OP076 Conversational agentic AI framework for natural language driven wound care analytics: Pilot evaluation of accuracy, speed and usability

Necip Gurler[1], Hollie Robinson[2], Samet Bulbul[1], Stephen Doades[1], Lucy Champ[1], Ozgur Guler[1]

[1]*eKare Inc, Fairfax, VA, United States*, [2]*South Warwickshire University NHS Trust, South Warwickshire, United Kingdom*

Aim: To evaluate the accuracy, efficiency and usability of a conversational agentic AI framework that allows clinicians to explore wound care data and generate reports using natural language queries compared with manual report generation, and to consider its potential contribution to efficiency and outcomes focused decision making.

Method: An in house agentic AI framework was developed using a foundational large language model and integrated into a digital wound care platform. The system interprets natural language queries, generates structured query language, executes queries against the clinical database, and returns tables with visualizations. Users can refine outputs with follow up questions and create personalized reports. The system was deployed and tested in a HIPAA compliant environment. In a single session, two tissue viability nurses and two domain experts generated six predefined reports using both manual methods and the developed framework, including reports such as Antimicrobial Usage Versus Infection Analysis and Healing Rates. Primary outcomes were the accuracy of generated tables and visualizations, and time required to generate reports with each method. Secondary outcomes were visualization appropriateness and usability measured with the system usability scale (SUS).

Results / Discussion: Accuracy of tables and visualizations generated by the framework exceeded 95%. Median report generation time decreased from 30 minutes with manual methods to 5 minutes with the framework. All visualizations were judged as appropriate, and the SUS score was 92/100.

Conclusion: In this pilot evaluation, a conversational agentic AI framework accurately generated wound care reports from natural language queries, markedly reduced report generation time compared with manual workflows by showing potential to improve efficiency, reduce reporting burden and support data driven outcome monitoring in wound care services.

OP077 Prospective clinical study on AI-based wound diagnosis of chronic leg ulcers compared to healthcare professionals and physicians

Carolin Victoria Jezewski[1], Dr. Maurice Moelleken[1], Prof. Dr. Joachim Dissemond[1], Jens Kleesiek[2], Alexander Brehmer[2]

[1]University Hospital Essen, Department of Dermatology, Venerology and Allergology, Essen, Germany, *[2]University Hospital Essen, Institute for AI in Medicine, Essen, Germany*

Aim: The aim of this prospective clinical study was to develop and validate an artificial intelligence (AI)-based classification model for distinguishing between differential diagnoses of chronic leg ulcers using wound images, followed by a performance comparison with nurses and physicians.

Method: The AI-model was developed and validated using an image dataset comprising a total of 798 wound photos to differentiate between venous leg ulcers, postoperative wounds, pyoderma gangrenosum, and necrobiosis lipoidica. Subsequently, its diagnostic accuracy was evaluated using 20 wound images and compared with the performance of nurses and physicians. Additionally, professional experience and attitudes toward AI applications were also assessed.

Results / Discussion: With an accuracy of 98.75% (F1 score 98.70%), the AI-model correctly identified 95.00% (n=19) of test images. In comparison, a total of 144 people participated in this study, including 75.00% nurses (n=108), which assigned only 26.00% (n=5,2) of the wound images (n=20) correctly, in contrast to the physicians, who diagnosed 34.00% of the wounds correctly, thus showing significantly higher results than nurses (U=1466.50; Z=-2.22; p=0.027). The average hit rate among test images was 27.10%. In comparison, these results were significantly lower than those achieved by AI. There was also a significant correlation between specific experience in wound care and diagnostic accuracy (ρ=0.24; P=0.004). Overall, 76.00% (n=109) of participants rated the use of AI as somewhat useful.

Conclusion: Systems using AI-based models showing great potential improving accuracy of wound diagnostic, especially in rare disease entities. The results stress the potential benefits of such models as a supportive tool for clinical assessment by specialists. The predominantly positive attitude toward AI highlights the prospect of future implementation in routine clinical practice.

OP078 The cost of diabetes foot disease

Nicoletta Frescos[1], Michelle Kaminski[2]

[1]Northern Health, La Trobe University, Melbourne, Australia, *[2]Monash Health, La Trobe University, Melbourne, Australia*

Aim: The economic impact of diabetes-related foot disease (DFD) is substantial in Australia, yet remains insufficiently quantified. This study sought to clarify the direct healthcare costs and resource utilisation associated with DFD by integrating contemporary evidence with insights from clinicians experienced in its management.

Method: An economic evaluation was conducted using a three-stage process. A systematic review first consolidated existing Australian cost data. Semi-structured interviews with healthcare professionals were then used to estimate resource use and address gaps identified in the literature. Finally, a Markov model was developed to calculate the direct costs of DFD at both the individual and health system levels, incorporating expenses related to hospitalisations, outpatient and community care, diagnostics, medications, wound care, offloading, and amputation management.

Results / Discussion: The mean annual cost of DFD management was estimated at AUD $20,601 per person. Outpatient and community care ($8,981), wound debridement ($5,155) and hospital admissions ($4,653) were the major contributors to overall expenditure. At a population level, DFD accounted for approximately AUD $839 million in healthcare spending in 2022, with projected costs rising to AUD $1.12 billion by 2026.

Conclusion: This analysis offers robust contemporary estimates of the financial burden of DFD in Australia. The findings highlight key cost drivers and provide valuable evidence to inform service planning, resource allocation, and strategies aimed at improving outcomes for people living with DFD.

HOME CARE

EP221 Registry-based clinical research in the outpatient setting using the BeoNet-Halle database

Lisa Remmert[1], Felix Bauch[2], Konstantin Moser[2], Thomas Frese[2], Christine Böhm[1], Martin Abel[1]

[1]Lohmann & Rauscher GmbH & Co. KG, Neuwied, Germany, *[2]Medical Faculty of the Martin-Luther-University Halle-Wittenberg, Halle, Germany*

Aim: The BeoNet-Halle registry is a systematic collection of anonymized and pseudonymized outpatient data automatically extracted from the practice management system of primary care practices in Germany. The database is operated by the Institute for Medical Epidemiology, Biometry, and Informatics and the Institute for General Medicine at the Faculty of Medicine of Martin Luther University Halle-Wittenberg. The aim of the pilot project was developing analysis strategies for detailed mapping of clinical reality using anonymized data sets. Wound care for leg ulcers due to venous insufficiency was chosen as example.

Method: Relevant data sets within a period of five years (2019 - 2024) were extracted from the database according to ICD-10 codes. Datasets were analyzed for duration of treatment, disease relevant prescriptions and associated cost.

Results / Discussion: 427 anonymised data sets with ICD-10 diagnosis covering venous leg ulcer (I83.0, I83.2, I87.21, L97) were identified. ICD-10 code L97 was coded most ("Ulcer of the lower limb not elsewhere classified"). The dataset was restricted to 150 consecutive cases for further analysis. 62 patients had at least one venous leg ulcer relevant prescription within 90 days following diagnosis. For 25 cases a follow-up diagnosis was made within 180 days, in 37 cases not. Treatment duration was followed by diagnosis coding in consecutive quarters. Product names and German pharmaceutical and medicinal product databases were used to analyse the prescriptions and associated costs. Patients with chronic conditions incurred significantly higher ulcer-related treatment costs on average than those without, in a timeframe of 90 days following first diagnosis (average cost €425.34 vs. €171.22; p = 0.0812 covering dressings, compression bandages, anti-septica).

Conclusion: The BeoNet-Halle registry allows for in-depth analysis of real world clinical data sets in an ambulatory care settings. Linking to the reimbursement database would be useful.

OP098 Evaluating post-discharge recovery of patients with hospital-acquired pressure ulcers (HAPUs): A prospective cohort study

Michelle Venâncio Hong[1], Bruna Velozo[1], Isabela Novello[1], Aglécia Budri[1 2], Meire Castro[1], Helio Miot[1], Luciana Abbade[1]

[1]São Paulo State University (UNESP), Medical School, Botucatu, Brazil, *[2]School of Nursing & Midwifery. Royal College of Surgeons in Ireland Skin Wounds and Trauma Research Centre, Dublin, Ireland, Dublin, Ireland*

Aim: This study aimed to evaluate the recovery and care provided to adult patients with hospital-acquired pressure ulcers (HAPUs) following hospital discharge.

Method: This prospective cohort study included adults who developed PUs during hospitalization in a tertiary hospital complex. From January 2022 to January 2023, post-discharge information was obtained through electronic records, primary care services, and phone contact. A checklist captured adherence to instructions, dressing changes, healthcare received, and clinical and healing status. Follow-ups occurred on days 7 (D7), 15 (D15), 30 (D30), and 60 (D60) post-discharge.

Results/Discussion: A total of 113 patients were included; 55.8% were male, and the mean age was 64.6 years (SD = 15.1). The median hospital stay was 40 days (IQR: 22–57). External trauma (22.1%) and neurological disorders (21.2%) were the main admission causes. Overall, 246 PUs were identified, most commonly in the sacral region (37.0%). Stage 2 ulcers were the most common ones (47.6%). By D60, 32.7% of patients were re-hospitalized and 22.1% had died. Only 42.5% showed wound healing or marked improvement at D60. Kaplan–Meier analysis revealed that stroke was statistically significantly associated with delayed or impaired healing (p = 0.021). Many patients experience persistent or deteriorating PUs, indicating that post-discharge care is suboptimal. High mortality and re-hospitalization rates highlight the need for structured follow-up1. Older adults, those with prolonged hospital stays, and patients who had a stroke showed reduced healing potential, reinforcing the need for targeted screening to identify those at higher risk and enable timely management and prevent complications2.

Conclusion: Strengthening post-discharge monitoring and implementing targeted care strategies are essential to improve outcomes and support wound healing in patients with HAPUs.

OP100 A multicenter study on early - warning factors for poor wound healing after total ankle arthroplasty

Yi Wang[1]

[1]Beijing Jishuitan Hospital, Beijing, China

Aim: To conduct a multicenter study on early - warning factors for poor wound healing after total ankle arthroplasty, so as to provide a theoretical basis for preventing the occurrence of poor wound healing after total ankle arthroplasty.

Method: A total of 553 patients with end-stage ankle osteoarthritis from January 2020 to October 2024 were selected. The clinical data of the patients were retrospectively collected. According to the unhealed incision without suture removal at 2 weeks after the operation, and the presence of incision skin edge necrosis, incision dehiscence, incision exudate, fat liquefaction, delayed incision healing, superficial infection, etc, they were divided into the good wound - healing group (n=489) and the poor wound - healing group (n=64). The situation of poor wound healing after total ankle arthroplasty was analyzed, and univariate and multivariate Logistic regression analyses were used to analyze the risk factors for poor wound healing after total ankle arthroplasty.

Results / Discussion: Among the 553 patients with end - stage ankle osteoarthritis, 64 had poor wound healing after total ankle arthroplasty, with an incidence rate of 11.57%. Multivariate *Logistic* analysis results showed that diabetes mellitus, smoking, pressure injuries caused by plaster, increased body mass index, prolonged operation time and antibacterial drugs were not applied 30 minutes before the operation were risk factors for poor wound healing after total ankle arthroplasty (P<0.05).

Conclusion: Diabetes mellitus, smoking, pressure injuries caused by plaster, increased body mass index, prolonged operation time and antibacterial drugs were not applied 30 minutes before the operation were factors leading to poor wound healing after total ankle arthroplasty, and clinical prevention and treatment measures could be taken accordingly.

OP103 Informal caregivers experience of empathetic wound care

Benjamin Bullen[1], Peta Tehan[1], Alison Vallejo[2], Michelle Gibb[3], Victoria Team[1], Sebastian Probst[4]

[1]Monash University, Melbourne, Australia, *[2]Total Wound Solutions, Birtinya, Australia*, *[3]Wound Specialist Services, Tasmania, Australia*, *[4]HES-SO University of Applied Sciences and Arts, University Hospital Geneva, University of Geneva, Geneva, Switzerland*

Aim: To explore how informal caregivers perceive, enact, and sustain empathy while supporting individuals living with chronic wounds.

Method: A qualitative descriptive design was used. Informal carers were recruited through private wound specialist nurses and participated in semi-structured interviews focused on their experiences and understandings of empathy in the wound care context. Open-ended questions encouraged carers to reflect on how they provide empathetic support and the challenges they encounter. Interviews were transcribed verbatim and analysed thematically. Coding was conducted independently by researchers before collaboratively reaching consensus on themes and subthemes to ensure rigour and analytic depth.

Results / Discussion: Eight informal carers, four females and four males, participated in this study. Thematic analysis produced four themes: (1) Empathy on a busy street; (2) Unseen, 'unofficial,' 'underestimated' and 'undervalued'; (3) A stitch in time saves nine; and (4) Navigating complexity. Carers offered valuable insight into empathetic wound care. Despite empathetic care being associated with increased patient satisfaction, particularly patients feeling valued and understood, carers in this study reported feeling undervalued and underestimated. They were infrequently included within key discussions concerning the patient, with evidence of active exclusion in hospital and community settings. Barriers to empathetic care included time constraints and workload pressures and carers requested specific, hands-on training and simple guidance.

Conclusion: This study provides novel insight into informal carers' experience of empathetic care. These results can inform the development of targeted support frameworks that enhance caregiver well-being, improve care quality and ultimately optimize healing trajectories in chronic wound care.

OP105 Implementation of a coordinated primary-care-based MDT-model

Christina Svarrer[1], Helle Elisabeth Nørgaard[1], Jane Stærkær[2], Christel Louise Rydahl Rasmussen[3], Merete Engell[4], Mathilde Monefeldt Samsson[4], Ann-Charlott Hansen[4], Jeff Kirk Svane[4], Jonas Askø Andersen[4]

[1]Wound clinic in primary care sector, Frederikssund, Denmark, *[2]Wound clinic in primary care sector, Helsingør, Denmark*, *[3]Wound clinic in primary care sector, Jægerspris, Denmark*, *[4]North Zealand Hospital, Hillerød, Denmark*

Aim: The aim of this study was to evaluate the effect on healing of hard-to-heal ulcers of implementing a multi-disciplinary-team (MDT) across the primary and secondary care sectors in the Danish health care system.

Method: This prospective multi-center cohort study was conducted between the 1st of March and the 30th of August 2025. Participants were included from three nursing clinics in the primary sector belonging to the capture area for North Zealand Hospital. The intervention consisted of implementation of an MDT approach, consisting of a wound care nurse and an orthopedic surgeon from the hospital setting and a wound care nurse from the primary sector. Participants where adults with either a diabetic foot ulcer or ulcer of any etiology that had not healed 3-months from occurrence.

Results / Discussion: A total of 153 individuals were screened, 43 were included, and 32 completed the study. 22 (68.8%) where male and the mean age was 73 (SD(±20)) years. Median ulcer duration before inclusion was 156 (Q1-Q3(94-404)) days. 7 (22%) had diabetic foot ulcer and the remaining 25 (78%) had a hard-to-heal ulcer with varying etiologies. 15 (47%) of participants achieved healing during the follow-up, and a further 6 (19%) in the observation period after their final visit in the study. Of the healed ulcers 13% recurred during follow-up and none during the observation period.

Conclusion: The results of this study show that there is a potential benefit of treating individuals with hard-to-heal ulcers in a cross-sectional MDT setup. It the results are reproduced in a randomized clinical trial, this MDT format may be implemented across Danish clinics and may be transferred to international setups.

INFECTION

OP011 Autofluorescence is not reliable in assessing bacterial burden in wounds when compared to clinical judgment or bacterial culture assays

Jérôme Patry[1 2], Emma Fontaine[1 2], Neal W. Pollock[1 2 3]

[1]Centre de recherche du CISSS de Chaudière-Appalaches, Lévis, Canada, *[2]Laval University, Québec City, Canada*, *[3]Centre hyperbare, Hôtel-Dieu de Lévis, Lévis, Canada*

Aim: To evaluate the clinical utility of autofluorescence imaging in identifying bacterial burden in chronic wounds, and to compare its performance with standard clinical judgment and semi-quantitative wound culture assays.

Method: Adults with chronic wounds were recruited during regular clinical visits, excluding those with neoplastic, radiation-related, or povidone-iodine-treated wounds, and those undergoing active cancer treatment. Following consent, wounds were cleaned, debrided, and assessed by a team of trained clinicians (physician and nurse) using a 3-point clinical scale for bacterial load (C0-none; C1-localized infection; C2-deep tissue infection). The *MolecuLight i:X* (Toronto, Canada) device was then used to capture autofluorescence images under dark conditions (negative or positive). Swab cultures were then collected from all wounds for laboratory assays. Cultures were graded semi-quantitatively (B0-no bacteria; B1-trace; B2-low; B3-moderate; B4-high). Chi^2 tests assessed the agreement of autofluorescence determination against clinical judgment and bacterial load assays (significance accepted at $p<0.05$).

Results / Discussion: Wounds on 100 individuals (63 men, 37 women; 69±15 [26-96] [mean±SD and range] years of age) were assessed. Clinical evaluation yielded C0=70; C1=14; C2=16. Positive autofluorescence evaluations were found in 26%, 50%, and 31% of these groupings, respectively ($Chi^2 = 3.29$, df 2; ns). Moderate or high bacterial loads were found in 33%, 29%, and 56%, respectively ($Chi^2 = 3.48$, df 2; ns). Among 70 fluorescence-negative wounds, 31% had moderate or high bacterial loads (B0=16; B1=22; B2=10; B3=7; B4=15). Culture results did not consistently align with clinical or autofluorescence findings.

Conclusion: Autofluorescence imaging is a commercially available, non-invasive, adjunct device marketed for identifying bacterial burden in chronic wounds. However, our trials found its diagnostic value to be inconsistent when compared to clinical assessment and laboratory bacterial cultures.

OP014 Endogenous bacteriophages in chronic wounds and their activity against wound isolates of the eskape pathogen *Pseudomonas aeruginosa*

Nicolas Krüger[1], Mandy Dittmer[1], Sophie Charlotte Liegenfeld[1], Univ-Prof. Dr. Ewa Klara Stürmer[1]

[1]Universitätsklinikum Hamburg-Eppendorf, Hamburg, Germany

Aim: Bacteriophages specifically infect and lyse bacteria. Their therapeutic efficacy against human pathogens has already been demonstrated in case studies and *in-vitro* experiments. To date, phages are predominantly isolated from environmental samples. However, the chronic wound milieu represents a distinct microbial ecosystem in which phages may naturally occur. The aim of this study was to investigate the presence and activity of wound-associated phages against *Pseudomonas aeruginosa* isolates.

Method: Biofilm samples were collected from chronically infected wounds of 20 patients. Screening for phages with lytic activity against two laboratory-adapted *P. aeruginosa* strains was performed using a double-layer-assay. Morphological characterization was carried out using transmission electron microscopy. Wound bacteria were cultured and taxonomically identified by 16S rRNA gene sequencing. The *P. aeruginosa* isolates were tested for their susceptibility to the phages using planktonic-killing-assays.

Results / Discussion: A total of 16 phages were isolated from the wound biofilm. Transmission electron microscopy revealed four morphologically distinct phage families (Podoviridae, Siphoviridae, Myoviridae, and flagellotrophic-like phages). In addition, 42 bacterial isolates were obtained from the wounds, including 11 *P. aeruginosa* isolates. Most phages exhibited pronounced lytic activity against clinical wound isolates in the planktonic model.

Conclusion: Our results demonstrate that bacteriophages are a natural component of the microbiome of chronic wounds and exhibit relevant antibacterial activity against wound-associated *P. aeruginosa* isolates. This supports the concept of a dynamic coexistence of bacteria and phages within the wound environment and highlights the potential of wound-derived phages for personalized phage therapy in resistant wound infections. Chronic wounds represent a natural reservoir of relevant bacteriophages.

OP016 Intraoperative infection control bundle adherence in highly contaminated combat-related wounds: A pilot audit

Yuliia Yurtsun[1]

[1]*Superhumans Center, Lviv, Ukraine*

Aim: To assess the importance of operating room nurses adhering to infection control principles during surgical treatment of highly contaminated combat wounds and to investigate its impact on the development of early infectious complications.

Method: A retrospective pilot audit of combat-related injuries requiring surgical debridement after evacuation over an estimated five months was conducted. Analysis was conducted by an operating room nurse through review of operating room logs and medical records, with specific focus on nursing-controlled intraoperative practices. The evaluated nursing-led bundle included: preparation of extended debridement instrument sets, organization and supervision of clean and contaminated zones, wound irrigation, control the glove changes etc, when clinically indicated and facilitation of microbiological sampling.

Results / Discussion: Patient with complete adherence to the nursing-led infection-control bundle experienced fewer early infectious complications compared with those with incomplete adherence. These findings indicated a clinically relevant association between structured nurse-led intraoperative infection-control practice and improved early postoperative outcomes. The observation included 50 male patients, age 23-57. 30 patients with full-adherence to the nursing bundle, and 20 with incomplete bundle. Early infection (with the patient being readmitted to the operating room after wound closure) occurred in 10% (3 of 30) with full nurse-led bundle adherence vs 80% (16 of 20) with incomplete adherence.

Conclusion: Systematic, nurse-led intraoperative infection control measures were associated with a reduction in the incidence of early infectious complications in patients with highly contaminated combat wounds. The results highlight the autonomous and critical role of the operating room nurse in infection prevention and emphasize the need for standardization of nursing protocols and documentation.

OP126 Pediatric wounds in Latin America: Humanized treatment in adverse context: Use of combinaton of Silver Sulfadiazine, Lidocaine and Vitamin A

Bárbara Diaz[1]

[1]*Ricardo Gutierrez Children's Hospital, Argentinian Burn Association, Argentinian Plastic Surgery Association, Buenos Aires, Argentina*

Aim: This research aims to identify the most efficacious and economically viable treatment strategies within these constrained circumstances focusing on pediatric patients from low socioeconomic backgrounds who have limited access to resources and parental care.

Method: Observational study of 230 children treated in the Burn Unit of the Children's Hospital of Buenos Aires from November 2018 to November 2025. The cohort included were treated with cream or spray composed by Silver Sulfadiazine, Lidocaine and Vitamin A on distinct stages of treatment. These topical combinations were used as an option to other wound advanced care dressings. The patients, who showed injuries of varying severity, came from socioeconomic environments with scarce resources, deficient sanitary controls or long-distances to the hospital. All

data were collected from hospitalization charts, systemic antibiotic use and specific advanced wound care treatments. Parental opinion regarding satisfaction was collected via standardized survey forms. Cost data related to different supplies and accessibility were also registered.

Results / Discussion: A high rate of successful healing was observed, with 96.6% of patients achieving recovery without sepsis. Infection occurred in only 3.4% of patients. A comparative cost analysis revealed that the average daily treatment cost for sulfadiazine was $2, whereas patients receiving active silver dressings incurred an average daily cost of $5. No adverse side effects were reported. Furthermore, both patients and their parents expressed high satisfaction and comfort with the respective treatments.

Conclusion: The combination of silver sulfadiazine plus lidocaine and vitamin A has been identified as a highly cost-beneficial treatment modality for paediatric wounds within resource-scarce environments. This conclusion is supported by clinical data indicating high efficacy and significant cost savings compared to alternative advanced dressings.

OP017 Predicting infection in diabetic foot ulcers from thermal images using deep learning

Darragh Ryan[1], Georgina Gethin[1], Adam Collins[1], Gerard O'Connor[1], Elaine Harris[2]
[1]University of Galway, Galway, Ireland, *[2]Technological University Dublin, Dublin, Ireland*

Aim: To train machine learning and deep learning techniques to predict infection status of chronic wounds, using data collected from over 260 patients with chronic foot wounds (diabetic foot ulcers, pressure ulcers, venous leg ulcers and arterial ulcers).

Method: Thermal and visual images were captured using a smartphone. Several state-of-the-art convolutional neural networks, pretrained on large-scale visual image datasets, were adapted to the task of wound image classification using transfer learning. The performance of this deep learning approach was compared with the classical machine learning alternatives based on logistical regression, random forests, support vector machines and gradient boosting machines -all trained on clinical tabular data.

Results / Discussion: The AUC score (ranging from 0 to 1) summarizes how well a model can distinguish between classes. Our results show that classical ML models achieve good cross validated AUC scores between 0.8 – 0.85, compared to the deep learning CNN models, where AUC scores are between 0.7 – 0.75. As transparency is essential for any potential clinical application, the predictions of both the classical and deep learning models were analysed. For the classical models, feature importance metrics and partial dependence plots were used to provide insight into their decision-making processes, while Grad-CAM heatmaps were employed to visualise the behaviour of the CNNs. We find that features capturing the relative variation in wound temperature are more reliable predictors of infection than measurements of the absolute temperature.

Conclusion: We conclude our findings confirm the promise of IR imaging as a point-of-care tool for monitoring and assessing chronic wounds in a fast, non-invasive and accessible way. Moreover, such a system can be deployed using a low-cost IR camera and smartphone.

LEG ULCER

OP080 Jet cold plasma treatment at air atmospheric preassure to acelerate healing of venous ulcers: A randomized clinical trial

Bernardo Hontanilla[1], Angel Henares[1], Sonia Villajos Garcia[2], Antonio Tejera[2], Lucía Gutiérrez[2], Iñigo Arroyo[1], Naroa Moreno[1], Ignacio Leal[3], Loreto Rubio[3], Javier Buendía[4], José Lasso[5], Ana Megía-Macías[6 6], Daniel Cortazar[6]

[1]Clinica Universidad de Navarra, Pamplona, Spain, *[2]Hospital Universitario La Mancha Centro, Alcazar de San Juan, Spain*, *[3]Clinica Universidad de Navarra, Madrid, Spain*, *[4]Hospital Clínico de San Carlos, Madrid, Spain*, *[5]Hospital General Universitario Gregorio Marañón, Madrid, Spain*, *[6]Comillas Pontificial University, Madrid, Spain*

Aim: To evaluate the efficacy and safety of air-based cold atmospheric plasma jet (CAPJ) therapy for chronic venous leg ulcers (VLUs), compared to standard of care (SOC).

Method: This is a prospective, randomized, controlled, open-label, multicentre clinical trial. 60 adult patients with non-healing VLUs were randomized to receive either CAPJ therapy twice weekly for 10 weeks or SOC. The primary outcome was the percentage reduction in wound area at weeks 4, 9, and 17. Secondary outcomes included granulation tissue formation, microbial burden (qualitative and quantitative), pain (VAS), aesthetic satisfaction, and adverse events. Data were analysed by intention-to-treat.

Results / Discussion: Both groups exhibited significant wound area reductions over time. Although the CAPJ group showed a greater mean reduction (–72.9% vs. –56.7% at week 17), the difference was not statistically significant ($p = 0.30$). Complete healing was observed in 42.9% of CAPJ patients vs. 30.4% with SOC ($p = 0.361$). CAPJ significantly decreased microbial burden immediately after application at weeks 0 and 4 ($p < 0.05$). Pain scores improved comparably in both groups, and aesthetic satisfaction was high without significant intergroup differences. No serious adverse events were attributed to air CAPJ. Transient pain-related sensations were the most frequent treatment-related effects.

Conclusion: Air CAPJ therapy achieved clinically relevant wound area reduction, rapid and intense antimicrobial action, and high patient acceptability without increased adverse effects. These findings support CAPJ as a safe, non-invasive adjunct for chronic VLU management.

OP081 The locus study: A multi-centre service evaluation assessing healing using localised compression for ulceration strapping of peri-malleolar ulceration, for multiple aetiologies across 11 sites in the United Kingdom

Georgina Ritchie[1]

[1]Accelerate CIC, London, United Kingdom

Aim: Pioneering clinicians developed a strapping technique, now recognized as ‘fan-strapping’, to address healing of peri-malleolar ulcers, an area recognized as ‘hard-to-heal’. Following success locally, findings were published internationally and the technique adopted as far afield as South America, LoCUS’s aim was to evaluate fan-strapping’s effectiveness.

Method: Service evaluation methodology to collect data to assess effectiveness was employed across 11 sites over 2 years. User-based-co-design frameworks were utilised, enabling leads from sites to co-design and influence the project. Manufacturers of the bandage required to construct the fan strap supported with a financial contribution but had no other influences. 100 participants with multiple causative etiologies (Venous-86%, CAVI-8%, Lymphovenous-3%, Other-3%) are reported in this abstract, 10 participants were withdrawn from the project, for a variety of biopsychosocial reasons, their etiology is not captured in this abstract. Participants were treated with standard care for 4-weeks within specialist teams, fan-strapping commenced if 50% epithelialization was not achieved by the end of the standard care period. A validated quality-of-life tool was incorporated.

Results / Discussion: Data indicates increased prevalence in males-64%, many participants had limited ankle range

of movement-52%, and medial presentation was more frequent than lateral-83%. Findings indicate a cohort of 14 patients healed on transition to inelastic compression bandages during the standard care period. Being seen in a specialist, not generalist service may cause/contribute to healing. Application of focused compression 'fan-strapping' did support healing in patients who had peri-malleolar ulceration of up to 5-year duration before entry to LoCUS-63%.

Conclusion: Findings provide a contribution to the evidence base for fan-strapping use, which may be useful to European colleagues challenged to heal peri-malleolar ulceration. % to nearest whole number.

OP082 Enhanced silver dressing versus dialkylcarbamoyl chloride-coated dressing in venous leg ulcers: A blinded re-assessment of randomized controlled trial findings

Rebecca Rodger[1], Prof. Dr. Joachim Dissemond[2], Constanza Cabrera[3], Jan Ljungqvist[1], Beate Paintner-Hanson[1]

[1]Convatec Technology Centre, Deeside, United Kingdom, *[2]Department of Dermatology, Venerology and Allergology, University of Essen, Essen, Germany*, *[3]Convacare Clinics, Bogotá, Colombia*

Aim: Venous leg ulcers (VLUs) are hard-to-heal wounds posing significant burden to patients and healthcare systems. A carboxymethylcellulose fibre dressing containing ionic silver, ethylenediaminetetraacetic acid (EDTA), and benzethonium chloride (CISEB*) was designed to address these challenges. A previous randomized controlled trial (RCT) demonstrated a significantly higher complete wound closure rate at 12 weeks with CISEB* compared to a dialkylcarbamoyl chloride-coated dressing (DACC†; 74.8% vs. 55.6%, p<0.0031).[1] This study aimed to validate these findings through independent, blinded re-assessment.

Method: Patients with hard-to-heal VLUs were randomized 1:1 to receive either CISEB or DACC for ≤4 weeks. Wounds not healed by week 4 received standard of care for ≤12 weeks or until healed. The full study design has been previously described.[1] The primary endpoint was complete wound closure at week 12, assessed by an independent, blinded reviewer using photographs. Inter-rater reliability was an exploratory endpoint. A post hoc tipping analysis modeled the probability of outcome reclassification based on disagreement rates.

Results / Discussion: In total, 113 VLUs from 105 patients were included (CISEB: n=49; DACC: n=56). Agreement between the independent reviewer and the original RCT assessment was 94.7% (Cohen's Kappa=0.89; 'near-perfect' agreement). Tipping point analysis confirmed a 98% probability that CISEB retained superiority under plausible reclassification scenarios; even using the upper 95% CI for disagreement (11.1%), probability remained 92.4%. High inter-rater agreement was observed across sites. By week 12, CISEB achieved higher closure rates than DACC (63.5% vs. 59.0%).

Conclusion: Independent blinded assessment confirmed that CISEB improves wound closure rates in hard-to-heal VLUs compared to DACC, aligning with previous RCT findings.

References:

[1] Beraldo S et al. *J Wound Care* 2025;34(3):170-178. *Aquacel Ag+ Extra †Cutimed Sorbact

OP083 Wound bed preparation with bromelain-based debridement in venous leg ulcers: Results from the chronex randomized controlled trial

Robert Snyder[1], Yaron Shoam[2], Adam Singer[3], Cyaandi Dove[4]

[1]MediWound Ltd., Yavne, Israel, *[2]Soroka University Medical Center, Beer Sheba, Israel*, *[3]Stony Brook University, Stony Brook, NY, United States*, *[4]Oregon Health & Science University, Potland, Oregon, United States*

Aim: Wound bed preparation (WBP) - complete removal of non-viable tissue with full granulation coverage, is essential for healing chronic wounds. The ChronEx randomized controlled trial evaluated the efficacy and safety of a bromelain-based enzymatic debridement (BBD) agent compared with gel vehicle (GV) and non-surgical standard of care (NSSOC).

Method: ChronEx was a multicenter, randomized, placebo-controlled study across 20 sites in the United States, Switzerland, and Israel. Patients with venous leg ulcers (VLUs) were randomized 3:3:2 to once-daily BBD, GV, or NSSOC for up to eight applications over 14 days or until complete debridement, followed by 12 weeks of non-active dressings. The primary endpoint was complete debridement within 2 weeks. Secondary/exploratory outcomes included time to debridement, WBP (complete debridement + 100% granulation tissue) and time to WBP.

Results / Discussion: 119 patients were randomized (BBD n=46; GV n=43; NSSOC n=30). Complete debridement within 2 weeks was achieved in 63.0% of BBD-treated patients versus 30.2% with GV (P=0.004) and 13.3% with NSSOC. Median time to debridement was significantly shorter with BBD (9 days) compared with GV (63 days; P=0.004) and NSSOC (59 days; P=0.016). Post-hoc analyses showed higher WBP rates within 2 weeks with BBD (50.0%) versus GV (25.6%; P=0.01) and NSSOC (9.7%; P=0.0001). Median time to WBP during the study was 11 days with BBD versus 85 days (GV; P=0.004) and 63 days (NSSOC; P=0.01). Early WBP (Day 14) increased the likelihood of healing (50.0% vs. 22.7%; RR=2.4; P=0.0005).

Conclusion: BBD enabled rapid, effective debridement and accelerated WBP, clearly outperforming GV and NSSOC. Early WBP strongly predicted healing, reinforcing its value as a therapeutic goal and supporting the Phase 3 VALUE study in VLU.

OP084 Infrared thermography as a predictive tool in venous leg ulcer management: Insights from a two-stage clinical study

Justyna Cwajda Białasik[1], Paulina Moscicka[1], Arkadiusz Jawien[1], Maria Teresa Szewczyk[1]

[1]Nicolaus Copernicus University in Torun, Torun, Poland

Aim: This two-stage study evaluated the clinical utility of infrared thermography (IRT) in venous leg ulcer (VLU) assessment, and its application for monitoring the effects of fish-collagen gel on healing, inflammation, pain, and quality of life.

Method: Stage 1 was a 12-week prospective observational study including 57 patients, generating over 680 thermograms. Temperature distributions were analysed for the ulcer surface, periwound skin (5 cm from the edge), and a healthy reference site. Prognostic modelling using panel regression (static dataset n=313; dynamic dataset n=368) assessed associations between temperature gradients and healing. Stage 2 was a 12-week randomized single-centre trial of 100 patients receiving standard compression and wound care, randomised to fish-collagen gel or placebo. Outcomes included healing (digital planimetry), local inflammation (IRT), and patient-reported symptoms.

Results / Discussion: In Stage 1, decreasing temperature differences between the wound and periwound skin strongly correlated with healing; each 1 cm2 reduction in wound area corresponded to a 0.04°C decrease in temperature gradient ($p<0.001$). IRT detected subclinical inflammation and microbiological deterioration several days before clinical signs appeared. In Stage 2, collagen therapy significantly improved healing and reduced local inflammation. Thermographic changes preceded visible healing by up to two weeks and distinguished healing from non-healing wounds earlier than planimetry (week 6 vs week 8). IRT confirmed the anti-inflammatory effect of collagen and its beneficial impact on wound-related symptoms

Conclusion: IRT is a sensitive modality for VLU assessment, capable of detecting subclinical changes and predicting healing dynamics. Fish-collagen gel effectively promotes healing and mitigates inflammation, supporting its integration into comprehensive VLU management.

OP085 Evaluation of the efficacy and safety of a new an innovative one-bandage multicomponent system in the treatment of lower limb edema (lymphedema and phlebolymphedema)

Pascal Filori[1]

[1]*Lymphologist, Marseille, France*

Aim: Lower limb edema significantly impairs quality of life of the patients and has no definitive curative treatment. Combined procedures including skin care, lymphatic drainage, movement, and compression therapy provide effective improvement. This pilot study was performed to evaluate the efficacy and safety of an innovative single-layer multicomponent compression system in that chronic pathology.

Methods: A clinical evaluation of a one-bandage multicomponent system was conducted in a private French lymphology practice. The primary endpoint was lower limb volume reduction after a period of one month duration. Secondary endpoints included ease of application, patient acceptability, change frequency, local tolerance, pain (VAS), quality of life (questionnaire and global health VAS).

Results: Nineteen patients were included (17 women, 2 men; mean age 63.5 years, mean BMI 25.7), previously treated mainly with a multilayer compression system: 10 with post-surgical lymphedema and 9 with phlebolymphedema. After a mean treatment duration of 39.0 ± 5.4 days (median 36 days), the limb volume decreased by 16.0% ± 4.8 for lymphedema and by 6.8% ± 3.5 for phlebolymphedema. All the treated patients considered that the oedema was partially resolved after the treatment period; Pain decreased from 3.29 to 2.24 on the VAS (mean, 32% reduction), and global health VAS scores improved from 60 to 80 (+33%). The system was well-tolerated without any adverse event, with comfort rated “good” to “very good” for 100% of the patients at the final visit. All the patients considered the self-application of the tested one bandage easier than the previous compression system. Additional clinical data will be presented.

Conclusion: This one-bandage multicomponent system appears effective, safe, and well-tolerated, offering a relevant alternative for managing lower limb oedema.

OP086 Brazilian bioinnovation in wound care: Synergistic effects of Hevea brasiliensis serum, Arnica, and infrared therapy

Camila Moraes[1], Marcelo Mendes[2 3]

[1]*Dra Camila Mendonca - Enfermagem Avancada, guaxupé, Brazil*, [2]*Cicatripelli, PA, Brazil*, [3]*Cicatripelli, Belem PA, Brazil*

Aim: To evaluate the clinical effects of combining Hevea brasiliensis serum, low-level infrared laser therapy (LLILT), and compression therapy on chronic venous ulcer healing.

Methodology: A descriptive clinical study with a quantitative approach was conducted with 104 patients presenting chronic venous ulcers, monitored by specialist wound-care nurses. All procedures followed ethical principles and were approved by an Ethics Committee. At each evaluation, wounds were cleansed, followed by LLILT application, topical administration of Hevea brasiliensis serum (Biocure), and coverage with an arnica-enriched Unna boot. Patients were followed for at least 30 days, with systematic documentation of tissue evolution, wound area measurements, and photographic records.

Results: All patients exhibited visible neoepithelialization at wound margins after 15 days. After 30 days, 87% showed a ≥50% reduction in wound area. These results suggest a synergistic effect of compression therapy, LLILT-induced neoangiogenesis, the anti-inflammatory and antimicrobial properties of Arnica montana, and the regenerative potential of Hevea brasiliensis serum. Corroborating these findings, previous studies show that LLILT enhances angiogenesis, increases mitochondrial ATP production, and stimulates fibroblast proliferation, accelerating tissue repair; Arnica montana assists in biofilm disruption and modulates local inflammation; Biocure, containing 10% natural Hevea brasiliensis serum, provides bioactive peptides and antioxidants that promote keratinocyte migration, regulate inflammation, and support extracellular matrix reconstruction.

Conclusion: The combination of compression therapy, photobiomodulation, and plant-derived bioactive components accelerated healing and improved clinical comfort in patients with chronic venous ulcers. This biologically synergistic strategy represents an innovative therapeutic approach and provides a basis for larger, controlled clinical trials to confirm and expand these findings.

OP087 A pilot study to investigate the relative effectiveness and safety of chemical wound debridement and curettage in the treatment of venous and mixed aetiology leg ulcers

Carla Leca[1], Debbie Delloson[1]

[1]*Pioneer Wound Healing and Lymphoedema Centres, Eastbourne, United Kingdom*

Aim: This pilot Randomised Controlled Trial compared the effect of a novel desiccating product (DebriChem®, Debx Medical) and sharp debridement when used to debride Venous Leg Ulcers (VLU) and mixed aetiology leg ulcers (MAU)

Method: This was a pilot, randomised, controlled, single-centre trial to determine the effectiveness of DebriChem in both the reduction of the surface area of wounds and reduction of slough covering the wound surface compared with the same outcomes where wounds were debrided using a curette.

Results / Discussion: Participants were recruited from patients receiving Pioneer Wound Healing and Lymphoedema Centres outpatient treatment for their wounds. The participants received either DebriChem (n=39) or curettage debridement (n=41). The two arms appeared well balanced at the start of the study: with the exception of post-debridement pain scores at Week 0 which tended to be higher in the DebriChem debridement group (mean pain score DebriChem 56.2; curettage 26.7). The mean and Standard Deviation (SD) wound area reduction in the DebriChem treated group was 52.2% (SD 55.7) and in the curettage group the mean reduction was 51.7% (SD 120.3). The percentage of the wound bed that was covered with slough generally fell during the study. Both debridement techniques produced positive benefits in terms of self-reported Health Related Quality of Life. The changes in WoundQOL scores between baseline and Week 12 were higher in both study arms than the Minimal Important Difference cited for this tool (0.5).

Conclusion: Both debridement methods produced similar clinical outcomes, suggesting that DebriChem debridement may be as effective as curettage debridement offering practical advantages in clinical settings with reduced staff training and rapid wound debridement.

OP088 Endovenous laser ablation of saphenous veins in treatment of chronic venous ulcers in patients with diabetes mellitus

Vugar Fattah-Pur[1]

[1]*Azerbaijan State Advanced Training Institute for Doctors named after A.Aliyev, Baku, Azerbaijan*

Aim: To evaluate the effectiveness of endovenous laser ablation (EVLA) of saphenous veins (SV) in the treatment of chronic venous ulcers (CVU) in patients with diabetes mellitus (DM).

Method: This randomized prospective study was conducted in 222 patients (151 women, 71 men) with diabetes, suffering from CVU, due to SV deficiency. The average age was 58.4 years. The 1st group of patients (N=119) was carried out by an EVLA with 1470 nm diode laser. In the 2nd group (N=76), the EVLA with 1940 nm was performed. The 3rd group of patients (N=27) received compression therapy (CT). The average ulcer area was 3.28±0.93 cm^2.

Results / Discussion: The average diameter of the treated saphenofemoral junction (SFJ) saphenopopliteal junction (SPJ) were 13.4±1.2 mm (from 7.8 to 28.6 mm) and 6.8±1.4 mm (from 5.2 to 11.6 mm) respectively. Pain in the postoperative period was observed in 44 patients (22.56%), ecchymosis in 162 patients (83.08%), induration in 113 patients (57.95%). 45 patients complained of paresthesia (23.08%). The healing time for ulcers in the 1st and 2nd groups was 38.7±8.4 and 37.9±9.2 days, respectively. In group 3, the ulcer healing time was 103±24.4 days. In this case, the wearing of compression knitwear of the 3rd class in the 1st and 2nd groups was 4-7 weeks, in the 3rd group - 14-19 weeks.

Conclusion: EVLA is an effective and minimally invasive method to eliminate inconsistent SV for the treatment of CVU in patients with DM, and also reduces the duration of CT.

NEGATIVE WOUND PRESSURE THERAPY

OP132 Outcomes of negative pressure wound therapy with instillation in post-mastectomy implant infections

Margarida Pascoal[1], Margarida Bernardo[1], Beatriz Costeira[1], António Soares[1], Rodrigo Oom[1], Cristina Costa[1], João Vargas Moniz[1], Nuno Abecasis[1], Sara Carvalhal[1]

[1]*Instituto Português de Oncologia de Lisboa, Lisboa, Portugal*

Aim: Oncoplastic breast surgery allows for oncologic resection and immediate reconstruction. Post-operative infection remains a significant complication that can result in implant loss, increased patient morbidity with delayed adjuvant therapy. Our aim was to characterize the cohort of patients who developed implant-associated infection (IAI) and subsequently underwent negative-pressure wound therapy with instillation (NPWTi).

Method: A single-center retrospective cohort study including patients who underwent oncologic breast surgery between January 2019 and October 2025. Our primary objective was to assess the impact of NPWTi in patients who developed IAI.

Results / Discussion: A total of 680 patients underwent mastectomy with implant-based reconstruction. Twenty-six patients (3.8%) developed IAI that required implant removal and NPWTi. All patients were female, with a median age of 50 years (IQR 43-55) and a median body mass index of 27.4 kg/m^2 (IQR 23.7-30.6). Median follow up time was of 33.5 months (13-53). The median time from surgery to IAI and subsequent NPWTi placement was 7 months (IQR 2-25). NPWTi was maintained for a median of 6 days (IQR 5-7). The success rate was of 84.6%, with only 4 patients (15.4%) experiencing complete reconstruction loss - significant risk factors included the use of a dorsal flap during the initial surgery (p=0.025) and infection with Staphylococcus aureus (p=0.007). Prior to NPWTi, oral antibiotics had been initiated in 23 patients (88.5%). No infectious agent was identified in 11 cases (42.3%).

Conclusion: IAI following mastectomy is uncommon but clinically significant. In our cohort, short duration NPWTi successfully managed IAI, validating this approach as safe and effective.

NUTRITION

OP101 The remaining burn area and post-injury day are non-linearly correlated with resting energy expenditure (REE) in burn patients

Yiran Wang[1], Xingang Wang[1]

[1]*The Second Affiliated Hospital of Zhejiang University College of Medicine, Hangzhou, China, Hangzhou, China*

Aim: Currently, most equations for the prediction of REE in burn patients were constructed through linear regression, with generally low accuracy. This study analyzed the correlation between remaining burn area and post-injury day with REE to guide the construction of future REE prediction models.

Method: A total of 49 burn patients with mechanical ventilation admitted in our hospital from April 2020 to December 2023 were enrolled. REEs were measured by indirect calorimetry at 3, 5, 7, 9, 11, 14 post-injury day and every 7 days thereafter until patients were successfully weaned from ventilator or died. The predicted REEs by equations were compared with measured REEs. Restricted cubic splines were used to explore the correlation between remaining burn area, post-injury day and actual REE.

Results / Discussion: We conducted a total of 259 measurements of REEs. The proportions of the predicted REEs within ±10% of the measured REE for Harris-Benedict equation, Xie equation, Thumb 25 equation, Xi equation, and Hangang equation were 8.1%, 12.7%, 19.7%, 27.4%, and 28.9%, respectively. After adjustment for gender, age, height, and weight, a significant nonlinear positive correlation was observed between the remaining burn area and measured REE (correlation p-value <0.001; nonlinear p-value = 0.017). A nonlinear negative trend was observed between post-injury day and measured REE (correlation p-value = 0.045; nonlinear p-value = 0.056).

Conclusion: Most current REE equations for burn patients are inaccurate. Due to non-linear relationships between remaining burn area, post-injury days, and actual REE, optimized modeling may improve accuracy. Our group plans to optimize REE prediction using machine learning based on 2,000 measurements from 400 patients.

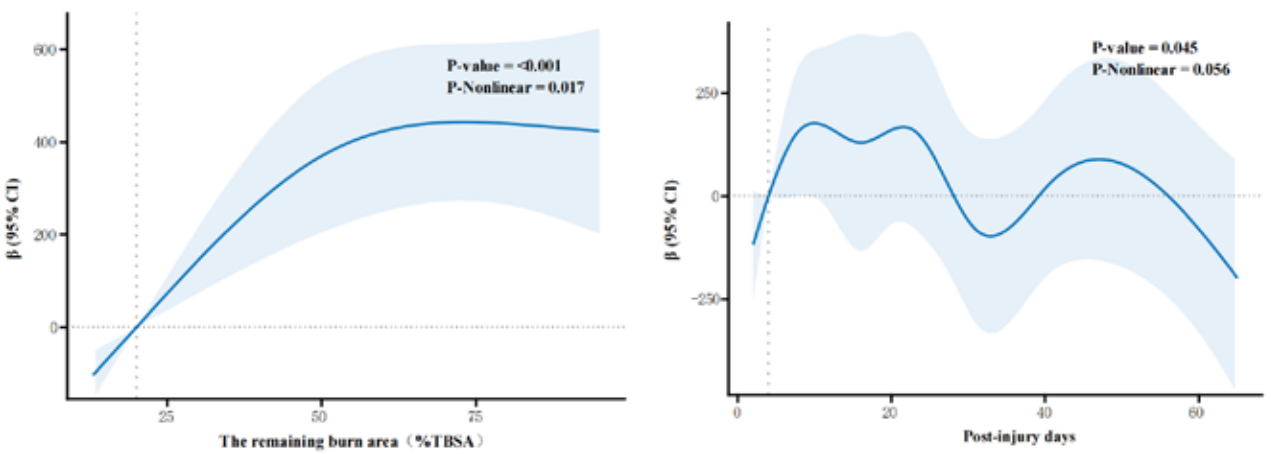

PAIN

OP097 The impact of fear on pain perception in wound therapy using VR technology

Anna Surmacz[1], Anna Englert-Bator[2], Dr. Przemysław Lipiński[3], Dariusz Bazaliński[1]

[1]Specialist Hospital, Podkarpackie Oncology Center named after Rev. B. Markiewicz, 36-200 Brzozów, Poland, Institute of Nursing, Faculty of Medical Sciences, University of Rzeszów, 35-959 Rzeszów, Poland, Rzeszów, Poland, [2]Department of Psychology, Faculty of Medical Sciences, University of Rzeszów, 35-959 Rzeszów, Poland, Rzeszów, Poland, [3]Pracownia Leczenia Ran, Centrum Medyczne ARGO, 90-212 Łódź, łódź, Poland

Aim: To assess the impact of virtual reality on anxiety and pain in a group of patients with chronic wounds.

Method: A randomized, controlled study was designed, enrolling 100 patients with lower limb ulcers who underwent acute wound debridement. In group A, standard local anesthesia was administered before the acute wound treatment procedure, while in group B, in addition to local anesthesia, the subjects used VR goggles on which calming 360° videos were played. Before the procedure, during the procedure, and 10 minutes after acute treatment, pain intensity was assessed using the NRS scale and the McGill Pain Questionnaire (MPQ). During the study, anxiety was measured using the State-Trait Anxiety Inventory (STAI).

Results / Discussion: No statistical differences were found in terms of pain variables. In the course of the study, baseline pain did not differ between groups. During the wound management procedure, group B reported significantly lower pain levels ($p = 0.012$), and this benefit persisted after the procedure ($p = 0.025$;). MPQ scores confirmed these findings (median = 14.0 vs. 16.0 during the procedure; $p = 0.009$). No relationship was found between situational anxiety or personality anxiety (situational anxiety $p = 0.201$; personality anxiety: $p = 0.401$), and anxiety did not correlate with pain reduction.

Conclusion: The use of virtual reality as part of a routine procedure secondary to local anesthesia results in mild to moderate clinical pain relief. The effect of virtual reality reduces pain perception by distracting the patient. The use of VR technology is a safe and inexpensive method of pain relief. Larger, stratified studies involving psychological profiling and cost-effectiveness analyses are needed to optimize patient selection and assess the durability of benefits.

PRESSURE ULCER

OP090 Use of wipes with emollient and barrier properties for the prevention of pressure injuries: A multi-centre randomized controlled trial

Hayley Ryan[1], Peta Tehan[2], Alison Hutton[3], Oya Gumuskaya[4], Brett Mitchell[5]

[1]University of Newcastle School of Nursing and Midwifery, Medicine and Wellbeing, University of Newcastle PhD researcher, Newcastle, Australia, [2]Monash University School of Clinical Sciences, Clayton, Australia, [3]Western Sydney University SWS Nursing & Midwifery Research Alliance|SWSLHD, Ingham Institute for Applied Medical Research South Western Sydney Local Health District (SWSLHD), Sydney, Australia, [4]Senior Lecturer|School of Nursing and Midwifery | Western Sydney University, Parramatta, Australia, [5]Professor of Nursing and Health Services Research, Avondale University Professor of Nursing, School of Nursing and Midwifery, Monash University Honorary Professor, School of Nursing and Midwifery, University of Newcastle Infection Research Program co-lead, Hunter Medical Research Institute Conjoint, Central Coast Local Health District, NSW., Avondale, Australia

Aim: To evaluate the effectiveness of a twice-daily application of a wipe impregnated with emollient and barrier ingredients in reducing incidence of pressure injury (PI) in aged care consumers.

Method: Design: A single-blinded, multi-centre randomised controlled trial (RCT). Setting: 20 residential aged care facilities (RACFs) in Rural and Metropolitan New South Wales and the Australian Capital Territory, Australia. Participants: 858 aged care consumers aged ≥65 years at risk of developing a PI (429 per group). Intervention: The intervention group received twice-daily applications of a pre-packaged wipe impregnated with emollient and barrier

ingredients (Contiplan®) to the sacrum, buttocks, and heels, in addition to standard care, for the study duration. Participants were randomised into intervention or control groups in a 1:1 ratio. Primary and secondary outcomes: The primary outcome was the incidence of PIs per 1000 consumer days. Secondary objectives were the incidence of incontinence-associated dermatitis and the time to PI or incontinence-associated dermatitis.

Results / Discussion: Between 1st November 2023 to 30th June 2024, 858 participants were included in the study. Within the control group, 55 (12.82%, 95%CI 9.8-16.6) PI events occurred compared to 27 PI events (6.29%, 95%CI 4.2-9.0) in the intervention group. The incidence of PIs per 1000 consumer days was significantly lower in the intervention group (0.31; 95% CI: 0.20–0.45) compared to the control group (0.62; 95% CI: 0.47–0.80; p = .003).

Conclusion: The use of wipes with emollient and barrier properties significantly reduced the incidence of PIs and prolonged the time to first PI, demonstrating efficacy as a PI preventive strategy in aged care. Trial registry: Australian and New Zealand Clinical Trials Registry (ACTRN12622001360707).

OP091 Risk factors for pressure injury in adults in intensive care: A decision tree analysis

Larissa Bernardo[1], Bruna Velozo[1], Meire Castro[1], Gustavo Arana[2], Lucas Calache[2], Aglécia Budri[1 3], Luciana Abbade[1]

[1]São Paulo State University (UNESP), Medical School,, Botucatu, Brazil, *[2]São Paulo State University (UNESP), School of Engineering, São João da Boa Vista, Brazil*, *[3]School of Nursing & Midwifery. Royal College of Surgeons in Ireland Skin Wounds and Trauma Research Centre, Dublin, Ireland*

Aim: To identify factors associated with pressure ulcer (PU) development in adults admitted to the intensive care unit (ICU) by integrating variables from the Braden, EVARUCI, Revised Cubbin and Jackson, Sunderland, and CALCULATE scales using a decision tree model.

Method: This prospective cohort study was conducted in an adult ICU of a tertiary hospital. Patients aged ≥18 years, hospitalized for ≥24 hours without pre-existing PU, were assessed daily using the five scales until PU occurrence, discharge, death, or 21 days of ICU stay. The model was developed in Jupyter Notebook (Python), with the dataset divided into 70% for training and 30% for testing. Performance metrics included accuracy, sensitivity (recall), specificity, and Area Under the Curve (AUC). Key predictive factors were also examined.

Results/Discussion: A total of 150 patients were evaluated, of whom 26.7% developed PU, resulting in 1,340 assessments per scale. The most relevant variables included skin integrity, body weight, underlying clinical condition, age, nutritional status, length of ICU stay, mobility, friction/shear, incontinence, and personal history. The model trained with these key variables achieved an AUC of 0.96, outperforming the individual scales (AUC 0.72–0.95). These findings align with Alderden et al. (2024), who reported an AUC of 0.80 and identified age and personal history as relevant predictors. Machine learning should complement—rather than replace—clinical judgment, supporting decision-making, improving predictive performance, and enhancing patient safety. Nevertheless, external validation remains a limitation and is essential for broader applicability across diverse clinical settings.

Conclusion: The decision tree proved to be a promising tool to support ICU care by highlighting critical factors. Future directions include expanding variables, comparing models, and developing an interactive web-based application.

OP092 A systematic review on the impact of sub-epidermal moisture assessments on pressure ulcer/injury care delivery pathways

Pinar Avsar[1], Declan Patton[1], Janet Cuddigan[2], Zena Moore[1]

[1]RCSI University of Medicine and Health Sciences, Dublin, Ireland, *[2]University of Nebraska Medical Center, Omaha, United States*

Aim: To assess how detecting elevated ssub-epidermal moisture (SEM, $\Delta \geq 0.6$) influences the delivery of pressure injury/ulcer (PI/PU) care pathways and whether SEM-guided interventions reduce PI/PU incidence in at-risk adults.

Method: A systematic review was conducted, including original prospective or retrospective studies reporting the impact of SEM assessment on PI/PU care delivery in adults at risk. The protocol was registered on PROSPERO (CRD42023416975). Searches were performed in May 2023 across PubMed, CINAHL, Scopus, Cochrane, EMBASE, Web of Science, and ScienceDirect. Data were extracted using a structured tool capturing country, setting, sample size, intervention, control, and study quality. Quality appraisal was undertaken using the Evidence-Based Librarianship (EBL) checklist.

Results / Discussion: Nine studies published between 2017 and 2022 were included, with six studies (67%) conducted in England. Studies encompassed acute care, medical-surgical, and palliative settings. Common PI/PU care pathway components included pressure-redistributing mattresses/cushions, repositioning plans, skin inspection, incontinence management, and mobility assessment. Seven studies reported PI/PU incidence. A meta-analysis of these seven studies (N = 18,451) demonstrated a statistically significant reduction in visual PI/PU development in favour of SEM-guided care pathways compared to usual care (odds ratio = 0.36; 95% CI: 0.24–0.53; $p < 0.00001$). Evidence indicates that SEM assessment prompts targeted, anatomy-specific interventions, leading to consistent reductions in hospital-acquired PI/PU incidence. Limitations include predominance of observational studies and variable study quality.

Conclusion: Implementing SEM assessments as part of PI/PU care pathways enhances preventive actions and reduces injury incidence. Findings support the integration of SEM monitoring across diverse care settings and patient populations, while highlighting the need for future randomised trials to strengthen evidence on the efficacy of SEM-guided preventive interventions.

OP093 To heal or not to heal: Establishing a benchmark for pressure ulcer healing

Robert Frykberg[1], Zweli Tunysiwa[2], Ryan Dirks[3]

[1]University of Texas San Antonio, San Antonio, Texas, United States, *[2]Open Wound Research, Charlotte, NC, United States*, *[3]United Wound Healing, Tacoma, United States*

Aim: To determine the frequency, distribution, temporal parameters, and mean healing times of pressure injuries (PI) and pressure ulcers (PU) managed exclusively with standard of care (SOC), using data from a large U.S.-based mobile wound registry.

Method: This retrospective descriptive study analyzed deidentified patient data from electronic health records across approximately 350 healthcare facilities in the U.S., spanning January 2022 to July 2024. Data included detailed patient demographics, lesion characteristics (stage and anatomical location), and healing outcomes. The analysis focused specifically on PI/PU cases managed solely through SOC without adjunctive advanced therapies. Healing times were calculated by lesion stage, and cumulative healing percentages were assessed at clinically meaningful intervals.

Results / Discussion: The registry encompassed 12,492 patients with 21,182 PIs/PUs. Patients had a mean age of 74.8 years (range: 17–108), with women comprising 51.0% of the cohort. The heel was the most common site of injury, representing 23.4% (4,949 lesions), followed by the buttocks at 20.9% (4,416 lesions). Stage 2 and Stage 3 wounds were most frequent, accounting for 16.5% and 31.5% of lesions, respectively. Overall, 49.5% of lesions healed with SOC alone, averaging 11.2 weeks. Specifically, combined Stage 2 and 3 lesions had a mean healing time of 11.1 weeks, with 49.8% achieving complete healing by 20 weeks.

Conclusion: This analysis demonstrates that nearly half of PI/PU cases managed with standard protocols achieved healing within approximately 11 weeks, providing crucial benchmark data for expected outcomes and supporting future comparative efficacy studies.

OP094 Touching the virtual, healing the real: Development of a digital twin–haptic mixed reality simulation for pressure injury management

Leyla Özdemir[1], Fatma Uslu Şahan[1], Nebahat Bora Güneş[1], Nebahat Bora Güneş[1], Ali Seydi Keçeli[1], Ercan Coş[1]

[1]Hacettepe University, Ankara, Türkiye

Aim: Nursing students often have limited opportunities to practice pressure injury management under safe and realistic conditions. To bridge this gap, simulation technologies that integrate physical and digital interaction have the potential to enhance experiential learning and clinical competence. This study aimed to describe the development of an innovative digital twin–haptic mixed reality (MR) software designed to create an immersive and nteractive educational experience for teaching pressure injury management in healthcare education.

Method: The MR software was developed using a marker-free computer vision and gesture recognition system that enables real-time synchronization between physical wound-care materials and their digital representations. Students perform a six-step simulation (1) wound measurement, (2) staging, (3) cleansing, (4) topical application, (5) dressing, and (6) positioning—using digitally anchored clinical materials such as wound rulers, saline solution, gauze, and dressings. Each object's digital twin is linked to its physical counterpart, allowing simultaneous tactile and visual interaction. Hand-tracking and haptic trait ensure natural manipulation and immersion. Upon completion, the system provides AI-generated feedback on procedural accuracy and task completion. Iterative testing refined synchronization, usability, and educational flow.

Results / Discussion: The software achieved seamless real-time interaction between digital and physical elements, producing a highly realistic, multisensory learning environment. User testing is planned to evaluate educational impact in the next phase.

Conclusion: The digital twin–haptic MR software provides a validated and scalable infrastructure for realistic, multisensory simulation in education. Future implementation studies will explore its effectiveness in improving skill acquisition and learning outcomes in wound care training.

OP095 Are beta blockers an overlooked risk factor for pressure injuries in older adults?

Busra Gokce[1], Oguzhan Firat[2], Ebru Caran Karabacak[1], Ekin Oktay Oguz[1], Fatma Kaplan Efe[1], Yelda Ozturk Kocaman[1], Eda Ceker[1], Meltem Koca[1], Suheyla Coteli[1], Pelin Unsal[3], Gözde Şengül Ayçiçek[1]

[1]Etlik City Hospital, Department of Geriatrics, Ankara, Türkiye, *[2]Erzincan Binali Yıldırım University, Faculty of Pharmacy, Department of Clinical Pharmacy, Erzincan, Türkiye*, *[3]Ankara Yıldırım Beyazit University, Faculty of Medicine, Ankara Bilkent City Hospital, Department of Geriatrics, Ankara, Türkiye*

Aim: To investigate the association between beta blocker use and the presence of pressure injuries in hospitalized older adults, and to assess whether beta blocker subclasses differ in their relationship with pressure injury occurrence.

Method: This cross-sectional study included 326 geriatric inpatients. Demographic characteristics, comorbidities, medication profiles, nutritional status, and Braden scores were extracted from clinical records. Patients were categorized as beta blocker users or non-users; users were further classified as receiving vasodilating (nebivolol/carvedilol) or non-vasodilating beta blockers. Multivariable logistic regression was performed to identify factors independently associated with pressure injury presence, adjusting for age, sex, stroke history, medication count, diabetes, Braden score, and MNA score.

Results / Discussion: Pressure injuries were identified in 31% of patients. Beta blocker use showed a trend toward increased pressure injury occurrence (adjusted OR 1.85; 95% CI 0.91–3.77; $p = 0.090$). Subgroup analysis indicated that non-vasodilating beta blockers were significantly associated with pressure injury presence (adjusted OR 2.22; 95% CI 1.03–4.79; $p = 0.042$), while vasodilating beta blockers showed a similar but non-significant trend (adjusted OR 2.39; 95% CI 0.70–8.15; $p = 0.163$). Lower Braden scores ($p < 0.001$) and lower MNA scores ($p = 0.001$) remained strong independent predictors of pressure injury presence. Pressure injury prevention protocols currently focus on mobility and nutrition, yet these findings suggest that medication-related vascular effects could also play a role in tissue perfusion and merit further investigation.

Conclusion: Beta blocker therapy may contribute to pressure injury occurrence in older adults, with the observed signal driven largely by non-vasodilating agents. Considering medication-related vascular effects in prevention strategies may support more targeted and individualized risk assessment in geriatric inpatients.

OP096 Retrospective analysis of healing outcomes and associated factors in patients with grade 2 or higher pressure ulcers

Jong-ho kim[1], Junseo Yun[1], Jin-Woo Kim[1]

[1]Seoul National University Bundang Hospital, Bundang-Gu, Seongnam-Si, Gyeonggi-Do 13620, Korea, Rep. Of South

Aim: pressure ulcers are a serious complication among immobilized or chronically ill patients, often resulting in prolonged hospitalization, morbidity, and increased healthcare costs. Despite therapeutic advances, predictors of long-term healing remain unclear. This study aimed to identify factors associated with one-year healing outcomes in patients with advanced pressure ulcers.

Method: this retrospective cohort study included adult patients diagnosed with grade 2 or higher pressure ulcers between January 2020 and January 2025. Clinical, laboratory, and wound-related variables were obtained from electronic records, including demographic data, comorbidities, nutritional indicators, ulcer features (stage, location, size, infection, bone exposure), and treatment modalities such as negative pressure wound therapy and surgical debridement. The primary outcome was complete wound healing within 12 months. Univariable and multivariable logistic regression analyses identified independent predictors of healing.

Results / discussion: a total of 240 patients (mean age, 61.5 ± 10.6 years; 69.6% male) were included in the final analysis. Complete healing at 12 months was achieved in 48.8% of patients. In the multivariate logistic regression model, negative pressure wound therapy (npwt), hospital-based treatment, lower initial ulcer stage, and absence of paralysis were independently associated with complete healing, with all predictors reaching statistical significance (all $p < 0.01$).

Conclusion: npwt, hospital-based management, lower initial ulcer stage, and absence of paralysis were strongly associated with improved one-year healing outcomes in patients with advanced pressure ulcers. These findings highlight the importance of early, structured wound care and suggest that both treatment setting and patient mobility status play critical roles in long-term recovery.

PREVENTION

OP128 A red flag to identify adults at high risk of early recurrence of venous leg ulcers

Kathleen Finlayson[1], Christina Parker[1], Ann Stewart[2], Amanda Pagan[3], Jane O'Brien[1]

[1]Queensland University of Technology, Centre for Healthcare Transformation, Kelvin Grove, Australia, *[2]Independent Practitioner, Sydney, Australia*, *[3]Health New Zealand, Te Whatu Ora, Southern District, Invercargill, New Zealand*

Aim: To identify clinical signs and symptoms predicting early recurrence of venous leg ulcers

Method: Secondary analysis was undertaken of data from four prospective cohort studies with adults who were recruited within four weeks of healing of a venous leg ulcer. Data was collected at baseline then every three months for 12 months on medical, clinical, preventive treatments and psychosocial factors. Cox proportional hazards regression was used to identify factors predicting venous leg ulcer recurrence.

Results / Discussion: A sample of 419 adults (51% female, mean age 73 years, SD 13.3) were recruited from tertiary hospital clinics, community clinics or home services in Australia and New Zealand. Half (51%) recurred within 12 months of healing, 20% within the first three months. Controlling for known risk factors such as history of deep vein thrombosis or multiple previous ulcers, the presence of erythema at the time of healing was associated with over twice the risk of ulcer recurrence ($p<0.001$), while presence of haemosiderosis was associated with 1.65 times higher risk of recurrence ($p=0.03$). Daily activity of moving around on feet at least 3 hours/day and wearing Class 2 hosiery or above for at least 5 days/week were associated with decreased risk ($p=0.005$ and 0.008 respectively).

Conclusion: The presence of clinical signs such as erythema and haemosiderosis indicates a need for close attention to preventive strategies and more frequent monitoring in order to prevent recurrence.

OP129 Closed incision negative pressure therapy (ciNPT) reduces abdominal donor site surgical wound dehiscence in deep internal epigastric perforator (DIEP) flap breast reconstructions: DEhiscence PREvention Study II (DEPRES II) - a randomized clinical trial

Anke Wijlens[1], Emmy Muller-Sloof[2], Erik De Laat[2], Onur Kenc[2], Ali Kumas[2], Vermeulen Hester[2], Stefan Hummelink[2], D.J.O. Ulrich[2]

[1]Radboud UMC, department of plastic and reconstructive surgery, Nijmegen, Nijmegen, Netherlands, *[2]Radboudumc Nijmegen, Nijmegen, Netherlands*

Aim: In breast reconstruction surgeries, surgical wound dehiscence is a serious complication which generates a significant burden on patients and healthcare systems. There are indications that postoperative treatment with closed incision negative pressure therapy (ciNPT) has been associated with reduced wound dehiscence rates. This randomized clinical trial examines the effect of ciNPT application on abdominal donor site surgical wound dehiscence in low- and high-risk patients undergoing a breast reconstruction with a deep internal epigastric perforator (DIEP) flap.

Method: 80 eligible women, stratified as low- or high-risk patients, were included and were randomized for treatment with either ciNPT or adhesive strips (AS) by drawing sealed, opaque envelopes. All surgeons were kept blind for allocation. Primary outcomes were surgical wound dehiscence and surgical site infection at the abdominal donor site upon follow-up after 12 weeks. Secondary outcomes were seroma and hematoma formation. Five patients were excluded from the study due to non-sufficient exposure to the study treatment (n=4) or major protocol deviation (n=1).

Results / Discussion: A total of 75 women, low-risk (n=38) and high-risk (n=37), received either ciNPT (n=36) or AS (n=39). Patients' demographics did not differ significantly. Donor-site surgical wound dehiscence occurred in 23 patients; the Absolute Risk Reduction was statistically significant (0.216, 95% Confidence Interval [0.015-0.417]). No statistically significant differences were found in surgical site infection or secondary outcomes.

Conclusion: In this randomized clinical trial, postoperative treatment with ciNPT decreased the incidence of surgical wound dehiscence at the abdominal donor site in low- and high-risk DIEP flap breast reconstruction patients.

OP131 Impact of a WOCN–ICU communication community on ICU pressure injury incidence: A retrospective observational study

Hyeonju Ryu[1]

[1]Pusan National University Yangsan Hospital, Yangsan, Korea, Rep. of South

Aim: To evaluate the potential impact of a structured Wound, Ostomy, and Continence Nurses (WOCNs)–ICU communication community on the prevention of ICU-acquired pressure injuries in a single institution

Method: Pressure injury incidence data were retrospectively collected from all ICUs of a tertiary hospital from 2021 to 2024. Observed rates were: 2021: 15.72%, 2022: 19.29%, 2023: 17.48%, and 2024: 14.02%. In Q3 2023, a WOCN–ICU communication community was implemented, involving regular online and offline discussions, consultations, and knowledge sharing focused on pressure injury prevention and management. Routine preventive measures continued throughout the study period, and no other systematic interventions were introduced.

Results / Discussion: Following implementation of the communication community, the previously increasing trend in ICU-acquired pressure injury incidence reversed, declining from 19.29% in 2022 to 17.48% in 2023 and 14.02% in 2024. While causality cannot be definitively established due to the retrospective observational design, the temporal association suggests that structured communication and collaboration between WOCNs and ICU staff may have contributed to improved prevention. Early identification of at-risk patients and timely preventive actions were likely facilitated by regular discussion and knowledge sharing.

Conclusion: The implementation of a structured WOCN–ICU communication network may be associated with a reduction in ICU pressure injury incidence. This study highlights the potential of collaborative communication strategies to enhance preventive care and support evidence-based practice in critical care. Further controlled studies are warranted to confirm causality and optimize implementation strategies.

OP133 Early management of incontinence-associated dermatitis and its impact on pressure ulcer prevention: A quality improvement initiative

Danielle Burnside[1]

[1]*North Tees and Hartlepool NHS Foundation Trust, Stockton-on-Tees, United Kingdom*

Aim: Moisture-associated skin damage (MASD), particularly incontinence-associated dermatitis (IAD), compromises skin integrity and increases pressure ulcer risk through friction and shear (Gray et al., 2011; EPUAP et al., 2019). In critical care (19 beds), varied use of barrier creams and soap substitutes produced inconsistent outcomes, and topical steroids were often used, yet skin breakdown persisted. This prompted introduction of an additional intervention layer via a structured pathway. Previously presented at EWMA, this approach showed significant reductions in MASD deterioration. This study now examines its impact on pressure ulcer incidence

Method: The pathway standardised early intervention and included:

- Prompt excoriation identification using an aide-memoir (Fig 1)
- Hydro-active colloid gel to restore moisture balance and repair superficial damage
- Enzyme alginogel to prevent infection and manage moisture in broken skin
- Routine monitoring of MASD and pressure ulcer incidence
- Staff training and feedback
- Data were collected for 24 weeks pre-intervention and 14 weeks during evaluation in critical care, with ongoing monitoring during wider rollout.

Results / Discussion: Evaluation showed a 53% reduction in moisture lesions (0.62 to 0.29 per week). Although the pathway was designed primarily to address MASD, pressure ulcer prevention remains a key priority for clinicians. Notably, pressure ulcer incidence fell by 84% (from 0.88 to 0.14 per week), highlighting the wider benefits of early IAD intervention (fig 2). Staff reported high satisfaction with ease of use and effectiveness, supporting the pathway's role in reducing harm.

Conclusion: Early IAD management within a structured pathway reduces MASD and helps prevent pressure ulcers, supporting NHS 10-Year Plan goals for prevention and patient safety (DHSC 2025).

QUALITY OF LIFE

OP099 The impact of wound-related pain on quality of life, psychosocial well-being, and pain beliefs in individuals with chronic lower limb wounds

Nicoletta Frescos[1], Windy Cole[2]

[1]*Northern Health and La Trobe University, Victoria, Australia*, [2]*Kent State University College of Podiatric Medicine, Independence, Ohio USA, United States*

Aim: Chronic lower limb wounds are frequently accompanied by persistent wound-related pain (WRP), which can significantly impair physical functioning, emotional well-being, and coping capacity. Despite its prevalence, the multidimensional impact of WRP remains underexplored in clinical practice. This study investigates the effects of WRP on quality of life (QoL), psychosocial health, and pain-related beliefs among individuals with chronic wounds.

Method: A cross-sectional survey of 105 patients from an outpatient wound clinic was conducted. Participants were grouped based on the presence or absence of WRP. Validated instruments—including the SF-MPQ, SF-BPI, M-RMDQ, DASS-21, CSQ, MHLC, PCS, and SOPA—were used to assess pain intensity, physical disability, emotional distress, coping strategies, and pain beliefs. Statistical analyses included t-tests, ANOVA, and Spearman's correlations.

Results / Discussion: Patients with WRP reported significantly higher pain scores (SF-MPQ total: μ=17.2 vs. 3.8, p<0.001), greater physical disability (M-RMDQ: μ=11.1 vs. 5.3, p<0.001), and elevated stress levels (DASS-21 stress: μ=4.7 vs. 2.4, p=0.007). Maladaptive coping strategies such as catastrophising and praying/hoping were more prevalent in the pain group. Pain beliefs differed by age and pain chronicity, with younger patients showing higher levels of catastrophising. Health locus of control varied, with pain sufferers more likely to attribute outcomes to internal or chance factors.

Conclusion: WRP in chronic wounds is a complex biopsychosocial phenomenon that significantly affects QoL and psychological resilience. Addressing pain beliefs and coping strategies through integrated wound care and mental health support may improve patient outcomes and promote healing.

OP102 Efficacy of personalized yoga rehabilitation on quality of life in survivors of extensive burns: A matched case-control study

Yiran Wang[1], Jianfen Zhang[2], Xingang Wang[1]

[1]The Second Affiliated Hospital of Zhejiang University College of Medicine, Hangzhou, China, *[2]Zhejiang Medical & Heath group Quzhou Hospital (Zhejiang Quhua Hospital), Quzhou, China*

Aim: To evaluate the comprehensive impact of adding personalized, phased yoga rehabilitation to standard rehabilitation care on joint range of motion, scar quality, activities of daily living (ADL), and mental health in survivors of extensive burns (TBSA ≥ 50%).

Method: Survivors of extensive burns undergoing rehabilitation at our institution between 2022 and 2025 were included. Patients were categorized into a 'Yoga Group' and a 'Standard Care Group' based on whether they received yoga rehabilitation. Whole-body range of motion (ROM), the Barthel Index, the Patient and Observer Scar Assessment Scale (POSAS), the Berg Balance Scale (BBS), the PTSD Checklist-Civilian Version (PCL-C), and the Beck Depression Inventory (BDI) were assessed before and after treatment. To enable comparative analysis, 1:1 case-control matching was performed based on rBaux scores and time post-injury.

Results / Discussion: A total of 64 patients were enrolled (Yoga Group: n=13; Standard Care Group: n=51). The Yoga Group received systematic yoga therapy for a mean of 7.2 ± 2.4 months. Post-treatment, the Yoga Group demonstrated significant improvements in the ROM of major joints (e.g., shoulder flexion: 101.25° ± 58.35° vs. 149.17° ± 26.10°, P=0.009; hip flexion: 73.33° ± 37.44° vs. 110.83° ± 23.14°, P=0.011). In the matched case-control analysis, the Yoga Group exhibited significantly better scar status (POSAS score: 55 ± 12 vs. 82 ± 26, P=0.012). Additionally, the Yoga Group showed trends toward superior scores on the Barthel Index, BBS, BDI, and PCL-C compared to the Standard Care Group.

Conclusion: Personalized yoga rehabilitation training significantly improved joint range of motion and scar quality in extensive burn survivors, and may offer additional benefits regarding ADL, balance function, and psychological well-being.

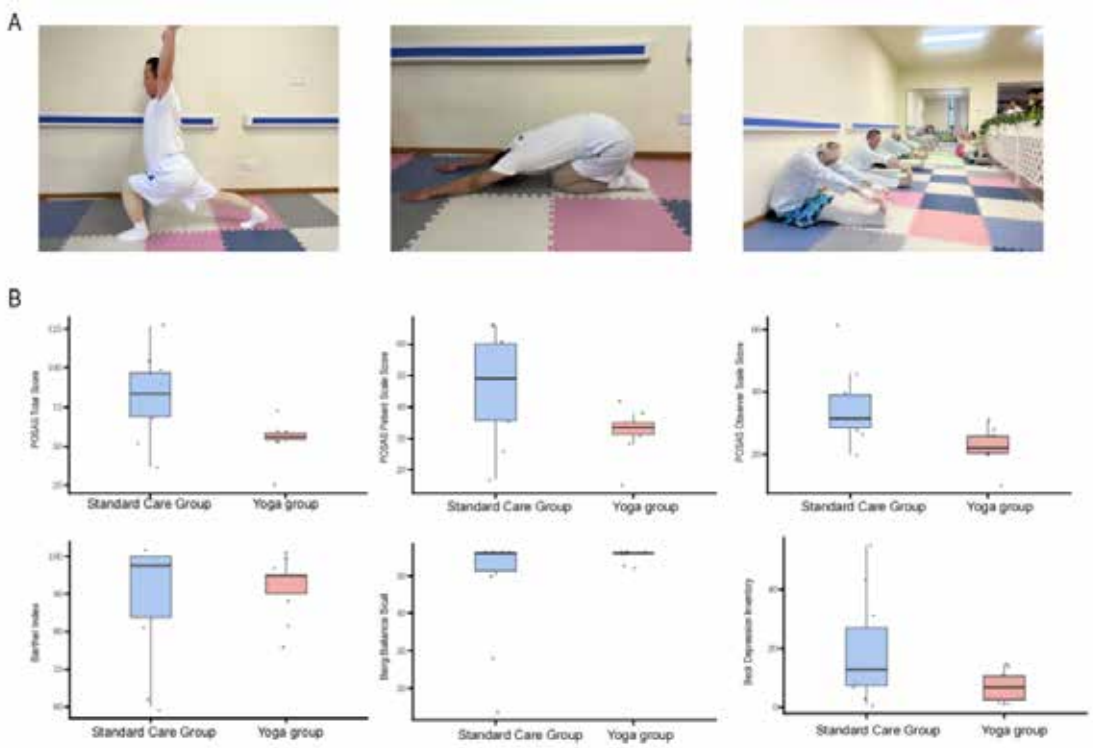

A. Yoga training scene; B. Results of various quality of life scales in the "Yoga group" and the "Standard Care Group" after case-control matching.

OP104 Impact of punch skin grafting in the quality of life of patients with hard-to-heal wounds

Clara Masó-Albareda[1 2 3], Marta Casals Zorita[1 2 3 4], Emma Puigoriol-Juvanteny[4 5 6], Natàlia Palacio Arronis[2 3], Ariadna Farres Serrat[1], Maria Carme Salomón Elcacho[1], Marta Otero Viñas[2 7], Marta Ferrer Solà[1 2 4]

[1]Fundació Hospital de la Santa Creu de Vic, Vic, Spain, *[2], Vic, Spain*, *[3]Doctoral School, University of Vic-Central University of Catalonia (UVic-UCC), Vic, Spain*, *[4]Consorci Hospitalari de Vic, Vic, Spain*, *[5]Faculty of Health Sciences and Welfare, University of Vic—Central University of Catalonia (UVic-UCC), Vic, Spain*, *[6]Multidisciplinary Inflamation Research Group (MIRG), Institute for Research and Innovation in Life and Health Sciences in Central Catalonia (IrisCC), Vic, Spain*, *[7]Department of Biosciences, Faculty of Science, Technology and Engineering, University of Vic-Central University of Catalonia (UVic-UCC), Vic, Spain*

Aim: Patients with complex wounds often have reduced health-related quality of life (HRQoL). Gaining insight into how it impacts on patient's HRQoL is crucial for optimizing healthcare delivery and guiding evidence-based clinical decision-making. This study aimed to evaluate HRQoL, pain and healing outcomes in patients treated with punch skin grafting.

Methods: This prospective observational study included patients with complex non-healing wounds (≥4–6 weeks) of any etiology treated in a wound care unit. Inclusion criteria were difficult-to-control pain, need for accelerated epithelialization, or palliative management. Patients with necrotic or infected wounds, dry eschar, uncontrolled anticoagulation (INR>3.5), or insufficient post-therapy immobilization were excluded. Sociodemographic data, healing outcomes, pain, and HRQoL (Wound-QoL-17) were collected and analyzed using descriptive non-parametric statistics.

Results: A total of 76 patients with 118 wounds were included, being venous the most prevalent etiology (n=42). Overall, 37 (48.7%) were female, and mean age was 75.5 years (SD 13.18). Baseline pain did not differ by gender (p=0.261) or age (p=0.184) but varied significantly across etiologies (p<0.001), with Martorell ulcers showing the highest pain levels (EVN 8.03), while neuropathic ulcers showed the lowest (EVN 1.42). Over time, HRQoL improved in Martorell, venous, traumatic, neuroischemic ulcers, remained stable in neuropathic wounds, and worsened in arterial ulcers. The Wound-QoL domains most affected were frustration due to prolonged healing time (73.8%), wound-related pain (67.3%), and concern about the ulcer (67.3%). Of the 118 wounds, 51(42.9%) had healed by the end of therapy.

Conclusions: Our findings suggest that effectiveness of punch skin grafting on pain and HRQoL is etiology-dependent, suggesting this therapy should be targeted to suitable wound types, while highlighting the need for alternative or intensified approaches in arterial ulcers.

SURGICAL APPROACHES

OP108 Allogeneic skin transplantation for refractory wounds in middle-aged and elderly patients

Xiang-Wei Ling[1], Peng Zhang[1], Su Li[1], Xiaoqiong Jiang[2], Tingting Zhang[1], Hong-Xin Wang[2]

[1]The First Affiliated Hospital of Wenzhou Medical University, Wenzhou, China, *[2]Wenzhou Medical University, Wenzhou, China*

Aim: To evaluate the clinical efficacy of allogeneic skin transplantation in the management of refractory wounds among middle-aged and elderly patients.

Method: A retrospective observational study was conducted involving 154 middle-aged and elderly patients with refractory wounds treated at the First Affiliated Hospital of Wenzhou Medical University from January 2023 to June 2025. All patients received vacuum sealing drainage for 7 days, followed by allogeneic skin transplantation. Subsequently, autologous skin grafting (ASG) or wound dressing changes were employed to promote wound healing. Outcome measures included: post- allogeneic skin transplantation of exposed tendons/bones and occurrence of tendon infection/osteomyelitis; survival rate of ASG at postoperative day 7; healing time in patients managed with wound dressing changes alone; patient satisfaction; and changes in pain intensity, sleep disturbance, and anxiety scores assessed before and 1 month after allogeneic skin transplantation.

Results / Discussion: After allogeneic skin transplantation, 153 patients exhibited robust granulation tissue formation achieving complete coverage of exposed tendons/bones, with no instances of tendon/bone necrosis, infection, or osteomyelitis. Among these, 76 patients underwent successful ASG at (45.4±12.0) d post-allogeneic skin transplantation (success rate 100.00%), 77 patients achieved primary wound healing through dressing changes alone within (65.2±13.4) d post-allogeneic skin transplantation. One patient experienced allogeneic skin transplantation dissolution and detachment, resulting in non-healing. The overall cure rate was 99. 4%. Patient satisfaction survey showed that 140 patients were very satisfied, 13 were satisfied, and 1 was dissatisfied (satisfaction rate 99.4%). Pain, sleep disturbance, and anxiety scores at 1 month post-allogeneic skin transplantation were significantly reduced compared to pre-transplantation scores (all $P < 0.05$). **Conclusion:** Allogeneic skin transplantation demonstrate excellent outcomes in treating refractory wounds in middle-aged and elderly patients.

OP109 Investigation on the clinical outcomes of wounds treated by the combination of extracellular dermal matrix and negative pressure wound therapy

Xingang Wang[1]

[1]The 2nd Affiliated Hospital of Zhejiang University School of Medicine, Hangzhou, China

Aim: To explore the clinical effects of the combination of extracellular dermal matrix and negative pressure wound therapy in repair severe skin defects.

Method: A total of 22 patients with varied skin defects receiving the combined use of extracellular dermal matrix and negative pressure wound therapy from January 2018 to October 2019. There were 13 males and 9 females with the average age of 53±15 years old. Of these patients, 14 patients received two-step transplantation of extracellular dermal matrix, and the other 8 patients with one-step transplantation.

Results / Discussion: (1) The situations of wound beds in the one-step transplantation group showed less tendon and/or bone exposure rather than those in the two-step transplantation group. (2) The patients receiving two-step transplantation had to spend more time (7 to 17 days averaged 12±3 days) between two surgeries for wound closure, while the other patients in the one-step transplantation group had no need for the secondary surgery. (3) For most of the admitted patients, the wounds reached good clinical outcomes with high-quality wound repair.

Conclusion: The one-step or two-step transplantation of extracellular dermal matrix combined with negative pressure wound therapy provides a good method for high-quality repair of severe skin defects. The clinicians can select one-step or two-step transplantations based on the situations of wound beds.

OP116 Wound-healing outcomes after UHFUS-guided deroofing in hidradenitis suppurativa: Enzymatic alginate gel versus hydrofibre alginate

Serena Corraro[1], Bianca Cei[1], Alessandra Michelucci[1], Irina Balan[1], Giammarco Granieri[1], Marco Romanelli[1], Valentina Dini[1]

[1]University of Pisa, Pisa, Italy

Aim: Hidradenitis suppurativa (HS) is a chronic inflammatory skin disease characterised by painful nodules, abscesses, and draining tunnels in areas where apocrine glands are present. Ultra-high frequency ultrasound (UHFUS; resolution 30 µm) can detect and visualise tunnels and microtunnels. This supports a targeted deroofing approach using a thermocautery scalpel and wound care. This study compared wound-healing times after UHFUS-guided deroofing in HS patients who were treated either with an enzymatic alginate gel or with a hydrofibre alginate dressing.

Method: A single-centre study was performed, including ten patients with inguinal HS. All lesions underwent UHFUS mapping with a 70 MHz probe to identify tunnels, that were marked with a dermographic pen. Then the tunnels were deroofed using a thermocautery scalpel, with immediate sonographic confirmation. Post-operatively, wounds were managed according to a standardised protocol using either the enzymatic alginate gel (n = 5) or a hydrofibre alginate dressing (n = 5). The primary endpoint was time to complete re-epithelialisation.

Results / Discussion: The mean time to wound closure was comparable in both groups: 35.8 days with the enzymatic alginate gel and 36.2 days with the hydrofibre alginate dressing (median: 37 vs. 36 days; range: 26–42 vs. 26–44 days). Despite the theoretical advantages of enzymatic alginate gel for autolytic debridement and biofilm control, no reduction in healing time was observed in this small study.

Conclusion: In ultrasound-guided deroofing for inguinal HS, both an enzymatic alginate gel and a hydrofibre alginate dressing achieved comparable overall wound-healing times. Further research is required in the form of larger prospective studies to determine whether specific dressings can influence postoperative outcomes in HS surgery.

OP107 Modified surgical management of hand deformities in patients with recessive dystrophic epidermolysis bullosa

Junwen Ge[1], Zishang Guo[1], Qunmei Zhou[1], xiaoyi Liu[1], Dan Deng[1], Pengjie Wan[2]

[1]Department of Dermatology, Shanghai Children's Medical Center, Shanghai Jiao Tong University School of Medicine, Shanghai, China., Shanghai, China, *[2]Department of Dermatology, Shanghai Children's Medical Center, Shanghai Jiao Tong University School of Medicine, Shanghai, China., shanghai, China*

Aim: This study aimed to evaluate the efficacy and safety of a modified surgical protocol for managing hand contractures and pseudosyndactyly in pediatric patients with recessive dystrophic epidermolysis bullosa (RDEB), with an emphasis on minimizing tissue trauma, avoiding skin grafts, and optimizing postoperative recovery.

Method: A retrospective analysis was conducted on 15 RDEB children (22 procedures) undergoing syndactyly release between 2023 and 2025. The surgical technique included dissection along natural tissue planes, internal fixation using 18-gauge injection needles, and wound coverage with intraoperatively shed autologous epidermis. Outcomes were assessed via the Birmingham Epidermolysis Bullosa Severity Score (BEBSS), epithelialization time, ABILHAND-Kids questionnaire, and parental satisfaction scores.

Results: The BEBSS improved significantly from 4.18 ± 0.50 preoperatively to 0.82 ± 0.50 postoperatively ($p < 0.001$). Median epithelialization time was 17.5 days, with a trend toward faster healing in children under 8 years (14.0 vs. 17.5 days, $p = 0.08$). Parental satisfaction was high (median score: 5.0), and only one case (4.5%) exhibited recurrence within 12 months. No major complications occurred.

Conclusion: The modified graft-free surgical approach effectively corrected hand deformities in RDEB children, promoting rapid wound healing, minimizing recurrence, and improving functional outcomes. This protocol represents a safe, practical, and cost-effective strategy for managing RDEB-related hand complications.

OP110 Impact of malodor on health-related quality of life (HRQoL) of patients with chronic wounds due to volatile organic compounds (VOCs)

Clara Nathrath[1], Univ-Prof. Dr. Ewa Klara Stürmer[1], Nicolas Krüger[1], Mandy Dittmer[1], Matthias Augustin[2], Modestus Wigger[3], Toni Maria Janke[2], Stefanie Sielemann[3], Sophie Charlotte Liegenfeld[1]

[1]Dept. of Vascular Medicine, Translational Wound Research, University Medical Center Hamburg-Eppendorf (UKE), Hamburg, Germany, *[2]Institute for Health Services Research in Dermatology and Nursing (IVDP), University Medical Center Hamburg-Eppendorf (UKE), Hamburg, Germany*, *[3]Hamm-Lippstadt University of Applied Sciences, Hamm, Germany*

Aim: Chronic wounds significantly impact health-related quality of life (HRQoL). Unpleasant wound odor, caused by bacterial colonization and necrotic processes, is a distressing symptom. Its exact composition is not well understood, but it could be the basis for a personalized odor avoidance strategy.

Method: Therefore, this feasibility study explored 92 wounds from 66 patients with the focus on wound odor, bacterial burden and their impact on health related-quality of life (HRQoL). Volatile organic compounds (VOCs) responsible for wound odors were detected at the molecular level, using gas chromatography-mass spectrometry and -ion mobility spectrometry and correlated to the HRQoL.

Results / Discussion: In patients analyzed (average age 69±13 years, wound persistence 24.31±70.8 months) 135 pathogens were identified by swabbing including 19% *Staphylococcus aureus*, 15% *Pseudomonas aeruginosa*, and 35% Enterobacteria. The specific questionnaire "Wound-QoL-14" showed a non-significant difference in HRQoL in patients with wound odor (2.1±1.0 vs. 1.8±1.0). The latter also had the highest number of VOC detections. The most frequently detected, relevant VOCs from prokaryotic sources were dimethyl-disulfide and diacetyl-(2,3-butanedione). Furthermore, potential biomarkers for specific pathogens were identified, including dimethyl-trisulfide for *P. aeruginosa* and indole for *E. coli*. The most prevalent substance groups were ketones and alcohols. In conclusion, the malodor of chronic wounds is caused by a mixture of the intrinsic odor of bacterial products and necrosis.

Conclusion: This exploratory study, which combines the analysis of decoded VOCs and the olfactory assessment of odor, could be a novel, targeted approach for identifying potential "anti-wound odor therapies" that will significantly benefit the HRQoL of patients with malodorous tumor wounds, in particular.

OP111 Lassels procedure for advanced lower extremity lymphedema

Uzay Cambaz[1], Okan Gürsoy[2], Tahsin Acartürk[1]

[1]University of Pittsburgh, Pittsburgh, United States, *[2]Istanbul University, Istanbul Faculty of Medicine, Istanbul, Türkiye*

Aim: Advanced lower extremity lymphedema often leads to debilitating volume increase and functional impairment. The LASSELS Procedure (Liposuction-Assisted Skin-Sparing Excisional Lymphedema Surgery) for Advanced Lower Extremity Lymphedema —combining liposuction with targeted skin and soft-tissue excision—was developed to reduce limb bulk, improve mobility, and achieve durable contouring in patients unresponsive to conservative therapy.

Method: Nine patients with advanced-stage lower limb lymphedema (eight unilateral, one bilateral) were included. Preoperative circumferences were measured at standardized anatomical points. The operation began with tumescent infiltration followed by circumferential liposuction, including the dorsal foot when required. Residual redundant tissue—most pronounced medially—was excised through a central medial incision. Primary closure was achieved under minimal tension; drains were used selectively. Postoperative care consisted of 4 weeks of compression therapy, 8 weeks of physiotherapy, and transition to long-term compression garments. Patients were followed for at least 12 months.

Results / Discussion: Ten limbs were operated on. Minor wound dehiscence occurred in two cases; no seroma, necrosis, or infection was observed. Limb circumference decreased significantly across all patients. Improvements in gait, mobility, and daily function were consistently reported. No recurrences or late infections occurred during follow-up. Several patients noted reduced heaviness even in non-operated areas.

Conclusion: The LASSELS procedure provides a less morbid and more functional alternative to classic operations such as Charles or Homans. By combining liposuction with controlled excision, the technique addresses limitations of liposuction-alone approaches—particularly skin redundancy—while reducing complications and improving quality of life. It represents a reliable option for carefully selected patients with advanced soft-tissue–predominant lymphedema.

OP112 Microsurgery and wound healing: A happy wedding?

Franco Bassetto[1], Carlotta Scarpa[1], Cesare Tiengo[1]

[1]*Plastic and Reconstructive Unit, Padova, Italy*

Aim: In this study, we evaluated the effectiveness of the microsurgical approach for the treatment of acute and chronic wounds.

Method: Between 2000 and 2025, we performed 76 free flaps for acute and chronic wounds of the lower extremities. Forty-two percent of patients had osteomyelitis, and in 59% of cases, the procedure was performed in combination with orthopedic therapy. After removal of the affected bone, we performed helix flaps or microsurgical flaps such as the ALT flap or the latissimus dorsi free flap. We monitored the quality of healing and function after 1 year.

Results / Discussion: Ninety-five percent of patients achieved good, stable healing over time, and good function. The remaining 5% experienced acute complications, such as thrombosis with total or partial loss of the flap, or late complications such as flap dehiscence. These late complications have been observed primarily in diabetic patients and in the heel area.

Conclusion: Although numerous advanced devices and dressings are available today to promote wound healing, they are sometimes insufficient, especially when treating patients with osteomyelitis or when achieving stable healing. The use of microsurgery can be a valuable ally for rapid and lasting wound healing.

OP113 Microsurgical management of post-traumatic lower limb defects: Outcomes of a 10-year experience

Petr Sin[1], Alica Hokynková[1], Andrea Pokorná[2], Vladimír Váňa[1 1], Tomáš Nevrtal[3]

[1]*University Hospital Brno, Czech Republic, Faculty of Medicine, Masaryk University Brno, Czech Republic, Brno, Czech Republic*, [2]*Masaryk University Brno, Czech Republic, Faculty of Medicine, Masaryk University Brno, Czech Republic, Brno, Czech Republic*, [3]*University Hospital Brno, Czech Republic, Brno, Czech Republic*

Aim: To present a structured diagnostic–therapeutic algorithm for acute and post-traumatic lower limb defects integrating systemic assessment, vascular evaluation, skeletal stability, and reconstructive decision-making within a multidisciplinary trauma-based model led by trauma surgeons.

Method: The algorithm is based on sequential evaluation of: (1) defect size and localisation; (2) exposure of deep structures; (3) skeletal integrity and need for stabilisation; (4) vascular status assessed clinically and by CT angiography; and (5) patient-related factors including age, comorbidities (diabetes, peripheral arterial disease, infection), and overall systemic condition (critical vs stabilised). Acute injuries are managed by trauma surgeons in collaboration with plastic surgeons, vascular specialists, radiologists, infectious disease experts, rehabilitation teams, and specialised wound-care nurses. When perfusion is compromised, revascularisation is prioritised before reconstruction. Wound-bed preparation includes radical debridement, infection control, and negative-pressure wound therapy. Reconstruction is selected according to defect characteristics and vascular findings: skin grafts for superficial wounds; local or regional flaps for moderate defects; and microvascular free flaps, including flow-through options when indicated, for extensive defects with exposed critical structures. Dermal substitutes may serve as staged alternatives in selected high-risk patients.

Results / Discussion: This structured pathway enables consistent decision-making in complex trauma scenarios. Early vascular assessment combined with coordinated trauma–plastic collaboration reduces delays to definitive coverage and expands limb-preserving options even in patients with significant comorbidities.

Conclusion: A trauma-driven, multidisciplinary algorithm provides a reproducible framework for managing complex post-traumatic lower limb defects, focusing on preservation of limb function and long-term quality of life.

EP352 Impact of Cockett (C1–C3) perforator vein endovenous laser ablation on recurrence prevention and ulcer healing in C6 venous disease: A comparative clinical study

Nubar Ismayilova[1], Vugar Fattah-Pur[1], Gulnar Ibrahimova[2 2]

[1]Azerbaijan State Advanced Training Institute for Doctors named by A. Aliyev, Baku, Azerbaijan, *[2]Scientific Center of Surgery named after M.A.Topchubashov, Baku, Azerbaijan*

Aim: To assess the impact of Cockett perforator EVLA, when added to standard C6 therapy (axial EVLA + miniphlebectomy), on ulcer healing time, completeness of closure, recurrence risk indicators, and duration of postoperative compression therapy.

Method: 22 CEAP C6 patients were included. All underwent EVLA of the incompetent great or small saphenous vein, combined with miniphlebectomy of tributaries. Patients were divided into two groups:Group A: Received additional EVLA of incompetent Cockett (C1–C3) perforator veins n=12, Group B: Did not undergo perforator ablation n=10. All patients received identical wound care protocols, hydrofiber or foam dressings as appropriate, and Class II–III compression therapy.

Results / Discussion: Complete ulcer healing was achieved in *all* Group A patients (100%) within a significantly shorter period (mean 6.2 ± 1.1 weeks). In contrast, only 7/10 patients (70%) in Group B achieved complete healing by week 12. The remaining 3 patients showed partial improvement but persistent ulceration, correlating directly with ongoing perforator reflux on duplex imaging. Group A required substantially shorter compression therapy (mean 5.5 weeks vs. 9.1 weeks in Group B).

Conclusion: Ablation of incompetent Cockett perforator veins significantly improves healing outcomes in C6 patients by eliminating deep-to-superficial venous hypertension. Incorporating perforator EVLA into the standard treatment algorithm leads to faster, more complete ulcer closure and reduces the need for prolonged compression therapy.

Keywords: C6, venous ulcer, perforator reflux, Cockett, EVLA, recurrence, ulcer healing

---

OP117 Sclerotherapy perforating and varicose veins as a complementary therapy for the healing of venous ulcers

Carlo Rivellini[1]

[1]AIUC, SIC, SICVE, AFI, Italy

Aim: We retrospectively analyzed patients with recurrent varicose veins, lipodermatosclerosis, and active ulceration (CEAP stages C5 and C6) treated with sclerotherapy for both refluxing perforators and varicose tributaries. The objective was to evaluate the safety of the method and its efficacy in terms of ulcer healing.

Method: Over a 4-year period, 165 patients with varicose veins, lipodermatosclerosis, and ulceration were consecutively treated (118 were hypertensive, 48 diabetic, 92 obese, and 28 with heart disease). Sclerotherapy was performed in 110 cases in the operating room on an outpatient basis, and in the remaining in an outpatient wound care clinic. All patients were treated with lauromacrogol 400 in varying concentrations depending on the case with foam. Simultaneous treatment of both limbs was performed in 27 patients, while compression with a cold tumescent solution was performed in 47 patients.

Results / Discussion: The success rate of the sclerotherapic procedure was 85% in terms of vessel obliteration; the ulcer healing rate was 92% over a period of 1 to 5 months, with a recurrence rate of 5.7% over a 12-month follow-up period. In all cases there was an improvement in the quality of life (SF-36 test).

Conclusion: Sclerotherapy of refluxing perforators and varicose tributaries has been shown to be safe and effective in treating venous reflux, even in patients with lipohermatosclerosis and ulceration. It has been shown to reduce healing times and the recurrence rate of lesions, resulting in a significant improvement in quality of life.

TRANSLATIONAL SCIENCE

OP123 The inflammatory profile of skin in incontinence-associated dermatitis compared to pressure-induced inflammation

Amanda Feldt[1 2], Peter Worsley[3], Anna Spångeus[1], Bijar Ghafouri[1], Sara Bergstrand[1]

[1]Department of Health, Medicine and Caring Sciences, Linköping University, Linköping, Sweden, *[2]Clinical Department of Acute Internal Medicine in Linköping, Region Östergötland, Linköping, Sweden*, *[3]Skin Sensing Research Group, School of Health Sciences, University of Southampton, Southampton, United Kingdom*

Aim: Differentiating incontinence-associated dermatitis (IAD) from pressure ulcers is clinically challenging, yet essential, as treatment strategies diverge. Accurate diagnosis prevents avoidable pain and delayed healing. This study uncovers molecular indicators of IAD and pressure induced inflammation, supporting future biomarker development to enable correct diagnosis. The aim was to compare the inflammatory profile in skin between incontinence associated dermatitis and pressure induced inflammation.

Method: The study included patients with stage 1 IAD (n=25) and patients receiving non-invasive ventilation therapy (n=11). Inflammatory proteins were sampled from affected skin sites and matched control sites using adhesive tape that absorbs proteins together with sebum from the skin. Protein concentrations (n=71) were quantified by U-PLEX electrochemiluminescence assay, followed by multivariate and protein network analyses.

Results / Discussion: In the IAD cohort, multivariate analysis distinguished IAD from control sites, driven by 24 proteins. Network analysis linked these proteins to chronic inflammation, macrophage activation, and defense response. In the facemask cohort, 21 proteins differentiated mechanical loading sites (nasal bridge) from controls, associated with tissue remodeling, vascular healing, cell death, and inflammation. Across cohorts, 33 key proteins (including overlaps) were compared, yielding a robust and significant multivariate model. Within this comparative model, 13 proteins were most influential in separating IAD from mechanical loading.

Conclusion: This study demonstrates distinct differences in the inflammatory profiles between IAD and pressure-induced skin inflammation, supporting future biomarker discovery. Multivariate analysis revealed clear separation between affected and control sites, confirming the reliability of local sampling using this method. Despite the small cohort, these findings open avenues for larger studies aimed at advancing molecular understanding and precision care strategies.

OP124 Laserobaria method for wound healing: Integrated dose–response modelling of ozone, UVA, PEMF, PBMT and oxygen based on in vitro fibroblast viability, biofilm suppression and real-world utilisation

Kinga Kostera[1 2], Dominik Dziadek[2 3], Magdalena Skonieczna[1]

[1]Silesian University of Technology, Gliwice, Poland, *[2]Inventmed Sp. z o.o., Świętochłowice, Poland*, *[3]Lazarski University, Warszawa, Poland*

Aim: To develop analytical frameworks identifying exposure conditions that balance antimicrobial effectiveness with tissue safety due to differing sensitivity thresholds of host fibroblasts and microorganisms. Dose optimization in the laserobaria method—O_3, pulsed electromagnetic field (PEMF), topical oxygen therapy (TOT), photobiomodulation therapy (PBMT), and UVA—was achieved by integrating dose–response relationships for fibroblast viability and biofilm reduction.

Method: Fibroblasts L929 and biofilms (*Staphylococcus aureus, Pseudomonas aeruginosa, Candida albicans*) were exposed to physical therapies. Fibroblast viability (MTT, A570) and morphology were assessed over 0–3 days after a single 30-min exposure to O_2, O_3, UVA, PBMT, and PEMF (5–100 Hz) and after graded exposures (5–25 min) to ozone and UV. Biofilms were analyzed quantitatively, metabolically and through CFU reduction in 1–3 species models. Therapeutic Synergy Index (TSI) integrated antimicrobial effectiveness with fibroblast tolerance, enabling cross-modal comparison.

Results / Discussion: Short ozone exposure increased fibroblast proliferation, whereas exposures ≥15 min caused cytotoxicity. Biofilms showed susceptibility to ozone and PEMF. Short ozone exposure combined with selected PEMF frequencies produced antimicrobial effects while preserving fibroblast safety. Metabolic activity of multi-species biofilms was reduced or transiently stimulated by individual physical factors. Sequential laserobaria protocols, including optimized dose, order and combinations of factors, produced biofilm metabolic reduction while maintaining tissue safety. Clinical data from over 5000 multimodal therapy sessions for chronic wounds confirmed operational stability and absence of adverse events. Antimicrobial effectiveness was supported by wound cultures, and observed analgesic effects indicated improved patient comfort.

Conclusion: Multimodal dose–response frameworks define therapeutic windows and support optimization of chronic wound therapy. The TSI model forms a translational bridge between in vitro findings, clinical use and therapeutic algorithms.

OP125 Probiotics as a game-changers for topical wound care: Activity against different pathogens and their biofilms

Oksana Gerulis[1], Marta Putrinš[1], Tanel Tenson[2], Karin Kogermann[1]

[1]*Institute of Pharmacy, University of Tartu, Tartu, Estonia*, [2]*Institute of Technology, University of Tartu, Tartu, Estonia*

Aim: To (1) evaluate the antimicrobial activity of *L. plantarum* Fibro 1 and *L. rhamnosus* Fibro 2 against common wound pathogens, and (2) assess their ability to inhibit and disrupt *S. aureus* DSM 2569 biofilms under wound-like conditions, and comparisons across different assay setups.

Method: Antimicrobial activity of probiotics against *E. coli* DSM1103, *S. aureus* DSM2569, *P. aeruginosa* DSM1117, *P. aeruginosa* PAO1 and *S. epidermidis* DSM28319 were determined using an agar overlay assay. Biofilm inhibition was examined by co-culturing *S. aureus* DSM2569 with probiotics in wound-environment–mimicking medium. To assess disruption of established biofilms, mature 24-h *S. aureus* biofilms (10E7) were treated with probiotic suspensions (10E6) in different volumes of medium (250 or 500 µL) for an additional 24-h. Viability was quantified by plate counts.

Results / Discussion: Both probiotic strains exhibited antimicrobial activity against all tested pathogens, with the strongest effect observed against *P. aeruginosa* PAO1. Lactobacilli significantly inhibited *S. aureus* biofilm formation, achieving bacterial count reductions of up to 2.5 $\log_{10}$ relative to controls ($p < 0.01$). In mature biofilms, treatment in a smaller medium volume (250 µL) resulted in an approximately 1.5-$\log_{10}$ reduction ($p < 0.05$) in bacterial count, whereas treatment in 500 µL showed no measurable effect. Comparative assays demonstrated higher efficacy in preventing biofilm formation than in disrupting established biofilms.

Conclusion: *L. plantarum* Fibro 1 and *L. rhamnosus* Fibro 2 displayed broad antimicrobial activity and notable anti-biofilm effects against *S. aureus* DSM2569, particularly during biofilm formation. These results support the potential of probiotics as topical antimicrobials for chronic wound management and underscore the importance of standardized testing methods.

Acknowledgments: Estonian Research Council PRG1507; Prof. Marika Mikelsaar funding, Doctoral mobility grant.

OP127 Evaluating the impact of umbilical cord–derived mesenchymal stem cell exosome therapy on the wound microenvironment in diabetic foot ulcers

Guzin Aygun[1], Cilga Ecem Lamba[1], Hamdullah Yanik[2], Buse Irem Koc[1], Meltem Hizal[1], Muhammed Emin Birgun[1], Mehmet Mert Hidiroglu[1], Kerim Bora Yilmaz[3]

[1]Department of General Surgery, University of Health Sciences, Gulhane Training and Research Hospital,, Ankara, Türkiye, *[2]Department of Basic Oncology, Cancer Institute, Hacettepe University, Ankara, Türkiye*, *[3]Department of General Surgery, University of Health Sciences, Gulhane Training and Research Hospital,, Department of Medical and Surgical Research, Institute of Health Sciences, Hacettepe University,, Ankara, Türkiye*

Aim: Mesenchymal stem cell–derived exosomes promote cell proliferation through cytokines and growth factors while limiting oxidative stress–related apoptosis. They also reduce inflammation, support angiogenesis and cell migration, contribute to collagen deposition, and influence macrophage polarization, thereby affecting chronic wound healing. This study evaluated the effects of exosome therapy on the chronic wound microenvironment and clinical outcomes in patients with diabetic foot ulcers.

Method: Twelve diabetic foot patients who developed postoperative tissue defects and received exosome therapy were included. Tissue samples collected before and after treatment were analyzed by flow cytometry. Wound sizes and healing duration were recorded during follow-up.

Results / Discussion: Flow cytometric analysis demonstrated an increase in M1 (CD38) and M2 (CD209) macrophages in wound tissue after treatment. A reduction in wound size was accompanied by measurable increases in myeloid and lymphoid cell populations. Among myeloid subsets, monocytes, neutrophils, and $CD4^+$ T lymphocytes increased, whereas B lymphocyte counts did not show a significant change. These findings indicate that exosome administration was associated with alterations in cell distribution and macrophage phenotype within the chronic wound microenvironment.

Conclusion: Mesenchymal stem cell–derived exosome therapy was associated with changes in granulation, epithelialization, immune cell profiles, and macrophage polarization in chronic diabetic wounds. The findings obtained in this study suggest that exosomes affected both cellular composition and inflammatory–reparative balance in the wound microenvironment in patients with diabetic foot ulcers.

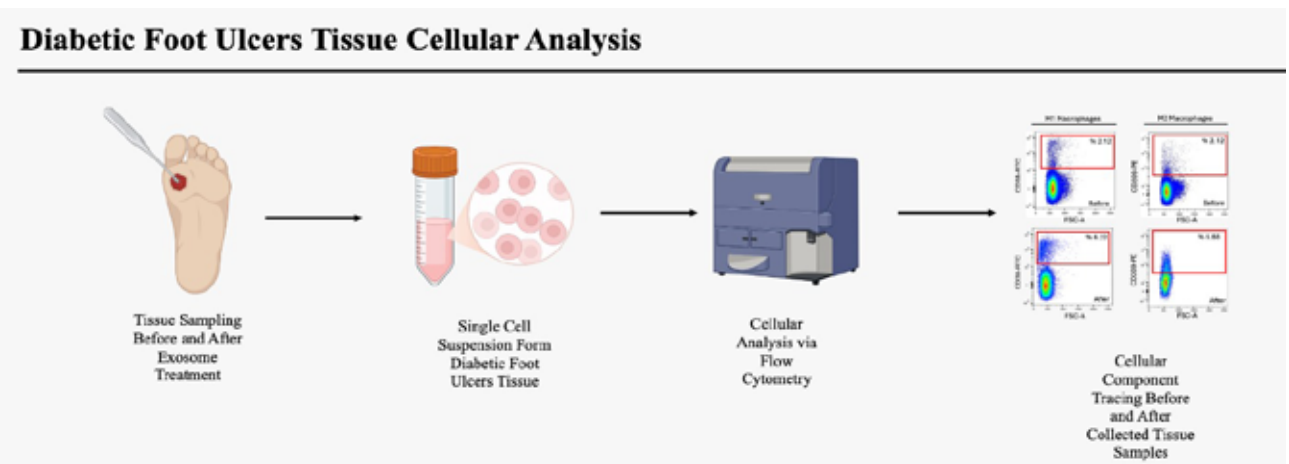

Figure 1. Diabetic Foot Ulcers Tissue Cellular Analysis

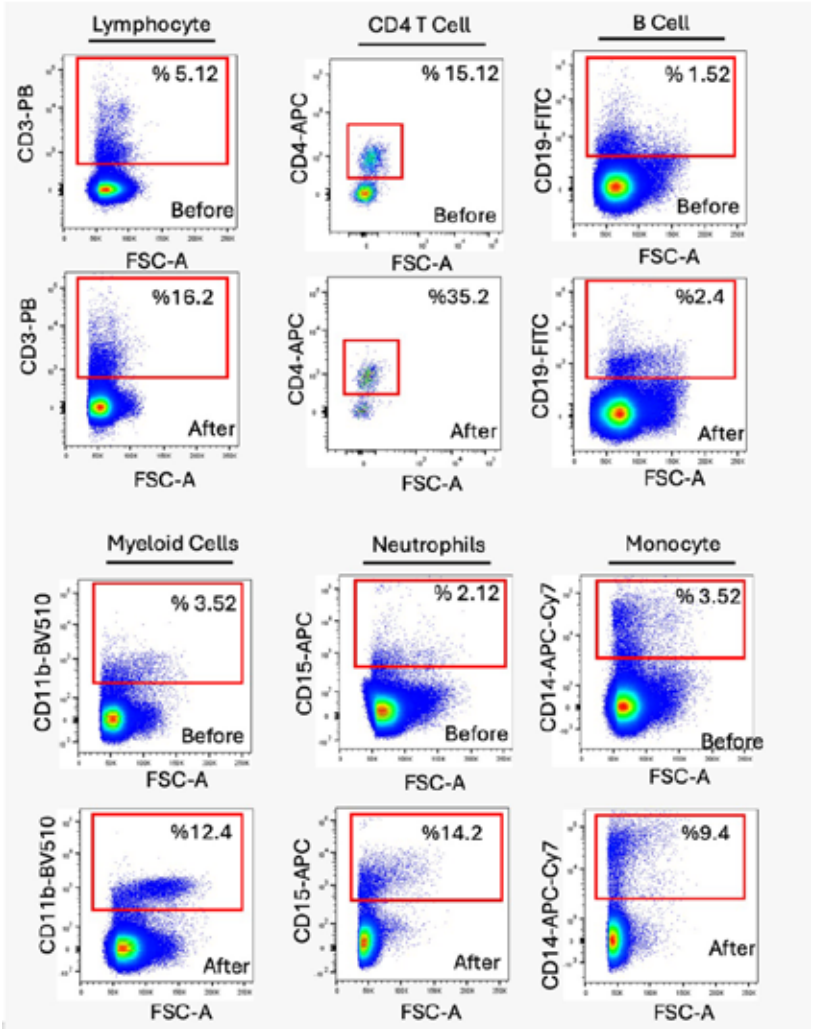

Figure 2. Immune Cell Profile Changes Observed By Flow Cytometry Following Exosome Therapy



Figure 3. Wound healing progression with exosome therapy

OP121 Proteomic patterns in acute and chronic wounds: Unveiling molecular insights for diagnostic and therapeutic strategies

Julian-Dario Rembe[1], Jan-Wilm Lackmann[2], Matthias Augustin[3], Prof. Dr. Joachim Dissemond[4], Wiebke Ibing[1], Kristian Wende[5], Hubert Schelzig[1], Univ-Prof. Dr. Ewa Klara Stürmer[6]

[1]University Hospital Duesseldorf, Heinrich-Heine University (HHU), Düsseldorf, Germany, *[2]Cologne Excellence Cluster for Cellular Stress Responses in Aging-Associated Diseases (CECAD), University of Cologne, Cologne, Germany, Cologne, Germany*, *[3]Institute for Health Services Research in Dermatology and Nursing Professions (IVDP), University Medical Center Hamburg-Eppendorf (UKE), Hamburg, Germany*, *[4]Department of Dermatology, Venereology and Allergology, Essen University Hospital, Essen, Germany*, *[5]ZIK plasmatis, Leibniz Institute for Plasma Science and Technology (INP), Greifswald, Germany*, *[6]Clinic and Polyclinic for Vascular Medicine, University Heart and Vascular Center, University Medical Center Hamburg-Eppendorf (UKE), Hamburg, Germany*

Aim: Chronic wounds remain a global clinical challenge driven by unresolved inflammation, dysregulated proteolysis, oxidative stress and impaired transition into regenerative phases. This study aimed to elucidate proteomic distinctions between acute and chronic wounds across six clinical entities, identify core versus entity-specific molecular signatures, and determine proteomic markers linked to healing trajectories.

Method: In this wound proteome investigation, wound exudates from 79 patients were analyzed using standardized swab collection followed by bottom-up LC-MS/MS proteomics (Orbitrap Exploris 480). Protein identification and quantification were performed via MaxQuant with LFQ and statistical validation (FDR ≤ 0.05). Data visualization involved PCA, hierarchical clustering, volcano plots, and pathway enrichment (ORA, GSEA). Chronic wounds were stratified by entity (VLU, ALU, MIX, PG, WHD) and healing status.

Results / Discussion: Proteomic separation of acute and chronic wounds was evident on PCA with minimal overlap, identifying 186 differentially abundant proteins. Acute wounds demonstrated enrichment of coagulation, cytoskeletal regulation and complement activation, while chronic wounds showed significantly elevated neutrophil-associated proteins, DAMP/PAMP signatures, NETosis-related mediators, and MMP-driven proteolysis (e.g., MMP8, MMP9). Entity profiling revealed unique signatures: PG with inflammatory cell-death markers (GSDMD, PYCARD), VLU with oxidative stress and antimicrobial peptide dominance, and WHD with epidermal barrier-linked proteins. Importantly, CRP emerged as the only significantly increased marker in non-healing wounds, suggesting its relevance in chronic inflammatory fixation.

Conclusion: The study highlights distinct proteomic landscapes underpinning acute versus chronic healing responses and reveals chronicity-defining networks driven by neutrophilic persistence, excessive proteolysis and inflammatory cell-death pathways. Entity-specific proteomic fingerprints underscore the need for precision-stratified wound therapeutics. CRP emerges as a key indicator of non-healing status, supporting its potential as a clinically relevant biomarker for chronic inflammation surveillance.

OP122 Immunomarker profiling in human chronic wound swabs reveals IL-1 beta/IL-1RA and CXCL8/CXCL10 ratios as potential biomarkers for wound healing, infection status and regenerative stage

Julian-Dario Rembe[1], Waseem Garabet[1], Matthias Augustin[2], Prof. Dr. Joachim Dissemond[3], Wiebke Ibing[1], Hubert Schelzig[1], Univ-Prof. Dr. Ewa Klara Stürmer[4]

[1]University Hospital Duesseldorf, Heinrich-Heine University (HHU), Düsseldorf, Germany, *[2]Institute for Health Services Research in Dermatology and Nursing Professions (IVDP), University Medical Center Hamburg-Eppendorf (UKE), Hamburg, Germany*, *[3]University Hospital Essen, Essen, Germany*, *[4]Clinic and Polyclinic for Vascular Medicine, University Heart and Vascular Center, University Medical Center Hamburg-Eppendorf (UKE), Hamburg, Germany*

Aim: Persistent inflammation and impaired tissue remodeling are common in chronic wounds. Traditional diagnostic methods, including visual inspection and microbiological cultures, offer limited insight into the wound micro-environment. Immunomarker profiling could provide a deeper understanding of the molecular mechanisms

underpinning wound healing, offering potential biomarkers for infection status and healing progression.

Method: This observational, multi-center cohort study, part of the 'Wound-BIOME' project, analyzed 110 swab samples from patients with acute and chronic wounds using multiplex immunoassays. Clinical parameters such as wound type, healing status, regeneration stage, and microbial burden were recorded. Total protein concentration was assessed, and 35 key immunomarkers, including cytokines (e.g. IL-1α, IL-1β), chemokines (CCL2, CXCL8, CXCL10), growth factors (FGF-2, VEGF) and matrix metalloproteinases (MMP-7, MMP-9, MMP-13), were quantified. Statistical analyses were performed to correlate immunomarker levels with clinical outcomes.

Results / Discussion: Pro-inflammatory markers, such as IL-1β, IL-18 and chemokines like CCL2 and CXCL8, were significantly elevated in non-healing and infected wounds compared to healing wounds. The study identified two new immunomarker ratios – IL-1β/IL-1RA and CXCL8/CXCL10 – as potential predictors of wound healing status. The IL-1β/IL-1RA ratio showed the highest accuracy for distinguishing healing from non-healing wounds (AUC=0.6837), while the CXCL8/CXCL10 ratio was most effective in identifying infection (AUC=0.7669).

Conclusion: Immunomarker profiling via wound swabbing offers valuable insights into the wound healing process. Elevated levels of pro-inflammatory cytokines and MMPs are associated with chronic inflammation and impaired healing. The IL-1β/IL-1RA and CXCL8/CXCL10 ratios emerge as promising biomarkers to distinguish between infection and inflammation, with potential in targeted wound care. Further studies are needed to validate these findings and implement them in clinical practice.

WOUND ASSESSMENT

OP130 Development and validation of woundpilot: A clinical decision support system for hard-to-heal-wound management

Steven Smet[1 2], Beele Hilde[1 3], Dimitri Beeckman[2 4]

[1]Wound Care Center, Ghent University Hospital, Ghent, Belgium, *[2]Skin Integrity Research Group (SKINT), University Centre for Nursing and Midwifery (UCVV), Ghent, Belgium*, *[3]Department of Dermatology, Ghent University Hospital, Ghent, Belgium*, *[4]Swedish Centre for Skin and Wound Research (SCENTR), Örebro University, Örebro, Sweden*

Aim: This study aimed to develop and validate a computerized clinical decision support system (CDSS) for managing hard-to-heal wounds in primary care. The system is designed to standardize assessment, guide treatment planning, and reduce variability in clinical practice. Although developed in [placeholder], the system is intended for potential international implementation in similar primary care settings.

Method: We applied the adapted RAND/UCLA Appropriateness Method to develop and validate the CDSS. A core panel of wound care experts, including two clinical nurse specialists, one dermatologist, and one nursing professor, constructed a clinical decision support tree (CDST) based on current evidence, guidelines, and prior research. This CDST was then converted into an interactive tool. The CDSS underwent two rounds of validation with 36 wound care experts (24 in round 1, 22 in round 2) to assess the relevance and clarity of each decision node using the item-level content validity index (I-CVI).

Results / Discussion: The initial CDSS focused on systematic assessment of wound etiology, infection, wound bed, exudate, and edges. In round 1, most nodes achieved an I-CVI > 0.78, with revisions made to improve infection assessment, wound classification, and exudate definitions. In round 2, all nodes met the I-CVI threshold, confirming strong content validity. The final system, named WoundPilot, incorporated expert feedback, improved navigation, and added definitions, images, and referral guidance.

Conclusion: WoundPilot provides a structured tool for managing hard-to-heal wounds in primary care. It enhances clinical reasoning, reduces practice variability, and facilitates timely referrals. Future studies should evaluate its effectiveness in real-world settings and explore digital integration.

OP134 A study on the accuracy of resistance monitoring in assessing the healing of thoracic surgical incisions

Hongying Jin[1], Shangqing Xu[1], Xiaoyan Han[1], Huiling Li[1], Kexin Ma[1], Minjie Ma[1]

[1]*The First Hospital of Lanzhou University, Gansu University of Chinese Medicine, lanzhou, China*

Aim: To incorporate the method of resistance monitoring in assessing surgical incisions. Through continuous dynamic monitoring of the resistance values of thoracic surgical incisions and their surrounding tissues we aim to provide an objective and visual evaluation basis for the management of thoracic surgical incisions.

Methods: A total of 65 patients with thoracic surgical incisions were included as study subjects. The resistance values of the pre-incision sites one day before surgery and the resistance values of the surgical incision and its surrounding tissues from 1 to 7 days after surgery were measured. Within one month after surgery, the incisions were classified into a non-infection group with good healing and an infection group with poor healing based on the healing status.

Results: There were statistically significant differences in the resistance values of the surgical incisions between the non-infection group and the infection group on the 1st, 4th, and 7th days after surgery ($P<0.05$). The AUC values on the 1st, 4th, and 7th days after surgery were greater than 0.8, indicating good predictive performance.

Conclusion: Resistance monitoring is conducive to improving the safety of thoracic surgical incisions assessment and has certain practicality. It can be used to assess the healing status of thoracic surgical incisions

---

EP379 Assessing the utility of infrared thermography in predicting surgical site infection - a systematic review

Shreya Bhatt[1 2], Natalia Rios Turek[2], Bharadhwaj Ravindhran[1 2], Ian Chetter[1 2], Daniel Carradice[1 2], George Smith[1 2]

[1]*Academic Vascular Surgical Unit, Hull, United Kingdom*, [2]*Hull University Teaching Hospitals NHS Trust, Hull, United Kingdom*

Aim: To review the evidence for the use of infrared thermography (IRT) in predicting surgical site infections (SSI) in acute surgical wounds

Method: A systematic literature search was conducted following PRISMA guidelines (results in Figure 1) to investigate the scope of IRT in assessing acute surgical wounds. Studies focusing on chronic wounds, non-English and animal studies were excluded. Two authors independently reviewed abstracts to determine eligibility. Any discrepancies were resolved by a third reviewer. Full texts of appropriate studies were retrieved and further reviewed to ensure they met inclusion criteria. Quality assessment was conducted using the Newcastle-Ottowa Scale by two independent authors.

Results / Discussion: Twenty-one studies were identified investigating IRT and SSI of which nine cohort studies were included. Five studies investigated abdominal wounds, three studies focussed on thoracic wounds and one study looked at knee replacement wounds. Cold spots within wounds (>2 °C difference between wound and healthy reference area), as early as 24 hours postoperatively, predicted the development of SSIs subsequently (OR 2.25-2.45). Temperature differences between areas that developed infection and healthy reference areas, were statistically significant. Lower wound temperature was significantly associated with poor healing and postoperative complications ($p<0.05$).

Conclusion: Early diagnosis of surgical site infection remains challenging and current evidence demonstrates the potential of infrared thermography as an objective tool for prediction/early diagnosis of surgical site infection. Identifying wound features that predispose to SSI early in the post-operative period may direct clinical resources toward closer wound surveillance or use of additional supportive interventions for healing (eg negative pressure wound dressings, additional antibiotics). However, larger trials are needed to corroborate these findings and investigate the cause for this temperature variation.

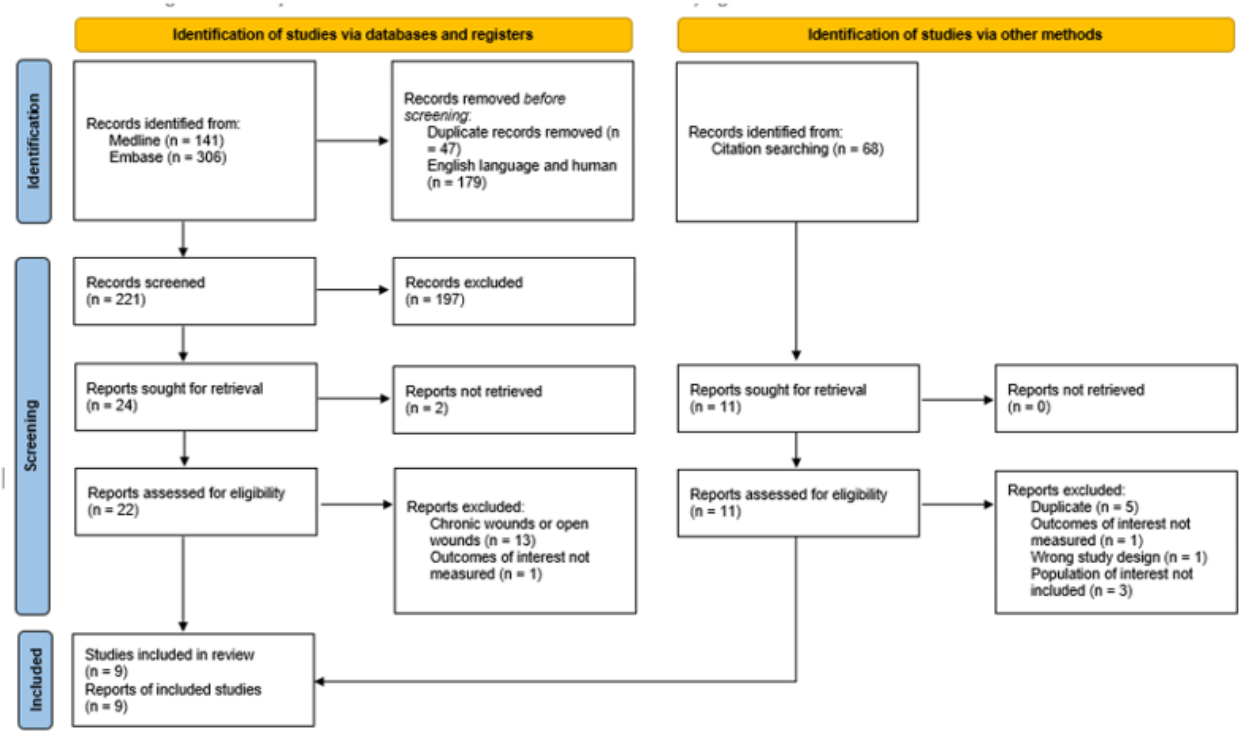

Figure 1: PRISMA flowchart detailing inclusion and exclusion of studies

OP089 The effectiveness of assessing skin changes for chronic venous insufficiency (CVI) in people with dark skin tones, and the impact on the patient journey and clinical care: A systematic review

Victoria Clemett[1], Jemell Geraghty[1], Neesha Oozageer Gunowa[2], Sue Woodward[1], Tesfamariam Aklilu Betemariam[1], Audrey Edomobi[1], Alice Milsom[1], Toby Prevost[1], Rianna John[1 3], Lukla Biasi[3]

[1]King's College London, London, United Kingdom, *[2]University of Surrey, Guildford, United Kingdom*, *[3]Guy's and St Thomas' NHS Foundation Trust, London, United Kingdom*

Aim: Variation in cutaneous manifestations of chronic venous disease across skin tones is under-explored. This review aimed to systematically identify, evaluate and synthesise the influence skin tone has on patient assessment and patient journey in people with chronic venous insufficiency (CVI).

Method: Systematic searches of MedLine, EMBASE, CINAHL, British Nursing Index, Scopus and registries of ongoing studies (ISRCTN registry, ClinicalTrials.gov) identified primary research studies, quality improvement projects or case reports published in English up to February 2025. Two reviewers independently screened, extracted data and appraised quality. (PROSPERO: CRD42023459310).

Results / Discussion: Twenty-two articles were included. Findings indicate people with dark skin tones may have venous disease related pathophysiological changes without some or all clinical presentations of venous insufficiency. This may delay diagnosis and prevent people with dark skin tones from receiving timely vascular specialist care and appropriate management in the early stages of venous hypertension. When presenting to specialists at clinics or to receive surgical interventions, people from Black ethnicity were more likely to have an active or healed venous leg ulcer (CEAP 5 & 6) than people from White ethnicity (RR = 1.39 [1.01, 1.91], z=2.04 p=0.04). Disparities in outcomes were evident. People with dark skin tones had higher treatment costs relating to their lower limb care,

more interventions and the least improvements following interventions. However, the contribution of unrecognised cutaneous vascular manifestations to these longitudinal outcomes remains unclear due to confounding factors, such as compression use.

Conclusion: Symptom-based referral for venous duplex ultrasound, supported by holistic assessment rather than visual cues, should be considered in patients with dark skin tones to reduce diagnostic delays and promote equity for patients with dark skin tones.

OP135 Measurements of pH and temperature reveal a more acidic micro-environment in acute healing vs. chronic non-healing wounds – results of a prospective, multi-center, observational cohort study

Julian-Dario Rembe[1], Mareike Witte[1], Neslihan Ertas[1], Prof. Dr. Joachim Dissemond[2], Waseem Garabet[1], Maria Hovhannisyan[1], Katharina Beckamp[1], Hubert Schelzig[1], Markus Udo Wagenhäuser[1], Univ-Prof. Dr. Ewa Klara Stürmer[3]

[1]University Hospital Duesseldorf, Heinrich-Heine University (HHU), Düsseldorf, Germany, *[2]University Hospital Essen, Essen, Germany*, *[3]Clinic and Polyclinic for Vascular Medicine, University Heart and Vascular Center, University Medical Center Hamburg-Eppendorf (UKE), Hamburg, Germany*

Aim: The local microenvironment of wounds plays a crucial role in healing, with pH and temperature emerging as promising biomarkers.

Method: This prospective, multi-center, observational study assessed pH and temperature in acute and chronic wounds to identify physicochemical patterns associated with healing. A total of 117 patients with various wound etiologies underwent 226 pH and 181 temperature measurements at the wound center, edge, and surrounding skin.

Results / Discussion: With a pH of 7.113±0.659 and 7.043±0.694, chronic and non-healing wounds exhibited significantly higher pH values than acute (6.592±0.617) and healing wounds (6.820±0.814; $p<.05$), with the wound center showing the largest difference (ΔpH=0.52). A pH gradient was observed, decreasing from wound center to surrounding skin. Longitudinal analysis revealed a weekly pH decline of 0.05 units in healing wounds. Temperature showed a similar downward trend over time, though differences between groups were less pronounced.

Conclusion: These findings indicate that progressive acidification of the wound environment correlates with healing, while alkaline pH is associated with chronicity and infection. Local pH, more so than temperature, may serve as a non-invasive, dynamic biomarker for wound monitoring and as a potential therapeutic target. Further interventional studies are warranted to evaluate pH-monitoring and potential modulation by wound therapies.

German E-poster Presentations

E-HEALTH

EP714 Evidenz von Schulungsprogrammen zur Förderung der fußbezogenen Gesundheitskompetenz bei Menschen mit Diabetes mellitus

Sarah Fabisch[1]

[1]*Medizinische Universität Lausitz - Carl Thiem, Lübben, Germany*

Ziel: Ziel war es im Rahmen meiner Bachelorarbeit, die Wirksamkeit von Schulungsprogrammen zur Förderung der fußbezogenen Gesundheitskompetenz und zur Prävention diabetischer Fußkomplikationen bei Menschen mit Diabetes mellitus zu untersuchen und hervorzuheben.

Methode: Zur Beantwortung der Forschungsfrage wurde eine systematische Literaturanalyse durchgeführt. Dabei wurden internationale Studien analysiert, die sich mit der Wirkung strukturierter Schulungsmaßnahmen auf Wissen, Verhalten und Prävention diabetischer Fußkomplikationen befassen.

Resultat / Diskussion: Die Analyse zeigt, dass strukturierte und praxisnahe Schulungsprogramme Wissen zur Fußpflege, gesundheitsförderliches Verhalten und die Prävention diabetischer Fußkomplikationen verbessern. Besonders wirksam sind Formate mit praktischen Übungen, individueller Betreuung und aktiver Beteiligung. Schulungen, die zusätzlich die Selbstwirksamkeit stärken, weisen eine nachhaltigere Wirkung auf. Die Ergebnisse betonen die Relevanz solcher Programme als Bestandteil präventiver Pflege. Pflegefachpersonen tragen wesentlich zur Wissensvermittlung und Förderung von Eigenverantwortung bei. Gleichzeitig besteht ein Mangel an langfristigen Evaluationen und wissenschaftlich begleiteten Ansätzen im deutschsprachigen Raum. Um den steigenden Bedarf zu decken, sind praxisnahe Forschung, konsequente Integration in bestehende Versorgungsstrukturen sowie eine kontinuierliche Überprüfung der Wirksamkeit erforderlich.

Schlussfolgerung: Gut konzipierte und praxisnahe Schulungsprogramme können das Wissen über Fußpflege, gesundheitsbewusstes Verhalten und die Prävention diabetischer Fußkomplikationen wirksam fördern. Besonders erfolgreich sind Trainingsformate, die praktische Übungen, individuelle Betreuung und aktive Mitarbeit einbeziehen. Programme, die zudem die Selbstwirksamkeit stärken, zeigen langfristig den größten Nutzen.

EP733 Zwischen Klinik und Alltag! Sektorenübergreifende Wundversorgung: Wirksamkeit der ambulanten Unterdrucktherapie in der poststationären Phase beim diabetischen Fuß

Alexandru Tigla[1]

[1]*Innklinikum Altötting, Gefäßchirurgie, Altötting, Germany*

Ziel: Die poststationäre Wundbehandlung stellt bei gefäßchirurgischen und insbesondere diabetischen Patienten eine entscheidende Phase des Heilungsverlaufs dar. Die Unterdruck-Wundtherapie (NPWT) ist fester Bestandteil der modernen Wundversorgung und wird zunehmend ambulant eingesetzt, um stationäre Aufenthalte zu verkürzen und gleichzeitig eine kontinuierliche Wundkonditionierung zu gewährleisten. Ziel dieser Analyse war es, die Wirksamkeit, die Heilungsdynamik und die organisatorischen Vorteile einer ambulanten NPWT im Rahmen einer strukturierten Kooperation zwischen Klinik und medizinischem Versorgungszentrum zu bewerten.

Methode: Im Jahr 2024 wurden 27 Patienten mit diabetischem Fußsyndrom (Durchschnittsalter 67 Jahre, 63 % männlich, 78 % mit PAVK) nach stationärer gefäßchirurgischer Intervention ambulant mit NPWT weiterbehandelt. Bei 33 % handelte es sich um eine erstmalige Anwendung, während 67 % bereits im stationären Bereich mit NPWT versorgt worden waren. Die ambulante Therapie wurde bei 58 % direkt am Entlassungstag, bei weiteren 31 % innerhalb der ersten Woche begonnen. Die durchschnittliche Dauer betrug 4–6 Wochen mit wöchentlichen Verbandswechseln.

Resultate / Diskussion: Nach vier Wochen ambulanter NPWT erreichten 22 % der Patienten einen vollständigen Wundverschluss. Eine deutliche Reduktion der Wundgröße wurde bei 73 % beobachtet. Innerhalb von acht Wochen wurden 52 % erneut stationär aufgenommen, um eine definitive Versorgung mittels Sekundärnaht oder Spalthauttransplantation zu erhalten. Die ambulante NPWT ermöglichte eine gezielte Wundoptimierung und damit planbare operative Bedingungen.

Schlussfolgerung: Die ambulante NPWT stellt eine effektive Bridging-Therapie dar, die eine frühzeitige Entlassung ermöglicht, ohne die Versorgungsqualität zu beeinträchtigen. Sie erleichtert die Vorbereitung der Wunde für einen zweiten, kurzen stationären Aufenthalt und verbessert sowohl organisatorische Abläufe als auch die Patientenzufriedenheit.

AKUTE WUNDEN

EP712 Eine innovative, sehr anpassbare Wundkontaktauflage ohne Textilkern: Ergebnisse einer prospektiven multizentrischen klinischen Studie (Die HEAL-Studie)

Prof. Dr. Steffan Loff[1,2], Sylvie Meaume[3]

[1]Klinikum Stuttgart, Kinderchirurgie, Stuttgart, Germany, *[1]Klinikum Stuttgart, Kinderchirurgie, Stuttgart, Germany*, *[3]Rothschild University Hospital, Geriatric Department, Paris, France*

Ziel: Bewertung der Leistung und lokalen Toleranz einer innovativen, sehr anpassbaren Wundkontaktauflage (Wundheilungsmatrix) aus Lipidokolloid-Technologie (TLC)* bei der lokalen Behandlung verschiedener Wunden.

Methode: Prospektive, multizentrische einarmige klinische Studie, durchgeführt in 23 Zentren in Frankreich. Erwachsene Patienten mit einer nicht infizierten kutanen Wunde akuten oder chronischen Ursprungs oder aufgrund von Epidermolysis bullosa (EB) in der Granulationsphase wurden vier Wochen lang mit der untersuchten Wundauflage behandelt, die durch das Fehlen eines Textilnetzes im Kern sehr flexibel ist. Der primäre Endpunkt war die relative Wundflächenreduktion (RWAR) in Woche 4.

Ergebnisse / Diskussion: 78 Patienten wurden mit postoperativen oder traumatischen Fingerwunden, Dermabrasionen/Hautrissen, Hauttransplantations-Spenderstellen, Verbrennungen, EB-Läsionen, überwiegend venösen Beinulcera oder Druckverletzungen eingeschlossen. Zu Beginn betrug die mittlere Wundoberfläche 4,2 cm^2, ohne nennenswerte Unterschiede zwischen den Wundtypen. In Woche 4 lag der mittlere RWAR zwischen 100,0% bei akuten Wunden und EB-Läsionen und 61,5% bei chronischen Wunden. Der Verband wurde alle 2±1Tage gewechselt und von medizinischen Fachkräften als ‘sehr einfach’/‘leicht’ anzubringen bei 96% der Wunden eingestuft und in 98% als ‘sehr einfach’/‘leicht’ zu entfernen, wobei das neu entstandene Gewebe zu 100% respektiert wurde, mit deutlich ähnlichen Ergebnissen bei Finger- und Handverletzungen. Patienten berichteten, dass die Verbandwechsel in 95% der Fälle schmerzfrei waren, was eine deutliche Verbesserung gegenüber den vorherigen Verbänden darstellt. Ein gutes Sicherheitsprofil wurde berichtet.

Schlussfolgerung: Diese innovative, textilnetzfreie TLC-Wundauflage fördert die Wundheilung, wird als gut verträglich beschrieben und von Patienten und medizinischem Fachpersonal sehr gut akzeptiert, entsprechend den verfügbaren Evidenzen zu anderen TLC-Verbänden, aber ihre verbesserte Anpassungsfähigkeit könnte einen zusätzlichen Nutzen für das Wundmanagement bieten.

*UrgoFit / UrgoTül Flex, Laboratoires Urgo, Frankreich

EP730 Komplexe Kraniofasziale Defekte Mit Intrakranieller Beteiligung Bei Unterschiedlicher Genese: Rekonstruktion Mit Freien Und Gestielten Lappenplastiken

Annika Schickle[1], Thiha Aung[1]

[1]*Institute for Medical Science and Engineering, Deggendorf, Germany*

Ziel: Darstellung eines standardisierten rekonstruktiven Vorgehens bei komplexen kraniofazialen Defekten bei unterschiedlicher Genese sowie Bewertung früher klinischer Ergebnisse anhand einer dreiteiligen Fallserie.

Methode: Retrospektive Analyse von drei Patienten mit ausgedehnten kraniofazialen Weichteilverletzung mit intrakranieller Beteiligung. Die initiale Behandlung folgte einem einheitlichen Stufenkonzept aus radikalem Débridement, antiseptischer Wundspülung sowie temporärer Wundkonditionierung mittels vakuumassistierter Wundtherapie (negative pressure wound therapy, NPWT). Nach stabiler Infektkontrolle wurden die Defekte zweizeitig rekonstruiert: zunächst mikrochirurgische Gefäßpräparation, anschließend Lappenplastik entsprechend Defektvolumen, Gewebekaliber und Empfängergefäßsituation. Eingesetzt wurden zwei freie Latissimus-dorsi-Lappen sowie ein gestielter Trapeziuslappen. Ergänzend erfolgte modifizierte Voll- bzw. Spalthautransplantation.

Resultat / Diskussion: In allen drei Fällen konnte nach Sepsiskontrolle und NPWT eine definitive Weichteildeckung erzielt werden. Der gestielte Trapeziuslappen verlief komplikationsfrei und ermöglichte eine Wiedererlangung der Alltagsfähigkeit. Ein freier Latissimus-dorsi-Lappen verlief intraoperativ ohne Auffälligkeiten, jedoch trat postoperativ eine Superinfektion auf welches in der folgenden Operation mit NPWT saniert werden konnte. Der zweite freie Latissimus-dorsi-Lappen zeigte keine intraoperativen Komplikationen; eine Keimbesiedelung am Lappen wurde identifiziert und operativ erfolgreich mit NPWT behandelt.

Schlussfolgerung: Komplexe kraniofaziale Defekte mit kraniofasziale Beteiligung bei unterschiedlicher Genese erfordern ein klar definiertes, multidisziplinäres Behandlungskonzept. Die Kombination aus radikaler Infektsanierung, standardisierter Wundkonditionierung mittels NPWT und präziser mikrovaskulärer Rekonstruktionen bilden die Grundlage für ein belastbares Outcome dar. Freie und gestielte Lappenplastiken stellen effektive Optionen dar.

EP734 Autologe Behandlung postoperativer Wunden nach Revisionsoperationen in der Gefäßchirurgie mit klinischen und ökonomischen Vorteilen

Sandra Fraund-Cremer[1], Irma Kasic[1]

[1]*UKSH-Kiel, Klinik für Gefäßchirurgie und endovaskuläre Chirurgie, Gefäßchirurgie, Kiel, Germany*

Ziel: Der Studie war zu untersuchen, wie die autologe Behandlung postoperativer Wunden nach Revisionsoperationen in der Gefäßchirurgie das Wundheilungstempo beschleunigen, das Wachstum von Heilungsfaktoren fördern und Komplikationen reduzieren kann. Zusätzlich wurde der ökonomische Nutzen durch verkürzte stationäre Aufenthalte und früheren Übergang zur ambulanten Betreuung bewertet.

Methode: In die Studie wurden 20 Patienten mit postoperativen Wunden nach Gefäßrevisionsoperationen eingeschlossen, alle mit Begleiterkrankungen wie Diabetes mellitus und peripherer arterieller Verschlusskrankheit. Die Wunden wurden mit autologem Material behandelt, das an die verschiedenen Phasen der Wundheilung angepasst war. Der Verlauf wurde anhand klinischer Befunde, Laborparametern, Infektionszeichen und Therapieanpassungen überwacht. Die Behandlung begann stationär und wurde anschließend ambulant unter sicherer Aufsicht fortgeführt.

Resultat / Diskussion: Bei allen Patienten wurde eine vollständige Wundheilung erreicht, im Durchschnitt innerhalb von drei Monaten, bei einigen Patienten schneller. Es traten keine relevanten Komplikationen auf, und keine erneuten chirurgischen Eingriffe waren erforderlich. Die verkürzte stationäre Behandlung ermöglichte eine sichere und frühere ambulante Betreuung.

Schlussfolgerung: Die autologe Behandlung postoperativer Wunden in der Gefäßchirurgie ist eine sichere und effektive Methode, insbesondere bei Patienten mit Begleiterkrankungen. Sie fördert eine schnellere Wundheilung, reduziert Komplikationen und verringert Behandlungskosten. Die Ergebnisse unterstützen eine breitere Anwendung und Standardisierung dieser Therapie.

ATYPISCHE WUNDEN

EP705 Wundversorgung in der septisch-plastischen Chirurgie Wundkonzept Übergabe aus dem OP auf die Station

Stefan Langer[1], Rima Nuwayhid[1], Simon Heister[1], Olga Kurow[1]

[1]*Universität Leipzig, Medizinische Fakultät, Klinik für Orthopädie, Unfallchirurgie und Plastische Chirurgie, Leipzig, Germany*

Ziel: Septische Defektwunden sind eine Herausforderung in der Patientenversorgung. Die Therapiekonzepte sind multimodal und umfassen innovative operative Techniken aus der plastischen und rekonstruktiven Chirurgie. Die Anwendung von antiseptischen Wundprodukten vor, während und nach der chirurgischen Versorgung sowie die kluge Auswahl von systemischen Antibiosen ist Bestandteil des Behandlungsprotokolls. In der interdisziplinären Zusammenarbeit mit medizinischen Disziplinen und Wundheilungsexperten können meist die betroffenen Extremitäten somit häufig erhalten und eine patientenfreundliche Versorgung ermöglicht werden. Die Weiterführung der antiseptischen Wundbehandlung auf Station muss gewährleistet sein.

Methode: Vorgestellt werden anspruchsvolle Wunddefekte nach Infektion, Tumorbestrahlung und anderen Komplikationen an den Extremitäten und dem Brustbereich aus dem Universitätsklinikum Leipzig. Die Entfernung aller Nekrosen durch ein „radikales Debridement“ und antiseptische Vorbereitung mit zertifizierten Wundprodukten ist Voraussetzung für den plastischen Wundverschluss. Im Management für moderne, insbesondere freie Lappentransplantate kommen Wundprodukte, meist hypochlorige Säure (Lavanox®) oder auch ein antiseptischer Schutz (meist PVP-Iod, Salbe) zum Einsatz. Auch nach der operativ-plastischen Therapie müssen die chirurgischen Ergebnisse antiseptisch weiterbehandelt werden, um eine Re-Etabilierung eines Biofilms zu vermeiden. Demonstriert werden Beispiele für den Einsatz moderner Wundprodukte (VAC, Instill, antiseptische Verbände) vor, im OP und nach der Operation von Lappenplastiken.

Resultat / Diskussion: Die moderne plastisch-rekonstruktive Chirurgie kann unter Anwendung antiseptischer Spül- und Wundprodukte helfen, aufwändige Wunden, die in der konservativen Therapie keine Chance auf Heilung haben, zu verschließen.

Schlussfolgerung: Hierzu ist die Zusammenarbeit des Wundteams auf der Station, dem Chirurgen und weiteren Behandlern nötig. Sowohl vor und nach plastischer Rekonstruktion meist mit Lappenplastiken ist die Behandlung mit antiseptischen Produkten erforderlich. Die entsprechenden Protokolle werden hier dargestellt und sollten im klinischen Alltag bei dem anspruchsvollen Patientenkollektiv Anwendung finden.

EP720 Wundtherapie bei Neugeborenen

Luzie Maier-Hasselmann[1]

[1]*Evelina London Children's Hospital, London, United Kingdom*

Ziel: Die Wundversorgung bei Neugeborenen stellt aufgrund der spezifischen Eigenschaften der Haut, speziellen physiologischen Besonderheiten der Wundheilung und auch des Mangels an Leitlinien und Empfehlungen eine besondere Herausforderung dar.

Methode: Anhand des Falles eines frühgeborenen Jungen mit einer ausgeprägten Wundheilungsstörung an einer peristomalen Wunde werden die besonderen Eigenschaften der neonatalen Haut im Unterschied zur Haut Erwachsener beschrieben und unterschiedliche Therapieansätze vorgestellt.

Resultat / Diskussion: Da es nur so gut wie keine evidenzbasierten Empfehlungen zur Wundtherapie dieser hochvulnerablen Patientengruppe gibt und Standardwundprodukte häufig off-label für diese Kinder verwendet werden, ist der Austausch über die Behandlungsformen im Rahmen von Fachkongressen eine Möglichkeit, Evidenz zu generieren. Ich möchte die Unterschiede zwischen der Haut von Frühgeborenen, Neugeborenen und Erwachsenen verdeutlichen und aufzeigen, welchen Einfluss diese Unterschiede auf die lokale Wundbehandlung nehmen.

Schlussfolgerung: Die neonatale Haut ist physiologisch unreif und ihre Entwicklung setzt sich nach der Geburt fort, nicht nur in ihrer strukturellen Beschaffenheit, sondern auch in ihren immunologischen Funktionen. Diese fortschreitende Reifung führt zu dynamischen Veränderungen der Hautmerkmale, die die Auswahl geeigneter lokaler Anwendungen beeinflussen.

EP722 Tyrothricin stärkt die kutane Abwehr durch eine effiziente, antibakterielle Aktivität und Induktion körpereigener antimikrobieller Peptide

André Rademaekers[1], Regine Gläser[2], Franziska Rademacher[2], Valentin Seega[2], Tom Lennart Brauckmann[2], Nina Heinemann[2], Jürgen Harder[2]

[1]Preclinical Research, Niederdorfelden, Germany, *[2]Universitätsklinik Schleswig-Holstein, Klinik für Dermatologie, Fachbereich Dermatologie, Kiel, Germany*

Ziel: Bakterielle Infektionen führen häufig dazu, dass Wunden langsamer und nicht vollständig heilen, was das Risiko für Morbidität und Mortalität deutlich erhöht. Wir haben die Aktivität des antimikrobiellen Peptids (AMP) Tyrothricin gegenüber verschiedenen *Staphylococcus aureus*-Stämmen untersucht und gleichzeitig in Langzeitstudien die Resistenzbildung gegen Tyrothricin getestet. Weiterhin wurde untersucht, inwiefern Tyrothricin die Expression körpereigener AMP's, z.B. RNAse 7, beeinflusst.

Methode: A: 31 *S. aureus*-Klinikisolate wurden mit Tyrothricin inkubiert und anschließend wurde das bakterielle Wachstum ermittelt. B: Humane Keratinozyten und verletzte *ex vivo*-Haut wurden mit einem *S. aureus*-Isolat infiziert und mit Tyrothricin inkubiert. Koloniebildende Einheiten (CFU) wurden durch Ausplattieren serieller Verdünnungen bestimmt. C: Keratinozyten und verletzte *ex vivo*-Haut wurden in An- und Abwesenheit eines bakteriellen Überstandmixes von Hautkommensalen gesunder Haut mit Tyrothricin inkubiert und die RNAse 7-Expression mittels Realtime-PCR analysiert. D: In einem MIC-Test (MIC = minimale Hemmkonzentration) mit 40 Passagen eines *S. aureus*-Wundisolates, das sublethalen Tyrothricinkonzentrationen ausgesetzt war, wurde eine mögliche Resistenzbildung untersucht. Als Kontrolle diente Na-Fusidat.

Resultat / Diskussion: Tyrothricin konnte bereits in geringen Konzentrationen alle 31 getesteten Bakterienisolate effektiv abtöten. Auch in infizierten Keratinozytenkulturen und auf humaner *ex vivo*-Haut wurden Staphylokokken effizient eliminiert. Weiterhin konnte gezeigt werden, dass Tyrothricin in Keratinozytenkulturen und auf *ex vivo*-Haut die Expression von RNAse 7 hochsignifikant steigerte. Dieser Effekt konnte in Anwesenheit eines Bakterienüberstandmixes weiter verstärkt werden. Im Langzeitresistenztest zeigte das *S. aureus*-Klinikisolat keine Anzeichen einer Resistenz gegenüber Tyrothricin. Gegen Na-Fusidat bildete sich bereits ab der 4. Passage eine hohe Resistenz aus.

Schlussfolgerung: Tyrothricin ist hochwirksam gegen *S. aureus*-Stämme. Durch Reduktion des bakteriellen Wachstums und Induktion weiterer körpereigener AMP's wird die kutane Abwehr gesteigert bei ausbleibender Resistenz. In Zeiten zunehmender Antibiotikaresistenzen können AMP's somit wertvolle therapeutische Ansätze liefern.

GRUNDLAGENWISSENSCHAFT

EP725 Partizipative Digitalisierung: Implementierung einer mobilen Bedside-Wunddokumentation

Katerina Preemann[1], Julian Seidel[2 3], Anna Brinker[2], Ole Janz[2]

[1]Pius-Hospital Oldenburg, Oldenburg, Germany, *[2]Pius-Hospital Oldenburg, Universitätsklinik für Visceralchirurgie, Oldenburg, Germany*, *[3]Carl von Ossietzky Universität Oldenburg, Pflegewissenschaft, Oldenburg, Germany*

Ziel: Ziel ist die Ablösung isolierter Dokumentationsschritte durch eine intuitive, mobile Bedside-Lösung. Fokus liegt auf einem gesamtheitlichen Ansatz: Von der Finanzierung über die Krankenhausinformationssystem (KIS)-Integration bis zu automatisierten Wundberichten. Angestrebt wurden Qualitätssteigerung und Effizienz durch Reduktion des Dokumentationsaufwands sowie die Aktualisierung der Wundtherapie-Standards.

Methode: Für dieses Optimierungsprojekt wurde ein interdisziplinäres Team berufen, bestehend aus der IT-Bereichsleitung, einem Fachtherapeuten Wunde und einer akademisierten Pflegefachperson. Der Prozess startete mit einer Ist-Analyse der finanziellen (u. a. Krankenhauszukunftsgesetz/KHZG) und technischen Rahmenbedingungen. Nach Ist-Analyse und erfolgreicher KHZG-Fördermittelzusage wählte das Team einen partizipativen Ansatz: Stakeholder (IT, Pflege, Medizin, Hygiene, Hersteller, Technik) definierten gemeinsam den Soll-Prozess und aktualisierten fachliche Inhalte. Nach Auswahl hygienekonformer Tablets erfolgte die Anpassung der Software-Usability. Ziel bei der Software-Usability war eine intuitive Menüführung, die sich konsequent an der klinischen Versorgungslogik orientiert. Die Implementierung begleiteten ein hybrides Schulungskonzept (Online/Präsenz) sowie verstärkter Rollout-Support.

Resultat / Diskussion: Trotz erhöhtem Vorbereitungsaufwand führte die frühzeitige Einbindung der Endnutzer*innen zu hoher Akzeptanz und intuitiven Workflows. Durch die Kooperation des interdisziplinären Teams konnten Risiken bei der Umsetzung präventiv minimiert werden. Zum Rollout waren bereits 60 % der Mitarbeitenden geschult. Die Einführung der mobilen Lösung und die Zusammenführung der Arbeitsschritte reduzierten die Dokumentationszeit um 50 %, während die automatisierte Berichterstellung die interne und externe Kommunikation signifikant verbesserte.

Schlussfolgerung: Digitalisierung erfordert Partizipation. Das Projekt zeigt, dass technische Innovation nur bei Orientierung an klinischen Prozessen gelingt. Durch die Einbindung aller Berufsgruppen wird aus einer technischen Umstellung ein messbarer Qualitätsgewinn, beispielsweise in Form eines verringerten Dokumentationsaufwands. Zukünftige Innovationen wie KI-gestützte Wunddiagnostik können hierauf aufbauen. Prozesse in der direkten Patient*innenversorgung sollten daher stets unter Digitalisierungsaspekten betrachtet werden, um analoge Hürden durch anwenderfreundliche, digitale Lösungen nachhaltig abzulösen.

VERBRENNUNGEN

EP721 Behandlung von Komplikationen der Elektrochirurgie mit Polylactid-Dermalmembran: Fallserie

Victor Loza-González[1], Mario Aurelio Martínez-Jimenez[2], Ana Lorena Novoa-Moreno[3], Nicolò Ceresini[4], Eleazar Samuel Kolosovas-Machuca[5], Jose Ramirez-Garcialuna[6]

[1]Institutional Doctorate of Engineering and Materials Science of the Autonomous University of San Luis Potosí, San Luis Potosi, Mexico, *[2]Medicine Faculty of the Autonomous University of San Luis Potosí, San Luis Potosí, Mexico*, *[3]Burn Unit of the High Specialty Regional Hospital "Ignacio Morones Prieto", San Luis Potosí, Mexico*, *[4]Università degli Studi di Parma, Parma, Italy*, *[5]Coordination for the Innovation and Application of Science and Technology (CIACYT), Autonomous University of San Luis Potosí, San Luis Potosí, Mexico*, *[6]Division of Experimental Surgery, Faculty of Medicine, McGill University, Montreal, QC, Canada*

Ziel: Ziel war die Bewertung des Heilungsverlaufs und der perilesionalen Temperaturdynamik bei elektrochirurgisch bedingten thermischen Hautverletzungen unter Anwendung einer synthetischen Polylactid-Dermalmembran.

Methode: In dieser Fallserie werden drei Patienten mit elektrochirurgisch bedingten thermischen Verletzungen der Haut nach der Anwendung eines monopolar geführten Geräts beschrieben. Nach initialer Reinigung der betroffenen Areale wurde eine Polylactid-Membran direkt auf das Wundbett aufgelegt. Die weitere Versorgung erfolgte ambulant durch wöchentliche klinische Kontrollen, Wundbehandlungen mit Polylactid-Hautersatz sowie thermographische Überwachung der Wunde und des periläsionalen Hautareals.

Resultat / Diskussion: Bei allen drei Patienten zeigte sich eine vollständige Epithelisierung innerhalb von 12 Wochen ohne Hinweise auf Chronifizierung oder Infektion. Die thermographischen Messungen ergaben initial einen perilesionalen Temperaturunterschied von bis zu 2.5 °C, der sich im Verlauf sukzessive normalisierte. Nach Abschluss der Wundheilung lag der Vancouver Scar Score zwischen 2 und 5 Punkten. Funktionelle Einschränkungen traten nicht auf.

Schlussfolgerung: Die Anwendung der Polylactid-Membran stellt eine effektive und gut verträgliche Option zur Behandlung akzidenteller thermischer Hautschädigungen infolge elektrochirurgischer Eingriffe dar und kann eine operative Rekonstruktion in ausgewählten Fällen vermeiden.

EP728 Elektrische Verbrennung des Thorax mit Freilegung der Rippenbögen, behandelt durch den Einsatz von Polymilchsäure zur Optimierung der Pleuragranulation sowie anschließender Hauttransplantation

Mario Aurelio Martínez-Jimenez[1], Ana Lorena Novoa-Moreno[1], Victor Loza-González[2], Eleazar Samuel Kolosovas-Machuca[3], Jose Ramirez-Garcialuna[4]

[1]Burn Unit of the High Specialty Regional Hospital "Ignacio Morones Prieto", San Luis Potosí, Mexico, *[2]Institutional Doctorate of Engineering and Materials Science of the Autonomous University of San Luis Potosí, San Luis Potosi, Mexico*, *[3]Coordination for the Innovation and Application of Science and Technology (CIACYT), Autonomous University of San Luis Potosí, San Luis Potosí, Mexico*, *[4]Division of Experimental Surgery, Faculty of Medicine, McGill University, Montreal, QC, Canada*

Ziel: Polymilchsäure (PLA) ist ein biologisch abbaubares, hydrolysiertes, resorbierbares, mikroporöses Polymer (70–150 µm), das die Schutzeigenschaften des menschlichen Epithels nachahmt, indem es bei Körpertemperatur an der Wundfläche haftet. Es reguliert Feuchtigkeit, transportiert Exsudat ab, fördert den Gasaustausch, erhält die mechanische Stabilität und reduziert Nekrosen – essenzielle Eigenschaften bei komplexen Verletzungen mit freiliegendem Knochen. Ziel dieser Arbeit ist die Evaluierung des Einsatzes von PLA bei komplexen elektrischen Verbrennungen.

Methode: Ein 24-jähriger Patient wurde nach einem Sturz auf eine 10.000-Volt-Hochspannungsleitung eingeliefert und erlitt Verbrennungen dritten und vierten Grades im rechten lateralen Thoraxbereich durch Funkenbildung. Ein chirurgisches Débridement in der ersten Woche zeigte eine Freilegung der zweiten bis siebten Rippe. In der zweiten Woche führte ein erneutes Débridement zur Freilegung des Brustfells aufgrund muskulärer Nekrose im Bereich des 4.–6. ICR. Anschließend wurde die gesamte Wunde mit einer Polymilchsäure-Matrix abgedeckt, um eine zweizeitige Defektdeckung zu ermöglichen.

Resultat / Diskussion: Die Applikation von Polymilchsäure führte zu einer deutlichen Verbesserung der Granulation des Brustfells und zur Stabilisierung seiner Struktur, wodurch die korrekte Rippenbeweglichkeit erhalten blieb. In der dritten Woche wurde daher transplantiert. Nach erfolgreicher Einheilung erfolgte in der sechsten Woche die Entlassung zur pulmonalen Rehabilitation. Die Nachuntersuchung nach acht Monaten zeigte einen stabilen Zustand ohne Komplikationen. Die vollständige Deckung der dritten und vierten Rippe steht noch aus und erfolgt schrittweise.

Schlussfolgerung: Polymilchsäure ist eine ausgezeichnete Option zur Förderung der Granulationsbildung in schlecht vaskularisiertem Gewebe, unterstützt die Migration und Proliferation von Fibroblasten und Kollagen, verbessert die Integration von Hauttransplantaten und reduziert kurzfristige Komplikationen.

INSTRUMENTE UND EINGRIFFE

EP703 Gefährliche Gemeinschaft? Pilze und Bakterien in chronischen Wundenbiofilmen

Mandy Dittmer[1], Sophie Charlotte Liegenfeld[1], Nicolas Krüger[1], Arianna Delle Coste[2], Maria Geffken[3], Ifey Alio[4], Univ-Prof. Dr. Ewa Klara Stürmer[1]

[1]Universitätsklinikum Hamburg Eppendorf, Translationale Wundforschung, Hamburg, Germany, *[2]Universitätsklinikum Hamburg Eppendorf, Abteilung für Mund-, Kiefer-, Gesichtschirurgie, Hamburg, Germany*, *[3]Universitätsklinikum Hamburg Eppendorf, Institut für Transfusionsmedizin, Hamburg, Germany*, *[4]Universität Hamburg, Abteilung für Mikrobiologie und Biotechnologie, Hamburg, Germany*

Ziel: Mikrobielle Wundbiofilme sind ein großes Problem in der Behandlung chronischer Wunden. In Klinik und Forschung liegt dabei der Focus auf bakterielle Biofilme; Hefen und Schimmelpilze erscheinen nahezu vernachlässigt. Studien zeigen jedoch, dass über 20 % der Wunden mit Pilzen, zumeist Candida Spezies, besiedelt sind. Neben der Antiseptika-Toleranz von Biofilmen gegen eine Vielzahl an antimikrobiellen Substanzen, spielen vor allem die Interaktionen der verschiedenen Spezies eine Rolle. Beispielsweise ist bekannt, dass Candida die (Wund)Infektion durch *S. aureus* verstärken kann, obwohl beide unter normalen Umständen typische Keime unseres Hautmikrobioms sind.

Methode: *C. albicans* und *S. aureus* wurden in Single- und Mixed-Spezies-Biofilmen im humanen Biofilm-Modell basierend aus Blutplasma, Immunzellen und Mikroorganismen untersucht. Betrachtet wurden ihre Toleranz gegen Octenidin-dihydrochlorid/Phenoxyethanol und Polyhexamethylen biguanid mittels quantitativ Suspensionsmethode und ihre räumliche Verteilung im Biofilm mittels konfokaler Laser-Scanning-Mikroskopie.

Resultat / Diskussion: Im humanen Biofilm-Modell löst die Anwesenheit von *S. aureus* bei *Candida albicans* die vermehrte Entwicklung von (Pseudo-)Hyphen aus, welche ein Virulenzfaktor dieser Hefe darstellt. Ferner können diese Hyphen eine bessere Penetration und Invasion des Wirtsgewebes erzeugen, welche auch für das Eindringen von *S. aureus* zum Vorteil werden können.

Schlussfolgerung: Wundbiofilme bestehen nicht zwangsläufig nur aus Bakterien, auch Pilze sind in chronischen Wunden aktiv. Auf Grund ihrer eukaryotischen Physiologie reagieren diese jedoch anders auf Antiseptika und können mit Bakterien unvorteilhafte Allianzen eingehen.

EP729 Multidisziplinäre Arbeit bei nekrotisierende Fasziitis im anorektalen Bereich

Annika Schickle[1], Thiha Aung[1]

[1]Institute for Medical Science and Engineering, Deggendorf, Germany

Ziel: Darstellung der rekonstruktiven Versorgung ausgedehnter Weichteildefekte nach Nekrotisierender Fasziitis mit septischem Verlauf anhand zweier Fälle sowie Bewertung der frühen klinischen und funktionellen Ergebnisse.

Methode: Retrospektive Fallserie zweier konsekutiven Patienten mit nekrotisierender Fasziitis im Perineal-/Genitalbereich und Sepsis. Initial erfolgten notfallmäßige radikale Débridements mit seriellen Wundrevisionen, mikrobiologischer Diagnostik und kalkulierter, anschließend resistenzgerechter Antibiotikatherapie sowie intensivmedizinischer Stabilisierung. Zur temporären Wundkonditionierung wurde eine Unterdruck-Wundtherapie (negative pressure wound therapy, NPWT) eingesetzt. Nach Infektkontrolle erfolgte die definitive Defektdeckung jeweils mittels gestieltem anterolateralem Oberschenkellappen (ALT) von der rechten Seite. Intraoperativ wurde die Lappenperfusion mittels Indocyaningrün (ICG) ermittelt. Bei Sphinkterbeteiligung wurde ergänzend eine Gracilis-Muskeltransposition von der linken Seite zur funktionellen Rekonstruktion durchgeführt.

Resultat / Diskussion: In beiden Fällen wurde eine stabile Weichteildeckung ohne Lappenverlust erzielt. Postoperativ bestanden keine Hinweise auf eine persistierende oder rezidivierende Infektion auf. Komplikationen gab es keine. Bei einer Patientin war eine Sekundärnaht erforderlich. Bei der Patientin mit Sphinkterbeteiligung konnte eine vollständige Wiederherstellung der Schließmuskelfunktion erreicht werden.

Schlussfolgerung: Bei nekrotisierender Fasziitis mit Sepsis erfordert ein konsequentes multidisziplinäres Stufenkonzept aus radikaler Infektsanierung, antiinfektiver Therapie und strukturierter Wundkonditionierung essenziell. Der gestielte ALT-Lappen stellt eine robuste Option zur Defektdeckung dar; bei Sphinkterbeteiligung kann die zusätzliche Gracilis-Transposition eine vollständige funktionelle Rekonstruktion ermöglichen.

DIABETISCHES FUSS SYNDROM

EP709 „Verhinderung einer Vorfuss Amputation durch die Anwendung von humanen, zellulären Hautersatzprodukten“

Regula Heimberg-Marti[1]

[1]*Spital Emmental AG, Wundambulatorium, Burgdorf, Switzerland*

Ziel: Verhinderung einer Vorfuss Amputation durch die Anwendung von humanen, zellulären Hautersatzprodukten.

Methode: Zuweisung eines 50-jährigen Diabetikers mit schnell progredientem Weichteilinfekt des linken Vorfusses im Rahmen eines diabetischen Fusssyndroms (HbA1c: 12.9%) mit Osteomyelitis, sowie Polyneuropathie, in unsere ambulante, interdisziplinäre Fusssprechstunde.

Nach erfolgtem, mehrmaligem operativem Débridement des Gangräns folgte die Wundbettvorbereitung mit Negative pressure wound therapy.

Um die Granulation im Wundbereich der freiliegenden, knöchernen Strukturen, sowie der freiliegenden Sehnen zu fördern, wurde ein humanes, zelluläres, nicht lebendes Hautersatzprodukt[1] appliziert. Dieses Hautersatzverfahren, liefert Proteine, Wachstumsfaktoren und Zytokine und unterstützt den Heilungsprozess aktiv. Die Wundbettvorbereitung war nach 3-maliger Anwendung soweit fortgeschritten, dass mit der Anwendung eines humanen, lebenden Hautersatzprodukts[2] gestartet werden konnte. Bei diesem Produkt handelt es sich um ein biotechnologisch hergestelltes, zweischichtiges, lebendes, humanes Hautersatzprodukt. Es besteht aus einer epidermalen Schicht humaner Keratinozyten und deren epidermalen Stammzellen, sowie der darunterliegenden dermalen Schicht aus Kollagen und humanen Fibroblasten.

Resultat / Diskussion: Nach 3-maliger Applikation des lebenden Hautersatzprodukts in Abstand von jeweils 2 Wochen, welche eine Verkleinerung der Wundfläche um 50% bewirkte, konnte die Wundheilung abschliessend mit mehrfacher Applikation des nicht-lebenden Hautersatzprodukts ergänzt und abgeschlossen werden.

Schlussfolgerung: Im genannten Patientenbeispiel führte der Einsatz von Hautersatzprodukten zu einer Verhinderung einer Amputation des Vorfusses, einer verkürzten Wundheilung und zu einem kürzeren Spitalaufenthalt durch die mögliche ambulante Therapie, und somit zu geringeren Kosten.

1 NuShield®
2 Apligraf®

AUSBILDUNG

EP707 Vom Stillstand zur Heilung – Wiederholte Diagnostik kann entscheidend sein

Dennis Gasiorek[1], Tina Uhlmann[1]

[1]Bundeswehrkrankenhaus Berlin, Klinik III - Dermatologie, Venerologie und Allergologie - Interdisziplinäres Wundzentrum (ICW), Berlin, Germany

Ziel: Dieser Fall soll herausstellen, dass eine korrekte Diagnosestellung mit nachfolgender kausaler Therapie der Schlüssel für eine erfolgreiche Behandlung chronischer Wunden ist und dass es dafür erforderlich ist, diese bei ausbleibender Heilungstendenz zu reevaluieren.

Methode: Im August 2025 wurde eine 76-jährige Patientin mit multiplen, großflächigen, stark schmerzhaften Ulzerationen beider Unterschenkel in unserem Wundzentrum stationär behandelt. In Zusammenschau von Befunden und klinischem Verlauf wurde zunächst von einer bakteriellen Genese der Ulcera crurum bei vorbestehendem Lipolymphödem ausgegangen. Aufgrund einer rasch progredienten Verschlechterung der Wundsituation nach Entlassung wurde die Diagnostik wiederholt und die Therapie angepasst, wodurch die Wunden zur Abheilung gebracht werden konnten.

Resultat / Diskussion: Während des zweiten stationären Aufenthaltes konnte anhand einer erneuten Probebiopsie zur histologischen sowie autoimmunologischer Diagnostik die Diagnose eines bullösen Pemphigoids gestellt und die Therapie angepasst werden. Unter einer Kombination einer immunsuppressiven Therapie mit einer großflächigen Spalthauttransplantation kam es zur vollständigen Abheilung der Ulzerationen. Die Patientin ist bis heute beschwerdefrei.

Schlussfolgerung: Bei unklarem Auslöser, atypischer Morphologie und/ oder fehlender Heilungstendenz von Ulzerationen trotz adäquater Therapie sollte spätestens nach sechs Wochen eine Reevaluation der Arbeitsdiagnose und weitere Diagnostik inklusive Histologie erfolgen. Ein kritisches Hinterfragen der eigenen Diagnose ist insbesondere in komplexen Fällen essenziell, da eine kausale Therapie Voraussetzung für eine erfolgreiche Wundbehandlung ist.

EP718 Drei atypische Giganten im differenzialdiagnostischen Fokus

Martina Zivkovic[1]

[1]Keine Zugehörigkeiten, Popovaca, Croatia

Ziel: Atypische Wunden sind selten und werden im klinischen Alltag häufig als gewöhnliche chronische Ulzera fehlinterpretiert. Ziel dieser Arbeit ist es, Pyoderma gangraenosum (PG), Martorell-Ulkus (MU) und Calciphylaxie (CPX) hinsichtlich Ätiologie, klinischen Merkmalen und Differenzialdiagnose zu beschreiben und gegenüber venösen, arteriellen und diabetischen Ulzera abzugrenzen.

Methode: Es wurde eine narrative Literaturrecherche in deutsch- und englischsprachigen Fachartikeln, Leitlinien und Übersichtsarbeiten durchgeführt. Eingeschlossen wurden Publikationen zu PG, MU und CPX bei Erwachsenen mit Angaben zu Ätiologie, klinischen Charakteristika, Diagnostik, Verlauf und Therapie sowie zum Vergleich mit häufigen chronischen Ulzera.

Resultat / Diskussion: Die Literatur beschreibt Pyoderma gangraenosum (PG), Martorell-Ulkus (MU) und Calciphylaxie (CPX) als seltene, aber klinisch unterscheidbare Wunden mit hoher Fehldiagnoserate. Gemeinsame Warnsignale sind starke, disproportionale Schmerzen, prolongierte Anamnese, atypische Lokalisationen sowie ein fehlendes oder sogar verschlechterndes Ansprechen auf Standardtherapien für venöse, arterielle und diabetische Ulzera. PG zeigt sich als rasch progrediente Ulzeration mit inflammatorischem Rand, häufig assoziiert mit systemischen Grunderkrankungen und Risiko der Verschlechterung nach chirurgischem Debridement. MU präsentiert sich als kleines, schmerzhaftes ischämisches Ulkus bei langjähriger arterieller Hypertonie mit harter, livider Umgebung und diskreter makrovaskulärer Diagnostik. CPX ist gekennzeichnet durch plaqueförmige Indurationen, nekrotische Ulzera und livedoartige Hautveränderungen bei fortgeschrittener Nierenerkrankung und medialer Gefäßverkalkung.

Die Abgrenzung gegenüber „klassischen“ Ulzera gelingt durch klinisches Muster, gezielte Biopsie und interdisziplinäre Abklärung.

Schlussfolgerung: PG, MU und CPX sind seltene, aber klinisch relevante Wunden, die häufig verkannt und inadäquat behandelt werden. Eine strukturierte differenzialdiagnostische Vorgehensweise mit klinischen Alarmzeichen, früher Biopsie und interdisziplinärer Abklärung kann die Zeit bis zur korrekten Diagnose verkürzen. Schulungskonzepte und einfache Algorithmen unterstützen Behandelnde, atypische Wunden frühzeitig zu erkennen und von venösen, arteriellen und diabetischen Ulzera zu unterscheiden.

HÄUSLICHE PFLEGE

EP710 Zeitabhängige Veränderungen auf (sub-) zellulärer Ebene nach Anwendung von Hämostyptika in vivo

Waseem Garabet [1], Arzu Mammadova[1], Helena Ströthoff[1], Polina Shabes[1], Katharina Wolters[1], Markus Udo Wagenhäuser[1], Hubert Schelzig[1], Julian-Dario Rembe[1]

[1]Universitätsklinikum Düsseldorf, Klinik für Gefäß- und Endovaskulärchirurgie, Düsseldorf, Germany

Ziel: Hämostyptika sind blutstillende Materialien, die bei dermatogefäßchirurgischen Eingriffen eingesetzt werden. Sie verbleiben dabei in der Wunde oder dienen als Wundauflage. Frühere Untersuchungen zeigten, dass unterschiedliche Hämostyptika variierende Auswirkungen auf die Wundheilung haben können. In unserer Studie wurde der Einfluss verschiedener Hämostyptika auf die Wundheilung im Mausmodell analysiert.

Methode: Bei C57BL/6J-Mäusen(n =192) wurden drei Hämostyptika – oxidierte-nicht-regenerierte-Zellulose(ONRC), oxidierte-regenerierte-Zellulose(ORC) und gelatinbasiertes Hämostyptikum(GELA) getestet und mit einer Kontrollgruppe verglichen. An den postoperativen Tagen 3, 7, 14 und 30 wurden Hautproben entnommen, histologisch aufgearbeitet und gefärbt. Zur Bewertung der Effekte der Hämostyptika kamen Immunhistochemie für Ki-67, Alpha-Smooth-Muscle-Actin(α-SMA) und CD68, sowie qPCR-Analysen für Transforming Growth Factor-β(TGF-β), Vascular Endothelial Growth Factor(VEGF), Fibroblasten-Wachstumsfaktor 2(FGF-2) und CD68 zum Einsatz.

Resultat / Diskussion: Nach 3 Tagen wurden keine signifikanten Unterschiede zwischen der Kontroll- und Anwendungsgruppen festgestellt.

Nach 7 Tagen führte GELA zu einem signifikanten Anstieg der CD68-Expression und die Ki-67-Konzentration im Vergleich zur Kontrollgruppe.

Nach 14 Tagen wurde die TGF-ß-Expression durch ORC signifikant im Vergleich zur Kontrollgruppe gehemmt(p=0,047).

Nach 30 Tagen war die Ki-67-Aktivität durch GELA signifikant erhöht(p=0,02), während die α-SMA-Aktivität durch GELA(p=0,038) und ORC(p=0,032) signifikant gesteigert wurde. Die VEGF-Expression wurde durch GELA(p=0,003) und ORC(p=0,013) signifikant gehemmt, während die TGF-ß-Expression durch ONRC signifikant aktiviert wurde(p=0,02). Für die FGF-2-Aktivität konnten keine signifikanten Unterschiede zwischen den untersuchten Gruppen gemessen werden.

Schlussfolgerung: Die untersuchten Hämostyptika zeigten keinen negativen Effekt auf die Wundheilung in der Frühphase. Die Inflammation und Zellproliferation wurden nach 7 Tagen durch GELA aktiviert. GELA und ORC haben nach 30 Tagen die Zellkontraktion positiv und die VEGF-Expression negativ beeinflusst, was bei verzögerter Wundheilung relevant sein kann. Beim Belassen von Hämostyptika in der Wunde sollte insbesondere bei gefährdeter Wundheilung, deren unterschiedliche Wirkung berücksichtigt werden.

INFEKTION

EP701 Grenzen der ambulanten Wundversorgung

Christian Hoffmann[1]

[1]*1A Wundzentrum GmbH, Hamburg, Germany*

Ziel: In Deutschland leben je nach Datenquelle rund 0,8-1,1 Millionen Menschen mit schwerheilenden bzw. chronischen Wunden. Ein zentrales Nadelöhr ist die häusliche Durchführung von Verbandswechseln, aktuelle Daten zeigen das 33,1% der Wundpatienten regelmäßige Verbandswechsel durch einen ambulanten Pflegedienst zuhause erhalten, hingegen aber nur 9% die spezifische HKP-Leistung "Wundversorgung einer chronischen und schwerheilenden Wunde" (Nr.31a, APN B81) abrechnen. Ziel = Sensibilisierung der HKP-Richtlinie zu spezialisierten Leistungserbringern (ambulanten Wundteams, pflegerischen Wundzentren)

Methode: Darstellung von extremen Beispielen in der ambulanten Wundversorgung. Schnittstellen zu interdisziplinären Netzwerken, Aufzeigen von Grenzen der häuslichen Versorgung.

Resultat / Diskussion: Diskussionspodium, Erfahrungsaustausch und Dialog mit den Teilnehmer:innen durch Aufklärung der HKP-Richtlinie, Vergütungsmodellen und fachlichen Austausch -> Förderung der Zusammenarbeit im Netzwerk.

Schlussfolgerung: Trotz großer Patientenzahlen bleibt die ambulante Wundversorgung durch Fragmentierung, begrenzte Nutzung spezialisierter HKP-Leistungen und Datenlücken eingeschränkt. Prioritär sind: klare Indikationspfade, flächendeckend qualifizierte spezialisierte Pflegedienste, verbindliche Netzwerke sowie standardisierte, sektorenübergreifende Wunddokumentation.

EP717 Endogene Bakteriophagen aus chronischen Wunden und deren Aktivität gegen Wundisolate des Eskape-Erregers Pseudomonas Aeruginosa

Nicolas Krüger[1], Sophie Charlotte Liegenfeld[1], Mandy Dittmer[1], Univ-Prof. Dr. Ewa Klara Stürmer[1]

[1]*Universitätsklinikum Hamburg-Eppendorf, Hamburg, Germany*

Ziel: Bakteriophagen sind hochspezialisierte Viren, die Bakterien spezifisch infizieren und lysieren. Ihre therapeutische Wirksamkeit gegen humane Pathogene wurde bereits in Fallstudien und *in-vitro* Experimenten gezeigt. Therapeutisch relevante Phagen werden bislang überwiegend aus Umweltproben isoliert. Das chronische Wundmilieu ist jedoch ein eigenständiges mikrobielles Ökosystem, in dem auch Phagen endogen vorkommen könnten. Ziel dieser Studie ist die Isolation Wund-assoziierter Phagen, ihre Analyse und die Testung ihrer Wirksamkeit gegen *P. aeruginosa* aus chronischen Wunden.

Methode: Aus chronisch-infizierten Wunden von 20 Patienten wurden Biofilm-Proben entnommen. Mittels Double-Layer-Assay erfolgte das Screening auf Phagen mit lytischer Aktivität gegenüber zwei laboradaptierte *P. aeruginosa* Stämme. Isolierte Phagen wurden vereinzelt und aufkonzentriert. Die morphologische Charakterisierung erfolgte mittels Transmissionselektronenmikroskopie. Parallel wurden bakterielle Wundisolate kultiviert und mittels 16S-rRNA-Sequenzierung identifiziert. Die isolierten *P. aeruginosa* aus Wunden wurden in planktonischen Killing-Assays auf ihre Sensitivität gegenüber den Phagen getestet.

Resultat / Diskussion: Insgesamt wurden 16 Phagen mit lytischer Aktivität gegen *P. aeruginosa* aus dem Wundmilieu isoliert. Die TEM-Analyse zeigte vier morphologisch unterschiedliche Phagenfamilien (Podoviridae, Siphoviridae, Myoviridae und flagellotrophen Artige). Zusätzlich wurden 42 bakterielle Isolate gewonnen, darunter 11 *P. aeruginosa*. Die Mehrheit der Phagen zeigte eine ausgeprägte lytische Aktivität gegenüber klinischen Wundisolaten im planktonischen Modell.

Schlussfolgerung: Die o.g. Ergebnisse zeigen, dass Bakteriophagen natürlicher Bestandteil des Mikrobioms chronischer Wunden sind und eine klinisch relevante antibakterielle Aktivität gegenüber wundassoziierten *P. aeruginosa* Isolaten besitzen. Dies spricht für eine dynamische Koexistenz von Bakterien und Phagen im Wundmilieu und eröffnet neue Perspektiven für wundeigene, personalisierte Phagentherapien bei resistenten Wundinfektionen. Chronische Wunden sind ein natürliches Reservoir klinisch wirksamer Bakteriophagen.

EP732 Sektorenübergreifendes Entlassmanagement im ländlichen Raum: Ergebnisse und Handlungsempfehlungen aus dem Verbundprojekt NAHVERSORGT

Jann Niklas Vogel[1], Hanna Hilgenhof[1], Ivonne Honekamp[2], Anne Petereit[2], Valerie Bühler[2], Chiara Kleinschmidt[2], Stefan Schmidt[1]

[1]Hochschule Neubrandenburg, Fachbereich Gesundheit, Pflege, Management, Neubrandenburg, Germany, *[2]Hochschule Stralsund, Fakultät für Wirtschaft, Stralsund, Germany*

Ziel: Ziel des Posterbeitrags ist es, empirisch fundierte Handlungsempfehlungen zur Weiterentwicklung des Entlassmanagements in ländlich geprägten Regionen vorzustellen. Im Mittelpunkt stehen Herausforderungen an den Schnittstellen zwischen stationärer Krankenhausversorgung, ambulanter und häuslicher Pflege sowie weiteren regionalen Unterstützungsstrukturen.

Methode: Im Verbundprojekt NAHVERSORGT wurde ein partizipativer Mixed-Methods-Ansatz umgesetzt. Nach einer initialen Bestandsaufnahme der Strukturen und Prozesse im Entlassmanagement in Deutschland auf Basis eines Scoping Reviews wurden im Jahr 2024 leitfadengestützte Fokusgruppendiskussionen durchgeführt. Diese fanden im Rahmen von vier bestehenden Runden Tischen in Mecklenburg-Vorpommern statt. Beteiligt waren regionale Akteur*innen aus Gesundheitswesen, Pflege, Sozialarbeit, Verwaltung und Zivilgesellschaft. Darauf aufbauend folgten 2025 vertiefende Fokusgruppendiskussionen, in denen ergänzend die Strukturlegetechnik zur gemeinsamen Analyse komplexer Problemzusammenhänge und zur Entwicklung von Lösungsansätzen eingesetzt wurde. Zusätzlich erfolgte eine quantitative Erhebung in allen 37 Krankenhäusern des Bundeslandes zu Strukturen, Prozessen und Rahmenbedingungen des Entlassmanagements. Die integrierte Auswertung der qualitativen und quantitativen Daten ermöglichte eine multiperspektivische Betrachtung der regionalen Versorgungssituation.

Resultat / Diskussion: Die Datenauswertungen weisen auf wiederkehrende Herausforderungen im Entlassmanagement ländlicher Regionen hin. Dazu zählen unter anderem begrenzte Übergangs- und Kurzzeitpflegeangebote, eingeschränkte Tagespflegekapazitäten, heterogene digitale Kommunikationswege sowie teilweise unklare Zuständigkeitsstrukturen. Zugleich wurden regionale Ressourcen identifiziert, darunter bestehende Kooperationsnetzwerke, Pflegestützpunkte und sozialräumliche Unterstützungsangebote. Auf dieser Grundlage wurden Handlungsempfehlungen erarbeitet, die sich unter anderem auf kommunale Koordinationsstrukturen, mobile und digitale Versorgungsformate sowie interprofessionelle Zusammenarbeit beziehen.

Schlussfolgerung: Die Forschungsergebnisse verdeutlichen die Bedeutung abgestimmter Prozesse und sektorenübergreifender Strukturen für ein verlässliches Entlassmanagement im ländlichen Raum. Die entwickelten Handlungsempfehlungen bieten Ansatzpunkte für die Weiterentwicklung regionaler Versorgungsstrukturen unter Berücksichtigung vorhandener Ressourcen und Rahmenbedingungen.

ULCUS CRUSIS

EP719 Jenseits der Standardversorgung: Bewertung der vergleichenden Wirksamkeit von polarisiertem Licht bei der Verbesserung des Verschlusses von venösen Beingeschwüren

Tatjana Mijuskovic[1]

[1]*BIOPTRON AG, Wollerau, Switzerland*

Ziel: Venöse Beingeschwüre (Ulcus cruris venosum) sind eine weit verbreitete chronische Erkrankung, die die Lebensqualität der Patienten erheblich beeinträchtigt und hohe Kosten im Gesundheitswesen verursacht.

Methode: Dieser Abstract fasst die Ergebnisse kontrollierter Studien zusammen, die die Rolle der Polarized Light Therapy (PLT) bei der Beschleunigung der Heilung von VLUs untersucht haben. In diesen Studien wurde die PLT (10-12 Minuten, dreimal wöchentlich über einen Zeitraum von 6 Wochen bis 3 Monaten) mit der Standard-Wundversorgung und anderen physikalischen Therapien verglichen, darunter die Unterdruck-Wundtherapie (NPWT), die monochromatische Infrarotenergie (MIRE) und die Low-Lever-Lasertherapie (LLLT). Die Wirksamkeit wurde in erster Linie durch die Messung der Ulkusoberfläche (USA) und des Ulkusvolumens (UV) und in zweiter Linie durch die Anzahl der Bakterienkolonien beurteilt.

Resultat / Diskussion: Die PLT zeigte im Vergleich zu den Kontrollen eine signifikante Beschleunigung der Heilungsrate bei VLUs. Im Vergleich zu MIRE waren beide Therapien hochwirksam und bei der Verringerung von USA und UV um 75 % nahezu gleichwertig. Andere Modalitäten zeigten jedoch bessere Ergebnisse. Die PLT erwies sich als wirksamer als die NPWT und verringerte das Ulkusvolumen nach 6 Behandlungswochen um 52 % (p= 0,01), gegenüber 34 % in der Kontrollgruppe. Die PLT-Patienten zeigten eine 71,6%ige Verringerung der Ulkusoberfläche (p=0,0001) im Vergleich zu 0% in der Kontrollgruppe und 60% in der mit LLLT behandelten Gruppe. Außerdem wurde ein signifikanter Rückgang der Bakterienkoloniezahlen beobachtet.

Schlussfolgerung: Die Therapie mit polarisiertem Licht ist eine wirksame und unverzichtbare ergänzende Therapie zur Behandlung von venösen Beingeschwüren, die erfolgreich die Heilungsraten verbessert und die mikrobielle Belastung reduziert. Während bestimmte fortschrittliche Modalitäten Vorteile bei bestimmten Heilungskennzahlen bieten können, bleibt die PLT ein leistungsfähiges und wirksames Instrument zur Bewältigung der Komplexität der Heilung chronischer VLU.

UNTERDRUCK WUNDTHERAPIE

EP711 DigiLeit: Digitalisierung evidenzbasierter Leitlinien – Qualitätsindikatoren zur Versorgung chronischer Wunden und personalisierte Mobilitätsförderung

Raphael Wilhelm[1], Marion Burckhardt[2], Alexandra Strobel[3], Stephan Grabbe[1]

[1]Universitätsmedizin Mainz, Hautklinik und Poliklinik, Mainz, Germany, *[2]Deutsche Gesellschaft für Wundheilung und Wundbehandlung e.V. (DGfW), Gießen, Germany*, *[3]Universitätsmedizin Halle, Institut für medizinische Epidemiologie, Biometrie und Informatik, Halle (Saale), Germany*

Ziel: Verbesserung der Leitlinienadhärenz bei der Versorgung von Patient:innen mit chronischen Wunden durch Digitalisierung leitlinienbasierter Empfehlungen sowie durch begleitende Schulungs- Audit- und Feedbackmaßnahmen im Rahmen des Projektes DigiLeit, um eine evidenzbasierte effiziente Patientenversorgung am *Point of Care* zu fördern und die Belastung für Betroffene und Leistungserbringende zu reduzieren.

Methode: Im durch den G-BA Innovationsfonds geförderten Projekt DigiLeit wurden bundesweit spezialisierte Wundzentren aufgebaut und auditiert. Dort erfolgt die Anwendung einer neuen Versorgungsform (nVF) mit digitalisierten Leitlinienempfehlungen und Diagnostik- und Behandlungspfaden. Zur Erfassung der Leitlinienadhärenz wurden interprofessionell entwickelte Qualitätsindikatoren eingesetzt, die erstmals direkt am Patienten erhoben werden können. Zudem wurde eine personalisierte Mobilitätsförderung implementiert, basierend auf einer initialen Mobilitätseinstufung und individuell angepassten Trainingsplänen mit regelmäßiger Reevaluation. Die Wirksamkeit dieser Maßnahmen wird im Rahmen einer multizentrischen, randomisierten, kontrollierten Studie bei Patient:innen mit chronischen Wunden bei pAVK, CVI und Diabetes Mellitus evaluiert.

Resultat/Diskussion: Durch die nVF soll die Umsetzbarkeit und Anwendung evidenzbasierter Leitlinien im Versorgungsalltag systematisch erfasst und bewertet werden. Als primärer Endpunkt wird die Wundheilung nach 20 Wochen im Vergleich zur Regelversorgung gemessen. Darüber hinaus erfolgt die Analyse der Ressourcenallokation und zahlreicher sekundärer Endpunkte. Die direkt am Patienten abfragbaren Qualitätsindikatoren sowie die strukturierte Förderung der Mobilität stellen innovative Elemente dar, deren Einfluss auf die Versorgungsqualität, Lebensqualität und letztlich Abheilung der Wunde im Rahmen der Studie untersucht wird.

Schlussfolgerung: DigiLeit adressiert zentrale Barrieren der Leitlinienimplementierung bei chronischen Wunden und verfolgt einen digital gestützten Ansatz zur Verbesserung der Versorgungsqualität. Das übergeordnete Ziel ist dabei die nachhaltige Überführung der nVF in die Regelversorgung, verbunden mit einer strukturellen Anerkennung sowie einer adäquaten und leistungsgerechten Vergütung pflegerischer und ärztlicher Leistungen. In dem geplanten Vortrag stehen die Mobilitätsförderung sowie die Qualitätsindikatoren im Vordergrund.

EP702 Venenerkrankungen, Lymphödem und Lipödem im Kontext der Adipositas: Übersicht zur Risikoevidenz und Relevanz der medizinischen Kompressionstherapie

Kristin Sauer[1], Janet Zowe[2], Eberhard Rabe[3], Astrid Riebeling[4], Prof. Dr. Markus Stücker[5]

[1]eurocom e.V., Berlin, Germany, *[2]medi GmbH & Co. KG, Bayreuth, Germany*, *[3]Praxis Pannier, Bonn, Germany*, *[4]BSN medical GmbH, Hamburg, Germany*, *[5]Klinik für Dermatologie, Venerologie und Allergologie Venenzentrum der dermatologischen und gefäßchirurgischen Kliniken Ruhr-Universität Bonn, Bochum, Germany*

Ziel: Venenerkrankungen, Lymphödeme und Lipödeme sind häufige und oft unterschätzte Folgeerkrankungen der Adipositas. Diese Übersichtsarbeit verfolgt das Ziel (a) Adipositas als Risikofaktor für die Entstehung dieser Erkrankungen sowie (b) die Bedeutung der medizinischen Kompressionstherapie (MKT) im Management adipöser Patientinnen und Patienten zu unterstreichen.

Methode: Grundlage war gemäß Methodik der Evidenzbasierten Medizin eine systematische Literaturrecherche in MEDLINE zur Risikoevidenz der Adipositas. Die Bedeutung der MKT wurde aus Leitlinien und unter Berücksichtigung aktueller Veröffentlichungen abgeleitet.

Resultat / Diskussion: (a) Adipositas erhöht das Risiko für Venenerkrankungen (OR: 10,22 [7,67-13,62]), Lymphödem (OR: bis 6,7 [2,1-23,0]) sowie für die Symptomverschlechterung eines bestehenden Lipödems (BMI, OR: 1,24 [1,19-1,29]).

(b) Die MKT ist ein zentraler Bestandteil im klinischen Management Adipositas-assoziierter funktioneller Veneninsuffizienz, des Lymphödems und Lipödems. Flachstrick wird insbesondere in Leitlinien beim Lymphödem sowie bei starken Umfangsänderungen und Hautfalten aufgeführt, Konstellationen, die bei Adipositas häufig auftreten. Medizinisch Adaptive Kompressionssysteme (MAKs) stellen hier eine weitere, klinisch wichtige Versorgungsoption dar.

Schlussfolgerung: Mit steigender Prävalenz der Adipositas nehmen Häufigkeit und/oder Schweregrad der Adipositas-assoziierten funktionellen Veneninsuffizienz sowie von Lymphödem und Lipödem zu. Die MKT sollte daher als essenzieller Bestandteil einer strukturierten und evidenzbasierten Versorgung im Rahmen eines Adipositas Disease Management Programms betrachtet werden. Diese Übersicht dient als Orientierung, um diese Erkrankungen adäquat zu behandeln.

SCHMERZEN

EP715 3-Phasenmodell der Eskalation und Chronifizierung von Wunden

Christian Hoffmann[1]

[1]*1A Wundzentrum GmbH, Hamburg, Germany*

Ziel: Erarbeitung eines vereinfachten Phasenmodells zur frühzeitigen Intervention von chronischen Wunden unter Berücksichtigung der Lebensqualität (Wound-QoL) und im Kontext anhand verschiedener Eskalationsstufen nach Glasl. Erstellung eines 3-phasigen Modells.

Methode: Wir können die Stufen von Glasl analog auf die „Eskalation" einer Wunde bis zur Behandlung beziehen und grafisch sowie tabellarisch abbilden.

Glasl-Stufe	Entsprechung Wundverlauf	Typische Probleme	Wound-QoL-Belastung	Dauer bis adäquate Behandlung
1-3 (WIN-WIN)	Akute Wunde	Verharmlosung, Bagatellisierung	Leicht (v.a. Schmerz)	Tage - Wochen
4-6 (WIN-LOSE)	Übergang zur Chronifizierung	Fehlversorgung, Konflikte zwischen Beteiligten	Mittel (Mobilität, Psyche)	Wochen - Monate
7-9 (LOSE-LOSE)	Chronische Wunde	Frustration, Resignatio, systemische Folgen	Hoch (alle Dimensionen)	Monate - Jahre

Resultat / Diskussion: Dieses Modell überträgt die Eskalationsstufen nach Glasl auf die Entstehung und Chronifizierung von Wunden. Es zeigt, wie Verzögerungen in der Wahrnehmung und Behandlung zur Eskalation führen – mit massiven Auswirkungen auf die Lebensqualität (Wound-QoL).

• Phase 1 (Win-Win): Akute Wunde, prinzipiell heilbar. Oft Bagatellisierung → kurze Verzögerung bis Behandlung.

• Phase 2 (Win-Lose): Beginn der Chronifizierung. Fehlversorgung, Konflikte zwischen Patienten, Angehörigen und Behandlern → deutliche Einschränkungen im Alltag.

• Phase 3 (Lose-Lose): Voll entwickelte chronische Wunde. Frustration, Resignation, Schmerzen, soziale Isolation → lange Verzögerung bis spezialisierte Therapie.

Schlussfolgerung: Die Eskalation einer Wunde gleicht der Eskalation nach Glasl:

Je länger die Behandlung hinausgezögert wird, desto schwieriger wird die Heilung – und desto gravierender sinkt die Lebensqualität (Wound-QoL).

Durch die Vereinfachung der 3 Phasen lassen sich interdisziplinäre Prozesse neugestalten und steuern, der herkömmliche Blick auf eine Chronifizierung der Wunde liese sich somit vermeiden, wenn man frühzeitig interveniert und phasengerecht behandelt. Wundversorgung ist Teamwork im wahrsten Sinne des Wortes und sollte so früh wie möglich interdisziplinär erfolgen.

DEKUBITUS

EP726 Rolle der Advanced Practice Nurse in der evidenzbasierten Dekubitusprophylaxe: Sensibilisierung und Kompetenzstärkung der Pflegeteams

Janine Koch-Grabowski[1]

[1]*Herz- und Diabeteszentrum NRW, Bad Oeynhausen, Germany*

Die Prävention von Dekubitus zählt zu den entscheidenden Qualitätsindikatoren in der Patientenversorgung und erfordert eine konsequente sowie evidenzbasierte Umsetzung prophylaktischer Maßnahmen. Trotz klarer Leitlinien besteht in der pflegerischen Praxis häufig eine unzureichende Umsetzung zwischen theoretischem Wissen und tatsächlicher Anwendung. Gründe hierfür sind unter anderem eine unzureichende Sensibilisierung des Personals, heterogene Kompetenzniveaus sowie strukturelle Herausforderungen im Versorgungsalltag. Der Einsatz einer Advanced Practice Nurse (APN) bietet ein vielversprechendes Konzept, um diese Lücke zu schließen und die Wirksamkeit der Dekubitusprophylaxe nachhaltig zu verbessern**.**

Ziel: Ziel der vorliegenden Arbeit ist es, den Beitrag der APN zur Sensibilisierung und Kompetenzsteigerung von Pflegefachpersonen hinsichtlich der Bedeutung und Umsetzung evidenzbasierter Prophylaxen zu untersuchen.

Methode: Zur Methodik wurde ein evidenzbasierter, praxisorientiert Ansatz gewählt, der aus einer qualitativen deskriptiven Analyse bestehend aus einer Literaturrecherche, einem Schulungskonzept, strukturiertes Bedside-Coaching und die Implementierung standardisierter Assessmentverfahren kombiniert wird. Zusätzlich wurden 18 Stationen geschult und zur Umsetzung der Prophylaxen angeleitet. Praxisbezogene Beobachtungen und strukturelle Prozessanalysen aus dem klinischen Setting wurden ebenfalls wie die Anzahl der Dekubitalulzera innerhalb eines Jahres und die Wunddokumentation, herangezogen.

Resultat / Diskussion: Die Ergebnisse zeigen, dass die kontinuierliche Unterstützung durch eine APN nicht nur das Verständnis für Risikofaktoren und präventive Interventionen vertieft, sondern auch zu einer erhöhten inneren Aufmerksamkeit für die Relevanz regelmäßiger Hautinspektionen, adäquater Lagerungstechniken und interprofessioneller Abstimmung führt. Zudem trägt die APN maßgeblich zur Sicherstellung einer einheitlichen und leitlinienorientierten Pflegepraxis bei, was sich in einer verbesserten Präventionsqualität und einer nachhaltigen Reduktion Dekubitus assoziierter Risiken widerspiegelt.

Schlussfolgerung: Insgesamt verdeutlicht die Analyse, dass die Integration einer APN einen wichtigen Beitrag zur Sensibilisierung von Pflegefachpersonen und zur Professionalisierung der Dekubitusprophylaxe leistet. Dies unterstreicht die Bedeutung erweiterter Pflegekompetenzen für die Optimierung patientensicherheitsrelevanter Prozesse im klinischen Setting.

EP727 Schwierigkeiten in der Klassifikation eines Dekubitus bei Intensivpatienten

Sofia Marantidou[1], Daniela Fassbender[1], Nadine van-Gerfsheim[1], Ulf Gillmann[1], Jaqueline Kiseljak[1], Ramin Chafii-Badavi[1], Knut Kröger[1]

[1]*Helios Klinik Krefeld, Krefeld, Germany*

Ziel: Anhand von ausgewählten Beispielen der Intensivstation des Klinikums soll dargestellt werden, wie schwierig es ist, bei Erstvorstellung vom Patienten eine Einstufung bzw. Klassifikation einer sakralen Läsion als Dekubitus vorzunehmen.

Methode: In der digitalen Patientenakte von Patienten, die zwischen 10.12.2024 und 01.12.2025 von der Forschungs- und Wundversorgungseinheit (Wundmanagement) des Klinikums betreut wurden, haben wir unter den Suchbegriffen „Flüssigkeits-assoziierte Hautschäden, livide Hautläsion und vermutete tiefe Gewebsschädigung - unbekannte Tiefe“ Patienten ausgewählt. Dies sind Patienten, bei denen wir zum Zeitpunkt der ersten Vorstellung nicht sicher beurteilen konnten, welche Hautläsion hier vorliegt.

Resultat / Diskussion: Insgesamt wurden aus den ca. 400 Fällen in diesem Zeitraum 12 Fälle aufgelistet. Von den 12 Fällen waren 7 männlich 5 weiblich im mittleren Alter von 49 bis 85 Jahren. Bei 7 Fällen hatten wir primär eine Mazeration vermutet. Bei den weiteren 5 Fällen war einmal eine livide Verfärbung, einmal eine Fissur und dreimal eine wegdrückbare Rötung dokumentiert worden. Nach im Durchschnitt 20,2 Tagen (Breite 4 - 42 Tage) hat sich unsere Einschätzung geändert, sodass wir bei 10 Patienten von einem Dekubitus ausgingen und diesen dann auch klassifizieren konnten und nur bei 2 Patienten blieb die Diagnose einer Mazeration bestehen.

Schlussfolgerung: Die Einstufung und Klassifizierung einer sakralen Hautveränderungen ist häufig nicht am Tag der Erstvorstellung möglich, sondern gelingt erst im Verlauf der Zeit. Bei unseren Patienten dauerte dies zwischen 4 und 42 Tagen. Diese Analyse soll helfen, das Verständnis für Diskrepanzen bei der Einschätzung einer sakralen Läsion durch verschiedene Einrichtungen oder Personal zu verstehen.

PRÄVENTION

EP706 Die Kommunikation mit einem Teil meines Körpers fehlt: Aspekte zur Lebensqualität von Menschen mit Diabetischem Fußulkus und fehlendem Schmerzempfinden

Ralf Lobmann[1], Alexander Risse[2], Arthur Grünerbel[3], Claas Lüdemann[4], Stephan Morbach[5], Holger Lawall[6], Holger Diener[7], Christoph Volkering[8], Bernhard Kulzer[9]

[1]Klinikum Stuttgart, Klinik für Endokrinologie, Diabetologie und Geriatrie, Stuttgart, Germany, *[2]Diabeteszentrum Berlin, Berlin, Germany*, *[3]Diabeteszentrum München-Süd, München, Germany*, *[4]Abteilung für Innere Medizin, Brixen, Italy*, *[5]Abteilung für Diabetologie und Angiologie, Marienkrankenhaus, Soest, Soest, Germany*, *[6]Gemeinschaftspraxis für Herz-Kreislauferkrankungen, Akademie für Gefäßkrankheiten, Prof. Diehm Dr. Lawall, Ettlingen, Germany*, *[7]Abteilung für Gefäßchirurgie und endovaskuläre Chirurgie, Wundkompetenzzentrum, Krankenhaus Buchholz, Buchholz, Germany*, *[8]Praxis Orthoevo München, München, Germany*, *[9]FIDAM GmbH Forschungsinstitut Diabetes-Akademie Bad Mergentheim, Bad Mergentheim, Germany*

Ziel: Erhebungen zur Lebensqualität bei Menschen mit Diabetischem Fußsyndrom (DFS) konzentrieren sich auf den Faktor Schmerz. Der Verlust der Schmerzwahrnehmung (Loss of protective pain (LOPP)) in Relation zur Lebensqualität ist nicht beschrieben, obwohl die Betroffenen Patienten mehrheitlich keine Schmerzen empfinden. In einer qualitativen Voranalyse sollten spezifische Items zur Lebensqualität (QoL) für diese besondere Patientengruppe identifiziert werden, mit dem Ziel diese in einer weiteren Erhebung zu testen.

Methode: Qualitative Voranalyse mit Patienten mit Typ 2 Diabetes (DM) und LOPP, die stationär oder ambulant in spezialisierten Fußeinrichtungen behandelt wurden. Die Patienten wurden mit einem semi-strukturierten Fragebogen interviewt. Eine thematische Content-Analyse wurde genutzt, um Schlüsselaspekte zum QoL für diese spezifische Patientengruppe zu identifizieren.

Resultat / Diskussion: Befragt wurden n=10 Patienten (Alter: 73,9±11,4 Jahre; Diabetesdauer: 9,4±8,1 Jahre; 70% (30%) mit fehlendem (stark eingeschränkten) Schmerzempfinden). Die Patienten nehmen wahr, dass das fehlende Schmerzempfinden ein neues Risiko für die Prognose ihres Fußulkus darstellt. Es wird als schwer empfunden mit dem unbekannten abstrakten Risiko umzugehen und es kommt häufig zu Verletzungen. Auf Grund der fehlenden Empfindung besteht eine größere Abhängigkeit von anderen bei der Versorgung des Fußes. Das Vertrauen in den Partner, das pflegende und medizinische Team hat eine zentrale Bedeutung für die Lebensqualität. Als mögliche neue Items wurden z.B. folgende getestet: „kein Schmerz“, „besserer Schlaf“, betreffend LOPP, verbesserte Alltagsaktivitäten, zunehmendes Sturzrisiko, schlechte Körper (Fuß-)-Wahrnehmung oder Verletzungen.

Schlussfolgerung: Die durchgeführten Interviews ergaben wichtige Einblicke (Insights) zu signifikanten Aspekten der QoL für Patienten mit LOPP. Die Ergebnisse werden genutzt, um in einem zweiten, bereits gestarteten Projektschritt LOPP-spezifische Items für einen ergänzenden standardisierten Fragebogen zu entwickeln, der in Zusammenhang mit der systematischen Untersuchung der wundspezifischen Lebensqualität für diese Patientengruppe genutzt werden kann.

CHIRURGISCHE ANSÄTZE

EP700 Kommunikation in der Wundversorgung - „No-Gos“ und „Red Flags“

Christian Hoffmann[1]

[1]1A Wundzentrum GmbH, Hamburg, Germany

Ziel: Kommunikation ist ein wesentlicher Bestandteil der professionellen Wundversorgung. Sie beeinflusst Adhärenz, Patientensicherheit und interprofessionelle Zusammenarbeit. Fehlerhafte, stigmatisierende oder unklare Kommunikation kann den Behandlungserfolg erheblich gefährden. Darstellung zentraler „No-Gos“ und „Red Flags“ in der Kommunikation der Wundversorgung auf Grundlage der Definitionen und Empfehlungen der Initiative Chronische Wunden e.V. (ICW).

Methode: Analyse der ICW-Begriffsdefinitionen und Kommunikationsempfehlungen sowie Auswertung einschlägiger Fachliteratur zur Lehrer:innen zentrierten Kommunikation.

Resultat / Diskussion: „No-Gos“ umfassen insbesondere stigmatisierende Begriffe, den unreflektierten Einsatz von Fachterminologie im Patientenkontakt sowie widersprüchliche Botschaften im Behandlungsteam. Als „Red Flags“ gelten Kommunikationssituationen mit erhöhtem Risiko für Missverständnisse, Adhärenzprobleme oder Vertrauensverlust. Die ICW betont die Bedeutung klarer, wertschätzender und standardisierter Sprache, um Missverständnisse zu vermeiden und die Versorgungsqualität zu sichern.

Schlussfolgerung: Die Reflexion kommunikativer Risiken und die konsequente Anwendung der ICW-Empfehlungen leisten einen entscheidenden Beitrag zur Patientensicherheit und zur Qualität der Wundversorgung. Kommunikation ist somit nicht nur unterstützend, sondern integraler Bestandteil professioneller Praxis und erfordert kontinuierliche Schulung und Sensibilisierung.

EP735 Holistisches Morphologie Modell der modernen Wundversorgung: Strukturierte Dimensionen für klinische Praxis; Schulung; Entwicklung und Entscheidungsfindung

Sabrina Ziegler[1], Tina Leeb[2], Heiko Krenmayer[3], Gerhard Kammerlander[4], Christian Rohrer[5]

[1]Lohmann & Rauscher GmbH & Co. KG, RD-Innovationsmanagement, Neuwied, Germany, *[2]Lohmann & Rauscher GmbH, Research & Development, Schönau an der Triesting, Austria*, *[3]Lohmann & Rauscher KG, Sales German-CH, St. Gallen, Switzerland*, *[4]Akademie-ZWM AG, CEO, Embrach, Switzerland*, *[5]Lohmann & Rauscher GmbH, Lohmann & Rauscher GmbH & Co. KG, Research & Development, Schönau an der Triesting, Austria*

Ziel: Die Wundversorgung ist ein umfangreiches und multidimensionales Behandlungsfeld, das zahlreiche Aktivitäten, Indikationen und Entscheidungsprozesse umfasst. Obwohl die Literatur eine Vielzahl detaillierter Handlungsleitfäden und Standards dokumentiert, fehlt bislang eine visuelle Gesamtübersicht, die die unterschiedlichen Dimensionen der modernen Wundversorgung auf einen Blick verständlich macht.

Methode: Im Rahmen eines Projektes wurde die Wundversorgung aus einer ganzheitlichen Perspektive analysiert, um zentrale Themenbereiche, Behandlungsschritte, Versorgungsprozesse und Interaktionen systematisch zu erfassen. Anstatt eine einzelne Indikation zu vertiefen, wurde eine allgemeine Perspektive gewählt, um die Vielfalt und Komplexität der Versorgung abzubilden.

Für die Entwicklung der Morphologie wurden aktuelle nationale und internationale Leitlinien der Wundversorgung berücksichtigt. Zusätzlich wurden Experten aus der Wundversorgung sowie erfahrene Wundberater aktiv einbezogen. Ergänzend flossen die erfolgreichsten Schulungs- und Projektergebnisse von zertifizierten Wundzentren ein, die als „Real-Life-Daten“ aus den letzten 25 Jahren in der DACH-Region zur Verfügung standen.

Resultat / Diskussion: Das Ergebnis ist die Entwicklung einer Morphologie der Wundversorgung, die eine klare, strukturierte und grafisch verständliche Übersicht aller wesentlichen Dimensionen ermöglicht. Die Morphologie wurde wiederholt gespiegelt, fachlich diskutiert und konsentiert. Sie versteht sich nicht als Handbuch, sondern als systematische und schnell erfassbare Orientierungshilfe.

Schlussfolgerung: Die gewonnenen Erkenntnisse unterstützen die strukturierte Analyse von Versorgungssituationen, erleichtern die interdisziplinäre Kommunikation und können gezielt in Schulungen und Trainings eingesetzt werden, um Verständnis, klinische Entscheidungs- & Strategiefähigkeit für Versorgungsqualität und Weiterentwicklungen in der Praxis zu fördern.

WUNDBEURTEILUNG

EP708 Anwendungsempfehlungen für SpinCare in der kinderchirurgischen Versorgung – ein Berliner Modell

Aileen Flach[1], Marcel Noatnick[1], Leila Harhaus-Wähner[2]

[1]Sana Klinikum Lichtenberg, Kinderchirurgie, Berlin, Germany, *[2]BG Klinikum Unfallkrankenhaus Berlin, Klinik für Hand-, Replantations- und Mikrochirurgie, Klinik für Schwerbrandverletzte und Plastische Chirurgie; Lehrstuhl für Hand-, Replantations-und Mikrochirurgie, Berlin, Germany*

Ziel: Vorgestellt werden soll eine Auswahl an Patient:innen, welche in domo mit SpinCare versorgt wurden. Anwendungsgebiete sind hier Gesicht, Kopf (post transplantationem), Genitale und Gesäß in der Kinderverbrennungsmedizin, sowie Anwendung bei Staphylokken Skin Scale Syndrom (SSSS). Es werden in einigen ausgewählten Fallbeispielen unsere Berliner **Standard Operating Procedure (SOP)** der SpinCare-Anwendung im Kindesalter erläutert.

Methode: Vorgestellt werden sollen hausinterne Fallberichte, in denen es zu einer Anwednung von SpinCare an in der kinderchirurgischen Versorgung kam. Vor allem im Bereich der kinderlichen Verbrennungsmedizin wenden wir SpinCare als Alternative zu regulären Verbandsanlagen regelmäßig an.

Resultat / Diskussion: Seit Oktober 2023 wird im Kinderbrandverletztenzentrum Sana Klinikum Lichtenberg in Kooperation mit dem Brandverletztenzentrum der BG Klinik Unfallkrankenhaus Berlin SpinCare regelhaft an Kindern mit adäquater Indikation angewendet, sodass sich eine Patientengruppe aus mehr als 75 Kindern ergeben hat.

Aus dieser Erfahrung hat sich im Laufe der Zeit ein Behandlungsstandard entwickelt, welchen wir nun gerne mit interessierten Kolleginnnen und Kollegen teilen würden.

Des Weiteren werden in der kinderchirurgischen Expertise neuerdings auch transiente dermale, infektiöser Erkrankungen mittels SpinCare versorgt.

Schlussfolgerung: Nach unseren Erfahrungen und mit dem erarbeiteten Standard ist die SpinCare-Technik eine echte Alternative zu den konventionellen Verbandsanlagen im Kindesalter und ermöglicht so den Kindern eine kindgerechte und schmerzfreie Versorgung ohne weitere Verbandswechsel oder Sedierungen. Wir wenden es aktuell standardisiert bei 2a-b gradigen thermischen Verletzungen im Kopf-Hals-Bereich, im Genital- und Glutealbereich und post transplantationem an. Abzuwarten bleibt, ob sich das Anwendungsgebiet unter kontrollierten medizinischen Bedingungen noch erweitern lässt.

EP723 Behandlung von Gesichtsverbrennungen einst versus heute

Michaela Berousek[1]

[1]Universitätsklinik für Plastische, Rekonstruktive und Ästhetische Chirurgie am AKH Wien, Intensivstation für Brandverletzte 13i1, Wien, Austria

Ziel: Brandverletzungen zählen zu den schwerwiegendsten Verletzungen, vor allem, wenn die Verletzung das Gesicht betrifft. Das Gesicht kann nicht verborgen werden, macht jede Veränderung des Aussehens sichtbar und hat große Auswirkung auf das weitere Leben der Patient:innen. Die Behandlung einer Gesichtsverbrennung spielt hier eine bedeutende Rolle, um physische und besonders psychische Auswirkungen für Betroffene möglichst gering zu halten. Das Ziel sollte sein, die bestmöglichen Heilungsergebnisse bei Gesichtsverbrennungen zu erreichen.

Methode: Herangezogen wurden Artikel aus Literaturrecherchen über Suchmaschinen im Internet zur Behandlung von Verbrennungen von der Antike bis ins 21. Jahrhundert. Die Qualität der Arbeiten wurde nicht bewertet. Behandlungsdaten der letzten Jahre sind Beobachtungen und Erfahrungsberichte von Patient:innen, die an unserer Klinik für Schwerbrandverletzte versorgt wurden.

Resultat / Diskussion: Aufgezeigt wird die Behandlung, die sich im Laufe der Jahrzehnte verändert hat. Vorgestellt werden Therapien aus der Antike bis hin zu zeitgemäßen Behandlungskonzepten im Wandel der Zeit.

Ziel der Behandlung von Gesichtsverbrennungen ist es, das Aussehen der Patient:innen so weit wie möglich wiederherzustellen. Der Behandlungserfolg hängt vom Schweregrad der Verletzung ab. Je tiefer und je größer die Verbrennung, desto schwieriger ist es, ein normales Aussehen des Gesichts zu erreichen. Die Versorgung von Gesichtsverbrennungen an unserer Klinik für Schwerbrandverletzte stellt eine vielseitige Herausforderung dar.

Schlussfolgerung: Da das Gesicht gut durchblutet ist, hat es ein hohes Potential zur Spontanheilung. Viele moderne Verbandstoffe unterstützen die konservativen Behandlungsstrategien. Die Rolle der Pflegepersonen, die hauptsächlich diese Therapien durchführt, sind ein wesentlicher Teil des Behandlungserfolges. Durch den Einsatz von Silberverbänden konnten in den letzten 20 Jahren viele 2- 3gradige Gesichtsverbrennungen konservativ behandelt werden. Das narbenfreie Gesicht bringt eine erhebliche Lebensqualität für Betroffene.

EP724 Sandbetttherapie bei Schwerbrandverletzte

Gunther Fuchs[1]

[1]Universitätsklinikum AKH Wien, Universitätsklinik für Plastische, Rekonstruktive und Ästhetische Chirurgie, Intensivstation für Schwerbrandverletzte 13i1, Wien, Austria

Ziel: Schwere Brandverletzungen, insbesondere am Rücken und Gesäß, stellen in der Akutversorgung von Brandverletzten eine erhebliche therapeutische Herausforderung dar. Die Notwendigkeit der dauerhaften Rückenlage des Patienten, oft bedingt durch gleichzeitige Verbrennungen an Rumpf, Armen oder Beinen, beeinträchtigt die Anheilungsraten von Transplantaten in diesen Bereichen durch Scherkräfte und persistierende Feuchtigkeit. Primäres Ziel dieser Arbeit ist es, die Wirksamkeit der Sandbetttherapie als wirksame Alternative zur sofortigen Operation am Rücken und Gesäß darzustellen.

Methode: Die der Analyse zugrunde liegenden Behandlungsdaten wurden auf empirischer Basis über einen Zeitraum von 15 Jahren retrospektiv erhoben. Untersucht wurden Patient:innen, die in unserer spezialisierten Klinik für Schwerbrandverletzte mit dorsalen Verbrennungen versorgt wurden.

Resultat / Diskussion: Die Arbeit erläutert detailliert die physikalische Funktion und die klinische Wirkungsweise des Sandbetts auf die offene dorsale Wundversorgung. Aufgrund der maximalen Druckentlastung durch das System kommt es zu einer signifikanten Reduzierung der Scher- und Reibungskräfte, wodurch eine weitere Schädigung des sensiblen, verbrannten Gewebes effektiv verhindert wird. Ein wesentlicher therapeutischer Effekt war die deutliche Reduktion der Keimlast, die durch die Schaffung eines trockenen Wundmilieus erreicht wurde. Physiologische Erkenntnisse zeigen zudem, dass die Epidermis und Dermis des Rückens stärker und besser durchblutet sind als an anderen Körperarealen, was das Ziel der konservativen Abheilung unterstützt.

Schlussfolgerung: Die langjährige klinische Erfahrung mit der konservativen Wundtherapie bei dorsalen Brandverletzungen durch das Spezialbett (Sands beziehungsweise Pearls) konnte eindrucksvoll belegen, dass das intrinsische Selbstheilungspotential des Rückens auch bei augenscheinlich drittgradigen (tiefen dermalen) Verbrennungen gegeben ist. Dieses Vor-gehen ermöglicht die konservative Behandlung von bis zu 18 % der Körperoberfläche nach der Neuner-Regel nach Wallace, ohne dass eine chirurgische Intervention mittels Spalthauttransplantation notwendig ist.

EP731 Einsatzmuster und DRG-Auswirkungen xenogener Hautersatzmaterialien bei Verbrennungen vor und nach der Kodierumstellung 2024 in Deutschland

Steffen Wahler[1], Christiane Koll[2]

[1]St. Bernward GmbH, Hamburg, Germany, *[2]Diabetespraxis Blankenese, Hamburg, Germany*

Ziel: Zum 1. Januar 2024 wurde ein neuer OPS-Code für den permanenten Hautersatz durch xenogene Materialien eingeführt, während der bisherige Dermisersatz-Code entfiel. Ziel dieser Untersuchung war es, den Einfluss dieser Kodierumstellung auf den klinischen Einsatz xenogener Hautersatzmaterialien bei Verbrennungen zu analysieren und deren Anwendung sowie DRG-Auswirkungen im Vergleich der Jahre 2023 und 2024 zu beschreiben.

Methode: Analysiert wurden die InEK-Abrechnungsdaten für 2023 und 2024. Berücksichtigt wurden ausschließlich Kodierungen für temporäre sowie permanente xenogene Hautersatzverfahren bei thermischen Verletzungen. Erhoben wurden demografische Daten, Hauptdiagnosen, Verbrennungsausdehnung, DRG-Zuordnungen und Verweildauer.

Resultat / Diskussion: Im Jahr 2023 wurden 220 Fälle mit permanentem Dermisersatz kodiert. Für 2024 ergeben sich 120 Fälle mit permanentem xenogenem Hautersatz. Diese Patientengruppe ist deutlich jünger (Median 15 Jahre) und weist eine kürzere Verweildauer (11,7 Tage) auf. Häufigste Hauptdiagnosen betrafen Verbrennungen dritten bzw. tief second-degree Grades der unteren Extremität. Temporäre xenogene Wunddeckungen blieben mit 200 Fällen (2023) und 166 Fällen (2024) stabil, zeigten jedoch 2024 eine deutliche Verschiebung in komplexere DRGs (Y03Z 53,6 %). Insgesamt steigt die Zahl xenogener Hautersatzkodierungen von 200 (2023) auf 286 (2024). Trotz geringerer Schweregrade der verbrannten Körperoberfläche bei permanent xenogen behandelten Patienten zeigte sich ein höheres Entgeltniveau, was auf eine veränderte DRG-Abbildung schließen lässt.

Schlussfolgerung: Die OPS-Neueinführung 2024 hat den dokumentierten Einsatz xenogener Hautersatzmaterialien bei Verbrennungen deutlich erhöht. Der permanente xenogene Hautersatz etabliert sich als eigenständige, zunehmend genutzte Behandlungsoption. Die vollständigen Jahresdaten 2024 werden weitere Einblicke in die Versorgungslandschaft thermischer Verletzungen ermöglichen.

POST-MARKET SURVEILLANCE

EP736 Fallbeispiel: Enterokutane Dünndarmfistel - Interdisziplinäres Wundmanagement

Jennifer Krautwald[1], Kerstin Heinemann[1], Gesine Mack[1]

[1]*Kath. Marienkrankenhaus Hamburg, Wundmanagement, Hamburg, Germany*

Ziel: Ziel dieser Falldarstellung ist die Analyse eines komplexen postoperativen Verlaufs mit enterokutaner Dünndarmfistel nach radikaler Zystektomie mit Ileum-Conduit und besonderer Berücksichtigung des spezialisierten Wundmanagements. Der Fokus liegt auf der evidenzbasierten Verzahnung chirurgischer, pflegerischer und wundtherapeutischer Interventionen zur effektiven Kontrolle der Fistelaktivität und Förderung der sekundären Wundheilung.

Methode: Es erfolgte eine retrospektive Fallanalyse des klinischen Verlaufs einer 68-jährigen Patientin im Zeitraum vom 02.10. bis 04.11.2025. Die Datenerhebung basierte auf der Auswertung ärztlicher Visitenprotokolle, Operationsberichte sowie pflegerischer Dokumentationen. Analysiert wurden die durchgeführten chirurgischen Interventionen, der Einsatz der vakuumassistieren Wundtherapie (VAC), Strategien des Drainage- und Exsudatmanagements, Maßnahmen zum periulcerären Hautschutz sowie nutritive und psychosoziale Begleitinterventionen im Rahmen des interdisziplinären Behandlungskonzeptes.

Resultat / Diskussion: Im fünfwöchigen Behandlungsverlauf waren mehrere chirurgische Revisionen aufgrund rezidivierender Dünndarmperforationen erforderlich. In jeder chirurgischen Revision erfolgten eine ausgedehnte Lavage sowie der primäre Fistelverschluss. Begleitend wurde eine subkutane VAC-Therapie mit intermittierendem Unterdruck eingesetzt, um kontrolliertes Exsudatmanagement, Reduktion der mikrobiellen Kontamination und Stimulation der Granulationsgewebsbildung zu erzielen. Postoperativ stand die gezielte Fistelversorgung unter Verwendung spezialisierter Fistelversorgungssysteme im Vordergrund, unterstützt durch stomaadaptierte Wundauflagen, Silikonbarrieren und individuell konfigurierte Hautschutzringe zur Stabilisierung des periulcerären Hautzustands. Durch engmaschige klinische Überwachung, gezielte Steuerung der Drainageleistung und nutritive Supportmaßnahmen konnte die Fistelausfuhr sukzessive reduziert und eine primäre Wundheilung erzielt werden.

Schlussfolgerung: Der Fall verdeutlicht, dass die erfolgreiche Behandlung persistierender enterokutaner Dünndarmfisteln ein strukturiertes, interdisziplinäres Fistel- und Wundmanagement erfordert. Der Heilungserfolg beruhte auf der Kombination wiederholter chirurgischer Revisionen, gezielter Fistelversorgung, adäquatem Hautschutz sowie fachgerechter pflegerischer Betreuung. Darüber hinaus erwiesen sich die interprofessionelle Koordination und frühzeitige psychosoziale Unterstützung als essenzielle Komponenten einer effektiven, patientenzentrierten Wundheilung.

EP737 Therapieoption bei aussichtslosen Wunde: Intact fish skin graft?

Thomas Kapp[1]

[1]*Spital Aarberg Inselgruppe, Chirurgie, 3270, Switzerland*

Ziel: Chronisch kritische Wunden mit freiliegenden Strukturen wie Schädelknochen oder Sehnen gelten häufig als therapeutisch aussichtslos. In den letzten Jahren hat sich das aus isländischer Kabeljauhaut gewonnene, dehydrierte intact fish skin graft (iFSG) als vielversprechende Option etabliert. Das Material zeichnet sich durch seine natürliche extrazelluläre Matrix, einen hohen Omega-3-Fettsäuregehalt und eine strukturelle Ähnlichkeit zur menschlichen Haut aus.

Methode: In dieser Übersicht werden aktuelle klinische Erfahrungen und Fallserien zur Anwendung von iFSG bei Wunden diskutiert, die aufgrund avitaler Weichteildefekte, Exposition von Knochen oder Sehnen oder fehlender lokaler Durchblutung traditionell eine plastisch-chirurgische Intervention erfordern. Besondere Aufmerksamkeit liegt auf Wunden mit freiliegender Schädeldecke sowie freiliegenden Sehnen ohne Restbedeckung.

Resultat / Diskussion: Mehrere Fallberichte zeigen, dass iFSG selbst in scheinbar hoffnungslosen Situationen eine schnelle Granulationsgewebsbildung induzieren kann. Die Matrix unterstützt Zellmigration, moduliert Entzündungsprozesse und schafft ein günstiges mikrobielles Milieu. Dadurch konnten Wunden, die als nicht deckungsfähig galten, innerhalb weniger Wochen einen stabilen Granulationsgrund entwickeln und sekundär epithelialisieren oder für eine definitive Deckung vorbereitet werden. Besonders bei freiliegender Schädelkalotte wurde eine rasche Gewebeproliferation dokumentiert, ohne die Notwendigkeit komplexer Lappenplastiken.

Schlussfolgerung: Das intakte Fischhaut-Transplantat stellt eine biologisch aktive, leicht anwendbare und kosteneffiziente Therapieoption für komplexe Wunden mit exponierten Strukturen dar. Auch wenn kontrollierte Studien nötig sind, deuten aktuelle Daten darauf hin, dass iFSG die Heilung selbst bei bisher als aussichtslos eingestuften Defekten ermöglichen kann.

EP738 Versorgung einer Laparostomie mit Dünndarmfistel und high Outputsymptomatik

Annette Buhl[1]

[1]*Klinikum Oberberg, Wundmanagement/Stomatherapie, Gummersbach, Germany*

[2]*Pflegetherapeutin Wunde ICW/ TÜV, Pflegeexpertin Stoma-Kontinenz-Wunde FgSKW, Wundassistentin DDG*

Ziel: Versorgung einer anspruchsvollen Wundsituation mit großer Bauchwunde und high Output Fistel als Komplikation nach einer Gynäkologischen Operation bei Endometrium Karzinom. Eine Versorgungssicherheit unter der Anwendung von cohesiven Wunddrainagebeuteln soll gewährleistet werden. Dabei sollen feuchtigkeitsbedingte Hautschäden vermieden oder minimiert werden. Bis zur möglichen chirurgischen Intervention wird eine häusliche Versorgung über einen Pflegedienst angestrebt. Ein Versorgungsintervall von ca. 5-6 Tagen wird durch ein adäquates Überleitungsmanagement ermöglicht. Die medizinische Gesamtsituation wird stabilisiert und eine operative Fistelentfernung mit Wundverschluss ermöglicht.

Methode: Fallstudie.

Resultat / Diskussion: Besondere Wundsituationen mit Versorgungsschwierigkeiten erfordern den Einsatz von einfach zu handhabenden, aber dennoch hocheffizienten Materialien. Erhöhte Materialkosten rechnen sich durch eine hautschonende cohesive Eigenschaft, ausreichendem Exsudatmanagement und langer Klebefähigkeit des Materials und so, mit einem deutlich verlängertem Versorgungswechselintervall. Die Steigerung der Lebensqualität der Patientin und eine Einsparung der Versorgungskosten im Krankenhaus rechtfertigen den erhöhten personellen Einsatz für das Überleitungsmanagement und der Anleitung des übernehmenden Pflegedienstes.

Schlussfolgerung: Eine adäquate Versorgung der Wundsituation bei Laparostomie mit Dünndarmfistelbildung und high Output Symptomatik wäre ohne die Verwendung von cohesiven Wunddrainagesystmen nicht möglich gewesen.

Hochwertiges Material mit hoher Aufnahmekapazität von Exsudat oder Ausscheidung hat dazu beigetragen einen

ausreichenden Wundrandschutz zu ermöglichen, die Verbandwechselintervalle auf 5-6 Tage einpendeln zu lassen und der Patientin eine Versorgung zu Hause zu ermöglichen.

Eine normale Stomaversorgung wäre wegen der Wundgröße und der ausgeprägten Reliefunebenheiten der peristomalen Umgebung nicht möglich gewesen.

Eine detaillierte Anleitung zur Versorgung ist unbedingt notwendig, damit auch Personen, die ungeübt in der Fistelversorgung sind, einen sicheren Umgang mit dem notwendigen Material bekommen und somit eine sichere Versorgung gewährleisten können.

German oral presentations

VERBRENNUNGEN

OP143 Behandlung von Gesichtsverbrennungen bei Kindern mit einer Polylactid-Basierten syntetischen Dermalmembran

Victor Loza-González[1], Mario Aurelio Martínez-Jimenez[2], Ana Lorena Novoa-Moreno[3], Eleazar Samuel Kolosovas-Machuca[4], Jose Ramirez-Garcialuna[5]

[1]Institutional Doctorate of Engineering and Materials Science of the Autonomous University of San Luis Potosí, San Luis Potosi, Mexico, *[2]Burn Unit of the High Specialty Regional Hospital „Ignacio Morones Prieto“, San Luis Potosí, Mexico*, *[3]Medicine Faculty of the Autonomous University of San Luis Potosí, San Luis Potosí, Mexico*, *[4]Coordination for the Innovation and Application of Science and Technology (CIACYT), Autonomous University of San Luis Potosí, San Luis Potosí, Mexico*, *[5]Division of Experimental Surgery, Faculty of Medicine, McGill University, Montreal, QC, Canada*

Ziel: Ziel dieser Studie war es, die klinische Wirksamkeit einer synthetischen Polylactid-Dermalmembran bei der Behandlung kindlicher Gesichtsverbrannungen zu untersuchen und deren Einfluss auf Heilungsdauer, Krankenhausaufenthalt und Bedarf an Nachbehandlungen zu bewerten.

Methode: Zwischen September 2024 und September 2025 wurde eine Kohortenstudie an pädiatrischen Patienten mit Gesichtsverbrennungen durchgeführt. Die Applikation der Membran erfolgte im Notfallbereich unter leichter Sedierung nach gründlicher Spülung der betroffenen Areale mit physiologischer Kochsalzlösung. Die Membran wurde direkt auf das Wundbett aufgelegt, ohne sekundäre Wundauflage. Der vollständige Abbau erfolgte innerhalb von 48–72 Stunden nach Applikation. Nach nahezu vollständigem Wundverschluss erhielten die Patienten standardisierte Anweisungen zur häuslichen Nachsorge und wurden mittels wöchentlicher Kontrollen nachbetreut.

Resultat / Diskussion: Insgesamt wurden 152 Patienten in der Verbrennungseinheit behandelt, davon 55 % Kinder. Die häufigsten Ursachen der thermischen Verletzungen waren Verbrühungen (55 %), gefolgt von direkter Flammeneinwirkung (15 %) und elektrischen Verletzungen (5 %). Gesichtsverbrennungen traten bei 81 % der pädiatrischen Patienten auf. Es fanden sich oberflächliche zweitgradige (14 %), tief zweitgradige (8 %) und drittgradige Verbrennungen (6 %). Eine Entlassung innerhalb von 48 Stunden war bei 55 % der Patienten möglich, innerhalb von 72 Stunden bei weiteren 35 % und am fünften Tag wurden die restlichen 10 % der Patienten entlassen. Hauttransplantationen waren in keinem Fall erforderlich. Es traten weder Infektionen noch andere unerwünschte Ereignisse auf; Analgetika wurden nicht benötigt.

Schlussfolgerung: Polylactid-Hautersatz ermöglicht eine standardisierte, sichere und effiziente Behandlung kindlicher Gesichtsverbrennungen mit zeitnaher Entlassung und geringem Bedarf an häuslicher Pflege. Die Therapie stellt eine empfehlenswerte Option für diese Patientengruppe dar.

DIABETISCHES FUSSSYNDROM

OP147 „Fußwaschkampagne“: Eine Strategie zur Vorbeugungsmaßnahme von Fußgeschwüren bei Menschen mit Diabetes mellitus in Brasilien

Camilla Andrade[1], Lidiany Felix[2], Kleane Araújo[2], Auridete Almeida[3]

[1]APS Santa Marcelina, São Paulo, Brazil, *[2]Universidade Federal de Campina Grande, Paraíba, Brazil*, *[3]Secretaria Municipal de Saúde de Campina Grande, Campina Grande, Brazil*

Ziel: Schätzungsweise 20 Millionen Brasilianer leben mit Diabetes mellitus (DM), der häufigsten Ursache für Amputationen der unteren Extremitäten im Land. Ziel ist es, über die Erfahrungen mit der Kampagne „Fußwaschen“ zu berichten, einer sozialen Aktion zur Prävention von Fußgeschwüren bei Menschen mit DM. Diese Initiative basiert auf einer nationalen Strategie des Gesundheitsministeriums, die Bevölkerung über die Risiken von DM aufzuklären und die Gesundheitserziehung zu fördern, indem sie Prävention mit der christlichen Symbolik von Ostern (der Fußwaschung Jesu) verknüpft.

Methode: Dies ist eine deskriptive Studie, ein Erfahrungsbericht, der im April 2025 in einer Familienmedizinischen Primärversorgungseinheit im Nordosten Brasiliens durchgeführt wurde. Die Aktivität wurde von Professoren und Studierenden des Studiengangs Pflege an der Bundesuniversität Campina Grande in Zusammenarbeit mit den Pflegekräften der Einrichtung organisiert.

Resultat / Diskussion: Die soziale Maßnahme umfasste die Mobilisierung der Bevölkerung durch die Verteilung von Einladungen durch Gemeindegesundheitshelfer. Fünfzig Menschen mit DM nahmen an der Intervention teil. Bei ihrer Ankunft in der Gesundheitseinrichtung wurden die Füße der Patienten von Krankenpflegeschülern und/oder Dozenten untersucht und gewaschen; außerdem wurden Fußinspektion und -hygiene durchgeführt. Dies ermöglichte es, die Patienten zu empfangen und zur Früherkennung möglicher Veränderungen beizutragen. Zusätzlich wurden Blutdruck und Blutzuckerwerte gemessen sowie eine vollständige körperliche Untersuchung der Füße durchgeführt (Tast- und Vibrationssensibilitätstest und Pulspalpation). Die Fälle mit Auffälligkeiten wurden besprochen und an das Ärzteteam weitergeleitet. Die Patienten erhielten Beratung zu Fußpflegemaßnahmen, Behandlung und Diabetes-Kontrolle.

Schlussfolgerung: Die soziale Aktion hat akademische Ausbildung und Gesundheitswesen in die Gemeinschaft. Die „Fußwaschkampagne“ zeigte das Potenzial, die Vernetzung zu fördern und das Wissen über Diabetes und seine Komplikationen zu vertiefen sowie den Zugang zu präventiver Gesundheitsversorgung auf eine ansprechende uns menschliche zu veranstalten, insbesondere im Kontext der Primärversorgung.

AUSBILDUNG

OP144 Aktuelle Studien zu Verbandsmaterialien zur Symptombehadlung bei malignen Wunden

Sofia Marantidou[1], Anastasia Tsichlakidou[2]

[1]*Helios Klinikum Krefeld, Krefeld, Germany*, [2]*Metaxa Cancer Hospital Piraeus, Greece, Athens, Greece*

Ziel: Das Ziel der Recherche war die systematische Erfassung aktueller Daten zur Symptom Behandlung maligne Wunden. Die Ergebnisse wurden mit einer früheren systematischen Übersicht (2008- 2017) verglichen.

Methode: Eine systematische Übersichtsarbeit wurde durchgeführt, um Originalforschungen zum Symptommanagement maligne Wunden zu identifizieren. Dabei wurden Schüsselwörter und ein zeitlicher Rahmen für den Zeitraum 2018 - 2024 in der Online- Datenbank Medline (NCBI) unter Verwendung kombinierter Ein- und Ausschlusskriterien angewendet.

Resultat / Diskussion: Insgesamt erfüllten elf originelle Studien die Einschluskriterien: drei randomisierte kontrollierte Studien, fünf Fallstudien und drei Beobachtungsstudien. Neun dieser Studien beschrieben den Einsatz spezifischer Lokaltherapien zur Symptomkontrolle. Insgesamt wurden 216 Patienten*innen mit verschieden Materialien behandelt, darunter oxidierte regenerierte Zellulose, Calciumalginat, Silberhaltige Sulfadiazinpräparate, Hydrogel, Polyhexanid , Metronidazol, Hydrofaserverbände mit oder ohne Silber, Paste- Mohs, Adrenalin sowie nicht haftende Verbände. Den Ergebnissen der RCT-Studien zufolge zeigten Metronidazol und Polyhexanid eine vergleichbare Wirksamkeit bei der Behandlung von Geruchsbildung. Die Blutungskontrolle wurde durch den Einsatz von Calciumalginat und oxidierter regenerierter Zellulose.

Schlussfolgerung: Die Ergebnisse deuten darauf hin, dass kostengünstigere Materialien wie Polyhexanid und Metronidazol zunehmend an Bedeutung gewinnen, nachdem frühere Studien vor allem teurere Produkte wie Silber und Manuka- Honig hervorhoben. Angesichts des hohen palliativen Versorgungsbedarfs besteht weiterer Forschungsbedarf zur Bewertung des Nutzen- Kosten- Verhältnisses dieser Therapien.

INFEKTION

OP141 Alte Idee neu Gedacht: Bakteriophagen als Therapie gegen Antibiotika-Resistente Eskape-Bakterienilm translationalen Biofilmmodell

Nicolas Krüger[1], Mandy Dittmer[1], Sophie Charlotte Liegenfeld[1], Maria Geffken[1], Univ-Prof. Dr. Ewa Klara Stürmer[1]

[1]*Universitätsklinikum Hamburg-Eppendorf, Hamburg, Germany*

Ziel: Der Einsatz von Bakteriophagen zur Bekämpfung multiresistenter Bakterien ist aufgrund ihrer hohen Spezifität und Wirksamkeit eine vielversprechende Alternative zur etablierten Antibiotikatherapie. Besonders bei chronischen Wundinfektionen mit Antibiotika-resistenten ESKAPE-Bakterien wie *Pseudomonas aeruginosa* könnten Phagen konkurrenzfähige therapeutische Optionen sein. Klinische Fallberichte demonstrieren Heilungserfolge und zahlreiche *in-vitro* Studien zeigen vielversprechenden Ergebnisse. Translationale Settings sind notwendig, um die präklinische Lücke zu schließen und die Wirksamkeit und Sicherheit von Phagen faktisch zu untermauern.

Methode: Zur Analyse der Wirkung von Bakteriophagen wurde ein Biofilmmodel aus humanem Plasma, Buffy Coat (Immunzellen) und *P. aeruginosa* PA14 etabliert. Phagenlysate wurden unter Verwendung standardisierter Protokolle isoliert und angereichert. Die Biofilm-Modelle wurde täglich mit zwei unterschiedlichen Phagen-Lysaten sowie deren Kombination behandelt und die Anzahl noch lebenden Bakterien nach 24, 48 und 72 Stunden bestimmt. Der Behandlungseffekt wurde anhand von konfokaler Laserscanning-Mikroskopie visualisiert sowie durch quantitative Suspensionsverfahren und Bildzytometrie analysiert.

Resultat / Diskussion: Alle Behandlungen mit *P. aeruginosa*-spezifischen Phagen führten zu einer signifikanten Reduktion der Bakterienzahl und des Biofilmvolumens. Die kombinierte Anwendung, sog. Phagen-Cocktails erzielte in diesem Fall keine höhere Eradikation, was darauf hinweist, dass die Phagenzahl maßgeblich ihre Wirksamkeit bestimmt. Cocktails aus mehreren Phagen sind jedoch weiterhin klinisch relevant, um eine Wirksamkeit gegen das komplexe Mikrobiom von Wundbiofilmen zu gewährleisten.

Schlussfolgerung: Spezifische Phagen reduzieren im Single-Spezies-Biofilmmodell *P. aeruginosa* signifikant, was klinische Fallberichte untermauert. Mittelfristig ist weitere Forschung zu Infektionsmechanismen und möglichen Wechselwirkungen mit humanen Zellen erforderlich. Langfristig eröffnet dies die Chance, individualisierte Phagentherapien für schwer behandelbare, Antibiotika-resistente Infektionen akuter und chronischer Wunden zu entwickeln. Bei zunehmender antimikrobieller Resistenz von Bakterien sollten Bakteriophagen wieder mehr als Therapieoption in Erwägung gezogen werden.

ULCUS CRURIS

OP140 Antimikrobielle Kontrolle als Voraussetzung: Biodegradable Matrix alleine Reicht unter Infektion nicht

Sophie Charlotte Liegenfeld[1], Niklas Philipp Straub[1], Mandy Dittmer[1], Nicolas Krüger[1], Arianna Delle Coste[2], Jan Tinson Strenge[2], Sophie Charlotte Rhode-Wedrich[3], Univ-Prof. Dr. Ewa Klara Stürmer[1]

[1]Universitätsklinikum Hamburg-Eppendorf, Klinik für Gefäßmedizin, Hamburg, Germany, *[2]Universitätsklinikum Hamburg-Eppendorf, Klinik für Mund-, Kiefer- und Gesichtschirurgie, Hamburg, Germany*, *[3]Universitätsklinikum Hamburg-Eppendorf, Abteilung für Plastische, Rekonstruktive und Ästhetische Chirurgie, Hamburg, Germany*

Ziel: Chronische und/oder bakteriell infizierte Wunden bleiben häufig therapierefraktär, da durch Biofilmbesiedlung die Migration von Fibroblasten und die Reepithelisierung behindert werden. Im Gegensatz dazu können akute, nicht infizierte Wunden heilen, wenn das physiologische Mikroenvironment stabilisiert wird. Seidenfibroin ist ein vielversprechendes, biokompatibles und biodegradables Material, dessen Struktur die Wundheilung unterstützen kann. Im folgenden Projekt werden zwei unterschiedlich strukturierte Matrices in einem standardisierten humanen *ex-vivo*-Hautwundmodell unter nicht infizierten und infizierten (chronisch-ähnlichen) Bedingungen analysiert.

Methode: Humanen Vollhautstanzen wurde zentral eine 3-mm-Wunde gesetzt und diese im Air-Lift bis zu 20 Tagen kultiviert. Fibroinmembranen oder elektrogesponnene Vliese wurden passgenau in die Wunden eingebracht. In infizierten Modellen wurden Inokula von *Staphylococcus aureus* oder *Pseudomonas aeruginosa* appliziert. Mittels verblindeter Histomorphologie und Histomorphometrie (H&E, Gram) wurden Reepithelisierung, Lokalisation der Bakterien im Gewebe sowie die Infektionsdynamik mit und ohne Membranen/Vlies analysiert.

Resultat / Diskussion: In nicht infizierten Wunden beschleunigten beide Wundmatrices die Heilung im Vergleich zur Kontrolle. Membranen unterstützten konsistent eine schnelle, nahezu kontinuierliche Reepithelisierung, indem sie ein glattes Migrationssubstrat und eine frühe Barriere bildeten. Vliese führten zu stärkerer dermaler Interaktion mit zellulärer Infiltration entlang der Fasern, jedoch mit langsamerem epithelialem Verschluss im Vergleich zu den Membranen. Im bakteriellen Infekt-Setting verloren die Matrices ihr Wundheilungs-förderndes Potenzial: Ein epithelialer Verschluss wurde nicht erreicht, und Gramfärbungen zeigten eine persistierende Kolonisation.

Schlussfolgerung: Die Struktur von Seidenfibroin birgt viele Vorteile für die Wundheilung: Membranen wirken als „Startbahnen“ für Keratinozyten, während Vliese als permissive 3D-Gerüste durch Einwachsen Wunden schließen. Unter Infektionsbedingungen verlieren sie jedoch ihre Effektivität. Die Ergebnisse unterstreichen einmal mehr die Notwendigkeit der Reduktion der bakteriellen Keimlast als Voraussetzung für die Wundheilung. „Antimikrobiellen“ Fibroin-Matrices zur Beschleunigung des Wundverschlusses könnten ein Lösungsansatz für chronische und infizierte Wunden sein.

UNTERDRUCK WUNDTHERAPIE

OP142 Gemeinsam besser heilen? Interprofessionelle Wundversorgung beim Ulcus cruris venosum – Einfluss auf Adhärenz, Lebensqualität, Heilung und Versorgungsqualität

Sarah Fabisch[1], Adriana Nowka[1], Anja Naumann[1]

[1]*Medizinische Universität Lausitz - Carl Thiem, Lübben, Germany*

Ziel: Untersucht wurde die aktuelle Evidenz zur Wirksamkeit interprofessioneller Versorgungsansätze beim Ulcus cruris venosum (UCV) und deren Einfluss auf Therapieadhärenz, Lebensqualität, Wundheilung und Versorgungsqualität.

Methode: Ein Rapid Review (PubMed, CINAHL, Cochrane Library; 2015-2025) schloss systematische Reviews und kontrollierte Studien zu interprofessionellen bzw. multidisziplinären Interventionen bei UCV mit mindestens einem der vier Outcomes ein. Die Qualitätsbewertung erfolgte mittels CASP und RoB-2.

Resultat / Diskussion: Vier Arbeiten erfüllten die Einschlusskriterien (Bossert et al. 2023; Weller et al. 2016; Probst et al. 2025; Senft et al. 2023). Insgesamt zeigen interprofessionelle Edukations- und Versorgungsprogramme konsistent eine Verbesserung der Therapieadhärenz, wie beispielsweise hinsichtlich der Steigerung von Leitlinienkonformität, einer erhöhten Selbstwirksamkeit und Wissenszuwachs (Probst et al. 2025; Senft et al. 2023). Trotz der nachweislich verbesserten Adhärenz führen diese Interventionen nicht zuverlässig zu schnelleren oder vollständigen Heilungen. Dies deutet darauf hin, dass die Adhärenz allein nicht ausreicht, da die Heilung von UCV stark durch multifaktorielle Pathogenese beeinflusst wird. Beobachtungszeiträume von 12-16 Wochen und heterogene Interventionsinhalte erschweren die Interpretation der Befunde. Hinsichtlich der Lebensqualität zeigen die Studien heterogene Befunde. Unterschiedliche Erfassungsmethoden und fehlende Standardisierung der Messinstrumente erschweren eine konsistente Bewertung. Auch für die Versorgungsqualität bestehen Forschungslücken. Während Senft et al. (2023) indirekt verbesserte strukturierte Prozesse und Leitlinienkonformität durch Case Management nachweisen, fehlen direkte patient*innenorientierte Qualitätsmessungen. Insgesamt verdeutlichen die Ergebnisse, dass interprofessionelle Versorgung zwar die Adhärenz signifikant verbessern kann, die Übertragung auf klinische Endpunkte wie Heilung und Lebensqualität jedoch bislang nicht eindeutig belegt ist.

Schlussfolgerung: Interprofessionelle Versorgung verbessert die Therapieadhärenz bei UCV. Positive Effekte auf Wundheilung und Lebensqualität sind nicht konsistent belegt. Methodisch robuste Langzeitstudien mit standardisierten Interventionen und Outcomes sind erforderlich, um klinische Wirksamkeit interprofessioneller Versorgungsmodelle zu evaluieren.

DEKUBITUS

OP142 Gemeinsam besser heilen? Interprofessionelle Wundversorgung beim Ulcus cruris venosum – Einfluss auf Adhärenz, Lebensqualität, Heilung und Versorgungsqualität

Sarah Fabisch[1], Adriana Nowka[1], Anja Naumann[1]

[1]*Medizinische Universität Lausitz - Carl Thiem, Lübben, Germany*

Ziel: Untersucht wurde die aktuelle Evidenz zur Wirksamkeit interprofessioneller Versorgungsansätze beim Ulcus cruris venosum (UCV) und deren Einfluss auf Therapieadhärenz, Lebensqualität, Wundheilung und Versorgungsqualität.

Methode: Ein Rapid Review (PubMed, CINAHL, Cochrane Library; 2015-2025) schloss systematische Reviews und kontrollierte Studien zu interprofessionellen bzw. multidisziplinären Interventionen bei UCV mit mindestens einem der vier Outcomes ein. Die Qualitätsbewertung erfolgte mittels CASP und RoB-2.

Resultat / Diskussion: Vier Arbeiten erfüllten die Einschlusskriterien (Bossert et al. 2023; Weller et al. 2016; Probst et al. 2025; Senft et al. 2023). Insgesamt zeigen interprofessionelle Edukations- und Versorgungsprogramme konsistent eine Verbesserung der Therapieadhärenz, wie beispielsweise hinsichtlich der Steigerung von Leitlinienkonformität, einer erhöhten Selbstwirksamkeit und Wissenszuwachs (Probst et al. 2025; Senft et al. 2023). Trotz der nachweislich verbesserten Adhärenz führen diese Interventionen nicht zuverlässig zu schnelleren oder vollständigen Heilungen. Dies deutet darauf hin, dass die Adhärenz allein nicht ausreicht, da die Heilung von UCV stark durch multifaktorielle Pathogenese beeinflusst wird. Beobachtungszeiträume von 12–16 Wochen und heterogene Interventionsinhalte erschweren die Interpretation der Befunde. Hinsichtlich der Lebensqualität zeigen die Studien heterogene Befunde. Unterschiedliche Erfassungsmethoden und fehlende Standardisierung der Messinstrumente erschweren eine konsistente Bewertung. Auch für die Versorgungsqualität bestehen Forschungslücken. Während Senft et al. (2023) indirekt verbesserte strukturierte Prozesse und Leitlinienkonformität durch Case Management nachweisen, fehlen direkte patient*innenorientierte Qualitätsmessungen. Insgesamt verdeutlichen die Ergebnisse, dass interprofessionelle Versorgung zwar die Adhärenz signifikant verbessern kann, die Übertragung auf klinische Endpunkte wie Heilung und Lebensqualität jedoch bislang nicht eindeutig belegt ist.

Schlussfolgerung: Interprofessionelle Versorgung verbessert die Therapieadhärenz bei UCV. Positive Effekte auf Wundheilung und Lebensqualität sind nicht konsistent belegt. Methodisch robuste Langzeitstudien mit standardisierten Interventionen und Outcomes sind erforderlich, um klinische Wirksamkeit interprofessioneller Versorgungsmodelle zu evaluieren.

Abstracts presented at the EWMA Cooperating Organisations Session 2026

Session title: Advocacy at national level for political change regarding wound care and wound healing including data registration

The following abstracts have not undergone peer review by the EWMA Scientific Committee but have been approved through a separate process.

Advocacy for universal reimbursement: a strategic initiative for equitable wound care in Portugal

Katia Furtado[1,2]

[1]Comprehensive Health Research Centre (CHRC), Universidade de Évora, 7000-671 Évora, Portugal; [2]Outpatient Department, Hospital of Portalegre, Unidade Local de Saúde do Alto Alentejo, 7300-312 Portalegre, Portugal

Aim: To present the national advocacy campaign led by the Portuguese Wound Society (ELCOS) to achieve universal reimbursement for therapeutic wound dressings and compression materials in outpatient settings, ensuring equitable access to care for all citizens.

Method: ELCOS initiated a formal public petition addressed to the highest national authorities, including the President of the Republic and the Parliament. The campaign's strategy was built on two pillars: the use of clinical evidence regarding the socio-economic burden of chronic wounds—such as pressure ulcers and diabetic foot—and the establishment of partnerships with healthcare professionals to lobby for changes in current reimbursement legislation. This was further supported by diagnostic studies identifying structural gaps in the national healthcare system, specifically the lack of formal Wound Prevention and Treatment Committees in 56% of institutions.

Results / Discussion: In the current Portuguese context, wound care products are only free of charge when administered within National Health Service (NHS) institutions. However, there is no reimbursement for these materials in outpatient settings or community pharmacies, with the exception of ostomy products. This creates a significant "reimbursement gap" for patients following hospital discharge, often leading to treatment discontinuation due to financial constraints, which increases morbidity, amputation rates, and long-term hospital costs. The petition specifically proposes the reimbursement of all therapeutic dressings and compression devices for lower limb venous pathology when prescribed by clinical teams. Furthermore, the advocacy efforts highlight that while nurses have autonomy in product selection, the lack of regulated nurse prescribing remains a barrier to streamlined community care.

Conclusion: The findings from ELCOS's advocacy work confirm that the lack of outpatient reimbursement is a major driver of health inequality in Portugal. Establishing a formal legal framework for reimbursement and legitimizing specialized wound committees are critical priorities. These measures would not only improve clinical outcomes and accelerate healing but also ensure social justice by protecting the most vulnerable populations from the high costs of chronic wound management.

Advocacy for wound care policy development in Türkiye: The role of the Wound Ostomy and Incontinence Nurses' Society

Zehra Göçmen Baykara[1,8], Şenay Gül[2,8], Derya Karakaya[3,8], Aysel Ören Hin[4,8], Emel Gülnar[5,8], Emine Sezgünsay[6,8], Ayişe Karadağ[7,8]

[1]*Faculty of Nursing, Gazi University, Ankara, Türkiye*
[2]*Faculty of Nursing, Hacettepe University, Ankara, Türkiye*
[3]*Pursaklar State Hospital, Ankara, Türkiye*
[4]*Stomatherapy Unit, Gazi University Hospital, Ankara, Türkiye*
[5]*Faculty of Health Sciences, Kırıkkale University, Kırıkkale, Türkiye*
[6]*Department of Nursing, Faculty of Health Sciences, İzmir University of Economics, İzmir, Türkiye*
[7]*School of Nursing, Koç University, Istanbul, Türkiye*
[8]*The Executive Board, Wound, Ostomy and Incontinence Nurses Association, Ankara, Türkiye*

Background: Professional organizations play a critical role in shaping healthcare policy by representing the collective expertise of clinicians, advocating for evidence-based practice, and contributing to the development of standards, education, and regulatory frameworks. Through collaboration with policymakers and other stakeholders, professional societies help translate clinical evidence into policies that improve patient outcomes and strengthen healthcare systems.[1,2] In line with these global frameworks, specialized nursing associations are essential drivers for establishing localized clinical standards and national care pathways.[3-5]
The Wound Ostomy and Incontinence Nurses' Society (YOIHD) is a national professional nursing organization founded in 2008 in Türkiye to advance professional development and improve the quality of care for patients with wounds, ostomies, and incontinence. YOIHD plays an active role in advocacy to strengthen wound care practice, education, and policy at the national level.

Methods: To evaluate and document YOIHD's policy contributions, a descriptive review of the Society's organizational structure, national activities, and stakeholder collaborations was conducted. As of December 2025, data from the Society's seven region and five active sub-commissions (Research, Publishing, Education, Membership, and Social Engagement) were analyzed. The scope of methodology encompasses YOIHD's ongoing participation in Ministry of Health workshops, curriculum development task forces, and national policy reporting mechanisms.

Results: The Society effectively represents 325 members across Türkiye. A major focus of YOIHD's advocacy activities has been contributing to the development and modernization of the national certification programme for stoma and wound care nurses regulated by the Turkish Ministry of Health. Society representatives have actively participated in curriculum revisions and supported the transition of theoretical components into online learning modules, improving accessibility and national standardization of wound care education. YOIHD experts are regularly invited to national workshops organized by the Ministry of Health to review and update the certification programme.
In addition to educational advocacy, the Society contributes to policy discussions by organizing national meetings and workshops where clinical challenges, professional issues, and patient care concerns in wound management are systematically discussed. Outcomes and recommendations from these meetings are documented and shared with the Ministry of Health to inform policy dialogue. Members of the YOIHD board also participate in governmental committees responsible for determining medical device standards and reimbursement policies, providing expert clinical input on wound care products used in hospitals.
YOIHD strengthens its advocacy efforts through partnerships with national and international stakeholders. At the national level, the Society collaborates with the Turkish Nurses Association and other specialty nursing organizations to advocate for professional recognition, improved working conditions, and professional rights of wound care nurses. Collaborative activities are also conducted with surgical and critical care societies. Internationally, YOIHD maintains active engagement with organizations such as EWMA, EPUAP, and ISTAP, facilitating knowledge exchange and strengthening advocacy for evidence-based wound care practices.

Conclusion: Through research initiatives, guideline dissemination, educational activities, and policy engagement, YOIHD continues to support evidence-informed decision-making and contributes to the advancement of wound care policy and practice in Türkiye.

References

1. World Health Organization. Health Policy and Systems Support to Optimize Community Health Worker Programmes. Geneva: WHO; 2018.
2. International Council of Nurses. Guidelines on Advanced Practice Nursing 2020. Geneva: ICN; 2020.
3. Wound, Ostomy and Continence Nurses Society (WOCN). Available from: https://www.wocn.org
4. World Council of Enterostomal Therapists (WCET). Available from: https://wcetn.org
5. Wound, Ostomy and Incontinence Nurses Society (YOİHD). Available from: https://www.yoihd.org.tr/tr

Patient education as a national advocacy strategy for wound prevention and early management: the AISLeC experience

Castiello Gianluca[1], Bond Silvia[1], Maffeini Pamela[1], Trentini Elisa[1], Ardondi Mirco[1], Borsani Valeria[1], Campoli Alessia[1], Vanzi Valentina[1], Ghizzardi Greta[1]

[1]*The AISLeC PePip Study Group*

Background: Patients' daily decisions and activities significantly influence wound healing outcomes, often independently of healthcare providers. Patient-centred education and effective self-management are therefore essential components of wound care plans. Appropriate education and improved adherence can reduce episodes of care, decrease healthcare expenditures, and prevent serious complications. Importantly, prevention and early intervention at the onset of skin lesions frequently occur at home, often in the absence of specialised healthcare professionals, placing responsibility on patients and their caregivers. Recognising this need, the Italian Association for the Study of Skin Lesions (AISLeC) has developed a multidisciplinary national advocacy initiative aimed at strengthening public awareness and supporting patient engagement at both hospital and community levels in order to promote patient education and awareness in wound prevention and early management.

Methods: The programme was developed through collaboration between AISLeC members, healthcare institutions, and communication experts. Partnerships included healthcare professionals, librarians, and literacy specialists who contributed to translating scientific wound care knowledge into language that is accessible and understandable for the general population. The initiative developed two complementary educational tools: 1. patient-oriented educational brochures focusing on common skin lesions (pressure injuries, skin tears, incontinence-associated dermatitis, radiodermatitis, and diabetic foot). These materials were designed using accessible graphics and plain language adapted from scientific content; 2. educational podcasts targeting the general population and focusing on prevention and early recognition of major skin lesions. In parallel, a national multicentre quasi-experimental pre–post study with a low-risk intervention and no control arm is currently underway. The primary objective is to evaluate the effect of an educational brochure 2-6-12 months after distribution (T1-T2-T3) on caregivers' knowledge regarding prevention and early management of skin tears, as well as assessing the incidence rate of skin tears at T1, T2, and T3.

Results: Educational brochures have been produced and distributed nationwide to hospitals and community healthcare services upon request. Five podcasts focusing on prevention of major skin lesions have also been developed and disseminated to the public.

Conclusions: accessible communication strategies and practical educational tools represent effective advocacy instruments to strengthen patient engagement and support early wound prevention and management. Ongoing research will further evaluate the impact of these educational materials on caregivers' knowledge and prevention behaviours related to skin tears.

References

Callender LF, Johnson AL, Pignataro RM. Patient-Centered Education in Wound Management: Improving Outcomes and Adherence. Adv Skin Wound Care. 2021 Aug 1;34(8):403-410. doi: 10.1097/01.ASW.0000753256.29578.6c.

Gethin G, Probst S, Stryja J, Christiansen N, Price P. Evidence for person-centred care in chronic wound care: A systematic review and recommendations for practice. J Wound Care. 2020 Sep 1;29(Sup9b):S1-S22. doi: 10.12968/jowc.2020.29.Sup9b.S1.

https://aislec.it/brochure-aislec/