



Case report

Gastric Antral Vascular Ectasia (GAVE) a case report, review of the literature and update of techniques



L. Fortuna^a, A. Bottari^{a,*}, D. Bisogni^b, F. Coratti^a, F. Giudici^a, B. Orlandini^c, G. Dragoni^c, F. Cianchi^a, F. Staderini^a

^a Digestive Surgery Unit, AOU Careggi, Firenze, Italy

^b Advanced Interventional Endoscopy, AOU Careggi, Firenze, Italy

^c Department of Experimental and Clinical Biomedical Sciences, University of Florence, Firenze, Italy

ARTICLE INFO

Keywords:

GAVE
Endoscopy
Endoscopic treatment
Acute GI bleeding
Minimally invasive treatment

ABSTRACT

Introduction and importance: Gastric Antral Vascular Ectasia is a rare disorder that causes up to 4 % of severe acute gastrointestinal bleeding. It affects elderly females with iron deficiency anemia due to chronic blood loss as a common presenting sign.

Case presentation: We report the case of a 70-year-old man admitted to the Urgency Department for severe asthenia associated with abdominal pain and severe anemia. An urgent upper endoscopic examination showed antral hyperemic streaks and vascular ectasias extending from the pyloric ring to the gastric body as well as signs of recent bleeding. Histological results demonstrated the pathognomonic features of GAVE.

Clinical discussion: The first line treatment is considered argon plasma coagulation (APC), given its wider availability, safety, efficacy and cost-effectiveness. In current literature, other therapies and different types of endoscopic treatments have been proposed, such as EBL, RFA and Yag: laser. To date, there is no specific recommendation that privileges one method over another in the treatment of GAVE, although APC has proven effective and even better in terms of complications and costs than the other techniques.

Conclusion: In our experience, endoscopic coagulation with APC probes is a relatively easy-to-use technique with low cost, minimal invasiveness and provides immediate results.

On the other hand, a standardized algorithm is also required concerning to the different subtypes to give the best treatment in every case.

1. Introduction

Firstly, described by Rider JA et al. as “an erosive type of gastritis with marked veno-capillary ectasia”, gastric antral vascular ectasia (GAVE) is a rare disorder that causes up to 4 % of severe acute Gastrointestinal (GI) bleeding. GAVE is also called “watermelon stomach” [1] and it affects especially elderly females with iron deficiency anemia (89 % of patients) due to chronic blood loss as a common presenting sign [2,3].

This condition is often associated with cirrhosis, which is found in up to 30 % of patients, or other systemic diseases such as autoimmune connective tissue disorders (62 %) or Raynaud's phenomenon (31 %). Less frequent associated conditions are chronic kidney disease, hypertension, familial Mediterranean fever, valvular heart disease, bone marrow transplantation and acute myeloid leukemia [4]. The GAVE

typical presentation is a transfusion-dependent chronic iron-deficiency anemia from occult GI bleeding.

The diagnosis of GAVE can be both endoscopic and histological, but one of the safest ways to diagnose is through biopsy. The hyperplasia of the mucosa, capillary ectasia and thrombosis and oedematous submucosa with dilated vessels are the typical histologic features due to chronic inflammation.

In 1989, Gilliam et al. proposed a scoring system for the diagnosis of GAVE, which considered two criteria: the co-presence of ectasia and/or fibrin thrombi and spindle cell proliferation (Gilliam's score). Subsequently, a third parameter, fibrohyalinosis, was added to improve sensibility and specificity and this score was called the “GAVE score”.

This latter score is used to make a differential diagnosis between GAVE to Portal Hypertensive Gastropathy (PHG) and it showed a higher diagnostic accuracy, up to 80 % (Table 1).

* Correspondence to: A. Bottari, Resident at Digestive Surgery Unit, AOU Careggi, Largo Giovanni Alessandro Brambilla, 3, 50134 Firenze, Italy.

E-mail address: andrea.bottari@unifi.it (A. Bottari).

<https://doi.org/10.1016/j.ijscr.2022.107474>

Received 7 July 2022; Received in revised form 30 July 2022; Accepted 30 July 2022

Available online 3 August 2022

2210-2612/© 2022 The Authors. Published by Elsevier Ltd on behalf of IJS Publishing Group Ltd. This is an open access article under the CC BY-NC-ND license (<http://creativecommons.org/licenses/by-nc-nd/4.0/>).

Sometimes GAVE is confused with PHG, an apparently similar condition, but, indeed, a deeply different entity. A correct biopsy is of utmost importance since it can distinguish GAVE from PHG, which Payen et al. established as distinct entities with different treatments since 1995.

Unlike GAVE, which occurs only in 2 % of patients on the transplant list and in 3 % of patients with HCV and advanced fibrosis, PHG has a prevalence between 20 and 80 % of patients with cirrhosis and/or portal of hypertension of other nature and its pathogenesis is not completely understood [5,6].

As well explained by Gjeorgjievski M and colleagues, PHG and GAVE affect different gastric locations, as PHG involves the proximal stomach, with a mosaic-like pattern surrounding polygonal areas of erythema (whereas GAVE shows erythema most commonly arranged linearly along folds in the antrum). Apart from the gastric involvement, these two entities show differences also in terms of pathological features and response to the therapies, thus configuring two distinguished entities. Moreover, the endoscopic approach plays an insignificant role in PHG bleeding, where the only recommended treatments for reducing the bleeding are Transjugular intrahepatic portosystemic shunt (TIPS) or more aggressive surgical approaches (i.e. portosystemic shunt) [7–9].

Concerning GAVE, it has histological, endoscopic and clinical pathognomonic findings. Its typical clinical presentation is a transfusion-dependent chronic iron-deficiency anemia or, less frequently, severe acute upper GI bleeding. Overall, GAVE accounts for 4 % of all nonvariceal upper GI bleeding cases.

1.1. Diagnosis

As previously explained, diagnosis is a combination of different criteria, including clinical, histological and endoscopic findings.

Concerning the clinic, patients usually experience iron deficiency anemia, thus requiring treatments with blood transfusions and iron supplementation; less frequently, acute gastrointestinal bleeding occurs with hematemesis or melena.

Table 2 summarizes the differences between GAVE and PHG.

However, endoscopic diagnosis is very important since the GAVE lesions are mainly focal and the diagnostic biopsy can be negative if it is taken in a non-affected area. As a consequence of that, if the biopsy is negative, GAVE cannot be excluded [10].

2. Presentation of case

We report the case of a 70-year-old man with a history of ischemic heart disease, congestive heart failure, diabetes, dyslipidemia, pulmonary hypertension, chronic kidney injury, arterial hypertension and atrial fibrillation. The patient was admitted to the Urgency Department of Careggi University Hospital for severe asthenia with abdominal pain.

The patient did not report any alcohol consumption. No history of rectal bleeding, melena or hematemesis was reported even if he was under anticoagulant therapy. A few weeks before he underwent a

Table 2
GAVE vs PHG.

GAVE	PHG
Associated to autoimmune and connective tissue diseases (scleroderma, pernicious anemia, hypothyroidism), liver cirrhosis, bone marrow transplant, chronic renal failure	Only in association with conditions inducing portal hypertension
Antrum Cherry Red Spots on pattern linear Watermelon	Body and fundus Cherry Red Spots on pattern a mosaic, resembling "snake-skin"
71 % women	75 % men
Specific histological score	Undiagnosed histology
No response to beta-blockers and TIPS	Response to beta-blockers and TIPS

gastroscopy, colonoscopy and video-capsule endoscopy for indeterminate gastrointestinal bleeding with anemia: non-specific antral gastritis was detected (maybe related to biliary duodenal-gastric reflux).

Heart rate and blood pressure showed normal ranges and no postural hypotension was detected.

Blood examination revealed severe anemia (Hb value 7 g/dl) with serum iron and ferritin deficiency.

The mean corpuscular volume was normal. The International Normalized Ratio (INR) was 1.9. No leukocytosis nor platelet alterations were reported. Urea and creatinine levels were respectively 64 mg/dL and 2.1 mg/dL.

An urgent upper endoscopic examination showed antral hyperemic streaks and vascular ectasias extending from the pyloric ring to the gastric body, together with signs of recent bleeding. Histological results of biopsies taken during the gastroscopy demonstrated the pathognomonic features of GAVE: hyperplastic foveolar (serrated) gastric epithelium, fibrohyalinosis, thrombosis in venules and spindle-cell proliferation.

Abdominal-CT scan excluded additional causes of gastrointestinal bleeding. After a multidisciplinary team evaluation, the patient was referred to an endoscopic treatment attempt.

Procedure was carried out with a forward-viewing endoscope (GIF-XTQ160 scope, Olympus Medical System, Co. Ltd., Tokyo, Japan) by an experienced endoscopist who has completed his learning curve (FS), with >5000 EGDS/life. Patients underwent a deep sedation with propofol and ketamine, according to the hospital guidelines; left side position was adopted.

A watermelon stomach, extending 360-degrees from the pyloric ring to the sub-angular region was detected (Figs. 1, 2A). A progressive coagulation of the mucosal vascular network was carried out with an APC probe (Erbe FiAPC Sonde 2200A – Erbe USA Inc., Marietta, Georgia, USA) (Fig. 2B). The patient tolerated this procedure well, no bleeding or other intraoperative complications occurred; operative time was measured at 52 min.

The initial postoperative course in the intensive care unit was uneventful, so the patient was transferred to the ordinary ward on the

Table 1
Histological score system for GAVE.

GAVE score (range 0-5)		Gilliam's score (range 0-4)	
SCORE	THROMBUS OF FIBRIN AND / OR VASCULAR ECTASIA	FIBROMUSCULAR HYPERTROPHY	FIBRO-HYALINOSIS
0	Both Absents	Absent	Absent
1	One Present	Increased	Present
2	Both Presents	Much Increased	-

GAVE Score > 3: diagnostic for GAVE.

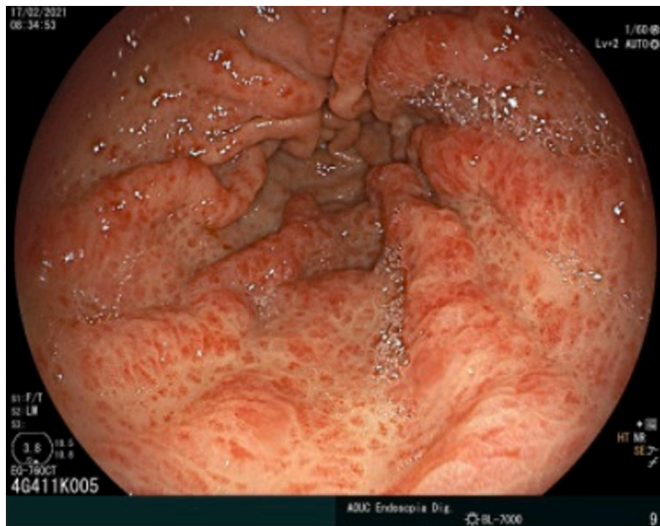


Fig. 1. Endoscopic appearance of gastric antral vascular ectasia (GAVE).

second postoperative day.

The patient did not experience pain and oral feeding was well tolerated, so that on the fourth postoperative day he was discharged.

The one-month control gastroscopy described the complete disappearance of the previously described vascular ectasia and no residual signs of mucosal bleeding were detected (Fig. 3).

3. Review of the literature

A screening of the literature available for all the English language papers in the electronic databases (Medline, PubMed, Google Scholar, SCOPUS, and the Cochrane Controlled Trials Register) was performed until January 2021. The following keywords were used as free text terms or Medical Subject Headings (MeSH): “GAVE”, “watermelon stomach”, “angiodysplasia”, “vascular ectasia of the stomach”, “endoscopic”, “treatment”. Major variations of these keywords were used to improve search results. Since the available literature on the subject is limited, we have used even generic keywords to expand our research fields, also individually examining the references to selected studies to increase our performance. Data were collected from the abstract, main manuscript, tables, supplementary material, or graphs. Only human adult subject studies whose outcomes of interest were retrievable were included in the analysis. Therapeutic modalities included in this review are APC, neodymiumdoped yttrium aluminum garnet (Nd:YAG), endoscopic band ligation (EBL), and radiofrequency ablation (RFA). To evaluate the effectiveness of the treatment, we included studies that examined at least one of our primary established outcomes as needed for transfusion, increased hemoglobin levels, and/or re-bleeding data for the techniques studied. For complications, we included case series with at least 5 patients, evaluating adverse events such as therapeutic failure, perforations and mortality. In total, 24 studies were included. Of these, 12 studies (5 prospective and 7 retrospective) collect the results of treatment with APC, 6 studies show the outcomes in the use of EBL, 5 studies (4 prospective and 1 retrospective) describe the experience in the use of RFA. One study compares APC and RFA. Tables 3-5 show the patient characteristics and the results reported in the included studies.

neodymiumdoped yttrium aluminum garnet (Nd:YAG), endoscopic band ligation (EBL), and radiofrequency ablation (RFA). To evaluate the effectiveness of the treatment, we included studies that examined at least one of our primary established outcomes as needed for transfusion, increased hemoglobin levels, and/or re-bleeding data for the techniques studied. For complications, we included case series with at least 5 patients, evaluating adverse events such as therapeutic failure, perforations and mortality. In total, 24 studies were included. Of these, 12 studies (5 prospective and 7 retrospective) collect the results of treatment with APC, 6 studies show the outcomes in the use of EBL, 5 studies (4 prospective and 1 retrospective) describe the experience in the use of RFA. One study compares APC and RFA. Tables 3-5 show the patient characteristics and the results reported in the included studies.

4. Discussion

Treatment of GAVE is predominantly symptomatic. The aim is to correct the blood loss with fluid resuscitation and/or blood transfusions and iron supplementation. Before endoscopic therapy, the gold standard treatment was the gastric antrectomy. Modern guidelines advise endoscopic ablation as the preferred treatment of GAVE since surgery is associated with higher mortality and it should be reserved only for

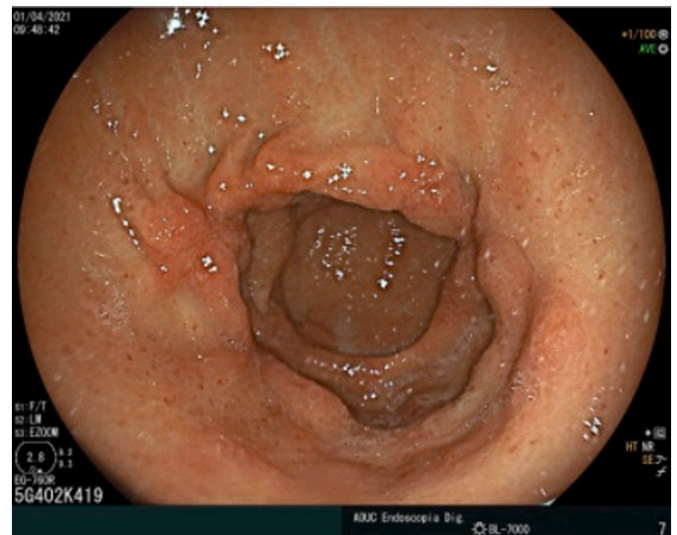


Fig. 3. One month follow up after APC coagulation.

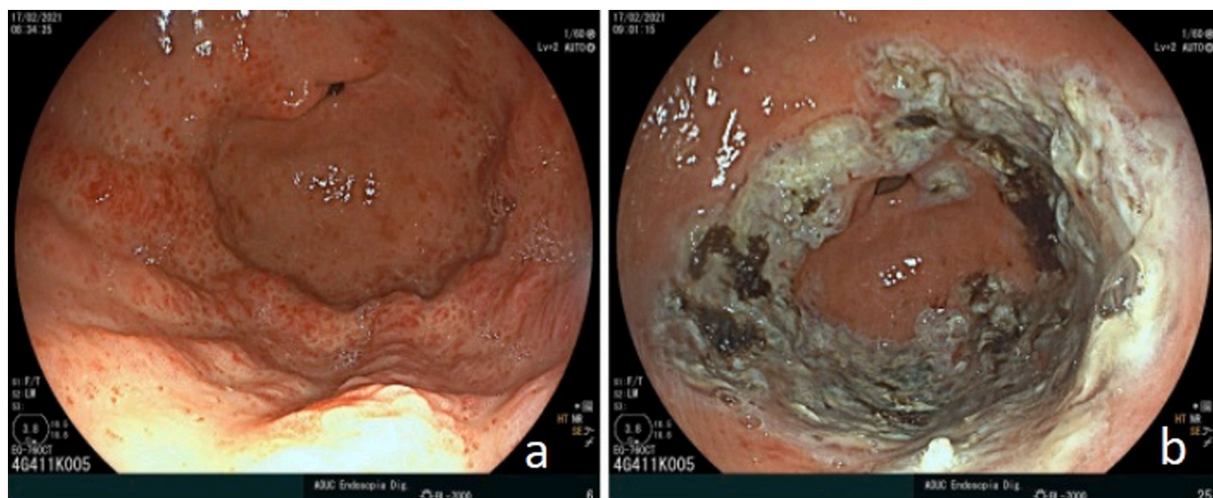


Fig. 2. Gastric antral vascular ectasia before (a) and after (b) APC coagulation.

Table 3

Results for the use of APC for the treatment of GAVE [2,16–20,21,22,24,26–39].

Author	N.	Study type	F-up (month)	Efficacy	N° of sessions	Complications
Probst et al. 2001	17	Prospective	30,4	Hb levels increase.	2	Asymptomatic antrum scarring
Yusoff et al. 2002	5	Retrospective	20	Hb levels increase; transfusion dependence ceased in all patients	2,6	Minor bleeding
Roman et al. 2003	21	Retrospective	15	Hb levels increase.	2,8	2 hematemesis, 1 sepsis
Sebastian et al. 2004	12	Retrospective	24	Hb levels increase; decrease transfusion need.	2	1 minor bleeding
Kwan et al. 2006	26	Prospective	16	Hb levels increase; decrease transfusion need.	2	None
Chaves et al. 2006	14	Prospective	9,9	70 % response;	3,2	35 % bleeding
Herrera et al. 2008	8	Prospective	24	87 % treatment success.	2,3	None
Leclaire et al. 2008	30	Retrospective	22	80 % treatment success.	2,18	None
Batthi et al. 2009	50	Prospective	8,5	Hb levels increase; decrease transfusion need.	5	None
Fuccio et al. 2009	20	Prospective	25	90 % treatment success.	3	Abdominal pain and bloating in 80 % of the cases
Chiu et al. 2012	19	Retrospective	NR	78,9 % recurrent bleeding	2,4	None
Garg et al. 2017	20	Retrospective	20,6	40 % treatment success	2–2,5	None
St. Romain et al. 2017	25	Retrospective	18	100 % treatment success	2,4	None

Table 4

Results for the use of EBL for the treatment of GAVE [15,27–29,31,40].

Author	N.	F-up (month)	Efficacy	Sessions	Complications
Wells et al. 2008	9	12.7	Higher rate of bleeding cessation, post-treatment transfusion and hospitalization with EBL.	1.9	None
Sato et al. 2012	12	15.6	8.3 % recurrence with EBL.	3	1 bleeding in EBL group
Keohane et al. 2013	8	26	100 % endoscopic improvement in EBL	2.5	None
Zepeda-Gomez et al. 2019	33	35.9	81,8 % responder	2.9	None
Fabián et al. 2020	18	/	Increased Hb levels	2.2	Two polyps after EBL procedure
OMorain et al. 2021	12	19.9	Increased Hb levels	2.9	None

unresponsive or refractory patients [4,7,11,12]. Only GAVE lesions with symptoms due to blood loss should be treated [13].

Endoscopic treatment consists of multiple techniques. Current treatment options include nonthermal (endoscopic band ligation) and thermal (APC, laser, and RFA) techniques. Some others, like cryotherapy and Nd:YAG laser are of limited use, because of a higher complication rate and the reduced diffusion.

Table 5

Results of the use of RFA for the treatment of GAVE [21,30,41–44].

Author	N.	Study type	F-up (month)	Efficacy	Sessions	Complications
Gross et al. 2008	6	Prospective	2	Hb levels increase in all patients; 1 patient remained transfusion dependent.	1.6	None
McGorisk et al. 2013	21	Prospective	6	86 % clinical success, significant increase in Hb.	2	1 superficial ulcer
Dray et al. 2014	24	Retrospective	6	Significant decrease in mean number of blood transfusions and increase in Hb levels.	1.8	None
Jana et al. 2015	7	Prospective	6	71 % clinical success based on post-treatment blood transfusion.	2	None
Raza et al. 2015	9	Prospective	11	67 % clinical success based on post-treatment blood transfusion.	3	None
St. Romain et al. 2017	28	Retrospective	18	Hb levels remained stable in all patients	2.3 (cirrhosis) 2.2 (non-cirrhosis)	None

Unlike in patients with GAVE, the endoscopic approach plays a small role in the treatment of PHG bleeding. The only treatment that might be recommended for prophylaxis is non-selective B-blockers while TIPS and surgery (portosystemic shunt) are used to reduce the severity of PHG.

The first line treatment is considered the argon plasma coagulation (APC), given its wider availability, safety, efficacy and cost-effectiveness. APC is a non-contact electro-coagulation technique that uses an ionized argon jet to apply a monopolar current on the target zone [14].

Twelve studies collected the results of the treatment with APC, seven retrospective and five prospective. Probst et al. reported the longest follow-up time of 30.4 months, the maximum number of patients enrolled was reached by the prospective study from Batthi et al. with 50 cases and a mean 8.5 months follow-up. Two sessions were found to be required with this technique. APC is shown to be equally effective in both diffuse and stripy patterns [4]. In the literature, most of the authors report excellent results in terms of reducing the need for blood transfusions and increasing hemoglobin levels [15–20]. Its clinical success rate varies between 100 % and 40 %, as reported respectively by St. Romain et al. and Garg et al. [21,22]. The good control of the depth of penetration of the coagulation with APC is one of the benefits that allows us to avoid excessive blood loss. It also does not create adhesions and secondary bleeding [23]. No complications or at least a limited bleeding was found with APC except for Fuccio et al., which reports a 90 % treatment success with abdominal pain and bloating in 80 % of the cases. Chaves et al. described postprocedural bleeding in 35 % of patients. Chiu et al. also reported an 80 % recurrence of bleeding during follow-up. Its long-term efficacy is still under discussion and this may not sufficiently support its exclusive use in GAVE [24].

Endoscopic band ligation (EBL), which was initially used when APC

was not available or as rescue therapy in case of inefficient APC, became a helpful alternative thanks to its ability to treat a larger area at once and to safely treat the deep vascular plexus, which has been shown to play a role in symptom recurrence [25,26].

This technique is supported by a limited number of studies [27–30], showing a low complication rate. The method has wide availability, and the short procedure time makes it more tolerated. It can also be used for lesions deeply involving mucosa and submucosa and appears to be effective even with a reduced number of sessions compared to APC; apparently, no important difference was found in the influence on hemoglobin level elevation and on the need for transfusion [31,32]. This could suggest that an earlier referral of patients presenting GAVE to an EBL may improve the outcomes, reducing the probability of recurrence. Zepeda-Gomez et al. 2019 reported an 81.8 % success in a cohort of 33 patients with a mean follow-up of 35.9 months, showing no significant complications. Fábían et al. and O'Morain et al. reported that the baseline hemoglobin level might possibly reflect of the likelihood response to EBL. It also seems that patients with a good response to EBL show a longer survival. Despite an initial good response, Keohane et al. found a recurrence-bleeding rate from 35 % to 78.9 %. In case of recurrence, patients can be treated again with EBL and in some cases, APC may be complementary. APC may be particularly useful in case of previous banding, where the scar tissue is difficult to suction, in order to achieve a correct banding. Patients treated with EBL with chronic renal failure, which promotes neovascularization from chronic ischemia, seem to have a higher rate of recurrence of GAVE [32].

The most common adverse events were ulcers, epigastric pain and mild bleeding. Although the efficacy of these techniques has not been universally identified for all the subtypes of GAVE, APC is still considered the first choice in linear GAVE, while EBL may be more useful in widespread and severe GAVE [14]. Recent studies suggest that more severe cases may be preferentially selected for EBL given the deeper penetration of this technique than APC. The differentiation of the subtypes of GAVE may help to find an effective therapeutic algorithm which could be useful in patient's selection [33].

On the other hand, Radiofrequency ablation (RFA) uses an alternating electrical high-frequency current locally delivered on tissue or mucosa with a controlled thermal coagulative necrosis depth. This approach has also achieved encouraging results, thanks to a uniform ablation depth, although it is not an easy-to-use technique and requires longer training. There is limited long-term data for RFA (Table 5). We evaluated six studies: no significant complications were reported, despite the mean 8 months follow-up. A retrospective study by St. Romain et al. shows no complications in 28 treated cases with a mean 18 months follow-up in 28 treated cases. Another retrospective work by Raza et al. shows good outcomes with 67 % of clinical success in a mean 11 months follow-up.

However, the available evidence suggests that it is equally effective and tolerable compared with APC requiring fewer sessions [29]. Moreover, RFA seems to be effective also on patients with APC-refractory GAVE. More controlled trials are necessary to evaluate its efficacy, safety, and reliability [29,33].

Another tool for endoscopic therapy is the Nd:YAG laser. Recent literature has confirmed the rationality of this endoscopic thermal therapy in reducing or in some cases avoiding the need for blood transfusions up to 50–80 % of cases. Some authors would particularly indicate Nd:YAG laser therapy for GAVE when associated with heart valve diseases, cirrhosis, chronic renal failure, and connective tissue diseases [34]. However, in the literature, there are few studies that have evaluated the effectiveness.

Nonetheless, APC proved to be just as effective, and even better in terms of complications and cost [21,22], while more APC sessions are generally required to achieve the same efficacy in terms of bleeding reduction [35].

Currently, there is no specific recommendation that privileges one method over another in the treatment of GAVE.

5. Conclusion

APC has been widely used in recent years and the technology is still improving. In our experience, endoscopic coagulation with APC probes is a relatively easy-to-use technique with low cost, minimal invasiveness and provides immediate results. We believe that it is safer and more effective when performed by experienced endoscopists.

On the other hand, a standardized algorithm is also required concerning the different subtypes, to give the best treatment in every case.

In conclusion, further studies are needed before any definitive conclusions are reached regarding the treatment.

Abbreviations

GAVE	gastric antral vascular ectasia
GI	gastrointestinal
PHG	portal hypertensive gastropathy
APC	argon plasma coagulation
EBL	endoscopic band ligation
RFA	radiofrequency ablation
Nd:YAG laser	neodymium-doped:yttrium aluminum garnet laser
EGDS	esophagogastroduodenoscopy
CT	computed tomography
T2D	type 2 diabetes
AF	atrial fibrillation
NOACs	new oral anticoagulants
TIPS	transjugular intrahepatic portosystemic shunt

Declaration of competing interest

Authors declare that they have no competing interests.

Acknowledgements

The authors thank Dr. Edda Russo PhD for English revision.

Author's contributions

LF and AB were a major contributor in writing the manuscript; FS and DB reviewed and analyzed the clinical data and critically revised the manuscript; FS and DB analyzed the data and provided pictures; FG, FS and FC reviewed the final version of the manuscript.

Personal financial interests

Authors declare that they have no personal financial interests.

Employment

Authors have nothing to declare.

Other competing interests

None.

Funding

None.

Ethics approval and consent to participate

Not applicable.

Consent for publication

Written informed consent was obtained from the patient for

publication of this case report and accompanying images. A copy of the written consent is available for review by the Editor-in-Chief of this journal on request.

Availability of data and materials

The datasets generated and/or analyzed during the current study are not publicly available due to the patient's privacy reason but are available from the corresponding Author on reasonable request.

Provenance and peer review

Not commissioned, externally peer-reviewed.

Guarantor

Prof. Fabio Cianchi, Director of Digestive Surgery Unit, AOU Careggi. Our work has been conducted the work has been reported in line with the SCARE criteria [45].

References

- [1] J.A. Rider, A.P. Klotz, J.B. Kirsner, Gastritis with veno-capillary ectasia as a source of massive gastric hemorrhage, *Gastroenterol* 24 (1953) 118–123.
- [2] D.M. Chaves, P. Sakai, C.V. Oliveira, S. Cheng, S. Ishioka, Watermelon stomach: clinical aspects and treatment with argon plasma coagulation, *Arq. Gastroenterol.* 43 (3) (2006 Jul-Sep) 191–195.
- [3] C.J. Gostout, T.R. Viggiano, D.A. Ahlquist, K.K. Wang, M.V. Larson, R. Balm, The clinical and endoscopic spectrum of the watermelon stomach, *J. Clin. Gastroenterol.* 15 (3) (1992 Oct) 256–263.
- [4] C.P. Selinger, Y.S. Ang, Gastric antral vascular ectasia (GAVE): an update on clinical presentation, pathophysiology and treatment, *Digestion* 77 (2) (2008) 131–137.
- [5] P. Calès, J.J. Voigt, J.L. Payen, E. Bloom, P. Berg, J.P. Vinel, et al., Diffuse vascular ectasia of the antrum, duodenum, and jejunum in a patient with nodular regenerative hyperplasia. Lack of response to portosystemic shunt or gastrectomy, *Gut* 34 (1993) 558–561.
- [6] J.L. Payen, P. Calès, J.J. Voigt, S. Barbe, C. Pilette, L. Dubuisson, et al., Severe portal hypertensive gastropathy and antral vascular ectasia are distinct entities in patients with cirrhosis, *Gastroenterology* 108 (1995) 138–144.
- [7] M. Gjeorgievski, M.S. Cappell, Portal hypertensive gastropathy: a systematic review of the pathophysiology, clinical presentation, natural history and therapy, *World J. Hepatol.* 8 (4) (2016 Feb 8) 231–262.
- [8] M. Peng, X. Guo, F. Yi, X. Shao, L. Wang, Y. Wu, C. Wang, M. Zhu, O. Bian, M. Ibrahim, S. Chawla, X. Qi, Endoscopic treatment for gastric antral vascular ectasia, *Ther. Adv. Chronic. Dis.* 12 (12) (2021 Aug), 20406223211039696.
- [9] M. Ito, Y. Uchida, S. Kamano, H. Kawabata, M. Nishioka, Clinical comparisons between two subsets of gastric antral vascular ectasia, *Gastrointest. Endosc.* 53 (2001) 764–770.
- [10] M. Jabbari, R. Cherry, J.O. Lough, D.S. Daly, D.G. Kinnear, C.A. Goresky, Gastric antral vascular ectasia: the watermelon stomach, *Gastroenterology* 87 (1984) 1165–1170.
- [11] J.H. Gilliam III, K.R. Geisinger, W.C. Wu, N. Weidner, J.E. Richter, Endoscopic biopsy is diagnostic in gastric antral vascular ectasia. The "watermelon stomach", *Dig. Dis. Sci.* 34 (6) (1989 Jun) 885–888.
- [12] A.M. Alkhormi, M.Y. Memon, A. Alqarawi, Gastric antral vascular ectasia: a case report and literature review, *J. Transl. Intern. Med.* 6 (2018) 47–51.
- [13] S. Peter, C.M. Wilcox, Radiofrequency ablation therapy – the grave for GAVE (gastric antral vascular ectasia)? *Endosc. Int. Open* 3 (2) (2015) E128–E129.
- [14] P. Kar, S. Mitra, J.M. Resnick, C.F. Torbey, Gastric antral vascular ectasia: case report and review of the literature, *Clin. Med. Res.* 11 (2) (2013) 80–85.
- [15] A. Fábian, R. Bor, E. Szabó, V. Kardos, A. Bálint, K. Parkas, Á. Milassin, M. Rutka, K. Szántó, T. Molnár, M. Szűcs, K. Lőrinczy, Á. Orbán-Szilágyi, T. Gyökeres, G. Gyimesi, A. Szepes, V. Kovács, I. Rác, Z. Szepes, Endoscopic treatment of gastric antral vascular ectasia in real-life settings: argon plasma coagulation or endoscopic band ligation? *J. Dig. Dis.* 22 (1) (2021 Jan) 23–30.
- [16] A. Probst, R. Scheubel, M. Wienbeck, Treatment of watermelon stomach (GAVE syndrome) by means of endoscopic argon plasma coagulation (APC): long term outcome, *Z. Gastroenterol.* 39 (2001) 447–452.
- [17] I. Yusoff, F. Brennan, D. Ormonde, B. Laurence, Argon plasma coagulation for the treatment of watermelon stomach, *Endoscopy* 34 (2002) 407–410.
- [18] S. Roman, J.C. Saurin, J. Dumortier, A. Perreira, G. Bernard, T. Ponchon, Tolerance and efficacy of argon plasma coagulation for controlling bleeding in patients with typical and atypical manifestations of watermelon stomach, *Endoscopy* 35 (2003) 1024–1028.
- [19] S. Sebastian, R. McLoughlin, A. Qasim, C.A. O'Morain, M.J. Buckley, Endoscopic argon plasma coagulation for the treatment of gastric antral vascular ectasia (watermelon stomach): long-term results, *Dig. Liver Dis.* 36 (2004) 212–217.
- [20] V. Kwan, M.J. Bourke, S.J. Williams, P.E. Gillespie, M.A. Murray, A.J. Kaffes, et al., Argon plasma coagulation in the management of symptomatic gastrointestinal vascular lesions: experience in 100 consecutive patients with long-term follow-up, *Am. J. Gastroenterol.* 101 (2006) 58–63.
- [21] P. St. Romain, A. Boyd, J. Zheng, S.C. Chow, R. Burbridge, D. Wild, Radiofrequency ablation (RFA) vs. argon plasma coagulation (APC) for the management of gastric antral vascular ectasia (GAVE) in patients with and without cirrhosis: results from a retrospective analysis of a large cohort of patients treated at a single center, *Endosc. Int. Open* 6 (3) (2018). E266–E270.
- [22] S. Garg, B. Aslam, N. Nickl, Endoscopic resolution and recurrence of gastric antral vascular ectasia after serial treatment with argon plasma coagulation, *World J. Gastrointest. Endosc.* 9 (6) (2017 Jun 16) 263–266.
- [23] J.A. Dumot, B.D. Greenwald, Argon plasma coagulation, bipolar cautery, and cryotherapy: ABC's of ablative techniques, *Endoscopy* 40 (2008) 1026–1032.
- [24] M.A. Batthi, A.A. Khan, A.K. Alam, A.K. Butt, F. Shafiqat, K. Malik, et al., Efficacy of argon plasma coagulation in gastric vascular ectasia in patients with liver cirrhosis, *J. Coll. Physicians Surg. Pak.* 19 (2009) 219–222.
- [25] S. Cho, S. Zanati, E. Yong, M. Cirocco, G. Kandel, P. Kortan, et al., Endoscopic cryotherapy for the management of gastric antral vascular ectasia, *Gastrointest. Endosc.* 68 (2008) 895–902.
- [26] R. Kumar, S. Mohindra, H.S. Pruthi, Endoscopic band ligation: a novel therapy for bleeding gastric antral vascular ectasia, *Endoscopy* 39 (S1) (2007). E56–7.
- [27] S. Zepeda-Gómez, R. Sultanian, C. Teshima, G. Sandha, S. Van Zanten, A. J. Montano-Loza, Gastric antral vascular ectasia: a prospective study of treatment with endoscopic band ligation, *Endoscopy* 47 (6) (2015) 538–540.
- [28] J. Keohane, W. Berro, G.C. Harewood, F.E. Murray, S.E. Patchett, Band ligation of gastric antral vascular ectasia is a safe and effective endoscopic treatment, *Dig. Endosc.* 25 (2013) 392–396.
- [29] N.R. O'Morain, H. O'Donovan, C. Conlon, E. Shannon, D. Manning, E. Slattery, Is endoscopic band ligation a superior treatment modality for gastric antral vascular ectasia compared to argon plasma coagulation? *Clin. Endosc.* 54 (4) (2021) 548–554.
- [30] S.A. Gross, M. Al-Haddad, K.R. Gill, A.N. Schore, M.B. Wallace, Endoscopic mucosal ablation for the treatment of gastric antral vascular ectasia with the HALO90 system: a pilot study, *Gastrointest. Endosc.* 67 (2008) 324–327.
- [31] T. Sato, K. Yamazaki, J. Akaike, Endoscopic band ligation versus argon plasma coagulation for gastric antral vascular ectasia associated with liver diseases, *Dig. Endosc.* 24 (2012) 237–242.
- [32] I.M. Gralnek, J.M. Dumonceau, E.J. Kuipers, et al., Diagnosis and management of nonvariceal upper gastrointestinal hemorrhage: european Society of Gastrointestinal Endoscopy (ESGE) guideline, *Endoscopy* 47 (10) (2015) a1–a46.
- [33] J. Eccles, V. Falk, A.J. Montano-Loza, S. Zepeda-Gómez, Long-term follow-up in patients with gastric antral vascular ectasia (GAVE) after treatment with endoscopic band ligation (EBL), *Endosc. Int. Open* 7 (12) (2019 Dec) E1624–E1629.
- [34] T.R. McCarty, T. Rustagi, Comparative effectiveness and safety of radiofrequency ablation versus argon plasma coagulation for treatment of gastric antral vascular ectasia: a systematic review and meta-analysis, *J. Clin. Gastroenterol.* 53 (8) (2019) 599–606.
- [35] G. Rosenfeld, R. Enns, Argon photocoagulation in the treatment of gastric antral vascular ectasia and radiation proctitis, *Curr. Endoscop. Prac.* 23 (2009) 801–804.
- [36] L. Fuccio, R.M. Zagari, M. Serrani, L.H. Eusebi, D. Grilli, V. Cennamo, et al., Endoscopic argon plasma coagulation for the treatment of gastric antral vascular ectasia-related bleeding in patients with liver cirrhosis, *Digestion* 79 (2009) 143–150.
- [37] Y.C. Chiu, L.S. Lu, K.L. Wu, W. Tam, M.L. Hu, W.C. Tai, et al., Comparison of argon plasma coagulation in management of upper gastrointestinal angiodysplasia and gastric antral vascular ectasia hemorrhage, *BMC Gastroenterol.* 9 (12) (2012) 67.
- [38] S. Herrera, J.M. Bordas, J. Llach, A. Ginès, M. Pellisé, G. Fernández-Esparrach, et al., The beneficial effects of argon plasma coagulation in the management of different types of gastric vascular ectasia lesions in patients admitted for GI hemorrhage, *Gastrointest. Endosc.* 68 (2008) 440–446.
- [39] S. Leclaire, E. Ben-Soussan, M. Antonietti, O. Gorla, G. Riachi, E. Lerebours, et al., Bleeding gastric vascular ectasia treated by argon plasma coagulation: a comparison between patients with and without cirrhosis, *Gastrointest. Endosc.* 67 (2008) 219–225.
- [40] C.D. Wells, M.E. Harrison, S.R. Gurudu, M.D. Crowell, T.J. Byrne, G. Depetris, et al., Treatment of gastric antral vascular ectasia (watermelon stomach) with endoscopic band ligation, *Gastrointest. Endosc.* 68 (2008) 231–236.
- [41] T. McGorisk, K. Krishnan, L. Keefer, S. Komanduri, Radiofrequency ablation for refractory gastric antral vascular ectasia (with video), *Gastrointest. Endosc.* 78 (2013) 584–588.
- [42] X. Dray, A. Repici, P. Gonzalez, C. Frstrup, S. Leclaire, S. Kantsevov, et al., Radiofrequency ablation for the treatment of gastric antral vascular ectasia, *Endoscopy* 46 (2014) 963–969.
- [43] T. Jana, N. Thosani, M. Fallon, A.W. Dupont, A. Ertan, Radiofrequency ablation for treatment of refractory gastric antral vascular ectasia (with video), *Endosc. Int. Open* 3 (2015) E125–E127.
- [44] N. Raza, D.L. Diehl, Radiofrequency ablation of treatment-refractory gastric antral vascular ectasia (GAVE), *Surg. Laparosc. Endosc. Percutan Tech.* 25 (2015) 79–82.
- [45] R.A. Agha, T. Franchi, C. Sohrabi, G. Mathew, for the SCARE Group, The SCARE 2020 guideline: updating consensus Surgical Case Report (SCARE) guidelines, *Int. J. Surg.* 84 (2020) 226–230.