



eISSN 2279-7483

<https://www.pagepressjournals.org/index.php/vl/index>

**Publisher's disclaimer.** E-publishing ahead of print is increasingly important for the rapid dissemination of science. The **Early Access** service lets users access peer-reviewed articles well before print / regular issue publication, significantly reducing the time it takes for critical findings to reach the research community.

These articles are searchable and citable by their DOI (Digital Object Identifier).

**Veins and Lymphatics** is, therefore, e-publishing PDF files of an early version of manuscripts that have undergone a regular peer review and have been accepted for publication, but have not been through the typesetting, pagination and proofreading processes, which may lead to differences between this version and the final one. The final version of the manuscript will then appear in a regular issue of the journal.

E-publishing of this PDF file has been approved by the authors.

*All legal disclaimers applicable to the journal apply to this production process as well.*

Veins and Lymphatics 2023 [online ahead of print]

To cite this article:

Stefano Bacci, Franco Bassetto, Alessandro Corsi, et al. Photobiomodulation in clinical practice. *Veins and Lymphatics*. 2023;12:11821. doi:10.4081/vl.2023.11821



©The Author(s), 2023

Licensee PAGEPress, Italy

*The publisher is not responsible for the content or functionality of any supporting information supplied by the authors. Any queries should be directed to the corresponding author for the article.*

*All claims expressed in this article are solely those of the authors and do not necessarily represent those of their affiliated organizations, or those of the publisher, the editors and the reviewers. Any product that may be evaluated in this article or claim that may be made by its manufacturer is not guaranteed or endorsed by the publisher.*

## Position Statement

### Photobiomodulation in clinical practice

Stefano Bacci,<sup>1</sup> Franco Bassetto,<sup>2</sup> Alessandro Corsi,<sup>3</sup> Ornella Forma,<sup>3</sup> Vieri Grandi,<sup>4,5</sup> Alberto Macciò,<sup>6,7</sup> Antonio Raspa,<sup>8</sup> Carlotta Scarpa,<sup>9</sup> Gregorio Stratta,<sup>10</sup> Mirko Tessari<sup>11</sup>

<sup>1</sup>Biology Department, Histology and Embryology Research Unit, University of Florence, Italy;

<sup>2</sup>UOC Reconstructive Plastic Surgery, Hospital-University of Padua, Italy;

<sup>3</sup>U.O. Vulnology, San Raffaele Hospital, Milan, Italy;

<sup>4</sup>Department of Health Sciences, University of Florence, Italy;

<sup>5</sup>Dermatology Section, P. Palagi Hospital, Florence, Italy;

<sup>6</sup>Head of Lymphology, Humanitas Medical Care & Gavazzeni Clinic, Bergamo, Italy;

<sup>7</sup>Executive Committee of the European Society of Lymphology – ESL;

<sup>8</sup>Ultrashort pulse laser Product Manager at Luxinar Ltd., Hull, United Kingdom;

<sup>9</sup>UOC of Plastic Reconstructive Surgery, Hospital-University of Padua, Italy

<sup>10</sup>Breast Surgeon, Humanitas Medical Care & Gavazzeni Clinic, Bergamo, Italy;

<sup>11</sup>Tessari Studi Legs Medical Institute – Phlebolympology Academy, Peschiera del Garda (VR), Italy;

**Corresponding author:** Mirko Tessari, Tessari Studi Legs Medical Institute – Phlebolympology Academy, Peschiera del Garda (VR), Italy.

E-mail: [mirko.tessari@gmail.com](mailto:mirko.tessari@gmail.com)

**Authors' contributions:** all the authors made a substantive intellectual contribution. All the authors have read and approved the final version of the manuscript and agreed to be held accountable for all aspects of the work.

**Conflict of interest:** the authors declare no potential conflict of interest.

*The publisher is not responsible for the content or functionality of any supporting information supplied by the authors. Any queries should be directed to the corresponding author for the article.*

*All claims expressed in this article are solely those of the authors and do not necessarily represent those of their affiliated organizations, or those of the publisher, the editors and the reviewers. Any product that may be evaluated in this article or claim that may be made by its manufacturer is not guaranteed or endorsed by the publisher.*

**Funding:** none.

**Availability of data and materials:** all data generated or analyzed during this study are included in this published article.

*The publisher is not responsible for the content or functionality of any supporting information supplied by the authors. Any queries should be directed to the corresponding author for the article.*

*All claims expressed in this article are solely those of the authors and do not necessarily represent those of their affiliated organizations, or those of the publisher, the editors and the reviewers. Any product that may be evaluated in this article or claim that may be made by its manufacturer is not guaranteed or endorsed by the publisher.*

## Preface

Alessandro Corsi, Ornella Forma

For the past few years, we have been witnessing a gradual but rapid change in the management of skin wounds: the so-called 'advanced' dressings have been joined, and partly replaced, by interactive dressings, in which the dressing itself interacts with the wound bed and perilesional skin, modulating one or more aspects of the tissue repair mechanism through the interaction with cells, chemical mediators and factors hindering healing.

The even more recent introduction of high-tech devices has definitively propelled Wound Care into the modern era of Tech Treatment, in which one or more technologies are employed in the management of the wound and the reparative process.

In this field, Regenerative Medicine and Surgery represent the most recent frontier reached by this 'technological expansion', through the use of dermo/epidermal substitutes and material stimulating the healing process in its different phases.

In the early 2000s, considerable interest was aroused by the attempt to apply 'phototherapy' to wound management: taking their cue from the results obtained some time ago in the treatment of certain lesions, cutaneous and otherwise, neoplastic and not, with the use of Photodynamic Therapy (by means of red light and 5 amino-levulinic acid), a Florentine research group (to which some of the authors of this paper belonged) began to study its effects on venous ulcers, with extremely encouraging results in terms of resumption of the reparative process, with evidence of increased angiogenesis, fibroblast number and antigen-presenting cells, amongst other things.

Over the years, other types of biophotonic treatment have been developed, with the introduction of monochromatic light sources (red, green, blue), capable of selectively interacting with the different tissue chromophores, and of triggering effects (so-called photobiomodulation) in the treated tissues, which differ according to the wavelength used and the chromophores stimulated each time.

More recent is the application of exogenous fluorophores, which can absorb radiant light and convert it into light of different wavelengths through a phenomenon known as fluorescence.

The enormous therapeutic possibilities offered by different treatments have led to exciting results from a tissue regeneration point of view.

However, as it often happens when a technology is affected by such sudden changes and developments, clinical practice currently suffers from certain biases, mainly related to the presence of uncoordinated protocols of use, for each technology, in the absence, therefore, of algorithms of use that would make their clinical application homogeneous, establishing, for each type of light stimulation, its role and real potential, setting its limits and indications, also on the basis of clinical risk.

*The publisher is not responsible for the content or functionality of any supporting information supplied by the authors. Any queries should be directed to the corresponding author for the article.*

*All claims expressed in this article are solely those of the authors and do not necessarily represent those of their affiliated organizations, or those of the publisher, the editors and the reviewers. Any product that may be evaluated in this article or claim that may be made by its manufacturer is not guaranteed or endorsed by the publisher.*

We felt it was time to sit around a table, bringing together some of the top experts in each field of this discipline, trying to clarify all the aspects that characterize the interaction of light with tissues, in a dialogue that brought together physicists, chemists, clinicians and experts in statistics and literature (among the best in the country, and with proven experience in the field in question), in order to find a common language and try to provide information for the correct indications for the use of this method of tissue regeneration, free from corporate and institutional influences, without any sponsorship and, above all, dictated by real experience developed in the various sectors, supported by data from the literature.

*The publisher is not responsible for the content or functionality of any supporting information supplied by the authors. Any queries should be directed to the corresponding author for the article.*

*All claims expressed in this article are solely those of the authors and do not necessarily represent those of their affiliated organizations, or those of the publisher, the editors and the reviewers. Any product that may be evaluated in this article or claim that may be made by its manufacturer is not guaranteed or endorsed by the publisher.*

## State of the art in Photobiomodulation

Alessandro Corsi, Ornella Forma, Mirko Tessari

Chronic injuries are a significant burden on the global healthcare system, costing more than \$30 billion per year.

Historically, wound healing interventions included standard medical procedures such as debridement, antimicrobial dressings, and skin substitutes. As medical technology has advanced, lesser-known and sometimes less expensive therapies have emerged, such as phototherapy, which offers new treatments for various conditions. Phototherapy has long been proposed as tissue healing therapy since its inception in the mid-20<sup>th</sup> century.

Since then, laser and, more recently, LED, employed in Photobiomodulation (PBM), has been applied to an increasing variety of skin lesions and conditions. However, the lack of an accepted set of optimal parameters has led to inconsistency in PBM experiences, resulting in a disparate range of procedural standards and results.

PBM was initially developed by Hungarian physician Endre Mester in 1967 when he noticed an unexpected acceleration of hair regrowth while studying the effects that exposure to laser light caused on cancer cell growth in a mouse model. Of course, light therapy has evolved significantly since its origins and has expanded in its application. PBM has been successfully used in dermatological treatments, non-healing lesions, scars, ulcers, musculoskeletal changes, chronic pain, analgesia, and immune modulation.

### *Evolution of the Photobiomodulation process*

Having established that PBM is a tissue response to light, modern technologies use this principle in the medical field as a therapy to treat different types of injuries.

The ability of PBM to interact with many key processes in the successful resolution of wound healing is widely demonstrated through the reduction of inflammatory reaction, promotion of angiogenesis, fibroblast proliferation, collagen production, and granulation tissue formation, although some studies have reported limited efficacy or inhibitory effects of PBM treatments for wound management, therefore calling into question the use of PBM in clinical practice as an effective therapeutic option. The main reason for these inconsistent results may depend on individual clinical conditions, the heterogeneity of current clinical studies, the experimental model chosen, as well as the type, severity of the lesion, and age of the patient, but most likely, it is due to the high degree of complexity intrinsic to this technology.

Furthermore, we should also consider that the occurrence of a biphasic dose-response (whereby low levels and high levels of light pursue stimulatory and inhibitory effects, respectively) reported for PBM in several studies, could possibly explain the incongruous results.

*The publisher is not responsible for the content or functionality of any supporting information supplied by the authors. Any queries should be directed to the corresponding author for the article.*

*All claims expressed in this article are solely those of the authors and do not necessarily represent those of their affiliated organizations, or those of the publisher, the editors and the reviewers. Any product that may be evaluated in this article or claim that may be made by its manufacturer is not guaranteed or endorsed by the publisher.*

An increasing number of scientific studies suggest that specific wavelengths of electromagnetic radiation ranging from visible to infrared (indigo violet: 380-450; blue: 450-500; green: 500-570; yellow-orange: 570-600; red: 600-750; Near-Infrared (NIR) 750-1100 nm) can lead to photophysical and photochemical effects that can modulate major biological processes, such as cell proliferation, mitochondrial function and inflammatory signaling responses in various eukaryotic organs, including humans.

Most literature reports the therapeutic effects of red light and NIR in promoting tissue healing and reducing inflammation.

However, there is still controversy in the application of PBM in practice, due to a lack of knowledge on how PBM produces its molecular effects and a poor understanding of the photo-physics and radiometric parameters that influence its accuracy and reliability. The importance of reporting treatment parameters in a consistent and reliable manner has been emphasized in several articles, and guidelines have previously been published for reporting radiometric properties that are of little use for therapeutic purposes.

These articles provided guidelines for reporting radiometric parameters by recommending a maximum of ten key parameters: wavelength, power, irradiation time, illuminated beam area, radiant energy, radiant exposure, pulse parameters, number of treatments, inter-treatment interval, and anatomical location.

*The publisher is not responsible for the content or functionality of any supporting information supplied by the authors. Any queries should be directed to the corresponding author for the article.*

*All claims expressed in this article are solely those of the authors and do not necessarily represent those of their affiliated organizations, or those of the publisher, the editors and the reviewers. Any product that may be evaluated in this article or claim that may be made by its manufacturer is not guaranteed or endorsed by the publisher.*

## Bibliography

- Jarbrink K, Ni G, Sonnergren H, et al. The humanistic and economic burden of chronic wounds: a protocol for a systematic review. *Syst. Rev.* 2017;6:15.
- Han G, Ceilley R. Chronic wound healing: a review of current management and treatments *Adv. Ther.* 2017;34:599-610.
- Chung H, Dai T, Sharma SK, et al. The nuts and bolts of low-level laser (light) therapy. *Ann. Biomed. Eng.* 2012;40:516-33.
- De Freitas LF, Hamblin MR. Proposed mechanisms of photobiomodulation or low-level light therapy. *IEEE J Sel Top Quantum Electron.* 2016;22:348-64.
- Da Fonseca ADS. Is there a measure for low-power laser dose? *Lasers in Medical Science.* 2018;1-12.
- Mester E, Szende B, Gartnerne T. Influence of laser beams on the growth of hair in mice, *Kiserl. Orvostud.* 1967;19:628-31.
- Taradaj J, Shay B, Dymarek R, et al. Effect of laser therapy on expression of angio- and fibrogenic factors, and cytokine concentrations during the healing process of human pressure ulcers. *Int. J. Med. Sci.* 2018;15:1105.
- Mosca RC, Ong AA, Albasha O, et al. Photobiomodulation Therapy for Wound Care. *Adv. Ski. Wound Care.* 2019;32:157-67.
- Gavish L, Hoffer O, Rabin N, et al. Microcirculatory Response to photobiomodulation - why some respond and others do not: a randomised controlled study. *Lasers Surg. Med.* 2020;52:863-72.
- Mignon C, Uzunbajakava NE, Castellano-Pellicena I, et al. Differential response of human dermal fibroblast subpopulations to visible and near-infrared light: Potential of photobiomodulation for addressing cutaneous conditions. *Lasers Surg. Med.* 2018;50:859-82.
- Petz FDFC, Felix JVC, Roehrs H, et al. Effect of photobiomodulation on repairing pressure ulcers in adult and elderly patients: a systematic review. *Photochem. Photobiol.* 2019;96:191-9.
- Brassolatti P, De Andrade ALM, Bossini PS, et al. Evaluation of the low-level laser therapy application parameters for skin burn treatment in experimental model: a systematic review. *Lasers Med. Sci.* 2018;33:1159-69.
- Machado RS, Viana S, Sbruzzi G. Low-level laser therapy in the treatment of pressure ulcers: Systematic review. *Lasers Med. Sci.* 2017;32:937-44.
- Edge D, Mellergaard M, Dam-Hansen C, et al. Fluorescent light energy: the future for treating inflammatory skin conditions? *J. Clin. Aesthet. Dermatol.* 2019;12:E61-8.

*The publisher is not responsible for the content or functionality of any supporting information supplied by the authors. Any queries should be directed to the corresponding author for the article.*

*All claims expressed in this article are solely those of the authors and do not necessarily represent those of their affiliated organizations, or those of the publisher, the editors and the reviewers. Any product that may be evaluated in this article or claim that may be made by its manufacturer is not guaranteed or endorsed by the publisher.*



Basso FG, Pansani TN, Soares DG, et al. Biomodulation of inflammatory cytokines related to oral mucositis by low-level laser therapy. *Photochem. Photobiol.* 2015;91:952-6.

Foley J, Vasily DB, Bradle J, et al. 830 nm light-emitting diode (LED) phototherapy significantly reduced return-to-play in injured university athletes: a pilot study. *Laser Ther.* 2016;25:35-42.

Hadis MA, Zainal SA, Holder MJ, et al. The dark art of light measurement: accurate radiometry for low-level light therapy Lasers. *Med. Sci.* 2016:1-21.

Castellano-Pellicena I, Uzunbajakava NE, Mignon C, et al. Does blue light restore human epidermal barrier function via activation of Opsin during cutaneous wound healing? *Lasers Surg. Med.* 2019;51:370-82.

Tani A, Chellini F, Giannelli M, et al. Red (635 nm), Near-Infrared (808 nm) and Violet-Blue (405 nm) Photobiomodulation potentiality on human osteoblasts and mesenchymal stromal cells: a morphological and molecular in vitro study. *Int. J. Mol. Sci.* 2018;19:1946.

Veleska-Stevkoska D, Koneski F. Haemostasis in oral surgery with blue-violet light. *Open Access Maced. J. Med. Sci.* 2018;6:687-91.

*The publisher is not responsible for the content or functionality of any supporting information supplied by the authors. Any queries should be directed to the corresponding author for the article.*

*All claims expressed in this article are solely those of the authors and do not necessarily represent those of their affiliated organizations, or those of the publisher, the editors and the reviewers. Any product that may be evaluated in this article or claim that may be made by its manufacturer is not guaranteed or endorsed by the publisher.*

## Physical basis of Photobiomodulation

Antonio Raspa

### Introduction

LASER: even though this five-letter word has now entered our current vocabulary, it is not easy to find a simple but non-superficial description of the technologies it embodies.

Wikipedia, rather than Treccani, starts by explaining that LASER stands for Light Amplification by Stimulated Emission of Radiation. It is interesting to note that this definition does not refer to a specific object or device, but rather to a process of light generation and manipulation, which, however, immediately requires a whole series of explanations and examples to describe the different physical phenomena, the different types of sources, their main characteristics, and real applications. In fact, we move from the definition of a theoretical, almost abstract process, gracefully described by the acronym, to a series of technical details and particular cases, typically selected according to the recipient of the information. Indeed, this incredible versatility of use was evident as far back as 1960, when the first device put into operation by Theodore Maiman was referred to as a solution in search of a problem, a humorous definition but one that was decidedly unfortunate and wrong in the light of the countless answers given to the various questions that were gradually raised over the years.

Yet, its enormous potential in the medical and biological fields was evident from the onset, and today LASER technology, which is constantly evolving, offers an extensive range of LASER devices, each with specific technical features. In this chapter, we will consider them as black boxes, avoiding discussion of the physical phenomena and engineering solutions underlying their operation, in order to focus on the properties of the LASER beam itself and to understand the application effects of the different parameters with the final aim of providing adequate evaluation tools to clinical users.

### *What is a LASER?*

A good starting point might be the (re)definition of LASER as a device capable of projecting a thin, bright, coloured beam of light.

In all scientific and technical fields, words are very important, and in this simple explanation, regardless of what actually goes on inside the device, all the really interesting elements for the user are briefly provided.

We, therefore, understand that a LASER is a generator of artificial light, with particular geometric characteristics (thin beam), intensity (bright), and color.

First, the LASER is another source of light, like natural light sources, such as the sun and stars, or artificial ones, such as fire or light bulbs: on the one hand, light sustains life through the natural processes of

*The publisher is not responsible for the content or functionality of any supporting information supplied by the authors. Any queries should be directed to the corresponding author for the article.*

*All claims expressed in this article are solely those of the authors and do not necessarily represent those of their affiliated organizations, or those of the publisher, the editors and the reviewers. Any product that may be evaluated in this article or claim that may be made by its manufacturer is not guaranteed or endorsed by the publisher.*

photosynthesis and, on the other hand, at the same time, has supported the progress of mankind since the discovery (and control) of fire.

Today, the LASER represents the most advanced form of light, artificially produced by man through a series of physical phenomena that have been understood and developed over the centuries, but which reached a turning point with “Über einen die Erzeugung und verwandlung des Lichtes betreffenden heuristischen Gesichtspunkt” (On a heuristic point of view concerning the production and transformation of light) (translator’s note) published in 1905 by Albert Einstein, in which he described his discoveries on the photoelectric effect, *i.e.* the generation and transformation of light, as stated in the justification for the Nobel Prize awarded to him in 1922.

Einstein's brilliant insight was to overcome the two previous theories on the nature of light, corpuscular and undulatory, by combining their properties. This led to the concept of the dual nature of light. On the one hand, the undulatory nature explains physical phenomena involving radiation at the macroscopic level; on the other hand, descending into the microscopic, one could think of small fundamental and quantized energy units (as if they were discrete packets of energy) which from now on we will call photons. Light, then, and more generally electromagnetic radiation, is both wavelike and corpuscular. Figure S1 shows the entire spectrum of electromagnetic radiation, from X-rays (wavelengths of billionths of a meter) to radio waves (hundreds of meters).

## The color of the LASER

We will now move on to develop the undulatory aspect, *i.e.*, the color of light, or rather LASER radiation: we typically associate this with the everyday perceptions of our senses and with the term “light” we think of what is visible to the human eye, limiting ourselves to a very small portion of the electromagnetic spectrum between 400 and 700 nanometres wavelength. We also associate the simultaneous presence of all visible wavelengths, in quantities that are proportionate to those of sunlight, with white light and define colored light as any imbalance in this distribution. In fact, the human eye has become specialized in detecting not all the sun's emission, but only the central part that reaches the ground through the atmosphere.

A LASER, unlike the Sun, will only emit colored light at a specific wavelength: the width of the emitted spectrum is so narrow that it is considered, with some exceptions, strictly monochromatic. As mentioned, there are different types of LASERs, and the first important classification can be made precisely on the basis of the color of the radiation emitted by the specific device, over a much broader range than visible light: as shown in Figure S2, they range from X-rays (wavelengths of nanometres or fractions thereof) to deep infrared (tens of thousands of nanometres).

The colour of the LASER beam is not simply an aesthetic or technological factor: it is directly related to the energy of the individual photon, *i.e.*, the small, fundamental and discrete energy units (quantized according to physics terminology) that can be transported and exchanged during the interaction between radiation and matter. As expressed in Planck's law, formulated in 1900, the energy associated with

*The publisher is not responsible for the content or functionality of any supporting information supplied by the authors. Any queries should be directed to the corresponding author for the article.*

*All claims expressed in this article are solely those of the authors and do not necessarily represent those of their affiliated organizations, or those of the publisher, the editors and the reviewers. Any product that may be evaluated in this article or claim that may be made by its manufacturer is not guaranteed or endorsed by the publisher.*

electromagnetic radiation transmitted by light quanta, later identified as photons, is inversely proportional to wavelength (via  $h$ , Planck's Constant).

$$E = \frac{h}{\lambda}$$

This formula provides us with the information that underlies all phenomena of energy exchange between radiation and matter, underlining the fact that they only occur by whole multiples: for the exchange to take place, it is necessary that the single receiving molecule receives exactly the energy of one or more photons. It is also worth noting that, by virtue of Planck's Law, the energy contained in a single photon in the Ultraviolet (UV) at 250 nm is four times that of a photon in the near-Infrared (IR) at around 980 nm: a UV photon can therefore interact very strongly with the receiving molecule to the point of breaking some chemical bonds, whereas an IR photon typically does not go beyond a simple increase in the vibrations of the molecule itself, *i.e.*, at the macroscopic level, the temperature.

Planck's Law is valid over the entire electromagnetic spectrum and for each molecule it is possible to reconstruct absorption curves, such as those of certain chromophores given in Figure S3. If we take our sun as an example, which radiates over a very broad spectrum, we have both the infrared component, which interacts above all with water and melanin, 'overheating' our skin, while the ultraviolet part (composed of 95% UVA rays and the remaining UVB), on the other hand, seriously endangers our epidermis to the extent that sun-creams with specific 'sun' filters are recommended.

In contrast to the sun, the monochromaticity of individual LASER sources offers us the possibility of selectively operating on a particular molecule, seeking the wavelength with the highest absorption in combination with the lowest absorption by other molecules. Clearly, given the complexity of biological tissues, the best compromise must be sought, while maintaining a high level of attention for possible side effects.

The color of LASERs is the basis of the interaction between light and biological tissues, but to fully understand, we must proceed by analyzing the other peculiarities of the LASER beam.

### ***The thin beam***

We begin with the so-called geometrical characteristics: in a LASER generator, by using the stimulated emission process, all the atoms are forced to operate in a strictly coordinated manner to generate a thin ray of light that irradiates in a very precise direction that can be assimilated, in the first approximation, to a half-line (in fact, in the 3rd century B.C. Euclid drew geometry with light, imagining the visual ray hypothesized a couple of centuries earlier by Empedocles). The association between an ideal half-line and the beam emitted by a LASER source is perfect for immediately grasping its very high directionality, but going a little deeper, we must abandon this geometric simplification. A real LASER beam, in fact, does not maintain absolute parallelism, *i.e.*, its diameter increases, albeit imperceptibly, during propagation. Therefore, it is always essential to specify two fundamental parameters: what is its beam diameter at the source, and what is its broadening or so-called divergence.

*The publisher is not responsible for the content or functionality of any supporting information supplied by the authors. Any queries should be directed to the corresponding author for the article.*

*All claims expressed in this article are solely those of the authors and do not necessarily represent those of their affiliated organizations, or those of the publisher, the editors and the reviewers. Any product that may be evaluated in this article or claim that may be made by its manufacturer is not guaranteed or endorsed by the publisher.*

While it is obvious that the beam diameter is given in millimeters, it should be clarified why divergence is measured as an angle. Referring to Figure S4, our sun is a source that radiates light uniformly in all directions, and therefore, extending the concept of plane angle to three-dimensional space, its divergence is equal to the entire solid angle subtended by a sphere (*i.e.*,  $4\pi$  steradians); similarly, a good LASER source might subtend a solid angle of less than a thousandth of a (ste)radian: a 1 mm diameter beam widens to 1.5 mm after one metre but becomes 500 mm at 1 km distance!

So, the ideal thin beam is actually a quasi-collimated beam, *i.e.*, it diverges slightly as it travels. If we then use a lens to focus it, so as to have a well-localised energy intensity, it turns out that we cannot go below a very small but not nil diameter (on the other hand, a point with nil dimensions would imply an infinite intensity).

Diameter and divergence are the fundamental parameters for the propagation and focusing of a LASER beam, but to understand how they are related to each other, we need to go a step further by analysing the intensity distribution within the beam itself.

To generate a beam with this level of directionality, it is necessary to confine the light according to predetermined geometries using within the generator, a device called an optical resonator. The simplest of these is made up of two flat, parallel mirrors, positioned in such a way that the photons can only be reflected back and forth in a specific direction, creating standing waves within the resonator itself. The different possible configurations of standing waves are called cavity modes; particularly important for our discussion are the Hermite-Gauss modes, each characterised, as shown in Figure S5, by a specific intensity profile which is perpendicular to the direction of propagation. The different modes are referred to by the abbreviation TEM (Transverse Electro-Magnetic) and a pair of indices related to the two transverse directions. However, each mode is characterized by its own divergence, the higher the indices.

In a real LASER beam the different modes generated in the optical resonator coexist, so the intensity distribution is given by the superposition of all the modes in the beam.

In the special case where there is only the TEM<sub>00</sub> fundamental mode, we have a beam called Gaussian because its intensity profile perpendicular to the propagation direction follows exactly a Gaussian distribution. A Gaussian beam maintains its profile while propagating in a homogeneous medium or through thin lenses: only the beam diameter changes, and this property gives it an important role in the study of LASER radiation. Furthermore, it is relatively easy to develop the various formulae describing, in wave terms, LASER radiation as well as generalizing them to beams that are not strictly Gaussian.

We shall now focus on the formula that gives the beam diameter  $\omega$  along the propagation axis  $z$ , starting from its minimum diameter  $\omega_0$ , (see also Figure S6).

$$\omega(z) = \sqrt{\omega_0^2 \left( 1 + \left( \frac{\lambda z}{\pi \omega_0^2} \right)^2 \right)}$$

*The publisher is not responsible for the content or functionality of any supporting information supplied by the authors. Any queries should be directed to the corresponding author for the article.*

*All claims expressed in this article are solely those of the authors and do not necessarily represent those of their affiliated organizations, or those of the publisher, the editors and the reviewers. Any product that may be evaluated in this article or claim that may be made by its manufacturer is not guaranteed or endorsed by the publisher.*

The function  $\omega(z)$  is a hyperbola and the Gaussian beam assumes the minimum value  $\omega_0$  at  $z=0$ , and then slowly increases with both positive and negative  $z$  ( $\omega_0$  is typically referred to by the English term beam waist).

Besides, for very large  $z$ , the formula can be simplified as

$$\omega(z) = \frac{\lambda z}{\pi \omega_0}$$

and the divergence  $\theta$  becomes

$$\theta = \frac{2 \omega(z)}{z} = \frac{2 \lambda}{\pi \omega_0}$$

If we define the Product of Beam Parameters (BPP) as the product of divergence times beam waist, it follows that for a Gaussian beam it is a constant that depends solely on the wavelength  $\lambda$ .

$$BPP_{GAUSS} = \theta \omega_0 = \frac{2 \lambda}{\pi}$$

A Gaussian beam has the lowest possible BPP, and it quantifies the goodness of a LASER beam and its ability to be focused on a small spot. The ratio between the BPP of a real beam and that of an ideal Gaussian beam at the same wavelength is given by  $M^2$ , and a value close to 1 indicates a very good beam, *i.e.*, almost perfectly Gaussian.

To sum up, the thin beam of light has exceptional directional qualities but, given such a high level, evaluation parameters are needed. In conclusion, we can say that:

BPP (divergence product per diameter) is constant for any LASER beam

BPP of a Gaussian beam is directly proportional to wavelength

The minimum diameter of a Gaussian beam is inversely proportional to its wavelength (given the same boundary conditions, it focuses on a gradually increasing diameter as it passes from UV radiation to IR radiation in the visible ones)

A real (multimode) beam can be related to a Gaussian beam via the  $M^2$  factor: a beam with  $M^2$  equal to 1.05 is very close to a Gaussian beam, while those with  $M^2$  equal to or greater than 2 deviate significantly

The divergence and minimum diameter of a real beam are always greater than a Gaussian beam (at the same wavelength)

Brilliance of the LASER beam

We shall now address the energy aspect of a LASER beam: as we have seen, a LASER radiates a highly directional beam, at a specific wavelength, carrying energy. We are looking at the overall macroscopic

*The publisher is not responsible for the content or functionality of any supporting information supplied by the authors. Any queries should be directed to the corresponding author for the article.*

*All claims expressed in this article are solely those of the authors and do not necessarily represent those of their affiliated organizations, or those of the publisher, the editors and the reviewers. Any product that may be evaluated in this article or claim that may be made by its manufacturer is not guaranteed or endorsed by the publisher.*

effect of a huge stream of photons all traveling in the same direction, each carrying the same amount (how much) of energy.

A very first assessment of how bright a LASER beam is, may be based on its luminous intensity, *i.e.*, the energy carried by the photon stream, but, as we shall see, this approach is very simplistic.

It is rather intuitive to imagine that, for the same total energy, the effects would be different if it were concentrated on different surface areas, as well as if it were delivered over longer or shorter time intervals. It is, therefore, appropriate to firstly discuss the geometric-spatial aspects and then move on to the time domain and how the photon flux is delivered.

In Physics, as well as in international standards, there is a photometric quantity, called Brilliance, to measure the intensity of a light source (intentionally, I adopted the term brilliance at the beginning of the paragraph). Brilliance is the power emitted per unit solid angle and unit surface area of the source: a LASER beam has a very high brilliance because it is characterized, as seen above, by very low divergence and a very small diameter. To make a comparison, we can think of our sun that emits in all directions about  $382 \times 10^{24}$  watts (382 followed by 24 zeros!): this is an enormous power, but the effects on our skin, even after excessive exposure, are incomparably negligible in relation to a LASER beam of just a few watts, even if unfocused.

At this point, it is clear how important it is to know, not just the power emitted by a LASER source but, above all, the beam parameters discussed in the previous paragraph. We shall take for example two similar LASER devices, emitting the same power but with  $M2 = 1.1$  the first and  $M2 = 1.5$  the second: after all calculations, we find that the second beam is less focusable than the first and that, as the surface area is approximately double the size, the power density per unit area is half.

One last important note on Gaussian beams: the beam waist, or diameter of the beam, which we discussed at length in the previous section, is defined as the distance from the z-axis at which the intensity is reduced by a factor of  $1/e^2$ . As can be seen from Figure S7, the intensity in the central peak of a Gaussian beam is approximately twice the average energy: this is very important because, in certain applications, one could be, at the same time, in the central area above the maximum safe threshold and on the outermost ring below the minimum threshold to be effective. It is, therefore, essential to know exactly the shape of the beam, as this is directly related to the energy distribution, *i.e.*, the interaction between the LASER beam and the biological tissues.

A LASER device makes it possible to control, not just the spatial distribution of energy in a thin beam, but also its delivery in longer or shorter time intervals.

The simplest mode is one in which the LASER generator is switched on or off as required, more or less like a light bulb: this type of operation implies a continuous output from the LASER system (called CW - Continuous Wave). To realize this type of function, it is sufficient to identify how much energy is radiated in the unit of time, *i.e.*, the power of the LASER.

Having a LASER operating in CW mode can, therefore, control the switching on/off of the LASER beam, and also select the power level between minimum and maximum. In fact, a LASER designed to operate

*The publisher is not responsible for the content or functionality of any supporting information supplied by the authors. Any queries should be directed to the corresponding author for the article.*

*All claims expressed in this article are solely those of the authors and do not necessarily represent those of their affiliated organizations, or those of the publisher, the editors and the reviewers. Any product that may be evaluated in this article or claim that may be made by its manufacturer is not guaranteed or endorsed by the publisher.*

in CW mode can operate either continuously or modulated, directly handling variations in energy output, even on relatively short timescales ranging in the order of microseconds ( $10^{-6}$  seconds) as in the various examples given in Figure S8.

It is also possible to have LASER sources designed to operate specifically in pulsed mode by inserting a device in the cavity that acts as an optical switch (with a very high switching speed). Such a switch abruptly changes the characteristics of the cavity itself (in technical language, the merit factor  $Q$  is said to be changed, hence the definition of a  $Q$ -switch mode) from a situation of total lock-up, during which energy is stored for a relatively long period of time, to a release phase in which all this energy is released in a very short time (as shown in Figure S9). This type of operation generates pulses lasting nanoseconds ( $10^{-9}$  or one billionth of a second), during which the peak power reaches enormous values because it is inversely proportional to the duration of the pulse itself.

With current technology, LASER sources can be further complicated to obtain even shorter pulses, called ultra-fast, ranging from picoseconds ( $10^{-12}$  sec) to femtoseconds ( $10^{-15}$  sec), in which peak power increases even further.

Consequently, summing up what has been said up to this point, we can observe that a LASER source artificially 'synthesizes' a beam of extremely pure light/energy that is monochromatic, which can be concentrated on a very small diameter and whose emission can be controlled up to very short time intervals: all these characteristics make possible the multiple interactions with matter and, more specifically, with biological tissues.

Yet, it becomes really important to understand the role and interconnection of the different parameters that make this beam so special (Table S1).

### ***LASER-Matter interaction***

After clarifying what LASER is, a device capable of projecting a thin, bright, coloured beam of light, we can now address the subject of its interaction with matter: it is the starting point of any LASER application and the key to a successful procedure depends on a good knowledge of the related phenomena.

An in-depth discussion can be made on two different levels: the first, of a physical nature, goes into the details of what happens between the atoms in the matter when they are under the action of electromagnetic radiation. This discussion can be carried out in great depth, but is only valid under ideal situations with well-defined boundary conditions. Therefore, we will not go into the details of the formulae, but will only look at the fundamental concepts that allow us a second, more technical-practical approach to understanding the phenomena at a macroscopic level.

In macroscopic terms, the interaction between electromagnetic radiation and matter is the result of the various processes that occur when a beam of known intensity/energy impacts on matter or, rather, a real object, such as refraction, reflection, diffraction, absorption and transmission. Figure S10 shows the most general case where radiation is not fully absorbed, due to a relatively thin material mass. In many cases,

*The publisher is not responsible for the content or functionality of any supporting information supplied by the authors. Any queries should be directed to the corresponding author for the article.*

*All claims expressed in this article are solely those of the authors and do not necessarily represent those of their affiliated organizations, or those of the publisher, the editors and the reviewers. Any product that may be evaluated in this article or claim that may be made by its manufacturer is not guaranteed or endorsed by the publisher.*



especially when dealing with biological tissue, complete absorption occurs instead, as shown in Figure S11.

It is worth quoting the principle of conservation of energy, which, in this case, is expressed by stating that the sum of the radiation transmitted inside the body and the radiation reflected and emitted by the surface of the body is exactly equal to the incoming radiation.

For the purposes of the LASER-matter interaction, we are obviously only interested in the part transferred within the material, but a further level of detail is required, which includes the specific evaluation of the transparency of the material, or rather, its opacity. In fact, if we consider the part of a LASER beam entering the material, we observe that only a fraction retains its directionality, while the remainder is absorbed or diffused, *i.e.*, deflected towards other directions (and then becomes subject again to the phenomena of absorption and diffusion). This situation is often found in biological tissues which, in addition to not being homogeneous, are often characterized by dissimilar layered structures. In summary, we therefore have that, of the incoming radiation, only a part is transmitted inside the body, and of this part, only a further fraction is actually absorbed, *i.e.*, interacts at a microscopic level.

As we have seen, light has a dual character, corpuscular and wave-like: the wave-like nature explains physical phenomena involving radiation at the macroscopic level; on the other hand, descending into the microscopic, one might think of small fundamental and quantified energy units, called photons, interacting with individual atoms of matter.

Depending on whether one refers to the wave-like or corpuscular model, color and intensity are related to different physical units: in the wave-like model, color is related to wavelength and intensity (brightness) to the amplitude of the wave; whereas in the corpuscular model, color is related to energy and intensity (brightness) to the number of photons.

When radiation spreads in a solid matter, its electromagnetic field is able to generate a force on the positive charges of the nuclei, the protons, and on the negatively charged electrons. Given the oscillatory nature of the radiation, the induced motion will also be oscillatory: remembering that the temperature increase of a solid is related to the width of vibration of the atoms, once can conclude that the main effect of the LASER radiation, bringing it down to a macroscopic level, is to generate an increase in temperature. This is known as the Photothermal Effect.

However, we have seen that individual photons carry a lot of energy and, especially for UV radiation where the photon is more energetic, the bonds between particles within atoms or molecules can be changed or even broken. This is called the photochemical effect. Although radiation-matter interaction, in the case of biological tissues, is in most cases, based on the Photothermal effect, which we will go into more detail soon, it is worth always considering the Photochemical one with its potential side effects and/or drawbacks.

## LASER-biological tissue Photothermal Interaction LASER

*The publisher is not responsible for the content or functionality of any supporting information supplied by the authors. Any queries should be directed to the corresponding author for the article.*

*All claims expressed in this article are solely those of the authors and do not necessarily represent those of their affiliated organizations, or those of the publisher, the editors and the reviewers. Any product that may be evaluated in this article or claim that may be made by its manufacturer is not guaranteed or endorsed by the publisher.*

LASER, due to its specific wavelength, has an elective affinity for specific targets (biological chromophores), and the absorption of energy by these targets determines the transformation mechanisms of the tissues in which they are contained. The transformations that can occur in biological tissues may be of different types but can be traced back to either photo-thermal or photo-chemical interactions.

Thinking, therefore, of the LASER energy absorbed by the target chromophore, I have several interaction modes, each with its own temperature rise and consequent effects. The main ones are listed in Table S2.

We have previously seen how versatile a LASER system can be in localising the beam over very small areas and in managing the delivery itself by modulating and/or concentrating the energy over extremely flexible time intervals. As a result, it is possible to control extremely precisely the temperature increase of biological tissues through controlled exposure to LASER radiation.

The gradual evolution of LASER sources makes it possible nowadays to choose the most effective mode of emission to irradiate tissues, thus achieving the most effective interaction in the shortest possible time. In fact, while the LASER beam delivers energy to a specific volume, raising its temperature, there is also the process of transporting heat to the surrounding tissues. For the same total energy delivered, a higher delivery speed corresponds to greater 'localization': this implies a more sudden rise in temperature in the irradiated volume and less diffusion of heat into the surrounding tissues, if the delivery speed is higher.

For example, if you want to induce selective necrosis of tumor tissue, you operate with relatively low power (about 1W) by 'slowly heating' the tumor tissue itself (which is more sensitive to high temperatures than healthy tissue) to make it reach about 45°C with consequent necrosis of the tissue itself. In other cases, you can remove (diseased) tissue through an incision by carrying out localized vaporization: in this case, high average power and a beam focused on the smallest possible diameter is more suitable.

It is very important to highlight that there is always a transition zone between the treated tissue and the perfectly healthy tissue, meaning that no thermal effect has occurred. For this purpose, a relationship was established that determines the distance  $L$  at which healthy tissue damage occurs as a relation to exposure time:

$$L^2 = 4 K \tau$$

where  $\tau$  is the duration of exposure and  $K$  is a coefficient that considers the characteristics of the fabric (this is the thermal transmittance of the matter expressed in  $\text{cm}^2/\text{sec}$ ).

This explanation, which is rather clear in the case of LASER with Continuous Emission (CW), becomes slightly more complicated when passing modulated and/or pulsed emission modes because it becomes relevant to assess the thermal effect of superposition in the tissue. In general, there are two opposite situations: in the first case, the superposition effects can be overlooked, as long as the duration and frequency of the pulses are such that they comply with what is called the thermal relaxation time, i.e., the time that a tissue (due to its optical characteristics) takes to dissipate at least 50% of the absorbed heat. Therefore, I will localize a certain amount of energy in a certain volume of tissue and allow an adequate amount of time for the generated heat wave to disperse.

*The publisher is not responsible for the content or functionality of any supporting information supplied by the authors. Any queries should be directed to the corresponding author for the article.*

*All claims expressed in this article are solely those of the authors and do not necessarily represent those of their affiliated organizations, or those of the publisher, the editors and the reviewers. Any product that may be evaluated in this article or claim that may be made by its manufacturer is not guaranteed or endorsed by the publisher.*

If, on the other hand, the impulses consecutively follow each other too quickly, *i.e.*, without having given the tissue enough time to dissipate the thermal effects of the previous one, you end up with heat accumulation, *i.e.*, an increase in the volume of tissue affected by a temperature rise.

In Figure S12, the following conditions are exemplified.

Lastly, with pulses of less than ten nanoseconds, we find ourselves in the condition in which the pulse duration is much shorter than the thermal relaxation time, and therefore the thermal dissipation phenomena become negligible: the absorbed energy remains localized in very small volumes, and the temperature rises much higher than that of the vaporization of the material. In the area hit by the beam, so-called plasma is generated, and the shock wave associated with the rapid expansion of the plasma generates a localized mechanical rupture at the points where the pressure increase exceeds the cohesion forces of the tissues.

To sum up, the study of LASER-tissue interaction starts with knowledge of absorption, transmission and diffusion in the tissue itself. The type of interaction changes considerably as the LASER device parameters vary and depending on how the radiation energy is converted at biomolecular level: these differences determine the different use of medical LASER devices and it is essential to evaluate the following parameters: i) radiation wavelength, ii) radiation intensity (energy, average power and peak power), iii) exposition time, iv) absorption and transmission coefficients in tissues, and v) depth of radiation penetration.

### ***Medical use of LASER***

The different combinations of wavelength, irradiation mode, and energy/power of different LASER devices have enabled their wide use in the medical field. This is an evolving field in which adequate clinical studies are needed to validate the use of a specific LASER source for a given therapeutic application. The main LASER applications in medicine are those outlined in Figure S13, and the relevant devices are listed in Table S3.

The various combinations of wavelength, irradiation mode, and energy/power of several LASER devices have allowed a considerable development of clinical applications. We now focus on the so-called Low-Level LASER Therapy (LLLT), trying to define a particularly articulated and difficult field of application. This complexity is already reflected in the considerable number of definitions in the international scientific literature, which justifies the common use of terms, all synonymous with LLLT, such as Photobiomodulation, phototherapy, photomedicine, photoirradiation, biomodulation, and bio-stimulation. In particular, we should emphasise the current tendency to prefer the term biomodulation, instead of bio-stimulation, to include not only stimulating effects but also inhibiting ones, in the positive sense of the term. Finally, expressions from the 1970s and 1980s, such as cold LASER or soft LASER, used to differentiate from high-power applications, are still sometimes encountered.

In general, we could speak of a field of application in which low doses of LASER radiation are used for a range of therapeutic applications with a particular focus on the stimulation of healing processes (bone,

*The publisher is not responsible for the content or functionality of any supporting information supplied by the authors. Any queries should be directed to the corresponding author for the article.*

*All claims expressed in this article are solely those of the authors and do not necessarily represent those of their affiliated organizations, or those of the publisher, the editors and the reviewers. Any product that may be evaluated in this article or claim that may be made by its manufacturer is not guaranteed or endorsed by the publisher.*

mucous membranes, skin...), analgesic action, and other treatments especially in the field of rehabilitation medicine. Without going into the details of the mechanisms induced by absorption in the chromophores of LASER radiation, the biological effects of LLLT depend on wavelength, energy density, and power, and they certainly benefit from selectivity (due to the monochromaticity of LASER). The possible alternatives offered by technology are many, and there is a certain lack of homogeneity in the parameters used, especially with regard to power density and fluence, which are essential to compare the results obtained with various LASER devices. It is important to highlight that working with low dosages triggers bio-chemical processes in the cells, the results of which are not immediate but show themselves gradually over time: too low dosages may be partially or totally ineffective, while too high dosages, while not creating irreversible damage, may lead to undesirable collateral or inhibiting effects. Besides, one operates on tissues and situations which can never be reproduced exactly.

My aim is not to enter in the clinical discussion, but in order to understand and compare the different protocols, given the wide variety of parameters that can be used and the possible combinations depending on the different LASER instruments, the elements below should be kept in mind.

### *Wavelength*

It is distinctive for each LASER (it depends on the active medium).

It can range from ultraviolet to infrared via the visible and is expressed in nanometres ( $1 \text{ nm} = 10^{-9} \text{ m}$ ).

According to its wavelength, a LASER is absorbed differently by certain substances called chromophores.

### *Power*

It is the quantity of energy that can be delivered in the unit of time and is expressed in watts (W).

When a LASER operates in pulsed mode, we must make a distinction between: i) peak power, which is the maximum power produced; it is the energy in the pulse divided by the duration of the pulse, and ii) average power, *i.e.*, the average between peaks and pauses between one pulse and the next.

### *Mode of emission*

Generally, for LLLT we use:

Continuous Wavelength (CW)

Pulsed with pulse chains

*The publisher is not responsible for the content or functionality of any supporting information supplied by the authors. Any queries should be directed to the corresponding author for the article.*

*All claims expressed in this article are solely those of the authors and do not necessarily represent those of their affiliated organizations, or those of the publisher, the editors and the reviewers. Any product that may be evaluated in this article or claim that may be made by its manufacturer is not guaranteed or endorsed by the publisher.*

**Frequency (pulsed mode only)**

When the LASER operates in pulsed mode, it shows the number of pulses emitted per second. It is measured in hertz (Hz).

It affects the depth of penetration into the tissue (depending on heat conduction properties).

*Pulse duration (pulsed mode only)*

When a LASER operates in pulsed mode, it shows the duration of each pulse.

*(Surface) power density*

It represents, in some ways, the 'dose' of power that is released into the treated tissue area and is calculated by dividing the power by the spot area of the emitted beam.

It is measured in watts per square centimetre (W/cm<sup>2</sup>).

In the case of pulsed mode, the average power density must be distinguished from the peak power density.

*Energy Density or Fluency*

This is the most important parameter for the comparison of applications performed with different devices.

It represents the total energy delivered over a given area of tissue.

It is measured dividing the emitted energy by the area of the LASER spot.

*The publisher is not responsible for the content or functionality of any supporting information supplied by the authors. Any queries should be directed to the corresponding author for the article.*

*All claims expressed in this article are solely those of the authors and do not necessarily represent those of their affiliated organizations, or those of the publisher, the editors and the reviewers. Any product that may be evaluated in this article or claim that may be made by its manufacturer is not guaranteed or endorsed by the publisher.*

**Bibliography**

- "Principles of Lasers" di Orazio Svelto (Editor: Springer, Publication year: 2010)
- "Solid-State Laser Engineering" di Walter Koechner (Editor: Springer, Publication year: 2006)
- "Laser-Tissue Interactions: Fundamentals and Applications" di Markolf H. Niemz (Editor: Springer, Publication year: 2019)
- "Laser" di Anthony Siegman (Editor: University Science Books, Publication year: 1986)
- "Optics" di Eugene Hecht (Editor: Pearson, Publication year: 2016)
- "Photonics: Optical Electronics in Modern Communications" di Amnon Yariv (Editor: Oxford University Press, Publication year: 2007)
- "Nonlinear Optics" di Robert W. Boyd (Editor: Academic Press, Publication year: 2020)
- "Ultrafast Laser" di Ursula Keller (Editor: CRC Press, Publication year: 2017)
- "Laser-Tissue Interactions: Therapeutic Applications and Photodynamic Therapy" by David H. Sliney and Clarence P. Cain (Editor: SPIE Press, Publication year: 2013)
- "Medical Laser Applications and Laser-Tissue Interactions" by Karl-Goran Tranberg (Editor: Elsevier, Publication year: 2013)
- "Laser Interaction with Biological Material: Mathematical Modeling" by Marc E. Levoy and Wonshik Choi (Editor: Cambridge University Press, Publication year: 2016)
- "Principles and Practice of Low-Level Laser Therapy" by Michael R. Hamblin (Editor: Elsevier, Publication year: 2014)
- "Lasers in Dermatology: Mode of Action and Clinical Applications" by David J. Goldberg, Richard E. Fitzpatrick and Mitchel P. Goldman (Editor Springer, Publication year: 2012)
- "Laser Ablation: Mechanisms and Applications" by Claude R. Phipps (Editor: Springer, Publication year: 2017)
- "Laser-Matter Interaction: Fundamentals and Applications" by Eugene G. Gamaly (Editor: CRC Press, Publication year: 2017)
- "Photonics" by Saleh Teich (Editor: Wiley, Publication year: 2019)

*The publisher is not responsible for the content or functionality of any supporting information supplied by the authors. Any queries should be directed to the corresponding author for the article.*

*All claims expressed in this article are solely those of the authors and do not necessarily represent those of their affiliated organizations, or those of the publisher, the editors and the reviewers. Any product that may be evaluated in this article or claim that may be made by its manufacturer is not guaranteed or endorsed by the publisher.*

## Cellular mechanisms induced by Photodynamic Therapy following the treatment of chronic ulcers

Stefano Bacci

### Introduction

Originally created by Von Toppeiner in collaboration with Jesionek (Szeimies *et al.*, 2001), Photodynamic Therapy (PDT) is now widely used for the treatment of various diseases (Kang and Bacci, 2022). In dermatology, the use of this therapy ranges from oncological and non-oncological diseases, bacterial, fungal, viral, immunological, or inflammatory infections, to the treatment of chronic wounds, such as cosmetology for photorejuvenation (Niculescu and Grumezescu, 2021).

The use of this therapy involves the application of photosensitizers that are activated by a specific wavelength of light energy: the topical use of 5 Aminolaevulinic Acid (ALA) has represented a breakthrough in PDT in the dermatological field as it is easily absorbed by the skin (Cappugi *et al.*, 2001; Grandi *et al.*, 2018).

Wound healing requires a complex interaction and coordination of different cells and molecules (Cañedo-Dorantes and Cañedo-Ayala, 2019), where mast cells assume a central role in organizing the cellular infiltrate response following an insult (Bacci, 2022). Any alteration of these events can lead to delayed or even non-healing of the wound itself (Martin and Nunan, 2015; Raziyeveva *et al.*, 2021). The aim of this paper is to clarify the cellular mechanisms involved in the treatment of photodynamic therapy in chronic ulcers that are often associated with social illness and high care costs. (Nesi-Reis *et al.*, 2018; Niculescu and Grumezescu, 2021; Falanga *et al.*, 2022).

### Acute skin lesions

The primary function of the skin is to act as a protective shield against the environment. Loss of integrity of large portions of the skin due to injury or disease can lead to severe disability or even death.

Wound healing is, therefore, the process that makes organisms wound-resistant, allowing them to survive. Being of fundamental importance for life, its basic mechanisms have been substantially maintained throughout evolution (Bacci, 2019). This phenomenon is divided into several stages whose mechanisms partially overlap both spatially and temporally (Figure 1).

After an injury, the hemostatic and coagulative phases take place thanks to platelets and the activation of tissue coagulation factors. The mediators released during this initial process trigger an inflammatory reaction involving the activation of mast cells and the retrieval of neutrophils and macrophages (including dendritic cells). These cell types produce pro-inflammatory cytokines and growth factors, resulting in the engagement of fibroblasts that differentiate into myofibroblasts, which are responsible for both Extracellular Matrix (ECM) deposition and wound contraction. Activation of these cells also stimulates

*The publisher is not responsible for the content or functionality of any supporting information supplied by the authors. Any queries should be directed to the corresponding author for the article.*

*All claims expressed in this article are solely those of the authors and do not necessarily represent those of their affiliated organizations, or those of the publisher, the editors and the reviewers. Any product that may be evaluated in this article or claim that may be made by its manufacturer is not guaranteed or endorsed by the publisher.*

the proliferation of endothelial and epithelial cells at the wound site to induce neo-angiogenesis and re-epithelialization, respectively.

The reformation phase begins about three weeks after an injury and lasts for more than a year. During this time, all processes activated in previous phases are silenced, and macrophages, isolated endothelial cells, and myofibroblasts go into apoptosis or are repositioned by the wound, leaving a region rich in collagen and other ECM deposition proteins. Interactions between the epidermis and dermis, together with additional feedback, allow for the continuous regulation of skin integrity and homeostasis (Singer *et al.*, 1999; Martin *et al.*, 2015; Cañedo-Dorantes and Cañedo-Ayala, 2019; Razyieva *et al.*, 2021).

### **Chronic skin lesions**

International literature considers chronic skin lesion that does not heal within six to eight weeks. In these lesions, the inflammatory reaction continues over time, balancing productive and degenerative phenomena without progressing through the normal, orderly, and timely sequence of the reparative process, or passes through these phases without succeeding in restoring the anatomical and functional integrity of the tissue (Razyieva *et al.*, 2021; Falanga *et al.*, 2022). The causes of the delay in the process, which leads to its block and, indeed, its chronicization, are many: considering that about 140 pathologies can act in this sense, and that the average co-morbidity over the age of 65 is about 6 (85% of the population is affected by at least one chronic disease; 30% have 3 or more diseases with a chronic history), in probabilistic terms it is possible to have a number of clinical scenarios equal to 1406. The etiology of skin ulcers includes several clinical scenarios and syndromes, which are well-known and identified in the literature, and whose discussion is beyond the scope of this paper (Razyieva *et al.*, 2021; Falanga *et al.*, 2022).

In ulcers, a prolonged inflammatory phase gives rise to high protease activity, resulting in degeneration of growth factors and other molecular stimuli that promote the reparative phase. Furthermore, in chronic wounds, excessive secretion of pro-inflammatory cytokines and hydrolytic enzymes prevents reparative processes from prevailing over destructive ones (Figures 2-3). It has, therefore, been suggested that action should be taken to reduce protease activity in order to protect endogenous growth factors and to allow the normal reparative process to continue. Therefore, while in the normal reparative process, a correct balance between the formation of new tissue and its physiological destruction is crucial, in chronic skin lesions, elevated levels of MMPs and decreased levels of tissue inhibitors of Matrix Metalloproteinase (MMPs) have been shown, resulting in altered reorganization of the ECM and its increased degradation (Razyieva *et al.* 2021; Falanga *et al.*, 2022).

It has also been shown that the skin microenvironment cells within chronic lesions become senescent and non-responsive to the stimulation of certain signals (cytokines, growth factors), as a result of phenotypic dysregulation phenomena (for example TGF- $\beta$ 1 and PDGF in the case of venous ulcers). Infections are also an important and frequent cause of repair process blockage: the increase in the bacterial load leads to the persistence of the inflammatory phase, with the production of high MMP levels and consequent aggravation of the destructive processes of the ECM (Razyieva *et al.*, 2021; Falanga *et al.*, 2022).

*The publisher is not responsible for the content or functionality of any supporting information supplied by the authors. Any queries should be directed to the corresponding author for the article.*

*All claims expressed in this article are solely those of the authors and do not necessarily represent those of their affiliated organizations, or those of the publisher, the editors and the reviewers. Any product that may be evaluated in this article or claim that may be made by its manufacturer is not guaranteed or endorsed by the publisher.*



### ***Photodynamic therapy***

Created for the non-surgical treatment of certain skin pathologies (Cappugi *et al.*, 2001), PDT is now one of the most innovative and promising options currently available for the treatment of different types of lesions (Corsi, 2012; Lecci *et al.*, 2013; Grandi *et al.*, 2018; Grandi *et al.*, 2022) (Figure 4).

PDT is a treatment procedure that utilizes a photo-sensitizer (administered topically or systemically), light (which interacts with the substance in question), and oxygen to cause selective cell death by necrosis or apoptosis of sensitized 'atypical' cells, in which the photo-sensitizer or its precursor -administered topically or intravenously - selectively accumulates. The photodynamic effect is mediated by the generation of reactive oxygen species, a process that depends on intracellular interactions of the photo-sensitizer with light and oxygen itself. The topical use of ALA represented a breakthrough in PDT in the dermatological field as it is easily absorbed in the skin. At a cellular level, the prodrug, once converted into protoporphyrin IX, by means of a light source, triggers the production of reactive oxygen species that cause cell death of the target cells (Cappugi *et al.*, 2001; Smits *et al.*, 2009; Allison and Sibata, 2010; Grandi *et al.*, 2018; Grandi *et al.*, 2022). The presence of Reactive Oxygen Species (ROS) in the immediate vicinity of cellular and sub-cellular membranes (in particular, the mitochondrial ridges) stops the process of cellular respiration, allowing the release of cytochrome C with consequent activation of the caspase cascade that eventually leads to the incipit of the apoptotic phenomenon by intrinsic pathway (Lecci *et al.* 2013, Grandi *et al.*, 2022) (Figure 5).

This effect is boosted by degeneration of small vessels and the triggering of an inflammatory reaction (Corsi *et al.*, 2013).

### ***Cellular mechanisms induced by photodynamic therapy in the treatment of chronic ulcers***

#### ***Activation of the immune system***

Research indicates that PDT can induce an acute inflammatory response mainly linked to the activation of the immune system (Reginato *et al.*, 2014).

This has been confirmed by the description of how PDT not only induces the diversification of new fibroblasts (effector cells) (Corsi *et al.*, 2016), but these cell types have close relationships with mast cells that are in turn positive for Fibroblast Growth Factor (FGF) (as well as TNF-alpha) in their granules.

These findings, therefore, support the suggestion that after therapy, mast cells may send signals for the same fibroblast recruitment and differentiation (Corsi *et al.*, 2016). As far as mast cells are concerned, they increase in number and undergo degranulation during therapy (Figure 6). The possible origin of their increase may be due to the migration of neighboring cells, differentiation of precursors already in the tissue, or the inflow of precursors and their differentiation into the latter cells. Therefore, these cell types would not only be recruited, but also activated to secrete their granules into the dermis in response to the

*The publisher is not responsible for the content or functionality of any supporting information supplied by the authors. Any queries should be directed to the corresponding author for the article.*

*All claims expressed in this article are solely those of the authors and do not necessarily represent those of their affiliated organizations, or those of the publisher, the editors and the reviewers. Any product that may be evaluated in this article or claim that may be made by its manufacturer is not guaranteed or endorsed by the publisher.*

treatment. The vessels of the sub-papillary plexus, presumably the venules, seem to be a privileged site of cell infiltration and cell clustering during therapy (Corsi *et al.*, 2016).

The activation of the immune system is further confirmed by the fact that after treatment with PDT, there is significant expression of both TNF-alpha (together with GM-CSF, a key player in the differentiation of dendritic cells including plasmacytoid cells, which in turn interact with the so-called regulatory T-type lymphocytes) and TGF-beta (de facto substantial in the differentiation of macrophages) by mast cells. In turn, the induction of TGF-beta is undoubtedly linked to the reduction of wound volume after treatment (Grandi *et al.*, 2018). Indeed, TGF-beta appears to influence, at various stages of ulcer healing, the epithelial-mesenchymal transition, which allows the migration of keratinocytes from the edges towards the wound bed. Furthermore, this cytokine is also able to induce differentiation into myofibroblasts as part of the processes observed in scar reshaping (Haensel and Day, 2018).

Other studies have also shown that PDT has a significant impact on the activation of neutrophils, which would contribute to the increase in pro-inflammatory cytokines after therapy. Parallel to the acute phase of inflammation resolution and restoration of tissue homeostasis, lipid mediators are produced (see Figure 2 on the lipofuscin indication), which are associated with anti-inflammatory and immunomodulatory properties, including inhibition of leukocyte chemotaxis, blockade of TNF-alpha and IL-6 production, which in turn induces increased IL-10 expression (Nesi-Reis *et al.*, 2018; Oyama *et al.*, 2020; Tottoli *et al.*, 2020, Grandi *et al.*, 2022).

We can, therefore, conclude that PDT has a significant impact on the immune system, with both immunostimulatory and immunosuppressive effects, being probably the determining factor related to the type of cell death induced.

### Neuroimmunomodulation

The immune system activity can be regulated by the nervous system (Steinmann, 2004): this close correlation is also documented in ulcer healing. Indeed, experimental observations suggest that neurogenic stimuli profoundly affect wound repair after injury and that delayed wound healing after surgical resection of skin nerves is observed in animal models (Laverdet *et al.*, 2015; Ashrafi *et al.*, 2016).

Recent studies have shown that the density of neuronal populations belonging to the autonomous nervous system, located in the dermis, containing the typical nerve mediators involved in ulcer healing (CGRP, NGF, NKA, NPY, SP, PGP 9.5 and VIP) (Laverdet *et al.*, 2015; Ashrafi *et al.*, 2016) increases after PDT treatment. Furthermore, the percentage of mast cells that contain and secrete NGF and VIP increases after a single irradiation. Considering that both VIP and NGF stimulate mast cell degranulation, these data seem to correlate with the previously reported increase in mast cell degranulation index after PDT treatment and suggest that this phenomenon may be related to neurogenic stimuli. With this in mind, we can assume that after therapy, mast cell activity consists of an increased release of NGF and VIP and that these mediators are able to activate neurons and nerve fibers in the dermis (Siiskonen *et al.* 2019; Grandi *et al.*, 2021; Grandi *et al.* 2022). The activation of nerve fibres could, in turn, be related to other

*The publisher is not responsible for the content or functionality of any supporting information supplied by the authors. Any queries should be directed to the corresponding author for the article.*

*All claims expressed in this article are solely those of the authors and do not necessarily represent those of their affiliated organizations, or those of the publisher, the editors and the reviewers. Any product that may be evaluated in this article or claim that may be made by its manufacturer is not guaranteed or endorsed by the publisher.*

phenomena, such as increased secretion of ECM by fibroblasts as has been previously observed, increased TGF-beta, and cellular infiltrate response (Corsi *et al.*, 2013; Lecci *et al.*, 2015; Corsi *et al.*, 2016).

Recently, NO has been added to the list of mediators involved in wound healing, an extracellular molecular messenger, defined as the smallest known signaling molecule capable of crossing membranes freely, due to its gaseous nature and characterized by a rather short half-life (Lee *et al.*, 2017). This molecule appears to be generated from the NOs enzyme complex, where the inducible isoform is over-regulated under conditions of stress; in fact, the expression of the enzyme is intensified in the presence of inflammatory cytokines, apoptotic bodies, or bacterial antigens. Consequently, iNOS has also been hypothesized to be involved in the inflammatory phase of wound repair, during which it promotes vasodilation and antibacterial activity (Shi *et al.*, 2001; Luo *et al.*, 2005; Grandi *et al.*, 2022). Preliminary results of experiments indicate that iNOS expression is intensified in chronic wounds treated with PDT. For mast cells, the degranulation index of these cell types increases, they contain iNOS, but the percentage of these cells containing this mediator after treatment decreases in contrast to granulocytes to M2-type macrophages and neurons where iNOS expression increases (Notari *et al.*, 2023).

However, the response analysis of other cell types involved in iNOS secretion and, therefore, wound healing after PDT is currently underway in the laboratory.

## Conclusions

The information given holds meaning, if we consider that the understanding and use of PDT is still at an early stage; further insights into its use can be gathered from the new concepts discussed regarding PhotoBioModulation. As far as the description of the cellular mechanisms induced by this type of therapy on chronic ulcers is concerned, this undoubtedly lacks a certain amount of experience, as the healing of ulcers and the response of the various tissues involved is still an unresolved problem. It is with this view that the involvement of the nervous system and its interactions with the immune system are important topics that, if investigated further, could be the key to understanding the resolution of this type of wound when given such therapy.

## Acknowledgements

All students would like to dedicate this contribution to the memory of their professor Pietro Cappugi, who launched and consequently encouraged, through his ideas, the experimental projects narrated within the text and brought together in the relative section of this document.

*The publisher is not responsible for the content or functionality of any supporting information supplied by the authors. Any queries should be directed to the corresponding author for the article.*

*All claims expressed in this article are solely those of the authors and do not necessarily represent those of their affiliated organizations, or those of the publisher, the editors and the reviewers. Any product that may be evaluated in this article or claim that may be made by its manufacturer is not guaranteed or endorsed by the publisher.*

## References

- Allison RR, Sibata CH. Photodynamic therapy: mechanism of action and role in the treatment of skin disease. *G Ital Dermatol Venereol.* 2010;145:491-507.
- Ashrafi M, Baguneid M, Bayat A. The role of neuromediators and innervation in cutaneous wound healing. *Acta Derm Venereol.* 2016;96:587-94.
- Bacci S. Fine regulation during wound healing by mast cells, a physiological role not yet clarified. *Int J Mol Sci.* 2022;23:1820.
- Bacci S. Cutaneous wound healing: cellular mechanisms and therapies (an update). *Medical Research Archives.* 2019;12:1-14.
- Cañedo-Dorantes L, Cañedo-Ayala M. Skin acute wound healing: A comprehensive review. *Int J Inflamm.* 2019;3706315-29.
- Cappugi P, Campolmi P, Mavilia L, et al. Topical 5-aminolevulinic acid and photodynamic therapy in dermatology: a minireview. *J Chemother.* 2001;5:494-502.
- Corsi A, Lecci PP, Bacci S, et al. Early activation of fibroblasts during PDT treatment in leg ulcers. *G Ital Dermatol Venereol.* 2016;151:223-9.
- Corsi A, Lecci PP, Bacci S, Cappugi P. Chronic wounds treated with photodynamic therapy: analysis of cellular response – preliminary results. *Acta Vulnol.* 2013;11:23-33.
- Corsi A. Chronic venous skin lesions and photodynamic therapy: scientific evidence for treatment. Master's Degree Thesis, Level II, 2012.
- Falanga V, Isseroff RR, Soulika AM, et al. Chronic wounds. *Nat Rev Dis Primers.* 2022;8:50.
- Grandi V, Bacci S, Corsi, A, et al. ALA-PDT exerts beneficial effects on chronic venous ulcers by inducing changes in inflammatory microenvironment, especially through increased TGF-beta release: A pilot clinical and translational study. *Photodiagnosis Photodynamic Ther.* 2018;21:252-6.
- Grandi V, Corsi A, Pimpinelli N, Bacci, S. Cellular mechanisms in acute and chronic wounds after PDT therapy: an update. *Biomedicines.* 2022;10:1624.
- Grandi V, Paroli G, Puliti E, et al. Single ALA-PDT irradiation induces increase in mast cells degranulation and neuropeptide acute response in chronic venous ulcers: A pilot study. *Photodiagnosis Photodynamic Ther.* 2021;34:102222.
- Grandi V, Sessa M, Pisano L, et al. Photodynamic therapy with topical photosensitizers in mucosal and semi mucosal areas: Review from a dermatologic perspective. *Photodiagnosis Photodyn Ther.* 2018;23:119-31.

*The publisher is not responsible for the content or functionality of any supporting information supplied by the authors. Any queries should be directed to the corresponding author for the article.*

*All claims expressed in this article are solely those of the authors and do not necessarily represent those of their affiliated organizations, or those of the publisher, the editors and the reviewers. Any product that may be evaluated in this article or claim that may be made by its manufacturer is not guaranteed or endorsed by the publisher.*

- Haensel D, Dai X. Epithelial-to-mesenchymal transition in cutaneous wound healing: where we are and where we are heading. *Dev Dyn*. 2018;247:473-80.
- Kang K, Bacci S. Photodynamic Therapy. *Biomedicines*. 2022;10:2701.
- Laverdet B, Danigo A, Girard D, et al. Skin innervation: important roles during normal and pathological cutaneous repair. *Histol Histopathol*. 2015;30:875-92.
- Lecci PP, Corsi A, Cappugi PP, Bacci S. Photodynamic therapy in the treatment of chronic skin lesions. Clinical evidence and experimental practice. Arachne Publisher, Rome, Italy, 2013;1-64.
- Lee M, Rey K, Besler K, et al. Immunobiology of nitric oxide and regulation of inducible nitric oxide synthase. *Results Probl Cell Diff*. 2017;62:181-207.
- Luo JD, Chen AF. Nitric oxide: a newly discovered function on wound healing. *Acta Pharmacol Sin*. 2005;26:259-64.
- Martin P, Nunan R. Cellular and molecular mechanisms of repair in acute and chronic wound healing. *Br J Dermatol*. 2015;173:370-8.
- Nesi-Reis V, Lera-Nonose SV, Oyama J, et al. Contribution of photodynamic therapy in wound healing: a systematic review. *Photodiagnosis Photodyn Therapy*. 2018;30:294-305.
- Niculescu AG; Grumezescu, AM. Photodynamic Therapy—An Up-to-Date Review. *Appl Sci*. 2021;11:3626.
- Notari L, Nardini P, Grandi V, et al. Neuroimmunodulation in chronic wounds healing after treatment with photodynamic therapy: the role of iNOs in Proceedings of the 2nd International Electronic Conference on Biomedicines, 1–31 March 2023, MDPI: Basel, Switzerland.
- Oyama J, Ramos-Milaré Á, Lera-Nonose SV, et al. Photodynamic therapy in wound healing in vivo, a systematic review. *Photodiagnosis Photodyn Therapy*. 2020;10:101682.
- Raziyeva K, Kim Y, Zharkinbekov Z, et al. Immunology of acute and chronic wound healing. *Biomolecules*. 2021;11:700.
- Reginato E, Wolf P, Hamblin MR. Immune response after photodynamic therapy increases anti-cancer and anti-bacterial effects. *World J Immunol*. 2014;4:1-11.
- Shi HP, Most D, Efron DT, et al. The role of iNOS in wound healing. *Surgery*. 2001;130:225-9.
- Singer AJ, Clark RA. Cutaneous wound healing. *N Engl J Med*. 1999;341:738-46.
- Siiskonen H, Harvima I. Mast cells and sensory nerves contribute to neurogenic inflammation and pruritus in chronic skin inflammation. *Front Cell Neurosci*. 2019;13:422.

*The publisher is not responsible for the content or functionality of any supporting information supplied by the authors. Any queries should be directed to the corresponding author for the article.*

*All claims expressed in this article are solely those of the authors and do not necessarily represent those of their affiliated organizations, or those of the publisher, the editors and the reviewers. Any product that may be evaluated in this article or claim that may be made by its manufacturer is not guaranteed or endorsed by the publisher.*

Smits T, van Laarhoven AI, Staassen A, et al. Induction of protoporphyrin IX by aminolaevulinic acid in actinic keratosis, psoriasis, and normal skin: preferential porphyrin enrichment in differentiated cells. *Br J Dermatol.* 2009;160:849-57.

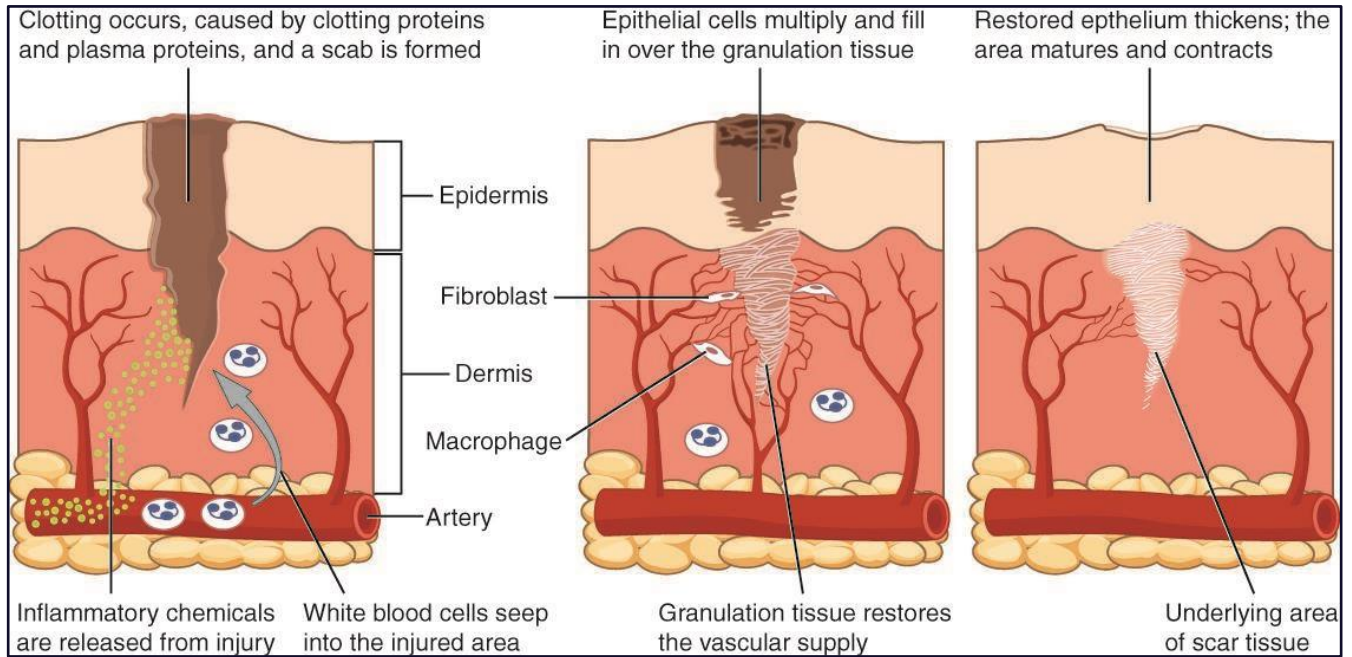
Steinmann L. Elaborate interactions between the immune and nervous system. *Nat Immunol.* 2004;5:575-81.

Szeimies RM; Drager J; Abels C; Landthaler M. History of photodynamic therapy in dermatology. In: *Photodynamic Therapy and Fluorescence Diagnosis in Therapy*; Calzavara-Pinton P, Rolf-Markus S Ortel B, Editori; Elsevier Science: Amsterdam, The Netherlands, Volume 2, pp. 3–15, 2001.

Tottoli EM, Dorati R, Genta I, et al. Skin wound healing process and new emerging technologies for skin wound care and regeneration. *Pharmaceutics.* 2020;12:735-65.

*The publisher is not responsible for the content or functionality of any supporting information supplied by the authors. Any queries should be directed to the corresponding author for the article.*

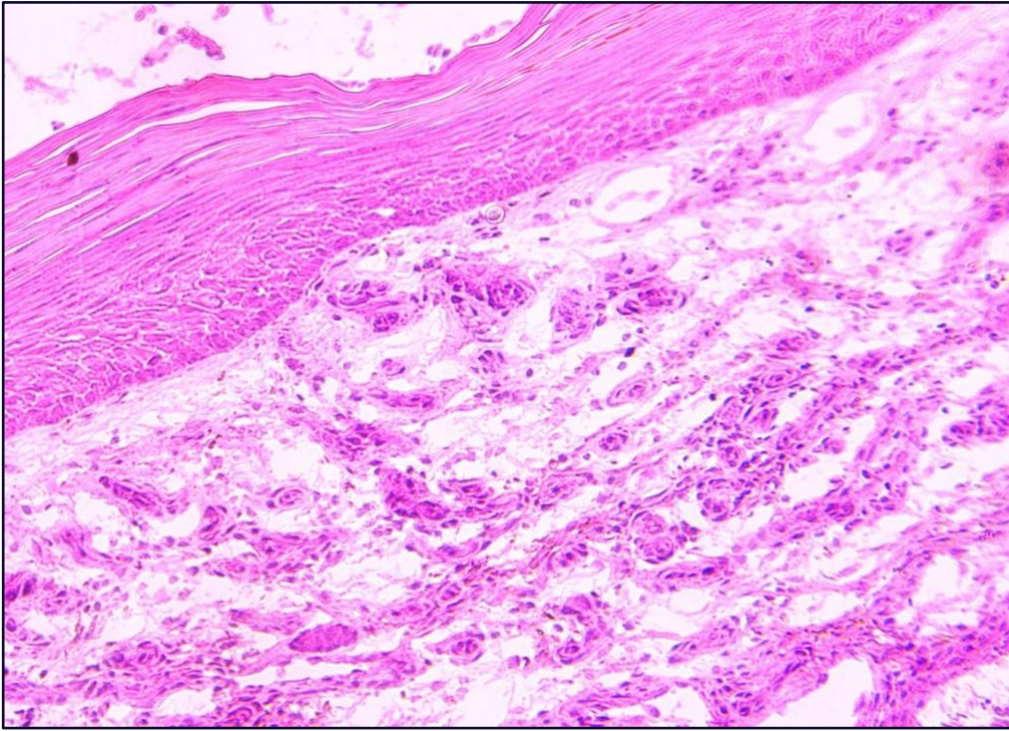
*All claims expressed in this article are solely those of the authors and do not necessarily represent those of their affiliated organizations, or those of the publisher, the editors and the reviewers. Any product that may be evaluated in this article or claim that may be made by its manufacturer is not guaranteed or endorsed by the publisher.*



**Figure 1.** Sample diagram of the various phases involved in the healing of ulcers (source: Wikipedia).

*The publisher is not responsible for the content or functionality of any supporting information supplied by the authors. Any queries should be directed to the corresponding author for the article.*

*All claims expressed in this article are solely those of the authors and do not necessarily represent those of their affiliated organizations, or those of the publisher, the editors and the reviewers. Any product that may be evaluated in this article or claim that may be made by its manufacturer is not guaranteed or endorsed by the publisher.*

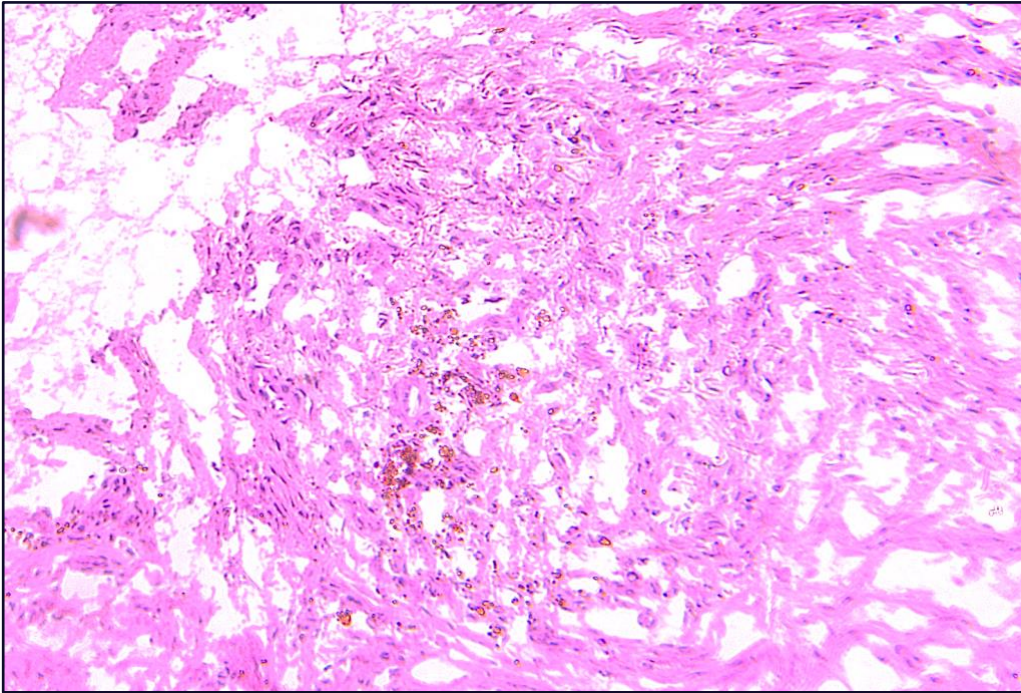


**Figure 2.** Chronic wound: Increased epidermis thickness and richness of cellular infiltrate. Light microscopy, x 40 magnification (courtesy of the author of this paper).

*The publisher is not responsible for the content or functionality of any supporting information supplied by the authors. Any queries should be directed to the corresponding author for the article.*

*All claims expressed in this article are solely those of the authors and do not necessarily represent those of their affiliated organizations, or those of the publisher, the editors and the reviewers. Any product that may be evaluated in this article or claim that may be made by its manufacturer is not guaranteed or endorsed by the publisher.*

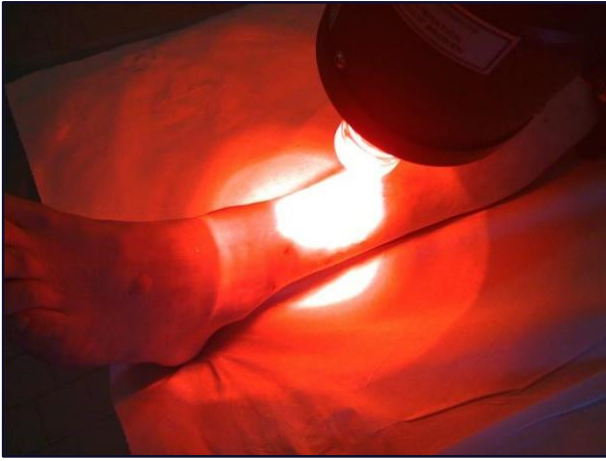




**Figure 3.** Chronic wound: rich cellular infiltrate and lipofuscins (granular accumulations of molecules that cannot be degradable by lysosomal hydrolases nor eliminable by exocytosis. Such granules usually take on a yellowish-brown color and are predominantly composed of lipids). Light microscopy, magnification x20 (courtesy of the author of this document).

*The publisher is not responsible for the content or functionality of any supporting information supplied by the authors. Any queries should be directed to the corresponding author for the article.*

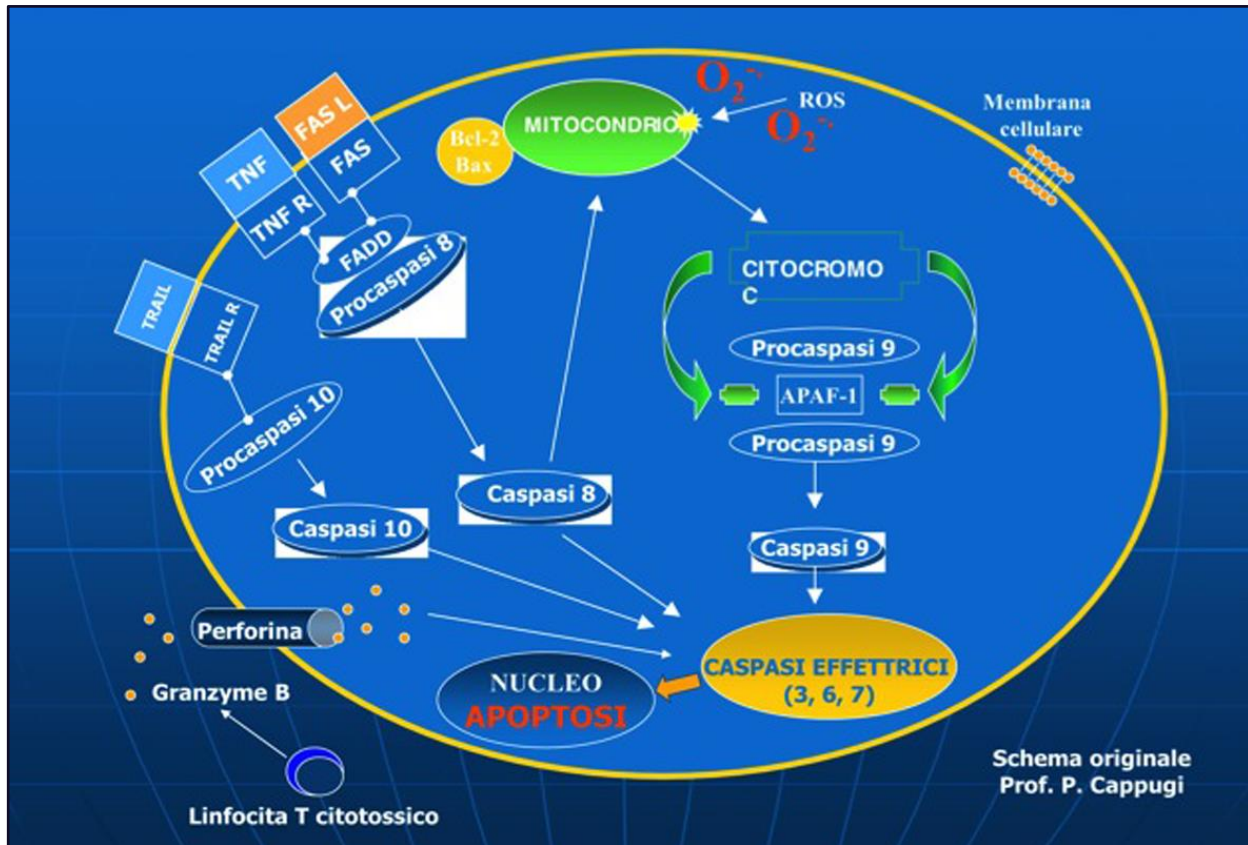
*All claims expressed in this article are solely those of the authors and do not necessarily represent those of their affiliated organizations, or those of the publisher, the editors and the reviewers. Any product that may be evaluated in this article or claim that may be made by its manufacturer is not guaranteed or endorsed by the publisher.*



**Figure 4.** Treatment modalities of PDT. (From: Lecci PP, Corsi A, Cappugi PP, Bacci S. Photodynamic therapy in the treatment of chronic skin lesions. Clinical evidence and experimental practice. Aracne Editor, Rome, Italy, 2013; 1-64.)

*The publisher is not responsible for the content or functionality of any supporting information supplied by the authors. Any queries should be directed to the corresponding author for the article.*

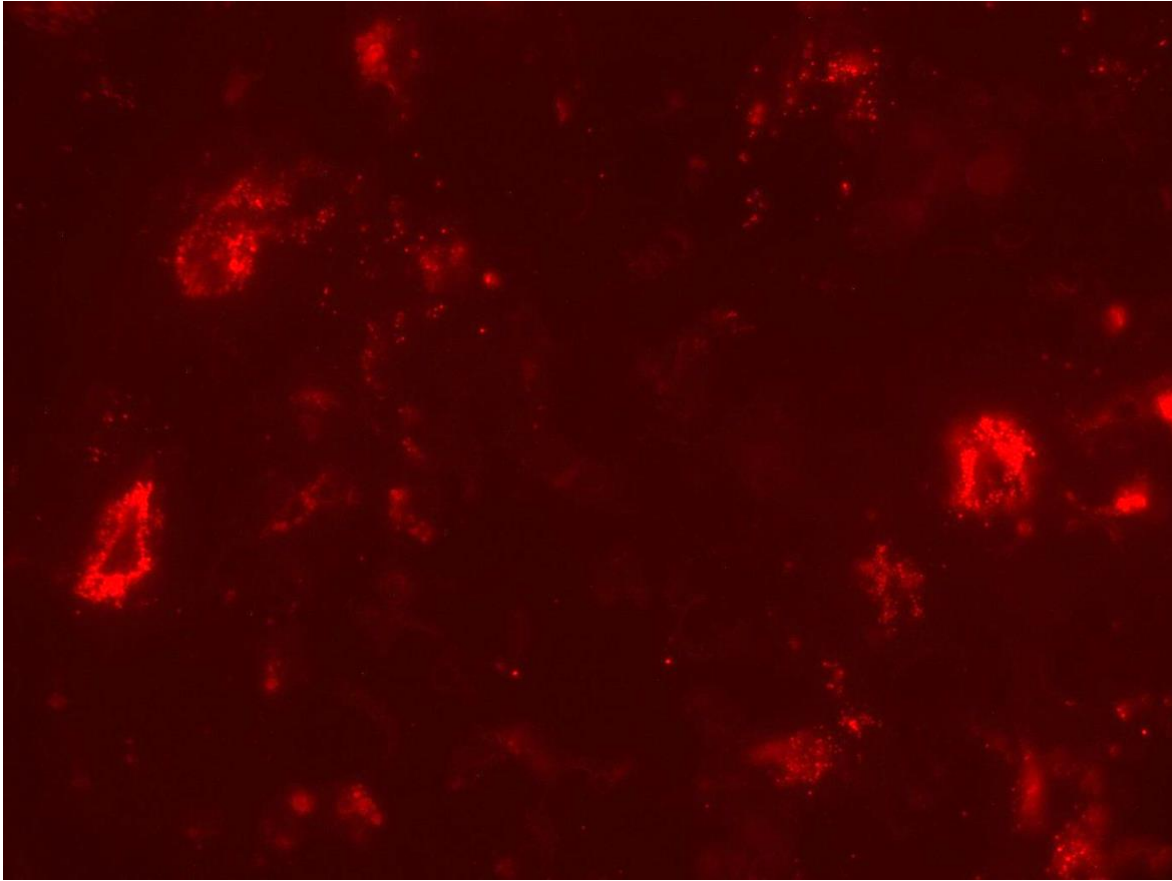
*All claims expressed in this article are solely those of the authors and do not necessarily represent those of their affiliated organizations, or those of the publisher, the editors and the reviewers. Any product that may be evaluated in this article or claim that may be made by its manufacturer is not guaranteed or endorsed by the publisher.*



**Figure 5.** PDT-induced cellular and molecular activations. (From: Lecci PP, Corsi A, Cappugi PP, Bacci S. Photodynamic therapy in the treatment of chronic skin lesions. Clinical evidence and experimental practice. Aracne Editrice, Rome, Italy, 2013; 1-64.)

*The publisher is not responsible for the content or functionality of any supporting information supplied by the authors. Any queries should be directed to the corresponding author for the article.*

*All claims expressed in this article are solely those of the authors and do not necessarily represent those of their affiliated organizations, or those of the publisher, the editors and the reviewers. Any product that may be evaluated in this article or claim that may be made by its manufacturer is not guaranteed or endorsed by the publisher.*



**Figure 6.** Degranulating mast cells. Fluorescence microscopy, x 40 magnification (courtesy of the author of this paper).

*The publisher is not responsible for the content or functionality of any supporting information supplied by the authors. Any queries should be directed to the corresponding author for the article.*

*All claims expressed in this article are solely those of the authors and do not necessarily represent those of their affiliated organizations, or those of the publisher, the editors and the reviewers. Any product that may be evaluated in this article or claim that may be made by its manufacturer is not guaranteed or endorsed by the publisher.*

## Photodynamic therapy

Vieri Grandi

Photodynamic Therapy (PDT) is a form of phototherapy that uses the interaction between three components: a photosensitizer, a light source, and tissue oxygen. The interaction between these generates selective toxic damage at the cell level.

The biochemical mechanism by which PDT acts is complex. In the presence of triplet oxygen ( $3O_2$ ), the photo-sensitizer penetrates into tissue and, irradiated by a light source with a wavelength absorbable by the photo-sensitizer itself, produces highly unstable Reactive Oxygen Species (ROS). Depending on the energy applied and the properties of the photosensitizers, variable levels of ROS can be generated (B. Yang, Chen, and Shi 2019). High levels of ROS may result in toxic damage that can destroy neoplastic cells or inactivate even multidrug-resistant pathogens, while less pronounced levels may induce tissue proliferation and/or regeneration (Vallejo *et al.* 2020). In the medical field, we use PDT in the treatment of numerous oncological and non-oncological pathologies (C. A. Morton *et al.* 2019; C. A. Morton *et al.* 2020), benefiting from its minimal invasiveness, its ease of use in the outpatient setting, and its excellent short- and long-term safety record.

The most important factor in PDT is undoubtedly the choice of photo-sensitizer: its photo-physical, photo-chemical, and pharmaco-kinetic properties and its deposition site at intracellular level determine the extent and selectivity of the photo-dynamic effect (Agostinis *et al.* 2011). Topical administration of the photo-sensitizer is preferable in the context of a chronic ulcer, as it allows proper visualization during application of the drug, a greater concentration of the drug in the area to be treated, and avoids the systemic photosensitivity that arises after intravenous administration. Intravenous administration may lead to damage at the vascular bed level; hypoxic damage may be useful in the treatment of a neoplasm, but it may be counterproductive in the context of a chronic non-neoplastic wound, as it increases the hypoxic state, which plays a key role in the noxa.

Provided that there is no single ideal photo-sensitizer, the choice must fall on molecules that can be applied topically and for which a positive effect on the healing of skin ulcers is documented. The topic is broad and has recently been analyzed in two reviews (Vallejo *et al.* 2021; 2020). Different chemical categories have been tested in predominantly preclinical settings and in a few pilot studies as photo-sensitizers in chronic ulcers, including photosensitizers derived from phenothiazines (methylene blue and toluidine blue), xanthenic dyes (such as rose Bengal), and tetrapyrrolic macrocycles and analogs such as porphyrins, chlorines, and phthalocyanines.

The choice of light source also plays a considerable role. For PDT in clinical practice, laser or LED (Light Emitting Diodes) sources are being used. Laser sources emit in a single wavelength at high fluence and with enormous precision. In contrast, LED sources are more cost-effective and can cover larger tissue areas, at the cost of lower fluence and less precision. The wavelength determines the ability of light to penetrate tissue. In particular, lengths around 600 to 800 nm are considered to have adequate penetration capacity into the skin to be used in clinical practice. In essence, the red color spectrum has the greatest penetration into the skin, followed in order by green and blue (Agostinis *et al.* 2011).

*The publisher is not responsible for the content or functionality of any supporting information supplied by the authors. Any queries should be directed to the corresponding author for the article.*

*All claims expressed in this article are solely those of the authors and do not necessarily represent those of their affiliated organizations, or those of the publisher, the editors and the reviewers. Any product that may be evaluated in this article or claim that may be made by its manufacturer is not guaranteed or endorsed by the publisher.*

Being a method based on the interaction of a tissue with a light energy, it is apparent that the effectiveness is to a large extent directly proportional to the total energy applied per volume of the treated area. This can be expressed in the form of a series of parameters, such as power, irradiance, energy density, irradiation time and release of light mode (simple or fractional) (Henderson, Busch, and Snyder 2006). The most commonly used way to report a PDT treatment schedule is energy density expressed as J/cm<sup>2</sup>, which in turn derives from the measurement of time (in seconds) and irradiance (in W/cm<sup>2</sup>) (Peplow, Chung, and Baxter 2012).

### ***Role of PDT in ulcer healing***

Although the intrinsic mechanisms by which PDT leads to improvement in ulcers are not fully clarified, we do know that ROS leads to cell death in tissue irradiated by apoptosis, necrosis, and/or autophagy. Since the pathogenetic mechanisms of inflammation in chronic ulcers involve cell lines that are also present in the tumor microenvironment, we can - in part - gather some of the data in the literature from studies carried out in the field of oncology. Inflammation plays a fundamental role in the healing process of ulcers both in normal conditions and in chronic pathological ulcers. In the latter, however, a state of chronic inflammation persists in which a variable amount of contamination, colonization, or even infection by numerous microorganisms takes over; overall, intrinsic and extrinsic factors determine the slowing/stopping of healing. PDT can act favorably on the inflammation of chronic ulcers by stimulating the induction of a new acute phase and reducing the bacterial/fungal load. There are numerous preclinical and clinical studies to support this hypothesis (Brown 2012; Morley *et al.* 2013; Clayton and Harrison 2007; Devirgiliis *et al.* 2011; Grandi *et al.* 2021; Lin *et al.* 2021; Kawczyk-Krupka *et al.* 2018; Grandi *et al.* 2018; Aspiroz *et al.* 2017; Lei *et al.* 2015; Jori *et al.* 2006; Krupka *et al.* 2021). At present, unfortunately, we have little data regarding the changes that occur *in vivo* in PDT-treated ulcers. We know that PDT acts on various stages of the healing process and that overall, it can accelerate tissue repair (Garcia *et al.* 2010; Z. Yang *et al.* 2021; T. Yang *et al.* 2020; de Vasconcelos Catão *et al.* 2015). The initial acute inflammatory phase in the tissue repair process is driven by neutrophil granulocytes, under the stimulus of TNF-alpha released following tissue damage. (Anzengruber *et al.* 2015; Gollnick and Brackett 2010). PDT causes an increase in neutrophils and their activation (Gollnick and Brackett 2010), with an increase in proinflammatory cytokines linked to the acute phase (Mroz and Hamblin 2011; Domínguez *et al.* 2010). Soon after a PDT treatment, there is an “*in situ*” accumulation of mast cells, monocytes, macrophages, and myeloid lineage cells, with a subsequent recall of CD8+ lymphocytes. This infiltrate is intended to eliminate damaged cells and extracellular material (Agostinis *et al.* 2011). Although in the very early stages, PDT causes an increase in acute inflammation (which is also reflected clinically in the form of erythema, edema, increased exudate, and sometimes burning or pain of variable intensity), PDT also has locally immunosuppressive activity, still not fully clarified but well summarised in the exhaustive review work of Mroz and collaborators (Mroz and Hamblin 2011). What we observe in the follow-up of some patients with chronic ulcers treated with PDT is a partial reduction of inflammation strongly linked to a reduction in the microbial load (Brown 2012; Morley *et al.* 2013; Lei *et al.* 2015). Moreover, in various experimental studies, PDT causes immunomodulation even in the absence of a microbial load (Giannopoulou *et al.* 2012), so it is fair to believe that PDT has direct immunomodulatory

*The publisher is not responsible for the content or functionality of any supporting information supplied by the authors. Any queries should be directed to the corresponding author for the article.*

*All claims expressed in this article are solely those of the authors and do not necessarily represent those of their affiliated organizations, or those of the publisher, the editors and the reviewers. Any product that may be evaluated in this article or claim that may be made by its manufacturer is not guaranteed or endorsed by the publisher.*

and immunosuppressive activities and not exclusively linked to its antimicrobial activity. After the acute phase and the reduction of inflammation and microbial load, PDT has a positive effect on the wound re-epithelialization phase. In experimental models of chronic ulcers treated with PDT, histologically, physiological re-epithelialization associated with the recall of fibroblasts, fibrin, granulation tissue, deposition of new collagen, keratinocyte proliferation, and neo-angiogenesis is observed. (Sperandio *et al.* 2010; Garcia *et al.* 2010; Mills *et al.* 2014; Grandi *et al.* 2018; 2021; Corsi *et al.* 2016). In the so-called reshaping phase, a dynamic balance between synthesis and degradation of the extracellular matrix is physiologically observed. An imbalance obviously determines a delay in healing, as well as in the quality and aesthetic appearance of the scar. In this late stage of the healing process, PDT works by increasing the local production of TGF-beta; in turn, TGF-beta (Beta1 and Beta3) plays a fundamental role in organizing the deposition of new collagen fibers (Mills *et al.* 2014; Grandi *et al.* 2021; 2018). Finally, PDT can increase the local production of several Metalloproteinases (MMPs), in particular 1 and 9, which act by degrading collagen and reshaping the extracellular matrix (Choi *et al.* 2010).

### ***PDT in clinical management of chronic ulcers***

Despite the above data, PDT is neither recognized nor specifically mentioned in the Wound Healing Society's 2006 Guidelines for the Treatment of Venous Ulcers or Diabetic Foot Ulcers (and their 2015 updates) (Marston *et al.* 2016; Steed *et al.* 2006; Robson *et al.* 2006; Lavery *et al.* 2016). Furthermore, no photosensitizer on the market is approved in Italy for the treatment of chronic venous ulcers or diabetic foot ulcers. It is, therefore, essential to carefully evaluate the use of PDT in chronic ulcers on a case-by-case basis. At present, it is suggested that PDT be used as supportive therapy in chronic ulcers, preferably in the context of controlled clinical trials. These are some points worth noting:

This method cannot and must not replace standard management, but can possibly be used in addition to it, as supportive therapy, in refractory or worsening cases after no less than 4 weeks of optimal management.

It is essential to use this technique only in patients with a proven diagnosis of a venous ulcer or a diabetic or mixed foot ulcer. There are no data on the use of PDT in the treatment of ulcers on an autoimmune or arterial insufficiency basis, while for the management of ulcers on a neoplastic basis the desirable goal is the radical removal of the neoplasm. If radical treatment options are not possible, in selected cases, and in the context of a multi-disciplinary discussion, PDT can be taken into consideration.

It is crucial to collect and maintain accurate medical records. Given the complexity of managing patients with chronic refractory ulcers, it is of paramount importance to collect as much information as possible and to use both qualitative and quantitative assessment systems, in addition to obtaining standardized photographs of treated wounds and possibly questionnaires to assess the patient's individual response.

The patient (or his or her legal guardian) must be fully informed of the off-label use of this method, of any potential risks and unwanted effects, primarily of the pain during the application and in the hours following it.

*The publisher is not responsible for the content or functionality of any supporting information supplied by the authors. Any queries should be directed to the corresponding author for the article.*

*All claims expressed in this article are solely those of the authors and do not necessarily represent those of their affiliated organizations, or those of the publisher, the editors and the reviewers. Any product that may be evaluated in this article or claim that may be made by its manufacturer is not guaranteed or endorsed by the publisher.*

It is recommended to be familiar with PDT in its approved indications before using it as support therapy in chronic ulcers. It is also highly preferable to be particularly familiar with the machine used and the chosen photosensitizer.

It is essential to report which photosensitizer was used, its concentration, incubation time, wavelength(s) applied, energy density (in J/cm<sup>2</sup>) or irradiation power (in mW/cm<sup>2</sup>) and irradiation time (in seconds) in the medical record for each single administration.

### ***Technical details of PDT in chronic ulcers***

There is not, at the time of writing of this document, a recommended standardized protocol for the use of PDT in chronic ulcers. There is also no clinical study that has compared the efficacy or safety of different photosensitizers or separate radiation protocols in chronic ulcers. The fundamental aspect to be considered is the choice of photosensitizer, which in turn determines the incubation time of the drug before irradiation, the wavelength that can be used to photoactivate the drug, and the energy density applied. In particular, if one decides to employ the most commonly used photosensitizers in Italy (5-Aminolevulinic Acid, ALA, or its methyl derivative, Methyl Aminolevulinate, MAL), the exposure time of the photosensitizer (in occlusive) using an LED light source in the red spectrum (630/635 nm) is between 3 and 4 hours, which corresponds to the exposure time used in therapeutic protocols for the treatment of actinic keratoses, squamous cell carcinoma in situ and basal cell carcinoma. The suggested steps are as follows: i) exposition and thorough cleansing of the wound (photographic documentation is useful in this step); ii) Application of the topical photosensitizer; iii) bandage in occlusive and held in pose; iv) bandage removal, drug removal, and washing with sterile saline; v) irradiation; vi) standard dressing and bandage as appropriate.

*The publisher is not responsible for the content or functionality of any supporting information supplied by the authors. Any queries should be directed to the corresponding author for the article.*

*All claims expressed in this article are solely those of the authors and do not necessarily represent those of their affiliated organizations, or those of the publisher, the editors and the reviewers. Any product that may be evaluated in this article or claim that may be made by its manufacturer is not guaranteed or endorsed by the publisher.*



**Bibliography**

- Agostinis P, Kristian Berg KA, Cengel TH, et al. Photodynamic Therapy of Cancer: An Update. CA: A Cancer Journal for Clinicians. 2011;61:250-81.
- Anzengruber F, Pinar Avci L, Hamblin MR. T-Cell Mediated Anti-Tumor Immunity after Photodynamic Therapy: Why Does It Not Always Work and How Can We Improve It? Photochemical & Photobiological Sciences: Official Journal of the European Photochemistry Association and the European Society for Photobiology. 2015;14:1492-509.
- Aspiroz C, Sevil M, Toyas C, Gilaberte Y. Photodynamic Therapy With Methylene Blue for Skin Ulcers Infected With Pseudomonas Aeruginosa and Fusarium Spp. Actas Dermo-Sifiliograficas. 2017;108:e45-8.
- Brown S. Clinical Antimicrobial Photodynamic Therapy: Phase II Studies in Chronic Wounds. Journal of the National Comprehensive Cancer Network: JNCCN 2012;10:S80-3.
- Choi JY, Park GT, Na EY, et al. Molecular Changes Following Topical Photodynamic Therapy Using Methyl Aminolaevulinate in Mouse Skin. Journal of Dermatological Science. 2010;58:198-203.
- Clayton TH, Harrison PV. Photodynamic Therapy for Infected Leg Ulcers. The British Journal of Dermatology. 2007;156:384-5.
- Corsi A, Lecci PP, Bacci S, et al. Early Activation of Fibroblasts during PDT Treatment in Leg Ulcers. Giornale Italiano Di Dermatologia E Venereologia: Organo Ufficiale, Societa Italiana Di Dermatologia E Sifilografia. 2016;151:223-9.
- Devirgiliis V, Panasiti V, Fioriti D, et al. Antibacterial Activity of Methyl Aminolevulinate Photodynamic Therapy in the Treatment of a Cutaneous Ulcer. International Journal of Immunopathology and Pharmacology. 2011;24:793-5.
- Domínguez A, Gómez C, García-Kass AI, García-Nuñez JA. IL-1beta, TNF-Alpha, Total Antioxidative Status and Microbiological Findings in Chronic Periodontitis Treated with Fluorescence-Controlled Er:YAG Laser Radiation. Lasers in Surgery and Medicine. 2010;42:24-31.
- Garcia VG, Alcântara de Lima M, Okamoto T, et al. Effect of Photodynamic Therapy on the Healing of Cutaneous Third-Degree-Burn: Histological Study in Rats. Lasers in Medical Science. 2010;25:221-8.
- Giannopoulou C, Cappuyns I, Cancela J, et al. Effect of Photodynamic Therapy, Diode Laser, and Deep Scaling on Cytokine and Acute-Phase Protein Levels in Gingival Crevicular Fluid of Residual Periodontal Pockets. Journal of Periodontology. 2012;83:1018-27.
- Gollnick SO, Brackett CM. Enhancement of Anti-Tumor Immunity by Photodynamic Therapy. Immunologic Research. 2010;46:216-26.

*The publisher is not responsible for the content or functionality of any supporting information supplied by the authors. Any queries should be directed to the corresponding author for the article.*

*All claims expressed in this article are solely those of the authors and do not necessarily represent those of their affiliated organizations, or those of the publisher, the editors and the reviewers. Any product that may be evaluated in this article or claim that may be made by its manufacturer is not guaranteed or endorsed by the publisher.*

- Grandi V, Bacci S, Corsi A, et al. ALA-PDT Exerts Beneficial Effects on Chronic Venous Ulcers by Inducing Changes in Inflammatory Microenvironment, especially through Increased TGF-Beta Release: A Pilot Clinical and Translational Study. *Photodiagnosis and Photodynamic Therapy*. 2018;21:252-6.
- Grandi V, Paroli G, Puliti E, et al. Single ALA-PDT Irradiation Induces Increase in Mast Cells Degranulation and Neuropeptide Acute Response in Chronic Venous Ulcers: A Pilot Study. *Photodiagnosis and Photodynamic Therapy*. 2021;34:102222.
- Henderson BW, Busch TM, Snyder JW. Fluence Rate as a Modulator of PDT Mechanisms. *Lasers in Surgery and Medicine*. 2006;38:489-93.
- Jori G, Fabris C, Soncin M, et al. Photodynamic Therapy in the Treatment of Microbial Infections: Basic Principles and Perspective Applications. *Lasers in Surgery and Medicine*. 2006;38:468-81.
- Kawczyk-Krupka A, Pucelik B, Międzybrodzka A, et al. Photodynamic Therapy as an Alternative to Antibiotic Therapy for the Treatment of Infected Leg Ulcers. *Photodiagnosis and Photodynamic Therapy*. 2018;23:132-43.
- Krupka M, Bożek A, Bartusik-Aebisher D, et al. Photodynamic Therapy for the Treatment of Infected Leg Ulcers-A Pilot Study. *Antibiotics (Basel, Switzerland)*. 2021;10:506.
- Lavery LA, Davis KE, Berriman SJ, et al. WHS Guidelines Update: Diabetic Foot Ulcer Treatment Guidelines. *Wound Repair and Regeneration*. 2016;24:112-26.
- Lei X, Liu B, Huang Z, Wu J. A Clinical Study of Photodynamic Therapy for Chronic Skin Ulcers in Lower Limbs Infected with *Pseudomonas Aeruginosa*. *Archives of Dermatological Research*. 2015;307:49-55.
- Lin M-H, Lee J Y-Y, Pan S-C, Wong T-W. Enhancing Wound Healing in Recalcitrant Leg Ulcers with Aminolevulinic Acid-Mediated Antimicrobial Photodynamic Therapy. *Photodiagnosis and Photodynamic Therapy*. 2021;33:102149.
- Marston W, Tang J, Kirsner RS, Ennis W. Wound Healing Society 2015 Update on Guidelines for Venous Ulcers. *Wound Repair and Regeneration*. 2016;24:136-44.
- Mills SJ, Farrar MD, Ashcroft GS, et al. Topical Photodynamic Therapy Following Excisional Wounding of Human Skin Increases Production of Transforming Growth Factor-B3 and Matrix Metalloproteinases 1 and 9, with Associated Improvement in Dermal Matrix Organization. *The British Journal of Dermatology*. 2014;171:55-62.
- Morley S, Griffiths J, Philips G, et al. Phase IIa Randomized, Placebo-Controlled Study of Antimicrobial Photodynamic Therapy in Bacterially Colonized, Chronic Leg Ulcers and Diabetic Foot Ulcers: A New Approach to Antimicrobial Therapy. *The British Journal of Dermatology*. 2013;168:617-24.
- Morton CA, Szeimies R-M, Basset-Seguín N, et al. European Dermatology Forum Guidelines on Topical Photodynamic Therapy 2019 Part 1: Treatment Delivery and Established Indications - Actinic Keratoses,

*The publisher is not responsible for the content or functionality of any supporting information supplied by the authors. Any queries should be directed to the corresponding author for the article.*

*All claims expressed in this article are solely those of the authors and do not necessarily represent those of their affiliated organizations, or those of the publisher, the editors and the reviewers. Any product that may be evaluated in this article or claim that may be made by its manufacturer is not guaranteed or endorsed by the publisher.*

Bowen's Disease and Basal Cell Carcinomas." Journal of the European Academy of Dermatology and Venereology: JEADV. 2019;33:2225-38.

Morton CA, Szeimies R-M, Basset-Séguin N, et al. European Dermatology Forum Guidelines on Topical Photodynamic Therapy 2019 Part 2: Emerging Indications – Field Cancerization, Photorejuvenation and Inflammatory/Infective Dermatoses. Journal of the European Academy of Dermatology and Venereology. 2020;34:17.

Mroz P, Hamblin MR. The Immunosuppressive Side of PDT." Photochemical & Photobiological Sciences: Official Journal of the European Photochemistry Association and the European Society for Photobiology. 2011;10:751-8.

Peplow PV, Chung T-Y, Baxter GD. Photodynamic Modulation of Wound Healing: A Review of Human and Animal Studies. Photomedicine and Laser Surgery. 2012;30:118-48.

Robson MC, Cooper DM, Aslam R, et al. Guidelines for the Treatment of Venous Ulcers. Wound Repair and Regeneration. 2006;14:649-62.

Sperandio FF, Simões A, Corrêa Aranha AC, et al. Photodynamic Therapy Mediated by Methylene Blue Dye in Wound Healing. Photomedicine and Laser Surgery. 2010;28:581-7.

Steed DL, Attinger C, Colaizzi T, et al. Guidelines for the Treatment of Diabetic Ulcers. Wound Repair and Regeneration. 2006;14:680-92.

Vallejo MCS, Moura NMM, Amparo Ferreira Faustino M, et al. An Insight into the Role of Non-Porphyrinoid Photosensitizers for Skin Wound Healing. International Journal of Molecular Sciences. 2020;22:E234.

Vallejo MCS, Moura NMM, Gomes ATPC, et al. The Role of Porphyrinoid Photosensitizers for Skin Wound Healing. International Journal of Molecular Sciences. 2021;22:4121.

Vasconcelos Catão MH, Weege Nonaka CF, Cavalcanti de Albuquerque RL, et al. Effects of Red Laser, Infrared, Photodynamic Therapy, and Green LED on the Healing Process of Third-Degree Burns: Clinical and Histological Study in Rats. Lasers in Medical Science. 2015;30:421-8.

Yang B, Chen Y, Shi J. Reactive Oxygen Species (ROS)-Based Nanomedicine. Chemical Reviews. 2019;119:4881-5.

Yang T, Tan Y, Zhang W, et al. Effects of ALA-PDT on the Healing of Mouse Skin Wounds Infected with *Pseudomonas Aeruginosa* and Its Related Mechanisms. Frontiers in Cell and Developmental Biology. 2020;8:585132.

Yang Z, Hu X, Zhou L, et al. Photodynamic Therapy Accelerates Skin Wound Healing through Promoting Re-Epithelialization. Burns & Trauma. 2021;9:tkab008.

*The publisher is not responsible for the content or functionality of any supporting information supplied by the authors. Any queries should be directed to the corresponding author for the article.*

*All claims expressed in this article are solely those of the authors and do not necessarily represent those of their affiliated organizations, or those of the publisher, the editors and the reviewers. Any product that may be evaluated in this article or claim that may be made by its manufacturer is not guaranteed or endorsed by the publisher.*

## Photobiomodulation with Blue Light

Alessandro Corsi, Ornella Forma

Chemical and physical characteristics of light, response of living tissue to light stimulation, and data from the literature allow us to consider the potential of monochromatic light.

There is no doubt that not all chromophores respond to every wavelength of light; specifically, we know that Cytochrome C Oxidase responds predominantly to infrared stimulation (*i.e.*, between 610 and 950 nm), Opsins to lengths between 410 and 550 nm (green/blue), Flavins to those between 410 and 500 (blue). The response of the chromophores themselves (and, consequently, of the tissue) is also conditioned by the irradiation time, the distance between the tissue and the light source, and the power of the latter. The same light radiation has a greater penetration capacity the more the wavelength increases (*i.e.*, moving from blue to red).

The definition of Photobiomodulation (which we have already seen) given by the North American Association for Laser Therapy and the World Association for Laser Therapy dates back to 2014: the document produced clarifies how each chromophore has a different absorption spectrum (*i.e.*, a different activation by different wavelengths) and how different photophysical and photochemical effects are produced in living tissues.

Considering the wavelength used and the chemical-physical characteristics mentioned above, those of the light source, the treatment protocol applied, and the type of lesions on which this type of Photobiomodulation is used, also in line with the data in the literature, the ability of blue monochromatic light stimulation (interfering with flavoproteins, redox-reductive enzymes involved in the processes of radical removal of the so-called "oxidative stress", in DNA repair and apoptosis, *i.e.* "programmed" cell death) it seems to be "limited" to the control of the microbial load and to a partial modulation of inflammation, with an effective spectrum of action only on superficial tissues, since blue light is unable to penetrate over 1 mm and does not activate on sensitive chromophore receptors at other wavelengths.

These aspects, however, do not limit its absolute effectiveness, since, by interfering with one of the most important local factors among those able to slow down or block the tissue repair process, the microbial load, the treatment with blue light alone can still lead to the resumption of the process itself, also being able, in part, to modulate the inflammation.

The simultaneous action of lights of different wavelengths proves to be more effective than that of the sum of the singles, due to the so-called "synchronization", a physical phenomenon that affects light radiation. Damien Kuffler (Institute of Neurobiology of the University of Puerto Rico) in his 2015 article clearly emphasizes that "multiple wavelengths applied simultaneously are more effective than any one applied alone".

In line with the above, the result of monochromatic stimulation (blue in this case) lacks, therefore, the simultaneous effects caused by other wavelengths, able to penetrate to greater depths and, therefore, also

*The publisher is not responsible for the content or functionality of any supporting information supplied by the authors. Any queries should be directed to the corresponding author for the article.*

*All claims expressed in this article are solely those of the authors and do not necessarily represent those of their affiliated organizations, or those of the publisher, the editors and the reviewers. Any product that may be evaluated in this article or claim that may be made by its manufacturer is not guaranteed or endorsed by the publisher.*

stimulate the perilesional tissues (however fundamental in ensuring a correct repair process), and to act on other chromophores involved in different phenomena (neoangiogenesis, cell regeneration, remodelling of the newly formed matrix).

On the other hand, some studies and practical applications in senology, report how blue light is capable of an inhibitory effect on fibroblasts and TGF- $\beta$  if administered at a higher energy density (up to 640 J / cm<sup>2</sup>).

The role of Photobiomodulation with blue light, however, remains fundamental in the management of the microbial load and, partially, in the modulation of inflammation (and, consequently, pain); It is essential to choose the type of lesion to be irradiated, considering the target you want to reach with the treatment, evaluating the characteristics of the lesion itself, in relation to the potential of the method applied.

*The publisher is not responsible for the content or functionality of any supporting information supplied by the authors. Any queries should be directed to the corresponding author for the article.*

*All claims expressed in this article are solely those of the authors and do not necessarily represent those of their affiliated organizations, or those of the publisher, the editors and the reviewers. Any product that may be evaluated in this article or claim that may be made by its manufacturer is not guaranteed or endorsed by the publisher.*

**Bibliography**

- Anders J, et al. Low-Level Light/Laser Therapy Versus Photobiomodulation Therapy. *Photomedicine and Laser Surgery*. 2015;33:183-4.
- Magni G, et al. Blue LED light modulates inflammatory infiltrate and improves the healing of superficial wounds. *Photodermatol Photoimmunol Photomed* 2019;00:1-3.
- Cicchi R, et al. Observation of an improved healing process in superficial skin wounds after irradiation with a blue-LED haemostatic device *J. Biophotonics*. 2016;9:645-55.
- Naik E, Dixit VM. Mitochondrial reactive oxygen species drive proinflammatory cytokine production. *The journal of experimental Medicine*. 2011;208:417-20.
- Landén NX, Li D, Ståhle M. Transition from inflammation to proliferation: a critical step during wound healing. *Cellular and Molecular Life Sciences*. 2016;73:3861-85.
- Rossi F, et al. Photobiomodulation of Human Fibroblasts and Keratinocytes with Blue Light: Implications in Wound Healing *Biomedicines* 2021;9:41.
- Adamskaya N, Dungal P, Mittermayr R, et al. Light therapy by blue LED improves wound healing in an excision model in rats. *Injury*. 2011;42:917-21.
- Ebbesen F, Vreman HJ, Hansen TWR. Blue-Green (~480 nm) versus Blue (~460 nm) Light for Newborn Phototherapy-Safety Considerations. *Int J Mol Sci*. 2022;24:461.
- Hourel N, Abrahamse H. Low-intensity laser irradiation stimulates wound healing in diabetic wounded fibroblast cells (WS1). *Diabetes Techno. Ther*. 2010;12:971-8.
- Franck A, Krol P, Kucharzewski M. Does low output laser stimulation enhance the healing of crural ulceration? Some critical remarks. *Med. Eng. Phys*. 2002;24:607-15.
- Davidson JR. Current concepts in wound management and wound healing products. *Vet. Clin. North Am. Smal. Anim. Bact*. 2015;45:537-64.
- Taniguchi D, Dai P, Hojo T, et al. Low-energy laser irradiation promotes synovial fibroblast proliferation by modulating p15 subcellular localization. *Lasers Surg. Med*. 2009;41:232-9.
- Ferraresi C, Beltrame T, Fabrizzi F, et al. Muscular pre- conditioning using light-emitting diode therapy (LEDT) for high-intensity exercise; a randomized double-blind placebo-controlled trial with a single elite runner. *Physiother. Theory Pract*. 2015;31:354-61.
- Schubert V. Effects of phototherapy on pressure ulcer healing in elderly patients after a falling trauma. A prospective, randomized, controlled study. *Photodermatol. Photoimmunol. Photomed*. 2001;17:32-8.
- Myakishev-Rempel M, Stadler I, Brondon P, et al. A preliminary study of the safety of red-light phototherapy of tissues harbouring cancer. *Photomed. Laser Surg*. 2012;30:551-8.

*The publisher is not responsible for the content or functionality of any supporting information supplied by the authors. Any queries should be directed to the corresponding author for the article.*

*All claims expressed in this article are solely those of the authors and do not necessarily represent those of their affiliated organizations, or those of the publisher, the editors and the reviewers. Any product that may be evaluated in this article or claim that may be made by its manufacturer is not guaranteed or endorsed by the publisher.*

De Sousa AP, Paraguassu GM, Silveira NT, et al. Laser and LED phototherapies on angiogenesis. *Lasers Med. Sci.* 2013;28:981-7.

Adamskaya N, Dungal P, Mittermayr R, et al. Light therapy by blue LED improves wound healing in an excision model in rats. *Injury.* 2011;42:917-21.

Gupta A, Dai T, Hamblin MR. Effect of red and near- infrared wavelengths on low-level laser (light) therapy- induced healing of partial-thickness dermal abrasion in mice. *Lasers Med. Sci.* 2014;29:257-65.

Kim WS, Calderhead RG. Is light-emitting diode phototherapy (LED-LLLT) really effective? *Laser Therapy.* 2011;20:205-15.

Vilela DD, Chamusca FV, Andrade JC, et al. Influence of the HPA axis on the inflammatory response in cutaneous wounds with the use of 670-nm laser photobiomodulation. *J Photochem. Photobiol.* 2012;116, 114-20.

Meirelles GC, Santos JN, Chagas PO, et al. A comparative study of the effects of laser photobiomodulation on the healing of third-degree burns: a histological study in rats. *Photomed. Laser Surg.* 2008;26:159-66.

Krynicka I, Rutowski R, Staniszewska-Kus J, et al. The role of laser biostimulation in early post- surgery rehabilitation and its effect on wound healing. *Ortop. Traumatol. Rehabil.* 2010;12:67-79.

Minatel DG, Enwemeka CS, Franca SC, Frade MA. Phototherapy (LEDs 660/890nm) in the treatment of leg ulcers in diabetic patients: case study. *An. Bras. Dermatol.* 2009;84:279-83.

Minatel DG, Frade MA, Franca SC, Enwemeka CS. Phototherapy promotes healing of chronic diabetic leg ulcers that failed to respond to other therapies. *Lasers Surg. Med.* 2009;41:433-41.

Lee SY, Seong IW, Kim JS, et al. Enhancement of cutaneous immune response to bacterial infection after low-level light therapy with 1072 nm infrared light: a preliminary study. *Photochem. Photobiol.* 2011;105:175-82.

Kuffler DP. Photobiomodulation in promoting wound healing: a review. *Regen. Med.* 2015;11:107-22.

Lan CC, Ho PY, Wu CS, et al. LED 590 lymphomodulation reduces UVA-induced metalloproteinase-1 expression via upregulation of antioxidant enzyme catalase. *Dermatol. Sci.* 2015;78:125-32.

Medrado AP, Soares AP, Santos ET, et al. Influence of laser photobiomodulation upon connective tissue remodelling during wound healing. *J Photochem. Photobiol.* 2008;92:144-52.

De Sousa AP, Santos JN, Dos Reis JA Jr., et al. Effect of LED phototherapy of three distinct wavelengths on fibroblasts on wound healing; a histological study in a rodent model. *Photomed. Laser Surg.* 2010;28:547-52.

Chandrasekaran B, Chettri R, Agrawal N, Sathyamoorthy C. Short-term multimodal phototherapy approach in a diabetic ulcer patient. *Singapore Med.* 2012;53:e122-4.

*The publisher is not responsible for the content or functionality of any supporting information supplied by the authors. Any queries should be directed to the corresponding author for the article.*

*All claims expressed in this article are solely those of the authors and do not necessarily represent those of their affiliated organizations, or those of the publisher, the editors and the reviewers. Any product that may be evaluated in this article or claim that may be made by its manufacturer is not guaranteed or endorsed by the publisher.*

Khoo NK, Shokrgozar MA, Kashani IR, et al. In vitro therapeutic effects of low-level laser at mrna level on the release of skin growth factors from fibroblasts in diabetic mice. *Avicenna. Med. Biotechnol.* 2014;6:113-8.

Min PK, Goo BL. 830 nm light-emitting diode low level light therapy (LED-LLLT) enhances wound healing: a preliminary study. *Laser Therapy.* 2013;22:43-9.

Lipovsky A, Nitzan Y, Lubart R. A possible mechanism for visible light-induced wound healing. *Lasers Surg. Med.* 2008;40:509-14.

Peplow PV, Chung TY, Baxter GD. Laser photobiomodulation of proliferation of cells in culture: a review of human and animal studies. *Photomed. Laser Surg.* 2010;28:S3-40.

Hourelid NN. Shedding light on a new treatment for diabetic wound healing: a review on phototherapy. *Scientific World Journal.* 2014;398412.

Jori G, Fabris C, Soncin M, et al. Photodynamic therapy in the treatment of microbial infections: basic principles and perspective applications. *Laser Surg Med.* 2006;38:468-81.

*The publisher is not responsible for the content or functionality of any supporting information supplied by the authors. Any queries should be directed to the corresponding author for the article.*

*All claims expressed in this article are solely those of the authors and do not necessarily represent those of their affiliated organizations, or those of the publisher, the editors and the reviewers. Any product that may be evaluated in this article or claim that may be made by its manufacturer is not guaranteed or endorsed by the publisher.*



## Fluorescence Photobiomodulation and tissue healing

Franco Bassetto, Carlotta Scarpa

Since ancient times, light has always been the subject of considerable interest for its possible applications in the medical field, especially dermatological including the treatment of skin cancers.

In the last 20 years, a specific type of treatment, called Photobiomodulation (PBM) has aroused considerable interest especially in the field of tissue healing. This treatment involves the use of non-ionizing light sources, including low-level lasers, Light-Emitting Diodes (LEDs) and broadband lights, in the visible and infrared spectrum, in order to stimulate biological functions through a non-thermal and, above all, non-cytotoxic process, based on the activation of endogenous chromophores.

Otherwise known as "non-visual photoreceptors", these chromophores occur naturally in many cells, including the skin, and in the extracellular matrix; specifically, it has been shown that Photobiomodulation works on specific endogenous chromophores: Cytochrome C oxidase, present in the inner membrane of mitochondria, and particularly sensitive to infrared (wavelength between 610 and 950 nm); Opsins, transmembrane proteins that are able to act on calcium channels by modulating their intracellular levels and that seem to be particularly sensitive to green and blue light (wavelength between 410 and 550 nm); Flavins, proteins involved in DNA repair processes and which seem to be more responsive to blue light (wavelength between 410 and 500 nm).

However, the direct application of only light of any colour causes a "limited" response in the target tissue. The various wavelengths, and consequently the different colours of light, are characterized by different penetration capacities and therefore by different biological actions:

Monochromatic blue light, if applied "alone", and directly, having a penetration capacity of about 1 mm, is able to penetrate the tissue only superficially, then act on surface bacteria modulating inflammation;

The green monochromatic light, penetrating the tissue in a range between 0.5 and 2 mm, stimulates the fibroblastic cells by regulating the final phases of tissue healing processes;

Yellow monochromatic light, penetrating the tissue in a range of 1 to 2 mm, acts on erythema, reduces edema, and stimulates blood circulation;

The red monochromatic light, having a penetration capacity between 1 and 6 mm, increases capillary flow, reduces inflammation, and increases collagen production.

In order to be able to use the whole spectrum of possible wavelengths and visible lights, and consequently to stimulate all the different biological responses (from the modulation of inflammation to the stimulation of neo-angiogenesis, from the production of extracellular matrix to the modulation of the scarring process), over the years research has developed to develop a specific Photobiomodulation, or the so-called Fluorescence Biomodulation.

*The publisher is not responsible for the content or functionality of any supporting information supplied by the authors. Any queries should be directed to the corresponding author for the article.*

*All claims expressed in this article are solely those of the authors and do not necessarily represent those of their affiliated organizations, or those of the publisher, the editors and the reviewers. Any product that may be evaluated in this article or claim that may be made by its manufacturer is not guaranteed or endorsed by the publisher.*

This treatment, currently also known as Fluorescent Light Energy (FLE), is based on the combined use of a multi-LED lamp that emits a blue monochromatic light (able to stimulate endogenous chromophores as we have just seen), and a vector topical gel, positioned in a thin layer (about 2 mm) on the bottom of the lesion, containing urea peroxide, water and substances called fluorophores., *i.e.* exogenous chromophores capable of absorbing light, transforming it and re-emitting it at different wavelengths, characterized by lower energy and different colour.

Specifically, once the blue monochromatic light illuminates the gel at a distance between 3 and 5 cm, the fluorophore chromophore contained in it acts as a photoconverter absorbing part of the light itself; this process leads to the excitation of the electrons contained within the fluorophore and at the moment of their "return to rest", through a mechanism known as "Stokes shift", the light is fluoresced again at different wavelengths between 510 and 700 nm; however, this reemission does not occur continuously, but, thanks to the Stokes phenomenon, the phase of excitation and emission is repeated thousands of times per second for the entire duration of activation of the gel, with consequent release of the different wavelengths in a dynamic and hyper-pulsed way.

This fluorescence phenomenon, verifiable thanks to the aid of glasses that allow you to follow the colour variations of the exogenous fluorophore gel, which changes from bright orange to white (exhausted gel) during its activation, runs out in a period of time between 5 minutes. During this interval, the wavelengths obtained from fluorescence (green, yellow and orange) act on the different tissue layers, leaving space, at the end of the activation of the exogenous fluorophore, to tissue actions due to the consensual stimulation of endogenous chromophores and which continue for 36-48 hours after the end of the treatment.

It is also important to underline how the tissue action obtained through the fluorescence biomodulation method is greater than the sum of the actions obtainable by direct administration of monochromatic lights only.

In recent years, there have been many studies aimed at better understanding the functioning of this method and the biological responses derived from it, and although much progress has yet to be done, it is clear that FLE acts fundamentally on: mitochondria, macrophages, neo-angiogenesis, inflammatory processes and related cytokines, stimulation of fibroblasts and wound healing, and bacteria.

### ***FLE and mitochondria***

Intracellular organelles responsible for cellular respiration, mitochondria are characterized by the presence of mitochondrial crests, that is, inflexions of the mitochondrial inner membrane that represent the seat of the oxidative phosphorylation process, fundamental to produce ATP (Adenosine Triphosphate), and therefore of energy, but also for the formation of Reactive Oxygen Species (ROS).

Recent *in vitro* studies have shown that the conversion of blue LED light, by chromophores, into a low-energy fluorescence emission, promotes the entry of photons into Cytochrome C oxidase, soluble electron transporter protein between Complex III and IV of the respiratory chain, resulting in greater activity of this enzyme and increased production of ATP, NO (Nitric Oxide) and ROS.

*The publisher is not responsible for the content or functionality of any supporting information supplied by the authors. Any queries should be directed to the corresponding author for the article.*

*All claims expressed in this article are solely those of the authors and do not necessarily represent those of their affiliated organizations, or those of the publisher, the editors and the reviewers. Any product that may be evaluated in this article or claim that may be made by its manufacturer is not guaranteed or endorsed by the publisher.*

A relationship between FLE and the upregulation of two genes named UCP1 and CPT1B respectively has been observed. Otherwise known as thermogenin, UCP1 is a mitochondrial uncoupling protein, active on cellular energy metabolism; its action is to disperse part of the electrochemical gradient given by oxidative phosphorylation while maintaining the production of ATP, but decreasing the ROS; UCP1 also seems to improve mitochondrial biogenesis thanks to the overexpression of the COX4I2 gene, a gene encoding a specific subunit of cytochrome C oxidase. CPT1B is a gene coding for Carnitine-palmitoyltransferase 1, a protein present in the inner part of the mitochondrial outer membrane and which has the task of promoting, at the mitochondrial level, the formation of ATP through the  $\beta$ -oxidation of long-chain fatty acids.

Finally, at the cellular level, the NF- $\kappa$ B signalling pathway is very important; also known as "nuclear factor kappa-light-chain-enhancer of activated B cells", this transcription factor is present in every cell and is activated by Cytochrome C oxidase through the stimulus given by the increased production of ROS; once activated NF- $\kappa$ B it can then enter the nucleus where it is involved in the expression of more than 150 genes with the promotion of cell proliferation.

### ***FLE and macrophages***

As known, macrophages play a fundamental role in inflammation; depending on the surrounding microenvironment, they can take on pro-inflammatory characteristics, for which we recognize them with the term M1, or anti-inflammatory and pro-reparatory, for which we recognize them with the term M2. Recent studies have reported how FLE can polarize cutaneous macrophage cells towards an M2 phenotype, therefore anti-inflammatory and pro-reparative, with consequent action both on proinflammatory cytokines and on reparative processes starting from neo-angiogenesis.

### ***FLE and neo-angiogenesis***

Strongly correlated with previous observations, recent studies have shown that the application of FLE can stimulate the production of VEGF (Vascular Endothelial Growth Factor), resulting in neovascularization of the treated area. In fact, a recent study (Edge D *et al.*) is very interesting, which reports how FLE can stimulate the formation not only of the main vessels, but also of the branch points, thus allowing not only the stimulation of tissue healing, but also reducing the possible perilesional erythema, providing a greater number of "distribution points" of blood flow.

### ***FLE and related inflammatory processes/cytokines***

As previously highlighted, FLE can modulate inflammatory processes by acting on the polarization of macrophages, but its activity can also affect the expression of proinflammatory cytokines. In fact, it has

*The publisher is not responsible for the content or functionality of any supporting information supplied by the authors. Any queries should be directed to the corresponding author for the article.*

*All claims expressed in this article are solely those of the authors and do not necessarily represent those of their affiliated organizations, or those of the publisher, the editors and the reviewers. Any product that may be evaluated in this article or claim that may be made by its manufacturer is not guaranteed or endorsed by the publisher.*

been shown that FLE: i) significantly reduces TNF alpha released by both fibroblasts and keratinocytes; ii) significantly reduces IL6 released by both fibroblasts and keratinocytes.

These last aspects appear to be of considerable interest: IL6, in fact, associated with TGF $\beta$  promotes the transformation of fibroblasts into myofibroblasts, cells characterized by the presence of alpha actin smooth muscle and therefore endowed with contractile capacity and involved in the tissue healing process; both TNF alfa and IL6 are also known to be overexpressed in keloid scars. It is therefore possible to hypothesize that the reduction caused by FLE of both cytokines can modulate the inflammatory response and consequently the scar formation, reducing the possibility of onset of pathological scars and / or characterized by retraction.

### ***FLE, fibroblast stimulation and wound healing***

As previously discussed, the production of different wavelengths and consequently of different colours, acts on different tissue targets. Specifically, fluorescence by consensually producing wavelengths included in green, yellow and orange is able to stimulate the proliferation of fibroblastic cells with consequent production and deposit of collagenous extracellular matrix. Recent studies (Din 2021) have shown in vivo how the application of FLE was able not only to stimulate fibroblastic proliferation, but also the correct orientation of collagen fibres during tissue healing. It is interesting to note how FLE can negatively modulate the expression of CTGF or the Connective Tissue Growth Factor, connective tissue growth factor particularly involved in fibrotic and scarring processes, consequently leading to tissue formation more similar to normal non-fibrotic tissue.

It is also interesting to note how FLE is able to stimulate keratinocyte proliferation from the edge of the lesion but not only, also notes the appearance of re-epithelialization tokens on the bottom of the lesion. Furthermore, evidence of the downregulation of scar fibrotic tissue and the formation of a tissue with characteristics very similar to healthy skin is the observation of melanocyte proliferation in patients characterized by phototypes V and VI, thus suggesting the ability of FLE to stimulate the formation of skin pigment with consequent response of the prosthetic tissues towards a sort of *restitutio ad integrum*.

### ***FLE and bacteria***

It is known that the interaction of direct monochromatic blue light and ambient oxygen can have an antibacterial action. Although the mechanisms are not yet fully understood, it has been hypothesized that this effect is attributable to a photochemical action; Blue light would, in fact, be active on different microorganisms modulating their motility, suppressing the formation of the biofilm or glycoprotein superstructure increasingly found on the surface of chronic ulcerative lesions and which acts as a "protective" barrier for the underlying bacterial population preventing the penetration of antibiotic drugs and the action of the so-called advanced dressings. An example of antibacterial activity has been reported against bacteria such as *Staphylococcus Aureus*, *Pseudomonas Aeruginosa*, and again *Cutibacterium acnes* and *Helicobacter pylori*. In these cases, the antibacterial effect would be conveyed by the

*The publisher is not responsible for the content or functionality of any supporting information supplied by the authors. Any queries should be directed to the corresponding author for the article.*

*All claims expressed in this article are solely those of the authors and do not necessarily represent those of their affiliated organizations, or those of the publisher, the editors and the reviewers. Any product that may be evaluated in this article or claim that may be made by its manufacturer is not guaranteed or endorsed by the publisher.*

photocytotoxicity of endogenous chromophores, such as proto-porphyrins, with a subsequent decrease in the production of cytotoxic ROS.

It is interesting to note that the application of the exogenous chromophore gel can act as an indicator of critical bacterial colonization at the lesional level. It is known that the skin is home to commensal bacteria and how skin lesions are consequently inhabited by microorganisms whose concentration can represent a common colonization or, with the increase of the bacterial concentration itself, a colonization defined as critical, up to a possible infection. It is interesting to note that the presence of a critical bacterial colonization or infected material at the bottom of the lesion, once in contact with the gel carrier, causes a chemical reaction, probably conveyed by the urea peroxide contained in the gel itself, which leads to the formation of foam visible to the naked eye with consequent change in density and transparency of the gel. This phenomenon allows the operator to modulate the management of the lesion once the FLE treatment is finished, applying, for example, advanced hydrophobic dressings capable of trapping the bacteria themselves.

### ***The mode of application***

Once a correct cleansing and disinfection has been carried out, the bottom of the lesion is debridement (using, for example, ultrasonic hydro-debridement or debridement, or more simply by mechanical debridement with the aid of polyester fibers) and the activation of the margins according to the principles of the so-called "wound hygiene". At this point, after rinsing with saline, the carrier gel containing the exogenous fluorophores, bright orange, is applied to the bottom of the lesion and to the perilesional skin in a layer of about 2 mm; a blue multi-LED lamp is then positioned, and switched on at a variable distance between 3 and 5 cm from the lesion. At this point, the fluorescence process, as mentioned above, is followed with the help of orange glasses that are worn by the operator and also delivered to the patient and that allow to follow, step by step, the chromatic variation of the gel and therefore the production of polychromatic light. This process lasts 5 minutes, at the end of which the gel appears white, or "exhausted", as it is depleted by exogenous fluorophores. At this point, it is possible to remove it using sterile gauze and saline and the application of any advanced dressing you decide to use rationally. As previously described, the effect on endogenous chromophores does not end during the application of FLE, but continues for the following 36-48 hours, with the need to repeat the treatment twice a week. However, it is possible, once the exhausted gel has been eliminated, to immediately perform the second session by applying a new gel and a new irradiation. This possibility allows better management of patients, for example very elderly, who cannot go to the clinic several times during the same week.

There are no known cross-reactions that prevent the use of this method with secondary dressings containing, for example, silver, or TLC or other types of advanced dressings; however, it should be verified that the patient does not report allergies to possible excipients or reports the intake of photosensitizing drugs; In this case it is not recommended any method that requires the use of lights.

*The publisher is not responsible for the content or functionality of any supporting information supplied by the authors. Any queries should be directed to the corresponding author for the article.*

*All claims expressed in this article are solely those of the authors and do not necessarily represent those of their affiliated organizations, or those of the publisher, the editors and the reviewers. Any product that may be evaluated in this article or claim that may be made by its manufacturer is not guaranteed or endorsed by the publisher.*

Current contraindications are also pregnant patients and paediatric patients: however, this last contraindication is to be considered related only to the scarcity of children so far treated, in an off-label regime, with this method.

### ***Clinical experience and possible applications***

Explanatory treatment both outpatient and, where available, at home, has been and is the subject of in vitro and in vivo studies both on animal models and on patients. The EUREKA study (The evaluation of real-life use of a bio-photonic system in chronic wound management) conducted in 2015 in Italy is well known. This multicentre study saw the enrolment of 100 patients suffering from venous ulcers, diabetics and pressure and the evaluation of the method in terms of efficacy (reduction of the lesion area during treatment and the follow-up period), safety (appearance of adverse effects related to the use of the method), and quality of life. In fact, the impact of the method on variations, related to its effectiveness, in the quality of life of the patient suffering from chronic lesions was evaluated.

From the study previously described, it emerged that the method is effective, leading to a reduction of the area with consequent improvement of the Wound Bed Preparation for a definitive surgery, and until, in some cases, to complete re-epithelialization, stable even in the follow-up period, in all three types of chronic ulcers considered.

At the same time, and to follow, many were the suggested applications; if the efficacy on chronic lesions of vascular and decubitus origin was known, the mechanisms of action of FLE have led and suggested its application also in acute diseases, such as, for example, superficial and deep second-degree burns, hidradenitis suppurativa, acne, both in the active phase and for scar modulation, acute toxin lesions, for example, of violin spider and finally the modulation of keloid hypertrophic scarring.

### ***FLE, burns and keloid hypertrophic scarring***

An international multicentre study evaluated the application of FLE in patients suffering from superficial and deep II-degree burns of different body regions. This study has shown that not only FLE leads to rapid and complete re-epithelialization of patients suffering from superficial second-degree burns, but it also and above all, has an action on deep second-degree burns, characterized by the presence of fibro-necrotic tissue, which would require at least one dermabrasion surgery in order to eliminate necrotic tissue and restart the tissue healing process in times of at least 4 weeks.

In these patients, the application of FLE allowed restitutio ad integrum without the aid of dermabrasion and advanced dressings (the application of polyethylene nets covered with nanocrystalline silver) in a time ranging from 10 to 15 days. It is also important to underline how tissue healing has not led to the formation of pathological scar tissue with a hypertrophic keloid tendency which, sometimes, unfortunately, is the evolution of deep II-degree burns.

*The publisher is not responsible for the content or functionality of any supporting information supplied by the authors. Any queries should be directed to the corresponding author for the article.*

*All claims expressed in this article are solely those of the authors and do not necessarily represent those of their affiliated organizations, or those of the publisher, the editors and the reviewers. Any product that may be evaluated in this article or claim that may be made by its manufacturer is not guaranteed or endorsed by the publisher.*

This phenomenon is due to the reduction of proinflammatory and profibrotic cytokines, such as IL6 which, as seen above, have the task of transforming fibroblasts into myofibroblasts, cells characterized by contractile activity that leads to the deposit, at each contraction, of collagen extracellular matrix and which are responsible for the scar remodeling phase, with consequent prevention, in predisposed patients, or improvement of scar quality itself. The application of FLE on hypertrophied/keloid scars has, in fact, the ability to reduce erythema, scar thickness, and pruritic symptoms reported by patients.

### ***FLE, hidradenitis suppurativa and acne***

Thanks to the anti-inflammatory effect given by the reduction of pro-inflammatory cytokines, anti-edema, and anti-erythema, given by the formation of new vessels that can act as "escape" points of blood circulation, and thanks to the antibacterial effect mentioned above, FLE is increasingly finding application in acne in the acute phase and in hidradenitis suppurativa in order to turn off both the inflammatory response and bacterial colonization and favor not only the production of extracellular matrix and proliferation of fibroblasts and keratinocytes, but also the modulation of profibrotic cytokines such as IL6, with consequent cicatricial improvement.

Recent studies have also shown the possibility of associating FLE with systemic treatments with isotretinoin or tetracyclines in order to reduce the bacterial load, without noteworthy side effects.

### ***Other possible applications***

Other possible applications can be identified, for example, to stimulate tissue healing in lesions attributable to toxins, such as that of the violin spider, or to diseases such as pyoderma gangrenosum. In these cases, FLE can be used to reduce inflammation, bacterial and toxic load in combination with other treatments such as antibiotic therapy or, for example, hyperbaric therapy

### **Conclusions**

Fast treatment and easy technical execution by nursing staff, in recent years, the fluorescence Photobiomodulation better known as FLE, has found increasing application in diseases of various aetiology, thanks also to the high profile of efficacy and safety repeatedly demonstrated both *in vitro* and *in vivo*. Unlike the application of monochromatic lights only, the possibility of combining the action of light with the stimulation of exogenous and endogenous chromophores, exploiting the physical phenomenon of fluorescence, has allowed to consider FLE as a suitable treatment for every phase of tissue healing, leading to its inclusion also in positioning documents of important scientific societies for the management of skin lesions.

*The publisher is not responsible for the content or functionality of any supporting information supplied by the authors. Any queries should be directed to the corresponding author for the article.*

*All claims expressed in this article are solely those of the authors and do not necessarily represent those of their affiliated organizations, or those of the publisher, the editors and the reviewers. Any product that may be evaluated in this article or claim that may be made by its manufacturer is not guaranteed or endorsed by the publisher.*

## Bibliography

- Poonam G, et al. Ancient light therapies: a boon to medical sciences. *Science and Culture*. 2016;82:231-6.
- Lazarus GS, Cooper DM, Knighton DR, et al. Definitions and guidelines for assessment of wounds and evaluation of healing. *Arch Dermatol*. 1994;130:489-93.
- Romanelli M, Piaggese A, Scapagnini G, et al. EUREKA study – the evaluation of real-life use of a biophotonic system in chronic wound management: An interim analysis. *Drug Des Devel Ther*. 2017;11:3551-8.
- Kirsner RS, Vivas AC. Lower-extremity ulcers: Diagnosis and management. *Br J Dermatol*. 2015; 173:379-90
- Piaggese A, Läubli S, Bassetto F, et al. . Advanced therapies in wound management: Cell and tissue-based therapies, physical and bio-physical therapies smart and IT based technologies. *J Wound Care*. 2018;27:S1–S137.
- Sen CK, Gordillo GM, Roy S, et al. Human skin wounds: A major and snowballing threat to public health and the economy. *Wound Repair Regen*. 2009;17:763–71.
- Romanelli M, Piaggese A, Scapagnini G, et al. Evaluation of fluorescence biomodulation in the real-life management of chronic wounds: the EUREKA trial. *J Wound Care*. 2018;27:744-53.
- Hourel NN. Shedding light on a new treatment for diabetic wound healing: a review on phototherapy. *Scientific World Journal*. 2014;2014:398412.
- Tian YS, Kim NH, Lee AY. Antiphotaging effects of light-emitting diode irradiation on narrow-band ultraviolet B-exposed cultured human skin cells. *Dermatologic Surg*. 2012;38:1695-703.
- de Carvalho FB, Andrade AS, Rasquin LC, et al. Effect of laser ( $\lambda$  660 nm) and LED ( $\lambda$  630 nm) photobiomodulation on formocresol-induced oral ulcers: A clinical and histological study on rodents. *Lasers Med Sci*. 2015;30:389-96.
- Karu T. Is it time to consider photobiomodulation as a drug equivalent? *Photomed Laser Surg*. 2013;31:189-91.
- Frangez I, Cankar K, Ban Frangez H, et al. The effect of LED on blood microcirculation during chronic wound healing in diabetic and non-diabetic patients—a prospective, double-blind randomized study. *Lasers Med Sci*. 2017;32:887-94.
- de Freitas LF, Hamblin MR. Proposed mechanisms of photobiomodulation or low-level light therapy. *IEEE J Sel Top Quantum Electron*. 2016;22:7000417.
- Barolet D. Light-emitting diodes (LEDs) in dermatology. *Semin Cutan Med Surg*. 2008;27:227-38.

*The publisher is not responsible for the content or functionality of any supporting information supplied by the authors. Any queries should be directed to the corresponding author for the article.*

*All claims expressed in this article are solely those of the authors and do not necessarily represent those of their affiliated organizations, or those of the publisher, the editors and the reviewers. Any product that may be evaluated in this article or claim that may be made by its manufacturer is not guaranteed or endorsed by the publisher.*



- Fushimi T, Inui S, Nakajima T, et al. Greenlight emitting diodes accelerate wound healing: Characterization of the effect and its molecular basis in vitro and in vivo. *Wound Repair Regen.* 2012; 20:226-35.
- Whelan HT, Smits RL, Jr, Buchman EV, et al. Effect of NASA light-emitting diode irradiation on wound healing. *J Clin Laser Med Surg.* 2001;19:305-14.
- Powers JG, Higham C, Broussard K, et al. Wound healing and treating wounds: Chronic wound care and management. *J Am Acad Dermatol.* 2016;74:607-25.
- Bowers S, Franco E. Chronic wounds: Evaluation and management. *Am Fam Physician.* 2020;101:159-66.
- Nikolis A, Grimard D, Pesant Y, et al. A prospective case series evaluating the safety and efficacy of the Klox BioPhotonic system in venous leg ulcers. *Chronic Wound Care Manag Res.* 2016;3:101-11.
- Oliveira MC, Jr, Greiffo FR, Rigonato-Oliveira NC, et al. Low-level laser therapy reduces acute lung inflammation in a model of pulmonary and extrapulmonary LPS-induced ARDS. *J Photochem Photobiol B.* 2014;134:57-63.
- Chen AC, Arany PR, Huang YY, et al. Low-level laser therapy activates NF-kB via generation of reactive oxygen species in mouse embryonic fibroblasts. *PLoS One.* 2011;6:e22453.
- Ferroni L, Zago M, Patergnani S, et al. Fluorescent Light Energy (FLE) Acts on Mitochondrial Physiology Improving Wound Healing. *J Clin Med.* 2020;9:559.
- De Lucca AJ, Carter-Wientjes C, Williams KA, et al. Blue light (470 nm) effectively inhibits bacterial and fungal growth. *Lett Appl Microbiol.* 2012;55:460-6.
- Yu S, Lan CE, Yu HS. Mechanisms of repigmentation induced by photobiomodulation therapy in vitiligo. *Exp Dermatol.* 2019;28:10-4.
- Hamblin MR. Mechanisms and applications of the anti-inflammatory effects of photobiomodulation. *AIMS Biophys.* 2017;4:337-61.
- Edge D, Møllergaard M, Dam-Hansen C, et al. FLUORESCENT LIGHT ENERGY: The Future for Treating Inflammatory Skin Conditions? *J Clin Aesthet Dermatol.* 2019;12:E61-8.
- Scapagnini G, Marchegiani A, Rossi G, et al. Management of all three phases of wound healing through the induction of fluorescence biomodulation using fluorescence light energy. *Proc. SPIE 10863, Photonic Diagnosis and Treatment of Infections and Inflammatory Diseases II, 108630W (7 March 2019).* SPIE; 2019. Available from: <https://spie.org/Publications/Proceedings/Paper/10.1117/12.2508066>.
- Zago M, Dehghani M, Jaworska J, et al. Fluorescent light energy in wound healing: when is a photon something more? *Proceedings Volume 11221, Mechanisms of Photobiomodulation Therapy XV; 112210A (2020).* San Francisco, California, United States: SPIE BiOS; 2020.

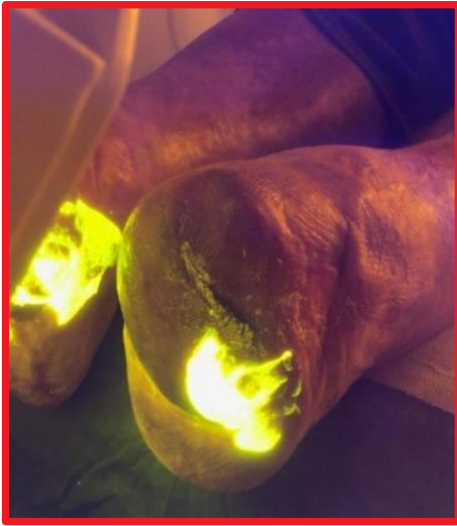*The publisher is not responsible for the content or functionality of any supporting information supplied by the authors. Any queries should be directed to the corresponding author for the article.*

*All claims expressed in this article are solely those of the authors and do not necessarily represent those of their affiliated organizations, or those of the publisher, the editors and the reviewers. Any product that may be evaluated in this article or claim that may be made by its manufacturer is not guaranteed or endorsed by the publisher.*

- Nikolis A, Fauverghe S, Scapagnini G, et al. An extension of a multicentre, randomized, split-face clinical trial evaluating the efficacy and safety of chromophore gel-assisted blue light phototherapy for the treatment of acne. *Int J Dermatol.* 2018;57:94-103.
- Braun SA, Gerber PA. A photoconverter gel-assisted blue light therapy for the treatment of rosacea. *Int J Dermatol.* 2017;56:1489-90.
- Koceva I, Rümmelein B, Gerber PA, et al. Fluorescent light energy: a new therapeutic approach to effectively treating acne conglobata and hidradenitis suppurativa. *Clin Case Rep.* 2019;7:1769-72.
- Nikolis AFS, Vezina D, Scapagnini G. Evaluation of biophotonic therapy in a non-healing diabetic foot ulcer: a case report. *Diabetic Foot Can.* 2016;2016:25-30.
- Dini V, Janowska A, Davini G, et al. Biomodulation induced by fluorescent light energy versus standard of care in venous leg ulcers: a retrospective study. *J Wound Care* 2019;28:730-6.
- Kuffler DP. Photobiomodulation in promoting wound healing: a review. *Regen Med* 2016;11:107-22.
- Dungel P, Hartinger J, Chaudary S et al. Low-level light therapy by LED of different wavelength induces angiogenesis and improves ischemic wound healing. *Lasers Surg Med* 2014;46:773-80.
- Crema A, Scarpa C, Sonda R, et al. Fluorescent Light Energy and Chronic Lesions: A Winning Association. *Plast Reconstr Surg Glob Open.* 2021;9:e3667.
- Russo A, Mellergaard M, Pellacani G, et al. Fluorescent light energy combined with systemic isotretinoin: A 52-week follow-up evaluating efficacy and safety in treatment of moderate-severe acne. *Clin Case Rep.* 2021;9:2057-68.
- Mellergaard M, Fauverghe S, Scarpa C, et al. Evaluation of Fluorescent Light Energy for the Treatment of Acute Second-degree Burns. *Mil Med.* 2021;186:416-23.

*The publisher is not responsible for the content or functionality of any supporting information supplied by the authors. Any queries should be directed to the corresponding author for the article.*

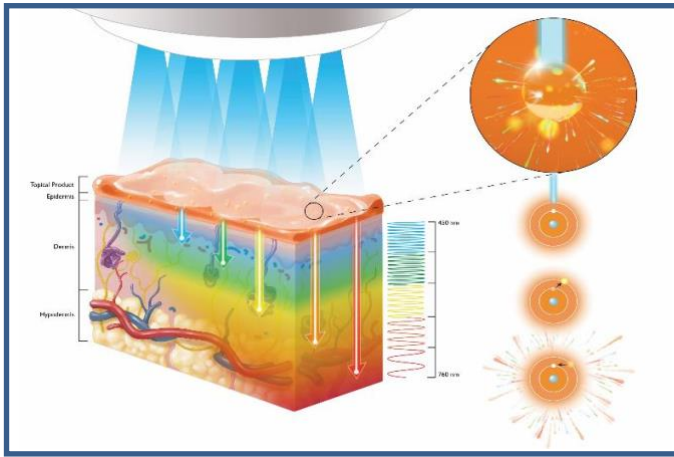
*All claims expressed in this article are solely those of the authors and do not necessarily represent those of their affiliated organizations, or those of the publisher, the editors and the reviewers. Any product that may be evaluated in this article or claim that may be made by its manufacturer is not guaranteed or endorsed by the publisher.*



**Figure 1.** Fluorescence during application.

*The publisher is not responsible for the content or functionality of any supporting information supplied by the authors. Any queries should be directed to the corresponding author for the article.*

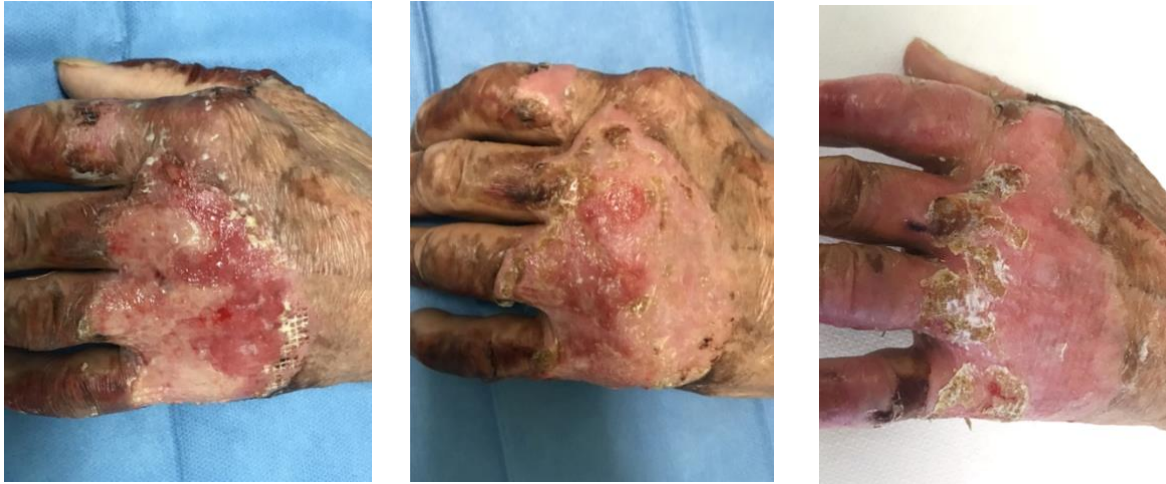*All claims expressed in this article are solely those of the authors and do not necessarily represent those of their affiliated organizations, or those of the publisher, the editors and the reviewers. Any product that may be evaluated in this article or claim that may be made by its manufacturer is not guaranteed or endorsed by the publisher.*



**Figure 2.** FLE in tissues.

*The publisher is not responsible for the content or functionality of any supporting information supplied by the authors. Any queries should be directed to the corresponding author for the article.*

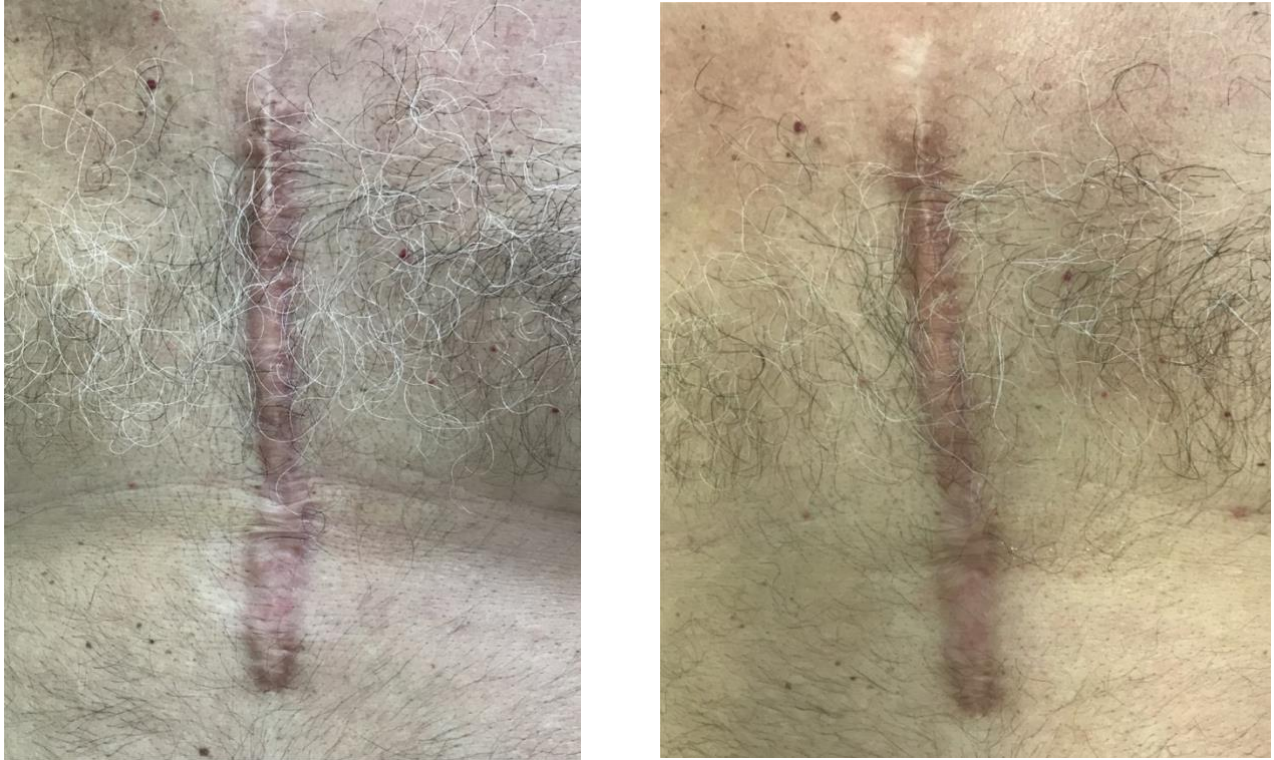*All claims expressed in this article are solely those of the authors and do not necessarily represent those of their affiliated organizations, or those of the publisher, the editors and the reviewers. Any product that may be evaluated in this article or claim that may be made by its manufacturer is not guaranteed or endorsed by the publisher.*



**Figure 3.** Superficial and deep second-degree burn in 80-year-old diabetic: the back of the hand pre and post at 15 days. See complete re-epithelialization.

*The publisher is not responsible for the content or functionality of any supporting information supplied by the authors. Any queries should be directed to the corresponding author for the article.*

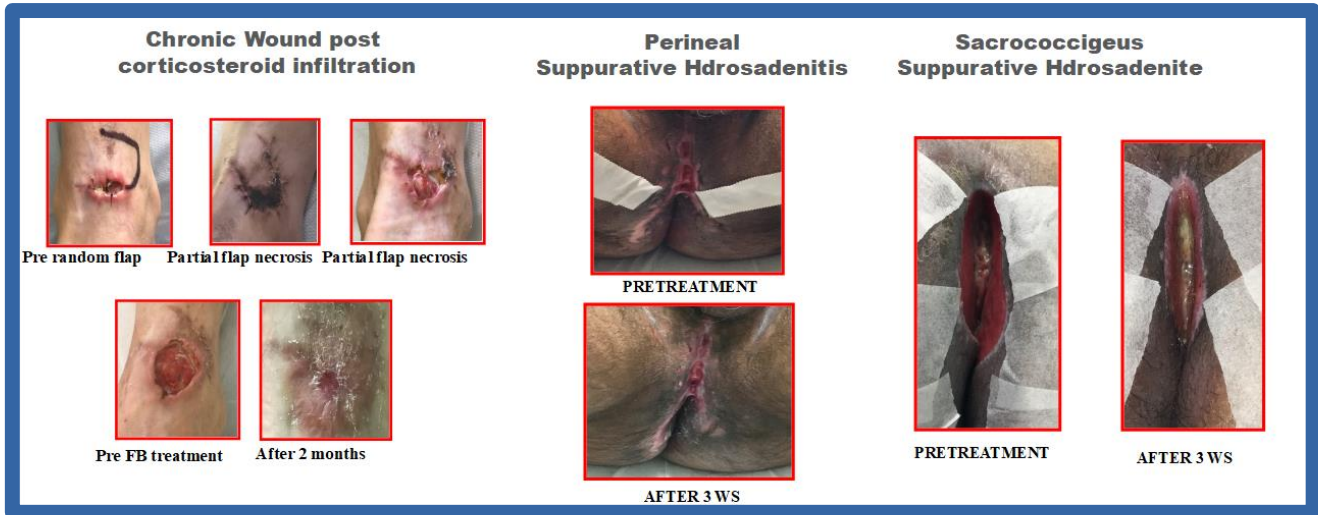
*All claims expressed in this article are solely those of the authors and do not necessarily represent those of their affiliated organizations, or those of the publisher, the editors and the reviewers. Any product that may be evaluated in this article or claim that may be made by its manufacturer is not guaranteed or endorsed by the publisher.*



**Figure 4.** Hypertrophic keloid scar from sternotomy present for about 15 years: pre and post treatment (2 sessions). See the reduction of thickness, erythema.

*The publisher is not responsible for the content or functionality of any supporting information supplied by the authors. Any queries should be directed to the corresponding author for the article.*

*All claims expressed in this article are solely those of the authors and do not necessarily represent those of their affiliated organizations, or those of the publisher, the editors and the reviewers. Any product that may be evaluated in this article or claim that may be made by its manufacturer is not guaranteed or endorsed by the publisher.*



**Figure 5.** A) Random flap necrosis in outcomes of corticosteroid treatment; complete re-epithelialization after 2 months of treatment with FLE. B-C) Perineal and sacrococcygeal hidradenitis suppurativa, post debridement treatment with FLE for 3 weeks; Note the reduction of the treated areas.

*The publisher is not responsible for the content or functionality of any supporting information supplied by the authors. Any queries should be directed to the corresponding author for the article.*

*All claims expressed in this article are solely those of the authors and do not necessarily represent those of their affiliated organizations, or those of the publisher, the editors and the reviewers. Any product that may be evaluated in this article or claim that may be made by its manufacturer is not guaranteed or endorsed by the publisher.*

## Photobiomodulation in Lymphology

Alberto Macciò

Lymphedema is an interstitial edema with a high protein concentration determined by a reduced capacity for lymphatic transport, congenital or acquired. It means dynamic decompensation when, on the other hand, in the face of a conserved transport capacity there is a significant increase in lymphatic load.

According to the World Health Organization (WHO), the incidence of diseases of the lymphatic circulation is to be considered very high (1 person every 20 has, to varying degrees, a disease of lympho-angiological relevance).

In the specifications, the Phlebo-lymphological Guidelines describe lymphedema as a "pathological condition that manifests itself with district edema with high interstitial protein concentration, with degenerative alterations of the connective tissues of the skin and subcutaneous, with frequent reduction of immune functions and a consequent significant incidence of infections; supra-fascial soft tissues are generally affected.'

It is, therefore, important to emphasize that patients with lymphedema often have impaired immune function that predisposes them to septic complications.

The prevalence of ulcers in patients with lymphatic circulation deficiency can be considered higher than in the general population.

In the lymphological field, the most frequent complications are:

### ***Lymphangitis (DLA – dermato-lympho-Angio adenitis)***

Lymphangitis is an inflammation of the lymphatic vessels. It can be acute or chronic and can affect superficial or deep lymphatics. Locoregional and perilesional lymphangitis, truncal lymphangitis, and diffuse lymphangitis are recognized. When the involvement of satellite lymph node structures also occurs, it is called lympho-angio-adenitis. To define diffuse lymphangitis with associated lymph node reaction, the Anglo-Saxons often use the acronym DLA (Dermato-Lympho-Angio-Adenitis).

From an etiopathogenetic point of view, lymphangitis recognizes various triggering causes: the most frequent is certainly the infectious one, especially linked to streptococci infections (group A beta hemolytic streptococcus type, also more commonly called erysipelas).

There are also manifestations associated with systemic inflammatory pathologies.

In 2005, a study presented at the European Congress of Lymphology showed that about 1% of accesses to Italian emergency rooms were connected to more or less acute clinical manifestations closely linked to primary or secondary lymphatic insufficiency.

*The publisher is not responsible for the content or functionality of any supporting information supplied by the authors. Any queries should be directed to the corresponding author for the article.*

*All claims expressed in this article are solely those of the authors and do not necessarily represent those of their affiliated organizations, or those of the publisher, the editors and the reviewers. Any product that may be evaluated in this article or claim that may be made by its manufacturer is not guaranteed or endorsed by the publisher.*



To improve diagnostic accuracy, a specific diagnostic "score" (Lymphangitis Score, Figure 1) was created divided into 8 simple anamnestic-semantic elements with the aim of helping physicians reduce false negatives during differential diagnosis.

### ***Lymphatic ulcers***

Two types of ulcers can be distinguished: true lymphatic ulcer, in which the lesion occurs on a known lymphedema (primary or secondary), or spurious lymphatic ulcer if the involvement of the lymphatic component occurs after ulceration.

The spurious lymphatic ulcer is actually the most frequent finding. The patient not already suffering from any particular pathology affecting the lymphatic circulation, due to the chronicization of the ulcer and perhaps local infectious relapses, may progressively manifest a picture of real perilesional lymphostasis that can also progressively involve the whole limb (post-infectious sclerotic degeneration of satellite lymph nodes with the appearance of secondary lymphedema).

We then recognize two types of True Lymphatic Ulcers:

Type 1: spontaneous (when it appears "*sine causa*" on a known lymphedema)

Type 2: secondary (when the ulceration, although it affects an already lymphoedematous limb, is to be considered secondary to a traumatic event, an infection and/or a skin disease)

When we talk about lymphatic ulcers, the clinical difficulty of management already arises at the level of critical colonization of the lesion as a step prior to the frankly infectious picture.

Lymphostasis generates immunodeficiency of the limb or in any case perilesional favouring the septic complication regardless of the virulence of the pathogen (often, in fact, there is also proliferation of saprophytic bacteria). Given the ease of septicaemic evolution of a lympho-angio-adenitic picture, it is necessary to implement primary prevention by minimizing local contamination.

Therefore, the treatment of lymphatic ulcers is performed in the following steps: i) wound hygiene, disinfection, and curettage of ulcers must be performed in a precise and punctual manner (even at the cost of being aggressive, different products with a broad spectrum of action must be used and be widely extended to the skin surface of the entire limb); ii) dressing, even the dressings used are often chosen with the specific intent to reduce the risk of proliferation of pathogens.

In our experience the most used dressings are: Cadexomer Iodine (Cytotoxic to bacteria), DACC - Dialchilcarbamoilchloride (hydrophobic uptake), and PHMB - Poliesametenbiguanide (bacterial captation).

*The publisher is not responsible for the content or functionality of any supporting information supplied by the authors. Any queries should be directed to the corresponding author for the article.*

*All claims expressed in this article are solely those of the authors and do not necessarily represent those of their affiliated organizations, or those of the publisher, the editors and the reviewers. Any product that may be evaluated in this article or claim that may be made by its manufacturer is not guaranteed or endorsed by the publisher.*

The absorbent dressings often abused in patients with lymphorrhea, and lymphorrhagia lose their meaning when, recognized the lymphatic circulatory deficit, ad hoc therapies are implemented, thus de facto reducing the abundant secretions.

A lymphangiological bandage performed correctly, restores a circulation function, and allows to stop a copious loss of lymph often in less than a week.

The most used bandage is a multilayer and multicomponent short stretch elasto-compressive system, which allows to obtain a high Static Stiffness Index (SSI) *i.e.*, low resting pressures and high working pressures.

### ***Bandage LyMB™***

In our experience, we use a type of multicomponent and multilayer bandage that we have called LyMB™ (Lymphatic Multilayer Bandage). Thanks to its characteristics, LyMB™ can also be used in the acute phase of the disease in which edema, dermatitis, and infection are present.

In fact, it is characterized by: i) very low rest pressures that become effective during walking (thanks to a high static stiffness index, which, however, remains useful even at 48 hours from packaging); ii) progressive and non-digressive pressures, to increase the action where the muscle pump is activated; iii) overlapping layers that include: a soft under-bandage (wide mesh) in the most delicate area, a medium stretch zinc oxide bandage, fine German cotton, a very short extendibility fixing bandage at least 12 cm high, and, finally, sandalwood fixing of the ankle to the first finger to avoid slipping effect on the sole and improve fit and resistance over time; and iv) high compliance by the patient as it has a final thickness of a few millimeters, thus not creating difficulties for the patient in walking.

In this brief exposition, we have recalled the fundamentals of the treatment of lymphatic ulcers, without which any further approach would prove to be ineffective.

All the patients treated by us have, therefore, been subjected to the flow chart just reported to which we have profitably associated also the Photobiomodulation.

### ***Photobiomodulation***

For our main experience, the rationale for the use of Photobiomodulation in lymphology is mainly linked to its antibacterial or bacteriostatic activity in management, in fact, of the local contamination of the lesion.

Specifically, in 2022, we visited 203 patients who underwent photodynamic treatment (the lamp with chromophore is used, both fixed and portable, thus having the possibility to follow patients even at home).

Table 1 shows some characteristics of patients.

*The publisher is not responsible for the content or functionality of any supporting information supplied by the authors. Any queries should be directed to the corresponding author for the article.*

*All claims expressed in this article are solely those of the authors and do not necessarily represent those of their affiliated organizations, or those of the publisher, the editors and the reviewers. Any product that may be evaluated in this article or claim that may be made by its manufacturer is not guaranteed or endorsed by the publisher.*

As one can see, about 80% of the patients had lymphatic ulcers (true/spurious), and the remaining 20% had venous or other ulcers, without lymphatic involvement.

We shall recall that the improvement in the outcome was both in terms of timing and in terms of reduction of local infectious relapses (less than 5% of treated patients had to repeat the course of antibiotic therapy during treatment).

In our experience, we also observed some adverse affections that we report hereunder: on some complex occasions, we have had a dimensional increase of squamous cell and basal cell tumors that are unknown, but which have manifested themselves as increasing in volume in the treated limb; in some patients, we have had hyperemic reactions of the skin, especially in elderly subjects with phototypes 1 and 2.

## Conclusions

The tissue immunodeficiency typical of lymphedema and chronic lymphostases, in general, is a serious problem for clinical lymphologists, who are often busy controlling lymphangitic recurrences and severe lymphatic ulcers complicated by lymphorrhea and real lymphorrhagia.

We are confident that further validation with specific multicentre studies is needed.

However, starting from the rationale for the management of bacterial colonization of ulcerative lesions, we can empirically affirm that the use of Photobiomodulation has brought an improvement in our patients both in terms of healing time and in terms of the number of local infectious relapses.

The abuse of antibiotic therapy, both systemic and topical, is widely discussed by modern medicine, for which it is mandatory to deepen all those methods that can help, in this sense, a more prudent and responsible consumption of therapeutic resources.

For the time being, our experience is linked to the treatment of ulcerations, but we are positively extending the method also in non-ulcerated lymphangitis (Figures 2- 4).

*The publisher is not responsible for the content or functionality of any supporting information supplied by the authors. Any queries should be directed to the corresponding author for the article.*

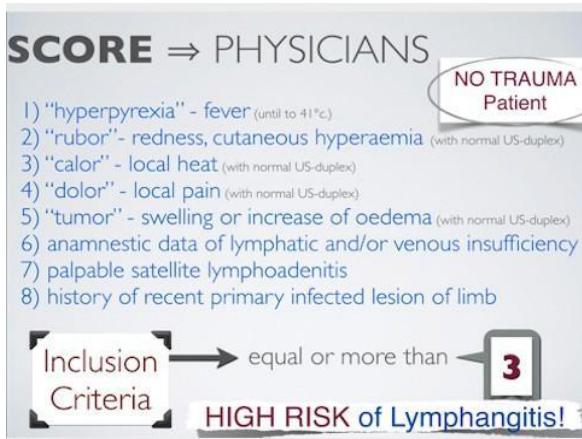
*All claims expressed in this article are solely those of the authors and do not necessarily represent those of their affiliated organizations, or those of the publisher, the editors and the reviewers. Any product that may be evaluated in this article or claim that may be made by its manufacturer is not guaranteed or endorsed by the publisher.*

**Bibliography**

- Boccardo F, Michelini S, Zilli A, Campisi C. Epidemiology of lymphedema. *Phlebology*. 1999;26:24-28.
- The diagnosis and treatment of peripheral lymphedema: 2020 consensus document of the International Society of Lymphology *Lymphology* 2020;19:53.
- Macciò A, Boccardo F, Polenzana B, et al. Lymphology in Emergency room. *The European Journal of Lymphology* 2005;15:44.
- Macciò A. Acute Lymphangitis score for early diagnosis and treatment. *The European Journal of Lymphology and Related Problems*. 2016;28:24.
- Stout N, Partsch H, Szolnoky G, et al. Chronic oedema of the lower extremities: international consensus recommendations for compression therapy clinical research trials. *Int. Angiol.* 2012,31:316-29.
- Macciò A. Compression in dermatolymphangioadenitis. *Veins and Lymphatics* 2016,5:5982.
- Son A, O'Donnell TF Jr, Izhakoff J, et al. Lymphedema- associated comorbidities and treatment gap. *J Vasc Surg Venous Lymphat Disord.* 2019;7:724-30.
- Wang W, Keast DH. Prevalence and characteristics of lymphoedema at a wound- care clinic. *J Wound Care.* 2016;25:S11-5.
- Flanagan M. *Wound healing and skin integrity, principles and practice.* John Wiley and Sons Ltd, 2013.

*The publisher is not responsible for the content or functionality of any supporting information supplied by the authors. Any queries should be directed to the corresponding author for the article.*

*All claims expressed in this article are solely those of the authors and do not necessarily represent those of their affiliated organizations, or those of the publisher, the editors and the reviewers. Any product that may be evaluated in this article or claim that may be made by its manufacturer is not guaranteed or endorsed by the publisher.*

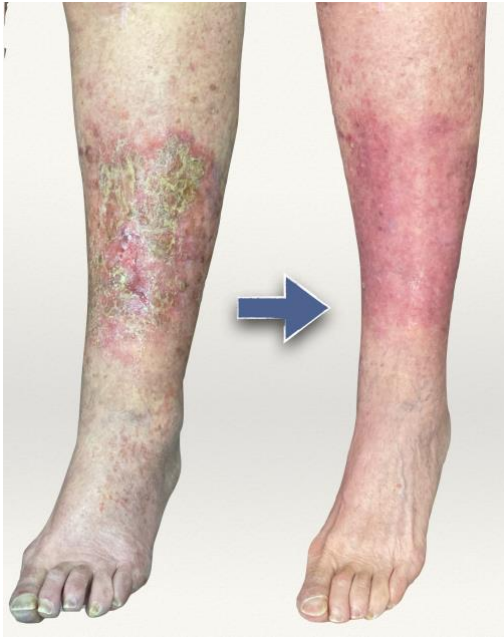

**Figure 1.** Lymphangitis Score: simple scoring system, to diagnose lympho-angio-adenitis. The diagnosis can be made if three or more criteria are present (not applicable after trauma).

*The publisher is not responsible for the content or functionality of any supporting information supplied by the authors. Any queries should be directed to the corresponding author for the article.*

*All claims expressed in this article are solely those of the authors and do not necessarily represent those of their affiliated organizations, or those of the publisher, the editors and the reviewers. Any product that may be evaluated in this article or claim that may be made by its manufacturer is not guaranteed or endorsed by the publisher.*

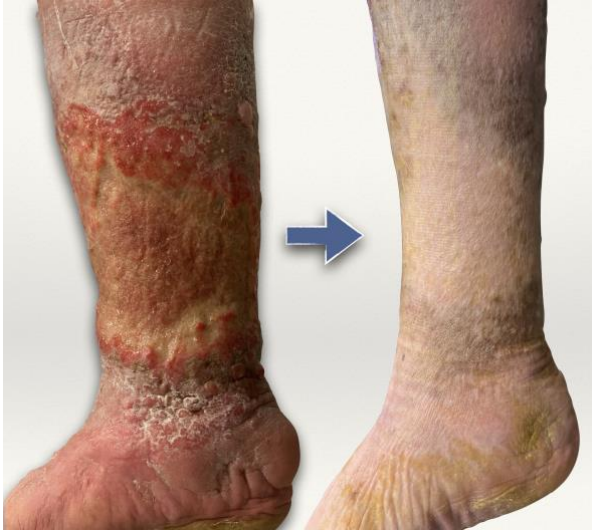**Figure 2.** Lymphangitis with initial ulcerations. Results after 10 days of therapy and 2 sessions of Photobiomodulation.



*The publisher is not responsible for the content or functionality of any supporting information supplied by the authors. Any queries should be directed to the corresponding author for the article.*

*All claims expressed in this article are solely those of the authors and do not necessarily represent those of their affiliated organizations, or those of the publisher, the editors and the reviewers. Any product that may be evaluated in this article or claim that may be made by its manufacturer is not guaranteed or endorsed by the publisher.*

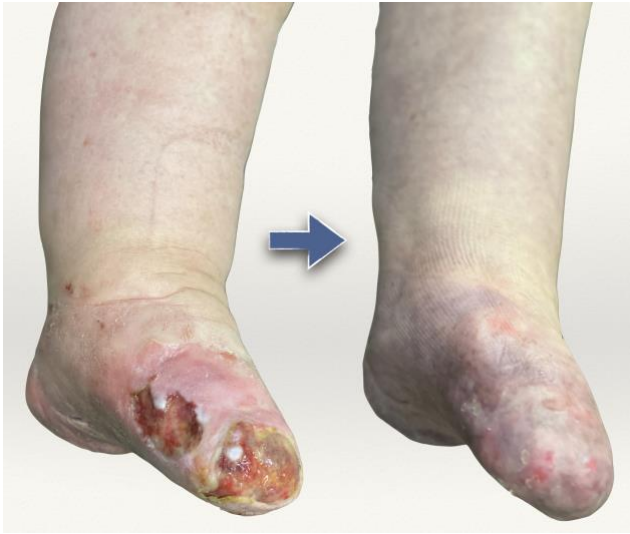**Figure 3.** Lymphatic ulcer not healing for several years. Results after 3 months of therapy and 12 sessions of Photobiomodulation.



*The publisher is not responsible for the content or functionality of any supporting information supplied by the authors. Any queries should be directed to the corresponding author for the article.*

*All claims expressed in this article are solely those of the authors and do not necessarily represent those of their affiliated organizations, or those of the publisher, the editors and the reviewers. Any product that may be evaluated in this article or claim that may be made by its manufacturer is not guaranteed or endorsed by the publisher.*

**Figure 4.** Ulcers not healing for years and worsening in traumatic sub-amputation and recurrent lymphangitis. Results after 5 months of therapy and 20 sessions of Photobiomodulation.



*The publisher is not responsible for the content or functionality of any supporting information supplied by the authors. Any queries should be directed to the corresponding author for the article.*

*All claims expressed in this article are solely those of the authors and do not necessarily represent those of their affiliated organizations, or those of the publisher, the editors and the reviewers. Any product that may be evaluated in this article or claim that may be made by its manufacturer is not guaranteed or endorsed by the publisher.*



Patient characteristics	N (%)
	203 (100)
<b>Gender</b>	
Male	88 (43)
Female	115 (57)
<b>Average age (years)</b>	78
<b>Diagnosis</b>	
Lymphatic ulcers (true/spurious)	160 (79)
Venous ulcers other nature	43 (21)

**Table 1.** Characteristics of the patients.

*The publisher is not responsible for the content or functionality of any supporting information supplied by the authors. Any queries should be directed to the corresponding author for the article.*

*All claims expressed in this article are solely those of the authors and do not necessarily represent those of their affiliated organizations, or those of the publisher, the editors and the reviewers. Any product that may be evaluated in this article or claim that may be made by its manufacturer is not guaranteed or endorsed by the publisher.*

## Application of Photobiomodulation in breast care

Gregorio Stratta

### Introduction

The definition provided by the Garzanti dictionary of senology is: medical discipline that studies physiology, anatomy, and pathology of the breast, *i.e.*, of the breasts.<sup>1</sup>

The breast surgeon is usually a general surgeon who specializes in breast surgery. The breast surgeon can biopsy a tumour and, in case of malignancy, surgically remove it and can also perform breast reconstruction following a mastectomy for breast cancer. Those who deal with this breast reconstruction can be a breast oncologist surgeon or a plastic surgeon. Surgeons trained in both of these specialties are known as oncoplastic surgeons. Some breast surgeons also deal with breast cosmetic surgery.<sup>2</sup>

From a clinical point of view, however, senology is a complex subject in continuous evolution that embraces different specialized branches, such as surgery, radiology, oncology, radiotherapy, pathological anatomy, endocrinology, physiatry and vulnology. The management of breast problems very often requires a multidisciplinary approach in order to achieve the best possible result.<sup>3</sup>

In this multidisciplinary scenario, the question we will try to answer in this chapter is what is today and what will be tomorrow the role of Photobiomodulation (PBM) in the breast field.

### *PBM in the management of breast cancer*

According to the data of the report "The numbers of cancer in Italy 2021" breast cancer is the most diagnosed neoplasm in women. Also, according to this report, about 55,000 new diagnoses of female breast cancer are estimated in Italy in 2020 and in 2021 12,500 deaths are estimated. Net survival at 5 years after diagnosis is 88%.

According to ISTAT data, in 2018, breast cancer represented, with 13,076 deaths, the first cause of death from cancer in women.<sup>4</sup>

In light of these data, it is clear that the prevention and treatment of oncological pathology are the main objectives of senology.

As is known, Photobiomodulation has already been used for the treatment of some side effects secondary to chemotherapy cancer treatments such as oral mucositis.

The main issue to be addressed to achieve universal acceptance of the use of PBM in cancer patients is the verification of its potential stimulating effect on the growth of any residual malignant cells escaped surgical or oncological treatment, which would determine an increased risk of disease recurrence or the onset of a new neoplasia.

*The publisher is not responsible for the content or functionality of any supporting information supplied by the authors. Any queries should be directed to the corresponding author for the article.*

*All claims expressed in this article are solely those of the authors and do not necessarily represent those of their affiliated organizations, or those of the publisher, the editors and the reviewers. Any product that may be evaluated in this article or claim that may be made by its manufacturer is not guaranteed or endorsed by the publisher.*

In this regard, the publication appeared in Oral Oncology in April 2019 entitled "Tumour safety and side effects of Photobiomodulation therapy used for prevention and management of cancer treatment toxicities" by Mariana de Pauli Paglioni *et al.* a systematic review of the literature available on Scopus, MEDLINE/PubMed and Embase was performed by selecting 27 articles in which PBM was applied in cancer patients for prevention of oral mucositis, lymphedema, radiodermatitis and peripheral neuropathies. The conclusions of this systematic review were that the use of PBM in the prevention and management of side effects from cancer treatments does not involve oncological safety concerns. The authors pointed out, however, that the limitations of the reported studies were short disease follow-ups, so they believed longer follow-ups would be necessary to confirm the safety of PBM application in cancer patients.<sup>5</sup>

Indeed, if we refer to the four articles related to the use of PBM in the treatment of lymphedema after mastectomy, the follow-ups were all less than a year, although none of them showed differences in terms of disease recurrence to the detriment of the group treated with PBMT.<sup>6-9</sup>

It is interesting, however, to note the result of the work by Héilton S. Antunes *et al.* entitled "Long-term survival of a randomized phase III trial of head and neck cancer patients receiving concurrent chemoradiation therapy with or without Low-Level Laser Therapy (LLLT) to prevent oral mucositis" published in Oral Oncology (Volume 71, August 2017) 10 included in the systematic review by de Pauli Paglioni *et al.*<sup>5</sup> which showed that the use of PBM for the prevention and treatment of oral mucositis in patients undergoing chemo-radiotherapy for oncological disease of the head and neck district was associated with better progression-free survival than in the placebo group. The interpretation reported by Mariana de Pauli Paglioni *et al.* was that the improvement in quality of life linked to the application of PBM led to greater compliance with medical treatments and a better general state of health for the cancer patient, thus determining overall an improvement in the patient's response to therapy.

These results are relevant from a breast perspective as unfortunately post-surgical complications can also affect a delay in the start of complementary radio-chemotherapy treatments or determine their suspension in the breast field, leading in some cases to a prognostic worsening. This discourse is particularly topical given the extensive execution of immediate breast reconstructions after mastectomy with the aid of implants that have been witnessed in recent decades. Not secondary was also the simultaneous increase in mastectomy interventions to reduce risk with immediate breast reconstruction in patients with increased risk of hereditary breast cancer ascertained. If it is true that in the second scenario, a failure of breast reconstruction is still an important aesthetic and psychological damage, in the first, there is also the possibility that a possible radio-chemotherapy treatment of completion must be postponed or interrupted, determining a possible prognostic worsening.<sup>11</sup>

It is, therefore, especially important today to have technologies whose preventive use can, on the one hand, reduce the risk that such surgical complications arise and, on the other, if they occur, can contribute to speeding up the healing processes in order to avoid delays in complementary oncological treatments. For this reason, the use of PBM could represent precisely this dual therapeutic weapon. To date, however, there is a lack of prospective randomized controlled studies that can confirm its positive impact on the

*The publisher is not responsible for the content or functionality of any supporting information supplied by the authors. Any queries should be directed to the corresponding author for the article.*

*All claims expressed in this article are solely those of the authors and do not necessarily represent those of their affiliated organizations, or those of the publisher, the editors and the reviewers. Any product that may be evaluated in this article or claim that may be made by its manufacturer is not guaranteed or endorsed by the publisher.*

healing of the breast surgical site even before certifying its application oncological safety with adequate follow-up.

Precisely about oncological safety, it is worth mentioning the publication by Shing Yau Tam *et al.* entitled "Review on the Cellular Mechanisms of Low-Level Laser Therapy Use in Oncology" published in *Frontiers in Oncology* in July 2020.<sup>12</sup>

Among the studies analyzed in the review, the most significant from the breast perspective is that of Silva *et al.* entitled "Exploring the effects of low-level laser therapy on fibroblasts and tumor cells following gamma radiation exposure" published in the *Journal of Biophotonics* in 2016.<sup>13</sup> In the *in vitro* study, fibroblasts and breast cancer cells (MDA-MB-231) were irradiated with 2.5 and 10 Gy of ionizing radiation and PBM (GaAlAs laser 660 nm, 30, 90, or 150 J/cm<sup>2</sup>) 24 hours after irradiation. In fibroblasts, PBM promoted survival and proliferation with reduced senescence. In cancer cells, on the other hand, there were no significant changes in survival, while there was a reduction in proliferation and an increase in senescence.

However, unfavourable evidence about cancer safety was always reported by Shing Yau Tam *et al.* citing, for example, the work of Bamps *et al.* entitled "Low-level laser therapy stimulates proliferation in head and neck squamous cell carcinoma cells" published in *Frontiers of Oncology* in 2018<sup>14</sup> in which an increase in proliferation and aggressiveness *in vitro* of squamous-cell carcinoma cells of the district was reported neck-test.

Similarly, PBM appeared to induce the proliferation of osteosarcoma and lung cancer cells, as published by de Castro JL *et al.* in the paper entitled "The effect of laser therapy on the proliferation of oral KB carcinoma cells: an *in vitro* study" published in *Photomed Laser Surgery* in 2005.<sup>15</sup>

The conclusion reached by Shing Yau Tam *et al.* at the end of their review of the literature was that PBM evidently affects a broad spectrum of cellular activities on different types of both normal and tumor cell lines. The authors once again pointed out the need for better-defined studies than available to evaluate the effects *in vitro* and especially *in vivo* of PBM. Finally, the authors urged caution before arriving at an extensive use of PBM in oncology since PBM could induce tumour cell proliferation.<sup>12</sup>

### ***Application of PBM in the treatment of prosthetic capsular contractures***

Prosthetic capsular contractures are the most frequent complication after plastic surgery due to increased breast volume or after post-mastectomy surgical reconstruction. This phenomenon leads to aesthetic dissatisfaction for the patient as well as possible repercussions on the quality of life linked to local pain and functional limitation. The treatment of this multifactorial phenomenon has been, over time, both surgical and conservative, with mixed fortunes. Currently, the most severe degrees of capsular contracture are treated more successfully through surgical procedures such as remodeling of the prosthetic pocket by capsulectomy or capsulotomy. The recurrence rate remains high despite the aforementioned surgical procedures, ranging from 10% to 46%, depending on the series. A relevant and promising experience in the management of this breast problem was undoubtedly that of Jason D. Johnson *et al.* entitled "Low-

*The publisher is not responsible for the content or functionality of any supporting information supplied by the authors. Any queries should be directed to the corresponding author for the article.*

*All claims expressed in this article are solely those of the authors and do not necessarily represent those of their affiliated organizations, or those of the publisher, the editors and the reviewers. Any product that may be evaluated in this article or claim that may be made by its manufacturer is not guaranteed or endorsed by the publisher.*

Level Laser Therapy: An Alternative Treatment for Capsular Contraction" published in The American Journal of Cosmetic Surgery in March 2015.<sup>16</sup> Based on empirical observation of clinical improvement of capsular contracture in two patients receiving PBM treatment for upper limb lymphedema ipsilateral to prosthetic breast reconstruction. Starting from this basis, Johnson *et al.* designed a prospective study in which 33 patients undergoing prosthetic breast reconstruction were enrolled with a clinical diagnosis of Baker III and IV capsular contracture (*i.e.*, with a breast prosthetic implant that could be fixed but with an aesthetic result still acceptable or with an unacceptable result and/or associated with significant clinical symptoms requiring surgery). Ten of these patients had also been treated with radiotherapy at the site of a prosthetic implant. Using the LTU-904 laser (RianCorp Pty Ltd, Richmond, South Australia), a class 1 laser that releases a series of pulses of 200 ns of 904 nm, all patients underwent a total of 6 treatments. The treated area was divided into a grid of 2x2 square cm. Each quadrant received one minute of treatment for a total of 10 minutes (300 mJ/1 min treatment = 1.5 J/cm<sup>2</sup>). Treatments continued weekly for 6 weeks with a subsequent follow-up of 4 weeks. Patients were then asked to report the level of comfort of breast tissues, the improvement in the perception of prosthetic rigidity and the level of satisfaction. All 33 patients completed the planned treatments. The need for surgery to resolve capsular contracture was avoided in 93.9% of cases (31 out of 33 patients). Of the 31 patients who avoided surgery, the perceived improvement in capsular stiffness ranged from 10% to 95% with an average of 43.6% with an improvement in overall perceived comfort of 10% to 95% with an average of 48.2%. Of the 10 patients who had previously undergone radiotherapy, only 1 patient said they did not appreciate improvements. All 31 patients reported that the improvement achieved with the treatment was sufficient to avoid corrective surgery and said that they would gladly undergo further PBM treatment again if necessary. A significant clinical improvement was also observed by the reference surgeons of each patient including patients who had not reported subjective improvement. About the 2 patients who had not reported an improvement and who had therefore undergone surgical treatment, at the time of publication the authors did not report any recurrence of capsular contraction. No adverse events were reported in the study.

The work of Johnson *et al.* undoubtedly represents a promising starting point for further exploring the application of this technology in the conservative treatment of periprosthetic capsular contractures, potentially reducing the need for invasive corrective surgery. As reported by the authors themselves, however, before presenting this technology as a valid alternative option to surgery, further studies are needed to validate the results obtained (including animal studies to investigate the mechanisms of action involved), randomized double-blind trials, larger study populations, objective measurements of tissue change and comparisons with other non-invasive methods of treatment.

### ***Clinical application of PBM in the treatment of lymphedema secondary to breast cancer***

One of the applications for which PBM is best known in the breast field is the treatment of lymphedema secondary to the treatment of breast cancer. Surgical interventions such as axillary lymphadenectomy and/or locoregional mammary radiotherapy may affect secondarily a persistent accumulation of lymphatic fluid in the interstitial tissue of the upper limb ipsilateral to the surgical site. PBM is already widely used as a supportive treatment for lymphedema patients due to its known beneficial effects on

*The publisher is not responsible for the content or functionality of any supporting information supplied by the authors. Any queries should be directed to the corresponding author for the article.*

*All claims expressed in this article are solely those of the authors and do not necessarily represent those of their affiliated organizations, or those of the publisher, the editors and the reviewers. Any product that may be evaluated in this article or claim that may be made by its manufacturer is not guaranteed or endorsed by the publisher.*

reducing inflammation, regenerating the lymphatic ducts, reducing pain, and preventing tissue fibrosis, as reported in the publications of E Lima MT *et al.* "Low-level laser therapy in secondary lymphedema after breast cancer: systematic review" published on Lasers Med Sci in 2014<sup>17</sup> and Omar MT *et al.* "A systematic review of the effect of low-level laser therapy in the management of breast cancer-related lymphedema" published on Support Care Cancer in 2012.<sup>18</sup>

The clinical efficacy of these treatments was evaluated by Chen HY *et al.* in the article entitled "Effects of Photobiomodulation therapy on breast cancer-related lymphoedema: a systematic review and meta-analysis of randomised controlled trials" published in the journal Complementary Therapies in Medicine in December 2019.<sup>19</sup> In their work, the authors analysed 9 randomized controlled trials that included a total of 316 patients and 6 studies for meta-analysis finding no significant differences between the PBM group compared to the control group in the reduction of arm circumference or arm volume after treatment at 1 and 3 months apart. Although a live reduction in arm circumference was observed, however, in favour of the group subjected to which did not reach statistical significance. Also, with regard to the recovery of grip strength and the pain score, no significant differences were detected between the PBM group compared to the control group. The conclusions reached by the authors were that although PBM appeared to result in a slight reduction in the volume of the treated arm compared to the control group, the results of the meta-analysis did not show significant benefits in alleviating lymphedema.

The clinical efficacy of PBM in the treatment of lymphedema secondary to the treatment of breast cancer was recently re-evaluated by authors Junwon Min and Yoonjoon Park through a comprehensive review of the available literature on the subject published over the past 20 years. The article titled "Clinical Applications of Photobiomodulation Therapy in the Management of Breast Cancer-related Lymphedema" was then published in the journal Medical Lasers in September 2021.<sup>20</sup> In analysis, only randomized controlled trials were considered, reducing to 7 the studies that agreed with the inclusion criteria imposed by the authors including the meta-analysis by Chen HY *et al.* mentioned above. The conclusions reached showed an overall positive trend in the reduction of the circumference of the arm affected by lymphedema and the symptoms related to it after treatment with PBM. Again, however, the authors stressed the need for further studies with a larger number of participants to evaluate the long-term effect and safety of PBM in the treatment of lymphedema secondary to breast cancer treatments.

### ***Application of PBM in keloid management***

Keloid is a detected scar characterized by excessive proliferation of fibroblasts and an imbalance between collagen production and degradation. Keloids do not regress spontaneously and cross the scar line in a disorganized and irregular manner. Beyond the unpleasant aesthetic aspect, keloids can also be itchy and/or painful. This combination of elements can negatively affect the quality of life. The localization of a keloid in the breast represents a negative aesthetic condition with regard to the final surgical result. The genesis of this clinical condition is not yet fully understood. However, some studies have shown that inflammatory aspects and fibroblast hyperproliferation is linked to an increase in the expression of Transforming Growth Factor Beta (TGF- $\beta$ 1) in endothelial cells in the neovascularization process and

*The publisher is not responsible for the content or functionality of any supporting information supplied by the authors. Any queries should be directed to the corresponding author for the article.*

*All claims expressed in this article are solely those of the authors and do not necessarily represent those of their affiliated organizations, or those of the publisher, the editors and the reviewers. Any product that may be evaluated in this article or claim that may be made by its manufacturer is not guaranteed or endorsed by the publisher.*

also an increase in the expression of Connective Tissue Growth Factor (CTGF). TGF- $\beta$  remains high and dysregulated even in the terminal stages of scar healing, where it normally tends to decrease.

*In vitro* experimental studies using keloid fibroblasts and human dermis have shown an increase in positive effects, including increased apoptosis rate and reduction in cell division rate of these fibroblasts as well as reduced collagen synthesis and TGF- $\beta$  expression. Blue light, in particular, is reported to have an inhibitory effect on fibroblasts and TGF- $\beta$  when administered at a higher energy density (up to 640 J/cm<sup>2</sup>).<sup>21</sup>

Some studies have actually reported the benefits of PBM in the progress of postoperative healing of scars from different types of interventions, demonstrating the safety and efficacy of such therapy.

Among these studies should be noted the experience of Park YJ *et al.* published under the title "Prevention of Thyroidectomy Scars in Asian Adults With Low-Level Light Therapy" in *Dermatologic Surgery* in 2016.<sup>22</sup> A total of 50 patients undergoing thyroidectomy with a linear scar were enrolled in the study, of which 35 were also treated with LED-LLT 830/590 nm daily for 11 minutes with 60 j/cm for one week starting from the first post-operative day and followed by 3 treatments per week for a further 3 weeks. The control group of 15 patients was not treated. The ulcers were then re-evaluated at 1 and 3 months after thyroidectomy with colorimetric evaluations using a tristimulus-colour analyser. The Vancouver Scale Score (VSS), the Global Clinical Assessment (GAS) and the subjective satisfaction score (range: 1-4) were also determined during the controls.

The reported results indicated that colour values were significantly reduced at 3-month follow-up in the study group compared to the control group. In addition, VSS and GAS scores were lower in the study group, while subjective satisfaction scores did not differ significantly between the two groups. The conclusion reached by Park YJ *et al.* was that PBM suppressed abnormal scarring after thyroidectomy in the absence of obvious adverse effects.

This experience could represent an interesting starting point for a similar study in the field of breasts.

To be monitored in this sense will be the progress of the study proposed by Jefferson André Piresi *et al.* entitled "Effect of the combination of PhotoBioModulation therapy and the intralesional administration of corticoid in the preoperative and postoperative periods of keloid surgery: A randomized, controlled, double-blind trial protocol study" whose prospectus was published on PLoS ONE on February 15, 2022 and registered on ClinicalTrials.gov (ID: NCT04824612).<sup>21</sup> The purpose of that study is to fill the absence of randomised double-blind trials on the subject of preventing keloid formation through the use of PBM. Specifically, the study was designed with a study group composed of 29 patients to whom PBM will be applied combined with the administration of intralesional corticosteroids in the preoperative phase and then, after surgical removal of the keloid, the PBM alone in the post-operative period using a blue LED light (470 nm, 400 mW, 4J per point on 10 linear points). The second placebo group, composed of 29 patients, will instead receive the administration of intralesional corticosteroids in the preoperative phase associated with a fake blue light and, therefore, in the post-operative period, only the fake blue light. The removed keloids will undergo a histopathological analysis to evaluate the differences in response between the two study groups. Patients will also undergo a clinical follow-up by a team of 5 plastic surgeons who

*The publisher is not responsible for the content or functionality of any supporting information supplied by the authors. Any queries should be directed to the corresponding author for the article.*

*All claims expressed in this article are solely those of the authors and do not necessarily represent those of their affiliated organizations, or those of the publisher, the editors and the reviewers. Any product that may be evaluated in this article or claim that may be made by its manufacturer is not guaranteed or endorsed by the publisher.*

will fill in the VSS. Patients will be asked to answer two questionnaires: one to assess quality of life (Qualifibro-UNIFESP) and one to assess satisfaction with scar outcome (PSAQ).

### ***Application of PBM in the treatment of puerperal mastitis***

Puerperal mastitis is a clinical condition usually treated conservatively using anti-inflammatory drugs and/or antibiotics or invasively through surgical drainage of any abscesses. The use of PBM as a therapeutic tool in this clinical picture is reported in the literature in a case report by Luiza Pokrajac Veloso *et al.* entitled "Photobiomodulation therapy in the post-operative management of puerperal mastitis-associated breast abscess" published in March 2022 in the journal Research, Society and Development.<sup>23</sup> In the case reported, PBM was applied to breast abscess already treated with antibiotic therapy and surgically drained with permanence of inflammation and local pain 11 days apart. The patient was then subjected to 3 sessions per week of treatment with PBM for a total of 15 sessions, assisting already after the third treatment to complete regression of local pain. At the end of 3 p.m., complete healing was achieved without the need for further surgical procedures, in the absence of any side effects.

Although the scientific weight of a single case report is limited, it is stimulating to reflect on the potential of PBM as a possible complementary or alternative therapeutic tool available to the breast specialist in this specific phase of female life where the administration of drugs or the application of surgical procedures is particularly delicate.

### ***Impact of PBM in the treatment of postoperative pain***

As is known, among the beneficial effects of PBM there is the pain-relieving action.<sup>24,25</sup>

The application of this technology in postoperative pain control was investigated by Jackson RF *et al.* entitled "Low-level laser therapy effectiveness for reducing pain after breast augmentation" and published in The American Journal of Cosmetic Surgery in 2009.<sup>26</sup>

In this prospective randomized double-blind multicentre study, patients undergoing bilateral breast augmentation were evaluated and treated in the study group of 50 patients with PBM using Erchonia EML laser (Erchonia Medical, Inc., McKinney, Texas, USA) characterized by two 7 mw (630–640 nm) laser that was applied 10 minutes after the start of surgery on each breast for 4 minutes at a distance of 6 inches. The procedure was then repeated within 10 minutes of the end of the surgery and then 24 hours and one week after surgery on both breasts. The control group of 54 patients was not treated with PBM.

The VAS pain scale was assessed before the procedure, 24 hours apart, and after an interval of 1, 2 and 4 weeks. The use of painkillers (vicodin ES, percocet 5/325 lortab 10/500, dolacet) was documented in the first seven days. The vertical and horizontal breast diameter measured with caliber and hydration parameters (evidence of edema and measurement of ankle circumference) were evaluated before the procedure, 24 hours apart, and after an interval of 1 week. Ulcers were examined for signs of infection at

*The publisher is not responsible for the content or functionality of any supporting information supplied by the authors. Any queries should be directed to the corresponding author for the article.*

*All claims expressed in this article are solely those of the authors and do not necessarily represent those of their affiliated organizations, or those of the publisher, the editors and the reviewers. Any product that may be evaluated in this article or claim that may be made by its manufacturer is not guaranteed or endorsed by the publisher.*



24 hours and 7 postoperative days. The Modified Hollander Cosmesis Scale was used to assess wound healing at the surgical site 7 days after surgery. Any injury complications were reported until the twenty-eighth postoperative day. The results achieved in the study led the authors to conclude that PBM significantly reduced postoperative pain and the use of pain relief therapy in the study group compared to the placebo group at 1 and 7 days after surgery. PBM was also easy and safe in its application in the absence of adverse effects reported by the researchers.

## Conclusions

Based on the available studies, PBM applied in the breast field is today a promising technology potentially useful in the prevention and management of surgical ulcers and prosthetic capsular contractures, in the prevention of keloid formation, and in the management of postoperative pain.

An interesting application still to be explored is its use in the management of puerperal mastitis.

For its safe and extensive clinical breast application, in particular, in the field of oncology, it is still necessary to continue the research path outlined by the authors reported in this chapter.

*The publisher is not responsible for the content or functionality of any supporting information supplied by the authors. Any queries should be directed to the corresponding author for the article.*

*All claims expressed in this article are solely those of the authors and do not necessarily represent those of their affiliated organizations, or those of the publisher, the editors and the reviewers. Any product that may be evaluated in this article or claim that may be made by its manufacturer is not guaranteed or endorsed by the publisher.*

**References**

- 1) <https://www.garzantilinguistica.it/ricerca/?q=senologia>
- 2) Medterms Medical Dictionary a-z list / breast surgeon definition - Medical Definition of Breast Surgeon. Available from: [https://www.medicinenet.com/breast\\_surgeon/definition.htm](https://www.medicinenet.com/breast_surgeon/definition.htm)
- 3) Kaufman CS. Breast care is a team sport. *Breast J.* 2004;10:469-72.
- 4) Ministero della Salute Italiano. Il tumore della mammella. Available from: <https://www.salute.gov.it/portale/tumori/dettaglioContenutiTumori.jsp?lingua=italiano&id=5538&area=tumori&menu=vuoto>
- 5) Mariana de Pauli Paglioni et al. Tumor safety and side effects of photobiomodulation therapy used for prevention and management of cancer treatment toxicities. *Oral Oncology.* 2019;93:23-8.
- 6) Carati CJ, Anderson SN, Gannon BJ, Piller NB. Treatment of post-mastectomy lymphedema with low-level laser therapy: a double blind, placebo-controlled trial. *Cancer.* 2003;98:1114-22.
- 7) Kaviani A, Fateh M, Yousefi Nooraie R, et al. Low level laser therapy in management of post mastectomy lymphedema. *Lasers MedSci* 2006;21:90-4.
- 8) Li K, Zhang Z, Liu NF, et al. Efficacy and safety of far infrared radiation in lymphedema treatment: clinical evaluation and laboratory analysis. *LasersMedSci.* 2017;32:485-94.
- 9) Storz MA, Gronwald B, Gottschling S, et al. Photobiomodulation therapy in breast cancer-related lymphedema: a randomized placebo-controlled trial. *Photodermatol Photoimmunol Photomed.* 2017;33:32-40.
- 10) Antunes HS et al. Long-term survival of a randomized phase III trial of head and neck cancer patients receiving concurrent chemoradiation therapy with or without low-level laser therapy (LLLT) to prevent oral mucositis. *Oral Oncology.* 2017;71:11-5.
- 11) de Melo Gagliato D, Chavez-MacGregor M. Delays in Adjuvant Chemotherapy Among Breast Cancer Patients: An Unintended Consequence of Breast Surgery? *Annals of Surgical Oncology.* 2018;25:1786-7.
- 12) Tam SY et al. Review on the Cellular Mechanisms of Low-Level Laser Therapy Use in Oncology. *Frontiers in Oncology.* 2020;10:1255.
- 13) Silva CR et al. Exploring the effects of low-level laser therapy on fibroblasts and tumor cells following gamma radiation exposure. *J Biophoton.* 2016;9:1157-66.
- 14) Bamps M, Dok R, Nuyts S. Low-level laser therapy stimulates proliferation in head and neck squamous cell carcinoma cells. *Front Oncol.* 2018;8:343.

*The publisher is not responsible for the content or functionality of any supporting information supplied by the authors. Any queries should be directed to the corresponding author for the article.*

*All claims expressed in this article are solely those of the authors and do not necessarily represent those of their affiliated organizations, or those of the publisher, the editors and the reviewers. Any product that may be evaluated in this article or claim that may be made by its manufacturer is not guaranteed or endorsed by the publisher.*

- 15) de Castro JL, Pinheiro AL, Werneck CE, Soares CP. The effect of laser therapy on the proliferation of oral KB carcinoma cells: an in vitro study. *Photomed Laser Surg.* 2005;23:586-9.
- 16) D. Johnson et al. Low-Level Laser Therapy: An Alternative Treatment for Capsular Contraction. *The American Journal of Cosmetic Surgery.* 2015;32:7-11.
- 17) Lima EMT et al. Low-level laser therapy in secondary lymphedema after breast cancer: systematic review. *Lasers Med Sci.* 2014;29:1289-95.
- 18) Omar MT, Shaheen AA, Zafar H. A systematic review of the effect of low-level laser therapy in the management of breast cancer-related lymphedema. *Support Care Cancer.* 2012;20:2977-84.
- 19) Chen HY et al. Effects of photobiomodulation therapy on breast cancer-related lymphoedema: a systematic review and meta-analysis of randomised controlled trials. *Complement Ther Med.* 2019;47:102200.
- 20) Min J, Park Y. Clinical Applications of Photobiomodulation Therapy in the Management of Breast Cancer-related Lymphedema. *Med Laser.* 2021;10:189-94.
- 21) Pires JA, et al. Effect of the combination of photobiomodulation therapy and the intralesional administration of corticoid in the preoperative and postoperative periods of keloid surgery: a randomized, controlled, double-blind trial protocol study. *PLoS ONE.* 2022;17:e0263453.
- 22) Park YJ, et al. Prevention of Thyroidectomy Scars in Asian Adults With Low-Level Light Therapy. *Dermatol Surg.* 2016;42:526-34.
- 23) Luiza Pokrajac Veloso, et al. Photobiomodulation therapy in the post-operative management of puerperal mastitis-associated breast abscess. *Research, Society and Development.* 2022;11:e32411427484.
- 24) Enwemeka CS, et al. The efficacy of lowpower lasers in tissue repair and pain control: a meta-analysis study. *Photomed Laser Surg.* 2004;22:323-9.
- 25) Naeser MA. Photobiomodulation of pain in carpal tunnel syndrome: review of seven laser therapy studies. *Photomed Laser Surg.* 2006;24:101-10.
- 26) Jackson RF et al. Low-level laser therapy effectiveness for reducing pain after breast augmentation. *The American Journal of Cosmetic Surgery.* 2009;26:144.

*The publisher is not responsible for the content or functionality of any supporting information supplied by the authors. Any queries should be directed to the corresponding author for the article.*

*All claims expressed in this article are solely those of the authors and do not necessarily represent those of their affiliated organizations, or those of the publisher, the editors and the reviewers. Any product that may be evaluated in this article or claim that may be made by its manufacturer is not guaranteed or endorsed by the publisher.*

*The publisher is not responsible for the content or functionality of any supporting information supplied by the authors. Any queries should be directed to the corresponding author for the article.*

*All claims expressed in this article are solely those of the authors and do not necessarily represent those of their affiliated organizations, or those of the publisher, the editors and the reviewers. Any product that may be evaluated in this article or claim that may be made by its manufacturer is not guaranteed or endorsed by the publisher.*

**Take home message**

Alessandro Corsi, Ornella Forma

Aligning and grouping the clinical experiences of Fotobiomodulazione in different application fields was not a trivial task and required a considerable and constant commitment to data collection and alignment with the literature, wide but, sometimes, dispersive.

As repeatedly pointed out, it has often been difficult to compare different clinical realities, with different attitudes towards this technology by applying various treatment methods.

Furthermore, the understanding of the phenomena that are triggered in the tissues by the interaction of light is still limited and this contributes to creating difficulties also in the field of application.

However, the work that has derived from this study, has allowed us to frame the multifaceted aspects of the interaction between light and living tissues, allowing us to underline some characteristics that, as described in the various chapters, belong specifically to fluorescent light stimulation and, respectively, to monochromatic light stimulation.

As already pointed out, it is not a question of identifying a better treatment, but, in the different fields of application, it has been highlighted how the choice of the most suitable technology changes in relation to the clinic.

We believe that the highest level Vulnology Centers should consider the use of light, in the treatment of skin lesions, not focusing on a single type (monochromatic or fluorescence), but expanding the devices supplied to the widest possible number among those present in the Wound Care market, to have greater applicability, clinical indications and better results.

This work (entirely conducted without any influence from companies) wants to act as a "pilot" for further investigations that, we are sure, will only lead to increasing the knowledge of this technology of which, probably, we still have an incomplete and partial vision.

*The publisher is not responsible for the content or functionality of any supporting information supplied by the authors. Any queries should be directed to the corresponding author for the article.*

*All claims expressed in this article are solely those of the authors and do not necessarily represent those of their affiliated organizations, or those of the publisher, the editors and the reviewers. Any product that may be evaluated in this article or claim that may be made by its manufacturer is not guaranteed or endorsed by the publisher.*