


## Article

# Lymphadenopathy after *BNT162b2* Covid-19 Vaccine: Preliminary Ultrasound Findings

Vincenza Granata <sup>1</sup>, Roberta Fusco <sup>1,\*</sup> , Sergio Venanzio Setola <sup>1</sup>, Roberta Galdiero <sup>1</sup>, Carmine Picone <sup>1</sup>, Francesco Izzo <sup>2</sup> , Roberta D'Aniello <sup>3</sup> , Vittorio Miele <sup>4</sup> , Roberta Grassi <sup>5</sup>, Roberto Grassi <sup>5,6</sup> and Antonella Petrillo <sup>1</sup> 

- <sup>1</sup> Radiology Division, “Istituto Nazionale Tumori IRCCS Fondazione Pascale—IRCCS di Napoli”, 80131 Naples, Italy; v.granata@istitutotumori.na.it (V.G.); s.setola@istitutotumori.na.it (S.V.S.); r.galdiero@istitutotumori.na.it (R.G.); c.picone@istitutotumori.na.it (C.P.); a.petrillo@istitutotumori.na.it (A.P.)
  - <sup>2</sup> Hepatobiliary Surgical Oncology Division, “Istituto Nazionale Tumori IRCCS Fondazione Pascale—IRCCS di Napoli”, 80131 Naples, Italy; f.izzo@istitutotumori.na.it
  - <sup>3</sup> Hospital Pharmacy Division, “Istituto Nazionale Tumori IRCCS Fondazione Pascale—IRCCS di Napoli”, 80131 Naples, Italy; r.daniello@istitutotumori.na.it
  - <sup>4</sup> Division of Radiodiagnostic, “Azienda Ospedaliero-Universitaria Careggi”, 50139 Firenze, Italy; vmiele@sirm.org
  - <sup>5</sup> Division of Radiology, University of Campania Luigi Vanvitelli, 80125 Naples, Italy; robertagrassi89@gmail.com (R.G.); roberto.grassi@unicampania.it (R.G.)
  - <sup>6</sup> Foundation SIRM, 20122 Milan, Italy
- \* Correspondence: r.fusco@istitutotumori.na.it; Tel.: +39-081590714; Fax: +39-0815903825



**Citation:** Granata, V.; Fusco, R.; Setola, S.V.; Galdiero, R.; Picone, C.; Izzo, F.; D'Aniello, R.; Miele, V.; Grassi, R.; Grassi, R.; et al. Lymphadenopathy after *BNT162b2* Covid-19 Vaccine: Preliminary Ultrasound Findings. *Biology* **2021**, *10*, 214. <https://doi.org/10.3390/biology10030214>

Academic Editor: Andrea Moriondo

Received: 19 February 2021

Accepted: 9 March 2021

Published: 11 March 2021

**Publisher's Note:** MDPI stays neutral with regard to jurisdictional claims in published maps and institutional affiliations.



**Copyright:** © 2021 by the authors. Licensee MDPI, Basel, Switzerland. This article is an open access article distributed under the terms and conditions of the Creative Commons Attribution (CC BY) license (<https://creativecommons.org/licenses/by/4.0/>).

**Simple Summary:** Eccentric cortical thickening with wide echogenic hilum and oval shape, asymmetric eccentric cortical thickening with wide echogenic hilum and oval shape, concentric cortical thickening with reduction in the width of the echogenic hilum and oval shape, and huge reduction and displacement of the echogenic hilum and round shape are the features that we found in post *BNT162b2* Covid-19 Vaccine lymphadenopathies.

**Abstract:** During a spontaneous and autonomous study, we assessed the ultrasound finding of lymphadenopathy after *BNT162b2* Pfizer vaccine. We enrolled 18 patients with 58 lymphadenopathies: in 10 patients, they were in the laterocervical side, while in 8 patients in the axillar site. The largest diameter was 16 mm with a range from 7 to 16 mm (median value = 10 mm). In the same patient, we found different ultrasound nodal findings. A total of 25 nodes showed eccentric cortical thickening with wide echogenic hilum and oval shape. In total, 19 nodes showed asymmetric eccentric cortical thickening with wide echogenic hilum and oval shape. Overall, 10 nodes showed concentric cortical thickening with reduction in the width of the echogenic hilum and oval shape. A total of four nodes showed huge reduction and displacement of the echogenic hilum and round or oval shape. No anomaly was found at the Doppler echocolor study. In conclusion, eccentric cortical thickening with wide echogenic hilum and oval shape, asymmetric eccentric cortical thickening with wide echogenic hilum and oval shape, concentric cortical thickening with reduction in the width of the echogenic hilum and oval shape, and a huge reduction and displacement of the echogenic hilum and round shape are the features that we found in post *BNT162b2* Covid-19 Vaccine lymphadenopathies.

**Keywords:** COVID-19 infection; vaccine; ultrasound; lymphadenopathy

## 1. Background

In December 2019, health authorities in Wuhan, China, identified a cluster of acute respiratory disease of unknown etiology [1]. Subsequently the researchers identified a new viral agent, SARS-CoV-2, as responsible for the heart of an international outbreak centered in Hubei. On 30 January 2020, World Health Organization (WHO) confirmed the COVID-19 epidemic as a public health emergency and on 11 March 2020 demarcated the

rapid spread of infection as a pandemic in the world [1,2]. Globally, at the time of writing (17 January 2021), there have been 93,194,922 confirmed cases of COVID-19, including 2,014,729 deaths, reported to WHO. In Italy, there have been 2,368,733 confirmed cases of COVID-19 with 81,800 deaths. Up to today, effective treatment has not yet been developed so that mechanical respiratory support is the only therapy in critically ill patients [3–5]. In this scenario, it was necessary to develop a vaccine as soon as possible, to prevent coronavirus disease 2019 and to protect persons who are at high risk for complications. At the time of writing in Italy have been approved two vaccines: the mRNA-1273 vaccine Moderna [6] and BNT162b2 Pfizer drug [7]. In 27 December, health authorities in Italy have authorized the administration of the *BNT162b2* Pfizer vaccine in healthcare personnel, defining this day as Vaccine (V)-day.

During the trial clinic on *BNT162b2*, vaccine data on local and systemic reactions and use of medication were collected with electronic diaries from participants in the reactogenicity subset (8183 participants) for 7 days after each vaccination [7]. Adverse event analyses are provided for all enrolled participants, with variable follow-up time after dose. More *BNT162b2* recipients than placebo recipients reported any adverse event (27 and 12%, respectively) or a related adverse event (21 and 5%). A total of 64 vaccine recipients (0.3%) and 6 placebo recipients (<0.1%) reported lymphadenopathy. We assessed ultrasound (US) findings in 18 consecutive patients from healthcare personnel that reported lymphadenopathy after *BNT162b2* Pfizer drug.

## 2. Materials and Methods

### 2.1. Patient Population

This is a spontaneous and autonomous study, without the authorization of the ethics committee, for which patients have allowed data processing in accordance with National Privacy Regulations [8]. This observational study included the period from 27 December 2020 to 16 January 2021, the date of the last administration of the vaccine first dose among the health personnel in Campania. In this time range, 18 consecutive patients from healthcare personnel who received the first dose of *BNT162b2* Pfizer vaccine were enrolled: 10 for palpable mass appeared after the vaccine, 8 sent to the ultrasound study by the pharmacovigilance physician.

In Table 1 we reported the patients study group characteristics.

**Table 1.** Patients study group characteristics.

Patient (Age; Sex)	Vaccine Administration Date	Time of Appearance/Disappearance	Number of Nodes	Side	Medication Use	Others Symptoms	Previous Covid Infection (Time)	Presence of Antibodies
1 (47 y; M)	01/04	36 h/5 days	3	laterocervical side	Yes	No	No	No
2 (63 y; F)	01/08	24 h/3 days	5	laterocervical side	Yes	Fever (37.5 °C); headache; fatigue; diarrhea	No	No
3 (38 y; F)	01/07	24 h/3 days	3	laterocervical side	No	No	No	No
4 (43 y; F)	01/06	12 h/24 h	4	laterocervical side	No	No	No	No
5 (42 y; F)	01/15	24 h/4 days	3	Axilla	No	No	No	No
6 (35 y; F)	01/15	12 h/24 h	3	laterocervical side	No	Fever (38 °C)	Yes	Yes

Table 1. Cont.

Patient (Age; Sex)	Vaccine Administration Date	Time of Appearance/Disappearance	Number of Nodes	Side	Medication Use	Others Symptoms	Previous Covid Infection (Time)	Presence of Antibodies
7 (54 y; M)	01/02	36 h/73 days	1	Axilla	No	Fever (37.5 °C)	Yes	No
8 (49 y; F)	06/01	36 h/5 days	3	Axilla	No	No	No	No
9 (42 y; F)	01/02	24 h/4 days	4	Axilla	Yes	Fever (37.5 °C)	No	No
10 (41 y; F)	01/05	36 h/5 days	1	laterocervical side	No	Fever (37.5 °C)	No	No
11 (56 y; M)	01/15	36 h/5 days	3	laterocervical side	No	Fever (38 °C)	Yes	Yes
12 (47 y; M)	01/04	24 h/3 days	4	Axilla	No	No	No	No
13 (63 y; F)	01/15	24 h/3 days	5	laterocervical side	Yes	Fever (37.5 °C); headache; fatigue; diarrhea	No	No
14 (35 y; F)	01/13	24 h/3 days	3	Axilla	No	No	No	No
15 (40 y; F)	01/05	24 h/3 days	4	Axilla	No	Fatigue	No	No
16 (61 y; F)	01/10	24 h/3 days	5	laterocervical side	Yes	Headache; fatigue; diarrhea	No	No
17 (51 y; M)	01/08	36 h/5 days	3	Axilla	No	No	No	No
18 (26 y; F)	01/10	24 h/3 days)	1	laterocervical side	No	No	No	No

## 2.2. US Protocol and Images Analysis

Nodes ultrasound exams were performed by dedicated radiologists, using RS85 Samsung System (Samsung Healthcare GmbH, Schwalbach, Germany) in combination with a linear 5 to 12-MHz array transducer.

A total of four in-site expert radiologists in interpretation of nodal images, recorded the data in consensus. Presence, side, size, shape, echogenicity, cortex feature, margin, and hilum of the lesions were categorized. We also assessed color doppler features.

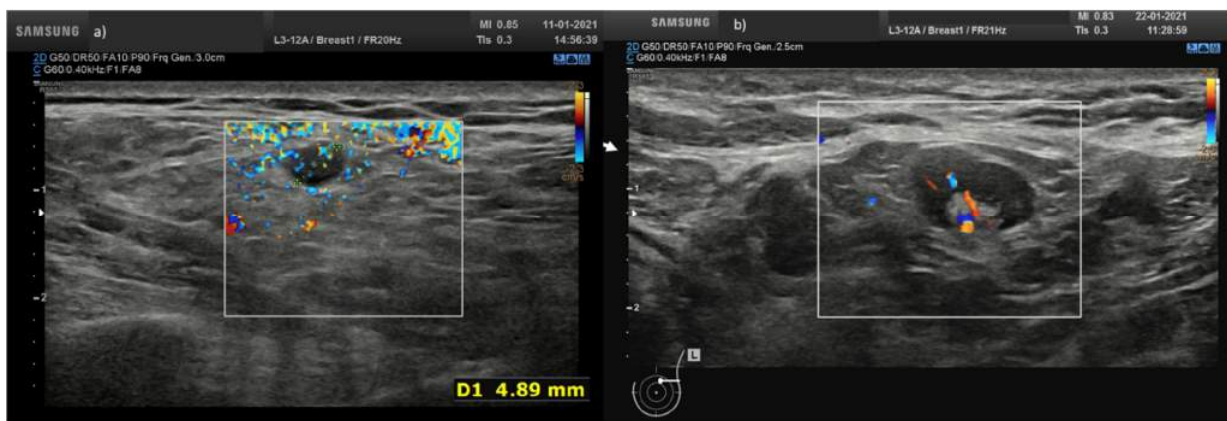
## 3. Results

We assessed 18 patients with 58 lymphadenopathy after *BNT162b2* Covid-19 Vaccine.

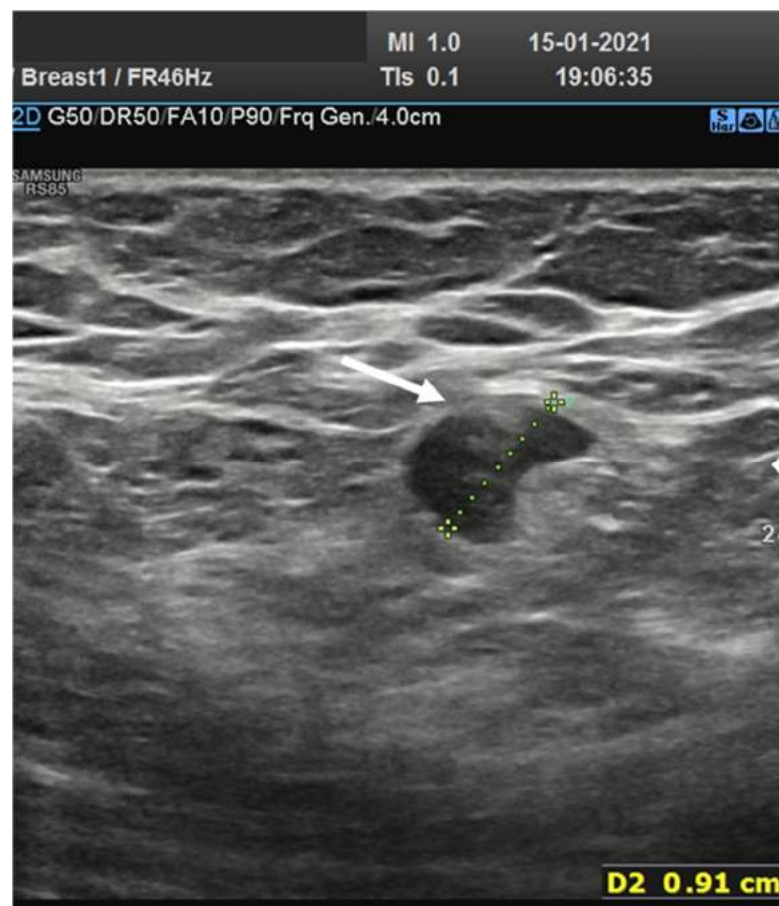In 10 patients (55.5%) they were in laterocervical side while 8 (44.5%) in the axillar site. The largest diameter was 16 mm with a range from 7 to 16 mm (median value = 10 mm). In the same patient we found different ultrasound nodal findings.

No anomaly was found on the Doppler echo-color study.

A total of 25 (43.1%) nodes showed eccentric cortical thickening with wide echogenic hilum and oval shape (Figures 1 and 2).

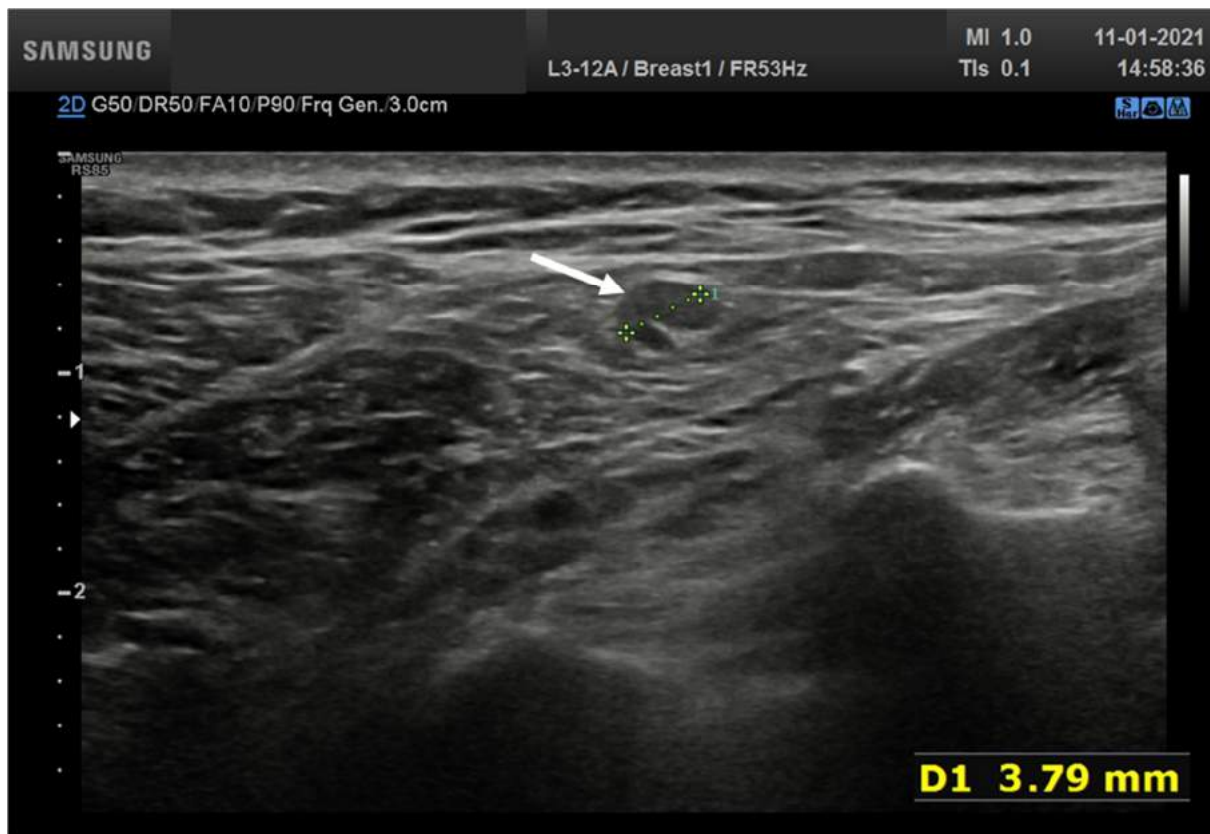


**Figure 1.** (a) Hypoechoic lymph node round shape without hilum (arrow) in laterocervical side; (b) axillary lymph node with concentric cortical thickening with reduction in the width of the echogenic hilum and oval shape.



**Figure 2.** Axillary lymph node with eccentric asymmetric cortical thickening with wide echogenic hilum and oval shape.

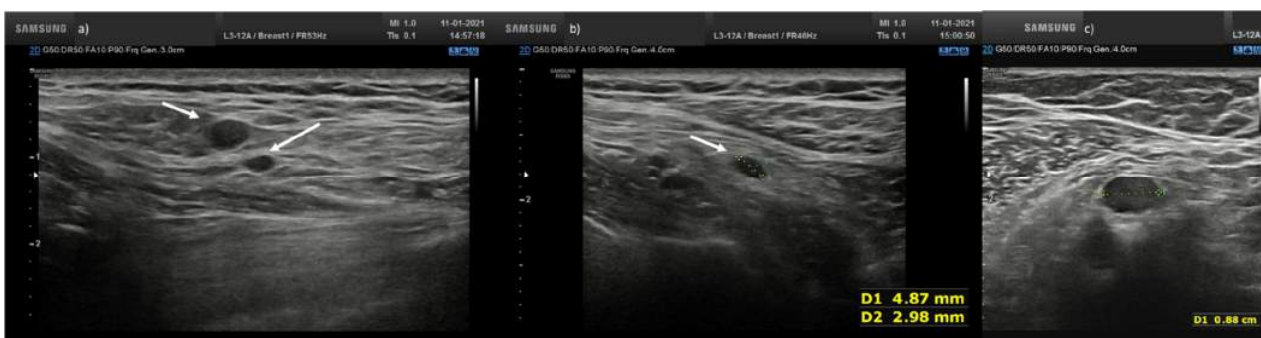
Overall, 19 nodes (32.8%) showed asymmetric eccentric cortical thickening with wide echogenic hilum and oval shape (Figure 3).



**Figure 3.** Lymph node (arrow) with asymmetric eccentric concentric cortical thickening in laterocervical side with reduction in the width of the echogenic hilum and oval shape.

A total of 10 nodes (17.2%) showed concentric cortical thickening with reduction in the width of the echogenic hilum and oval shape (Figure 1b).

In total, four nodes (6.9%) showed huge reduction and displacement of the echogenic hilum and round or oval shape (Figure 4).



**Figure 4.** (a) Hypoechoic lymph node round shape without hilum (arrows) in laterocervical side; (b) Hypoechoic lymph node oval shape without hilum (arrow) in laterocervical side; (c) Axillary small hypoechoic lymph node oval shape without hilum (arrow).

#### 4. Discussion

Recent results have revealed the efficiency of some imaging methods, including chest radiographs and chest computed tomography scans, in the management of COVID-19 disease [9–30]. Instead, at the best of our knowledge, this is the first paper describing the appearance of nodes after *BNT162b2* Covid-19 vaccine. Although the onset of lymphadenopathy after vaccine is known, Polack et al reported a frequency of only 0.3% [7].



However, we think that the date may be underestimated, in consideration of our sample size, although it is a representative population of a small community. Moreover, although in 10 patients the lymph nodes were painful, in four patients the data were an occasional finding diagnosed during a US examination performed for another reason.

US is commonly regarded as the imaging modality of choice in the assessment of palpable soft-tissue abnormalities. According to the appropriateness criteria of the American College of Radiology, US is “usually appropriate” to evaluate superficial or palpable soft-tissue masses, while magnetic resonance imaging (MRI) is “usually appropriate” in case of non-diagnostic initial US evaluation [31], while CT is appropriate for assessment of systemic diseases [32].

Lymph node cortical thickness and uniformity are the most important criteria for distinguishing between normal and abnormal nodes. Normal lymph nodes have a reniform shape, a uniformly hypoechoic cortex with a maximal thickness of 3 mm, smooth margins, and a central fatty hilum [33]. Findings of cortical thickness in excess of 3 mm, eccentric thickening, irregular margins, and encroachment on or displacement of the fatty hilum are suggestive of a pathologic process [33].

We found different US findings in the same patient; 43.1% of lymph nodes showed eccentric cortical thickening with wide echogenic hilum and oval, 32.8% of lymph nodes showed asymmetric eccentric cortical thickening with wide echogenic hilum and oval shape. A total of 17.2% of lymph nodes showed concentric cortical thickening with reduction in the width of the echogenic hilum and oval shape and 6.9% showed huge reduction and displacement of the echogenic hilum and round or oval shape.

We believe it is important to know and recognize these structural alterations, since as soon as the vaccine will be also available to non-healthcare personnel, it is important for a radiologist to be able to identify post-vaccine lymphadenopathy compared to lymphadenopathy for another cause, especially in cancer patients.

There are multiple limitations of this work. First of all, the small and spontaneous sample, consequently we did not know the real incidence of lymphadenopathy. Second, not having performed an elastosonographic and echocontrastographic examination; finally, the absence of a pathological correlation.

Future objective is an evaluation of the entire population of our institution undergoing vaccination for a correct estimate of the incidence and a more complex ultrasound analysis.

## 5. Conclusions

Eccentric cortical thickening with wide echogenic hilum and oval shape, asymmetric eccentric cortical thickening with wide echogenic hilum and oval shape, concentric cortical thickening with reduction in the width of the echogenic hilum and oval shape, and huge reduction and displacement of the echogenic hilum and round shape are the features that we found in post *BNT162b2* Covid-19 Vaccine lymphadenopathies.

**Author Contributions:** V.G. wrote the main manuscript text. S.V.S. prepared figures. V.G., R.F., S.V.S., R.G. (Roberta Galdiero), C.P., F.I., R.D., V.M., R.G. (Roberta Grassi), R.G. (Roberto Grassi), and A.P. performed the investigations and reviewed the manuscript. All authors have read and agreed to the published version of the manuscript.

**Funding:** This research received no external funding.

**Institutional Review Board Statement:** “National Cancer Institute of Naples Pascale Foundation” Institutional Review Institute (IRB) approved the study and renounced the written informed consent for this retrospective study, considering the ongoing epidemic emergency, which assessed the unidentified data and did not involve risks potential for patients.

**Informed Consent Statement:** Consent for publication was received.

**Acknowledgments:** The authors are grateful to Alessandra Trocino, librarian at the National Cancer Institute of Naples, Italy. Moreover, they are grateful to Assunta Zazzaro for the collaboration.

**Conflicts of Interest:** The authors declare no conflict of interest.

## References

1. Lake, M.A. What we know so far: COVID-19 current clinical knowledge and research. *Clin. Med.* **2020**, *20*, 124–127. [[CrossRef](#)]
2. World Health Organization (WHO). Available online: <https://www.who.int/emergencies/diseases/novel-coronavirus-2019/events-as-they-happen> (accessed on 21 January 2021).
3. Chaudhary, S.; Benzaquen, S.; Woo, J.G.; Rubinstein, J.; Matta, A.; Albano, J.; De Joy, R., III; Lo, K.B.; Patarroyo-Aponte, G. Clinical Characteristics, Respiratory Mechanics and Outcomes in Critically Ill Subjects with COVID-19 Infection in an Underserved Urban Population. *Respir. Care* **2021**. [[CrossRef](#)]
4. Zhou, S.; Xu, J.; Sun, W.; Zhang, J.; Zhang, F.; Zhao, X.; Wang, X.; Zhang, W.; Li, Y.; Ning, K.; et al. Clinical Features for Severely and Critically Ill Patients with COVID-19 in Shandong: A Retrospective Cohort Study. *Ther. Clin. Risk Manag.* **2021**, *17*, 9–21. [[CrossRef](#)]
5. Bagherzade, M.; Parham, M.; Zohali, S.; Molaei, S.; Vafaeimanesh, J. Plasmapheresis with corticosteroids and antiviral: A life-saving treatment for severe cases of Covid 19. *Caspian J. Intern. Med.* **2020**, *11*, 572–576. [[CrossRef](#)] [[PubMed](#)]
6. Baden, L.R.; El Sahly, H.M.; Essink, B.; Kotloff, K.; Frey, S.; Novak, R.; Diemert, D.; Spector, S.A.; Rouphael, N.; Creech, C.B.; et al. COVE Study Group. Efficacy and Safety of the mRNA-1273 SARS-CoV-2 Vaccine. *N. Engl. J. Med.* **2020**. [[CrossRef](#)]
7. Polack, F.P.; Thomas, S.J.; Kitchin, N.; Absalon, J.; Gurtman, A.; Lockhart, S.; Perez, J.L.; Pérez Marc, G.; Moreira, E.D.; Zerbini, C.; et al. C4591001 Clinical Trial Group. Safety and Efficacy of the BNT162b2 mRNA Covid-19 Vaccine. *N. Engl. J. Med.* **2020**, *383*, 2603–2615. [[CrossRef](#)]
8. Available online: <https://www.privacy-regulation.eu/en/> (accessed on 21 January 2021).
9. Carotti, M.; Salaffi, F.; Sarzi-Puttini, P.; Agostini, A.; Borgheresi, A.; Minorati, D.; Galli, M.; Marotto, D.; Giovagnoni, A. Chest CT features of coronavirus disease 2019 (COVID-19) pneumonia: Key points for radiologists. *Radiol. Med.* **2020**, *125*, 636–646. [[CrossRef](#)]
10. Shaw, B.; Daskareh, M.; Gholamrezanezhad, A. The lingering manifestations of COVID-19 during and after convalescence: Update on long-term pulmonary consequences of coronavirus disease 2019 (COVID-19). *Radiol. Med.* **2021**, *126*, 40–46. [[CrossRef](#)] [[PubMed](#)]
11. Belfiore, M.P.; Urraro, F.; Grassi, R.; Giacobbe, G.; Patelli, G.; Cappabianca, S.; Reginelli, A. Artificial intelligence to codify lung CT in Covid-19 patients. *Radiol. Med.* **2020**, *125*, 500–504. [[CrossRef](#)]
12. Borghesi, A.; Maroldi, R. COVID-19 outbreak in Italy: Experimental chest X-ray scoring system for quantifying and monitoring disease progression. *Radiol. Med.* **2020**, *125*, 509–513. [[CrossRef](#)] [[PubMed](#)]
13. Di Serafino, M.; Notaro, M.; Rea, G.; Iacobellis, F.; Delli Paoli, V.; Acampora, C.; Ianniello, S.; Brunese, L.; Romano, L.; Vallone, G. The lung ultrasound: Facts or artifacts? In the era of COVID-19 outbreak. *Radiol. Med.* **2020**, *125*, 738–753. [[CrossRef](#)]
14. Giovagnoni, A. Facing the COVID-19 emergency: We can and we do. *Radiol. Med.* **2020**, *125*, 337–338. [[CrossRef](#)] [[PubMed](#)]
15. Cozzi, D.; Albanesi, M.; Cavigli, E.; Moroni, C.; Bindi, A.; Luvarà, S.; Lucarini, S.; Busoni, S.; Mazzoni, L.N.; Miele, V. Chest X-ray in new Coronavirus Disease 2019 (COVID-19) infection: Findings and correlation with clinical outcome. *Radiol. Med.* **2020**, *125*, 730–737. [[CrossRef](#)]
16. Neri, E.; Miele, V.; Coppola, F.; Grassi, R. Use of CT and artificial intelligence in suspected or COVID-19 positive patients: Statement of the Italian Society of Medical and Interventional Radiology. *Radiol. Med.* **2020**, *125*, 505–508. [[CrossRef](#)] [[PubMed](#)]
17. Borghesi, A.; Zigliani, A.; Masciullo, R.; Golemi, S.; Maculotti, P.; Farina, D.; Maroldi, R. Radiographic severity index in COVID-19 pneumonia: Relationship to age and sex in 783 Italian patients. *Radiol. Med.* **2020**, *125*, 461–464. [[CrossRef](#)] [[PubMed](#)]
18. Gatti, M.; Calandri, M.; Barba, M.; Biondo, A.; Geninatti, C.; Gentile, S.; Greco, M.; Morrone, V.; Piatti, C.; Santonocito, A.; et al. Baseline chest X-ray in coronavirus disease 19 (COVID-19) patients: Association with clinical and laboratory data. *Radiol. Med.* **2020**, *125*, 1271–1279. [[CrossRef](#)] [[PubMed](#)]
19. Agostini, A.; Floridi, C.; Borgheresi, A.; Badaloni, M.; Esposto Pirani, P.; Terilli, F.; Ottaviani, L.; Giovagnoni, A. Proposal of a low-dose, long-pitch, dual-source chest CT protocol on third-generation dual-source CT using a tin filter for spectral shaping at 100 kVp for CoronaVirus Disease 2019 (COVID-19) patients: A feasibility study. *Radiol. Med.* **2020**, *125*, 365–373. [[CrossRef](#)]
20. Caruso, D.; Polici, M.; Zerunian, M.; Pucciarelli, F.; Polidori, T.; Guido, G.; Rucci, C.; Bracci, B.; Muscogiuri, E.; De Dominicis, C.; et al. Quantitative Chest CT analysis in discriminating COVID-19 from non-COVID-19 patients. *Radiol. Med.* **2021**, *126*, 243–249. [[CrossRef](#)]
21. Palmisano, A.; Scotti, G.M.; Ippolito, D.; Morelli, M.J.; Vignale, D.; Gandola, D.; Sironi, S.; De Cobelli, F.; Ferrante, L.; Spessot, M.; et al. Chest CT in the emergency department for suspected COVID-19 pneumonia. *Radiol. Med.* **2021**, *126*, 498–502. [[CrossRef](#)]
22. Grassi, R.; Belfiore, M.P.; Montanelli, A.; Patelli, G.; Urraro, F.; Giacobbe, G.; Fusco, R.; Granata, V.; Petrillo, A.; Sacco, P.; et al. COVID-19 pneumonia: Computer-aided quantification of healthy lung parenchyma, emphysema, ground glass and consolidation on chest computed tomography (CT). *Radiol. Med.* **2020**, *18*, 1–8. [[CrossRef](#)]
23. Cappabianca, S.; Fusco, R.; de Lisio, A.; Paura, C.; Clemente, A.; Gagliardi, G.; Lombardi, G.; Giacobbe, G.; Russo, G.M.; Belfiore, M.P.; et al. Correction to: Clinical and laboratory data, radiological structured report findings and quantitative evaluation of lung involvement on baseline chest CT in COVID-19 patients to predict prognosis. *Radiol. Med.* **2021**, *126*, 29–39. [[CrossRef](#)]
24. Giannitto, C.; Sposta, F.M.; Repici, A.; Vatteroni, G.; Casiraghi, E.; Casari, E.; Ferraroli, G.M.; Fugazza, A.; Sandri, M.T.; Chiti, A.; et al. Chest CT in patients with a moderate or high pretest probability of COVID-19 and negative swab. *Radiol. Med.* **2020**, *125*, 1260–1270. [[CrossRef](#)]

25. Lombardi, A.F.; Afsahi, A.M.; Gupta, A.; Gholamrezanezhad, A. Severe acute respiratory syndrome (SARS), Middle East respiratory syndrome (MERS), influenza, and COVID-19, beyond the lungs: A review article. *Radiol. Med.* **2020**, *26*, 1–9. [[CrossRef](#)]
26. Ierardi, A.M.; Wood, B.J.; Arrichiello, A.; Bottino, N.; Bracchi, L.; Forzenigo, L.; Andrisani, M.C.; Vespro, V.; Bonelli, C.; Amalou, A.; et al. Preparation of a radiology department in an Italian hospital dedicated to COVID-19 patients. *Radiol. Med.* **2020**, *125*, 894–901. [[CrossRef](#)] [[PubMed](#)]
27. Fichera, G.; Stramare, R.; De Conti, G.; Motta, R.; Girauda, C. It's not over until it's over: The chameleonic behavior of COVID-19 over a six-day period. *Radiol. Med.* **2020**, *125*, 514–516. [[CrossRef](#)]
28. Granata, V.; Fusco, R.; Izzo, F.; Venanzio Setola, S.; Coppola, M.; Grassi, R.; Reginelli, A.; Cappabianca, S.; Grassi, R.; Petrillo, A. Covid-19 infection in cancer patients: The management in a diagnostic unit. *Radiol. Oncol.* **2021**. [[CrossRef](#)]
29. Reginelli, A.; Grassi, R.; Feragalli, B.; Belfiore, M.P.; Montanelli, A.; Patelli, G.; La Porta, M.; Urraro, F.; Fusco, R.; Granata, V.; et al. Coronavirus Disease 2019 (COVID-19) in Italy: Double Reading of Chest CT Examination. *Biology* **2021**, *10*, 89. [[CrossRef](#)] [[PubMed](#)]
30. Grassi, R.; Fusco, R.; Belfiore, M.P.; Montanelli, A.; Patelli, G.; Urraro, F.; Petrillo, A.; Granata, V.; Sacco, P.; Mazzei, M.A.; et al. Coronavirus disease 2019 (COVID-19) in Italy: Features on chest computed tomography using a structured report system. *Sci. Rep.* **2020**, *10*, 17236, Erratum in *Sci. Rep.* **2021**, *11*, 4231. [[CrossRef](#)] [[PubMed](#)]
31. Kransdorf, M.J.; Murphey, M.D.; Wessell, D.E.; Cassidy, R.C.; Czuczman, G.J.; Demertzis, J.L.; Lenchik, L.; Motamedi, K.; Pierce, J.L.; Sharma, A.; et al. ACR appropriateness criteria<sup>®</sup> soft-tissue masses. *J. Am. Coll. Radiol.* **2018**, *15*, S189–S197. [[CrossRef](#)] [[PubMed](#)]
32. Cozzi, D.; Dini, C.; Mungai, F.; Puccini, B.; Rigacci, L.; Miele, V. Primary pulmonary lymphoma: Imaging findings in 30 cases. *Radiol. Med.* **2019**, *124*, 1262–1269. [[CrossRef](#)] [[PubMed](#)]
33. Net, J.M.; Mirpuri, T.M.; Plaza, M.J.; Escobar, C.A.; Whittington, E.E.; Collado-Mesa, F.; Yepes, M.M. Resident and fellow education feature: US evaluation of axillary lymph nodes. *Radiographics* **2014**, *34*, 1817–1818. [[CrossRef](#)] [[PubMed](#)]